

Byzantina Symmeikta

Vol 27 (2017)

BYZANTINA SYMMEIKTA 27



The Fall of Polystylon Fort to the Ottomans: The Historical Context and the Narrative of its decapitated Defender

Anagnostis AGELARAKIS

doi: [10.12681/byzsym.8928](https://doi.org/10.12681/byzsym.8928)

Copyright © 2017, Anagnostis AGELARAKIS



This work is licensed under a [Creative Commons Attribution-NonCommercial-ShareAlike 4.0](https://creativecommons.org/licenses/by-nc-sa/4.0/).

To cite this article:

AGELARAKIS, A. (2017). The Fall of Polystylon Fort to the Ottomans: The Historical Context and the Narrative of its decapitated Defender. *Byzantina Symmeikta*, 27, 11–52. <https://doi.org/10.12681/byzsym.8928>

INSTITUTE OF HISTORICAL RESEARCH
SECTION OF BYZANTINE RESEARCH
NATIONAL HELLENIC RESEARCH FOUNDATION



ΙΝΣΤΙΤΟΥΤΟ ΙΣΤΟΡΙΚΩΝ ΕΡΕΥΝΩΝ
ΤΟΜΕΑΣ ΒΥΖΑΝΤΙΝΩΝ ΕΡΕΥΝΩΝ
ΕΘΝΙΚΟ ΙΔΡΥΜΑ ΕΡΕΥΝΩΝ



BYZANTINA ΣΥΜΜΕΙΚΤΑ

BYZANTINA SYMMEIKTA

ANAGNOSTIS AGELARAKIS

THE FALL OF POLYSTYLON FORT TO THE OTTOMANS:
THE HISTORICAL CONTEXT AND THE NARRATIVE
OF ITS DECAPITATED DEFENDER

ΑΘΗΝΑ • 2017 • ATHENS

THE FALL OF POLYSTYLON FORT TO THE OTTOMANS: THE HISTORICAL
CONTEXT AND THE NARRATIVE OF ITS DECAPITATED DEFENDER

Prelude

There was not to be any forthcoming succor to the siege of Polystylon fort at the Aegean shores of western Thrace¹. During the tumultuous years following the most destructive Byzantine dynastic civil wars between Andronikoi II and III², and later between John VI Kantakouzenos³ and the self-proclaimed

1. During the Late Byzantine period Polystylon continued to operate in the Aegean shorelines of western Thrace both as a fort, *φρούριον*, according to Gregoras, *Roman History* (ed. L. SCHOPEN – I. BEKKER, v. I-III [CSHB, Bonn 1829-55]), XII. 16: v. II, 626 [hereafter Gregoras, *Roman History*]: relative excerpt: *διὰ δὴ ταῦτα καὶ ἄσμενος, τὴν Διδυμοτείχου ἐπιτροπὴν παραδοὺς Εἰρήνῃ τῇ συζύγῳ καὶ βασιλίδι σὺν τὰδελεφῶ Μανουὴλ τῷ Ἀσάν, ἀφίκετ' εὐθὺς καὶ ὠχύρον τὸ φρούριον, ὃ Πολύστυλον ὀνομαζόμενον πάλαι πρὸς θάλατταν νῦν αὐτὸς ἐξ οἰκείας δαπάνης συνεστήσατο παρὰ τὰς τοῦ Νέστου ἐκβολάς,* and a functional harbor of a coastal village described as *πολίχιον παράλιον* according to John VI Kantakouzenos, cf. Cantacuzenus, *Histories* (ed. L. SCHOPEN, *Ioannis Cantacuzeni eximperatoris Historiarum Libri IV*, v. I-III [CSHB, Bonn 1828-1832], III. 37: v. II, 226 [hereafter: Cantacuzenus, *Histories*].

2. During 1321-1322, and 1327-1328, between the Andronikoi II and III, with destructive effects afforded on the land, population and state resources, cf. Cantacuzenus, *Histories*, I.28: v. I, 137-138, and further between John VI Kantakouzenos and the self-proclaimed regency of John V Palaiologos between 1341-1347, cf. Gregoras, *Roman History*, XV. 1: v. II. 747-748.

3. D. M. NICOL, *The Byzantine family of Kantakouzenos (Cantacuzenus) ca. 1100-1460: A genealogical and prosopographical study*, Dumbarton Oaks, Washington, DC 1968, 35ff [hereafter NICOL, *Family of Kantakouzenos*], 35-103. *PLP*, n. 10973.

regency⁴ of John V Palaiologos, Emperor John VI Kantakouzenos had abnegated the throne in 1354⁵, in favor of his son co-Emperor Matthew Kantakouzenos, who in turn was dethroned in 1357, by Emperor John V Palaiologos⁶ (Emperor Andronikos III' son). Meanwhile the remnants of the Byzantine Empire were in an alienated⁷ and ruinous state⁸, imminently threatened by the intrusions of the Bulgars⁹, the invasion of the Serbian state¹⁰, and the incursions in imperial lands of Karasi emirate razzias¹¹. The Ottomans, previously implicated into the belligerent Byzantine matters¹², were already established by stratagem in 1352 at the stronghold of Tzymbé on the shores of the Dardanelles; under the leadership of Orhan's¹³ son

4. Empress Anna of Savoy (wife of Andronikos III), the Patriarch of Konstantinople John XIV Kalekas, and Megas Doux Alexios Apokaukos (who had risen in hierarchy only through the support of John VI Kantakouzenos), cf. D. M. NICOL, *The Last Centuries of Byzantium, 1261-1453*, Cambridge Univ. Press, 2002, 185-188, 253ff.

5. D. M. NICOL, The Abdication of John VI Cantacuzene, *BF* 2 (1967) [=Polychordia. *Festschrift F. Dölger*], 275-279 [=IDEM, *Collected Studies II. Studies in Late Byzantine History and Prosopography*, London 1986, n. VI].

6. Son in law to Emperor John VI Kantakouzenos, through marriage to his daughter Helena [*PLP*, n. 21365], cf. A. LUTTRELL, John V's Daughters: A Palaiologan Puzzle, *DOP* 40 (1986), 103-112. Further, one of their daughters, most probably Eirene [*PLP*, n. 21352], was betrothed (or wedded but of an unconsummated marriage) to Orhan's son Halil, cf. NICOL, *Family of Kantakouzenos*, 134-135, and footnote 4; LUTTRELL, John V's Daughters, 103.

7. During the civil war of 1341-47 there had also been significant social strife and alienation between the aristocracy and the *μέσοι* with significant economic consequences, cf. A. E. LAIOU – C. MORRISSON, *The Byzantine Economy*, New York 2007, 195-200.

8. In addition to civil strife, there were matters of religious disparity, and the ravaging effects of the plague, cf. NICOL, *Last Centuries*.

9. NICOL, *Last Centuries*, 168-169.

10. See in general G. Ch. SOULIS, *The Serbs and Byzantium during the reign of Tsar Stephen Dušan (1331-1355) and his successors*, Dumbarton Oaks, Washington, DC, 1984 [2nd edition Athens 1995].

11. E. ZACHARIADOU, The Emirate of Karasi and that of the Ottomans: Two Rival States, in: *The Ottoman Emirate (1300-1389)*, ed. EADEM [Institute for Mediterranean Studies, Halcyon Days in Crete I, University of Crete Press, Rethymnon 1993], 225-236.

12. As allies to Kantakouzenos against the self-proclaimed triumvir regency (they had blatantly violated Emperor Andronikos III' terms whereby he had entrusted his young son John V Palaiologos to the care of his dear friend and Grand Domestic, Regent, John Kantakouzenos) on behalf of the adolescent John V Palaiologos.

13. Emir Orhan of Bithynia, son of Osman, had solicited the hand and subsequently

Süleyman Pasha, decidedly taking immediate advantage of the earthquake effects of 1354, had initiated their rapidly expanding conquests in Thrace¹⁴.

On Matters of the Historical and Archaeological-Anthropological Records

Having crossed the Dardanelles to Thrace with Süleyman Pasha, marching warrior-lord Gāzī¹⁵ Evrenos (Εβρενός) Bey¹⁶ of a Christian family of warriors in north-western Asia Minor that had converted to Islam¹⁷, had conquered the city of Komotini by 1361. Further expanding the westward frontiers of

married Emperor John VI Kantakouzenos' daughter Theodora [PLP, n. 10940], in 1346, soon after the latter's coronation in Adrianople, cf. Gregoras, *Roman History*, XV. 5, v. II, 762-763; Cantacuzenus, *Histories*, III.95: v. II. 585-589; Doukas, *Historia Turco-Bizantina (1341-1462)*, ed. V. GRECU, Bucharest 1958, 57-61. Hence, Emperor John VI Kantakouzenos was father in law of both Emir Orhan, and Emperor John V Palaiologos.

14. N. OIKONOMIDES, From Soldiers of Fortune to Gazi Warriors: The Tzympe Affair, in: *Studies in Ottoman History in Honour of Professor V.L. Ménage*, eds. C. HEYWOOD – C. IMBER, Istanbul 1994, 239-247 [= ID., *Society, Culture and Politics in Byzantium* (Variorum Collected Studies Series: CS 824), XX.

15. A warrior or raider for the faith, or one that carries holy war against the infidels, cf. I. COLIN, What Does *Ghazi* Actually Mean?, in: *The Balance of Truth: Essays in Honour of Professor Geoffrey Lewis*, eds. C. BALIM-HARDING – C. IMBER, Istanbul 2000, 165-178. C. FINKEL, *Osman's Dream: The History of the Ottoman Empire 1300-1923*, London 2005, 10 [hereafter: FINKEL, *Osman's Dream*]. By the way of inscriptions Orhan is the first of the Ottoman rulers to be mentioned, since the 1330s, as "Sultan of the Gazis": FINKEL, *Osman's Dream*, 10; cf. C. KAFADAR, *Between Two Worlds. The Construction of the Ottoman State*, Berkeley 1995, 76.

16. One of the most famous marcher-warrior lords, allied yet quasi-independent from the Ottomans, fought for the conquest of "Rumeli". At Komotini as his base in Thrace he erected some of the earliest Muslim buildings in the region to accommodate the needs of the faith warriors, cf. FINKEL, *Osman's Dream*, 9, 19; H. W. LOWRY, *The Nature of the Early Ottoman State*, Albany 2003, 58-66; M. KIEL, Observations on the History of Northern Greece during the Turkish Rule, Historical and Architectural Description of the Turkish Monuments of Komotini and Serres, their Place in the Development of Turkish Ottoman Architecture, and their Present Condition, in: ID., *Studies of the Ottoman Architecture of the Balkans*, Hampshire 1990, III. 426-428 [First published in *Balkan Studies* 12 (1971), 415-444]; ID., The Oldest Monuments of Ottoman – Turkish Architecture in the Balkans, in ID., *Studies on the Ottoman Architecture ...*, XIV. 127-133 [First publ. in *Sanat Tarihi Yilligi* 12 (1983), 117-138]. Cf. PLP, n. 5955.

17. The family of Evrenogullari (sons of Evrenos), cf. FINKEL, *Osman's Dream*, 19; I. MÉLIKOFF, art. Ewrenos Oghullari, *EI*², 720-721.

the perseveringly budding Ottoman state he had conquered during the second half of the 1360s the urban centers of Peritheórion, Xántheia, and Maróneia; cities that were immediately peripheral to Polystylon. Conterminous were the advances and possessions of Ottoman Turk forces in Didymoteichon and Adrianoupolis, successfully pre-paved by Súleyman Pasha and following his accidental death in 1357 under the leadership of his brother Murad¹⁸, as the commander in chief in Thrace¹⁹. Consequently, following the marcher-lord conquests on behalf of the Ottomans in their immediate region, the Romans (Byzantines) at Polystylon had been under a cloud of blockade. They were restricted from the grids of communications with their peripheral urban centers, in what was perceptibly steadily and ominously devolving to a grievous and un-sustaining surrounding by the countryside²⁰, while from the seaward-winds, foaming the piracy infested waves, there was no relief from western Christian ships in the horizon²¹. Yet Polystylon must have served, by

18. On the case that Sultan Murad married a daughter of Emperor John V Palaiologos in 1389, cf. NICOL, *Family of Kantakouzenos*, 134-135; LUTTRELL, *John V's Daughters*, 103.

19. cf. FINKEL, *Osman's Dream*, 17.

20. Since the initial waves of Turcoman fighters, *gāzīs*, *dervishes* (Muslim holy men of Turco-Islamic culture who supported and fought with the marching warriors), the invasion of *yoruks*, and the raids of the *akincis* (for the latter cf. Mihailović, *Konstantin, Memoirs of a Janissary*, ed. S. SOUCEK, Translated by B. STOLZ, Princeton 2011, 42, 89-91 [hereafter *Mihailović, Memoirs*]; cf. C. G. LIAKOPOULOS, *The Ottoman Conquest of Thrace: Aspects of Historical Geography* (Bilkent University, Ankara 2002), 56, and 87 [<http://hdl.handle.net/11693/29189>]; as a comparative reference for the gruesome intent of polluting a besieged stronghold with the blood of fallen soldiers, their putrefied bodies, and the odor of their cremation cf. Nestor-Iskander, *The Tale of Constantinople (Of Its Origin and Capture by the Turks in the Year 1453)*. Translated and Annotated by W. K. HANAK – M. PHILIPIDES, New Rochelle 1998, 30. 47 [hereafter Nestor-Iskander]; cf. also the new edition of the Russian Text with a Spanish translation: *Néstor Iskándér Relato sobre la toma de Constantinopla*. Estudio preliminar, traducción y notas de M. C. OLEA [Fuentes y documentos 2], Granada 2003, 59 [hereafter: *Relato*]; for archaeometrically derived dietary intake analyses of the *Polystylites* during this Late Byzantine period cf. A. P. AGELARAKIS – A. AGELARAKIS, *Abdera/ Polystylon: A Byzantine Town in Western Thrace in the Context of Historical Developments during the 6th – 14th Centuries as Depicted by its Archaeo-Anthropological Record*, *ByzSym* 25 (2015), 35, 39 [hereafter: AGELARAKIS – AGELARAKIS *Abdera/ Polystylon*].

21. As a comparative reference to allied aid provided during the siege of Constantinople cf. *Giorgio Sfranze, Cronaca* (ed. R. MAISANO [CFHB 20]), 140-142 [hereafter *Sfranze, Cronaca*]; cf. *The Fall of the Byzantine Empire: A Chronicle by George Sphrantzes 1401-1477*.

means of its enduring persistence, as the local refuge fort (*φορούριον*) and of what had remained of the regional *κατεπανίκιον*²².

Whereas historical references addressing specific details on Polystylon under siege (either by the earlier arrival of Turkic hordes in Thrace²³ or during the subsequent more systematic arrival of Ottoman military forces in “*Rumeli*”) are missing, relative historical recordings specific to the regional locality and data derived from the combined archaeological and anthropological records of the coeval component of the site’s contexts and cemetery²⁴ (Figure 1), provide elucidating particulars on the narrative of the final years of the fort. The folks and *πάροικοι* of Polystylon, as a premise of what their forbearers and elders had resolved in a multitude of occasions²⁵ sought refuge and reassurance behind the strong walls of the fort²⁶. Their auxiliary militia efforts²⁷ augmented the garrison force²⁸, the

Translated by M. PHILIPIDES, University of Massachusetts Press, Amherst, 1980, § XXXVI, 71-74 [hereafter *Sphrantzes The Fall of the Byzantine Empire*].

22. A “Κατεπανᾶτον”, or “Κατεπανίκιον” was governed by a “Κατεπάνω”, “Ἄρχων”, or “Κεφαλή”, cf. L. ΜΑΚΣΙΜΟΒΙĆ, *The Byzantine Provincial Administration under the Palaiologoi*, Amsterdam 1988, 70-83.

23. Turks that had remained in Thrace since their coalition with the Catalan pillaging, and then by reason of the second civil war (1341-54), they were making a living “... as mere bandit groups ...” raiding the Byzantines under the exercise of “holy war” against the Christians, cf. ΛΙΑΚΟΠΟΥΛΟΣ, *The Ottoman Conquest*, 56.

24. In the context of relative diachronic records spanning from the Early to the Late Byzantine periods’ sites and cemeteries of Abdera/Polystylon.

25. AGELARAKIS – AGELARAKIS, Abdera/ Polystylon, 33-39.

26. The *Polystylites* and the fort had benefited significantly from Kantakouzenos’ efforts. In 1342 he supplied the population and the fort with wheat provisions, redoubling the stronghold and stationing soldiers to assist in military matters and defense operations, cf. AGELARAKIS – AGELARAKIS, Abdera/ Polystylon, 25, footnote 40.

27. Cf. Thomas Magistros, *Λόγος περὶ πολιτείας*, ed. J. P. MIGNÉ, *PG* 145, cols. 495-548. M. BARTUSIS, Urban Guard Service in Late Byzantium: The Terminology of the Institution, *Macedonian Studies* 5 (1988), n.s. 2, 52-77; cf. AGELARAKIS – AGELARAKIS, Abdera/ Polystylon, 35.

28. During times of war the membership of the force would have included irregulars and *φύλακες* (guards) from the civilian *Polystylites*, along with *στρατιῶται* (soldiers), *τοξόται* (archers), *τζαγκαρότορες* (crossbow men), and a number of cavalry (*ἵππεῖς*) under a seasoned commander. For a relative discussion cf. M. BARTUSIS, *The Late Byzantine Army: Arms and Society, 1204-1453*, University of Pennsylvania Press 1992, 270-321.

sons of any *προνοιάριοι*²⁹ dutiful to their inheritable obligations³⁰, and any militia and military men who had fled from the conquered regional cities³¹. In their *intra muros* aggregate, through intergenerational wisdom, the vivid narratives of the local elders and experience of any present *προκαθήμενοι* and *καστροφύλαξ*³², as well as the relatively constant mode of *vi et armis*, they had implemented buffer mechanisms and strategies to provide for coping abilities with occasional *ab extra*, and intramural dietary resource procurement³³.

Polystylon³⁴ fort, with the fortification repairs and military preparations

29. Gregoras recorded that Kantakouzenos reassessed and redistributed *πρόνοιαι*, in 1341, to the entire soldiery, cf. Gregoras, *Roman History*, XII. 6: v. II, 595. Given that Polystylon had benefited by taking Kantakouzenos' side during the civil war against the self-proclaimed regency of John V Palaiologos (see footnotes 4, and 12, supra), it is suggested that although there could have been a number of pronoiars established in the locality before 1341, they would have been established after the *πρόνοιαι* redistribution of 1341.

30. Transferable by imperial privilege regarding pronoiar soldiers and/or of communally held *πρόνοιαι* cf. N. ΟΙΚΟΝΟΜΙΔΗΣ, A propos des armées des premiers Paléologues et des compagnies de soldats, *TM* 8 (1981), 368-369 [=Id., *Society, Culture and Politics in Byzantium* (as in n. 14), XVI].

31. Also considering the possibilities that a number of civilians, delegates, and even people of the cloth could have fled from the peripheral urban centers seeking refuge at the fort; some of them anticipating a seaward escape.

32. Cf. BARTUSIS, *The Late Byzantine Army*, 313-314.

33. Cf. AGELARAKIS - AGELARAKIS, Abdera/ Polystylon, 34, 39, footnote 63.

34. CH. ΒΑΚΙΡΤΖΙΣ, Western Thrace in the Early Christian and Byzantine Periods: Results of Archaeological Research and the Prospects, 1973-1987, *BF* 14/1 (1989) [=First International Symposium for Thracian Studies "Byzantine Thrace". *Image and Character*, Komotini, May 28th-31st 1987], 41-58; cf. P. ΓΕΩΡΓΑΝΤΖΙΣ, Η ἐκκλησιαστική ὀργάνωση καὶ διοίκηση τῆς Δ. Θράκης κατὰ τὴ Βυζαντινὴ ἐποχὴ, *BF* 14/1 (1989), 204-205 (and particularly the explanatory footnotes *ibid.* 28, 29, 30, and 31). CH. ΒΑΚΙΡΤΖΙΣ, Ανασκαφή Πολύστυλου Αβδήρων, *ΠΑΕ* (Athens, 1982), 18-26; ID., Ανασκαφή Πολύστυλου Αβδήρων, *ΠΑΕ* (Athens, 1983), 13-19; ID., "Byzantine Thrace", in V. ΠΑΠΟΥΛΙΑ - Μ. ΜΕΡΑΚΛΙΣ - CH. ΣΥΜΕΟΝΙΔΗΣ - TH. ΚΟΡΡΕΣ - P. ΧΗΔΙΡΟΓΛΟΥ (eds.), *Thrace*, Komotini 1994, 158-162; CH. ΒΑΚΙΡΤΖΙΣ - N. ΖΕΚΟΣ, Ανασκαφή Πολύστυλου Αβδήρων, *ΠΑΕ* (Athens, 1984), 12-17; A. P. AGELARAKIS - A. AGELARAKIS, The Palaeopathological Evidence at Polystylon Abdera, Greece, *BF* 14/1 (1989), 9-26; A. P. AGELARAKIS, Archaeological Reconstructions of the Late Byzantine Polystylon Population, Research and Exploration, *National Geographic Society* 8(1) [1992], 119; ID., Excavations at Polystylon (Abdera): Aspects of Mortuary Practices and Skeletal Biology, *ΑΔ* 47-48 [1992-1993], (1997), 293-308; A. P. AGELARAKIS - CH. ΒΑΚΙΡΤΖΙΣ, Cemeteries at Polystylon (Abdera), On Burial Customs and Practices in the Rhodopes, *Rhodopica*, 1998/1, 57-67.

in order³⁵, was strategically positioned on the acropolis hill of ancient Abdera³⁶, outfitted to offer the structural integrity of a stronghold to the collective force of defenders and refuge seekers. Aspects of the circumstances experienced during the upheaval of the Late Byzantine period at Polystylon may be gleaned not only from coeval historical narratives describing the violent conquest of Byzantine lands, but as importantly through analyses of the skeletal population interred at its intra-mural cemetery site. Dietary evaluations through stable isotopic analysis revealed an unprecedented in diachronic scale, since the foundation of Abdera in the 7th c. BC, decrease in terrestrial animal protein intake, reduced to the lowest measure of dietary contribution of just 8.0%, also uniquely lacking any protein intake with isotopic signs of foods drawn from the littoral zone of the fort. Similarly, C3 pathway photosynthesizing plants, like wheat and barley, revealed the lowest intake level since the 7th c. BC, while hardier C4 pathway photosynthesizing plants reached the most significant intake, at 41% of consumption³⁷.

Regarding a number of demographic dynamics during the last occupation phase of Polystylon, an ominous mortality predominance at 62.5% of the population sample had affected the young individuals, the vast majority of whom had ranged within the cohorts of the later *terminus* (ca. 4.0-5.5 years) of the Infancy I³⁸ and of the later Infancy II³⁹ age subgroup

35. See footnote 26, supra.

36. Herodotus, I. 168, ed. C. HUDE, *Herodoti Historiae*, Oxford³ 1927; Aelian, *Varia Historia* 12.9 [Loeb Classical Library - 486], ed.-transl. N. G. WILSON, Harvard University Press, Cambridge Massachusetts, 1997, 360; Cf. A. AGELARAKIS, Klazomenians of Three Continents: Emphasis of the 7th c. BC, in: *NOSTOI. Indigenous Culture, Migration and Integration in the Aegean Islands and Western Anatolia during the Late Bronze and Early Iron Age*. Eds.: N. STAMPOLIDIS - Ç. MANER - K. KOPANIAS, Istanbul: Koç University Press 2015, 923-985; ID., The Clazomenian Colonization Endeavor at Abdera in Retrospect: Evidence from the Anthropological Record, in: A. MOUSTAKA - E. SKARLATIDOU - M.-C. TZANNES - Y. ERSOY (eds.), *Klazomenai, Teos and Abdera: Metropoleis and Colony, Proceedings of International Symposium*, Thessaloniki 2004, 327-349; ID., On the Clazomenian Quest in Thrace during the 7th and 6th centuries BC, as revealed through Anthropological Archaeology, *Εὐλιμένη* 2 (2001), 161-186.

37. AGELARAKIS - AGELARAKIS, Abdera/ Polystylon, 15, 34-35, footnote 65, figure 12.

38. Infancy I ranges from Birth to 6.0 years of age.

39. Infancy II ranges from 6.01 to 12.0 years of age.

years (ca. 8.0-11.0 years). Adult⁴⁰ male individuals, who had ranged between 18 to 50 years, followed with 33.33% prevalence at the mortality curve; they were trailed, divergently among all earlier occupation phases at Polystylon/Abdera, by a single adult individual representing the female cohort⁴¹. Adult male individuals included a good number of veterans and seasoned combatants, based on forensic anthropological analyses of their skeletal remains. Evidentiary lines were provided by skeletomuscular changes and relative markers of stress, as well as palaeopathological assessments on the nature, type, and significant observation ratio of healed, healing, and *perimortem* skeletal trauma impacts⁴². Furthermore, a considerable membership of the *Polystylite* and fort defenders' population sample comprised closely knit kinship relationships as revealed by skeleto-anatomic morphometric and epigenetic non-metric trait studies⁴³. An overwhelming ratio of observed prevalence was particularly disclosed among the Infancy I and Infancy II age cohort individuals with a focus on the dental expression variables of the Carabelli's trait. This indicated that the young cohort of the *Polystylite* population sample, during the last phase of its occupation,

40. "Adults" combines in this context three separate age subgroups: 1) Young Adults (18.0-25.0 years), 2) Middle Adults (25.01 to 35.0 years), and Late Adults (35.01 to 45.0 years).

41. Only an adult female was identified, interred at the Late Byzantine cemetery, a unique case of intra-population sample dynamics compared with all cemeteries and burial grounds of earlier Byzantine and pre-Byzantine periods at Polystylon/Abdera reaching to the 7th c. BC. Although the potentiality is considered that females could have attainably sustained a better survivorship score compared to males, the study of the previous phase of occupation at Polystylon clearly indicated through biometric and palaeopathological analyses, parameters of severe morbidity and comorbidity which had resulted to a significant attrition within their cohorts, affording consequences to the dynamics of female prevalence in the composition of immediate future generations, cf. AGELARAKIS - AGELARAKIS, *Abdera/Polystylon*, 19-22, 26-27. The possible action is also considered that a female or number of females could have been evacuated to "safer" places contemplating the imminent danger of capture and abduction by the marauding invaders and/or enslavement in case of the fall of the fort; reminiscent of similar precautions that had to be taken by a directive that had been issued by Emperor Andronikos II «to evacuate people in the endoplains and to repair-fortify the towns», cf. G. Pachymeres, *Historical Relations* (ed. A. FAILLER, *Georges Pachymeres Relations Historiques*, v. 1-5 [CFHB 24/1-5], Paris 1984-2001), VII.37: v. III.121.

42. AGELARAKIS - AGELARAKIS, *Abdera/Polystylon*, 27, 41-42.

43. AGELARAKIS - AGELARAKIS, *Abdera/Polystylon*, 27-28, 41-42, footnote 47.

presented expressed epigenetic discrete traits as a result of gene reshuffling of a nearly endogamous population affected by isolationism⁴⁴.

Hence, traces revealing of significant bonds of affinity epitomized by interwoven blood relations, along with the high level of shared social knowledge, as it usually exists within tightly woven communities, the power of trust and loyalty in their lengthy interactions, the experience of cooperation and coherency⁴⁵ in the midst of a shattered and atrocious milieu must have had catalytically solidified the spirit and determination of the defenders' resolve in their engagement against the archenemy forces. The important elements of firmness of purpose, the warm fellowship, and comradeship of the Polystylites, a *modus vivendi* tested and honed through generations of recurrent adversities and hardships, contributed significantly to the leadership resolve of the seasoned military commander of the fort, sustaining and emboldening the uniquely long lasting resistance of Polystylon in the assaulting attempts by waves of outlandish invaders⁴⁶; the latter were exhilarated and encouraged by the *dervishes* to press on the fight with the promise of land properties and possessions, as well as booty allotments at the defeat of the besieged Byzantines⁴⁷. Repelled at their advances against the fort however, they would have retracted and would not have likely made "...another attempt for a long time"⁴⁸; particularly as the surrounding fertile

44. Along other provincial socio-cultural norms, safety matters, and economical reasons such as patrilocal tendencies of the villagers, private land owners (*οικοδεσπότες*), and *προνοιάρχιοι* for the preservation of homestead holdings, constraining pressures restricting the range of movement of the Byzantines must have abruptly intensified by the incursions of the invaders and the capture of all peripheral urban centers particularly since 1361.

45. Able to operate as a closed network to efficiently resolve emerging problems while having an expert local knowledge of the advantages and weaknesses of their situation

46. Without excluding the probability that Christian renegades, converts to Islam, and/or alienated Byzantines could have joined the Ottoman lot in its immediate needs of a rapidly expanding state, cf. LOWRY, *The Nature of the Early Ottoman State* [as in n. 16], 57, 95-96, 102; Apropos, Gāzī Evrenos Bey's early system of the youth-levy for military service is thought to had taken place in the 1380s, cf. V. DEMETRIADES, Some Thoughts on the Origins of the Devşirme, in *The Ottoman Emirate (1300-1389)* [as in n. 11], 23-31.

47. Cf. FINKEL, *Osman's Dream* [as in n. 16], 9.

48. Cf. *Mihailović, Memoirs*, 43. 94 (offered as a means of comparison from a relatively coeval component).

lands between the plains of Polystylon region and Xantheia⁴⁹ could have been distributed accordingly among the Osmanlis for settlement and dividends of tax-levy from the conquered populations of the peripheral cities, from both owners (*οικοδεσπότες* and *προνοιάριοι*) and tenants (*πάροικοι* and *περσίοικοι*), without necessarily the fall of the fort. This however, could inherently involve the lingering threat of opportune punitive skirmishes by the fort's mounted militia within a certain radius from Polystylon⁵⁰.

Delimited by the actions and spatial limitations imposed by the conquerors in the regional locality it appears that the defenders of Polystylon continued to sternly defy subjugation by the imposing and increasingly truncating presence of the Turks that had successively trespassed their environs of old. Thus, resisting the plundering and pillaging pursuits of the invaders⁵¹, the confiscation of their landed properties and valuable possessions, the abduction and enslavement of captured Byzantines⁵², matters of record which were recently admitted through historical research by a number of scholars as the *raison d'être* of the conquest⁵³, the Polystylites were rejecting to concede to the predatory realities of territorial expansion fueled by opportune and expendable coalitions between Muslims and some apostate Christians, under the machinations of the emerging Ottoman "Realpolitik"⁵⁴. Thus, defying bondage and the denigration to the status of

49. The specific cohesion and exertion of elements of resolve, mentioned above, which must have predominated at Polystylon, comprised most critical strategy framework against the enemy. Such conditions however would have been remarkably challenging to sustain within the context of survivorship requirements of a much larger and more open membership network in the urban centers in the immediate region of Polystylon.

50. A new center emerged in the region, the Ottoman settlement of Yenisea, located about an hour's horse ride due north from Polystylon, at the center of the plains of Xanthe, cf. AGELARAKIS - AGELARAKIS, *Abdera/ Polystylon*, 24, footnote 36.

51. FINKEL, *Osman's Dream*, 10, 15; cf. LOWRY, *The Nature of the Early Ottoman State*, 57, 95-96, 102.

52. *Mihailović, Memoirs*, 47. 96-97.

53. FINKEL, *Osman's Dream*, 10, 15; cf. LOWRY, *The Nature of the Early Ottoman State*, 57, 95-96, 102.

54. For example: 1) omitting from their early state chronicles that Orhan was not only allied but also married with the Byzantine royal bloodline; and 2) in their alliances with Christian warrior lords they had subdued and annexed the lands of their Muslim neighbors in Asia Minor such as that of the Karesi emirate, cf. FINKEL, *Osman's Dream*, 15-16.

re'aya, it clearly appears that the Polystylites must have instead reckoned to stand in resistance, truthful to their ancestors and the legacy of their land-lordship, seemingly with no exit strategy; particularly it is suggested following the exchange of hostilities⁵⁵ with the enemy since the early junctures of the successful defense of the fort.

Along with marching warrior-lord Gāzī Evrenos Bey there was another important marcher warrior-lord family of Christian origin from north-western Asia Minor, the Mihaloğullari⁵⁶, at the conquest vanguard in Thrace, initially with commander in chief Süleyman Pasha and subsequently with Murad. Following Orhan's death in 1362, Sultan Murad continued to spearhead successful conquests and territorial annexations occupying much of the southern Thracian region, and having defeated the combined forces of the Serbian and Bulgarian lords at the battle of Çirmen in 1371, in the region of the river Maritsa west of Adrianoupolis (Turkified to Edirne)⁵⁷, he pre-paved the conditions for the Ottoman expansion in Macedonia.

Following the combined revolts against their fathers and the consequent execution of Savci, as well as the imprisonment and blinding of Andronikos, respectively the sons of Sultan Murad and Emperor John V Palaiologos⁵⁸ in 1373, Manuel, the younger son of Emperor John V Palaiologos escaped to Thessaloniki⁵⁹ for fear of his life after the strife between Emperor John V Palaiologos and his son Andronikos had been resolved in 1381; and particularly since the latter's son, John, was slated as the successor to the Byzantine throne. Once in Thessaloniki, Manuel ruled to initiate operations

55. Having created an unforgettable and unforgiving precedent comprising wounded and killed comrades on both sides, blasphemies, curses, threats, and hatred.

56. The sons of Köse-Mihal (Mihal the «Beardless»), an important dynasty with significant land holdings in Thrace from the early years of Ottoman territorial expansion in «Rumeli». The patriarch of the family was lord of Harman-Kaya, and friend to Osman, having also saved the life of the latter, tradition has it, from a plot against his (Osman's) life in 1298, at the wedding ceremony of the Greek lord of Bilecik who was about to marry the daughter of the Greek lord of Yarhisar named Nilüfer; she became the wife of Orhan, cf. *Mihailović, Memoirs*, 9. 16-17, footnote 3, 10. 18, and footnote 1; cf. also FINKEL, *Osman's Dream*, 19, 75.

57. FINKEL, *Osman's Dream*, 18.

58. He had to acknowledge Ottoman suzerainty and hence became Sultan Murad's vassal.

59. Cf. CH. BAKIRTZIS, The Urban Continuity and Size of Late Byzantine Thessalonike, *DOP 57* (2003)[= *Symposium on Late Byzantine Thessaloniki*], 35-64.

against Ottoman expansion in Macedonia. Sultan Murad who was implicated in the Byzantine, despotic, affairs⁶⁰ was thus prompted to send his chief commander Kara Hallil Hayreddin Çandarli against Thessaloniki, having first amassed a great force in Thrace⁶¹. In the year 1383 the Ottoman forces already lay siege outside the walls of Thessaloniki, having first conquered in their passage important cities while conducting lateral military operations where conquest of Christian strongholds had been pending. By 1385, the year that marked the death of Manuel's blinded brother Andronikos, Kara Hallil Hayreddin Çandarli's mosque was an architectural and religious feature at the conquered city of Sérres⁶².

Whereas the specific date of Polystylon's conquest is lost in history, it is considered to have befallen during the earlier 1380s, rather than in the later mid-1380s⁶³, approximately following the systematic advance of the Ottoman army toward Thessaloniki which was led by the able Kara Hallil Hayreddin Çandarli who, along with the position of the first supervisor of the Ottoman army, was to also serve as the chief justice, and chief minister (hence the grand vizier) of Sultan Murad⁶⁴.

60. P. CHARANIS, *The Strife among the Palaeologoi and the Ottoman Turks, 1370-1402*, *Byz.* 16 (1944), 268-314 [=Id., *Social, economic and political life in the Byzantine Empire* (Variorum Reprints), London 1973, n. VI].

61. On the Ottoman conquest of Thessaloniki cf. S. J. VRYONIS, *The Ottoman Conquest of Thessaloniki in 1430*, in: *Continuity and Change in Late Byzantine and Early Ottoman Society*, ed. A. BRYER - H. LOWRY, Birmingham 1986, 281-321; N. NECİPOĞLU, *Byzantium Between The Ottomans and the Latins: Politics and Society in the Late Empire*, Cambridge 2009, 41-118, 184-234.

62. cf. FINKEL, *Osman's Dream*, 19-20.

63. Cf. C. HAYWOOD, *The Via Egnatia in the Ottoman period: The Melzihanés of the Sol Kol in the late 17th / early 18th century*, in: *The Via Egnatia under Ottoman Rule (1380-1699)*, *Halcyon Days in Crete II*, ed. E. ZACHARIADOU (University of Crete Press, 1996, Rethymnon), 129-141; In the middle of the 1380s with the advent of the Ottomans in the region the days of Polystylon were coming to an end, whereas a new center emerged in the region, the Ottoman settlement of Yenisea located at the center of the plains of Xanthe, cf. A. AGELARAKIS and Ch. BAKIRTZIS, manuscript titled: "Physical Anthropology and Human Skeletal Remains: The Abdera/Polystylon Project (Three Cemeteries from the 6th to the 14th Centuries)", *Abstracts of 21st International Congress of Byzantine Studies*, British National Committee of the Association Internationale des Etudes Byzantines, London, 2006.

64. See footnote 62, supra. Further grand vizier Kara Hallil Hayreddin was the forebear of grand vizier Halil Candarli of Sultan Mehmed II *Fatih*.

Echoes Configured from the Final Assault Days against Polystylon Fort

Evidently, based on a synthesis of available historical and archaeological records, Polystylon comprised the last Byzantine stronghold to be vanquished by the Ottomans in the regional locality of the Western Thracian shores⁶⁵. During the last days behind the fort walls, the besieged Polystylites, having remarkably held out in resistance for over two decades since the conquest of Komotini had been outnumbered⁶⁶, inadequately provisioned, progressively malnourished, increasingly fatigued, under psychological duress, and sustaining intensified attrition effects by combat related injuries, consequent secondary infections, and aggravated comorbidity⁶⁷. Yet, bravely, they resisted during this asymmetric conflict and boldly fought the jostle of the attackers in what was a focused military assault on multiple sides⁶⁸ of the walls and gates of the fort by the Ottoman forces. Vigilantly defending, ingeniously repairing, and stoutly averting with all their might and courage with crossbow bolts, arrows⁶⁹, stones, pikes, and the sword, enemy attempts

65. See footnote 63, supra; AGELARAKIS - AGELARAKIS Abdera/Polystylon, 24, footnote 36, 40-41 (regarding the new Ottoman settlement of Yenisea in the region, nearly half way from Polystylon toward Xantheia).

66. As a comparative note of reference to the pressures imposed to a fortress by the numbers of the Ottoman troops in siege, Doukas (ed. GRECU, 249) notes on Thessaloniki *Μόλις γὰρ ἐν δέκα προμαχώσιν εἷς τζαρχοβόλος ἴστατο* (“There was barely one crossbowman to cover ten turrets”: H. J. MAGOULIAS, *Doukas. Decline and Fall of Byzantium to the Ottoman Turks: An Annotated Translation of Historia Turko-Byzantina*, Detroit 1975, 171).

67. For a demographic profile insight of the population sample interred in the Late Byzantine period cemetery of Polystylon cf. AGELARAKIS - AGELARAKIS, Abdera/ Polystylon, 25-27, 35 (the latter for the high prevalence of traumatic injuries).

68. For a comparative strategy of the preparations and military assault on a fort or fortress by Ottoman troops coeval to the era cf. *Mihailović, Memoirs*, 45. 93.

69. The author is in support of the distinction made between *τοξόται* (archers) and *τζαρχάτορες* (crossbow men) as for example mentioned by Doukas (as in 66); cf. T. G. KOLIAS, *Byzantinische Waffen*, [BV XVIII], Vienna 1988, 220-238, 245-253. Based on the author’s personal experience archers use different upper extremity muscle groups (antagonistic in action) to draw the bow and aim compared to crossbow men, draw different types of bow sidedness (right-handed versus left-handed), length, type (i.e. self-bow, compound, recurve) and draw weight (i.e. from 55-75+ pounds), use different types of arrow shaft length, weight, and fletching, must train constantly for keeping up with marksmanship, use different techniques and require more space to draw and shoot compared to crossbow men, and may carry a lighter upper body protective panoply (also a helmet would have been very

to breach, scale, or undermine the walls they were under the tumult of drums, the uproar, the shouting and battle cries, skillfully aimed by the troops of the invaders to drive them in psychologic despair⁷⁰. The firing of early culverins by enemy gunners in the morning, the shower of arrows and javelins, sling shots, stone missiles hurled with great force from trebuchets and catapults⁷¹, as well as the battering rams combined with fire set on the gates⁷² by flaming arrows on incendiary materials⁷³ would be scoring direct hits and ricocheting on the walls and on the sheltering structures within the peripheral wall of the fort with ruinous effects, eliminating perishable resources, and debilitating the capabilities of the defenders.

The defenders, despite their predicament, would encourage each other with zeal to fight bravely⁷⁴, striking the enemy whenever possible with ardor and being struck themselves, while they knew that for every wounded or fallen comrade missing from their defensive post, it would have been easier for the hooked ropes and climbing ladders⁷⁵ to facilitate the enemy's passage on the battered walls. The critical number of the Byzantine guard and auxiliary combatants manning the fort⁷⁶ diminishing, lacking adequate replenishment of sustenance, weapons, and necessary shot supplies, coupled

dysfunctional) with greater flexibility in the shoulder and elbow joints, yet requiring more protection in the lower half of the forearm and carpus holding the grip of the bow.

70. For comparative Ottoman tactics during siege cf. Nestor-Iskander, 58:75 [=Relato, 51]. *Mihailović, Memoirs*, 45. 93-94.

71. Trebuchets and catapults had been since earlier days siege weapons of the Ottomans in conquering Byzantine cities and strongholds in Asia Minor.

72. For comparative Ottoman military tactics in siege of forts cf. Kritovoulos, *History* (ed. D. REINSCH, *Critobuli Imbriotae Historia* [CFHB 22]), I. 35:49-50 [hereafter Kritovoulos, *Historia*], Berlin-New York 1983 [=History of Mehmed the Conqueror, translated from Greek by C.T. RIGGS, Greenwood Press, Westport, 1970, Part I: 150-151 [hereafter Kritovoulos, transl. RIGGS]

73. Kritovoulos, *Historia* I.35: 49-50. Kritovoulos, transl. RIGGS, 148. 48, 150. 50.

74. As a comparative reference cf. Nestor-Iskander, 59. 75; *Relato*, 77.

75. As a comparative reference cf. Nestor-Iskander, 52. 69-71; *Relato*, 70-71.

76. It is suggested, based on comparative references (Kritovoulos, *Historia* I.32-33: 47-48 [=Kritovoulos, transl. RIGGS, 143-144, and 146], recording the fate of Therapia, Studius, and Prinkipo forts), that an approximate number of 40-60 professional soldiers could have manned the fort along with a comparable number of auxiliaries from the Polystylon village and regional locality).

by the constant shattering of the battlements and turrets, the devastation of the walls, the gates, and even of the inner citadel tower⁷⁷ were ominous signals indicative of the impending, unavoidable, fate. Alas, there couldn't be a favorable exit strategy in sight. There wouldn't be any solace to the groaning and sobs of the wounded comrades or any healing hand to their suffering. There wouldn't be any soothing and encouraging words whispered to the young, voicing of an optimistic prospect. The days of any standing defenders were to be forcibly veiled by either impalement or execution by the sword⁷⁸; any boys and girls particularly⁷⁹, and any useful adult civilians⁸⁰ were to be taken or sold as slaves⁸¹, if spared by the menace of the subjugators at the fall of the fort.

Historical records substantiate that all Byzantine urban centers peripheral to Polystylon⁸², namely Peritheorion, Xantheia, and Maroneia,

77. John VI Kantakouzenos, in strategically addressing issues of security in this important locality had carried out reinforcement works to redoubt the fort by means of his own funds, apparently remaining in the locality for some time possibly until the completion of the construction works (see Gregoras, *Roman History*, XII.16: v. II, 626-627: ἄρτι δ' εἰς πέρας ἤγοντες τῆς οἰκοδομίας, ἀφικνεῖσθαι πλησίον ἡμελλε καὶ Χρέλης ο Τριβαλλός, providing for a terminus ante/post quem of 1342 AD relative to the subsequent military engagement in Christopolis, *ibid.* XII.16: v. II, 626-627. Further, a gird of fortification walls with a tower, in essence a citadel internal to the peripheral acropolis walls of the small town, have been discovered cf. CH. BAKIRTZIS, Byzantine Thrace [as in n. 34], 158-162. *Id.*, Western Thrace in the Early Christian and Byzantine Periods [as in n. 34], 45-46; BAKIRTZIS - ZEKOS, *Ανασκαφή Πολύστυλου Αβδήρων*, (1984) 12-17; BAKIRTZIS, *Ανασκαφή Πολύστυλου Αβδήρων* (1983), 13-19; BAKIRTZIS, *Ανασκαφή Πολύστυλου Αβδήρων* (1982), 18-26.

78. Cf. Kritovoulos, *Historia* I.32-33:47-48 (recording the fate of the defenders in the Therapia, Studius, and Prinkipo forts), IV.12, 171-172 (On Mitylene-Lesbos), IV.14: 173 (On Nikorezos Gateliouzes), V.2. 183-184 (On Venetian prisoners and Peloponnesians), V.16, 203-204 (On Illyrian prisoners) [=Kritovoulos, transl. RIGGS, 143-144, 146, 183-184, 185, 196-197 respectively].

79. Comparative examples of practices cf. *Mihailović, Memoirs*, 27:50, 31:61, and 42:89; Kritovoulos, *Historia* IV.12: 172 = Kritovoulos, transl. RIGGS, 185.

80. Cf. Ιωάννης Αναγνώστης, *Διήγησις της τελευταίας Αλωσης της Θεσσαλονίκης*, in: *Χρονικά των Αλώσεων της Θεσσαλονίκης*, μετάφρ. Χ. ΜΕΣΣΗΣ - Εισαγωγή - Σχόλια Ρ. ODRICO, Athens 2009, 14. 336.

81. Cf. *Mihailović, Memoirs* 47: 96-97; Kritovoulos, *Historia* I.33: 47-48 = Kritovoulos, transl. RIGGS, 83. 183-184; Ιωάννης Αναγνώστης, *Διήγησις*, 14-15. 335-339.

82. Gregoras, *Roman History*, XII. 16, v. II, 626.

conquered⁸³ in the 1360s by Gāzī Evrenos Bey operations, continued to be occupied under Turkified names⁸⁴. However, the fort and its pericoastal settlement seem to comprise an exception given the absence of archaeological traces, of historical evidence from Ottoman records, and even of the lack of oral tradition vestiges⁸⁵ in support either of a continued occupation after the conquest, a subsequent resettlement, or even the designation of a Turkified toponym for Polystylon⁸⁶.

An Unmuted Narrative of the Grave Context

Inside the hauntingly towering remnants of the battered fortification walls as they endured to our days, at the highest elevation area of the fort, where once lay the western courtyard of a three-ailed basilica, lay Polystylon's cemetery site of the Late Byzantine Period; designated as provenience "ΞΑ4" its terminal phase dated within the 14th century AD⁸⁷, was excavated in 1991 by the 12th Hellenic Ephorate of Byzantines Antiquities⁸⁸ (Figure 2).

One of the twenty graves⁸⁹ recovered at said cemetery site and investigated carefully had safely preserved skeletal remains of a fallen Polystylite defender, destined to reveal of carnage and revengeful subjugation by the conquerors at the sacking of Polystylon fort. Apparently he had been put to the sword at the hands of the Ottoman captors. His decapitated remains⁹⁰,

83. Gregoras, VII.6, v. I, 244; LIACOPOULOS, *The Ottoman Conquest of Thrace*, 82-84.

84. Cf. LIACOPOULOS, *The Ottoman Conquest of Thrace*, 88-89 (Peritheorion was renamed as "Buru", Xantheia with a variety of names as "Ksani", "Isketye", "Eskice", and Maroneia as "Marulya").

85. The author has been carrying out anthropologic research in the region since 1983.

86. See footnote 84, *supra*.

87. AGELARAKIS – BAKIRTZIS, *Cemeteries at Polystylon (Abdera)*, 57-67.

88. AGELARAKIS – AGELARAKIS, *Abdera/ Polystylon*, 11-56.

89. All skeletal remains were excavated and investigated with the author *in situ* and subsequently in the field lab assisted by his students Jennifer Winick, Dominick Auciello, and Nikolaos Bakirtzis, in a collaborative effort with the 12th Ephorate of Byzantine Antiquities.

90. Of the cranial structure the hyoid bone was missing, while of the infracranial axial components there were recovered at the time of excavation fragments of the first three (atlas, epistropheus, and third cervical) cervical vertebrae. Their state of preservation (certainly affected by taphonomic conditions) did not allow for conclusive evaluations that could substantiate the presence of traces of mechanical impact, other than the observation that their right lateral sides, with the greatest emphasis on the third cervical, were more compromised compared to their left lateral counterparts.

showing a *perimortem* compressed-comminuted fracture over the anterior latero-lateral region of the frontal bone, had been intentionally laid to rest at the intermediate, contextual, stratigraphic layer of a box-shaped grave of a 4.5/5.5 year old individual⁹¹. As with the rest of the burial features at the Late Byzantine period cemetery of Polystylon, grave No. 13 had safely retained through the passage of time the remains of the two individuals (Figures 3, and 4).

The young individual in the grave lay anatomically undisturbed on a supine and extended position, oriented on a west to east axis and facing east with the forearms crossed over at the mid-thoracic region, inferiorly to the xiphoid process of the sternum, while the left forearm superimposed the right (Figure 5). Several bronze beads at the region of the left carpus comprised components of a stringed bracelet. The lower extremities lay parallel to each other, nearly equidistant from a projected anatomic median line. Further, an outline of square iron nails recovered from the basal stratigraphic layer of the boxed-shaped grave⁹² was indicative of a wooden quadrangular in shape coffin that had been used for the interment of the young individual. Manifestations of mild porotic hyperporosis, without hyperostosis, had marked bilaterally the roofs of the orbital cavities, indicative of an active response to either an infectious pathogenic agent, and/or a case of mild anemia that was active at the occurrence of death. Lacking other discernible pathologic changes or conditions of skeletal developmental difficulties the young individual revealed an epigenetic expression, a variable of the Carabelli's trait, marking as a slight pit the mesio-palatal crown area of the first left uninterrupted permanent maxillary molar (L.M¹). Further on the dental record, deciduous incisal and occlusal wear patterns reflected on a very carefully prepared diet, void of materials that could have functioned as dietary grit or alternatively to have had caused enamel micro-fractures especially at the peripheral margins of the dental crowns. There was also a lack of any traces of cariogenic lesions.

91. Due to the immature skeleto-biological developmental state of the young individual (age assessed within the Infancy I age subgroup, chiefly based on dental development and maturation) it was not possible to assess its biological sex on inspectional and mensurational evaluations.

92. The sides of the grave had been constructed with two stone slabs (spolia from earlier structural functions) and several unworked stones.

Earth materials that had been deposited either as sediment thrown on the coffin and/or in the preparation of the basal layer of the young individual's burial bed were rich in sandy, subrounded, and rounded particles⁹³ along with small fragments of waterworn marine bivalve shells⁹⁴. These sedimentological materials were recovered from the third in sequence (basal) intra-contextual stratigraphic layer of the burial feature; they presented a unique basal stratigraphic layer mainly composed of deposits from the littoral sediments of the fort, lacking from the rest of the intra-contextual stratigraphic layers of the remaining 19 graves⁹⁵ documented at this cemetery of Polystylon. Hence, references from the skeletal and dental records, epitaphic aspects of the burial feature, along with the manifestly central position of the grave within the funerary activity area indicated of a rather distinct interment of a youth within Polystylon fort (Figure 6).

Regarding the remains of the decapitated warrior, the *in situ* location of the three cervical vertebral fragments and mandible provided evidentiary data in assessing the placement of the head in the grave at the time of interment. Even if anatomically incomplete, the remains of the beheaded became at the time of interment, based on stratigraphic superposition, the primary burial of the grave and given its non-conterminous depositional relation to the earlier interment (Figure 7).

Relatively soon after the beheading, the detached head and partial neck of the warrior with a majority of their soft tissues intact (which ensured the “syndesmotic” retention of the metopic anatomy, the connectivity of the upper three cervical vertebrae to the base of the head, and the preservation of the temporo-mandibular articulations), must have been located, identified, and retrieved. The individual(s)⁹⁶ that carried out the endeavor to recover

93. Mostly comprising fine (1/8-1/4mm) sand with a 25% proportionality of medium (1/4-1/2mm) sized sand, and a 10YR 5/2 (grayish brown) Munsell reading, cf. Munsell Color Company, (2000). Munsell Soil Color Charts. Munsell Color GretagMacbeth, New Windsor, NY.

94. A sediment composition with attributes representative of the littoral deposits of the adjacent shoreline.

95. AGELARAKIS -AGELARAKIS, Abdera/Polystylon, 25.

96. If the individual(s) were *Polystylites* then this would indicate that they survived the melee at the fall of the fort and acted out of sympathy, devotion, respect, and duty. Alternatively, the possibility is not excluded that the individual(s) were Christian members of the Ottoman troops. Henceforth, “the individual(s)” are addressed as “sympathizers”. For a relative example

the decapitated remains either knew as eye witnesses of the specific location the head had fallen during the decapitation, had otherwise being informed by others, or had independently discovered, at some point in time, the actual locus of the detached head. It is suggested that the particular action would have rather been acted in secrecy and not by permission of the subjugators⁹⁷, given that the rest of the body was not recovered⁹⁸ to be united and to undergo the same funerary process as the detached head. Furthermore, the sympathizer(s) that retrieved and intended to entomb the decapitated remains knew both of the particular location and nature of the grave and its orientation⁹⁹, according to the cardinal directions, in order to carefully excavate the upper sedimentological layer(s) of a partial yet specific locus of the grave, without truncating or disturbing the earlier burial of the young individual¹⁰⁰. Thoughtfully interring the head to rest on the proximal¹⁰¹ position of the grave its placement corresponded to where the head of an

cf. *Mihailović, Memoirs*, 27. 51 (Sympathizers that carried and buried during the night in Constantinople the bodies of two beheaded youths from Adrianople, "... beside an empty church called *Does Not See the Sun*.").

97. As in the case of the Serbs who were serving in Sultan Baiazit's army, having asked for permission they carried and buried the body of Prince Lazar, who had just been decapitated, at Ravanica monastery cf. *Mihailović, Memoirs*, 16. 25; as in the case of "Helene, David's (Emperor of Trebizond Komnenos) wife buried the remains of her relatives (her husband and noblemen of the imperial family executed) and then became a nun." Cf. *Sphrantzes, The Fall of the byzantine empire* [as in n. 21], &XLII: 2. 85, endnote 35 (p.143).

98. There are many complexities to consider on this matter including but not limited to the following: 1) If the body was recognizable (following the combined effects of putrefaction and the intent of the subjugators for it to rot and to be eaten by crows and dogs) and recoverable (i.e. not impaled, not burned, available at a relatively short distance from the fort such as the camp of the Ottoman troops), it would not have been easily transferable by one individual to the specific cemetery area for interment; 2) If recoverable and interred, the body would be conspicuous by its absence to any subjugators remaining in the area of the fort; 3) If recoverable the body would require a larger grave, requiring a greater effort and more time thus revealing noticeable traces, arresting any efforts to conceal the act.

99. This suggests that the grave location was visible at ground level, and that it possibly represented a recent burial.

100. Suggested to have been selected either as a more inconspicuous grave location for an adult, and/or possibly due to affinity between the two individuals in the grave.

101. Describes both the cardinal western, short, side of the grave, and when in reference to the skeletal remains the anatomic directional toward the head/cranium.

anatomically complete individual were to be located, and positioned to face due east, simulated the burial-custom decorum and symbolism of a Christian burial; this was in concert to the funerary formalities documented at the cemeteries at Polystylon since the early Byzantine period.

In order to ensure the particular burial positioning of the head, as explained above, the head and partial neck were laid to rest on their left lateral side, superimposing the proximal, center-right, domain of the lid of the coffin which in some form of structural integrity functioned as the provisional basal layer in the grave for the placement of the decapitated (Figure 8).

Consequently, the decapitated remains of the warrior were discovered at the time of excavation resting at the lower *terminus* of the intermediate (second in sequence) intra-grave stratigraphic layer, void of sandy deposits¹⁰². This intermediate stratigraphic layer comprised subsurface rich in silt soil-deposits¹⁰³ mingled with a good number of angular and subangular pebbles, small rock and *kourasáni* compound fragments¹⁰⁴ while superiorly to the ectocranial surfaces of the vault bones and of the right mandibular condyle and ramus lay the more rich in organic materials, loamy, superficial sediment layer¹⁰⁵ of the grave.

The mandible and the preserved left side fragments of the upper three cervical vertebrae, in their settling process in the grave, void of a majority of soft tissues, conglomerated over time with intermediate stratigraphic layer sediment particles, thus retaining their basic *in situ* position of laying on their left side (see Figure 7). An important stabilizing parameter to the

102. The specific location of the cranial remains at the time of excavation lend support, under most probabilities, of the structural preservation of the coffin lid at the time the head had been laid for interment.

103. 10YR 5.5/5 (yellowish brown/ light yellowish brown/brownish yellow) Munsell reading, cf. footnote 93, supra. There were also present two cranial bone fragments of an adult individual of intrusive nature.

104. A Byzantine mortar material used as a bond in architectural structures constructed with stone and bricks.

105. 10YR 3/2.5 (very dark brown/dark brown) Munsell reading, cf. footnote 93, supra. The excavation procedure followed (in regards to stratigraphic layer identification and designation) the methodological process of Harris' Matrix, cf. C. E. HARRIS, *Principles of Archaeological Stratigraphy*, Academic Press, 1989, London.

settling process of the mandible was afforded by the presence of a large fragment of a utilitarian ceramic vessel. It is suggested that after its use as a provisional spade for the excavation and preparation of the pit in the grave that was to receive the head burial it was left *in situ*; its concave area facing down, mounting the sediment that had been excavated rightward. In time, following the decay of the casket and southern long wall of the coffin the ceramic fragment inserted, through taphonomic processes, quasi-vertically in depth, obstructed otherwise by surrounding sediments to settle at a horizontal level, reaching to the collapsed right ribcage locus, the splanchnal abdominal region, and the lower pelvic domain of the young individual.

The *calvaria*, situated as it was at a higher axonometric elevation than the stratigraphic level of recovery of the younger individual's cranial remains, it is suggested underwent settling processes whereby it slowly "caved in" somewhat, by the nuchal area of the occipital, once a partial void had been generated by the gradual weakening of the structural integrity of both the wooden lid and the southwestern sides of the coffin¹⁰⁶. During this process the *calvaria* traced an incremental quasi-dextrorotatory track further induced by taphonomic circumstances affecting the rebalance of its center of weight. Additionally, perennial fluctuations in the wateriness, compactness, and weightiness of the superimposing sediments, intrinsic components of the taphonomic processes, combined with the seasonal use of the area for the cultivation of cereals up to recent historic times¹⁰⁷ afforded downward compression loads on the antero-ventral calvarial vault area. Its structural integrity however, had been already compromised by a *perimortem* compressed and comminuted fracture that had affected the anterior area of the frontal bone, at the supero-mesial locus on the frontal-belly region of the right fronto-occipital muscle. Hence, the combined effects of the *ante mortem* injurious condition, the taphonomic processes, and the relatively recent historic anthropogenic land use effects resulted to a partial

106. As explained above, the coffin lid had previously served as the basal layer of entombment at the time the head had been placed in the grave for interment.

107. Personal communication with land owners, and Antiquities Authority Chief Guard of the region, the late Mr. Katsikas of the historic village of Abdera, since 1983.

buckling, inferiorly of the calvarial upper¹⁰⁸ region, at the upper middle and lower facial regions¹⁰⁹, as well as of the left demi-lateral cranial wall¹¹⁰.

The horrific head trauma at the metopic region¹¹¹ it is assessed had been caused by the piercing component, the ἔδρα, of a heavy weapon that had fatally penetrated subdurally the cerebral area of the frontal lobe¹¹². The nature and magnitude of the striking force implemented by the blow had also caused the severe compressed and comminuted fracture described above.

Whereas the neurocranial fracture would most certainly have caused immediate fatality, it has been described above as of *perimortem* nature in order to consider the sequence of events that could have transpired between the metopic trauma and the decapitation. As such, in the case that the metopic trauma preceded the beheading, the decapitation would not have comprised an execution but a *post mortem* mutilation of the deceased's body. In the case where the beheading would have been an act of execution, the head trauma would have comprised a *post mortem* punitive mutilation of the deceased. In the realm of examining in retrospect the gruesome minutiae on the sequence of an act of execution versus a punitive post mortem act, historical records provide ample narratives, also with eye witnesses' accounts, of both executions by impalement and beheading of combatants that had surrendered in battle against the Ottomans¹¹³, and of *post mortem*

108. The three frontal fragments that had been caused by the comminuted fracture folded into the brain case, hence collapsing the entire supraorbital line up to the frontal tuberosities, along with the fronto-nasal and the fronto-zygomatic suturaleal joints.

109. From the superior level of the orbits and naso-ethmoidal complex to the maxillo-palatine component.

110. The left sphenoidal wing region, and left temporal.

111. In the forehead region.

112. If not already seriously wounded by other causative agent, the warrior would have lost immediately consciousness.

113. As a comparative reference to such acts cf. Kritovoulos, *Historia*, I. 32: 47 = Kritovoulos, transl. RIGGS, 143. *Mihailović, Memoirs*, 16. 25 (for the heads of Miloš Obilić, Prince Lazar ruler of the Serbian kingdom, and Voivode Krajmir), 27. 50 (on the surrender of Novo Brdo "Emperor Machomet ... All those among the men who were the most important and distinguished he ordered decapitated), 30. 57 (on Leontarion and other Morean fortresses), 33. 68 (on the surrender of Mytilene-Lesbos chiefly of a contingent sent by the Pope-(also corroborated by Kritovoulos, *Historia*, IV. 12: 171-172 = Kritovoulos, transl. RIGGS IV: 83.

decapitations for the verification, and celebrated communication, through trophy keeping, of the ultimate defeat of important individuals that had fallen with valor and conspicuous gallantry in battle while resisting Ottoman subjugation¹¹⁴.

In aiming to decode a frame of reference on the possible identity and role of the Byzantine warrior in the defense of Polystylon, the inquiry at hand carefully observed that he was apparently the only one given by the sympathizer(s) the privilege of interment in a decapitated, anatomically incomplete, state. Therefore, although possibly limited by parameters set by the archaeological record, the question is nevertheless begged if he could have been the only one beheaded at the fall of the fort, either through an act of execution or as of a *post mortem* war trophy acquisition. In either of the prior or the latter case the decapitated warrior would have been identified by the Osmanlis as a protagonist (such as it would have been for the *κεφαλή*¹¹⁵ of the fort) in the military actions and defense strategy of the fort. Lending

184), 34. 70-71 (for the heads of Emperor of Trebizond David Komnenos, of Bosnian prince Tvrtko Kovačević, and of Bosnian King Thomač and his friend), 35. 72 (on braking the bones of all Venetian at the fall of Negropont); Sfranze *Cronaca* 160 = *Sphrantzes, The Fall of the Byzantine Empire*, XI:5. 81 (regarding the lords of Kastritzi by Sultan Mehmed II, "... some were decapitated and others were impaled", and in Gardiki where the inhabitants sought better protection, "... they surrendered, and all inhabitants, including women and children, were put to the sword."; *Melissenos Makarios, The Chronicle of the Siege of Constantinople April 2 to May 29 1453*, in *Sphrantzes, The Fall of the Byzantine Empire*, VI (Book III, 10-12) 133 (regarding the beheading of Lord Loukas Notaras and his two sons, and "... the executions of many eminent noblemen followed, including the Venetian bailey and his son together with the Catalan consul and his sons."). Further, on the beheading of Venetian Bailo Jeruolemo Minoto cf. Nicolo Barbaro, *Diary of the Siege of Constantinople 1453*, Translated by JOHN MELVILLE-JONES, 1969, Exposition Press, New York, 70.

114. Cf. *Mihailović, Memoirs*, 16. 25 (in this case after execution heads provided as evidence), 23. 40-41 (head of King Vladislav of Hungary), 26. 47-48 (head of Emperor Konstantin XI). Further on the latter cf. Doukas, ed. GRECU, 377. Cf. H. J. MAGOULIAS, *Doukas. Decline and Fall of Byzantium* [as in n. 66], 40.3, p. 232, and cf. Nestor-Iskander, 82. 93 [=Relato, 93].

115. For the formal title and range of responsibilities of the chief military commander of Byzantine forts and *κάστρα* during the 14th c. cf. K. N. SATHAS, *Μεσαιωνική Βιβλιοθήκη*, Athens 1972, VI, 642; (ἔνταλμα κεφαλατικίου). MAKSIMOVIC, *The Byzantine Provincial Administration under the Palaiologoi*, 116-167; BARTUSIS, *The Late Byzantine Army: Arms and Society*, 314;

support to the evidentiary line identifying his leadership role at the fort may be glimmers of symbolic meaning reflected from the unique case of his interment in the cemetery of Polystylon, while additional tesserae of his *προσωπογραφία*, are elucidated by no faint traces permanently recorded on his dento-skeletal remains.

On Information yielded through Dental Anthropology

Dental linear enameloblastic hypoplasias were revealing of early life systemic stress conditions¹¹⁶ that had affected the warrior at 3.25, and 4.5 years of age, within the Infancy I period of his life. These temporary circumstances of ill health were surpassed as clearly revealed by the formation of the enamel defects that recorded the two cases of arrested and subsequently improved biological growth. Further on his dental record, the right central maxillary incisor (R.I¹) and the left maxillary third molar (L.M³) had been lost relatively shortly before death (based on incipient intra-alveolar remodeling), compared to the antedating loss of the right maxillary third (R.M³) and second (R.M²) molars as attested by the advanced yet incomplete alveolar osteoreparative process, interrupted by the occurrence of death (Figure 9).

In addition to the maxillary *ante mortem* dental loss, the maxillary arcade showed unilaterally, at the left component of its alveolar process, a discernible mesial compression toward the palatine process; a condition that accentuated the labial truncation of the left second maxillary incisor (L.I²). Symptomatic manifestations of periodontal disease were discerned, involving slight buccal supragingival calculus deposits, hyperporosis at the margins of the alveoli, noticeable traces of alveolar bone absorption, and flattening of interdental *septae*, thus simulating a continued eruption of dental root anatomical surfaces into a clinical environment, particularly at the loci of trifurcation among the remaining molars *in situ*. Further, there were no cariogenic lesions.

Similar conditions of periodontal disease, although with fewer traces of calculus deposits yet with moderate to slightly concave interdental *septae* absorption, were observed among the dental arcade of the mandible which had bilaterally retained all permanent molars. The rest of the mandibular teeth were not preserved *in situ* having been lost under *post mortem*

116. Caused for example by fevers and/or communicable child diseases.

conditions with the exception of the left lateral incisor (L.I₂), the left canine (L.C₁), and left first premolar (L.PM₁) that had been lost *ante mortem*. While the alveolus of the left lateral incisor (L.I₂) was partially preserving its walls, the alveoli of the left canine (L.C₁), and left first premolar (L.PM₁) had been obliterated long before death as their anatomic location had been the focal point of trauma impact (Figure 10).

«Fractura Mandibulae» Healed

The Byzantine warrior had sustained a mandibular fracture, a unique find in itself at Polystylon. Based on evaluations of the palaeopathological manifestations it pertained to a healed left parasymphyseal fracture¹¹⁷. The trauma impact had fractured the dentoalveolar and basal region of the mandible causing a comminuted-complex and vertically unfavorable cleft along with a basal triangle (Figure 11). The particular causative agent of the mandibular fracture could not be determined in a deductive manner among competing explanatory hypotheses which ranged from the domain of a forceful fall injury from riding a horse, of a trauma caused in battle by a spearhead thrust while mounted, by a forceful strike by a sharp hand-held weapon at close-encounter battle engagements, or by a ballistic in nature projectile-inclusive of a missile¹¹⁸ propelled by black powder¹¹⁹; a jousting

117. For concise reviews on the diagnostics, prevalence, and treatments of mandibular fractures cf. E. ELLIS – K. F. MOOS – EL-A. ATTAR, Ten years of mandibular fractures: An analysis of 2,137 cases. *Oral Surgery Oral Medicine Oral Pathology* 59 (1985), 120-129; J. C. KOSHY – M. E. FELDMAN – J. C. CHIKE-OBI, and J. M. BULLOCKS, Pearls of Mandibular Trauma Management, Seminars in Plastic Surgery, Thieme Medical Publishers, New York, (2010), V. 24:4. 357-374; D. ERDMANN – K. E. FOLLMAR – M. DEBRUIN – A. D. BRUNO – SIN-HO JUNG – D. EDELMAN – S. MUKUNDAN – R. J. MARCUS, A Retrospective Analysis of Facial Fracture Etiologies, *Annals of Plastic Surgery* 60 (2008), 398-403.

118. R. PILCHER, Management of missile wounds of the maxillofacial region during the 20th century, *Injury* 27 (1996), 81-88; P. K. STEFANOPOULOS – K. FILIPPAKIS – O. T. SOUPIOU – V. C. PAZARAKIOTIS, Wound ballistics of firearm-related injuries-part 1: Missile characteristics and mechanisms of soft tissue wounding, *International Journal of Oral and Maxillofacial Surgery* 43:12 (2014), 1445-1458.

119. R. M. COUPLAND, Wound ballistics and surgery, in P.B. KNEUBUEHL – R. M. COUPLAND – M. A. ROTHCHILD – J. M. THALI (eds.), *Wound Ballistics and applications*, Berlin 2011, 305-320; STEFANOPOULOS – SOUPIOU – PAZARAKIOTIS – FILIPPAKIS, Wound ballistics of firearm-related injuries-part 2: Mechanisms of skeletal injury and characteristics of maxillofacial ballistic

trauma was rendered highly unlikely given the context of cascading warfare events during the period. And yet, clues based on palaeopathologic evaluations revealed of post-traumatic conditions, of medical intervention, and of the healing process outcomes reflecting on additional facets of the Polystylon warrior's experiences, and contributing to the nexus toward his prosopography.

It could thus be established that the mandibular fracture had been treated medically by means of a closed reduction. The physician manually placed the two major jaw fragments in their approximate anatomic position *ante* implementing concurrently the technique of intervention by partially securing the realignment of the dentate jaw fragments, paying attention to the restoration of functional occlusion through the inter-wiring or threading of mandibular teeth adjacent to the locus of rupture to the third molars. Relative dental traces were discerned in the shape of ca. 0.8 to 1.34mm in width bands traversing circumferentially the left and right mandibular molars preserved *in situ*. These bands were noticeable on the interdental and bucco-lingual surfaces of the molars. They were marking the lower borders within the domains of the distal thirds of the crowns, primarily above the margins of the cemento-enamel junctions, canvassed by the void of slight supragingival calculus which otherwise had deposited on the surepo-inferior borderlines of the bands. Noticeably, the mesio-buccal middle and distal thirds of the enamel crown component of the first right mandibular molar (R.M₁) revealed in addition a sharply bordered horizontal (transversal to the long axis of the tooth) depression, of mechanical nature, creating a well-defined imprint that was reaching into the dentino-enamel junction; suggested to have been an outcome of the dental inter-wiring intervention. While it was not possible to run trace element analysis on said dental surfaces, seeking to identify residual gold metal-threading signatures, it was possible to determine through inspectional evaluations the lack of silver alloy discolorations, and as expected, an absence of cupric acid (from bronze) or patina (from copper) stains.

trauma, *International Journal of Oral and Maxillofacial Surgery*, 44: 1. (2015), 67-78; D. DEMETRIADES – S. CHAHWAN – H. GOMEZ – A. FALABELLA – G. VELMACHOS – D. YAMASHITA, Initial evaluations and management of gunshot wounds to the face, *Journal Trauma* 45 (1998), 39-41.

While subsequent matters of essential mandibular fragments' immobilization by external bandages, fixed on orofacial and postero-lateral head loci and firmly fastened on the vault of the head¹²⁰, could not be verified skeletally, it would most probably have been implemented as part of the recommended treatment. The latter is suggested would have materialized given that it comprised the next step in the *cheiroúrgical* intervention for the treatment of mandibular fractures, following the realignment of the dentate jaw fragments by interdental gold wire threading, as recommended in the medical directions, advice, and precautions provided to physicians since the 5th c. BC by the Hippocratic corpus¹²¹. Further, the Hippocratic method was also underlining recommendations and concerns on the overall post-operative ability of the patient to follow the prescribed regimen during the recovery process; conditions which were claimed would influence the end result of the healing process.

In retrospect, based on the severity and complexity of the warrior's parasymphyseal comminuted fracture, treated with closed reduction, certain outcomes were evident following the healing process with a callus formation between the healed mandibular components. Following the osteosynthesis process an overriding misalignment of the mandibular parts had taken place with a post-left lateral incisor (L.I₂) to pre-left second premolar (L.PM₂) bone defect (Figure 12). Ventrally, it involved the mandibular domains of the mental fossa, the oblique line, and mental tubercle. Inferiorly it affected the digastric fossa, infero-lingually the submandibular fossa, and lingually the mental spines of the genial tubercles. Hence, there was a derangement of the fused mandibular fragments, most discernible at the epicenter of the healed counterparts with a mesio-posterior ectopism of the left mandibular component and a significant lingual callus formation necessitating the postero-lingual migration of *m. genioglossus*, *m. styloglossus* (due to the repositioning of *m. genioglossus*' origin on the mental spine and the contiguous repositioning of the postero-lateral domains of the tongue),

120. A few relative images are available in figure 5 of p. 1010, and figure 6 of page 1012 in F. GAHHOS – S. ARIYAN, Facial Fractures: Hippocratic Management, in *Head and Neck Surgery* 6.6 (1984), 1007-1013.

121. Hippocrates. *Περί ἄρθρων*, XXXIII:1-XXXIV:32, ed.-transl. E. T. WITHINGTON, *Hippocrates, On Joints* [Loeb Classical Library 149], Harvard University Press, Cambridge Massachusetts 1928 [repr. 1999], v. III. 258-264.

and of the suprahyoid muscle group attachments (Figure 13). The latter, along with any untoward sequelae of the fractured mandible¹²², would have functioned during the early stages of secondary bone healing (before bony healing) in antagonism with the muscles of mastication hindering proper ossification alignment of the bicortical mandibular bone fragments, and the repair of the ruptured neurovascular bundles¹²³.

Partially due to embedded hematoma, soft tissue remnants, and detached bone fragments which could not be extracted under the closed reduction treatment¹²⁴, and possibly due to the patient's inability in *fractura mandibulae* to strictly adhere to the firm course of prescribed immobility, as cautioned in the Hippocratic treatise¹²⁵, were the reasons of the slight mandibular malunion rather than the surgeon's inability to carefully line up or follow up with manual adjustments the comminuted fragments as endorsed since the Hippocratic corpus¹²⁶. In fact, had there not been follow up adjustment treatments of the aligned jaw fragments by the physician, the fractured jaw component identified as the base triangle would not have been set to fuse as close to the contour of the mandibular oblique line (Figures 14, and 14a). Hence, it could be surmised that the patient had benefited from the available intervention of an experienced physician and the accessible necessities for the duration of a lengthy healing process¹²⁷, whereby certain

122. In the case under investigation it appears that there should not have been any consequent effects by a delay in receiving medical help.

123. Following the fracture and during the healing process there had been acutely intensified, antagonistic, directional dynamics between: a) the muscles of mastication (m. temporalis, m. masseter, and mm. mesial and lateral pterygoids), basically lifting the left mandibular fragment upwards (action: elevator muscles—the lateral pterygoid also acts as a mandibular protrusion muscle) with trajectory emphasis at the *gonion*, and b) the suprahyoid muscles (m. digastric, m. geniohyoid, m. stylohyoid [as it assists in the lowering of the mandible], and m. mylohyoid) which would pull the right mandibular fragment mainly downwards (action: depressor-retractor muscles) with emphasis at the anterior mandibular region of the *pogonion*. Similarly to the latter, the base triangle fragment would have been pulled downwards.

124. Although on the positive side closed reduction does not challenge surgically the vascular network.

125. Hippocrates, *Περί ἄρθρωσιν* [as in. n. 121], v. III, 258.

126 Hippocrates. *Περί ἄρθρωσιν*, v. III, 162.

127. Immobility of the masticatory apparatus possibly through maxillo-mandibular fixation.

integral amenities operated by a support group must have been in place¹²⁸; a rather privileged although necessary treatment, particularly for a patient suggested to have been of certain socio-political/military *gravitas*. Such surgical intervention and healing regimen would not have been easily attainable while for example in the field during military campaigns, or by a non-preferential attention paid on the medical care and aid provided; particularly under the precipitous circumstances imposed during the tumultuous events of the period and the activities of the encroaching Ottoman forces which branded the adult life period of the warrior.

Emphasis on the high quality of care and of the erudite level of therapeutic methods applied by the medical follow up and relative support during the healing process is provided not only by the absence of any skeletal manifestations that would indicate the presence of any complications due to secondary infectious changes¹²⁹, but also by the alignment of the healed mandibular fragments that resulted in a favorable grade of functional occlusion in masticatory processes between maxillo-mandibular incisal and occlusal dental surfaces¹³⁰, supported by a high degree of attention to oral hygiene matters¹³¹.

128. For example not only to minimally care and feed the patient for four to six weeks, but to also follow up the wounded area and to provide for the adjustments necessary regarding functional occlusion till recovery within the range of eight to eleven months (for the latter under modern medical conditions, personal communications, since 1992, with Drs. Irwin D. Mandel, Director of Clinical Research, and Sidney L. Harowitz, Acting Dean, School of Dental and Oral Surgery, Presbyterian Hospital, Columbia University).

129. For comparative purposes to current protocols and methods cf. K. PETERSEN - D. K. HAYES - J. P. BLICE - R. G. HALE, Prevention and management of infections associated with combat-related head and neck injuries, *Journal Trauma* 64 (2008), Supplement, 265-267; D. R. HOSPENTHAL - C. K. MURRAY - R. C. ANDERSON - R. B. BELL - J. H. CALHOUN - L. C. CANCIO - J. C. CLASPER - T. J. WHITMAN - T. K. CURRY - M. E. FLEMING - J. C. WENKE - J. R. FICKE Prevention of infections associated with combat-related extremity injuries, *Journal Trauma*, 71: 2 (2011), Supplement 2, 235-257.

130. Despite a slight mesial displacement of the right mandibular condyle with an ipsilateral articular extension within the right temporo-mandibular fossa, and concomitant osteoarthropathic effects with a focus on the left temporo-mandibular joint counterparts; the latter as a result of years of functional modification through masticatory processes.

131. Considered as most important since the recommendations of the Hippocratic corpus, cf. J. C. AILIANOS, Hippocrates and dental surgery, *Bulletin d'Académie de Chirurgie Dentaire* 23 (1977-1978), 67-73.

Hence, dental wear patterns between functioning maxillo-mandibular counterparts that were preserved *in situ* showed smooth, nearly horizontally homogenous, occlusal surfaces, also reflecting on a very good quality of preparation of foods consumed; indicative of a dental age at death¹³² within the terminal Middle Adulthood to early Late Adulthood, between the range of 35 to 40 years (ca. at a mean of 37.5 years). Meanwhile a set of maxillary teeth *in situ*, namely the left canine (L.C¹) and first premolar (L.PM¹), having lost the capacity for functional occlusion (due to the mandibular fracture) with their mandibular counterparts, had retained the level *ante* of their incisal and occlusal enamel surfaces, showing slight cusp tip flattening on the canine with traces of an incipient islet of dentin and a more moderate buccal cusp flatter on the premolar with a better defined islet of dentin (see figure 9). Such wear patterns revealed that the two teeth had not been used in functional masticatory modification for a considerable time, providing based on their condition for a dental age of approximately 25 to 28 years, thus suggesting that the mandibular fracture would have been sustained approximately ten years before¹³³ the occurrence of death (ca. at 27.5 years of age), hence around the year 1373 AD¹³⁴.

A Nexus of Archaeo-Anthropological Assessments with the Historical Record

At the interval before 1373 AD the city of Komotini had already been conquered for nearly twelve years, since 1361, by marching warrior-lord Gāzī Evrenos Bey, while the urban centers of Peritheorion, Xantheia, and Maroneia, immediately peripheral to Polystylon, had fallen in the mid-1360s, just several years before the occurrence of the mandibular fracture. During the same period Polystylon¹³⁵ must have been under a cloud of

132. Based on dental wear patterns adjusted for the population sample of Polystylon.

133. The evidentiary data retrieved from dental anthropological evaluations were corroborated by palaeopathological assessments on the histologic and morphological nature of the mandibular callus formation indicative that the mandibular healing had taken place long term before death.

134. Considering that in ca. 1383 AD, the year of Polystylon's fall, the warrior would have been ca. 37.5 years of age.

135. Protected by a gird of fortification walls with a tower, in essence a citadel internal to the peripheral acropolis walls of the small town, cf. Ch. BAKIRTZIS, Byzantine Thrace, 158-162. ID., Western Thrace in the Early Christian and Byzantine Periods, 45-46; BAKIRTZIS -

blockade, having successfully defied the military assaults of Gāzī Evrenos Bey and his ilk, yet restricted from the grids of communications with the peripheral urban centers in what was perceptibly steadily and ominously devolving to a grievous and un-sustaining surrounding. It is thus suggested that the Polystylite warrior could have sustained the mandibular injury during defense operations of the fort against the invaders, and that he was subsequently treated medically throughout the healing process at the *intra muros* environment.

In addition to any skeletally untraceable intraoral cavity soft tissue defects that could have been caused by the injury¹³⁶, the mandibular and left lower mid-facial external scarrings¹³⁷ could have been somewhat concealed by the growth of facial hair and beard. In addition to dental loss, as a result of deficient neurovascular plexus functions at the inferior alveolar locus, it is suspected that the warrior would have vocalized with audible changes in certain aspects of speech resonance¹³⁸, while he would have experienced *παραισθησία* and sensory loss toward and around the chin area due to damage of the inferior alveolar nerve¹³⁹. Further, there would have been additional chronic implications¹⁴⁰ from the trauma impact, possibly even of the base of the head and neck, whereas the suffering from temporo-mandibular joint disorder (showing considerable osteoarthropathic changes-consequences of causative agents traced at the effects of the injurious event) has been established. Despite these conditions with the potential for enervation, however limited the dento-cranial record may be in order to reflect on the rest of the Polystylite warrior's skeletal

ΖΕΚΟΣ, Ανασκαφή Πολύστυλου Αβδήρων (1984), 12-17; ΒΑΚΙΡΤΖΗΣ, Ανασκαφή Πολύστυλου Αβδήρων (1983), 13-19; ΒΑΚΙΡΤΖΗΣ, Ανασκαφή Πολύστυλου Αβδήρων (1982), 18-26.

136. Including but not limited to salivary sublingual gland and submandibular gland and duct functions as well as of the tongue's multiple functions (i.e. particularly in chewing and swallowing).

137. The traumatic event had afforded concomitant traces of injury at the left maxillary component and left lateral locus of the maxillo-zygomatic suture.

138. Minimally due to the postero-lingual repositioning of muscle groups and oral mucosa tissues within the oral cavity that aid in speech production.

139. Particularly the left mental nerve, but also of vascularization damage specifically of the inferior labial artery and vein and their respective mental branches.

140. Some carrying pain producing sensations.

narrative, it nevertheless clearly disclosed that he had endured serious life threatening conditions, revealing of his seasoned veteran experiences in battle encounters. Subsequent to the healing process, defying enfeeblement, duly involved at a commanding position in the utterly protracted in the region resistance and defense of Polystylon against the Ottomans, he was discovered six hundred years later in the grave of a youth at the center of the fort's cemetery site; uniquely documented, separate from others, to have been persecuted and decapitated as a *κεφαλή* by the invaders¹⁴¹.

Epilogue

With his *ψυχοροράγμια* the glow of the flickering torch of the last Byzantine vestige in the region was put out. The revengeful act of subjugation by decapitation, a punishment toward worthy opponents by the infidels, possibly inadvertently aimed to belittle, dehumanize, and to silence him forever. Advertently however, it aimed to annihilate a praiseworthy if not celebrated leader of the Romans, to negate him of any proper funerary rights after death, to refute the physical location of a grave and any commemoration of a protagonist's burial, throwing his body to rot in oblivion. Yet, as it appears, despite those methods and schemes, it was fated that the decapitated commander of *Polystylon* would surface under the rays of sun once more, to prompt and to call in mind of forgotten legendary events, and of Polystylon's thermopylaean stance.

Acknowledgements

The author dedicates this article to the memory of his two doctoral research mentors and advisors from the School of Dental and Oral Surgery of Columbia University, Dr. Irwin D. Mandel and Dr. Sidney L. Harowitz.

The image of forensic anthropologic individuation (Fig. 8) was completed by Shannon Fitzgerald, BA, in a collaborative effort with Argie Agelarakis, MA, and the author. The medical illustration drawings (Figs. 11, 14, and 14a) were completed by Argie Agelarakis. The photographic images, unless otherwise indicated, are the author's.

141. Indicative that the fort did not surrender peacefully but that it must have been taken by force (*cebren*).



1) Aerial view of the *Polystylon* fort, courtesy of Dr. Ch. Bakirtzis, Ephor of the 12th Ephorate of Byzantine Antiquities-Hellenic Antiquities Authority in 1991. Arrows indicate the locus of “ΞΑ4” site.



2) During the archaeological investigations at “ΞΑ4” site.



3) Grave No. 13, at “ΞΑ4” site, after initial cleaning of superficial stratigraphic layer.



4) Grave No. 13, intra-contextual remains during the excavation and documentation process.




5) Grave No. 13, recovery of supra-abdominal skeletal remains of the young individual.



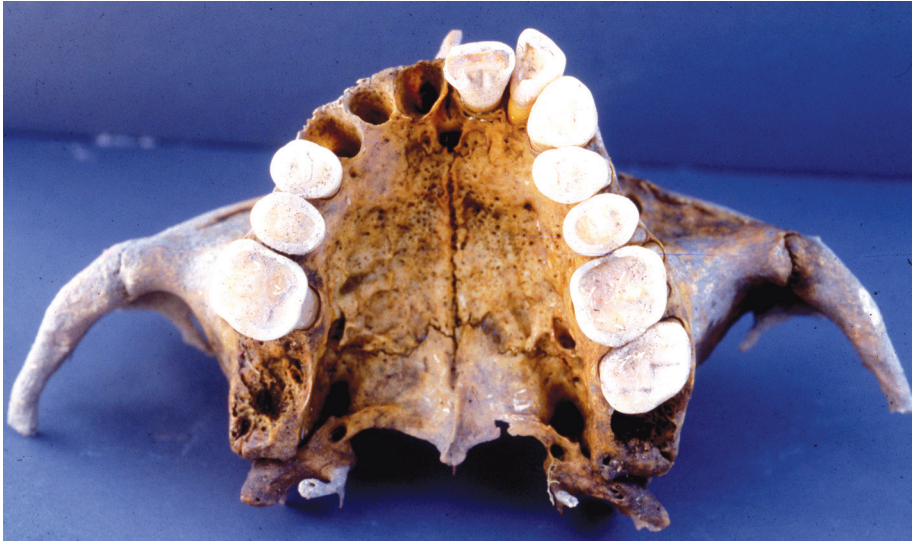6) Overview of Grave No. 13 placement within the funerary activity area of “ΞΑ4” site.



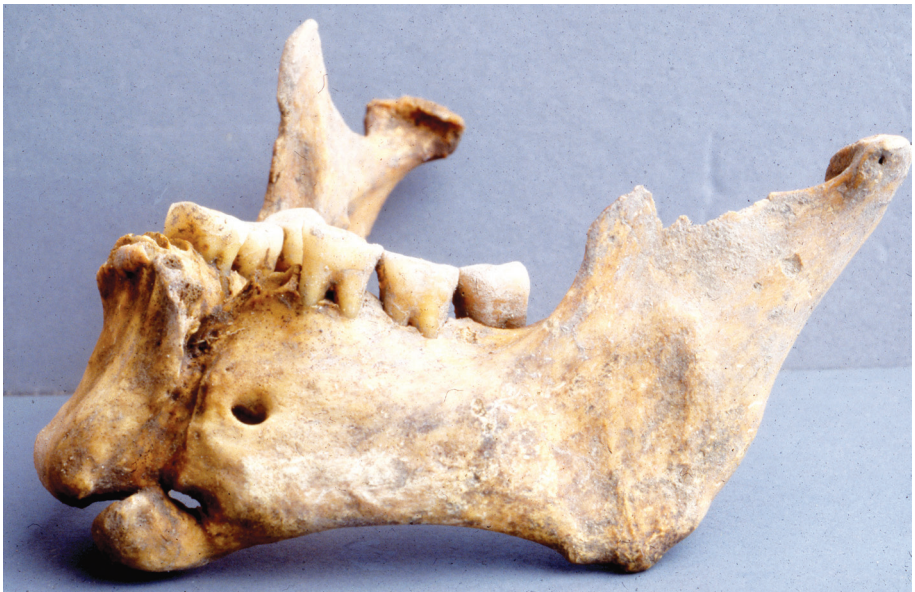7) Close up of decapitated individual and its spatial intra-contextual relations with the skeleton of the youth.



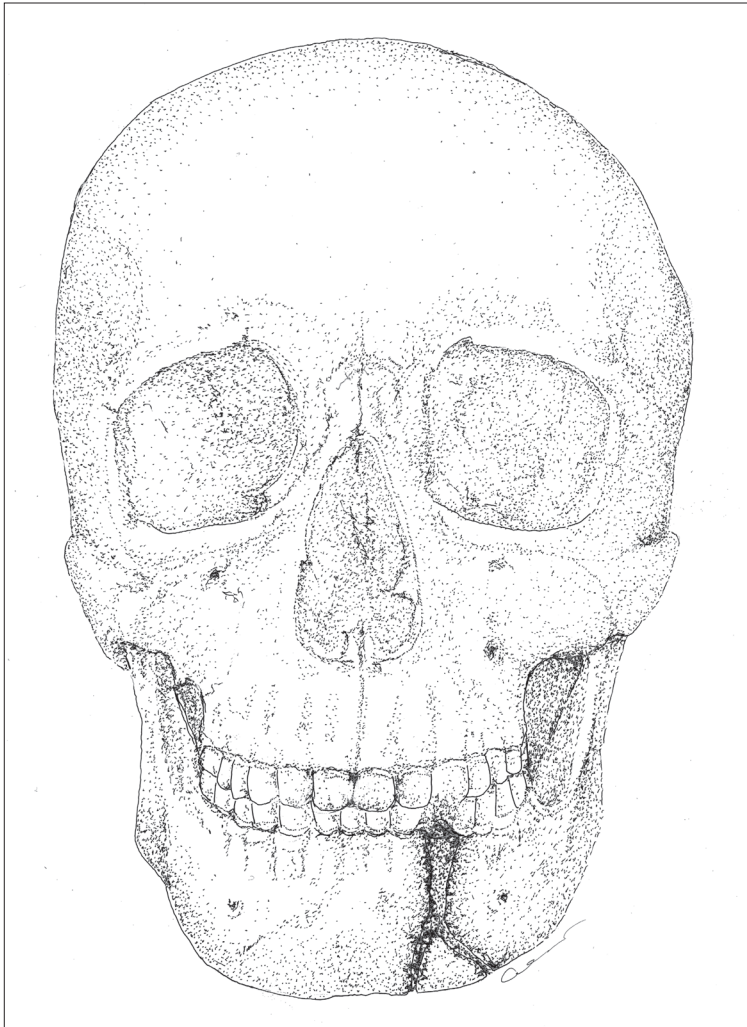
8) Medical illustration, individuation reconstruction of the decapitated individual as interred *in situ*, a rendering based on a synthesis of archaeo-anthropological and forensic biometric data.



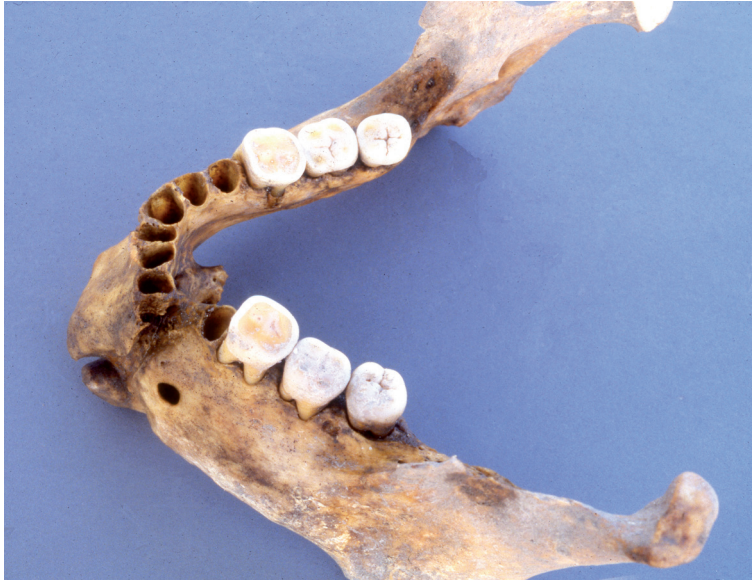9) Focus on the inferior maxillo-dental surfaces and dental alveoli of the decapitated individual.



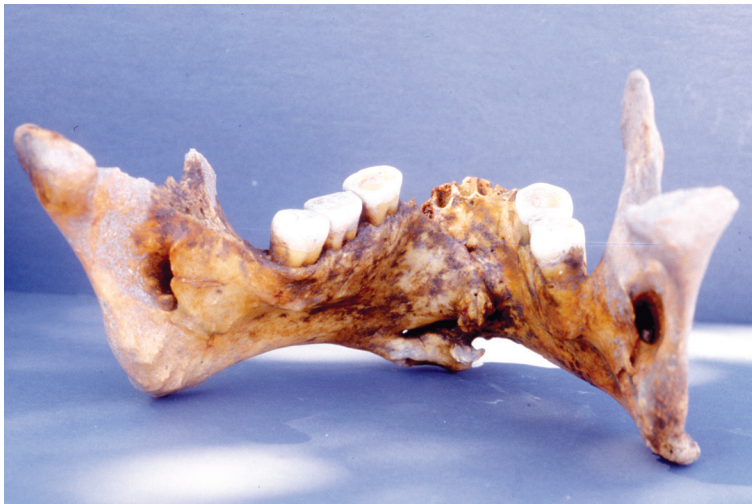10) Left ventro-lateral view of the mandible with a focus on the healed fracture, alveolar bone, and molars *in situ*.



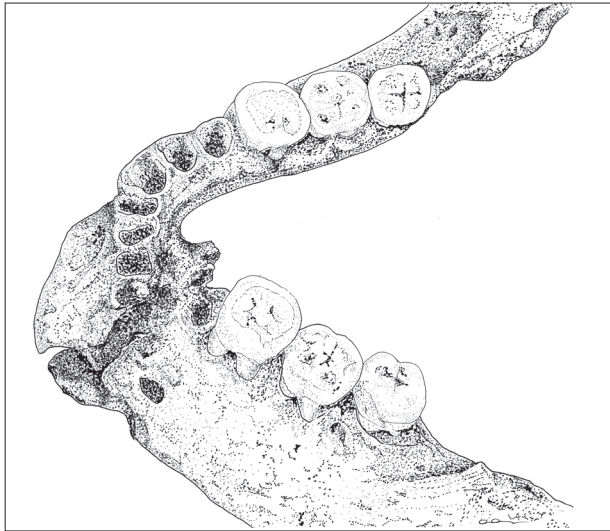
11) Technical in scale drawing, reconstruction of the cranial skeleton, in ventral view, showing the location and extent of *fractura mandibulae*.



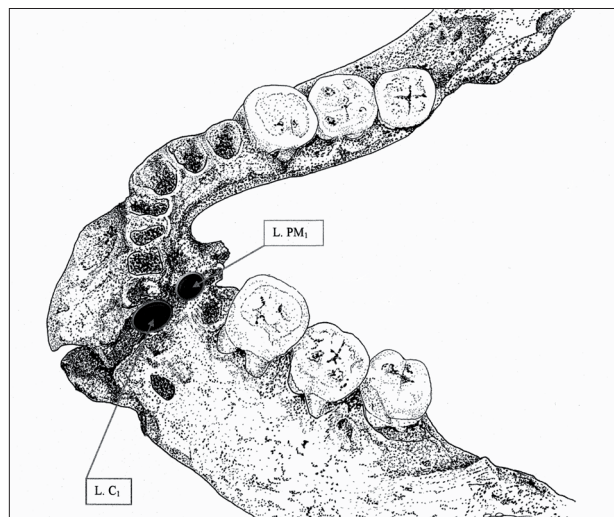
12) Left supero-lateral mandibular view showing the overriding misalignment of the mandibular parts.



13) Dorso-lingual view of mandible with a focus on the callus formation and subsequent dorso-ectopic loci of attachments on Ms. *genioglossus*, *geniohyoideus*, *digastricus*, and *mylohyoideus*.



14) Technical in scale drawing of a left supero-lateral mandibular view, showing the location of the healed fracture.



14a) Technical in scale drawing with a focus on the misalignment of the mandibular parts as demonstrated by the partial absence of the distal alveolar wall of the left lateral incisor (L. I₂), the obliterated dental alveoli of the left canine (L. C₁) and first premolar (L. PM₁).

Η ΑΛΩΣΗ ΤΟΥ ΦΡΟΥΡΙΟΥ *ΠΟΛΥΣΤΥΛΟΝ* ΑΠΟ ΤΟΥΣ ΟΘΩΜΑΝΟΥΣ:
ΤΟ ΙΣΤΟΡΙΚΟ ΠΛΑΙΣΙΟ ΚΑΙ Η ΠΕΡΙΠΤΩΣΗ ΤΟΥ ΑΠΟΚΕΦΑΛΙΣΜΕΝΟΥ ΥΠΕΡΑΣΠΙΣΤΗ ΤΟΥ

Στο άρθρο συνεξετάζονται αρχαιολογικά και ανθρωπολογικά δεδομένα από τις ανασκαφές στο Πολύστυλον/Άβδηρα. Οι ιστορικές μαρτυρίες από τον τελευταίο αιώνα του Βυζαντίου, συνδυάζονται με τις παλαιοπαθολογικές ενδείξεις από τα σκελετικά υπολείμματα ενός βυζαντινού πολεμιστή, και διαφωτίζεται η κατάσταση των ανθρώπων ιδιαίτερα στα χρόνια της πολιορκίας του φρουρίου *Πολύστυλον* (αρχαία Άβδηρα) από τους Οθωμανούς και της απέλπιδας αντίστασης των υπερασπιστών του.