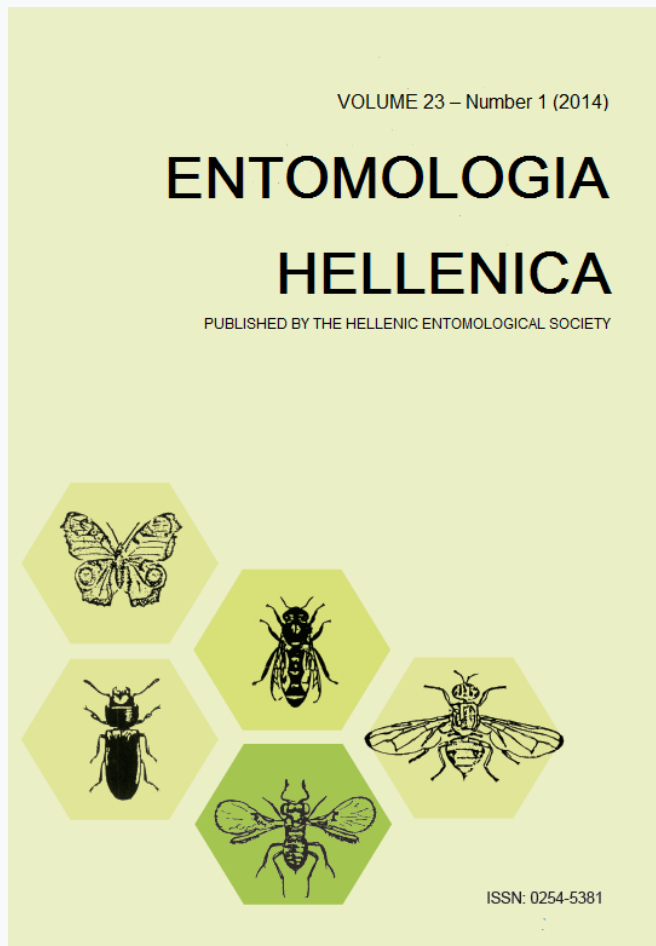


ENTOMOLOGIA HELLENICA

Vol 23, No 1 (2014)



Wound myiasis caused by *Lucilia sericata* in an open femoral fracture treated with external fixation

P. V. Flegkas, S. S. Andreadis, E. S. Andreadou, J. Delis, T. Moumtsidelis, M. Savopoulou-Soultani

doi: [10.12681/eh.11533](https://doi.org/10.12681/eh.11533)

Copyright © 2017, P. V. Flegkas, S. S. Andreadis, E. S. Andreadou, J. Delis, T. Moumtsidelis, M. Savopoulou-Soultani



This work is licensed under a [Creative Commons Attribution-NonCommercial-ShareAlike 4.0](https://creativecommons.org/licenses/by-nc-sa/4.0/).

To cite this article:

Flegkas, P. V., Andreadis, S. S., Andreadou, E. S., Delis, J., Moumtsidelis, T., & Savopoulou-Soultani, M. (2014). Wound myiasis caused by *Lucilia sericata* in an open femoral fracture treated with external fixation. *ENTOMOLOGIA HELLENICA*, 23(1), 39–42. <https://doi.org/10.12681/eh.11533>

Wound myiasis caused by *Lucilia sericata* in an open femoral fracture treated with external fixation

P.V. FLEGKAS¹, S.S. ANDREADIS^{2,3*}, E.S. ANDREADOU⁴, J. DELIS¹,
T. MOUMTSIDELIS¹ AND M. SAVOPOULOU-SOULTANI²

¹Orthopaedic Department, General Hospital of Giannitsa, Giannitsa, Greece

²Laboratory of Applied Zoology and Parasitology, School of Agriculture, Aristotle University of Thessaloniki, 54124 Thessaloniki, Greece

³Current address: Unit of Chemical Ecology, Department of Plant Protection-Biology, Swedish University of Agricultural Sciences, 23053 Alnarp, Sweden

⁴Department of Paediatrics, General Hospital of Thessaloniki "G. Gennimatas – Ag. Dimitrios", 54635 Thessaloniki, Greece

ABSTRACT

On examination of the wound of a patient who was treated previously with external fixation for a diaphysial fracture of the femur, we observed the presence of multiple living larvae (maggots) of dipterous flies. Treatment included removal of the maggots and use of antibiotic. The importance of hygiene and sanitation is discussed.

KEY WORDS: antibiotics, hygiene, larvae, sanitation, wound myiasis.

Introduction

Myiasis is derived from the Greek word, myia, meaning fly. It is used to describe infestations, both obligatory and accidental, in vertebrate animals and humans by certain dipterous larvae (maggots), which feed upon the living, necrotic or dead tissues for at least a period of time (Robbins and Khachemoune 2010, Sotiraki and Hall 2012). Human myiasis is a rare clinical condition but more frequently seen in underdeveloped countries and tropical and subtropical areas, which are associated with poor hygiene, bad housing conditions, suppurative lesions, alcoholism and senility (Verettas et al. 2008, Bayindir et al. 2012, Nagy 2012). Moreover, unsatisfactory wound care contributes to the development of myiasis on humans. Apart from tropical and subtropical areas, myiasis

can also exist in Europe especially during summer months mainly due to international travel, both for business and tourism (Krajewski et al. 2009, Hannam et al. 2011). Herein we report an unusual case of wound myiasis by maggots of the fly *Lucilia sericata* (Meigen) (Diptera: Calliphoridae) in a child who underwent external fixation to femoral shaft fracture due to open femur after a serious car accident.

Case report

A male child aged 14 years was admitted to the Emergency Department of the Hospital of Giannitsa, northern Greece. Case history revealed a 14-year-old child who has been treated approximately 6 months before with external fixation for a diaphysial fracture of the femur. The postoperative course and fracture union in frequent monitoring was

*Corresponding author: stefandreadis@yahoo.gr

normal. However, 15 days after the last review the child was admitted to the emergency department with extensive pain in the area of pins. Thus, we removed the body of the external fixation and then surgically cleaned the wound. At examination of the wound we observed redness, swelling and the presence of multiple larvae, known as maggots, of dipterous flies (Fig. 1). Maggots were carefully removed with forceps and sent for identification. They were 11–14 mm long, conical-shaped and whitish to pale yellow. Moreover, they had a smooth surface with no obvious body processes. The peritreme on their posterior spiracles was complete with a single indentation. The posterior spiracle had three lobes. These features were compatible with *L. sericata* larvae. The larvae were thus identified as third instar larvae of the species *L. sericata*. After 7 days of antibiotic therapy the pins were removed and after 3 months both clinically and radiologically results were very good.

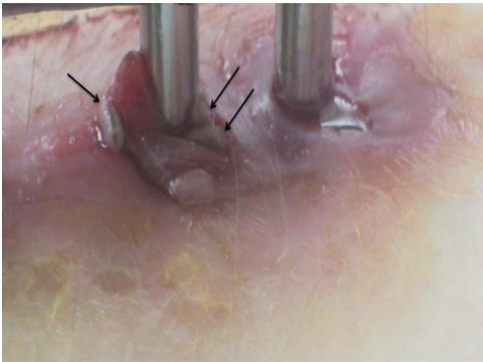


FIG. 1. Numerous third instar larvae of *L. sericata* (black arrows) infesting the soft tissues around the external fixation of the femur of the patient

Discussion

The green bottle fly, *L. sericata*, is known to be widely distributed throughout the world. In northern and central Europe it is one of

the most common facultative parasites which causes myiasis mainly in animals, and rarely in humans as an ectoparasite, leading to economic losses in the livestock industry and serious human health problems, respectively (Wang et al 2010, Savopoulou-Soultani et al. 2011, Sotiraki and Hall 2012). However, in other parts of the world such as in America, Africa, and Asia, it is considered to be the most known species in human infestation (Service 1996).

A case of wound myiasis caused by *L. sericata* occurred in a patient who underwent external fixation to femoral shaft fracture due to open femur after a serious car accident. Projected timing indicated that the eggs were laid while the patient was recovering at home. The development of myiasis was facilitated mainly by the physical debility and dependency of the patient, the presence of necrotic tissue in the wound which attracted the female flies and the period of the year which allowed increased fly activity. Treatment consisted of mechanical removal of the larvae and cleansing of the infected area with water and povidone iodine. The aim of the treatment was to remove the larvae and to treat any secondary infestation with antibiotics. The patient's clinical condition was controlled without the appearance of further signs of infestation.

Prevention against human myiasis is usually simple and adequate. Open wounds should be cleaned and irrigated intermittently, and proper clothing should be applied. Patients with any type of wound should clean the wound regularly, not be allowed to sleep outside and, if in an indoor or hospital environment, the windows should be opened with caution (Caissie et al. 2008). Similar cases to our observation were previously reported in a 67-year-old insulin-dependent diabetic woman and two elderly diabetic men with trochanteric fractures of the femur in a nearby region of Greece due to diabetes, immobilization, poor hygiene and low immune status. However, definition of the

exact species of fly responsible for the infestation could not be made due to the fly's larval stage (Verettas et al. 2008). To our knowledge, this case is the first to be reported of human wound myiasis caused by *L. sericata* in Greece. The importance of personal hygiene and sanitation even in rural areas especially during the summer period, when high fly population exists, is illustrated.

References

- Bayindir, T., M.T. Cicek, M. Atambay and A. Kizilay. 2012. Cutaneous myiasis in a malignant wound of the head and neck region. *J. Craniofac. Surg.* 23: e19-20.
- Caissie, R., F. Beaulieu, M. Giroux, F. Berthod and P.E. Landry. 2008. Cutaneous myiasis: Diagnosis, treatment and prevention. *J. Oral Maxillofac. Surg.* 66: 560-568.
- Hannam, P., K. Khairnar, J. Downey, J. Powis, F. Ralevski and D.R. Pillai. 2011. Cutaneous myiasis in traveler returning from Ethiopia. *Emerg. Infect. Dis.* 17: 2385-2386.
- Krajewski, A., B. Allen, D. Hoss, C. Patel and R.Y. Chandawarkar. 2009. Cutaneous myiasis. *J. Plast. Reconstr. Aesthet. Surg.* 62: 383-386.
- Nagy, V. 2012. Unusual presentation of the urogenital myiasis caused by *Lucilia sericata* (Diptera: Calliphoridae). *Ann. Agric. Environ. Med.* 19: 802-804.
- Robbins, K. and A. Khachemoune. 2010. Cutaneous myiasis: a review of the common types of myiasis. *Int. J. Dermatol.* 49: 1092-1098.
- Savopoulou-Soultani, M., S.S. Andreadis and C.V. Soultani-Zouroulidi. 2011. Insects and arthropods of medical importance [in Greek]. CopyCity Publish, Thessaloniki (Greece), 1st ed. 482 pp.
- Service, M.W. 1996. Medical entomology for students. Chapman and Hall. London, 1st ed. 278 pp.
- Sotiraki, S. and M.J.R. Hall. 2012. A review of comparative aspects of myiasis in goats and sheep in Europe. *Small Ruminant Res.* 103: 75-83.
- Verettas, D.A., C.N. Chatzipapas, G.I. Drosos, K.C. Xarchas, C. Staikos, P. Chloropoulou, K.I. Kazakos and A. Ververidis. 2008. Maggot infestation (myiasis) of external fixation pin sites in diabetic patients. *Trans. R. Soc. Trop. Med. Hyg.* 102: 950-952.
- Wang, X., M. Zhong, J. Wen, J. Cai, H. Jiang, Y. Liu, S.M. Aly and F. Xiong. 2012. Molecular characterization and expression pattern of an odorant receptor from the myiasis-causing blowfly, *Lucilia sericata* (Diptera: Calliphoridae). *Parasitol. Res.* 110: 843-851.

**Επιμόλυνση πύλης εισόδου βελονών εξωτερικής οστεοσύνθεσης
σε ανοικτό κάταγμα διάφυσης μηριαίου με προνύμφες του
Lucilia sericata (Diptera: Calliphoridae)**

**Π.Β. ΦΛΕΓΚΑΣ¹, Σ.Σ. ΑΝΔΡΕΑΔΗΣ^{2,3*}, Ε.Σ. ΑΝΔΡΕΑΔΟΥ⁴,
Ι. ΝΤΕΛΗΣ¹, Θ. ΜΟΥΜΤΖΙΔΕΛΛΗΣ¹
ΚΑΙ Μ. ΣΑΒΒΟΠΟΥΛΟΥ-ΣΟΥΛΤΑΝΗ²**

¹Ορθοπαιδική Κλινική, Γενικό Νοσοκομείο Γιαννιτσών, 58100 Γιαννιτσά

²Εργαστήριο Εφαρμοσμένης Ζωολογίας και Παρασιτολογίας, Γεωπονική Σχολή, Αριστοτέλειο
Πανεπιστήμιο Θεσσαλονίκης, 54124 Θεσσαλονίκη

³Current address: Unit of Chemical Ecology, Department of Plant Protection-Biology, Swedish
University of Agricultural Sciences, 23053 Alnarp, Sweden

⁴Τμήμα Παιδιατρικής, Γενικό Νοσοκομείο Θεσσαλονίκης "Γ. Γεννηματάς – Αγ. Δημήτριος",
54635 Θεσσαλονίκη

ΠΕΡΙΛΗΨΗ

Η μυΐαση είναι η τέταρτη πιο κοινή δερματική ασθένεια στον άνθρωπο που σχετίζεται με ταξίδια ενώ η δερματική μυΐαση είναι η συνηθέστερη κλινική μορφή. Αναφέρεται σε μη-ιατρογενή μόλυνση των ιστών από προνύμφες διπτέρων εντόμων και εμφανίζεται κυρίως σε ασθενείς που έχουν κακή υγιεινή, με συνθήκες κακής στέγασης, διανοητική καθυστέρηση, προχωρημένη ηλικία, διαβήτη, ακινητοποίηση και χαμηλό ανοσοποιητικό σύστημα. Ασθενής 14 ετών, ο οποίος είχε υποβληθεί πριν 6 μήνες σε εξωτερική οστεοσύνθεση μηριαίου λόγω κατάγματος διάφυσης μηριαίου, προσήλθε στα επείγοντα ιατρεία με άλγος στην περιοχή των βελονών. Κατά την εξέταση του τραύματος διαπιστώθηκε ερυθρότητα, οίδημα αλλά και η παρουσία ζωντανών προνυμφών διπτέρων εντόμων. Αφού ελέγχθηκε ακτινολογικά το κάταγμα της διάφυσης αφαιρέθηκε σε πρώτο χρόνο το σώμα της εξωτερικής οστεοσύνθεσης και έγινε σχολαστικότατος καθαρισμός. Με κατάλληλα χειρουργικά εργαλεία, απομονώθηκαν όλες οι προνύμφες από το τραύμα και τοποθετήθηκαν σε κατάλληλο υπόστρωμα για περαιτέρω εξέταση και προσδιορισμό του είδους. Έπειτα από μικροσκοπική εξέταση των προνυμφών και με βάση κατάλληλες μορφολογικές κλειδές προσδιορίστηκαν ως προνύμφες 3ης ηλικίας του είδους *Lucilia sericata* (Meigen) (Diptera: Calliphoridae). Έπειτα από 7 ημέρες αντιβιοτικής αγωγής ευρέως φάσματος, κλινοστατισμού, σχολαστικής περιποίησης των τραυμάτων και αφού είχαμε σαφή βελτίωση της περιοχής γύρω από τις βελόνες έγινε αφαίρεση αυτών. Κατά τις επανεξετάσεις έως και 6 μήνες μετά, τόσο κλινικά όσο και ακτινολογικά τα αποτελέσματα ήταν πολύ καλά.