Short Communication

Mediterranean Marine Science
Indexed in WoS (Web of Science, ISI Thomson) and SCOPUS
The journal is available on line at http://www.medit-mar-sc.net
DOI: http://dx.doi.org/10.12681/mms.1959

Fatal impalement of a blue shark *Prionace glauca* by a swordfish *Xiphias gladius*

J. PENADÉS-SUAY, J. TOMÁS and F.J. AZNAR

Marine Zoology Unit, Cavanilles Institute of Biodiversity and Evolutionary Biology, University of Valencia, Valencia, Spain

Corresponding author: jaime.penades@uv.es

Handling Editor: Argyro Zenetos

Received: 3 November 2016; Accepted: 19 March 2017; Published on line: 26 July 2017

Abstract

In September, 2016, an adult female blue shark (*Prionace glauca*) 247 cm long stranded alive on the coast of Valencia (Spain, Western Mediterranean) but died shortly afterwards. The necropsy revealed an ongoing pregnancy, with 65 embryos in the early stages of development, and a healthy condition with no signs of starvation. Two fishing hooks surrounded by scarred tissue were detected in the mandible, indicating past interaction with fisheries. In addition, a fragment of the tip of a swordfish (*Xiphias gladius*) rostrum (length: 18 cm long, width: 0.5 cm (distal) and 3 cm (proximal)) was removed from the animal. The fragment had pierced the head producing an incision of 3.5 cm width close to the left eye, crossing the head anterior to the pre-orbital process. No apparent damage was observed in the olfactory capsule or the eye, but the fragment had penetrated both sides of the skull causing extensive lesions in the brain, which were inferred to be the cause of death. Allometric analysis suggested that the swordfish was ca. 110 cm long, corresponding to a juvenile only 1-2 years old. Swordfish had previously been reported driving their rostrum into pelagic sharks, allegedly as a defensive strategy. However, this is the first report of impalement as the direct cause of death in blue sharks.

Keywords: Lethal interaction, impalement, *Prionace glauca*, *Xiphias gladius*, stranding, western Mediterranean.

Introduction

Swordfish (*Xiphias gladius* L.) are known for their highly active and aggressive behaviour. There are reports of swordfish driving its rostrum into a great variety of inanimate objects (e.g., Fierstine & Crimmen, 1996) and animals, including large fishes (e.g. Fierstine, 1997; Fierstine *et al.*, 1997), whales (Jonsgard, 1962), marine turtles (e.g., Frazier *et al.*, 1994), people (e.g., Haddad & De Figueiredo , 2009; Georgiadou *et al.*, 2010) and even submarines (Zarudski & Haedrich, 1974). This behaviour may result in a transverse fracture of the bill, leaving the distal segment embedded in the substratum. Here, for the first time, direct evidence is presented of a blue shark (*Prionace glauca* L.) killed by the interaction with a swordfish.

In September, 2016, an adult female blue shark was washed ashore on the coast of Valencia, Spain, in the western Mediterranean (39.55536º N, -0.28942º W). The animal was alive when found and performed slow swimming movements, but died shortly afterwards (Fig. 1A). It measured 247 cm in total length and 186 cm in fork length. The necropsy revealed no signs of starvation or macroscopic evidence of disease. Two fishing hooks sur-



Fig. 1: **A:** picture of a blue shark (*Prionace glauca* L.) which appeared stranded in the coast of Valencia province (East Spain, western Mediterranean) with a swordfish (*Xiphias gladius* L.) rostrum pierced in its skull. Scale indicates 50 cm. **B:** details of the bill's incision close to the left eye. Scale bar indicates 2 cm.

rounded by scarred tissue were detected after removing the mandible, indicating old interactions with fisheries. The shark was in the early stages of pregnancy, having 33 less developed embryos in the left uterus and 32 more developed embryos in the right uterus. An incision 35 mm long was found 11 mm anterior to the left eye (Fig. 1B). Upon close examination, a fragment of the tip of a billfish rostrum (length 18 cm, width 0.5 cm distally and 3 cm proximally) was discovered and removed from the incision. The fragment was orientated 30º with respect to the longitudinal axis and had pierced the head parallel to the dorsoventral plane, crossing the head anterior to the preorbital process without causing apparent damage to the olfactory capsule or the eye (Fig. 2A, B, C). However, it had penetrated through the skull causing significant lesions in the brain (Fig. 2A, B, C). Brain damage was inferred to be the cause of death.

The rostrum fragment (Fig. 3A) was identified as belonging to a swordfish based on the following combination of features (Fierstine & Voigt, 1996): (1) flattened appearance in cross-section (i.e., depth less than half of width); (2) absence of denticles on the surface, and (3) presence of central chambers in cross-section. To estimate the total length (TL) of the swordfish, the ratio of maximum width to length of the fragment (R) was calculated providing a value of 0.169 (Fig. 3B). Then, the point in which R≈ 0.169 was estimated in the rostrum of two swordfish specimens conserved at the Osteological Collection of the Department of Zoology, University of Valencia (Fig. 3A). Assuming an isometric relationship, the distance from the tip to the breaking point was one-third relative to total snout length (TSL). Thus, TSL in our swordfish specimen was calculated to be *ca*. 48 cm. The arrangement of the paired nutrient canals observed at the breaking point in our specimen was similar to that shown in cross-sections, at roughly the same distance from the tip, in a swordfish analysed by Habegger *et al.* (2015). The allometric regression between TSL and body length from post operculum to tail fork (BL) (McGowan, 1988) suggested that the individual had a BL ≈ 110 cm, corresponding to a juvenile 1-2 years old. The allometric regression between BL and round weight (RW) (Aliçli *et al.*, 2012) suggested a RW ≈ 20 kg.

Blue sharks are opportunistic predators that feed on a wide variety of cephalopods and fishes (Hernández-Aguilar *et al.*, 2015, and references therein), sometimes including swordfish in their diet (Vaske-Júnior *et al.*, 2009; Markaida & Sosa-Nishizaki, 2010). However, the weight of consumed individuals (*ca.* 1 kg, see Vaske-Júnior *et al.*, 2009) is by far smaller than that estimated for the swordfish that speared and killed the blue shark in this report. The question is, therefore, what was the type of interaction between these species. One possibility is that the blue shark and the swordfish accidentally collided while feeding through the same school of fish. This reason has been invoked to explain the impalement by billfishes on non-aggressive species, such as marine turtles (Frazier *et al.*, 1994). In these cases, it is believed that collisions occur because the target preys of billfishes are under the turtles so that the billfishes cannot turn or stop abruptly (Frazier *et al.*, 1994). It is clear, however, that billfishes can spear other animals on purpose, e.g., the reported attacks on large fishes (Starck 1960, Cliff et al. 1990, Fierstine

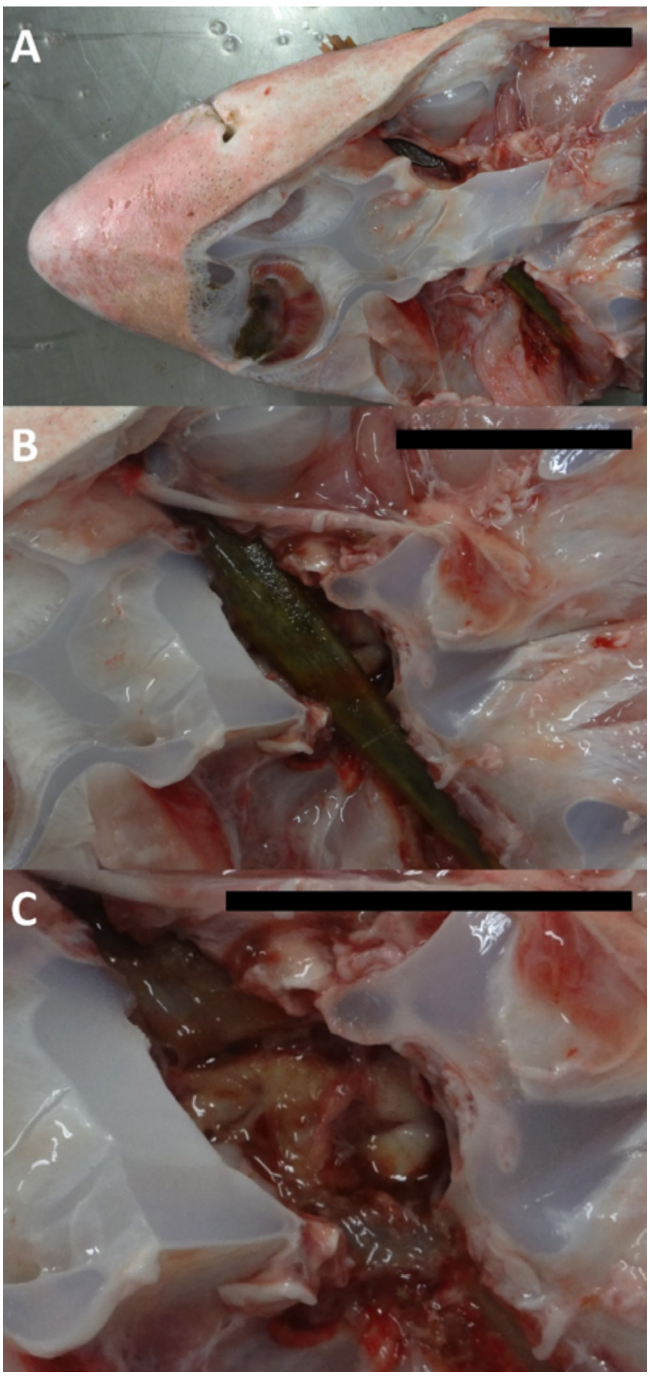

Fig. 2: Pictures showing the injury inflicted by a swordfish's bill to a blue shark: 'A' ventral view of the wound showing the bill perforating both sides of the skull, 'B' ventral view of the injury showing the bill's trajectory crossing the skull, 'C' ventral view of the lesion.

Fig. 3: The fragment of the swordfish (*Xiphias gladius* L.) rostrum found impaled in a blue shark (*Prionace glauca* L.) skull, in comparison to a bill from the Osteological Collection of the Zoology Department from the Universitat de València (Spain). 'A': distal fragment of the swordfish rostrum in the blue shark skull. Scale bar indicates 2 cm. 'B': Comparison with the specimen labelled as "J. L. Granel" which measured 83 cm (TSL). Scale bar indicates 15 cm.

1997). Thus, there is the possibility that, in the present case, the swordfish attacked the shark because it was considered a threat (see Fierstine, 1997).

An important point for future analysis is whether fatal impalements are anecdotal or represent a significant cause of mortality of sharks and other animals. Cases of impalement are probably overlooked, at least for two reasons (Fierstine, 1997). Firstly, oceanic 'victims' of billfish stabbing may suffer severe injuries or death and disappear without being noticed. Secondly, wounds caused by stabbing or slashing with the rostrum may not be easily detected or attributed to impalement unless a fragment of the rostrum remains after stabbing. Another question is whether billfishes use spearing as a typical defence strategy or only as a last resort behaviour. Numerous studies indicate that the bill has important hydrodynamic and feeding-related functions (Habegger *et al.*, 2015; Videler *et al.*, 2016), thus bill breakage could be seriously disadvantageous for billfishes. However, there are several reports of apparently healthy billfishes with damaged, malformed or even missing rostra (Frazier *et al.*, 1994).

There are previous reports of putative deadly interactions of swordfish and marine turtles (Frazier *et al.*, 1996), and one short report describing putative wounds in a bigeye thresher, *Alopias superciliosus*, similar to that reported in the present study (Vacchi et al. 1999). However, the present report is the first providing direct evidence of a shark death caused by a swordfish.

Acknowledgements

We thank the Servicio de Vida Silvestre, Conselleria de Agricultura, Medio Ambiente, Cambio Climático y Desarrollo Rural of the Valencian Government and the Stranding Network of the Valencian Community for logistic assistance. The Local Police of Massamagrell (Valencia, Spain) and the Service for the Protection of Nature (SEPRONA, Guardia Civil) helped us during the shark stranding event. Thanks are also due to Ángeles Raduán, from the Department of Zoology, University of Valencia, for making available swordfish specimens for bill comparison, and Pablo García for his assistance during the necropsy. The comments of two referees are greatly appreciated.

References

Aliçli, T. Z., Oray, I. K., Karakulak, F. S., Kahraman, A. E., 2012. Age, sex ratio, length-weight relationships and reproductive biology of Mediterranean swordfish, *Xiphias gladius* L., 1758, in the eastern Mediterranean. *African Journal of Biotechnology*, 11, 3673-3680.

Cliff G., Dudley S. F. J., Davis B., 1990. Sharks caught in the protective gill nets off Natal, South Africa. 3. The shortfin mako shark *Isurus oxyrinchus* (Rafinesque). *South African Journal of Marine Science*, 9, 115-126.

Fierstine, H. L., 1997. An Atlantic blue marlin, *Makaira nigricans*, impaled by two species of billfishes (Teleostei: Istiophoridae). *Bulletin of Marine Science*, 61, 495-499.

Fierstine, H. L., Crimmen, O., 1996. Two erroneous, commonly cited examples of "swordfish" piercing wooden ships. *Copeia*, 1996, 472-475.

Fierstine, H. L., Voigt, N. L., 1996. Use of rostral characters for identifying adult billfishes (Teleostei: Perciformes: Istiophoridae and Xiphiidae). *Copeia*, 1996, 148-161.

Frazier, J. G., Fierstine, H. L., Beavers, S. C., Achaval, F., Suganuma, H., Pitman, R. L., Yamaguchi, Y., Prigioni, C. M., 1994. Impalement of marine turtles (Reptilia, Chelonia: Cheloniidae and Dermochelyidae) by billfishes (Osteichthyes, Perciformes: Istiophoridae and Xiphiidae). *Environmental Biology of Fishes*, 39, 85-96.

Georgiadou, D., Zografos, G. N., Vaidakis, D., Avlonitis, S., Katopodi, A., Tzirakis, E. N., Sioutos, P., Drossos, C., Lampropoulou, P., Papastratis, G., 2010. Swordfish bill injury involving abdomen and vertebral column: case report and review. *BMC Surgery*, 10-30.

Habegger, M. L., Dean, M. N., Dunlop, J. W., Mullins, G., Stokes, M., Huber, D. R., Winters, D., Motta, P. J., 2015. Feeding in billfishes: inferring the role of the rostrum from a biomechanical standpoint. *Journal of Experimental Biology*, 218, 824-836.

Haddad, V., De Figueiredo, J. L., 2009. Attack upon a bather by a swordfish: a case report. *Wilderness & Environmental Medicine*, 20, 344-346.

Hernández-Aguilar, S. B., Escobar-Sánchez, O., Galván-Magaña, F., Abitia-Cárdenas, L. A., 2015. Trophic ecology of the blue shark (*Prionace glauca*) based on stable isotopes (δ 13 C and δ 15 N) and stomach content. *Journal of the Marine Biological Association of the United Kingdom*, 96, 1403-1410.

Jonsgard, A., 1962. Three finds of swords from swordfish (*Xiphias gladius*) in the Antarctic fin whale (*Balaeonoptera physalus* L.). *Norsk Hvalfangst-tidende*, 51, 287-291.

Markaida, U., Sosa-Nishizaki, O., 2010. Food and feeding habits of the blue shark *Prionace glauca* caught off Ensenada, Baja California, Mexico, with a review on its feeding. *Journal of the Marine Biological Association of the United Kingdom*, 90, 977-994.

McGowan, C., 1988. Differential development of the rostrum and mandible of the swordfish (*Xiphias gladius*) during ontogeny and its possible functional significance. *Canadian Journal of Zoology*, 66, 496-503.

Starck W. A., 1960. Spear of swordfish, *Xiphias gladius* Linnaeus, embedded in a silk shark, *Eulamia floridana* (Schroeder and Springer). *Quarterly Journal of the Florida Academy of Sciences 23:* 165-166.

Vacchi M., Serena F., Di Sciara G. N., 1999. On a large specimen of bigeye thresher shark *Alopias superciliosus* (Lowe, 1839) (Chondrichthyes: Alopiidae) stranded in Tavolara Island (eastern Sardinia, Mediterranean). In Seret B. and Sire J.-Y. (eds) *Proceedings of the 3rd European Elasmobranch Association Meeting, Boulogne-sur-47 Mer (France)*, 1999. Société Française d'Ichtyology and IRD, Paris: 3, 84. [Abstract]

Vaske-Júnior, T., Lessa, R. P., Gadig, O. B. F., 2009. Feeding habits of the blue shark (*Prionace glauca*) off the coast of Brazil. *Biota Neotropica*, 9, 55-60.

Videler, J. J., Haydar, D., Snoek, R., Hoving, H. J. T., Szabo, B. G., 2016. Lubricating the swordfish head. J*ournal of Experimental Biology,* 219, 1953-1956.

Zarudski, E. F. K., Haedrich, R. L., 1974. Swordfish (*Xiphius gladius*) attacks submarine (ALVIN). *Oceanology*, 3, 111-116.