

Mediterranean Marine Science

Vol 20, No 2 (2019)



Aggressive interactions between juvenile swordfishes and blue sharks in the Western Mediterranean: a widespread phenomenon?

JAIME PENADÉS-SUAY, PABLO GARCÍA-SALINAS,
JESÚS TOMÁS, FRANCISCO JAVIER AZNAR

doi: [10.12681/mms.18102](https://doi.org/10.12681/mms.18102)

To cite this article:

PENADÉS-SUAY, J., GARCÍA-SALINAS, P., TOMÁS, J., & AZNAR, F. J. (2019). Aggressive interactions between juvenile swordfishes and blue sharks in the Western Mediterranean: a widespread phenomenon?. *Mediterranean Marine Science*, 20(2), 314–319. <https://doi.org/10.12681/mms.18102>

Aggressive interactions between juvenile swordfish and blue sharks in the western Mediterranean: a widespread phenomenon?

Jaime PENADÉS-SUAY^{1,2}, Pablo GARCÍA-SALINAS^{2,3}, Jesús TOMÁS¹ and Francisco Javier AZNAR¹

¹Marine Zoology Unit, Cavanilles Institute of Biodiversity and Evolutionary Biology, Universitat de València, València, Spain

²Associació LAMNA per a l'estudi dels elasmobranquis a la Comunitat Valenciana

³Fundación Oceanogràfic

Corresponding author: jaime.penades@uv.es

Handling Editor: Fabrizio SERENA

Received: 23 June 2018; Accepted: 4 April 2019; Published on line: 4 June 2019

Abstract

There are numerous reports of billfishes spearing objects, marine organisms, and even humans. Whether or not this behaviour is intentional and, if so, what is its functional meaning, are open questions. In 2016, an adult blue shark (*Prionace glauca*) was found to be killed by a juvenile swordfish (*Xiphias gladius*) in the western Mediterranean. Here we report on four more recent cases involving both species in the same area. In February 2017, an adult male blue shark was found stranded in Garrucha (Spain) with a fragment of a juvenile swordfish's rostrum (18cm long x 2cm wide at proximal end) inserted in its cranium. In March 2017, an adult pregnant female blue shark was stranded alive on the coast of Ostia (Italy) but died shortly afterwards; a fragment of a juvenile swordfish's rostrum (25x3cm) was found allocated between the eye and the cranium. In February 2018, an adult female blue shark appeared stranded in the coast of Vera (Spain), with a putative impalement injury anterior to the right eye but without an associated bill fragment. Surprisingly, X-ray and computed tomography revealed an older injury in the right nostril, with a small piece of a juvenile swordfish's rostrum (5.3x1.2cm). Finally, in August 2018, an adult male blue shark appeared stranded alive in the coast of Manacor (Spain) with a fragment of swordfish bill (6.8x1.5cm) embedded in the snout. These cases suggest that juvenile swordfish would drive their rostrum into blue sharks as a defensive or territorial strategy that is likely to be far from anecdotal. We suggest that no regular cases of these interactions are reported because they occur at high sea and evidence of them, when available, can easily be overlooked.

Keywords: *Xiphias gladius*; *Prionace glauca*; lethal interaction; impalement; stranding; western Mediterranean.

Introduction

Over the last decades, impalement of inanimate objects and marine organisms by swordfish (*Xiphias gladius* L.) has been reported in a number of scientific publications and media news. There are reports of swordfish driving its rostrum into inanimate objects, such as vessels (Gudger 1940, Fierstine & Crimmen 1996), bales of rubber (Smith 1956) and submarines (Zarudski & Haedrich 1974). There are also reports of impalement on animals, such as large fishes (Starck 1960, Smith 1961), whales (Jonsgard 1962), marine turtles (Frazier *et al.* 1994 and references therein) and even people (e.g., Haddad & De Figuereido, 2009; Georgiadou *et al.*, 2010). Usually, these interactions are detected by the presence of the distal segment of the bill embedded in the substratum, which results from a transverse fracture of the bill due to the stress of the impact.

The functional meaning of this spearing behaviour is

still under discussion. Carey & Robinson (1981) reported evidence of intraspecific spearing events. In other billfishes similar cases have been accounted for accidental collisions. For instance, Fierstine *et al.* (1997) linked the injuries in other billfish species to the hypothetical collisions produced while feeding on the same bait ball. Likewise, impalement of marine turtles would occur when swordfish try to prey on the fishes that use shadow beneath turtles as cover (Frazier *et al.* 1994). In other cases, however, impalement has been interpreted as intentional (Smith 1956, Ellis 2013, for a detailed historical account). The clearest evidence of aggressive behaviour comes from cases involving humans, particularly when swordfish are provoked or disturbed (Georgiadou *et al.* 2010, and references therein; Romeo *et al.* 2017, and references therein), which has sometimes resulted in fatal spearing (Gooi *et al.* 2006). Descriptions of some of the events indicate that swordfish usually try to pierce its 'enemy' with the bill (Romeo *et al.* 2017).

Penadés-Suay *et al.* (2017) recently reported the case of a blue shark (*Prionace glauca* L.) apparently killed by a swordfish. An adult female blue shark stranded alive but died shortly afterwards, and the necropsy revealed a fragment of the tip of a young swordfish's rostrum that caused significant lesions in the brain. Penadés-Suay *et al.* (2017) raised the question whether or not impalements by swordfish are anecdotal, and to what extent swordfish uses spearing as defence behaviour. The answer to both questions deemed difficult because the literature contains mostly case studies, or reviews of 'fait-acompli' records scattered over long periods.

In the present paper we report evidence of four additional cases of impalement of blue sharks by swordfish that occurred between February 2017 and August 2018 in the western Mediterranean. Based on the new evidences, we suggest that impalement of blue sharks could be far from anecdotal and might represent an overlooked behaviour within the defensive or territorial strategy of juvenile swordfish.

Materials and Methods

The four shark specimens included in the present study were found dead on the beach at the moment of stranding or shortly afterwards. The sharks were measured *in situ* to the nearest cm and visually examined for external lesions. In two cases, a standard necropsy was carried out on the stranding beach (Figs. 1, 2). A detailed description of the injuries provoked by the swordfish rostrum was performed, and the rostrum fragment was collected, photographed and measured to the nearest mm. In the third case (Fig. 3), the intact head of the shark was carried out to the laboratory

for X-ray and computed tomography (CT). Diagnostic imaging studies included the following:

(1) Plain radiographic evaluation with a Philips Practix 400 unit (Philips Medical Systems) and a Kodak Direct View Classic CR System (Carestream Health) with 35 × 43 cm Kodak cassettes (Kodak PQ Storage Phosphor Screen Regular and 100 Microns, Carestream Health) in dorsal-ventral (DV) and lateral-lateral (LL) projections. Focal distance was 1 m, using exposure values 75 kV and 7.2 mAs based on animal size. Digital images were processed afterwards with Kodak Acquisition Software (Onyx-RAD Diagnostic Viewer) for better visualization and image interpretation.

(2) A CT was done using a Somatom Volume Access (Siemens). Acquisition parameters through head exploration of the blue shark were 5 mm slice thickness and 5 mm slice interval, with 0.5 mm retro-recon acquisition under lung and mediastinal algorithms. Images were post-processed with Osirix software version 3.3.1 (Pixmeo).

Rostrum fragments were identified as belonging to a swordfish (*X. gladius*) based on the following combination of features (Fierstine & Voigt 1996, Penadés-Suay *et al.* 2017): (1) flattened appearance in cross-section (i.e., depth less than half of width); (2) absence of denticles on the surface, and (3) presence of central chambers in cross-section. To estimate swordfish total body length (TL), the ratio of maximum width to length of the fragment (R) was calculated. Then, the rostrum of two swordfish specimens conserved at the Osteological Collection of the Department of Zoology, University of Valencia, were used to obtain the points in which the value of R was equal to the value obtained in each case (Penadés-Suay *et al.* 2017). Assuming an isometric relationship in the growth of the snout, total snout length (TSL) was



Fig. 1: 'A': Blue shark (*Prionace glauca* L.) stranded in the coast of Garrucha (East Spain, western Mediterranean) with a swordfish (*Xiphias gladius* L.) rostrum in its skull. Scale indicates 50 cm. 'B': details of the bill stuck close to the left eye. Scale bar indicates 5 cm. 'C': details of the fractured swordfish rostrum. Scale bar indicates 2 cm.



Fig. 2: 'A': blue shark (*Prionace glauca* L.) stranded in the coast of Ostia province (West Italy, western Mediterranean) with a swordfish (*Xiphias gladius* L.) rostrum piercing its skull. Scale bar indicates 50 cm. 'B': details of the bill's incision close to the right eye. Scale bar indicates 5 cm. 'C': details of the fractured swordfish rostrum. Scale bar indicates 2 cm.



Fig. 3: 'A': blue shark (*Prionace glauca* L.) stranded in the coast of Vera (East Spain, western Mediterranean) with a swordfish (*Xiphias gladius* L.) rostrum piercing its skull. Scale indicates 50 cm. 'B': details of the bill's incision close to the right eye. Scale bar indicates 5 cm. 'C': details of the fractured swordfish rostrum. Scale bar indicates 2 cm.

calculated for each case in relation to the distance from the tip to the breaking point. To add further correction, we observed the arrangement of the paired nutrient canals at the breaking point, as shown in cross sections, to compare it with a swordfish analysed by Habegger *et al.* (2015). The allometric regression between TSL and body length (BL), from post operculum to tail fork, was obtained following McGowan (1988).

Results

Case 1: Garrucha (Spain)

On the 17th of February, 2017, a dead adult male blue shark (TL: 236 cm) was found washed ashore on the coast of Garrucha (Almería), Spain, 37.1883333° N 1.8155556° W (Fig. 1A). The animal had an inci-

sive injury between the left eye and the snout. During the necropsy, the broken tip of a swordfish bill, measuring 180 mm long and 20 mm wide at the breaking point, was found inside the cranium (Fig. 1B). The bill entered the skull at 30° angle from the anteroposterior axis. The lesion was assumed to be the cause of death due to the associated brain damage. The broken tip found (Fig. 1C) could be part of a snout ca. 404 mm long, corresponding to a juvenile swordfish.

Case 2: Ostia (Italy)

On the 8th of March, 2017, an adult female blue shark (TL: 260 cm) was found stranded on the coast of Ostia, Italy, 41.70861111° N 12.32638889° E (Fig. 2A). The animal was alive when found, but died shortly afterwards. The shark showed an advanced state of pregnancy, with five developed embryos inside her uterus, and no sign of starvation or disease. An incision was visible between the first gill slit and the right eye. The necropsy revealed the presence of a swordfish bill penetrating the flesh between the optic capsule and the post-orbital process (Fig. 2B). Apparently, the incision did not damage any sensory organ. The swordfish fragment (Fig. 2C) was 250 mm long and 30 mm wide at its proximal end, corresponding also to a juvenile swordfish (snout ca. 505 mm long).

Case 3: Vera (Spain)

On the 28th of February, 2018, an adult female blue shark (TL: 260 cm) was found dead stranded in the coast of Vera (Almería), Spain, 37.19388889° N 1.81361111° W (Fig. 3A, 3B). An incision close to the right eye was found, entering the head at 20° angle from the anteroposterior axis. No fragment of bill was found by visual inspection. Both X-ray (Fig. 4A) and CT (Fig. 4B) also failed to find fragments of bill inside the incision but, surprisingly, revealed the presence of a distal fragment of swordfish bill inside the right nostril, anterior to the firstly detected injury. No external sign of injury was apparent in this case. The cavity of the nostril was surrounded by scarred tissue (Fig. 5). The broken tip of the bill (Fig. 3C) measured 53 mm long and 12 mm wide at its proximal end, corresponding also to a juvenile swordfish (snout ca. 242 mm long).

Case 4: Manacor (Spain)

On the 2nd of August, 2018, an adult male blue shark (TL: 293 cm) was found stranded and returned to the water by bystanders several times within an hour in the coast of Manacor (Balearic Islands), Spain, 39.457296° N 3.277984° W (Fig. 5A). By the time the rescue team arrived, the shark was motionless in lateral decubitus close to the shore, half meter deep in the water, without reacting to any stimulus. After euthanasia, the necropsy revealed signs of starvation and the presence of a distal fragment of a swordfish bill embedded in the snout (Fig. 5B). The fragment (Fig. 5C), measuring 68 mm long and 15 mm wide at its proximal end, had entered the centre of the snout from

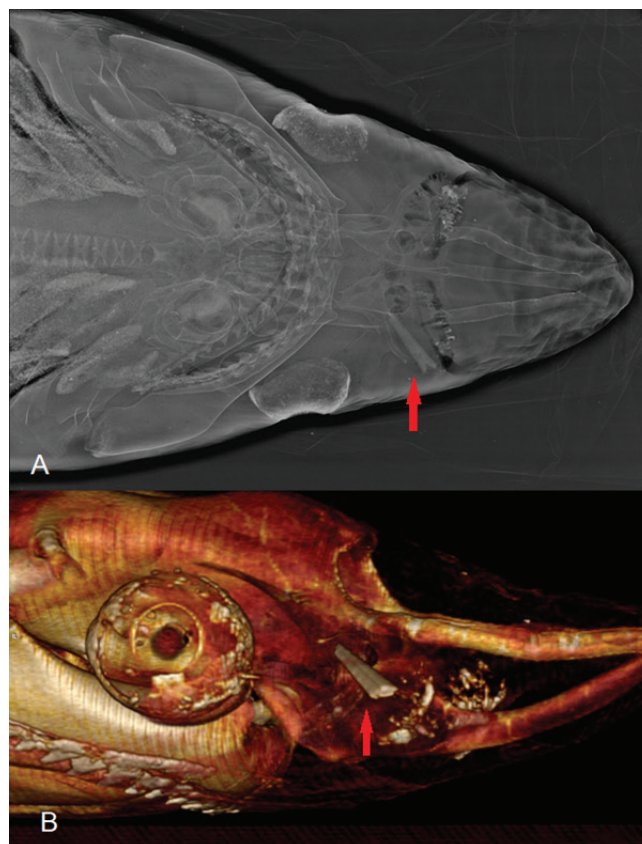


Fig. 4: Pictures showing the injury inflicted by a swordfish's bill to a blue shark stranded in Vera (Spain): 'A' ventral view of the injury with X-rays, showing the fractured bill allocated inside the nostril. 'B' lateral view of the wound using Computed Tomography, showing the bill perforating the nostril. Red arrows indicate the location of the swordfish' fractured bill in both pictures.

the right posterior side in a close angle to the anteroposterior axis of the shark and was identified as belonging to a juvenile swordfish (snout ca. 303 mm long).

Discussion

This survey reports four cases of impalement of blue sharks by juvenile swordfish in the western Mediterranean in less than two years. The question that arises is the extent to which such events are instances of accidental collision between both species or of purposeful behaviour. Although we cannot rule out the first possibility, there are some lines of evidence that conform to the hypothesis that swordfish could actually have intentionally hit sharks. Firstly, all cases here examined involved only small swordfish and adult blue sharks. There is the possibility that juvenile swordfish perceive large blue sharks as a threat, given that blue sharks are opportunistic predators that feed on a wide variety of cephalopods and fishes (Vaske-Júnior *et al.* 2009; Markaida & Sosa-Nishizaki 2010), and some studies of their diet included swordfish, although the size of swordfish consumed (*ca.* 1 kg, see Vaske-Júnior *et al.* 2009) seems to be smaller than that estimated for individuals in the present study. As noted



Fig. 5: 'A': blue shark (*P. glauca* L.) stranded on the coast of Manacor (Balearic islands, western Mediterranean) with a swordfish (*Xiphias gladius* L.) rostrum piercing its snout. Scale indicates 1 m. 'B': details of the bill's incision close to the centre of the snout. Scale bar indicates 5 cm. 'C': details of the fractured swordfish rostrum. Scale bar indicates 1 cm.

above, swordfish frequently displays pugnacious behaviour, even towards *prima facie* non-threatening species, including humans (Smith 1956, Georgiadou *et al.* 2010, Ellis 2013). Secondly, in all cases of impalement on blue sharks reported so far (Penadés-Suay *et al.* 2017; present study), the angle of piercing indicates a nearly horizontal strike with respect to the sharks' anteroposterior axis. Although there is no reason to exclude the possibility of an accidental collision during an act of predation to the same prey, a voluntary offense to the blue shark by juvenile swordfish is to be considered, given that the type of impalement described could hardly result from random collisions. Finally, at least the shark stranded in the coast of Vera showed signs of two diverse interactions with swordfish happened at different times, which would refer to two swordfish interactions.

In this context, one may wonder if swordfish use spearing as a typical defence strategy/territoriality aggression or only as a last resort behaviour against blue sharks. This is difficult to ascertain. On one hand, several studies suggest that the swordfish' bill has important hydrodynamic and feeding-related functions (Habegger *et al.* 2015, Videler *et al.* 2016) thus bill breakage could be seriously disadvantageous for swordfish. On the other hand, at least in billfishes, there are several reports of apparently healthy individuals with damaged, malformed or even missing rostra (Frazier *et al.* 1994). This raises the possibility that juvenile swordfish may experience a trade-off between the benefits of repelling a perceived serious threat and the potential impairment of swimming performance if the bill eventually breaks.

A third important question concerns the frequency of

such intentional impalements. The present study, and that by Penadés-Suay *et al.* (2017), report on stabbings that were inflicted on the head and, in some cases, resulted in the death of the victim. However, blue sharks are oceanic predators that only exceptionally are washed ashore when moribund or dead (hence the lack of studies reporting these events, see Neto *et al.* 2013). In general, most carcasses of large marine vertebrates disappear at sea (Carretta *et al.* 2016 and references therein). Hence, there is the possibility that many cases of fatal impalement of blue sharks have gone undetected because carcasses were consumed by scavengers or sank before they could be discovered. On the other hand, non-fatal impalement lesions could easily be overlooked. Blue sharks are target species of long-line fishery and, therefore, many individuals are visually exposed in fish markets. Also, the fact that only fragments from juvenile swordfish were found leaves the question on whether they are more prone to breakage than those of adults, giving then an added difficulty to finding evidence of the collisions in those cases. However, our study shows that not all impalements result in a breakage of the swordfish' bills, thus leaving only a small external incision that is difficult to draw attention or even to be noticed unless it is a specific target for examination. Moreover, old lesions are not visible externally, even when bill fragments remain in the scarred tissue, unless sophisticated technologies (X-rays, CT) are used, and only a deep, thorough necropsy could reveal the evidence of such past interactions. In fact, the finding of an old impalement in shark 3 in our study was serendipitous.

In conclusion, our study reports four cases within less than two years and only in the Western Mediterranean ba-

sin, suggesting the relevance of this phenomenon. As an additional example, there is one short report describing putative wounds in a bigeye thresher *Alopias superciliosus* (Vacchi *et al.* 2000), similar to the case of a blue shark reported in the same region by Penadés-Suay *et al.* (2017). More attention on this matter is needed, looking for evidences in all necropsy protocols and investigating this kind of interactions in other shark species.

Acknowledgements

We would like to thank Equinac for all their field work and assistance with the investigation in the first two cases from Spain, MedSharks (especially Aldo Marinelli, Simona Clò and Eleonora de Sabata) for their report and information from the case in Italy and Guillem Félix along with the team from Palma Aquarium and the Balearic Islands Government (Direcció General de Pesca de la Conselleria de Medi Ambient, Agricultura i Pesca de les Illes Balears) for their report on the last case. Special acknowledgement goes to the staff of the Veterinary Department of the Oceanogràfic Aquarium in Valencia for letting us use their equipments to take some of the images shown in this paper and, by doing so, allowing us to add further insight into the discussion. FJA and JT are supported by project PROMETEO III of the Generalitat Valenciana.

References

- Carey, F.G., Robinson, B.H., 1981. Daily patterns in the activities of swordfish, *Xiphias gladius*, observed by acoustic telemetry. *Fishery Bulletin*, 79, 277-292.
- Carretta, J.V., Danil, K., Chivers, S.J., Weller, D.W., Janiger, D.S., *et al.*, 2016. Recovery rates of bottlenose dolphin (*Tursiops truncatus*) carcasses estimated from stranding and survival rate data. *Marine Mammal Science*, 32 (1), 349-362.
- Ellis, R., 2013. *Swordfish: A biography of the ocean gladiator*. University of Chicago Press, Chicago, 279pp
- Fierstine, H.L., 1997. An Atlantic Blue Marlin, *Makaira nigricans*, impaled by two species of billfishes (Teleostei: Istiophoridae). *Bulletin of marine science*, 61 (2), 495-499.
- Fierstine, H.L., Crimmen, O., 1996. Two erroneous, commonly cited examples of "swordfish" piercing wooden ships. *Copeia*, 1996 (2), 472-475.
- Fierstine, H.L., Voigt, N.L., 1996. Use of rostral characters for identifying adult billfishes (Teleostei: Perciformes: Istiophoridae and Xiphiidae). *Copeia*, 1996, 148-161.
- Frazier, J.G., Fierstine, H.L., Beavers, S.C., Achaval, F., Sukanuma, H., 1994. Impalement of marine turtles (Reptilia, Chelonia: Cheloniidae and Dermochelyidae) by billfishes (Osteichthyes, Perciformes: Istiophoridae and Xiphiidae). *Environmental Biology of Fishes*, 39, 85-96.
- Georgiadou, D., Zografos, G.N., Vaidakis, D., Avlonitis, S., Kato podi, A., 2010. Swordfish bill injury involving abdomen and vertebral column: case report and review. *BMC Surgery*, 10 (1), 30.
- Gooi, B.H., Khamizar, W., Suhani, N.M., 2006. Swordfish attack – Death by penetrating head injury. Case Report. *Asian Journal of Surgery*, 30 (2), 158-159.
- Gudger, E.W., 1940. The alleged pugnacity of the swordfish and the spearfishes as shown by their attacks on vessels. *Royal Asiatic Society of Bengal*, 12, 215-315.
- Habegger, M.L., Dean, M.N., Dunlop, J.W., Mullins, G., Stokes, M., 2015. Feeding in billfishes: inferring the role of the rostrum from a biomechanical standpoint. *Journal of Experimental Biology*, 218, 824-836.
- Haddad, V., De Figueiredo, J.L., 2009. Attack upon a bather by a swordfish: a case report. *Wilderness & Environmental Medicine*, 20, 344-346.
- Jonsgard, A., 1962. Three finds of swords from swordfish (*Xiphias gladius*) in the Antarctic fin whale (*Balaenoptera physalus* L.). *Norsk Hvalfangst-tidende*, 51, 287-291.
- Markaida, U., Sosa-Nishizaki, O., 2010. Food and feeding habits of the blue shark *Prionace glauca* caught off Ensenada, Baja California, Mexico, with a review on its feeding. *Journal of the Marine Biology Association UK*, 90, 977-994.
- McGowan, C., 1988. Differential development of the rostrum and mandible of the swordfish (*Xiphias gladius*) during ontogeny and its possible functional significance. *Canadian Journal of Zoology*, 66, 496-503.
- Neto, D.G., Dos Santos, R.S., Maracini, P., Caltabellotta, F.P., Gadig, O.B.F., 2013. Strandings of the shortfin mako and the pelagic stingray on the coast of São Paulo state, southeastern Brazil: report of cases. *Boletim do Instituto de Pesca São Paulo*, 39 (2), 187-194.
- Penadés-Suay, J., Tomás, J., Aznar, F.J., 2017. Deadly impalement of a blue shark *Prionace glauca* by a swordfish *Xiphias gladius*. *Mediterranean Marine Science*, 18 (2), 340-343.
- Romeo, T., Ammendolia, G., Canese, S., Andaloro, F., Battaglia, P., 2017. Recent records of swordfish attacks on harpoon vessels in the Sicilian waters (Mediterranean Sea). *Acta Adriatica*, 58 (1), 147-156.
- Smith, J.L.B., 1956. Pugnacity of marlins and swordfish. *Nature*, 178, 1065.
- Smith, J.L.B., 1961. Battle of sea-giants. *Field and Tide*, 3 (9), 6-7.
- Starck, W.A., 1960. Spear of swordfish, *Xiphias gladius* Linnaeus, embedded in a silk shark, *Eulamia floridana* (Schroeder and Springer). *Quarterly Journal of the Florida Academy of Sciences*, 23, 165-166.
- Vacchi, M., Serena, F., Notarbartolo Di Sciara, G., 2000. On a large specimen of bigeye thresher shark *Alopias superciliosus* (Lowe, 1839) (Chondrichthyes: Alopiidae) stranded in Tavolara Island (eastern Sardinia, Mediterranean). p. 84. In: *Proceedings of the 3rd European Elasmobranch Association Meeting, Boulogne-sur-Mer (France), 27-29 May 1999*. Société Française d'Ichtyology and IRD, Paris.
- Vaske-Júnior, T., Lessa, R.P., Gadig, O.B.F., 2009. Feeding habits of the blue shark (*Prionace glauca*) off the coast of Brazil. *Biota Neotropica*, 9, 55-60.
- Videler, J.J., Haydar, D., Snoek, R., Hoving, H.J.T., Szabo, B.G., 2016. Lubricating the swordfish head. *Journal of Experimental Biology*, 219, 1953-1956.
- Zarudski, E.F.K., Haedrich, R.L., 1974. Swordfish (*Xiphias gladius*) attacks submarine (ALVIN). *Oceanology*, 3, 111-116.