

Journal of the Hellenic Veterinary Medical Society

Vol 62, No 2 (2011)



Tritrichomonas foetus: a new cause of diarrhea in cats in Greece

P. G. XENOULIS (Π.Γ. ΞΕΝΟΥΛΗΣ)

doi: [10.12681/jhvms.14842](https://doi.org/10.12681/jhvms.14842)

To cite this article:

XENOULIS (Π.Γ. ΞΕΝΟΥΛΗΣ) P. G. (2017). Tritrichomonas foetus: a new cause of diarrhea in cats in Greece. *Journal of the Hellenic Veterinary Medical Society*, 62(2), 132–140. <https://doi.org/10.12681/jhvms.14842>

Tritrichomonas foetus: a new cause of diarrhea in cats in Greece

Xenoulis P. G., DVM, Dr.med.vet., PhD

Department of Small Animal Clinical Sciences, College of Veterinary Medicine and Biomedical Sciences,
Texas A&M University, Texas, USA

Tritrichomonas foetus: μια νέα αιτία διάρροιας στις γάτες στην Ελλάδα

Π. Γ. Ξενούλης, DVM, Dr.med.vet., PhD

Τμήμα Κλινικών Επιστημών Μικρών Ζώων, Κτηνιατρική Σχολή, Πανεπιστήμιο Texas A&M, Τέξας, ΗΠΑ

ABSTRACT. Over the past few years, the protozoan parasite *Tritrichomonas foetus* (*T. foetus*) has emerged as a new and important cause of feline diarrhea in the international veterinary community. In a recent study, the presence of *T. foetus* was confirmed for the first time in cats in Greece. The protozoan parasite *T. foetus* has been primarily known as a cause of trichomoniasis in cattle. In this animal species, the parasite affects the reproductive system of both males and females and is associated with infertility and other reproductive problems. It was first described as a cause of feline diarrhea in 2003 in the United States. Since then, feline *T. foetus* -associated diarrhea has been reported in many countries around the world and, recently, it was, also, described in cats in Greece. The trophozoites of the parasite are excreted in the feces and healthy cats are infected with the ingestion of *T. foetus* trophozoites. *T. foetus* affects mainly the colon and the last part of the small intestine. *T. foetus*-associated diarrhea occurs mainly in young cats, but cats of any age can be infected and develop clinical signs. The main clinical sign is diarrhea, which may contain mucus or blood, and it often has spontaneous remissions and exacerbations. General clinical signs such as anorexia, weight loss and fever occur less frequently. If left untreated, the diarrhea often persists for months or years. In some cats, the clinical signs eventually resolve without treatment, but this can take up to 2 years. Moreover, these animals usually remain infected and are a source of infection for other cats (or humans) and often the clinical signs relapse in situations of stress. Feline *T. foetus* infection can be diagnosed mainly by: a) microscopic examination of fecal samples, b) fecal culture specific for *T. foetus* and c) fecal PCR. None of the above methods is diagnostic in 100% of cases and, therefore, these methods should be used in combination and bearing in mind the disadvantages of each method. Most antiparasitic and antibiotic drugs are not effective in treating diarrhea caused by *T. foetus*. Transient improvement can be seen with the use of common antibiotics or antiparasitic drugs, but the clinical signs typically recur with discontinuation of treatment. The only drug with proven efficacy against *T. foetus* in cats is ronidazol, which is usually used at a dose of 30 mg/kg, orally every 24 hours for 14 days. In some cases, the clinical signs recur with discontinuation of treatment but they usually resolve after one additional treatment cycle. The most serious side effect of ronidazole in cats is the development of neurological signs, but those usually resolve with discontinuation of treatment. Finally, *T. foetus* may be transmitted to humans, although this has not been proven.

Keywords: feline, gastrointestinal, diarrhea, infection, *Tritrichomonas foetus*, trichomoniasis

ΠΕΡΙΛΗΨΗ. Τα τελευταία περίπου πέντε χρόνια έχει γίνει γνωστό στη διεθνή κτηνιατρική κοινότητα ένα νέο αίτιο διάρροιας της γάτας, το πρωτόζωο *Tritrichomonas foetus* (*T. foetus*). Σε μια μελέτη η οποία δημοσιεύτηκε πρόσφατα, η παρουσία του

Correspondence: Xenoulis P. G.
Department of Small Animal Clinical Sciences, College of Veterinary Medicine & Biomedical
Sciences, Texas A&M University, Texas, 4474 TAMU, TX, 77843, USA
Tel: +1 979 458 3303, Fax: +1 979 458 4015, E-mail: pxenoulis@gmail.com

Αλληλογραφία: Π. Γ. Ξενούλης
Τμήμα Κλινικών Επιστημών Μικρών Ζώων, Κτηνιατρική Σχολή, Πανεπιστήμιο Texas A&M, Τέξας,
4474 TAMU, TX, 77843, ΗΠΑ
Τηλ.: +1 979 458 3303, Fax: +1 979 458 4015, E-mail: pxenoulis@gmail.com

Submission date: 17.05.2011
Approval date: 05.07.2011

Ημερομηνία υποβολής: 17.05.2011
Ημερομηνία εγκρίσεως: 05.07.2011

συγκεκριμένου παρασίτου επιβεβαιώθηκε για πρώτη φορά και στην Ελλάδα. Το πρωτόζωο παράσιτο *T. foetus* είναι κυρίως γνωστό ως το αίτιο της τριχομόνωσης των βοοειδών. Στο ζωικό αυτό είδος, το παράσιτο προσβάλλει το γεννητικό σύστημα τόσο των αρσενικών όσο και των θηλυκών και συνδέεται με στείρωση και άλλα αναπαραγωγικά προβλήματα. Ως αίτιο διάρροιας της γάτας περιγράφηκε για πρώτη φορά το 2003 στις Ηνωμένες Πολιτείες της Αμερικής. Διάρροια οφειλόμενη σε *T. foetus* έχει από τότε αναφερθεί σε πολλές χώρες και πρόσφατα περιγράφηκε και σε γάτες στην Ελλάδα. Το παράσιτο απεκκρίνεται με τα κόπρανα των μολυσμένων γατών και οι υγιείς γάτες μολύνονται με την κατάποση των τριχομονάδων που βρίσκονται στα κόπρανα. Προσβάλλει κυρίως το παχύ έντερο και την τελική μοίρα το λεπτού εντέρου. Διάρροια από *T. foetus* εμφανίζεται κυρίως σε νεαρές γάτες, όμως γάτες κάθε ηλικίας μπορούν να μολυνθούν και να εμφανίσουν κλινικά συμπτώματα. Κλινικά το κύριο χαρακτηριστικό είναι η διάρροια η οποία μπορεί να περιέχει βλέννα ή αίμα και η οποία συχνά παρουσιάζει υφέσεις και εξάρσεις. Γενικά συμπτώματα όπως ανορεξία, απώλεια βάρους και πυρετός εμφανίζονται λιγότερο συχνά. Χωρίς θεραπεία η διάρροια συχνά συνεχίζεται για μήνες ή χρόνια. Σε μερικές γάτες, τα κλινικά συμπτώματα κάποια στιγμή υποχωρούν χωρίς θεραπεία, αλλά μπορεί να χρειαστεί μέχρι και 2 χρόνια για να συμβεί αυτό. Επιπλέον, τα ζώα αυτά συνήθως παραμένουν μολυσμένα και αποτελούν πηγή μόλυνσης για άλλες γάτες (ή και τον άνθρωπο), ενώ πολλές φορές τα συμπτώματα υποτροπιάζουν σε καταστάσεις καταπύησης. Η διάγνωση της μόλυνσης της γάτας από *T. foetus* μπορεί να γίνει με τρεις, κυρίως, τρόπους: α) με μικροσκοπική εξέταση κοπράνων, κατά την οποία είναι δυνατός ο εντοπισμός τροφοζωιδίων του παρασίτου, β) με ειδική καλλιέργεια κοπράνων και γ) με PCR σε δείγματα κοπράνων. Καμία από τις παραπάνω μεθόδους δεν είναι διαγνωστική στο 100% των περιπτώσεων και, κατά συνέπεια, οι μέθοδοι αυτές θα πρέπει να χρησιμοποιούνται σε συνδυασμό και λαμβάνοντας υπ' όψιν τα μειονεκτήματα της κάθε μεθόδου. Οι περισσότερες αντιβιοτικές και αντιπαρασιτικές ουσίες δεν είναι αποτελεσματικές για την αντιμετώπιση της διάρροιας που οφείλεται σε *T. foetus*. Παροδική βελτίωση μπορεί να υπάρξει με τη χρήση αντιβιοτικών ή αντιπαρασιτικών φαρμάκων, τα συμπτώματα όμως επανεμφανίζονται μετά τη διακοπή της θεραπείας. Το μόνο φάρμακο με αποδεδειγμένη αποτελεσματικότητα κατά της *T. foetus* στη γάτα είναι η ρονιδαζόλη, η οποία συνήθως χρησιμοποιείται στη δόση των 30 mg/kg, από το στόμα, κάθε 24 ώρες για 14 ημέρες. Σε ορισμένες περιπτώσεις, τα συμπτώματα υποτροπιάζουν μετά το τέλος της θεραπείας, αλλά συνήθως υποχωρούν μετά από έναν επιπλέον κύκλο θεραπείας. Η πιο σοβαρή παρενέργεια από τη χρήση ρονιδαζόλης στη γάτα είναι η εμφάνιση νευρικών συμπτωμάτων τα οποία, όμως, συνήθως υποχωρούν με διακοπή της θεραπείας. Τέλος, η *T. foetus* πιθανόν να μεταδίδεται και στον άνθρωπο αν και αυτό δεν έχει αποδειχθεί.

Λέξεις ευρετηρίασης: γάτα, γαστρεντερικό, διάρροια, λοίμωξη, *Trichomonas foetus*, τριχομόνωση

INTRODUCTION

Over the past few years, the protozoan parasite *Trichomonas foetus* (*T. foetus*) has emerged as a new and important cause of feline diarrhea in the international veterinary community (Tolbert and Gookin 2009). In a recently published study, the presence of this parasite was confirmed for the first time in cats in Greece (Xenoulis et al. 2010a). Given the worldwide distribution and importance of this parasite in feline medicine, a concise and practical discussion on this topic seemed necessary in order to inform feline practitioners in Greece.

ETIOLOGY

T. foetus is a flagellated protozoan obligate parasite that does not form cysts and it is transmitted from host to host in the form of trophozoites (Stockdale et al. 2006, Tolbert and Gookin 2009; Figure 1). It is primarily known as the cause of trichomoniasis in cattle, in which it affects the genitourinary tract of both male and female animals and causes infertility and other reproductive problems. It was first described as a cause of feline diarrhea in the United States in 2003 (Levy et al. 2003). Previous studies published in the

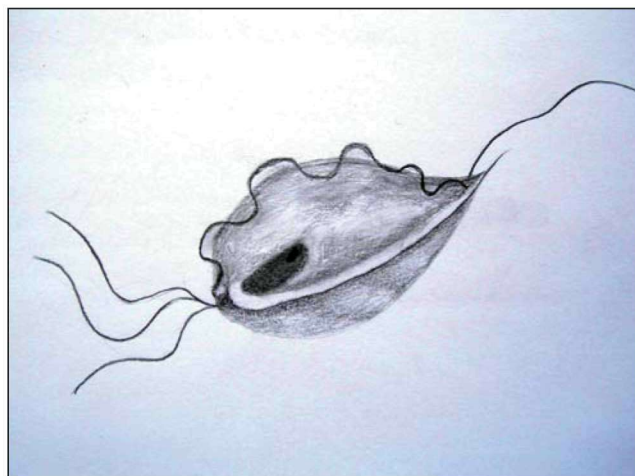


Figure 1. Line drawing of a *T. foetus* organism. There are three anterior and one posterior flagella. Note the undulating membrane and the single nucleus.

late 1990s had reported a small number of cats with trichomonal diarrhea, but the exact identification of the parasite was not reported (Romatowski 1996, Romatowski 2000). The origin of feline *T. foetus* is unknown. Although initially it was believed that *T. foetus* isolates from cats were identical to the ones

causing disease in cattle, recent evidence suggests that the isolates from those two animal species are genetically distinct (Slapeta et al. 2010). There is currently no evidence that feline *T. foetus* originated from cattle (Stockdale et al. 2007, Slapeta et al. 2010).

PREVALENCE OF INFECTION

Since 2003 and the first reports of *T. foetus* as a cause of diarrhea in cats in the United States, the existence of *T. foetus* has been reported in many countries around the world (for example, many European countries, Canada, Australia, New Zealand, Korea), including Greece (Gunn-Moore et al. 2007, Steiner et al. 2007, Bissett et al. 2008, Frey et al. 2009, Holliday et al. 2009, Pham 2009, Xenoulis et al. 2010a). The prevalence of infection of cats with *T. foetus* depends mainly on the location (country), the cat population tested and the diagnostic methods used. The reported prevalence of feline *T. foetus* infection varies from 10% to 32% (Gookin et al. 2004, Gunn-Moore et al. 2007, Steiner et al. 2007, Bissett et al. 2008, Frey et al. 2009, Holliday et al. 2009, Stockdale et al. 2009). In Greece, 19.4% of 31 cats tested were found to be infected with *T. foetus* (Xenoulis et al. 2010a).

PATHOGENESIS

The pathogenesis of *T. foetus* infection in the cat has been investigated in both experimental and clinical studies (Gookin et al. 2001, Foster et al. 2004, Tolbert and Gookin 2009). Trophozoites of the parasite are transmitted from cat to cat via the fecal-oral route (no cysts are formed by the parasite). *Tritrichomonas foetus* trophozoites are present in the feces of infected cats, where they can survive for several days if the feces remain moist. Healthy cats are infected after swallowing of live *T. foetus* trophozoites. Therefore, the source of infection of healthy pet cats is usually the litter box, where their paws get in touch with the feces of infected cats and the trophozoites of the parasite get ingested during grooming. There is no convincing evidence that reproductive tract infection plays any role in the transmission of *T. foetus* in cats (Gray et al. 2010). *T. foetus* affects mainly the colonic mucosa and the mucosa of the last part of the small intestine (Gookin et al. 2001, Yaeger and Gookin 2005).

SIGNALMENT

Cats of any age, breed or sex can be infected with *T. foetus*. Purebred and young cats that are densely

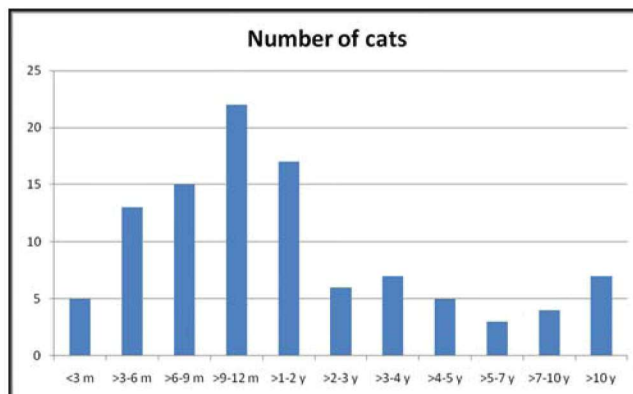


Figure 2. Age distribution of cats diagnosed with intestinal *T. foetus* infection. Based on data from: Xenoulis et al. Intestinal *T. foetus* infection in cats: a retrospective study of 104 cases. 28th Annual ACVIM Forum, J Vet Intern Med 2010;24:750. (m=months, y=years).

housed (e.g., cats in catteries, pet shops, animal shelters, multi-cat households) seem to be at increased risk (Gookin et al. 2004, Tolbert and Gookin 2009). Infection that is associated with clinical signs is most commonly seen in young cats (i.e., those that are less than 12 months of age), but older cats may, also, be infected and develop clinical signs. The reported age range for feline *T. foetus* infection is 3 months to 13 years (Xenoulis et al. 2010b; Figure 2). The infection is often asymptomatic in adult cats and these cats constitute an important source of infection for other cats (Tolbert and Gookin 2009, Xenoulis et al. 2010a).

CLINICAL PICTURE

The clinical signs of *T. foetus* infection in cats can vary greatly, ranging from asymptomatic infections to severe chronic refractory diarrhea (Gookin et al. 2001, Foster et al. 2004, Tolbert and Gookin 2009). Adult cats may be less likely to develop clinical signs than younger cats. Clinical signs are often intermittent. The most common clinical sign is chronic or recurrent diarrhea, which most commonly is large bowel and is characterized by soft or liquid feces, increased frequency of defecation, and might contain mucus or fresh blood (Gookin et al. 2001, Foster et al. 2004, Tolbert and Gookin 2009, Xenoulis et al. 2010b; Figure 3). The diarrhea (or even the stool with normal consistency in infected but asymptomatic cats) is often reported to be extremely malodorous. The duration of the diarrhea can range from days to years (Gookin et al. 2001, Foster et al. 2004, Tolbert and Gookin 2009,

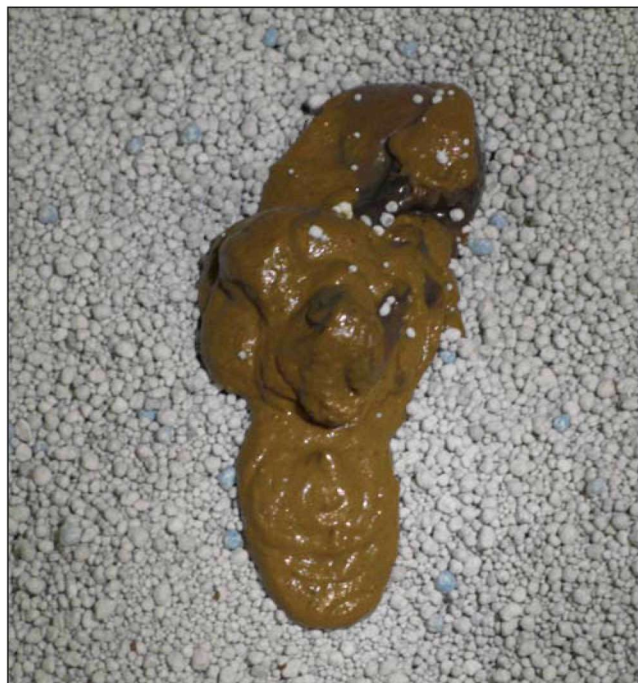


Figure 3. Typical appearance of a fecal sample from a cat with *T. foetus* infection. The feces are poorly formed and may or may not contain mucus or blood.

Xenoulis et al. 2010b). Due to the fact that many cats acquire the infection in catteries or pet shops, many owners report clinical signs since adaption or shortly after (Xenoulis et al. 2010b). In cats with severe chronic diarrhea, the anal region can become edematous and painful and incontinence might be present (Tolbert and Gookin 2009). Tenesmus may, also, be seen. Typically, the overall health of the infected cat is not affected. Other clinical signs such as anorexia, depression, vomiting, weight loss and fever may occur in some cats but are not very common (Xenoulis et al. 2010b; Figure 4). When such signs are present, they are more likely to be the result of concurrent diseases rather than the intestinal *T. foetus* infection (Xenoulis et al. 2010b).

If left untreated, *T. foetus*-associated diarrhea often persists intermittently for several months, years or even for the rest of the animal's life (Foster et al. 2004, Tolbert and Gookin 2009, Xenoulis et al. 2010b). While in most cats diarrhea usually resolves spontaneously at some point, this might take several months or years, and these cats will often experience recurrent bouts of diarrhea after being exposed to stress (e.g., surgery, travel, adaption of a new animal,

| Clinical sign | Percentage of cats |
|------------------------------|--------------------|
| Diarrhea | 98,1 |
| Anorexia | 27,2 |
| Depression | 23,5 |
| Weight loss/ failure to gain | 19,8 |
| Vomiting | 19,4 |
| Fecal incontinence | 14,9 |
| Hyperthermia | 13,8 |
| Abdominal pain | 8,9 |
| Increased appetite | 2,9 |

Figure 4. Clinical signs and their frequencies in 104 cats with intestinal *T. foetus* infection. Based on data from: Xenoulis et al. Intestinal *T. foetus* infection in cats: a retrospective study of 104 cases. 28th Annual ACVIM Forum, J Vet Intern Med 2010;24:750.

diet change). The majority of untreated cats usually remains infected even after clinical resolution of diarrhea and can transmit the parasite to healthy cats (Foster et al. 2004, Tolbert and Gookin 2009).

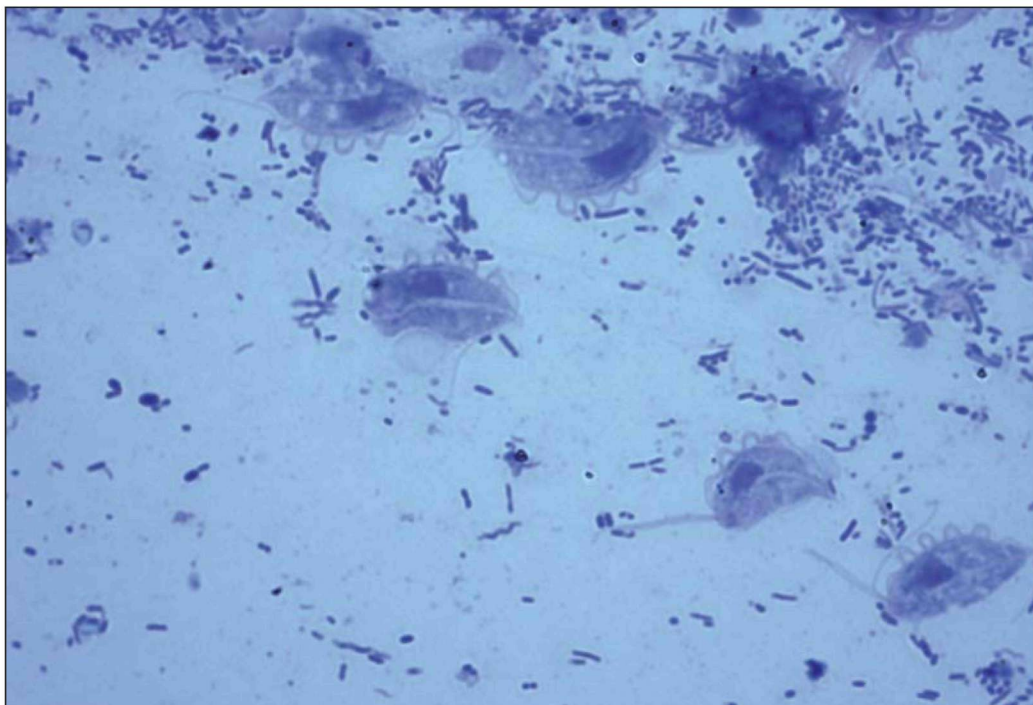
WHICH CATS SHOULD BE TESTED?

Ideally, every cat with diarrhea (especially with large bowel diarrhea) should be tested for *T. foetus* infection. Young cats and cats from multi-cat environments with diarrhea seem to be at increased risk and testing is highly recommended in these cases. Similarly, cats with an incomplete response to standard antibiotic treatment (e.g., tylosin or metronidazole) or with a relapse after discontinuation of medication are highly suspect for a *T. foetus* infection. Furthermore, cats that are unresponsive to treatment for suspected *Giardia* spp. infection should be tested for *T. foetus* infection, as the two parasites often coexist and are often confused on routine fecal smear evaluation.

DIAGNOSIS

The diagnosis of *T. foetus* infection can be made with the following three methods: a) direct fecal smear examination, b) fecal culture, and c) PCR analysis of fecal material. Diagnosis can, also, be made by histopathological examination of colonic biopsies, but due to its invasiveness, this method is not routinely used. None of the tests mentioned above is 100% sensitive and specific for *T. foetus*. Thus, combinations of these tests are usually indicated. *T. foetus* does not have a cyst stage and, therefore, fecal flotation and sedimentation techniques are rarely useful for the

Figure 5. Five *T. foetus* organisms in a fecal smear from an infected cat. Note the single nucleus and the undulating membrane of each microorganism. The anterior flagella are also visible. (Diff-Quick; magnification: 400x; Photo courtesy of Dr. Jody Gookin, North Carolina State University)



diagnosis of *T. foetus* infection.

Direct fecal smear examination

Direct examination of fecal smears should be performed in every cat with diarrhea, not only to look for *T. foetus* trophozoites but, also, for other infectious agents (e.g., *Giardia* spp.). It is crucial that multiple fecal smears are examined because this significantly increases the sensitivity of the method (Gookin et al. 2004, Tolbert and Gookin 2009). It is, also, important to use freshly voided fecal samples (less than 6 hours old and ideally less than 2 hours old) or samples collected directly from the rectum (preferably using the saline flash method) in order to ensure survival of the microorganism (Hale et al. 2009, Tolbert and Gookin 2009). This is important because motility of the trophozoites of the microorganism facilitates its identification. Not freshly voided, dried-out, refrigerated or frozen feces do not contain live *T. foetus* organisms and complicate diagnosis. In addition, diarrheic feces that contain mucus or blood should be preferred because *T. foetus* microorganisms are more likely to be found in these samples. Some authors, also, recommend discontinuation of antibiotics a few days before sampling (Tolbert and Gookin 2009). A small amount of fresh feces is placed on a microscope slide, mixed with a drop of saline (0.9%), covered with a

coverslip and examined under a light microscope. Smears must be rather thin to ensure that the parasites are visible. After the slide has been checked for motile trophozoites, Lugol, methylene blue or Diff-Quick staining may be used to facilitate morphological identification of the microorganism.

T. foetus trophozoites are characterized by rapid forward motion and can be seen at magnifications of at least 100x, although their structural characteristics are better seen at 400x (Tolbert and Gookin 2009). *T. foetus* can be easily confused with *Giardia* spp. because they both have similar size. The two microorganisms can be differentiated based on their structural differences (e.g., in contrast to *Giardia* spp., *T. foetus* has a single nucleus and an undulating membrane) and the characteristic rapid forward motion of *T. foetus* (Figure 5). However, experience and appropriate equipment is required for accurate differentiation. *T. foetus* might, also, be difficult to distinguish from the non-pathogenic *Pentatrichomonas hominis* (*P. hominis*), which is considered to be part of the normal microbiota in many animals (Tolbert and Gookin 2009). This means that, in the case of the identification of a microorganism that looks like *T. foetus*, one cannot be 100% confident that this is what it is, only based on the microscopic appearance. The main limitation of direct fecal smear examination is its low sensitivity,

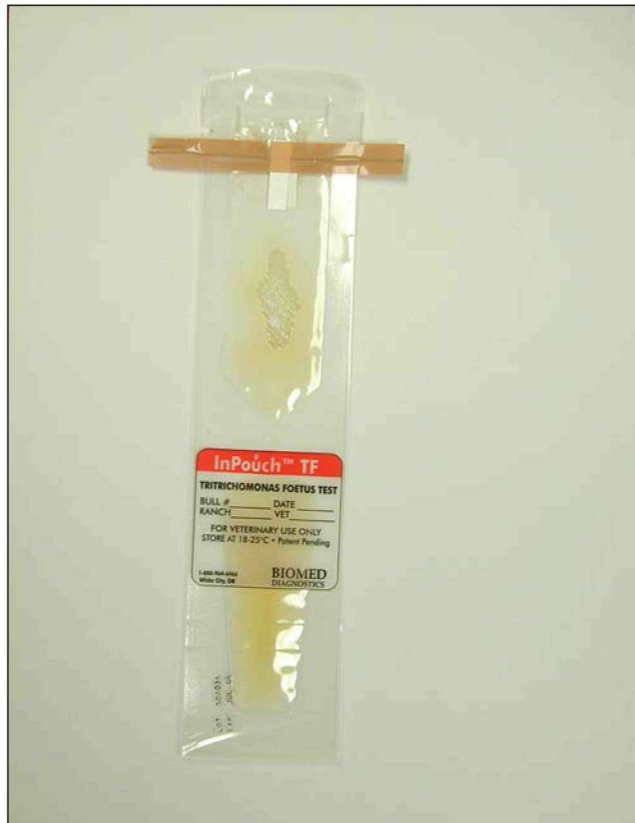

Figure 6. A pouch used for feline *T. foetus* culture. (Photo courtesy of Dr. Mike Willard, Texas A&M University).

which, in one study, was reported to be as low as 14% (Gookin et al. 2004). Therefore, it is important to note that a negative fecal smear examination result (even when multiple smears are examined) does not exclude the infection. Examination of multiple fecal smears is thought to increase the sensitivity of the method.

Culture

T. foetus can be cultured in-house (i.e., there is no need to send samples to a laboratory) using the commercially available culture system “In PouchTF” (Biomed Diagnostics, Inc, White City, Oregon, USA); Gookin et al. 2003, Tolbert and Gookin 2009; Figure 6). Pouches should be inoculated with less than 0.1 g of freshly voided feces (less than 2 hours old) and then incubated in the dark at 25 °C for up to 12 days or at 37 °C for 2 days. Incubation at 25 °C is preferred by the author because overgrowth seems to be less common. Overgrowth will lead to death of the microorganisms and make their identification difficult or impossible. Pouches incubated at 25 °C need to be evaluated under a light microscope every other day for the presence of

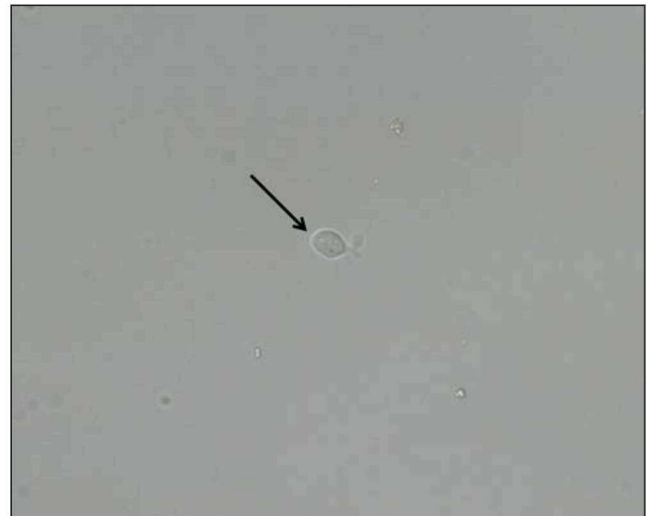

Figure 7. A single *T. foetus* organism from a culture as seen under the microscope. (magnification: 200x).

T. foetus trophozoites in order to avoid overgrowth (Figure 7). Results are usually obtained between 1 and 12 days of setting up a pouch. The growth of *Giardia* spp. and *P. hominis* is not supported by the culture media and, therefore, a positive culture is highly suggestive of *T. foetus* infection. Fecal culture is more sensitive than direct fecal smear examination (sensitivity of about 50% if performed correctly), but it might be negative if only small numbers of *T. foetus* trophozoites are present in the feces or if it is not performed correctly (Gookin et al. 2004, Tolbert and Gookin 2009). Limitations of culture include its suboptimal sensitivity, difficulties in interpretation of results, the necessity of using freshly voided feces and the fact that results might not be available for up to 12 days.

Polymerase chain reaction (PCR)

T. foetus DNA can be amplified from feline fecal samples by PCR (Gookin et al. 2002, Stauffer et al. 2008). PCR has been shown to be the most sensitive method for detecting *T. foetus* in fecal samples and it is ideally suited for direct diagnosis of *T. foetus* infection (Gookin et al. 2004, Tolbert and Gookin 2009). Advantages of PCR testing compared to culture include a higher sensitivity and easier handling and storing of samples because DNA is relatively stable under various temperature conditions. Fecal samples can be stored and sent frozen to the laboratory for PCR testing. Only a small number of veterinary diagnostic laboratories in Europe (e.g., United Kingdom) and the United States offer the specialized PCR

assay for *T. foetus* infection in cats. However, these laboratories accept samples from almost anywhere in the world. Unfortunately, the PCR assay for feline *T. foetus* is currently not available in Greece.

Practical diagnosis of feline *T. foetus* infection in Greece

Due to limited availability of some of the methods described above, the most practical method for the diagnosis of feline *T. foetus* infection in Greece is definitely the direct fecal smear examination. Understanding of the limitations of this method (i.e., the fact that negative results do not exclude the disease and that positive results should be interpreted with caution because of the similarity of *T. foetus* with *Giardia* spp and *P. hominis*) is crucial for the avoidance of false negative and false positive diagnoses. Use of the culture system In PouchTF would add substantially to the diagnostic effort and this culture system can be purchased online. Repeated testing using freshly voided diarrheic fecal samples will increase the sensitivity of both methods. Discontinuation of antibiotics might, also, be necessary. In severe cases, in which the previous two methods are not diagnostic, a fecal sample can be sent to one of the laboratories that perform PCR analysis for *T. foetus*.

TREATMENT

As mentioned previously, *T. foetus*-associated diarrhea often persists for several months or years if left untreated. Although spontaneous resolution of clinical signs may occur, this might take several months and these cats will often experience recurrent bouts of diarrhea after being exposed to stress. In addition, most untreated cats remain infected and can transmit the parasite to healthy cats. Therefore, treatment of *T. foetus*-associated diarrhea is highly recommended.

T. foetus-associated diarrhea in cats does not usually respond to most antibiotics and antiparasitic agents currently available, such as metronidazole, tylosin, erythromycin, enrofloxacin, amoxicillin, clyndamycin, fenbendazole, aldendazole and others (Kather et al. 2007, Gookin et al. 2007, Tolbert and Gookin 2009). Temporary improvement may be seen initially with the use of these drugs, but the clinical signs almost always relapse after discontinuation of treatment. Currently, the only drug that has been shown to be effective against *T. foetus* infection in cats both *in vitro* and *in vivo* is ronidazole (Gookin et al.

2006, Levine et al. 2011). This drug is a 5-nitroimidazole (it belongs to the same group as metronidazole) and might be potentially carcinogenic. Therefore, human contact should be avoided (e.g., use of gloves when handling the drug or feces from cats treated with this drug).

In most countries, ronidazole is not approved for use in companion animals and it is rarely used in other animal species. Therefore, obtaining ronidazole for use in cats can represent a challenge for the small animal clinician. Powders containing ronidazole might be available in some countries and they are typically intended to treat trichomoniasis in pigeons, but due to the extreme bitterness of ronidazole, it is almost impossible to administer sufficient quantities of these formulations to cats. The safer, most accurate and currently recommended method of administering ronidazole to cats is to use 100% pure chemical grade ronidazole in capsule form obtained from specific pharmacies. To the author's knowledge, such ronidazole formulations are not legally available in Greece. Therefore, ronidazole for treatment of *T. foetus*-associated diarrhea in cats could be purchased from reputable pharmacies in Europe (typically from the UK) after obtaining signed informed owner consent.

The most commonly used treatment protocol of ronidazole for the treatment of *T. foetus*-associated diarrhea in cats is 30 mg/kg by mouth once daily for 14 days (Gookin et al. 2006, Tolbert and Gookin 2009). In some cases, clinical signs may relapse after discontinuation of treatment, but they usually resolve after an additional treatment cycle. Neurological signs (e.g., depression, ataxia, weakness) might be seen in a small number of cats treated with ronidazole (especially if higher doses are used), but they usually resolve after discontinuation of the drug (Rosado et al. 2007). Due to this potentially serious side effect, treatment with ronidazole should be reserved only for those cats that show clinical signs and have well-confirmed *T. foetus* infection and these cats should be closely monitored during treatment with ronidazole. For the same reason, therapeutic trials in cats with unconfirmed *T. foetus* infections are not recommended.

Typically, *T. foetus*-infected cats treated with ronidazole show some improvement of the clinical signs during the course of treatment. However, both *in vivo* and *in vitro* resistance of feline *T. foetus* isolates to ronidazole has been shown and, therefore, some cats

might not respond to ronidazole treatment (Gookin et al. 2010). The response to treatment should ideally be based on PCR testing 1-2 weeks after completion of the treatment. Although a negative PCR result does not definitively exclude the infection, other causes of diarrhea should be considered in cats with a negative PCR result and persistence of the clinical signs. Alternatively, culture or direct fecal smear examination can be used, but it must be kept in mind that these tests are even less sensitive and negative results do not confirm parasitological cure. It should be noted that, because even asymptomatic cats may be infected, re-infection of treated cats is possible and sometimes difficult to prevent in multi-cat households. Finally, because co-infections with other parasites are relatively common (especially with *Giardia* spp.), identification and appropriate treatment of the coexisting parasitic infections are crucial.

Ronidazole should not be used in cats that are systemically severely ill, in very young kittens (<12

weeks of age) and in pregnant or nursing queens, because the safety of ronidazole in these groups of cats is questionable.

ZOONOTIC POTENTIAL

Several trichomonad species, both pathogenic and non-pathogenic, have been found in humans (Duboucher et al. 2006). However, only two reports of *T. foetus* infection in human beings exist in the literature. The first reported case was a case of *T. foetus*-associated meningoencephalitis in a recipient of allogeneic peripheral blood stem cell transplantation (Okamoto et al. 1998). In the other case, *T. foetus*-like organisms were identified in the bronchoalveolar lavage sample of a patient with AIDS (Duboucher et al. 2006). Infection of healthy humans by *T. foetus* has not been reported, but it cannot be excluded. Therefore, people handling cats infected with *T. foetus* should take measures to prevent possible transmission of the microorganism. ■

REFERENCES

- Bissett S, Gowan R, O'Brien C, Stone MR, Gookin JL (2008) Feline diarrhoea associated with *Tritrichomonas cf. foetus* and *Giardia* co-infection in an Australian cattery. Australian Veterinary Journal, 86:440-443.
- Duboucher C, Caby S, Dufernez F, Chabé M, Gantois N, Delgado-Viscogliosi P, Billy C, Barré E, Torabi E, Capron M, Pierce RJ, Dei-Cas E, Viscogliosi E (2006) Molecular identification of *Tritrichomonas foetus*-like organisms as coinfecting agents of human *Pneumocystis pneumonia*. Journal of Clinical Microbiology, 44:1165-1168.
- Foster DM, Gookin JL, Poore MF, Stebbins ME, Levy MG (2004). Outcome of cats with diarrhea and *Tritrichomonas foetus* infection. Journal of the American Veterinary Medical Association 225:888-892.
- Frey CF, Schild M, Hemphill A, Stünzi P, Müller N, Gottstein B, Burgener IA (2009). Intestinal *Tritrichomonas foetus* infection in cats in Switzerland detected by in vitro cultivation and PCR. Parasitology Research, 104:783-788.
- Gookin JL, Levy MG, Mac Law J, Papich MG, Poore MF, Breitschwerdt EB (2001) Experimental infection of cats with *Tritrichomonas foetus*. American Journal of Veterinary Research, 62:1690-1697.
- Gookin JL, Birkenheuer AJ, Breitschwerdt EB, Levy MG (2002) Single-tube nested PCR for detection of *Tritrichomonas foetus* in feline feces. Journal of Clinical Microbiology, 40:4126-4130.
- Gookin JL, Foster DM, Poore MF, Stebbins ME, Levy MG (2003) Use of a commercially available culture system for diagnosis of *Tritrichomonas foetus* infection in cats. Journal of the American Veterinary Medical Association, 222:1376-1379.
- Gookin JL, Stebbins ME, Hunt E, Burlone K, Fulton M, Hochel R, Talaat M, Poore M, Levy MG (2004) Prevalence of and risk factors for feline *Tritrichomonas foetus* and giardia infection. Journal of Clinical Microbiology, 42:2707-2710.
- Gookin JL, Copple CN, Papich MG, Poore MF, Stauffer SH, Birkenheuer AJ, Twedt DC, Levy MG (2006) Efficacy of ronidazole for treatment of feline *Tritrichomonas foetus* infection. Journal of Veterinary Internal Medicine, 20:536-543.
- Gookin JL, Stauffer SH, Cocco MR, Poore MF, Levy MG, Papich MG (2007) Efficacy of tinidazole for treatment of cats experimentally infected with *Tritrichomonas foetus*. American Journal of Veterinary Research, 68:1085-1088.
- Gookin JL, Stauffer SH, Dybas D, Cannon DH (2010) Documentation of in vivo and in vitro aerobic resistance of feline *Tritrichomonas foetus* isolates to ronidazole. Journal of Veterinary Internal Medicine, 24:1003-1007.
- Gray SG, Hunter SA, Stone MR, Gookin JL (2010) Assessment of reproductive tract disease in cats at risk for *Tritrichomonas foetus* infection. American Journal of Veterinary Research, 71:76-81.
- Gunn-Moore D, McCann T, Simpson K (2007) Prevalence of *Tritrichomonas foetus* infection in cats with diarrhoea in the UK. Journal of Feline Medicine and Surgery, 9:214-218.
- Hale S, Norris JM, Slapeta J (2009) Prolonged resilience of *Tritrichomonas foetus* in cat faeces at ambient temperature. Veterinary Parasitology, 166:60-65.
- Holliday M, Deni D, Gunn-Moore DA (2009) *Tritrichomonas foetus* infection in cats with diarrhoea in a rescue colony in Italy. Journal of Feline Medicine and Surgery, 11:131-134.
- Kather EJ, Marks SL, Kass PH (2007) Determination of the in vitro susceptibility of feline tritrichomonas foetus to 5 antimicrobial agents. Journal of Veterinary Internal Medicine, 21:966-970.
- Levine DN, Papich MG, Gookin JL, Davidson GS, Davis JL, Hayes RB (2011) Ronidazole pharmacokinetics after intravenous and oral immediate-release capsule administration in healthy cats. Journal of Feline Medicine and Surgery, 13:244-50.

- Levy MG, Gookin JL, Poore M, Birkenheuer AJ, Dykstra MJ, Litaker RW (2003). *Tritrichomonas foetus* and not *Pentatrichomonas hominis* is the etiologic agent of feline trichomonal diarrhea. *Journal of Parasitology*, 89:99-104.
- Okamoto S, Wakui M, Kobayashi H, Sato N, Ishida A, Tanabe M, Takeuchi T, Fukushima S, Yamada T, Ikeda Y. (1998) *Trichomonas foetus* meningoencephalitis after allogeneic peripheral blood stem cell transplantation. Bone Marrow Transplantation, 21:89-91.
- Pham D (2009) Chronic intermittent diarrhea in a 14-month-old Abyssinian cat. *Canadian Veterinary Journal*, 50:85-87.
- Romatowski J (1996) An uncommon protozoan parasite (*Pentatrichomonas hominis*) associated with colitis in three cats. *Feline Practice*, 24:10-14.
- Romatowski J (2000) *Pentatrichomonas hominis* infection in four kittens. *Journal of the American Veterinary Medical Association*, 216:1270-1272
- Rosado TW, Specht A, Marks SL (2007) Neurotoxicosis in 4 cats receiving ronidazole. *Journal of Veterinary Internal Medicine*, 21:328-31.
- Slapeta J, Craig S, McDonell D, Emery D (2010) *Tritrichomonas foetus* from domestic cats and cattle are genetically distinct. *Experimental Parasitology*, 126:209-13.
- Stauffer SH, Birkenheuer AJ, Levy MG, Marr H, Gookin JL (2008) Evaluation of four DNA extraction methods for the detection of *Tritrichomonas foetus* in feline stool specimens by polymerase chain reaction. *Journal of Veterinary Diagnostic Investigation*, 20:639-641.
- Steiner JM, Xenoulis PG, Read SA, Suchodolski JS, Globokar M, Huisinga, Thuere S (2007) Identification of *Tritrichomonas foetus* DNA in feces from cats with diarrhea from Germany and Austria. *Journal of Veterinary Internal Medicine*, 21:649.
- Stockdale HD, Spencer JA, Dykstra CC, Blackburn BL, West GS, Hanks T (2006) Feline Trichomoniasis: An emerging disease? *Compendium of Continuing Education*, 28:463-471.
- Stockdale H, Rodning S, Givens M, Carpenter D, Lenz S, Spencer J, Dykstra C, Lindsay D, Blagburn B (2007) Experimental infection of cattle with a feline isolate of *Tritrichomonas foetus*. *Journal of Parasitology*, 93:1429-1434.
- Stockdale H, Givens M, Dykstra C, Blagburn BL (2009). *Tritrichomonas foetus* infections in surveyed pet cats. *Veterinary Parasitology*, 160:13-17.
- Tolbert MK, Gookin JL (2009) *Tritrichomonas foetus*: a new agent of feline diarrhea. *Compendium*, 31:374-390.
- Xenoulis PG, Saridomichelakis MN, Read SA, Suchodolski JS, Steiner JM (2010a) Detection of *Tritrichomonas foetus* in cats in Greece. *Journal of Feline Medicine and Surgery*, 12:831-833.
- Xenoulis PG, Lopinski DJ, Doyal LC, Read SA, Suchodolski JS, Steiner JM (2010b). Intestinal *Tritrichomonas foetus* infection in cats: a retrospective study of 104 cases. 28th Annual ACVIM Forum, *Journal of Veterinary Internal Medicine*, 24:750.
- Yaeger MJ, Gookin JL (2005) Histologic features associated with *Tritrichomonas foetus*-induced colitis in domestic cats. *Veterinary Pathology*, 42:797-804.

