

Journal of the Hellenic Veterinary Medical Society

Vol 62, No 3 (2011)



Acute tracheal narrowing presumptively associated with anticoagulant rodenticide intoxication in a dog

D. S. PARDALI (Δ.Σ. ΠΑΡΔΑΛΗ), Κ. Κ. ADAMAMA-MORAITOU (Κ.Κ. ΑΔΑΜΑΜΑ-ΩΡΑΪΤΟΥ), Μ. Ν. PATSIKAS (Μ.Ν. ΠΑΤΣΙΚΑΣ), Α. Φ. KOUTINAS (Α.Φ. ΚΟΥΤΙΝΑΣ)

doi: [10.12681/jhvms.14855](https://doi.org/10.12681/jhvms.14855)

To cite this article:

PARDALI (Δ.Σ. ΠΑΡΔΑΛΗ) D. S., ADAMAMA-MORAITOU (Κ.Κ. ΑΔΑΜΑΜΑ-ΩΡΑΪΤΟΥ) Κ. Κ., PATSIKAS (Μ.Ν. ΠΑΤΣΙΚΑΣ) Μ. Ν., & KOUTINAS (Α.Φ. ΚΟΥΤΙΝΑΣ) Α. Φ. (2017). Acute tracheal narrowing presumptively associated with anticoagulant rodenticide intoxication in a dog. *Journal of the Hellenic Veterinary Medical Society*, 62(3), 235–239. <https://doi.org/10.12681/jhvms.14855>

■ Acute tracheal narrowing presumptively associated with anticoagulant rodenticide intoxication in a dog

Pardali D. S.^{1*} DVM, PhD, Adamama-Moraitou K. K.¹ DVM, PhD,
Patsikas M. N.² DVM, PhD, DipECVDI, Koutinas A. F.¹ DVM, PhD, DipECVD

¹ Companion Animal Clinic, Medicine, Faculty of Veterinary Medicine, Aristotle University of Thessaloniki – Greece

² Companion Animal Clinic (Diagnostic Imaging), Faculty of Veterinary Medicine, Aristotle University of Thessaloniki - Greece

■ Τοξίκωση από μυοκτόνες ουσίες με αντιβιταμινική Κ δράση: οξεία στένωση της τραχείας σε σκύλο

Δ. Σ. Παρδάλη^{1*} DVM, PhD, Κ. Κ. Αδαμαμά-Μωραΐτου¹ DVM, PhD,
Μ. Ν. Πατσίκας² DVM, PhD, DipECVDI, Α. Φ. Κουτίνης¹ DVM, PhD, DipECVD

¹ Κλινική Ζώων Συντροφιάς (Μονάδα Παθολογίας), Κτηνιατρική Σχολή Α.Π.Θ.

² Κλινική Ζώων Συντροφιάς (Μονάδα Απεικονιστικής Διαγνωστικής) Κτηνιατρική Σχολή Α.Π.Θ.

ABSTRACT. A 3.5-year-old, spayed female, German shepherd-cross dog was presented with cough, hemoptysis, inspiratory stridor and fascial plane hematomas. Routine bleeding profile showed prolonged prothrombin time (PT) and partial thromboplastin time (PTT). Radiography revealed severe narrowing of tracheal lumen accompanied by increased thickness and opacity of its wall. Tracheal diameter was measured objectively, employing the ratio of its diameter (TD) to thoracic inlet distance (TI) and that of the midpoint between thoracic inlet and the carina (TT) to the 3rd rib width (3R), as well as the ratio of TT to predicted diameter of tracheal lumen [D_{Pred} ($D_{Pred} \text{ cm} = 0.47 (\text{weight kg})^{0.39}$)]. All three ratios were found lower than normal. The space occupying effect of extensive and severe sub-mucosal hemorrhage due to anticoagulant rodenticide intoxication was incriminated.

Keywords: Trachea, canine, rodenticide poisoning, tracheal diameter

ΠΕΡΙΛΗΨΗ. Σκύλος, θηλυκός στείρωμένος, ηλικίας 3,5 ετών και φυλής Γερμανικός Ποιμενικός προσκομίστηκε με βήχα, αιμόπτυση, εισπνευστικό συριγμό και αιματώματα στις περιτονίες των μυών του προσώπου. Ο συνήθης αιμοστατικός έλεγχος έδειξε αύξηση του χρόνου προθρομβίνης (PT) και μερικής θρομβοπλαστίνης (PTT). Στα ακτινογραφήματα του θώρακα και του τραχήλου διαπιστώθηκε σοβαρού βαθμού μείωση της διαμέτρου του αυλού της τραχείας που συνοδευόταν από αύξηση της ακτινοσκοπιότητας και του πάχους του τοιχώματός της. Η διάμετρος της τραχείας μετρήθηκε αντικειμενικά με τον προσδιορισμό του λόγου της διαμέτρου της (TD) προς τη διάμετρο της εισόδου του θώρακα (TI), το λόγο της διαμέτρου της τραχείας στο μέσο της απόστασης από την είσοδο του θώρακα ως το διχασμό της (TT) προς το εύρος της 3^{ης} πλευράς (3R), όπως και από το λόγο της TT προς την αναμενόμενη διάμετρο του αυλού της τραχείας [D_{Pred} ($D_{Pred} \text{ cm} = 0.47 (\text{weight kg})^{0.39}$)]. Όλοι οι λόγοι βρέθηκαν μικρότεροι του φυσιολογικού. Ως αίτιο της χωροκατακτητικής αλλοίωσης που αφορούσε στο τοίχωμα της τραχείας θεωρήθηκαν οι εκτεταμένες και σοβαρές υποβλεννογόνιες αιμορραγίες λόγω της τοξίκωσης από ποντικοφάρμακο με ανταγωνιστική της βιταμίνης Κ δράση.

Λέξεις ευρετηγίας: Τραχεία, σκύλος, τοξίκωση από ποντικοφάρμακο, διάμετρος τραχείας

Correspondence: * Pardali D. S.

Companion Animal Clinic, Medicine, Faculty of Veterinary Medicine, Aristotle University of Thessaloniki, St. Voutira 11str., 546 27, Thessaloniki – Greece
Tel.: +30 2310 994514, Fax: +30 2310 994516, E-mail didipardali@yahoo.gr

Αλληλογραφία: * Σ. Δ. Παρδάλη

Κλινική Ζώων Συντροφιάς (Μονάδα Παθολογίας), Κτηνιατρική Σχολή Α.Π.Θ.
Στ. Βουτυρά 11, 546 27 Θεσσαλονίκη
Τηλ.: +30 2310 994514, Fax: +30 2310 994516, E-mail didipardali@yahoo.gr

Submission date: 16.06.2011

Approval date: 07.09.2011

Ημερομηνία υποβολής: 16.06.2011

Ημερομηνία εγκρίσεως: 07.09.2011

Case History

A three and a half year-old, spayed female, German shepherd-cross dog, weighing 20.6 kg, was referred to the Companion Animal Clinic, with a 3-day history of coughing, hemoptysis, dyspnea, depression and anorexia. Prior to admission, the dog had been treated with enrofloxacin and dexamethasone, by the referring practitioner, but a rapid worsening of its clinical status occurred.

Physical examination revealed pale mucous membranes, mild to moderate respiratory distress, inspiratory stridor and moist cough followed by non-frothing hemoptysis. Soft swellings were seen over the angle of the left mandible and the left proximal tibia and tarsus and they were proved to be hematomas after paracentesis; prolonged bleeding was, also, noticed at the venipuncture site of the jugular vein.

Complete blood count (CBC) revealed a low hematocrit value (20.9%; reference intervals: 37.0%-55.0%) and hemoglobin concentration (7.3 g/dl; reference intervals: 12.0-18.0 g/dl), thrombocytopenia (76.000/ μ l; reference intervals: 175.000-500.000/ μ l) and neutrophilic leukocytosis (23.600/ μ l; reference intervals: 6.000-16.900/ μ l) (QBC Vet Autoread®, IDEXX, Maine, USA). Reticulocyte production index (RPI) was low (0.8; normal value > 2), as well as the concentration of total solids (5.9 g/dl; reference intervals: 6.0-8.0 g/dl). Routine bleeding profile showed a prolonged prothrombin time (PT; > 70 sec; reference intervals: 7-14 sec) and partial thromboplastin time (PTT; > 600

sec; reference intervals: 90-107 sec) (SCA-2000, Synbiotics Co, Lyon, France). Serology with the aid of Dot-Elisa for *Ehrlichia canis* antibody (Immunocomb Canine Ehrlichia Antibody Test Kit, Biological-Galed Labs, Kibbutz Galed, Israel) and *Dirofilaria immitis* antigen (Snap Canine Heartworm PF, IDEXX, Westbrook, ME, USA) was negative.

Lateral radiographs of the neck and thorax disclosed a diffuse interstitial and multifocal alveolar pattern in the caudal lobe of the lung, along with a mild pleural effusion. At the same time, an extensive and severe narrowing of the tracheal lumen accompanied by increased thickness and opacity of its wall was visualized (Figure 1). By applying objective criteria to assess the diameter of tracheal lumen, the ratio of its diameter (TD) to the thoracic inlet distance (TI), the ratio of its diameter at the midpoint between thoracic inlet and carina (TT) to the 3rd rib width (3R) and that of TT to the predicted diameter of tracheal lumen [D_{Pred} ($D_{Pred} \text{ cm} = 0.47 (\text{weight}_{\text{kg}})^{0.39}$)] were calculated accordingly (Harvey and Fink 1982, Burton 2003, Coyne and Fingland 1992). The values of these ratios are listed in Table 1.

Upon establishing a tentative diagnosis of anticoagulant rodenticide intoxication (ARI), the dog was immediately transfused with fresh whole blood (450 ml) and vitamin K₁ (Konaktion; Roche, Austria) was given at the loading dose of 5 mg/kg b.w., subcutaneously followed by 2.5 mg/kg b.w., subcutaneously, BID for 15 days; to minimize the

Figure 1. Lateral thoracic radiograph of a dog with anticoagulant rodenticide intoxication showing generalized tracheal narrowing, diffuse interstitial pulmonary pattern, with focal pulmonary infiltrates at the caudal lobe of the lung and mild pleural effusion. a: tracheal lumen diameter (TD) b: thoracic inlet distance (TI) c: width of the third rib (3R) d: tracheal lumen at its midpoint between the thoracic inlet and the carina (TT)

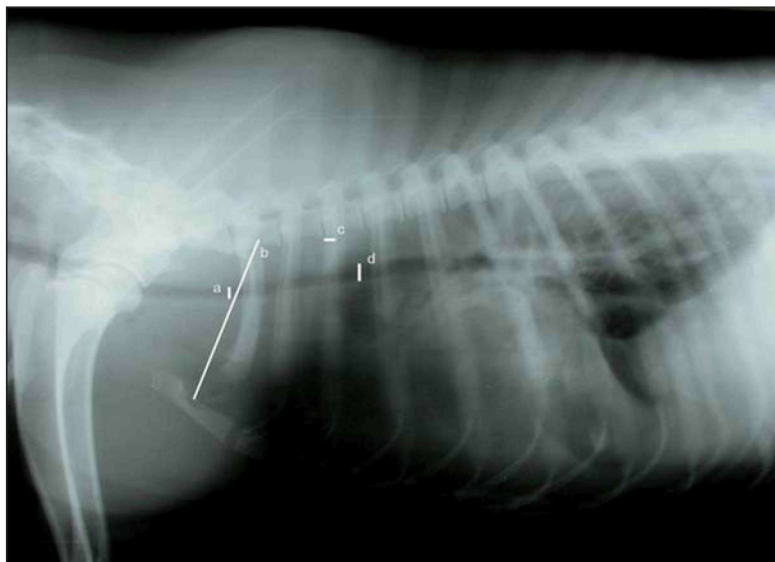


Table 1. Ratios calculated for the evaluation of tracheal lumen narrowing in the dog with rodenticide intoxication

Ratios	Case	Reference intervals
TD / TI	0.065	0.201 ± 0.031^a
TT / 3R	0.575	≥ 3
TT / Dpred	0.146	0.890 ± 0.059^b

TD / TI: the ratio of tracheal lumen diameter (TD) to the thoracic inlet distance (TI)

TT / 3R: the ratio of tracheal lumen diameter at the midpoint between thoracic inlet and carina (TT) to the 3rd rib width (3R)

TT / Dpred: the ratio of tracheal lumen diameter at the midpoint between thoracic inlet and carina TT to the predicted diameter of tracheal lumen [D_{Pred} (D_{Pred} cm = 0.47 (weight kg)^{0.39})]

^a Mean \pm standard deviation

^b Mean \pm standard of the mean

possibility of spontaneous bleeding, strict cage rest was instituted. The dog responded well to this treatment within two days and it was discharged three days later. The owner was instructed to continue the parenteral treatment with vitamin K₁ for 10 additional days, along with reasonable restriction of the animal's daily activities. Discontinuation of vitamin K₁ administration was followed by a total of 5 normal PT measurements performed every other day. One year after the admission, the owner reported that the dog remained clinically normal.

Discussion

The aim of this report was to present the case history of a dog with respiratory distress and inspiratory stridor, due to acute and extensive tracheal narrowing, intrapulmonary hemorrhages and hemorrhagic pleural effusion, all appearing secondary to anticoagulant rodenticide intoxication (ARI). The clinical diagnosis of spontaneous and severe blood loss due to ARI was based on the dramatic decrease of hematocrit value, hemoglobin and total protein concentrations, as no trauma had been witnessed by the owner or detected on physical examination. The response to vitamin K₁ supplementation and fresh whole blood transfusion supported the diagnosis of ARI in this dog (Nelson and Couto 2003). Serial PT measurements, starting three days from the cessation of vitamin K₁ administration, confirmed the complete restoration of hemostasis. The early disappearance of inspiratory stridor and respiratory distress clearly indicated a positive correlation between the sub-

mucosal hemorrhages and the response of the animal to the specific therapy for ARI.

Anticoagulant rodenticide intoxication is, perhaps, the most common intoxication reported by veterinary hospitals and animal poisoning centers, at least in the dog (Felice and Murphy 1995, Zawadzki et al. 2007). Primary intoxication, via the ingestion of baits containing anticoagulant rodenticides (ARs), is far more common than secondary occurring after dogs' preying or scavenging on poisoned rodents.

Anticoagulant rodenticides are usually marketed as ready-to-use baits, the strength of which depends on their generation, concentration and formulation. First generation ARs include warfarin, dicoumarol, coumafuryl, valone, pindone and diphacinone, whereas brodifacoum, bromadiolone, flocoumafen and difenacoum belong to the second generation group (Felice and Murphy 1995). The latter ARs have been developed because of the emergence of warfarin-resistant rats. Anticoagulant rodenticides act by inhibiting vitamin K epoxide reductase enzyme, thus leading to a decrease of vitamin K active form, which is indispensable for the activation of clotting factors II, VII, IX and X (Sheafor and Couto 1999a, Nelson and Couto 2003). Concentration of ARs in baits and ingested quantity play an important role in the variability, severity and timing of the clinical expression of the intoxication in the dog. From a clinical point of view, canine ARI is characterized by dyspnea, cough, hemoptysis, superficial or deep hematomas, prolonged bleeding from venipuncture sites, intracranial hemorrhage and CNS signs and hemorrhagic effusions, all occurring in variable combinations and severity (Berry et al. 1993, Felice and Murphy 1995, Rickman and Gurfield 2009). They are frequently accompanied by pallor, lethargy, weakness and prostration (Felice and Murphy 1995, Sheafor and Couto 1999a, Sheafor and Couto 1999b, Zawadzki et al. 2007).

Furthermore, thoracic radiographs disclosed the presence of pleural effusion, along with patchy opacities in the caudal lung lobes. These radiographic findings taken together with hemoptysis led to the presumptive diagnosis of hemothorax and pulmonary hemorrhages (Spackman et al. 1984). The generalized bleeding diathesis was further strengthened by the detection of fascial plane hematomas at the left mandibular angle and left proximal tibia and tarsus brought ARI, a common emergence in our area, to be

the top of differentials.

Moderate thrombocytopenia (76.000/ μ l), a frequent finding in ARI, has been attributed to platelet consumption occurring secondary to extensive hemorrhages (Nelson and Couto 2003, Peterson and Streeter 1996, Lewis et al. 1997, Harvey and Fink 1982). However, other mechanisms, such as dilution of platelets following intravenous fluid administration and/or redistribution of interstitial fluid to intravascular compartment to compensate the acute blood loss would, also, be incriminated (Lewis et al. 1997). Low platelet count coupled with a substantial prolongation of PT and PTT would also imply the presence of disseminated intravascular coagulation, but this diagnosis was uncertain due to the absence of schistocytes in the peripheral blood smears and the rapid clinical response of the animal to whole fresh blood transfusion and parenteral vitamin K₁ administration (Sheafor and Couto 1999a, Nelson and Couto 2003, Lewis et al. 1997, Kirby and Rudloff 2000). Unfortunately, measurement of fibrinogen degradation products level was not available at that time.

Neutrophilia was suggestive of a stressful condition and tissue damage, while the non-regenerative anemia (RPI: 0.8) was the result of acute blood loss (Lee and Drobatz 2004). The far prolonged PT and PTT values in this dog indicated the chronicity and severity of ARI. Prothrombin time, testing the integrity of extrinsic and common coagulation cascade, reflects the concentration of factor VII the short half-life of which (4-6 hours) signifies the prolongation of PT one or two days after the ingestion of the bait (Sheafor and Couto 1999a). On the other hand, PTT evaluates the intrinsic and common coagulation cascade and its value increases when blood levels of factors II, IX and X, the half-lives of which are 40 h, 13.9 h and 16.5 h respectively, fall far below (Sheafor and Couto 1999a). Prolonged bleeding at the venipuncture site, a common finding in canine ARI, usually takes 3-5 minutes to appear after the insertion of the needle and is due to the impairment of secondary hemostatic pathway, because it does not permit the strengthening and maintenance of the primary hemostatic plug (Sheafor and Couto 1999a, Sheafor and Couto 1999b).

Cough and hemoptysis, also observed in approximately 30% of ARI cases, were the result of excessive bleeding within the tracheobronchial tree and pulmonary alveoli, and pressure against the mechanical

receptors of tracheal mucosa elicited by sub-mucosal hemorrhages (Sheafor and Couto 1999b, Bailiff and Norris 2002). The inspiratory stridor was the result of tracheal lumen narrowing, although laryngeal obstruction could be another option, since it was reported in a dog with brodifacoum poisoning (Peterson and Streeter 1996). The severe clinical picture of laryngeal obstruction (Peterson and Streeter 1996), however, should be excluded as a possibility in our dog that showed a mild respiratory distress probably secondary to tracheal lumen narrowing, pulmonary hemorrhages and pleural effusion.

The most common radiographic findings in 14 dogs with ARI were pleural effusion (95%) and generalized or multifocal interstitial - alveolar pulmonary pattern (60%) (Berry et al. 1993). In this dog, the similarities of interstitial - alveolar pattern, resulting from extensive pulmonary hemorrhages to that of acute pulmonary edema, made their differentiation to rely on the inspiratory stridor, mild dyspnea, generalized bleeding diathesis, non-frothy hemoptysis, perhaps the presence of pleural effusion in the thoracic radiographs and the absence of abnormalities on cardiac evaluation. In ARI, the pulmonary alveolar pattern has been attributed to the increased vascular permeability and the ensuing intra alveolar pooling of blood (Bailiff and Norris 2002). Neck and thorax radiographs demonstrated a severe narrowing of tracheal lumen, which is a rare finding in canine ARI (Berry et al. 1993). Assumingly, sub-mucosal hemorrhages were responsible for this radiographic abnormality, since the same type and site of lesions have been reported in 3 dogs with ARI (Berry et al. 1993, Blocker and Roberts 1999). In addition, the radiographic pattern of a post-traumatic intramural tracheal hematoma is different (Pink 2006).

All three ratios calculated for a more objective evaluation of tracheal lumen narrowing were found to be lower than normal. These ratios were initially applied to compare the diameter of tracheal lumen between brachycephalic and non-brachycephalic dogs, but they are currently recognized as a non-invasive diagnostic method in tracheal hypoplasia (Harvey and Fink 1982, Burton 2003, Coyne and Finland 1992). The use of these ratios in the present report made the evaluation of tracheal lumen narrowing more precise and objective. Unfortunately, the follow-up radiography, in order to access the progressive improvement

of tracheal lumen stenosis, was not feasible because of the owner's non-compliance.

The possibility of tracheal sub-mucosal hemorrhages, although quite uncommon in dogs with ARI,

should be investigated thoroughly when there is clinical and radiographic evidence of upper airway obstruction and bleeding diathesis, since its presence worsens the already guarded prognosis. ■

REFERENCES

- Bailliff NL, Norris CR (2002) Clinical signs, clinicopathological findings, etiology and outcome associated with hemoptysis in dogs: 36 cases (1990-1999). *J Am Anim Hosp Assoc* 38:125-133
- Berry CR, Gallaway A, Thrall DE, Carlisle C (1993) Thoracic radiographic features of anticoagulant rodenticide toxicity in fourteen dogs. *Vet Radiol Ultra* 34:391-396
- Blocker LT, Roberts BK (1999) Acute tracheal obstruction associated with anticoagulant rodenticide intoxication in a dog. *J Small Anim Pract* 40:577-580
- Burton C (2003) Surgical diseases of the trachea in the dog and cat. In *Pract* October:514-527
- Couto CG (2003): Disorders of hemostasis. In: *Small Animal Internal Medicine*. 3rd ed., Mosby Inc, Missouri: pp 1185-1199
- Coyne BE, Finland RB (1992) Hypoplasia of the trachea in dogs: 103 cases (1974-1990). *J Am Vet Med Assoc* 201:768-772
- Felice LJ, Murphy MJ (1995) CTV update: Anticoagulant rodenticides. In: *Kirk's Current Veterinary Therapy XII Small Animal Practice*, WB Saunders Co, Philadelphia: pp 228-232
- Harvey CE, Fink EA (1982) Tracheal diameter: Analysis of radiographic measurements in brachycephalic and nonbrachycephalic dogs. *J Am Anim Hosp Assoc* 18:570-576
- Kirby R, Rudloff E (2000) Acquired coagulopathy VI: disseminated intravascular coagulation. In: *Schalm's Veterinary Hematology*, 5th ed., Lippincott Williams and Wilkins, Philadelphia: pp 581-587
- Lee JA, Drobotz KJ (2004) Respiratory distress and cyanosis in dogs. In: *Textbook of Respiratory Disease in Dogs and Cats*, Saunders, Missouri: pp 1-12
- Lewis DC, Bruyette DS, Kellerman DL, Smith SA (1997) Thrombocytopenia in dogs with anticoagulant rodenticide-induced hemorrhage: eight cases (1990-1995). *J Am Anim Hosp Assoc* 33:417-422
- Peterson J, Streeter V (1996) Laryngeal obstruction secondary to brodifacoum toxicosis in a dog. *J Am Vet Med Assoc* 208:352-355
- Pink JJ (2006) Intramural tracheal haematoma causing acute respiratory obstruction in a dog. *J Small Anim Pract* May 47(3):161-164.
- Rickman BH, Gurfield N (2009) Thymic Cystic Degeneration, Pseudoepitheliomatous Hyperplasia, and Hemorrhage in a Dog with Brodifacoum Toxicosis. *Vet Pathol* 46:449-452
- Sheafor SE, Couto CG (1999a) Clinical approach to a dog with anticoagulant rodenticide poisoning. *Vet Med* May:466-471
- Sheafor SE, Couto CG (1999b) Anticoagulant rodenticide toxicity in 21 dogs. *J Am Anim Hosp Assoc* 35:38-46
- Spackman MJA, Caywood DD, Feeney DA, Johnston GR (1984) Thoracic wall and pulmonary trauma in dogs sustaining fractures as a result of motor vehicle accidents. *J Am Vet Med Assoc* 185:975-977
- Zawadzki M, Magdalan S, Niedzwiedz A (2007) Poisonings with anticoagulant rodenticides. *Arch Med Sadowej Kryminol* 57:427-439

