ePublishing

Journal of the Hellenic Veterinary Medical Society

Vol 62, No 4 (2011)



Eosinophilic dermatitis with edema (Wells'-like syndrome) possibly triggered by cooked fish in a dog

G. D. GIANNOULOPOULOS (Γ.Δ. ΓΙΑΝΝΟΥΛΟΠΟΥΛΟΣ), R. FARMAKI (Ρ. ΦΑΡΜΑΚΗ), Ch. K. KOUTINAS (Χ.Κ. ΚΟΥΤΙΝΑΣ), A. F. KOUTINAS (Α.Φ. ΚΟΥΤΙΝΑΣ)

doi: 10.12681/jhvms.14862

To cite this article:

GIANNOULOPOULOS (Γ.Δ. ΓΙΑΝΝΟΥΛΟΠΟΥΛΟΣ) G. D., FARMAKI (Ρ. ΦΑΡΜΑΚΗ) R., KOUTINAS (Χ.Κ. ΚΟΥΤΙΝΑΣ) C. K., & KOUTINAS (Α.Φ. ΚΟΥΤΙΝΑΣ) A. F. (2017). Eosinophilic dermatitis with edema (Wells'-like syndrome) possibly triggered by cooked fish in a dog. *Journal of the Hellenic Veterinary Medical Society*, *62*(4), 320–326. https://doi.org/10.12681/jhvms.14862

https://epublishing.ekt.gr | **e-Publisher:** EKT | **Downloaded at:** 24/01/2026 05:37:29

JOURNAL OF THE HELLENIC VETERINARY MEDICAL SOCIETY 2011, 62(4): 320-326
ΠΕΡΙΟΔΙΚΟ ΤΗΣ ΕΛΛΗΝΙΚΗΣ ΚΤΗΝΙΑΤΡΙΚΗΣ ΕΤΑΙΡΕΙΑΣ 2011, 62(4): 320-326

Case report
Κλινικό περιστατικό

Eosinophilic dermatitis with edema (Wells'-like syndrome) possibly triggered by cooked fish in a dog

Giannoulopoulos G. D.[1], DVM, **Farmaki R.**[1], DVM, PhD, DipECVD, **Koutinas Ch. K.**[2], DVM, PhD, **Koutinas A. F.**[2], DVM, PhD, DipECVD

[1] *Clinic of Medicine, School of Veterinary Medicine, University of Thessaly*
[2] *Companion Animal Clinic, Faculty of Veterinary Medicine, Aristotle University of Thessaloniki*

Εωσινοφιλική δερματίτιδα με οίδημα σε σκύλο (Wells'-like syndrome) μετά από κατανάλωση ψαριών

Γ. Δ. Γιαννουλόπουλος[1], DVM, **Ρ. Φαρμάκη**[1], DVM, PhD, DipECVD, **Χ. Κ. Κουτίνας**[2], DVM, PhD, **Α. Φ. Κουτίνας**[2], DVM, PhD, DipECVD

[1] *Παθολογική Κλινική, Κτηνιατρική Σχολή, Πανεπιστήμιο Θεσσαλίας*
[2] *Κλινική Παθολογίας Ζώων Συντροφιάς, Κτηνιατρική Σχολή, Αριστοτέλειο Πανεπιστήμιο Θεσσαλονίκης*

ABSTRACT. A 2-year old intact female mongrel dog was admitted with multifocal skin lesions appearing suddenly and extending symmetrically over most of the body. The dog was living indoors and one day before the admission it had consumed cooked fish. Neither medication, nor vaccination had been given to the dog, at least during the last 3 months. Physical examination revealed only non-pruritic and non-painful macules, papules and plaques that were distributed mainly over the head, pinnae, neck and thorax. The lesions were annular, acriform or serpiginous with a tendency to coalesce. Skin histopathology (H-E) revealed a superficial dermal edema, post-capillary venule congestion and perivascular to interstitial eosinophilic dermatitis as the main pattern. The dog was initially placed on oral vitamin E, sulphasalazine and doxycycline, but to no avail. As soon as the diagnosis of eosinophilic dermatitis with edema was confirmed by histopathology, the former treatment stopped and oral prednisolone was given for two months during which there was a remarkable improvement of skin lesions and complete disappearance with no relapse. The cooked fish, consumed by the dog the night before the incident, was assumed to be the cause of the acute eosinophilic hypersensitivity reaction.

Keywords: dog, eosinophilic dermatitis with edema, food-induced

ΠΕΡΙΛΗΨΗ. Μία σκύλα δύο ετών, ακαθόριστης φυλής, προσκομίστηκε με πολυεστιακές δερματικές αλλοιώσεις που εμφανίστηκαν αιφνίδια και επεκτείνονταν συμμετρικά στον κορμό του σώματος. Το ζώο αυτό ζούσε μέσα στο σπίτι και είχε καταναλώσει μαγειρεμένα ψάρια μία ημέρα πριν από την προσκόμιση, ενώ δεν του είχαν χορηγηθεί φάρμακα ή εμβόλια τους 3 τελευταίους μήνες. Κατά την κλινική εξέταση διαπιστώθηκαν μη κνησμώδεις και ανώδυνοι πομφοί, βλαττίδες και πλάκες που κατανέμονταν κυρίως στην κεφαλή, τα πτερύγια των αυτιών, τον τράχηλο και τα τοιχώματα του θώρακα. Οι δερματικές αυτές αλλοιώσεις ήταν κυκλοτερείς, τοξοειδείς ή οφιοειδείς με τάση συνάθροισης. Η ιστοπαθολογική εξέταση αποκάλυψε την ύπαρξη οιδήματος στο επιπολής χόριο, συμφόρηση των μετα-τριχοειδών φλεβιδίων και περιαγγειακή-διάμεση εωσινοφιλική

Correspondence: Koutinas Ch. K.
St. Voutyra 11, Thessaloniki
Tel: +2310994500, Fax: +2310994516, email: quark@vet.auth.gr

Αλληλογραφία: Koutinas Ch. K.
St. Voutyra 11, Thessaloniki
Tel: +2310994500, Fax: +2310994516, email: quark@vet.auth.gr

Submission date: 12.07.2011
Approval date: 31.01.2012

Ημερομηνία υποβολής: 12.07.2011
Ημερομηνία εγκρίσεως: 31.01.2012

δερματίτιδα. Αρχικά στο σκύλο χορηγήθηκε από το στόμα βιταμίνη Ε, σουλφασαλαζίνη και δοξυκυκλίνη, χωρίς όμως αποτέλεσμα. Μετά την ιστοπαθολογική επιβεβαίωση της εωσινοφιλικής δερματίτιδας, η παραπάνω θεραπεία αντικαταστάθηκε από την πρεδνιζολόνη, από το στόμα, για 2 μήνες, κατά τη διάρκεια των οποίων ο σκύλος παρουσίασε σημαντική βελτίωση μέχρι την εξαφάνιση των δερματικών αλλοιώσεων, χωρίς στη συνέχεια να εμφανίσει υποτροπές. Το πιθανότερο αίτιο της εωσινοφιλικής αυτής αντίδρασης υπερευαισθησίας ήταν η κατανάλωση μαγειρεμένων ψαριών από το σκύλο αυτό.

Λέξεις ευρετηρίασης: σκύλος, εωσινοφιλική δερματίτιδα με οίδημα, τροφογενής

INTRODUCTION

The main causes of eosinophilic dermatitis in the dog are the allergic reactions and parasitic infestations, although it is not uncommon for the underlying trigger factor or the disease to remain unknown (Moriello 2003). In this type of dermatitis, eosinophils predominate in the inflammatory infiltrate which is localized in the dermis and/or subcutis (Scott et al. 2001, Leiferman and Peters 2007). Eosinophils, named after the affinity of their granules for eosin (Harvey 2001, Bloom 2006), have phagocytic properties, engulfing immune complexes, mast cell granules, aggregated immunoglobulins and certain bacteria and fungi (Grodecki 2000, Scott et al. 2001). In order to fulfill their function, eosinophils degranulate potent molecules, such as major basic protein, eosinophil peroxidase and eosinophilic-derived neurotoxin (Moriello 2003, Raskin et al. 2004, Bloom 2006, Leiferman and Peters 2007).

In the dog, the specific eosinophilic dermatoses, so far recognized, include nasal folliculitis/furunculosis syndrome, eosinophilic granuloma, eosinophilic proliferative otitis externa, sterile eosinophilic pinnal folliculitis, eosinophilic pustulosis and eosinophilic dermatitis with edema (EDE) or Wells'-like syndrome. The latter disease is uncommonly occuring in the everyday practice, as only 39 cases have been reported so far in the veterinary literature (Vitale et al. 1994, Holm et al. 1999, Mauldin et al. 2006). In the affected dogs, erythematous macules and papules that progress and coalesce into plaques of various shapes, usually appear suddenly and are mainly localized on the pinnae, ventral abdomen, thorax and the extremities and they are occasionally accompanied by facial or generalized pitting edema (Holm et al. 1999). Primary histopathologic features of EDE, in both humans and dogs, are consistent with dermal eosinophilia, along with severe dermal edema and flame figures (Holm et al. 1999, Weedon 2009). The exact pathogenesis of the disease is still unknown, but it may actually represent an eosinophil-rich inflammatory reaction to a variety of insults (McKee et al. 2005). This paper describes a non-relapsing canine case with skin lesions typical of EDE, which were most likely triggered by cooked fish consumption.

CASE HISTORY

A 2-year-old intact female mongrel dog, weighing 5 kg, was admitted to a private practice in Athens with a sudden onset of multifocal skin lesions. The dog was fed with homemade diets, it was regularly vaccinated and dewormed and it was the only pet living in the house. According to the history, the skin lesions appeared suddenly during the night, approximately 12 hours prior to admittance. The evening before lesion appearance, the dog had consumed a meal consisting of cooked fish. The dog had no pruritus, pain, discomfort or any other systemic clinical signs. The last vaccination and deworming of the dog was 3 months ago and neither medication nor any kind of food supplementation had been given during that time. Moreover, the dog did not have any history related to allergy and other cutaneous or internal diseases.

During admission, the dog was active and presented no other clinical abnormalities apart from the skin lesions, which were multifocal, with a relatively bilateral symmetrical distribution. The lesions consisted of deeply erythematous macules with central clearing and papules, some of which coalesced to form plaques of various sizes (Fig. 1a and 1b), especially pronounced and numerous on the pinnae, neck and thorax, to a lesser extent on the ventral abdomen, over a diffusely erythematous backround (Fig. 2) and, moreover, on the limbs and dorsum. They did not blanch with diascopy and they appeared in various shapes, such as circular, annular, acriform or serpiginous with well-demarcated margins and coalescing tendency. On the lesional areas, there was no alopecia-hypotrichosis or surface exudation, but just a fine and

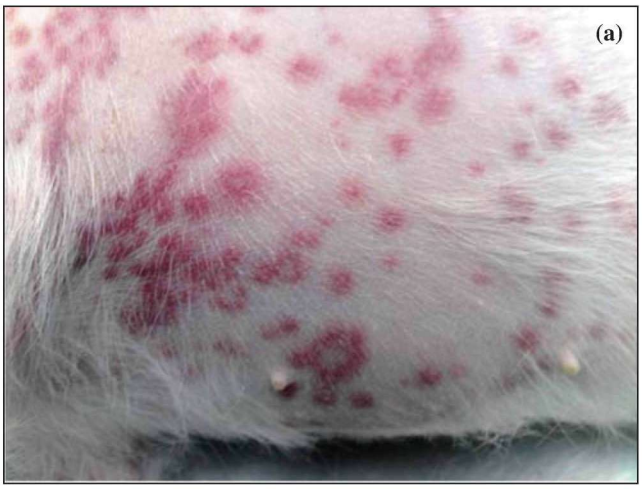

Figure 1 (a). Lateral view of the body trunk showing a multifocal and severe erythematous maculopapular exanthema.
(b) Lesional configuration of the ventral neck area is circular, annular or acriform.

Figure 2. Ventral abdomen of the dog with scattered hemorrhagic-looking macules on a diffusely erythematous skin.

mild scaling. Skin scrapings and fungal culture (DTM) from the lesions were negative for mites and dermatophytes, respectively. The initial list of differential diagnosis included thrombocytopenic purpura, cutaneous vasculitis, erythema multiforme and EDE. Furthermore, a blood sample was taken for CBC and routine serum biochemistry, respectively. Skin punch biopsies were obtained from sites representing macules, papules and plaques and, subsequently, submitted for histopathological examination.

Complete blood count was unremarkable, with all its parameters found to be within normal values. Serum biochemistry revealed hypoproteinemia, hypoglobulinemia, mild hyperglycemia and hypocalcemia as well as a slightly increased ALT activity. The result of serology testing for *Ehrlichia canis* (WITNESS®, Synbiotics Corporation) was found weakly positive.

The microscopic lesions were consistent with a mild to moderate superficial eosinophilic dermatitis demonstrating a perivascular to interstitial pattern. The predominating eosinophils were intermingled with fewer mast cells, histiocytes, plasma cells and neutrophils. A superficial dermal edema with mucinosis and congested post-capillary venules, the lumen of which was usually occupied by eosinophils, were, also, observed (Fig. 3a and 3b). The less common changes included a mild orthokeratotic hyperkeratosis of the

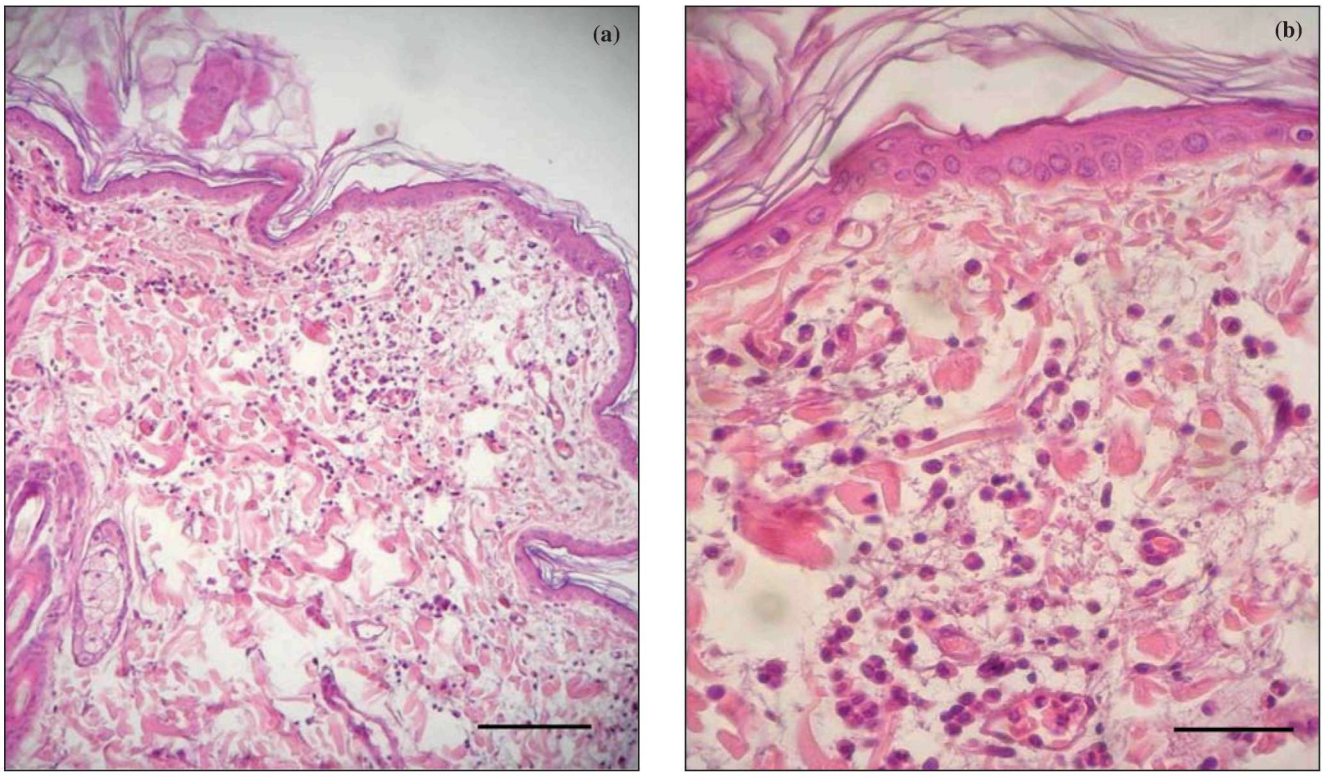

Figure 3 (a). Photomicrograph of a skin biopsy specimen obtained from an erythematous macule. Notice the superficial and moderate eosinophilic interstitial dermatitis along with edema in the upper dermis (100X). Bar=100μm. **(b)** Higher magnification (400x) of the previous photomicrograph. Notice the predominance of eosinophils in the inflammatory infiltrate accompanied by fewer plasma cells. Intraluminal engorgement of a post-capillary venule and dermal edema with mucinosis are, also, quite visible. H&E stain, Bar=50μm.

epidermis and minimal follicular atrophy, dilatation and keratosis. Deeper dermal and pannicular involvement, flame figures and/or dermal hemorrhage were not observed, at least in the skin biopsies reviewed.

The dog was put on an oral immunomodulatory treatment consisting of vitamin E (generic) (200 IU/dog, BID), sulphasalazine (Salopyrine®, Adelco) (25mg/kg b.w., TID) and doxycycline (Ronaxan®, Merial Animal Health) (5.5 mg/kg b.w., BID) for almost one week, but to no avail. When the diagnosis of EDE had been confirmed histopathologically, the dog was switched to oral prednisolone (Prednisolone®, Fort Dodge) (2 mg/kg b.w., SID), with instructions to the owner to taper the dose after a two-week period and, eventually, to discontinue it, according to the results of future re-examinations. On the first re-examination, one week later, there was a slight improvement, although quite encouraging to the owner (Fig. 4a). At that time the dog was polyphagic, polidipsic and polyuric, due to glucocorticoid administration, but otherwise clinically healthy. On the second reexamination, after 3 additional weeks, skin lesions had almost vanished, apart from a few smaller macules, still visible over the concave surface of the pinnae, the elbow and the ventral abdomen. On the third re-examination, after the discontinuation of the 2-month treatment with prednisolone, no skin lesion could be seen (Fig. 4b). A year after the incident, the owner reported no relapse of skin lesions and confirmed that the dog was doing well.

DISCUSSION

The case reported here fulfilled the clinical and histopathologic criteria of EDE, as they have been established for the dog (Holm et al. 1999, Mauldin et al. 2006). Eosinophilic dermatitis with edema is an uncommon reaction pattern, most likely of multifactorial allergic etiology, characterized by a unique histopathologic pattern (Gross 2005). Wells' syndrome in people, also called eosinophilic cellulitis, is clinically different from canine EDE, although a severe case, involving a Beagle dog and characterized by multiple dermal and subcutaneous nodules, had close clinical and histopathological similarities to human disease

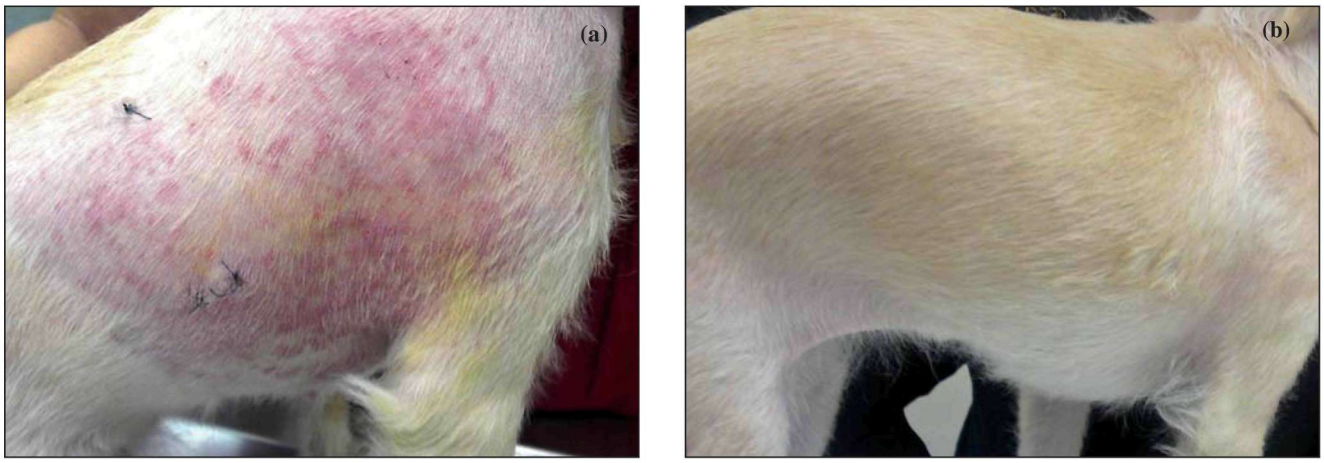

Figure 4. Lateral view of the dog's body trunk **(a)** one week (partial resolution of the skin lesions) and **(b)** 3 months (complete cure) after the initiation of prednisolone therapy.

(Gross 2005, Weedon 2009). The clinical and histopathological similarities between this variant of canine EDE and cutaneous eosinophilic granulomas make the differentiation difficult, although the latter are often limited in number and localized on specific sites (Gross 2005).

Wells' syndrome in humans and EDE in dogs would be considered a reaction pattern than a specific diagnosis because of its many causes or trigger factors incriminated (Bloom 2006). The human disease, apart from being idiopathic, has been associated with various infectious and parasitic diseases, heredity, malignant neoplasms, drugs, vaccines, atopic disease, arthropod bites, the hypereosinophilic syndrome and urticaria (Dijkstra et al. 1986, Weedon 2009). In the dog, EDE has been associated with gastrointestinal disease, drugs, arthropod bites and allergic diseases (Holm et al. 1999, Bloom 2006, Mauldin et al. 2006). In a retrospective analysis of 29 canine EDE cases, severe gastrointestinal disease was the most common trigger factor that may have causal drug association (Mauldin et al. 2006). Approximately half of the reported canine cases had a history of atopy, suggesting a tendency to hypersensitivity reaction to various agents (Bloom 2006). In another retrospective study on canine EDE (Holm et al. 1999), only 2 out of 9 dogs had been exposed to new food, although its role could be questioned because other factors may have, also, exerted their influence simultaneously. In the study of Mauldin et al. (2006), at least one dog was eventually diagnosed with food allergy, while three others were therapeutically placed on limited antigen or hydrolyzed diets. Interestingly, one of the authors (AFK) has reported urticarial reaction in two dogs that appeared soon after the consumption of fried fish, only to disappear a couple of hours later. On the other hand, the eosinophilic cellulitis of humans has been associated with urticaria (Dijkstra et al. 1986). It is possible that the cooked fish, consumed by the dog, triggered the sudden appearance of EDE, which shares some clinical and histopathological characteristics with urticaria (Gross 2005). Nevertheless, this is hypothetical, since we did not challege the dog with a fish-meal after its complete clinical recovery for ethical reasons. Acute reactions occurring within hours of drug administration or perhaps food consumption without previous exposure are well-documented in people and are thought to be mediated by pre-activated T-cells that have cross-reacted with other peptides (Gerber and Pichler 2004, Gerber and Pichler 2006). The fact of no recurrence of skin lesions, by avoiding feeding the dog with fish, might, also lead to false conclusions, because relapses are uncommon in the canine disease (Holm et al. 1999, Mauldin et al. 2006). Finally, erythema multiforme, considered a top differential in canine EDE, has, also, been associated with food (or food allergy) in a dog (Itoh et al. 2006).

This dog developed diffuse erythroderma with macules and papules coalescing quickly to plaques, thus formulating a clinical picture typical of canine EDE (Holm et al. 1999, Mauldin et al. 2006). However, the other clinical components of the disease, such as pruritus, fever, facial or generalized edema and lymphadenopathy (Holm et al. 1999) were not seen in this dog.

Skin biopsy is especially recommended to rule out more severe diseases with clinical similarities as the outcome of EDE is usually favourable, as it has been described in our dog. Skin histopathology was quite compatible with acute EDE (Holm et al. 1999) because we did not notice the characteristic flame figures, which may be seen at a later stage (subacute dermatitis) following the eosinophil degranulation (Wood et al. 1986). Notably, in 18 out of 29 dogs with EDE, no flame figures could be seen on lesional histology (Mauldin et al. 2006); the corresponding figure was 4/9 in the other EDE case series (Holm et al. 1999). The explanation of the flame figures, the presence of which is not specific for canine EDE or the Wells' syndrome in humans (Mauldin et al. 2006), is the major basic protein released via eosinophil degranulation and can bind to collagen fibers resulting in their structural or morphological alteration (Peters et al. 1983). In Wells' syndrome, the superficial edema, when severe enough, may evolve into sub-epidermal vesciculation (blistering), reminiscent of bullous pemphigoid (McKee et al. 2005), although this change has never been seen in its canine counterpart (Holm et al. 1999, Mauldin et al. 2006). The dermal mucinosis, also seen in this dog, is a histologic feature of eosinophil annular erythema that would be considered a variant of Wells' syndrome (Howes et al. 2008) and exhibits more clinical similarities to canine EDE.

Although the appearance of the cutaneous lesions of this dog were, also, reminiscent of erythema multiforme, cutaneous vasculitis and perhaps of urticaria, their histopathologic picture is different than that of EDE (Scott et al. 2001, Gross 2005). Multiple erythema (lymphocytic interface dermatitis with keratinocyte apoptosis occurring in all epidermal layers plus lymphocytic satellitosis) and cutaneous vasculitis (vascular thrombosis, perivascular hemorrhage, intramular changes) were ruled out with the aid of histopathology (Gross 2005). Vasculitis is not normally a feature of Wells' syndrome or EDE, although extravasation of erythrocytes may sometimes be evident (Brehmer-Andersson et al. 1986). Surprisingly, dermal hemorrhage, as suggested by the clinical findings, was not present in this dog, as it has, also, been reported before (Holm et al. 1999). On the other hand, the absence of lesions' blanching on diascopy ruled out beforehand urticaria as a diagnostic option, apart from the fact of their persistence, morphology and variation (Scott et al. 2001, Gross 2005). Consequently, the cutaneous reaction presented by this dog did not fit either the clinical criteria of Wells' syndrome in humans or the typical type 1 hypersensitivity-urticarial reaction (Mauldin et al. 2006) and it seems to be unique to the canine species.

Peripheral eosinophilia, which is rather common in Wells' syndrome in people, was not seen in this dog, as it was, also, the case in 7 out of 9 dogs with the same disease (Holm et al. 1999), in contrast to what was witnessed in another EDE dog, the skin lesions of which were tentatively associated with a reaction to diethylcarbamazine (Vitale et al. 1994). Hypoproteinemia seems to be a common laboratory finding in EDE, although, in this dog, it was attributed to hypoglobulinemia instead of hypoalbuminemia that has been demonstrated in almost all of the hypoproteinemic EDE dogs reported so far (Holm et al. 1999, Mauldin et al. 2006).

In both the human and canine eosinophilic dermatitis, a systematic diagnostic approach to unravel the underlying factor should be performed to avoid the indiscriminate and chronic use of glucocorticoids, especially when the disease waxes and wanes (Bloom 2006). This dog appeared to respond favourably to prednisolone, with all its skin lesions disappearing by the time of its discontinuation. This response to glucocorticoids was very similar to that of other dogs with EDE (Holm et al. 1999). The failure to respond to immunomodulatory treatment (doxycycline, sulfasalazine, vitamin E) initially prescribed to the dog, would be attributed to the short period allowed (one week). For patients who fail to completely resolve on glucocorticoids or relapse often enough, treatment with minocycline, dapsone, antihistamines, cyclosporine or interferon alpha might be beneficial (Stetson 2003). Minocycline and doxycycline have been used in isolated cases of the human disease (Moossavi and Mehregan 2003).

In conclusion, when a dog is presented with skin lesions of sudden onset and reminiscent of something between erythema multiforme, cutaneous vasculitis and urticaria, clinical suspicion for EDE should be raised, especially when it is associated with drugs, vaccinations or the consumption of a novel food.

REFERENCES

Bloom PB (2006) Canine and Feline Eosinophilic Skin Diseases. The Veterinary clinics of North America. Small animal practice 36:141-160

Brehmer-Andersson E, Kaaman T, Skog E and Frithz A (1986) The histopathogenesis of the flame figure in Wells' syndrome based on five cases. Acta Derm Venereol 66:213-219

Dijkstra JW, Bergfeld WF, Steck WD and Tuthill RJ (1986) Eosinophilic cellulitis associated with urticaria. A report of two cases. J Am Acad Dermatol 14:32-38

Gerber BO and Pichler WJ (2004) Cellular mechanisms of T cell mediated drug hypersensitivity. Curr Opin Immunol 16:732-737

Gerber BO and Pichler WJ (2006) Non-covalent interactions of drugs with immune receptors may mediate drug-induced hypersensitivity reactions. AAPS J 8:E160-165

Grodecki K (2000) Leucocyte disorders: selected topics; Eosinophilia. In: Manual of Canine and Feline Hematology and Transfusion Medicine. ed, BSAVA, pp 131-138

Gross TL (2005) Skin diseases of the dog and cat: clinical and histopathologic diagnosis. 2nd ed, Blackwell Science, Ames, Iowa: pp 224

Harvey JW (2001) Leucocytes. In: Atlas of Veterinary Hematology, Blood and Bone Marrow of Domestic Animals. ed, WB Saunders, Philadelphia: pp 45-74

Holm KS, Morris DO, Gomez SM, Peikes H, Byrne KP and Goldschmidt MH (1999) Eosinophilic dermatitis with edema in nine dogs, compared with eosinophilic cellulitis in humans. J Am Vet Med Assoc 215:649-653

Howes R, Girgis L and Kossard S (2008) Eosinophilic annular erythema: a subset of Wells' syndrome or a distinct entity? Australas J Dermatol 49:159-163

Itoh T, Nibe K, Kojimoto A, Mikawa M, Mikawa K, Uchida K and Shii H (2006) Erythema multiforme possibly triggered by food substances in a dog. J Vet Med Sci 68:869-871

Leiferman KM and Peters MS (2007) Eosinophils in Cutaneous diseases. In: Fitzpatrick's Dermatology in General Medicine. 7th ed, McGraw-Hill Professional, pp 307-318

Mauldin EA, Palmeiro BS, Goldschmidt MH and Morris DO (2006) Comparison of clinical history and dermatologic findings in 29 dogs with severe eosinophilic dermatitis: a retrospective analysis. Vet Dermatol 17:338-347

McKee PH, Calonje JE and Granter SR (2005) Pathology of the Skin - with clinical correlations. ed, Mosby Ltd - Elsevier, pp 697-699

Moossavi M and Mehregan DR (2003) Wells' syndrome: a clinical and histopathologic review of seven cases. Int J Dermatol 42:62-67

Moriello KA (2003) Eosinophilic dermatoses. In: Manual of small animal dermatology. ed, BSAVA, pp 233-241

Peters MS, Schroeter AL and Gleich GJ (1983) Immunofluorescence identification of eosinophil granule major basic protein in the flame figures of Wells' syndrome. Br J Dermatol 109:141-148

Raskin RE, Latimer KS and Tvendten H (2004) Leukocyte Disorders. In: Small Animal Clinical Diagnosis by Laboratory Methods. ed, WB Saunders, St Louis: pp 63-91

Scott DW, Miller WH and Griffin CE (2001) Miscellaneous skin diseases. In: Small Animal Dermatology. 6th ed, WB Saunders, Philadelphia: pp 1125-1184

Stetson C (2003) Eosinophilic dermatoses. In: Dermatology. ed, Mosby, Edinburgh: pp 403-409

Vitale CB, Ihrke PJ and Gross TL (1994) Putative Diethylcarbamazine-induced Urticaria with Eosinophilic Dermatitis in a Dog. Veterinary Dermatology 5:197-203

Weedon D (2009) Weedon's Skin Pathology. 3rd ed, Churchill Livingstone - Elsevier, pp 940-941

Wood C, Miller AC, Jacobs A, Hart R and Nickoloff BJ (1986) Eosinophilic infiltration with flame figures. A distinctive tissue reaction seen in Wells' syndrome and other diseases. Am J Dermatopathol 8:186-193