

## Journal of the Hellenic Veterinary Medical Society

Vol 61, No 3 (2010)



### Cutaneous lymphohistiocytic and multifocal lymphoma in an adult mare

K. M. SPANOUEDES (Κ.Μ. ΣΠΑΝΟΥΔΗΣ), C. M. McGOWAN, N. E. DIAKAKIS (Ν.Ε. ΔΙΑΚΑΚΗΣ), A. F. KOUTINAS (Α.Φ. ΚΟΥΤΙΝΑΣ)

doi: [10.12681/jhvms.14887](https://doi.org/10.12681/jhvms.14887)

#### To cite this article:

SPANOUEDES (Κ.Μ. ΣΠΑΝΟΥΔΗΣ) K. M., McGOWAN, C. M., DIAKAKIS (Ν.Ε. ΔΙΑΚΑΚΗΣ) N. E., & KOUTINAS (Α.Φ. ΚΟΥΤΙΝΑΣ) A. F. (2017). Cutaneous lymphohistiocytic and multifocal lymphoma in an adult mare. *Journal of the Hellenic Veterinary Medical Society*, 61(3), 207–211. <https://doi.org/10.12681/jhvms.14887>

## Cutaneous lymphohistiocytic and multifocal lymphoma in an adult mare

Spanoudes K. M.<sup>1</sup>, McGowan C. M.<sup>2</sup>, BVSc, MACVSc, DEIM, DECEIM, PhD, MRCVS, FHEA,  
Diakakis N. E.<sup>3</sup>, DVM, MSc, PhD, Koutinas A. F.<sup>3</sup>, DVM, PhD, DipECVD

<sup>1</sup> *Veterinary Student, Faculty of Veterinary Medicine, Aristotle University of Thessaloniki, Greece*

<sup>2</sup> *Equine Division, Faculty of Veterinary Science University of Liverpool, UK*

<sup>3</sup> *Companion Animal Clinic, Faculty of Veterinary Medicine, Aristotle University of Thessaloniki, Greece*

## Περιστατικό δερματικού λεμφώματος (πολυεστιακό και λεμφοϊστοκυτταρικό) σε ενήλικη φοράδα

K. M. Σπανούδης<sup>1</sup>, McGowan C. M.<sup>2</sup>, BVSc, MACVSc, DEIM, DECEIM, PhD, MRCVS, FHEA,  
N. E. Διακάκης<sup>3</sup>, DVM, MSc, PhD, Α. Φ. Κουτίνας<sup>3</sup>, DVM, PhD, DipECVD

<sup>1</sup> *Φοιτητής, Κτηνιατρική Σχολή, Αριστοτέλειο Πανεπιστήμιο Θεσσαλονίκης*

<sup>2</sup> *Equine Division, Faculty of Veterinary Science University of Liverpool, UK*

<sup>3</sup> *Κλινική Ζώων συντροφιάς, Κτηνιατρική Σχολή, Αριστοτέλειο Πανεπιστήμιο Θεσσαλονίκης*

**ABSTRACT.** Cutaneous or subcutaneous lymphoma is one of the four different forms appearing in the horse. This type of equine lymphoma is usually lymphohistiocytic with a T, B or mixed-cell immunophenotype and with a prevalence of less than 3% among skin neoplasms. This is all about a 9-year old Warmblood mare admitted with a 5-month history of multiple cutaneous masses spreading to many parts of the body. Apart from the multiple subcutaneous nodules and plaques, which did not provide discomfort to the horse, no other abnormalities were found either in clinical or laboratory examination. Lesional histopathology and immunohistochemistry revealed a lymphohistiocytic T-cell lymphoma, which most likely was primary. The owner elected not to have her horse treated, but readmitted it for euthanasia 5 months later, because of the worsening of skin lymphoma and the appearance of general and systemic clinical signs. The ensuing postmortem was suggestive of distant metastatic disease (liver, mediastinal lymph nodes, pharyngeal wall) most likely originating from the skin.

**Keywords:** cutaneous lymphoma, horse, neoplasia

**ΠΕΡΙΛΗΨΗ.** Το δερματικό λέμφωμα αντιπροσωπεύει τον έναν από τους τέσσερις κλινικούς φαινότυπους του νεοπλασματος αυτού στο άλογο. Στην μορφή αυτή το λέμφωμα συνήθως είναι λεμφοϊστοκυτταρικό με B, T ή μικτό κυτταρικό ανοσοφαινότυπο. Στο άλογο η συχνότητα εμφάνισης του δερματικού λεμφώματος είναι κάτω από το 3% των νεοπλασμάτων του δέρματος συνολικά. Αν και αναφέρεται ότι δεν υπάρχει προδιάθεση ως προς τη φυλή, το φύλο ή την ηλικία, η νόσος εμφανίζεται συχνότερα στα ενήλικα – ηλικιωμένα άλογα και τις φοράδες. Η εργασία αυτή πραγματεύεται την περίπτωση μιας εννιάχρονης φοράδας που προσκομίστηκε (Κλινική Ιπποειδών, Κτηνιατρική σχολή Πανεπιστήμιο του Ελσίνκι, Φινλανδία), επειδή από 5μήνου παρουσίαζε πολυάριθμες δερματικές μάζες σ'ολόκληρο σχεδόν το σώμα. Εκτός από τα δερματικά οζίδια και τις πλάκες, που βασικά είχαν υποδόρια εντόπιση και δεν συνοδεύονταν από αλωπεκία ή/και εξέλκωση του δέρματος, και δεν

*Correspondence:* Spanoudes K.-A.  
25, Xenofontos str., Thessaloniki 546 39, Greece  
Tel.: 2310-824493, 6951000331, Email:kspanoud@vet.auth.gr

*Αλληλογραφία:* Κ.-Α, Σπανούδης  
Ξενοφώντος 25, 546 39 Θεσσαλονίκη  
Tel.: 2310-824493, 6951000331, Email:kspanoud@vet.auth.gr

*Submission date:* 02.07.2010  
*Approval date:* 12.10.2010

*Ημερομηνία υποβολής:* 02.07.2010  
*Ημερομηνία εγκρίσεως:* 12.10.2010



ενοχλούσαν το ζώο, δεν βρέθηκε κάτι το παθολογικό τόσο στην κλινική όσο και στην εργαστηριακή εξέταση. Στο σημείο αυτό η διαφορική διάγνωση θα μπορούσε να περιλάβει το ψευδολέμφωμα, την κνίδωση, την άσηπτη υποδερματίτιδα, το αμελανωτικό μελάνωμα, το μαστοκύττωμα, το εωσινοφιλικό κοκκίωμα και ορισμένα σαρκοειδή. Η ιστοπαθολογική και ανοσοϊστοχημική εξέταση βιοψίας από τις δερματικές αυτές μάζες έδειξαν ότι επρόκειτο για λεμφοϊστιοκυτταρικό T-λεμφοκυτταρικό λέμφωμα που πιθανότατα ήταν πρωτογενές μη επιθηλιοτρόπο. Η ιδιοκτικότητα του αλόγου απέκλεισε κάθε είδους θεραπεία και επανέφερε ύστερα από 5 μήνες το ζώο για ευθανασία, επειδή εκτός από την επιδείνωση των δερματικών μαζών είχε αρχίσει να παρουσιάζει γενικά και εσωτερικά συμπτώματα (δύσπνοια και φαρυγγική δυσφαγία). Η μακροσκοπική εξέταση που ακολούθησε ήταν ενδεικτική του μεταστατικού χαρακτήρα του λεμφώματος αυτού, αφού βρέθηκαν λευκωπές εστίες στο ήπαρ, διόγκωση των μεσοπνευμόνιων λεμφογαγγλίων και διόγκωση του βλεννογόνου του φάρυγγα και των επιχώριων λεμφογαγγλίων. Με βάση την κλινική εξέλιξη του περιστατικού, το πιθανότερο είναι ότι η μετάσταση στα εσωτερικά όργανα ξεκίνησε από το δέρμα. Επισημαίνεται ότι μια τέτοια εξέλιξη αναμένεται να συμβεί συχνότερα, όταν τα νεοπλασματικά λεμφοκύτταρα είναι κάπως άτυπα, παρά καλά διαφοροποιημένα. Το λέμφωμα αυτό δε θα μπορούσε να είναι επιθηλιοτρόπο, όχι μόνο επειδή είχε υποδόρια κυρίως εντόπιση, αλλά και επειδή το τελευταίο χαρακτηρίζεται από γενικευμένη αποφολιδωτική δερματίτιδα που μπορεί να συνοδεύεται από κνησμό, έλκη και οζίδια.

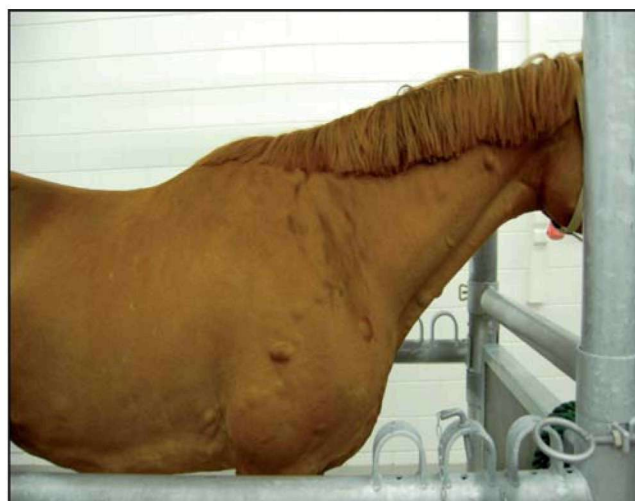*Λέξεις ευρητηρίας:* δερματικό λέμφωμα, ίππος, νεοπλασία

## CASE HISTORY

A 9-year old Warmblood chestnut mare was presented to Equine Hospital of the Veterinary Medicine Faculty of University of Helsinki with a history of intermittent dyspnea and multiple skin masses. According to the owner, these masses started appearing 5 months ago over the shoulder area; no treatment had been attempted at that time.

Physical examination showed a bright, alert and in good body condition mare with slightly congested mucous membranes, rectal temperature of 37,6°C, heart rate 42 beats/min and respiratory rate 24/min. The caudal mesenteric/iliac and peripheral lymph nodes were palpated normal. Dermatological examination revealed the presence of multiple subcutaneous nodules and fewer plaques, all having an almost symmetrical distribution over many parts of the body, such as neck, shoulder, trunk and thighs (Fig. 1). These subcutaneous masses were neither pruritic, painful, alopecic, ulcerated nor fistulated and were variable in size (1-7 cm). No other abnormalities could be detected upon physical examination apart from a bilateral and symmetrical periorcular non-pruritic alopecia reminiscent of alopecia areata; this lesion was not further investigated histologically.

A subcutaneous nodule, located on the right shoulder, was excised (with local anaesthesia) for histopathology to rule-in or out the tentative diagnosis of cutaneous lymphoma. Unfortunately, fine needle aspiration cytology from any of these masses was not attempted before the skin biopsy. Part of the excised skin nodule was fixed in 10% buffered formalin,



**Figure 1.** Non-epitheliotropic cutaneous lymphoma. Multiple and variable in size subcutaneous nodules and plaques over the neck and shoulder of the right side of the horse.

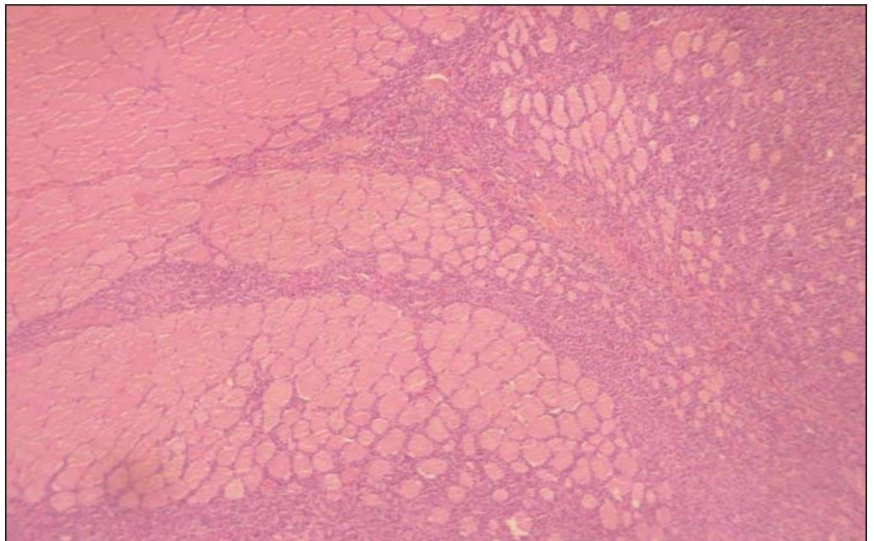
embedded in paraffin wax, sectioned at 4μm and stained with haematoxylin-eosin. A pitfall of histopathology was that the epidermis and most of the dermis and its adnexa were not included in the fixed specimen. The ensuing histopathology revealed a diffuse lymphoid and histiocytic infiltration of the deep dermis and subcutis with finger-like projections to the underlying adipose tissue and skeletal muscle (Fig.2). The lymphocytic population was monomorphic and consisted of small to medium sized, but atypical lymphocytes; the less prominent histiocytic component included typical and larger macrophages with variably stained cytoplasm (Fig. 3). The mitotic rate of lymphocytes was 0-2/HPF.



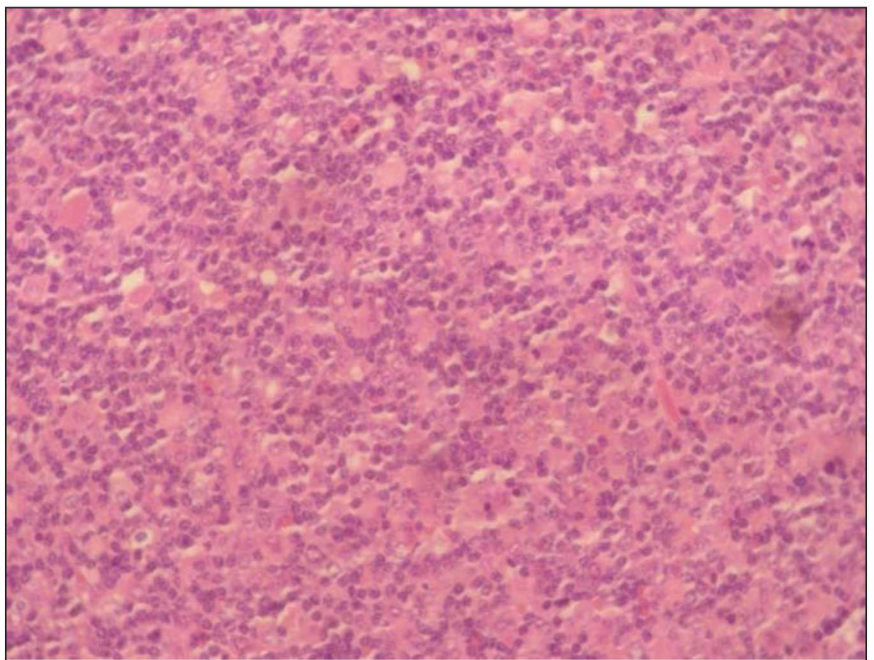
Sections stained with Ziehl-Neelsen and Gomori Methenamine Silver (GMS) did not reveal the presence of mycobacteria and fungi, respectively. In an attempt to demonstrate the immunophenotype of lymphoma in this horse, which may influence prognostication and the final outcome, the paraffin embedded tissue sample was sectioned at 4 $\mu$ m subjected to immunohistochemical labelling with a panel of antisera specific for B (CD79a) or T (CD3) lymphocytes and counterstained with hematoxylin. Immunohistochemical staining with this panel of specific antisera resulted in membrane staining for CD3, but not for CD79a for more than 80% of the total cell population (Fig. 4a, b). The histiocytic component was negative with both reagents.

Consequently, the diagnosis of this cutaneous neoplasm was that of T-cell lymphohistiocytic lymphoma, and most likely non-epitheliotropic and primary.

After the owner was advised of the diagnosis, she decided to leave the horse in the paddock untreated and simply to monitor the progress of the disease. After 5 months and apart from the number and size of subcutaneous masses that had increased by that time and spread all over the body, the horse experienced marked weight loss, deterioration of the pre-existing dyspnea and pharyngeal dysphagia. At that point, the owner decided to have her horse euthanized. At postmortem, apart from the cutaneous lesions already described, a number of firm nodules were observed over the surface of the liver along with some moderately enlarged mediastinal lymph nodes and marked hyperplasia of the pharyngeal mucosa and the adjacent lymphoid tissue. Unfortunately, none of these lesions was subjected to histopatho-



**Figure 2.** Satellite view of the biopsy section showing finger-like projections of the lymphohistiocytic infiltrate into the underlying skeletal muscle (HE stain x 100).



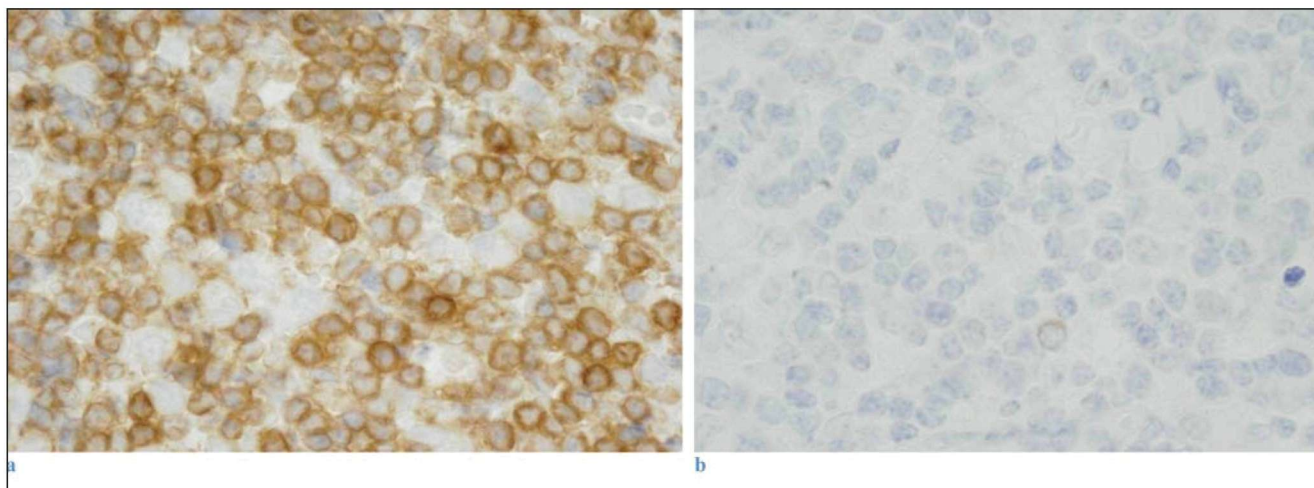
**Figure 3.** Histological section of the biopsy specimen showing diffuse infiltration of the deep dermis by a mixed population of small to medium size, but atypical lymphocytes and larger histiocytic cells (HE stained X 400).

logical and immunohistochemical examination.

## DISCUSSION

In this paper, a case of multifocal subcutaneous lymphohistiocytic lymphoma in a 9-year old mare is described. Cutaneous-subcutaneous lymphoma accounts for 0.6 to 3% of the skin neoplasms of the horse and is seen in 4% to 35% of the total equine lymphoma cases





**Figure 4.** Immunohistochemical section of the lesional specimen showing CD3-positive (a), but CD79a-negative (b) neoplastic lymphocytes; the larger histiocytic cells (a) remain unstained (haematoxylin counterstain x 1000).

presented in every day practice (Scott and Miller 2003). Its aetiology is still unknown, despite the detection of retroviral virions and the isolation of coryneform bacteria from tumour tissue (Seahan et al. 1980, Dettileaux et al. 1989).

A predisposition for females seems to exist, since in a series of published clinical studies or case reports totalling 22 horses, 16 (72,7%) were mares (de Brujin et al. 2007), as it was, also, the case with this horse. However, the same is not true regarding the age or the breed of the affected horses, although cutaneous lymphoma more often occurs in adult to aged animals (Scott and Miller 2003). From a clinical and histopathological point of view, the primary cutaneous lymphoma in the horse is actually non-epitheliotropic and subcutaneous and only rarely epitheliotropic (Staempfli et al. 1988, Littlewood et al. 1995, Hilbe et al. 1997, Johnson et al. 1998, Potter and Anez 1998, Epstein and Hodge 2005, de Brujin et al. 2007). The latter form is expressed as multifocal to generalized exfoliative dermatitis and is accompanied or not by pruritus and sometimes by nodules and ulcerations, as it has been witnessed in other animal species (Scott and Miller 2003). Nevertheless, generalized paraneoplastic pruritus and alopecia have been reported in a horse with diffuse non-epitheliotropic lymphoma (Finley et al 1998). The subcutaneous localization of the nodules and plaques in this mare was suggestive of the non-epitheliotropic nature of lymphoma, although the absence of epidermis and hair in the tissue sample obtained and evaluated microscopically does not permit to come to a definitive conclusion. The dia-

gnosis of lymphoma in this mare was based on both the characteristic clinical and histopathological features, although FNA cytology would have given earlier diagnostic clues if it had been applied at the time of physical examination. From a clinical standpoint, equine non-epitheliotropic lymphoma resembles pseudolymphoma, sterile panniculitis, amelanotic melanoma, mastocytoma, eosinophilic granuloma, certain types of sarcoids and urticaria (Reed et al. 2004, Pascoe and Knottenbelt 1999). Histopathology of one subcutaneous nodule did reveal a diffuse lymphohistiocytic lymphoma infiltrating the deep dermis, subcutis and the underlying skeletal muscle. This histological phenotype has been reported to comply with the typical clinical picture of cutaneous non-epitheliotropic lymphoma that was, also, witnessed in this mare (Scott and Miller 2003, Epstein and Hodge 2005). Although the majority of horses with multicentric lymphoma is typically euthanized, because of poor prognosis, subcutaneous lymphoma can regress and reappear over the next months to years (Meyer et al. 2006). Many horses with this type of lymphoma have been reported to survive for 5 months to 11 years after the appearance of the first nodules (de Brujin et al. 2007). Therefore, equine lymphoma appears to be a clinically and pathologically heterogeneous neoplasm with features different from the lymphoma of the other animal species.

Peripheral blood haematology and serum biochemistry were normal in this mare, as it may happen in the majority of horses with the non-epitheliotropic phenotypic form of cutaneous lymphoma (Sheaham et



al. 1980, Littlewood et al. 1995, Gerard et al. 1998, Johnson 1998). Nevertheless, in equine lymphoma, and regardless of its clinical phenotype, anemia or erythrocytosis, neutropenia, lymphocytosis or leukemia, hypoalbuminemia and/or hyperglobulinemia, either polyclonal or monoclonal, may be seen, more or less frequently (Meyer et al. 2006). In another study, five horses with cutaneous lymphoma (non-epitheliotropic), but without abnormalities on routine haematology, flow cytometry showed changes in the peripheral blood lymphocyte population (de Bruijn et al. 2007).

Although equine non-cutaneous lymphomas can be B-cell or T-cell in origin (Kellen and Mahaffey 1998), its non-epitheliotropic and epitheliotropic counterparts are usually T-cell, as it was seen in this case, the lymphocytes of which stained only with CD3, but not with CD79a antibodies. Cutaneous lymphoma in the horse often exhibits a T-cell rich B-cell or TCRBCL immunophenotype (Kelley and Mahaffey 1998, Seahan et al. 1980, Dettileux et al. 1989) that is considered to represent a relatively non-aggressive subtype of the disease (de Bruijn et al. 2007). However, many classification and prognostication issues that are mainly

based on histopathology and immunohistochemistry remain unresolved or are still controversial awaiting their clarification (Scott and Miller 2003). For example, horses with allegedly lymphohistiocytic or TCRBCL cutaneous lymphomas that survive more than 4 years may actually represent pseudolymphoma cases, which have benign biological behaviour (Scott and Miller 2003). Despite the relatively asymptomatic state of this mare at the first admittance in the Hospital, the progressive deterioration of cutaneous lesions and the gradual appearance of systemic clinical signs over the ensuing 5 months, the neoplastic appearance of tissue lymphocytes and, finally, the distant metastasis, make the pseudolymphoma option quite distant.

Since the current treatment protocols for equine lymphoma are expensive, associated with complications and of unproven benefit, the owner's decision to leave the mare untreated and, finally, to have her euthanized seems to be both reasonable and morally justified. This is particularly true for the cutaneous form of lymphoma in which the affected horses remain actually asymptomatic for a long period of time. ■

## REFERENCES

- De Bruijn C.M., Veenman J.N., Rutten V.P.M.G., Teske E., Van Nieuwstadt R.A. and Van den Ingh T.S.G.A.M. 2007: Clinical, histopathological and immunophenotypical findings in five horses with cutaneous malignant lymphoma. *Res. Vet. Sci.* 83: 63-72.
- Dettileux PG, Cheville NE Sheahan BJ: Ultrastructure and lectin histochemistry of equine cutaneous histiolympocytic lymphomas. *Vet Path* 26:409-419, 1989.
- Epstein V, Hodge D: Cutaneous lymphosarcoma in a stallion. *Aust. Vet. J.* 2005 Oct;83(10):609-11.
- Finley MR, Rebhun WC, Dee A., Langsetmo I.: Paraneoplastic pruritus and alopecia in a horse with diffuse lymphoma *J Am Vet Med Assoc.* 1998 Jul 1;213(1):102-4.
- Gerard, M.P., Healy, L.N., Bowman, K.F., Miller, R.T., 1998. Cutaneous lymphoma with extensive periarticular involvement in a horse. *J Am Vet Med Assoc.* 213 (3).
- Hilbe, M., Meier, D., Feige, K., 1997. Ein Fall eines malignen epitheliotropen kutanen lymphoms (Mycosis Fungoides) bei einem Pferd. *Berliner Munchner Tierarztlichen Wochenschrift* 110, 86-89.
- Johnson, P.J.(1998) Dermatological tumors (excluding sarcoids). *Vet. Clin. N. Am.:* *Equine Pract.* 14:625-659.
- Kelley L.C. and Mahaffey E.A., 1998. Equine malignant lymphomas: morphologic and immunohistochemical classification. *Veterinary Pathology*, 35, 241-252.
- Littlewood, J.D., Whitwell, K.E., Day, M.J., 1995: Equine cutaneous lymphoma: a case report. *Veterinary Dermatology* 6 (2), 105-111.
- Meyer J., DeLay J. and Bienzle D. 2006. Clinical, laboratory and histopathologic features of equine lymphoma. *Vet. Pathol.* 43: 914-924.
- Pascoe and Knottenbelt, *Manual of Equine Dermatology*, WB Saunders 1999, p 257.
- Potter, K., Anez, D., 1998. Mycosis Fungoides in a horse. *J Am Vet Med Assoc.* 212 (4), 550-552.
- Reed SM, Bayly WM, Sellon DC (2004): *Disorders of the Skin In: Equine Internal medicine.* 2nd ed. Saunders Ltd Philadelphia: pp 667-720.
- Scott D.W., Miller W. H. (2003) *Neoplastic and Non-Neoplastic Tumors In: Equine Dermatology.* Elsevier Science Ltd Missouri: pp 698-795.
- Sheahan BJ, Atkins GJ, Russell RJ, O'Connor JP. Histiolympocytic lymphosarcoma in the subcutis of two horses. *Vet Pathol.* 1980; 17:123-133.
- Staempfli H.R., McAndrew K.H., Valli V.E.O., McEwen B.J., 1988. An unusual case of lymphoma in a mare. *Equine Veterinary Journal* 20 (2), 141-143.