

Journal of the Hellenic Veterinary Medical Society

Vol 59, No 1 (2008)



The effect of prolonged decalcification on the immunohistochemical staining of *Leishmania infantum* amastigotes in formalin-fixed, paraffin-embedded canine soft tissues (lymph nodes)

E PAPADOGIANNAKIS, A KOUTINAS, V KONTOS

doi: [10.12681/jhvms.14951](https://doi.org/10.12681/jhvms.14951)

Copyright © 2018, E PAPADOGIANNAKIS, A KOUTINAS, V KONTOS



This work is licensed under a [Creative Commons Attribution-NonCommercial 4.0](https://creativecommons.org/licenses/by-nc/4.0/).

To cite this article:

PAPADOGIANNAKIS, E., KOUTINAS, A., & KONTOS, V. (2018). The effect of prolonged decalcification on the immunohistochemical staining of *Leishmania infantum* amastigotes in formalin-fixed, paraffin-embedded canine soft tissues (lymph nodes). *Journal of the Hellenic Veterinary Medical Society*, 59(1), 77–80.
<https://doi.org/10.12681/jhvms.14951>

The effect of prolonged decalcification on the immunohistochemical staining of *Leishmania infantum* amastigotes in formalin-fixed, paraffin-embedded canine soft tissues (lymph nodes)

Papadogiannakis E., DVM, Cert.SAD, PhD,
Koutinas A., DVM, PhD, Dipl. ECVD, Kontos V., DVM, PhD

Department of Veterinary Public Health, National School of Public Health (NSPH), Athens, Greece
Clinic of Companion Animals, Veterinary School of Aristotle University (AUTH), Thessaloniki, Greece

Η επίδραση της παρατεταμένης απασβέστωσης πάνω στην ανοσοϊστοχημική χρώση των αμαστιγωτών της *Leishmania infantum* σε μονιμοποιημένους σε φορμόλη και εμποτισμένους σε παραφίνη μαλακούς ιστούς σκύλου (λεμφογάγγλια)

Ε. Παπαδογιαννάκης, DVM, Cert.SAD, PhD, Αναπληρωτής Καθηγητής ΕΣΔΥ,
Α. Κουτίνας, DVM, PhD, Dipl. ECVD, Καθηγητής Κτηνιατρικής Σχολής Α.Π.Θ.,
Β. Κοντός, DVM, PhD, Καθηγητής ΕΣΔΥ

Τομέας Κτηνιατρικής Δημόσιας Υγείας, Εθνική Σχολή Δημόσιας Υγείας, Αθήνα
Κλινική Ζώων Συντροφιάς, Κτηνιατρική Σχολή, Αριστοτέλειο Πανεπιστήμιο, Θεσσαλονίκη

ABSTRACT. The aim of this report was to present the preliminary results of the effect of prolonged decalcification on the immunohistochemical staining of *Leishmania infantum* in formalin-fixed, paraffin-embedded canine soft tissues. A heavily parasitized by *Leishmania infantum* amastigotes popliteal lymph node was used in this study. One half of a surgically excised lymph node was processed according to a decalcification protocol (for 40 days), while the other half was processed without decalcification. Immunohistochemical staining for *Leishmania infantum* was then applied on both decalcified and non-decalcified lymph node sections. The amastigotes were stained and detected in non-decalcified sections, whereas a significant reduction of immunostaining was observed in decalcified sections. It is likely that parasite antigens are altered by the decalcification procedure, probably as a result of the long lasting effect of decalcifying acids on both the amastigotes and the host cell cytoplasm. Consequently, it seems that immunohistochemical detection of *Leishmania infantum* amastigotes is significantly affected following prolonged tissue decalcification.

Key words: decalcification of soft tissues, immunohistochemistry, *Leishmania infantum*, dog

ΠΕΡΙΛΗΨΗ. Σκοπός της αναφοράς αυτής είναι η παρουσίαση των προκαταρκτικών αποτελεσμάτων της επίδρασης της παρατεταμένης απασβέστωσης πάνω στην ανοσοϊστοχημική χρώση της *Leishmania infantum* σε μονιμοποιημένους σε φορμόλη και εμποτισμένους σε παραφίνη ιστούς σκύλου. Χρησιμοποιήθηκε γνυακό λεμφογάγγλιο με έντονη παρασίτωση με αμαστιγωτά της *Leishmania infantum*. Το μισό από το λεμφογάγγλιο, μετά τη χειρουργική του αφαίρεση, υποβλήθηκε στη διαδικασία απασβέστωσης (διάρκειας 40 ημερών) σε αντίθεση με το άλλο μισό. Η ανοσοϊστοχημική χρώση της *Leishmania infantum* εφαρμόστηκε στη συνέχεια σε απασβεστωμένες και μη απασβεστωμένες τομές του λεμφογαγγλίου. Στις τελευταίες, τα αμαστιγωτά χρώ-

Correspondence: Papadogiannakis E., Department of Veterinary Public Health, National School of Public Health, 196 Alexandras Avenue, 115 21 Athens, Greece
E-mail:dermpap1@otenet.gr

Αλληλογραφία: Ε. Παπαδογιαννάκης, Τομέας Κτηνιατρικής Δημόσιας Υγείας, Εθνική Σχολή Δημόσιας Υγείας, Λεωφ. Αλεξάνδρας 196, 115 21 Αθήνα
E-mail:dermpap1@otenet.gr

Submission date: 26.09.2007
Approval date: 02.01.2008

Ημερομηνία υποβολής: 26.09.2007
Ημερομηνία εγκρίσεως: 02.01.2008

στηκαν και ανιχνεύθηκαν χωρίς δυσκολία σε αντίθεση με τις απασβεστωμένες τομές. Πιθανόν, τα παρασιτικά αντιγόνα τροποποιούνται με τη διαδικασία της απασβέστωσης λόγω της παρατεταμένης επίδρασης των οξέων που χρησιμοποιούνται πάνω στα αμαστιγωτά όσο και στο κυτταρόπλασμα των κυττάρων. Επομένως, η ανοσοϊστοχημική ανίχνευση των αμαστιγωτών της *Leishmania infantum* φαίνεται να επηρεάζεται σημαντικά μετά από παρατεταμένη απασβέστωση του ιστού.

Λέξεις ευρετηρίασης: απασβέστωση μαλακών ιστών, ανοσοϊστοχημική χρώση, *Leishmania infantum*, σκύλος

Canine visceral leishmaniosis is a protozoal infection caused by *Leishmania infantum* (Dereure et al. 1999, Gradoni 1999). Several methods are currently used for the diagnosis of the disease, such as serology, culture, microscopic detection of the parasite in bone marrow and lymph node aspirates and PCR. Histopathological examination of skin or other organ biopsies, routinely stained with hematoxylin and eosin, is usually inconclusive when the parasite number is low. In these cases, the immunohistochemical staining of leishmania amastigotes has proved to be undoubtedly efficient in establishing the diagnosis (Bourdoiseau et al. 1997). Canine visceral leishmaniosis is believed to be a cause of claw disease that is usually reminiscent of immune-mediated (e.g lupus erythematosus) or auto-immune skin disease (Koutinas, unpublished data). Amputation of the distal phalanx of a digit is commonly used for histopathological examination following decalcification of the bone of the excised phalanx. The purpose of this study was to evaluate the effect of the above decalcification protocol on the immunohistochemical staining of *Leishmania infantum* amastigotes in formalin-fixed, paraffin-embedded canine soft tissues. The material consisted of surgically excised, formalin-fixed, popliteal lymph node from a dog examined at the Small Animal Hospital of the Veterinary School of the University of Thessaloniki. The diagnosis of leishmaniosis was confirmed both by cytology of fine needle aspiration biopsy from popliteal lymph nodes and serologic indirect fluorescent test (*Leishmania*-Spot IF, Biomerieux, Marcy l'Etoile, France). Direct smear made from the aspirated material and stained with Haemacolor stain (Merck, Darmstadt, Germany) revealed a high number of *Leishmania infantum* amastigotes under light microscopy. Following the establishment of the diagnosis, the left popliteal lymph node was surgically excised. One half of the lymph node was fixed in 10% neutral buffered formalin and then embedded in paraffin according to routine procedures, while the other half underwent decalcifi-

cation, before being routinely processed. For decalcification, the tissue was placed in a solution consisted of sodium citrate and formic acid, prepared according to the following protocol: solution A was prepared by adding 50g anhydrous sodium citrate or 81.1 g hydrate sodium citrate to 250 ml of distilled water, while solution B is prepared by adding 125 ml formic acid 90% to 125 ml of distilled water. Then solutions A and B were mixed and the distal phalanx was placed in decalcifying solution for 10 days. This step was repeated 4 times, with freshly prepared solution each time, rising the overall decalcification period to 40 days (Bancroft and Cook 1984). Both samples were then sectioned at 6 μ m (six sections each) and stained with the immunohistochemical procedure described for labelling *Leishmania infantum* amastigotes (Bourdoiseau et al. 1997) with several modifications (Papadogiannakis et al. 2005). Briefly, the slides were deparaffinized, hydrated and incubated in 4% hydrogen peroxide to block endogenous peroxidase activity. A hyper-immune serum from another dog naturally infected with *Leishmania infantum* (IFA titer: 1/3200) diluted 1:100 in 0.01M PBS was used as primary antibody. Following an over night incubation at 4°C in a humid chamber and washing in PBS, the slides were incubated with sheep anti-canine IgG conjugated with horseradish peroxidase (Serotec, Kidlington, Oxford, U.K). The reaction was developed with 3.3 diaminobenzidine (DAB) solution (Sigma, St. Louis, MO, U.S.A). Finally, the slides were dehydrated, cleared, counter-stained with Harris' hematoxylin and mounted with coverslips. Before being incubated with the primary antibody, three sections were subjected to antigen retrieval in citrate buffer, 0.1M, pH 6 in a microwave oven for 15 min, as previously described (Shi et al. 1993).

Leishmania infantum amastigotes were stained and easily detected in non-decalcified sections without antigen retrieval (Figure 1). However, in decalcified sections, even those that underwent the antigen retrieval procedure, the immunohistochemical staining

Figure 1. Non-decalcified lymph node section in which a high number of *Leishmania infantum* amastigotes are seen by immunohistochemistry (DAB chromogen, x 1000).

Εικόνα 1. Ιστολογική τομή από μη απα-σβεστωμένο λεμφογάγγλιο στο οποίο παρατηρείται μεγάλος αριθμός αμαστιγωτών της *Leishmania infantum* με ανοσοϊστοχημική χρώση (χρωμογόνο DAB, x 1000).

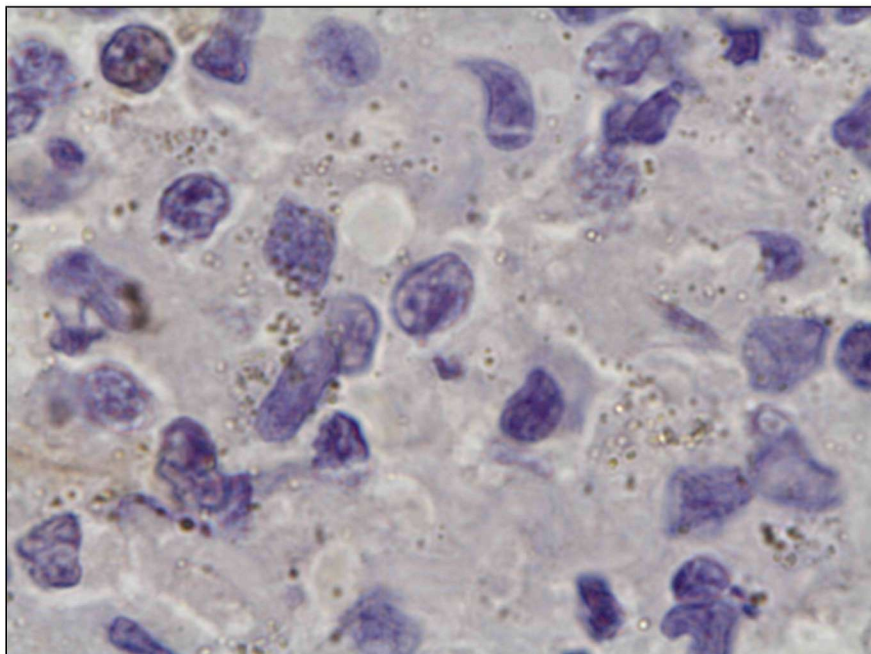
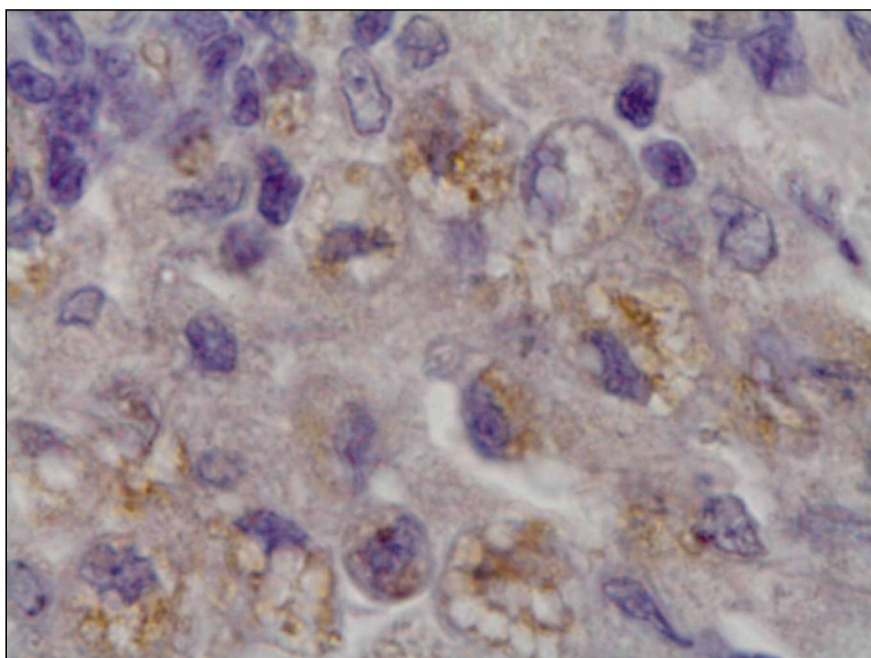


Figure 2. Decalcified lymph node section in which severe vacuolation of the cytoplasm of parasitized cells is observed along with significantly reduced staining of *Leishmania infantum* amastigotes by immunohistochemistry following antigen retrieval (DAB chromogen, x 1000).

Εικόνα 2. Ιστολογική τομή από απα-σβεστωμένο λεμφογάγγλιο στο οποίο παρατηρείται έντονη κενотоποίηση του κυτταροπλάσματος των παρασιτισμένων κυττάρων παράλληλα με σημαντική μείωση της χρώσης των αμαστιγωτών της *Leishmania infantum* με ανοσοϊστοχημική χρώση μετά την αποκάλειψη του αντιγόνου (χρωμογόνο DAB, x 1000).



intensity was significantly reduced leading to the observation of a low number of faintly stained amastigotes in most areas of the sections. Additionally, severe vacuolation of the cytoplasm of parasitized cells was also observed making the detection of faintly stained amastigotes even more difficult (Figure 2). Since vacuolar degeneration of basal cells has already been observed in claw biopsies in canine leishmaniosis, but also in several other diseases of the canine claws,

decalcification procedure, which is always applied in claw biopsies, cannot be excluded as the cause of this vacuolation.

The decalcification procedure, applied in this study, significantly reduced the immunohistochemical staining of *Leishmania infantum* amastigotes, probably because several epitopes were destroyed or modified by the prolonged action of the decalcifying agents on the structure of the parasite antigens. This assumption

is further supported by the fact that immunohistochemical staining of amastigotes was significantly reduced even when antigen retrieval was employed. The severe vacuolation of the cytoplasm, observed in many parasitized cells, could be attributed to the long lasting action of the formic acid on the sulfur-containing structures of the cytoplasm leading to carbon monoxide elaboration or to the degenerating effect of the chemicals on cytoplasmic vacuoles or other structures.

Lymphocytic interface dermatitis has recently been observed in claw beds of dogs with positive diagnosis of leishmaniosis both in clinically unaffected claws as well as in dogs presenting with onychogryposis, without observation of *Leishmania infantum* amastigotes in amputated and decalcified distal phalanx sections stained with hematoxylin and eosin (Koutinas, unpublished data). Immunohistochemical staining for the detection of *Leishmania infantum* amastigotes in these cases would offer a necessary next step in further elucidating the pathogenesis of canine leishmaniosis. However, based on the results of this study, the amputation of the distal phalanx and the subsequent

decalcification described above would most likely interfere significantly with the immunohistochemical staining of amastigotes. As an alternative, either another decalcification protocol could be used following its evaluation, or preferably, the onychobiopsy without onychectomy technique for canine claws (Muller and Olivry 1999) could be performed which due to the small size of the bone sampled, decalcification time is short and probably immunostaining of amastigotes would not be affected significantly, since at least in humans it has been shown that immunoperoxidase staining of several antigens (in particular IgG and IgA) in soft tissues are not affected significantly when the decalcification time is short (Mukai et al. 1986). Further research has to be carried out in order the results of this preliminary study to be better evaluated, in which a higher number of samples both from dogs with leishmaniosis and normal dogs will be examined.

Acknowledgement

The authors would like to thank Mr. John Kouroudis and Mrs Theodora Kalafati for the excellent technical assistance. ■

REFERENCES - ΒΙΒΛΙΟΓΡΑΦΙΑ

- Bancroft J and Cook H (1984) Manual of histological techniques. London, Churchill Livingstone.
- Bourdoiseau G, Marchal T and Magnol J (1997) Immunohistochemical detection of *Leishmania infantum* in formalin-fixed, paraffin-embedded sections in canine skin and lymph nodes. *Journal of Veterinary Diagnostic Investigation* 9(4): 439-440.
- Dereure J, Pratlong F and Detet J (1999) Geographical distribution and the identification of parasites causing canine leishmaniasis in the Mediterranean Basin. *Proceedings of the International Canine Leishmaniasis Forum*. Barcelona, Spain pp 18-25.
- Gradoni L (1999) Epizootiology of canine leishmaniasis in southern Europe. *Proceedings of the International Canine Leishmaniasis Forum*. Barcelona, Spain pp 32-39.
- Mukai K, Yoshimura S and Anzai M (1986) Effects of decalcification on immunoperoxidase staining. *Am J Surg Pathol* 10(6):413-419.
- Muller R and Olivry T (1999) Onychobiopsy without onychectomy: description of a new biopsy technique for canine claws. *Veterinary Dermatology* 10:55-59.
- Papadogiannakis E, Koutinas A, Saridomichelakis M et al. (2005) Cellular immunophenotyping of exfoliative dermatitis in canine leishmaniosis (*Leishmania infantum*). *Veterinary Immunology and Immunopathology* 104:227-237.
- Shi S, Chaiwun B, Cote R and Taylor C (1993) Antigen retrieval technique utilizing citrate buffer or urea solution for immunocytochemical demonstration of androgen receptor in formalin-fixed paraffin sections. *Journal of Histochemistry and Cytochemistry* 41:1599-1604.