

## Journal of the Hellenic Veterinary Medical Society

Vol 57, No 4 (2006)



### Sensitivity, specificity and accuracy of diagnostic imaging methods for the diagnosis of ectopic ureters in the dog

P. MANTIS, D. BROCKMAN, C. WHATMOUGH, S. P. GREGORY, C. R. LAMB, P. MAHONEY, S. JAKOVLJEVIC

doi: [10.12681/jhvms.15059](https://doi.org/10.12681/jhvms.15059)

#### To cite this article:

MANTIS, P., BROCKMAN, D., WHATMOUGH, C., GREGORY, S. P., LAMB, C. R., MAHONEY, P., & JAKOVLJEVIC, S. (2017). Sensitivity, specificity and accuracy of diagnostic imaging methods for the diagnosis of ectopic ureters in the dog. *Journal of the Hellenic Veterinary Medical Society*, 57(4), 289–296. <https://doi.org/10.12681/jhvms.15059>

## Sensitivity, specificity and accuracy of diagnostic imaging methods for the diagnosis of ectopic ureters in the dog

Mantis P.<sup>1</sup>, Brockman D.<sup>1</sup>, Whatmough C.<sup>1</sup>, Gregory S. P.<sup>1</sup>, Lamb C. R.<sup>1</sup>, Mahoney P.<sup>1</sup>, Jakovljevic S.<sup>2</sup>

**ΠΕΡΙΛΗΨΗ.** Σκοπός της αναδρομικής αυτής μελέτης είναι η διερεύνηση της ευαισθησίας, ειδικότητας και ακρίβειας των απεικονιστικών μεθόδων που χρησιμοποιούνται για τη διάγνωση του έκτοπου ουρητήρα στο σκύλο. Μελετήθηκε αρχειακό υλικό του νοσοκομείου ζώων Queen Mother Hospital for animals του Royal Veterinary College της Μεγάλης Βρετανίας από το Νοέμβριο του 1995 μέχρι τον Ιανουάριο του 2006. Μόνο σκύλοι με τουλάχιστον μία ακτινολογική μελέτη με χρήση σκιαγραφικής ουσίας, υπερηχογραφική εξέταση, εξέταση των ουρητήρων και χειρουργική διάγνωση συμπεριελήφθησαν. Πραγματοποιήθηκε συγκριτική αξιολόγηση της ενδοφλέβιας ουρογραφίας (ΕΟ), παλλίνδρομης ουρογραφίας (ΠΟ), υπερηχογραφικής εξέτασης (ΥΠΟ) και χειρουργικής διάγνωσης. Όλα τα περιστατικά αξιολογήθηκαν ανά ουρητήρα ξεχωριστά, αλλά και με βάση το περιστατικό συνολικά ανεξάρτητα από την απόληξη του κάθε ουρητήρα. Η ΥΠΟ βρέθηκε να έχει την υψηλότερη ευαισθησία, ειδικότητα και ακρίβεια ανά περιστατικό και με βάση την τελική διάγνωση, ενώ η ΕΟ είχε υψηλότερη ευαισθησία στην ανάλυση ανά ουρητήρα. Το κυριότερο μειονέκτημα της ΥΠΟ είναι η μη εντόπιση της σωστής θέσης του έκτοπου ουρητήρα. Όταν η ανάλυση πραγματοποιήθηκε με βάση την τελική διάγνωση του περιστατικού και ανεξάρτητα από την απόληξη του κάθε ουρητήρα, η ΥΠΟ είχε τέλεια ευαισθησία, ειδικότητα και ακρίβεια. Η χαμηλότερη ειδικότητα και ακρίβεια των μεθόδων ΕΟ και ΠΟ φαίνεται να σχετίζεται με τη δυσκολία αναγνώρισης της θέσης απόληξης των ουρητήρων.

### Introduction

The ureters originate from the kidneys and course caudoventrally and medially towards the neck of the urinary bladder. Each ureter terminates on the respective dorsolateral aspect of the urinary bladder at the ureterovesicular junction, just caudal to the neck,

## Sensitivity, specificity and accuracy of diagnostic imaging methods for the diagnosis of ectopic ureters in the dog

Mantis P.<sup>1</sup>, Brockman D.<sup>1</sup>, Whatmough C.<sup>1</sup>, Gregory S. P.<sup>1</sup>, Lamb C. R.<sup>1</sup>, Mahoney P.<sup>1</sup>, Jakovljevic S.<sup>2</sup>

**ABSTRACT.** The clinical records of dogs with urinary incontinence, examined at the Queen Mother Hospital for animals between November 1995 and January 2006, were reviewed. Only dogs that had at least one contrast radiographic study, ultrasonographic examination of the ureters and surgical diagnosis were included. All the cases were examined on an individual ureter basis and on a case basis. The sensitivity, specificity and accuracy were calculated for intravenous urography, retrograde urethrography or retrograde vaginourethrography and ultrasonographic examination of the ureterovesicular junctions. Ultrasonographic examination of the ureterovesicular junctions had the higher sensitivity, specificity and accuracy from the imaging methods with only intravenous urography having mildly higher sensitivity when examined on a ureter base. The main failure of ultrasonographic examination of the ureterovesicular junctions was the identification of the correct side of ectopia. When evaluated on a case basis ultrasonographic examination of the ureterovesicular junctions had perfect sensitivity, specificity and accuracy. The lower mainly specificity and accuracy of intravenous urography and retrograde urethrography or retrograde vaginourethrography were probably related to the difficulty in identifying the location of the ureterovesicular junction.

**Keywords:** radiography, ultrasonography, ectopia, urinary system, ureter

after a short intramural course. Dysembryogenesis may cause one or both ureters to terminate in an abnormal site, hence the term ectopic ureter(s). Ectopic ureters are a common cause of urinary incontinence in dogs, especially in bitches. Various types of ectopic ureter(s) have been described including the intramural, intramural

<sup>1</sup>Department of Veterinary Clinical Sciences, Royal Veterinary College, Hawkshead Lane, North Mymms, Hatfield, Hertfordshire AL9 7TA

<sup>2</sup>Dick White Referrals, Station Farm, London Rd, Six Mile Bottom, Newmarket, Suffolk CB8 0UH

<sup>1</sup>Department of Veterinary Clinical Sciences, Royal Veterinary College, Hawkshead Lane, North Mymms, Hatfield, Hertfordshire AL9 7TA

<sup>2</sup>Dick White Referrals, Station Farm, London Rd, Six Mile Bottom, Newmarket, Suffolk CB8 0UH



with double opening, extramural, ureteral trough and intramural with no distal orifice (Mason et al 1990, Stone and Mason 1990, Osborne et al 1995, Fossum 1997).

A combination of intravenous urography, cystography and retrograde urethrography or retrograde vaginourethrography is commonly performed in an attempt to diagnose ectopic ureter(s) (Holt et al 1982, De Baerdemaeker et al 1984, Mason et al 1990, Holt and Gibbs 1992, Holt and Hotson Moore 1995, Osborne et al 1995). Ultrasonography is a relatively recent addition to the imaging examinations used for the diagnosis of ectopic ureters. Ultrasonographic examination of the ureterovesicular junctions allows identification of the ureterovesicular junctions as small structures protruding into the lumen of the urinary bladder, at its dorsolateral aspect (Douglas 1993). The appearance of ureteral jets originating from the ureterovesicular junction has been described in animals and humans (Cox et al 1992, Lamb and Gregory 1994, Lamb and Gregory 1998). Furthermore, a close correlation between ultrasonographic and surgical findings was found in a study of 14 dogs (Lamb and Gregory 1998).

The aim of this study was to evaluate the sensitivity, specificity and accuracy of intravenous urography, retrograde urethrography or retrograde vaginourethrography and ultrasonographic examination of the ureterovesicular junctions in the diagnosis of ectopic ureters.

## Materials and Methods

The clinical records of dogs examined at the Queen Mother Hospital for Animals for urinary incontinence between November 1995 and January 2006 were retrieved. Only dogs that had at least one radiographic contrast study, USU and surgical confirmation (or not) of ectopic ureter(s) were included in the present study. The dogs were divided into two groups. The positive group included the dogs with surgically confirmed ectopic ureters. The negative group included dogs with urinary incontinence and normal ureteral termination in the urinary bladder during surgery.

The radiographs from the animals of both groups were retrieved, randomised and reviewed simultaneously by a radiologist (PM) and a soft tissue surgeon (DB), who were blind to the final diagnosis. Both reviewers were required to agree on a final radiographic diagnosis. The original ultrasonographic diagnosis, made at the time of the clinical examination, was noted.

The intravenous urography (IVU) was performed on anaesthetised dogs after intravenous injection of iodinated contrast material (Urographin 370, Schering AG ltd) at a dose of 800mg of iodine per kilogram of body weight.

Radiographs were taken prior to and after injection of contrast material at times 0 minute (ventrodorsal view of the abdomen), 5 minutes (ventrodorsal view of the abdomen), 10 minutes (lateral view of the abdomen) and 15 minutes (ventrodorsal and lateral views of the caudal abdomen). A pneumocystogram was performed prior to the contrast injection to assist in better visualisation of the ureteral termination.

Retrograde urethrography (RU) was performed, in male dogs, by injecting in the urethra an iodinated contrast material (Urographin 370, Schering AG ltd) diluted with sterile water to half the original strength, through a catheter placed in the penile urethra. A right lateral view of the area of the caudal abdomen was taken at the end of the injection, with the hind limbs of the dogs extended cranially. Retrograde vaginourethrography (RVU) was performed by injecting the contrast material through a Foley catheter with the balloon inflated and securely placed in the vagina at a level caudal to the urethral orifice. Lateral radiographs of the caudal abdomen and pelvic region were obtained immediately after the end of the injection. The amount of contrast given was empirically calculated based on the size of the animal with a dose of approximately 1ml/ kg of body weight.

In cases with both IVU and RU/ RVU examinations, IVU was performed first followed, as it is the examination protocol, by RU/RVU. For both IVU and RU/RVU identification of a ureter not terminating into the bladder was considered positive sign for ectopia. If the termination of the ureter was uncertain, the result was considered equivocal and was noted as uncertain.

Four examiners, all experienced board-certified radiologists, performed the ultrasonographic examinations of the dogs included in the present study. The ultrasonographic examination of the ureterovesicular junctions (USU) was performed after the contrast radiographic studies, the ultrasonographer possibly having prior knowledge of the radiographic findings. The transducer was placed on the ventral abdominal wall close to the midline with the dog on either lateral or dorsal recumbency. In some cases a parasagittal approach was used for better visualisation of the terminal part of the ureters and their termination. All the examinations were performed using a 7.5 MHz sector (Apogee CX, ATL Ltd., Letchworth, Herts., UK) or an 8.5 MHz curvilinear (Sequoia 512, Acuson Ltd, Hounslow, Middlesex, UK) transducer. In cases that the ultrasonographic examination was performed after the contrast studies, no noticeable deterioration of the ultrasonographic image quality was noticed. Identification of an ureter extending caudally beyond the bladder with no evident termination into the bladder

**Table 1. Results of the evaluation on an individual ureter basis.**

Animals				IVU		RU/RVU		USU		Surgery		
Dog	Breed	Age (yr)	Sex	Right ureter	Left ureter	Right ureter	Left ureter	Right ureter	Left ureter	Right ureter	Left ureter	
1	Labrador	2.2	MN	+	+	+	+	+	-	+	-	
2	Labrador	0.3	F	+	+	+	+	+	-	+	-	
3	Labrador	3.5	F	+	+	N/A	N/A	+	-	+	-	
4	Golden Retriever	0.5	F	+	+	N/A	N/A	-	+	-	+	
5	Golden Retriever	9	M	+	+	+	+	+	+	+	+	
6	Labrador	1.1	F	+	+	+	+	+	+	+	+	
7	Labrador	0.5	F	+	?	+	?	?	+	+	-	
8	Crossbred	0.7	FN	+	+	+	+	+	+	+	+	
9	Bulldog	0.7	FN	+	+	+	+	+	+	+	+	
10	Border Terrier	0.5	F	?	+	?	+	?	+	-	+	
11	Jack Russell Terrier	2.7	FN	-	?	?	+	+	-	+	-	
12	Golden Retriever	0.4	F	?	+	+	+	-	+	-	+	
13	Labrador	0.4	F	+	+	+	+	+	-	-	+	
14	Labrador	0.7	F	+	+	?	?	+	+	-	+	
15	Golden Retriever	3.8	M	+	+	+	+	+	+	+	+	
16	SBT	0.4	F	+	?	+	?	+	-	+	-	
17	Irish Setter	12.3	FN	?	?	-	-	-	-	-	-	
18	Irish Setter	1.4	FN	?	?	-	-	-	-	-	-	
19	Labrador	0.3	F	+	-	+	+	+	+	+	-	
20	English Springer Spaniel	12.3	FN	-	-	-	-	-	-	-	-	
21	Bulldog	2.1	F	?	?	?	?	?	?	+	-	
22	Dalmatian	3.3	FN	?	?	-	-	-	-	-	-	
23	English Shorthaired Pointer	1.5	F	-	-	?	?	-	-	-	-	
24	Labrador	1.5	FN	+	-	?	?	+	-	+	-	
Totals:												
				+	15	13	12	12	14	11	14	10
				-	3	4	4	4	7	12	10	14
				?	6	7	6	6	3	1	0	0
				N/A	0	0	2	2	0	0	0	0

F = female; M = male; FN = female neutered; MN = male neutered

? = termination of the ureter not definitely identified; + = ectopic ureteral termination; - = normal ureteral termination

N/A = Not Available

IVU = intravenous urography; RU = retrograde urethrography; RVU = retrograde vaginourethrography;

USU = ultrasonography of the ureterovesicular junctions

or no identification of the ureteral jets within the bladder was considered positive for ectopia.

All the cases were assessed on an individual ureter basis and on a case basis. On a case basis, only the presence or absence of ectopic ureters was noted. Using the above data, sensitivity, specificity and accuracy of each imaging modality were calculated. Sensitivity was calculated as the percentage of ectopic ureters that were correctly diagnosed in each study. Therefore, when assessed on a case basis, sensitivity was calculated as the percentage of dogs having at least one ectopic ureter

that was diagnosed as ectopic. Specificity was calculated as the percentage of ureters terminating normally in the urinary bladder and that were diagnosed as normal in each individual study. On a case basis, specificity was calculated as the percentage of dogs that were diagnosed as having normal ureteral terminations (Vining and Gladish, 1992). Accuracy was calculated as the percentage of correctly diagnosed normal and abnormal ureters. On a case basis, accuracy was calculated as the percentage of all the dogs with a correct final diagnosis.



**Table 2. Results of the evaluation on a case basis irrespective of unilateral or bilateral ureteral ectopia.**

Dog	Breed	Age (yr)	Sex	IVU	RU/RVU	USU	Final diagnosis
1	Labrador	2.2	MN	+	+	+	+
2	Labrador	0.3	F	+	+	+	+
3	Labrador	3.5	F	+	N/A	+	+
4	Golden Retriever	0.5	F	+	N/A	+	+
5	Golden Retriever	9	M	+	+	+	+
6	Labrador	1.1	F	+	+	+	+
7	Labrador	0.5	F	+	+	+	+
8	Crossbred	0.7	FN	+	+	+	+
9	Bulldog	0.7	FN	+	+	+	+
10	Border Terrier	0.5	F	+	+	+	+
11	Jack Russell Terrier	2.7	FN	?	+	+	+
12	Golden Retriever	0.4	F	+	+	+	+
13	Labrador	0.4	F	+	+	+	+
14	Labrador	0.7	F	+	?	+	+
15	Golden Retriever	3.8	M	+	+	+	+
16	SBT	0.4	F	+	+	+	+
17	Irish Setter	12.3	FN	?	-	-	-
18	Irish Setter	1.4	FN	?	-	-	-
19	Labrador	0.3	F	+	+	+	+
20	English Springer Spaniel	12.3	FN	-	-	-	-
21	Bulldog	2.1	F	?	+	+	+
22	Dalmatian	3.3	FN	?	-	-	-
23	English Shorthaired Pointer	1.5	F	-	?	-	-
24	Labrador	1.5	FN	+	+	+	+
Totals:							
				+	17	16	19
				-	2	4	5
				?	5	2	0
				N/A	0	2	0

F = female; M = male; FN = female neutered; MN = male neutered

? = presence of ureteral ectopia cannot be assessed; + = presence of ureteral ectopia; - = normal ureteral termination

N/A = Not Available

IVU = intravenous urography; RU = retrograde urethrography; RVU = retrograde vaginourethrography;

USU = ultrasonography of the ureterovesicular junctions

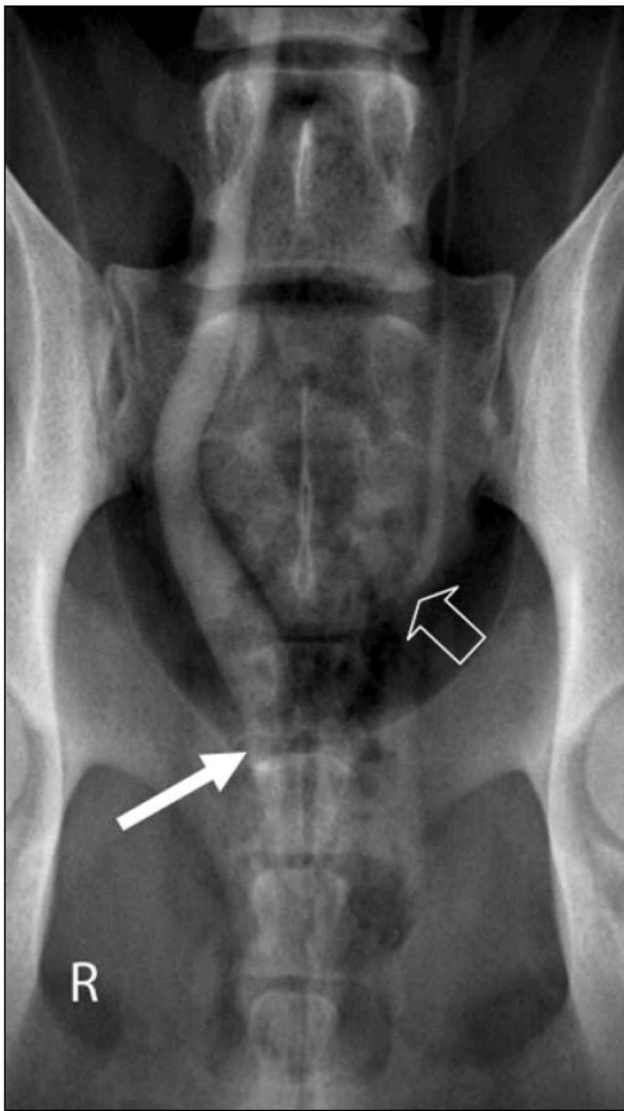
## Results

The results are summarized in tables 1 and 2. A total of 24 dogs, representing 48 ureters, satisfied the selection criteria and were included in the study: 19 dogs with surgically confirmed unilateral or bilateral ureteral ectopia (positive group) and 5 dogs with surgically confirmed normal ureteral terminations (control group). All dogs had IVU, 22 dogs had RU/RVU (17 from the positive and 5 from the control group) and all dogs had USU.

There were 21 females and 3 males of a variety of breeds: 16 females and 3 males in the positive group and

5 females in the control group. Labrador Retrievers were over-represented in the positive group. In the positive group the mean age for the male dogs was 5 years (2.2 – 9 years) and for the female dogs was 1 year (0.3 – 3.5 years). In the negative group, the mean age for the female dogs was 6.2 years (1.4 – 12.3 years). At surgery, unilateral ureteral ectopia was diagnosed in 14 dogs (right ectopic ureter in 9 dogs and left ectopic ureter in 5 dogs) and bilateral ectopia in 5 dogs.

IVU (table 1, figure 1) enabled the correct identification of 22 out of 24 ectopic ureters (sensitivity 91.7%) and 5 out of 24 normally ending ureters



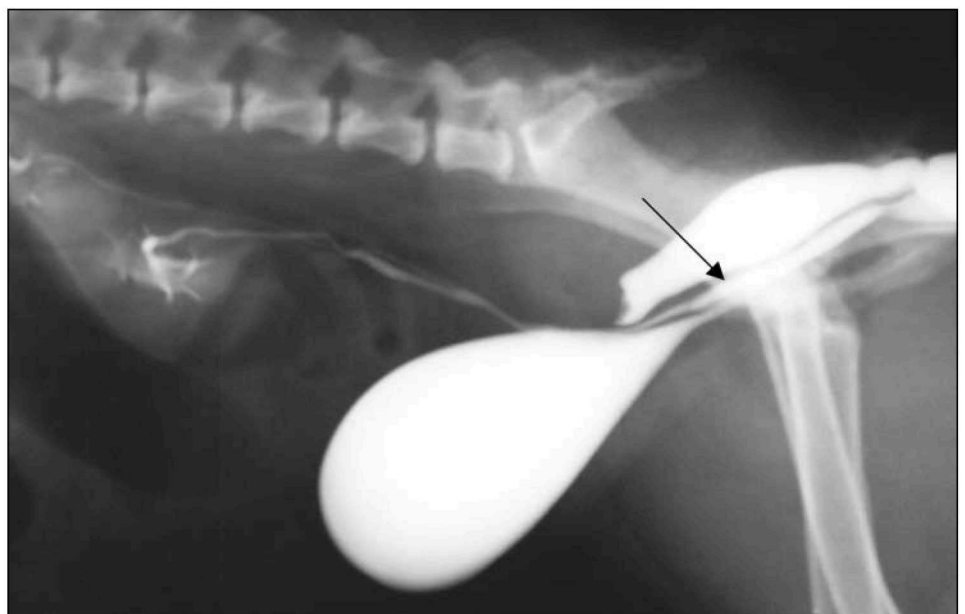
**Figure 1.** One and a half year old, female neutered Labrador retriever. Intravenous urography combined with pneumocystography: a ventrodorsal radiograph was obtained 5 minutes after the injection of contrast material. Right ectopic ureter is visible caudal to the urinary bladder and entering the urethra (long white arrow). The left ureter appears to terminate normally (open arrow). A pneumocystogram, in combination with IVU, greatly helps to outline the ureteral termination.

(specificity 20.8%). Overall, 27 out of 48 ureters were correctly diagnosed as normal or ectopic (accuracy 56.3%). For 13 ureters, the IVU findings were equivocal as the examiners could not identify their termination.

RU/RVU (table 1, figure 2) enabled the correct identification of 18 out of 22 ectopic ureters (sensitivity 81.8%) and 6 out of 22 normally ending ureters (specificity 27.3%). Overall, 28 out of 44 ureteral terminations were correctly diagnosed (accuracy 63.6%). For 12 ureters, RU/RVU did not allow to identify conclusively the ureteral termination. RU/RVU were not available in two cases.

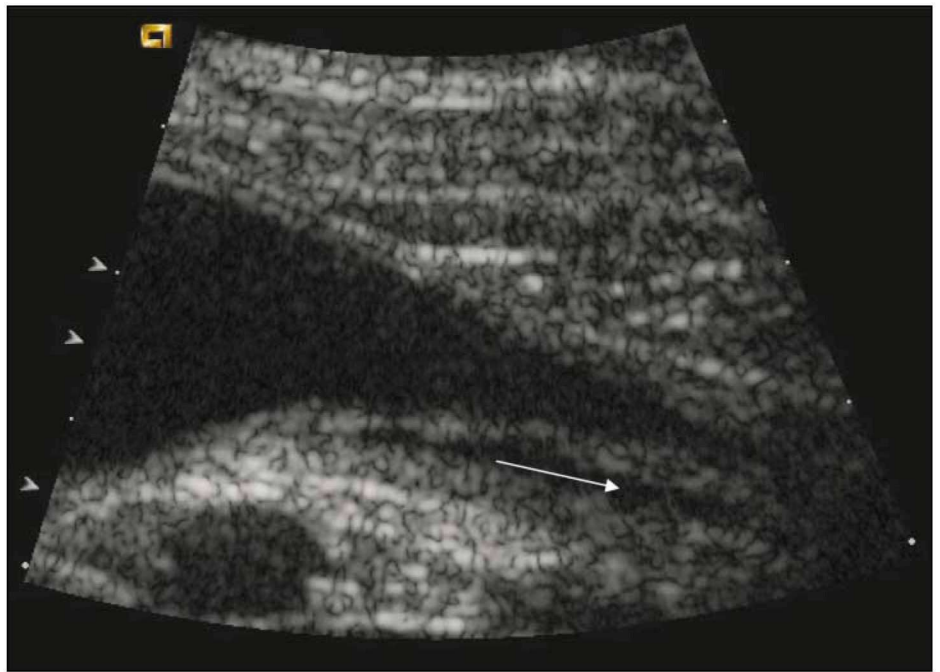
USU (table 1, figures 3 and 4) enabled the correct identification of 21 out of 24 ectopic ureters (sensitivity 87.5%) and 18 out of 24 normally ending ureters (specificity 75%). Overall, 39 out of 48 ureters were correctly diagnosed as normal or ectopic (accuracy 81.3%). The termination of 4 ureters could not be conclusively identified with USU.

On a case basis (table 2), when the diagnosis of ureteral ectopia was assessed irrespective of the side of the ectopia, IVU enabled the correct identification of 17 out of 19 dogs with ectopic ureters (sensitivity 89.5%).



**Figure 2.** Lateral radiograph from an 8-month-old-female-neutered Bulldog with bilateral ectopic ureters. A retrograde vaginourethrogram was performed immediately after intravenous urography. One ureter is clearly visible entering the urethra (arrow).





**Figure 3.** Oblique parasagittal image of the area of the bladder trigone and urethra of a 2-year-old Labrador Retriever. The right ureter (arrow follows ureteral lumen) appears to continue caudal to the bladder trigone.

The ureteral endings of 2 dogs could not be identified conclusively. IVU allowed correct identification of the ureteral termination in 2 of 5 dogs from the negative group (specificity 40%). No conclusion was reached in 3 control dogs. Overall, 19 of 24 dogs were diagnosed correctly (accuracy 75%).

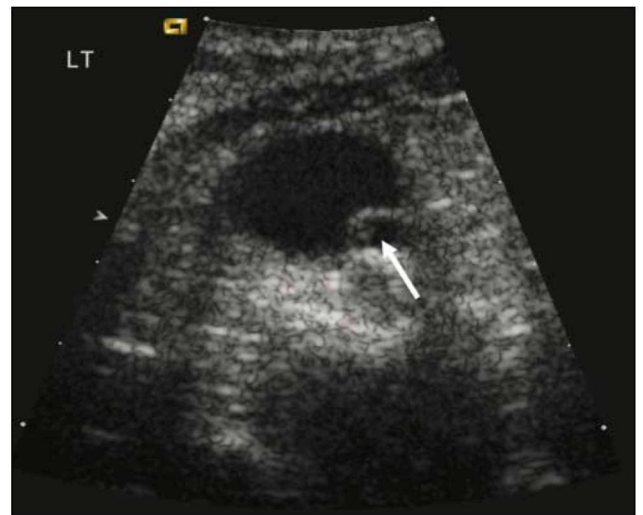RU/RVU, where available, enabled the correct identification of 16 out of 17 dogs with ectopic ureters (sensitivity 94.1%). There was no conclusion in one case. Four out of five negative dogs were correctly identified as normal (specificity 80%), while the RU/RVU findings were inconclusive in the remaining dog. Overall, 20 out of 22 animals were correctly diagnosed with RU/RVU (accuracy 90.9%).

USU enabled the correct identification of all the dogs with ureteral ectopia and the dogs from the negative group (sensitivity, specificity and accuracy 100%).

## Discussion

Thorough evaluation of the urinary tract, in dogs with urinary incontinence and suspicion of ectopic ureters, is required in order to choose an appropriate treatment. Survey radiographs of the abdomen, contrast radiographic studies and ultrasonographic examinations are performed in these cases in order to: confirm the presence of unilateral or bilateral ectopic ureters; evaluate the morphology of the urinary tract and identify the possible presence of associated abnormalities of the urinary tract (Mason and others 1990).

The results of this study confirm previously published results (Fossum 1997, Lamb 1998) that



**Figure 4.** Four-month-old Labrador Retriever. Transverse sonogram of the urinary bladder at the area of the trigone. The left ureter (arrow) appears dilated and not terminating in this area. The left ureter continued caudally and terminated in the cranial part of the urethra.

ectopic ureters are more common in female than in male dogs. The mean age of male dogs with ectopic ureters is higher than the mean age of female dogs with ectopic ureters, which is in agreement with other published findings (Holt and Hotson Moore 1995).

IVU had the highest sensitivity when the cases were examined on an ureter basis, and a very low specificity and accuracy, not only when the dogs were evaluated on a case basis, but also when evaluated on the basis of



individual ureters. The level of sensitivity of IVU identified in this study is higher to the level of sensitivity reported in previous studies (Carnizzo et al 2003, Samii et al 2004). The higher ratio of ureters wrongly diagnosed as ectopic with IVU in the present study, in comparison to the other studies, may be associated with the difficulty in identifying the exact termination of the ureter, which although it may appear to bypass the urinary bladder, actually enters the bladder in a normal fashion, as has also been observed previously (Holt, Gibbs and Pearson 1982, Hager and Blevins 1986).

In comparison with IVU, RU/ RVU showed lower sensitivity when examined on an individual ureter basis, but slightly higher when examined on a case basis. This could be a result of the lower number of animals included in the present study. However, this was an unexpected finding, since increased intravesicular pressure, caused by a full bladder during RU/RVU, is thought to enhance shunting of the urine with contrast through the ectopic ureteral branches, leading to a more exact identification of the ureteral ending. Based on the above reasoning, it would be expected that RU/RVU had a much higher sensitivity, especially in comparison to IVU. In some cases with an intrapelvic bladder, the superimposition of the pelvic bones caused difficulty in accurately identifying the ureteral ending. The decreased specificity of RU/RVU in comparison to USU reflects the difficulty in identifying normal ureters, especially when the ureteral ending is not clearly visible due to superimposed structures and/or contrast material. This, in combination with the appearance of the visible caudal part of the ureter, may lead to the erroneous diagnosis of ectopic ureter due to the ureter appearing to bypass the bladder, as it may also happen with IVU. Furthermore, RU/RVU showed higher sensitivity when examined on a case basis which can be attributed to the fact that only lateral radiographs were taken in the RU/RVU studies. The availability of single lateral radiograph has probably hindered the identification of the side of ureteral ectopia and the identification of the ureteral endings. An additional orthogonal view and/or oblique ventrodorsal views may have allowed a more unobstructed view of the trigone area of the urinary bladder. The sensitivity reported in this study is lower than the perfect sensitivity reported for urethrography in a previous study. This may be attributed to the use of static images taken at 2 frames per second and the use of also ventrodorsal views in that study (Samii et al 2004). Both studies though agreed in the very low specificity of urethrography in the diagnosis of ureteral ectopia.

USU had the highest specificity and accuracy in

comparison with the other imaging modalities. When the animals were evaluated on a case basis, taking into consideration only the final diagnosis, sensitivity, specificity and accuracy were 100%, indicating that the main limitation of USU lies in identification of the correct side of ureteral ectopia. Direct visualisation of the ureteral ending allows more certainty in the identification of the location. Factors that may hinder the examination include the difficulty in identifying the ureter if only mildly or not dilated and the difficulty in visualising both ureterovesicular junctions in the same plane on a transverse view in order to assess which ureter is ectopic. Furthermore, in some animals the ureterovesicular junctions were very small and difficult to identify. In these cases, the diagnosis, which may be based solely on the identification of the ureteral jets of urine and not on the identification of the actual ureterovesicular junctions, can lead to an erroneous diagnosis. In the latter case, the detection of an ureteral jet may give the false impression that the jet originated from a normal ureterovesicular junction, when in fact it had originated from an ectopic ureter and was directed retrogradely towards the urinary bladder. This is more likely to occur in cases where the ectopic ureter terminates in the most cranial portion of the urethra. Inability to identify the ureters during USU may be due to a combination of the above reasons or due to intrapelvic location of the bladder, which dramatically limits the available acoustic window and the freedom in positioning the transducer ventral to the bladder at the level of the ureterovesicular junctions. In spite of the fact that in most cases the ultrasonographer had previous knowledge of the radiographic findings, it is unlikely that the ultrasonographic diagnosis was influenced by these, even when the radiographic findings were positive, as evidenced by the difference in the radiographic and ultrasonographic diagnosis in some cases. Attribution of the ectopia to the wrong site, as in case 7, may be due to failure of the ultrasonographer to orient the image properly or due to the location of the urinary bladder to one side of the abdominal cavity that may give the wrong impression about the side of the ectopia, especially when the other ureter cannot be identified.

USU appears to have the highest sensitivity, specificity and accuracy of all the imaging methods that are commonly performed in cases of suspected ectopic ureters. However, these examinations are performed not only for the diagnosis of ectopic ureters, but also for the identification of concomitant abnormalities of the urogenital tract. The inability of the ultrasonographic examination to adequately evaluate the entire length of the ureter unless it is markedly dilated, and also the



inability to completely evaluate the genital tract, indicate that IVU and RU/RVU are also required for complete evaluation of the urogenital tract and for accurate surgical or medical treatment planning.

In order to improve the results of the imaging studies in the diagnosis of ectopic ureters, the following solutions are suggested: the radiographic studies and USU should be performed in a specific sequence, in order to obtain the most information from each examination and to provide specific answers to questions still remaining from the preceding studies of the sequence. It is suggested that plain radiographs should be followed by IVU, then RU/RVU, and finally by USU. Using a combination of contrast radiographic studies in cases of suspected ectopic ureters is also likely to improve results. Ventrodorsal and ventrodorsal

oblique views during RU/ RVU would probably increase the sensitivity of this method in the diagnosis of ectopic ureters, because it would help to avoid superimposition of structures in some cases with clearer visualisation of the ureteral termination. USU in transverse and parasagittal views would help to avoid false positive results that may ensue when only the transverse view is used.

In conclusion, this study outlines the lower sensitivity, specificity and accuracy for the radiographic methods and possibility of false positives for the USU in the identification of ureteral terminations. USU appears to be the imaging modality of choice for the evaluation of the ureterovesicular junctions in cases of suspected ureteral ectopia. □

## BIBΛΙΟΓΡΑΦΙΑ - REFERENCES

- Carnizzo, K.L., McLoughlin, M.A., Mattoon, J.S., Samii, V.F., Chew, D.J., DiBartola, S.P., 2003. Evaluation of transurethral cystoscopy and excretory urography for diagnosis of ectopic ureters in female dogs: 25 cases (1992-2000). *J.Am.Vet.Med.Assoc.* 223, 475-481.
- Cox, I.H., Erickson, S.J., Foley, W.D., Dewire, D.M., 1992. Ureteral jets: evaluation of normal flow dynamics with color Doppler sonography. *American Journal of Roentgenology* 158, 1051-1055.
- De Baerdemaeker, G.C., 1984. Post spaying vaginal discharge in a bitch caused by acquired vaginoureteral fistula. *Veterinary Record* 115, 62.
- Douglas, J.P., 1993. Bladder wall mass effect caused by the intramural portion of the canine ureter. *Veterinary Radiology & Ultrasound* 34, 107-107.
- Fossum, T.W., 1997. Surgery of the kidney and ureter. In: *Small Animal Surgery*. Mosby, St. Louis, USA, pp. 461-480.
- Hager, D., Blevins, W.E., 1986. Ectopic ureter in a dog: extension from the kidney to the urinary bladder and to the urethra. *Journal of the American Veterinary Medical Association* 189, 309-310.
- Holt, P.E., Gibbs, C., Pearson, H., 1982. Canine ectopic ureter-a review of twenty-nine cases. *Journal of Small Animal Practice* 23, 195-208.
- Holt, P.E., Gibbs, C., 1992. Congenital urinary incontinence in cats: A review of 19 cases. *Veterinary Record* 130, 437-442.
- Holt, P.E., Hotson Moore, A., 1995. Canine ureteral ectopia: An analysis of 175 cases and comparison of surgical treatments. *Veterinary Record* 136, 345-349.
- Lamb, C.R., Gregory, S.P., 1994. Ultrasonography of the ureterovesicular junction in the dog: a preliminary report. *Veterinary Record* 134, 36-38.
- Lamb, C.R., Gregory, S.P., 1998. Ultrasonographic findings in 14 dogs with ectopic ureter. *Veterinary Radiology & Ultrasound* 39, 218-223.
- Lamb, C.R., 1998. Ultrasonography of the ureters. *Veterinary Clinics of North America (Small Animal Practice)* 28: 823-848.
- Mason, L.K., Stone, E.A., Biery, D.N., Robertson, I., Thrall, D.E., 1990. Surgery of ectopic ureters: pre- and postoperative radiographic morphology. *Journal of the American Animal Hospital Association* 24, 73-79.
- Osborne, C.A., Johnson, G.R., Kruger, J.M., 1995. Ectopic ureters and ureteroceles. In: *Canine and Feline Nephrology and Urology*. Williams & Wilkins, Baltimore, USA, pp. 608-622.
- Samii, V.F., McLoughlin, A., Mattoon, J.S., Drost, T., Chew, D.J., DiBartola, S.P., Hoshaw-Woodard, 2004. Digital fluoroscopic excretory urography, digital fluoroscopic urethrography, helical computed tomography and cystoscopy in 24 dogs with suspected ureteral ectopia. *J Vet Intern Med* 18, 271-281.
- Stone, E.A., Mason, L.K., 1990. Surgery of ectopic ureters: Types, Method of Correction and postoperative results. *Journal of the American Animal Hospital Association* 26, 81-88.
- Vining, D.J., Gladish, G.W., 1992. Receiver operating characteristic curves: a basic understanding. *Radiographics* 12, 1147-1154.