


Journal of the Hellenic Veterinary Medical Society

Vol 63, No 3 (2012)



Control of liver abscesses in lambs by using marbofloxacin

D. C. ORFANOU (Δ.Κ. ΟΡΦΑΝΟΥ), I. A. FRAGKOU (Η.Α. ΦΡΑΓΚΟΥ), G. C. FTHENAKIS (Γ.Χ. ΦΘΕΝΑΚΗΣ), V. S. MAVROGIANNI (Β.Σ. ΜΑΥΡΟΓΙΑΝΝΗ)

doi: [10.12681/jhvms.15436](https://doi.org/10.12681/jhvms.15436)

To cite this article:

ORFANOU (Δ.Κ. ΟΡΦΑΝΟΥ) D. C., FRAGKOU (Η.Α. ΦΡΑΓΚΟΥ) I. A., FTHENAKIS (Γ.Χ. ΦΘΕΝΑΚΗΣ) G. C., & MAVROGIANNI (Β.Σ. ΜΑΥΡΟΓΙΑΝΝΗ) V. S. (2017). Control of liver abscesses in lambs by using marbofloxacin. *Journal of the Hellenic Veterinary Medical Society*, 63(3), 213–216. <https://doi.org/10.12681/jhvms.15436>

■ Control of liver abscesses in lambs by using marbofloxacin

Orfanou D.C., Fragkou I.A., Fthenakis G.C., Mavrogianni V.S.

Veterinary Faculty, University of Thessaly, 43100 Karditsa, Greece

■ Αντιμετώπιση ηπατικών αποστημάτων σε αρνιά με χρήση μαρβοφλοξακίνης

Ορφανού Δ.Κ., Φράγκου Η.Α., Φθενάκης Γ.Χ., Μαυρογιάννη Β.Σ.

Τμήμα Κτηνιατρικής, Πανεπιστήμιο Θεσσαλίας, 43100 Καρδίτσα

ABSTRACT. We describe cases of liver abscesses in a group of newborn lambs. Diagnosis was based on the combination of clinical signs with the findings of ultrasonographic examination of the abdomen: oval, hypoechoic structure with regular borders in the liver of the affected lambs. Administration of marbofloxacin (dose rate: 3.0 mg per kg bodyweight, on three occasions, once daily, two days apart) was effective for treatment; three weeks later, the affected lambs were clinically healthy.

Keywords: abscess, *Fusobacterium necrophorum*, liver, marbofloxacin, sheep

ΠΕΡΙΛΗΨΗ. Περιγράφονται περιστατικά ηπατικών αποστημάτων σε αρνιά. Η διάγνωση βασίστηκε στο συνδυασμό των κλινικών συμπτωμάτων με τα ευρήματα της υπερηχογραφικής εξέτασης της κοιλιάς: παρουσία ωοειδούς, υποηχογενούς σχηματισμού, με σαφή όρια στο ήπαρ των προσβεβλημένων αρνιών. Η χορήγηση μαρμποφλοξακίνης (δοσολογία: 3,0 mg ανά kg σωματικού βάρους, τρεις φορές, ανά δύο ημέρες) ήταν αποτελεσματική για την αντιμετώπιση της παθολογικής κατάστασης, καθώς, όπως φάνηκε σε επόμενη εξέταση των ζώων μετά από τρεις εβδομάδες, αυτά ήταν κλινικώς υγιή.

Λέξεις ευρετηρίασης: απόστημα, ήπαρ, μαρμποφλοξακίνη, πρόβατο, *Fusobacterium necrophorum*

Correspondence: V.S. Mavrogianni,
Veterinary Faculty, University of Thessaly, 43100 Karditsa, Greece.
E-mail: vmavrog@vet.uth.gr

Αλληλογραφία: Β.Σ. Μαυρογιάννη,
Τμήμα Κτηνιατρικής, Πανεπιστήμιο Θεσσαλίας, 43100 Καρδίτσα.
E-mail: vmavrog @vet.uth.gr

Date of initial submission: 13 June 2012
Date of revised submission: 3 July 2012
Date of acceptance: 4 July 2012

Ημερομηνία αρχικής υποβολής: 13 Ιουνίου 2012
Ημερομηνία αναθεωρημένης υποβολής: 3 Ιουλίου 2012
Ημερομηνία αποδοχής: 4 Ιουλίου 2012

INTRODUCTION

Three newborn lambs, liver abscesses ('liver abscess syndrome' or 'liver abscess complex') are usually the result of infection through the umbilical cord. *Fusobacterium necrophorum* is the most frequent aetiological agent of the disorder, although other organisms (e.g., *Arcanobacterium pyogenes*, *Staphylococcus* spp.) can also cause the disorder (Dennis, 1974; Al-Qudah and Al-Majali, 2003; Watkins, 2007). Apart from the liver, lesions may develop, occasionally, elsewhere in the body (e.g., joints). The condition is predisposed by substandard hygiene in the lambing pens, as contaminated bedding and increased temperature can facilitate rapid multiplication of microorganisms (Van Metre et al., 2008). There is very little information regarding treatment of the disorder. In general, treatment with 'appropriate antibacterial drugs' is recommended (Watkins, 2007); it has even been suggested that no treatment can be undertaken, as the disease is considered to be difficult to diagnose (British Columbia Ministry of Agriculture Food and Fisheries, 2006). However, for welfare reasons, there is a need for effective treatment of affected lambs, as well as because affected animals do not thrive and may develop secondary diseases, e.g. hepatitis or peritonitis (Foster et al., 2009).

In this paper, we describe control of liver abscesses in a group of newborn lambs by using marbofloxacin, a third-generation broad-spectrum fluoroquinolone. Fluoroquinolones can be useful in disorders caused by more than one pathogen, such as liver abscesses. Moreover, these drugs have excellent pharmacokinetic properties in soft tissues (including the liver, as postulated by Hamada et al. [2006]) and can achieve penetration into abscesses for bacterial killing therein (Papich and Riviere, 2001). The above properties make them potentially useful drugs for control of the disorder.

CASE DESCRIPTION

Three Lacaune-cross lambs (12- to 15-day-old) from a batch of 25 newborn (younger than three weeks) animals at the same semi-intensively managed (Gelasakis et al., 2010) farm were presented with depression and lack of appetite. The farmer mentioned that all lambs received colostrum immediately after birth; no tail-docking was practiced in the farm. At clinical examination, consistent findings in the three lambs were as follows: increased temperature

(>41.2 °C), distended abdomen, discomfort and pain during abdominal palpation, but absence of diarrhoea. One small abscess (0.4 cm in diameter) was seen on the abdominal wall, at the area of the umbilicus. No other abnormalities were evident during clinical examination; no abnormal findings were found either during auscultation of the lungs or during examination of the joints.

Ultrasonographic examination of the abdomen was performed by using a 6.0 MHz sector transducer, with a convex probe; 40 and 80 mm scanning depths were used. Special attention was paid to the area around the umbilicus, which was scanned with the probe at right angle to the abdominal wall, as well as to the area caudal to the costal arch, which was scanned with the probe pointed towards the shoulder (Scott and Sargison, 2010). The examination revealed a round to oval, hypoechoic, unilocular structure (~ 1.5×1.7 cm) with regular borders within the liver parenchyma (~ 1.0 cm sub-superficially) of the affected lambs (Fig. 1a). In one case, sedimentation could be scarcely observed at the central cavitation of the structure.

Based on all the above findings, a diagnosis of liver abscess was made. For treatment, marbofloxacin (dose rate: 3.0 mg per kg bodyweight) was injected subcutaneously to each clinically ill lamb on three occasions, once daily, two days apart. Other, clinically healthy, newborn lambs (n=22) in the farm were also injected once with the drug (dose rate as above). The farmer was also advised to improve conditions at the lambing pens and to dip the umbilical cord of every subsequently newborn lamb into iodine solution. The three affected lambs were examined at regular time-points (4, 7, 10, 14, 21 days) after treatment. All lambs in the farm were also re-examined 21 days after treatment.

In the three affected lambs, four days after instigation of treatment, rectal temperature and appetite returned to normal. No signs of pain or discomfort during abdominal palpation were evident two weeks after start of treatment; moreover, there was no evidence of the superficial abscess in the abdominal wall. Finally, three weeks after start of treatment, on ultrasonographic examination of the abdomen, only a small, focal lesion was seen; this was still hypoechoic to the surrounding liver (Fig. 1b), but of increased echogenicity compared to the lesion that had been observed at the original examination.

Further cases of the disorder were not diagnosed

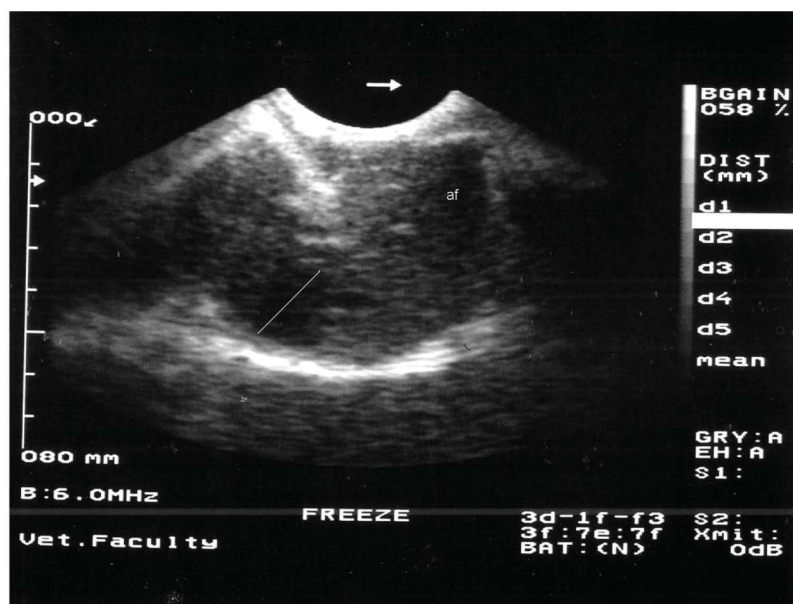


Fig. 1a. Findings in the liver of a lamb with abscess, during ultrasonographic examination: round to oval, hypoechoic, unilocular structure with regular borders (marked with bar across the borders) [af: artifact].

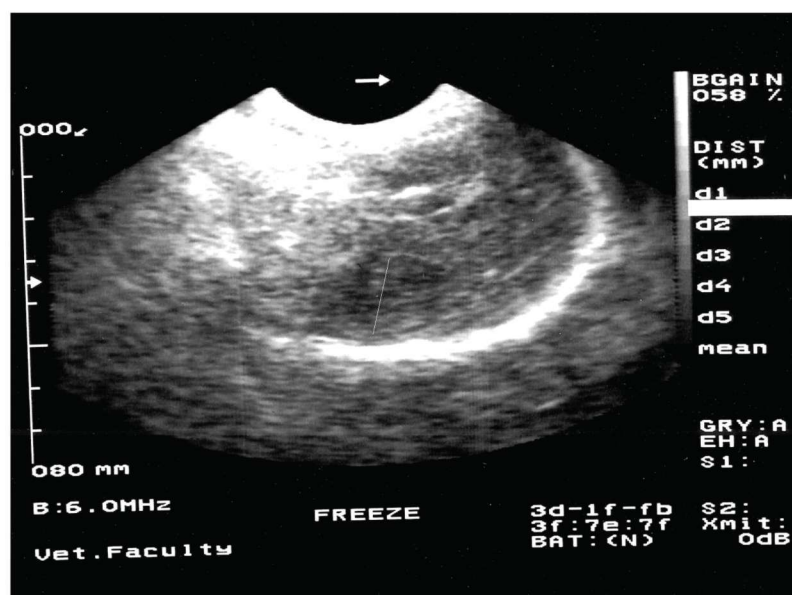


Fig. 1b. Findings in the liver of a lamb with treated abscess, during ultrasonographic examination three weeks after instigation of treatment: small, focal hypoechoic lesion (marked with bar across the borders); lesion is of increased echogenicity to that observed at the original examination (Fig. 1a.).

in the flock until the end of the lambing season, neither among the 22 lambs treated with marbofloxacin, nor among lambs born thereafter (n=85).

DISCUSSION

As mentioned above, there is very little information regarding treatment of liver abscesses in newborn lambs. Various approaches, in general vague, have been reported in the literature (British Columbia Ministry of Agriculture Food and Fisheries, 2006; Watkins, 2007).

In cattle, various treatment regimes have been suggested for the disorder. These include mainly administration of antibacterial agents, for example incorporation of tylosin (Simpson, 1969) or virginiamycin (Rogers et al., 1995) in the feed and injectable administration of sulphonamides (Radostits et al., 1999) or penicillin (Van Metre et al., 2008), but with varying and not always satisfactory results. In human medicine, effective treatment of liver abscesses includes administration of antimicrobial agents active against a broad-spectrum of pathogens (gram-positive, gram-negative; aerobic, anaerobic organisms) and starts immediately after diagnosis of the disorder (Johannsen et al., 2000); this approach is considered particularly effective in patients with unilocular abscesses less than 3 cm in diameter (Chung et al., 2007).

Diagnosis of disorders in newborn lambs can also be improved by the use of ultrasonography, as an adjunct to clinical examination (Scott and Sargison, 2010). In this case, the findings of ultrasonographic examination confirmed the presence of an intra-hepatic abscess and, allied to clinical findings, where a skin abscess had been first observed, led to diagnosis. The use of a non-invasive technique, i.e ultrasonography, was helpful and made the sacrifice of lambs unnecessary; thereafter, it also assisted in evaluation of treatment outcome.

Marbofloxacin (total dose: 9.0 mg per kg bodyweight) was effective for treatment of the disorder. In previous studies (Dubreuil et al., 1996), the drug has been found to be effective against anaerobic bacteria. Moreover, the pharmacokinetic properties of the drug support its use against soft tissue abscesses, as confirmed by effective treatment of the clinically ill lambs within three weeks after drug administration; it is noteworthy that the drug has a longer half-life than other fluoroquinolones (Papich and Riviere, 2001), hence increased antibacterial concentrations, necessary for penetration into abscesses, can be maintained for a longer period.

The combination of improved hygiene measures at the lambing pens with administration of a smaller dose

of the drug (3.0 mg per kg bodyweight) in lambs already born in the flock, i.e. being at risk to develop the disorder, could have contributed to avoid further cases. Prophylactic administration of antibiotics against the disorder has been documented in calves (Simpson, 1969; Rogers et al, 1995), but there is no evidence for similar benefits in small ruminants. Hence, it should be restricted in farms with confirmed cases of the syndrome (metaphylactic administration), if at all. Finally, to note that as fluoroquinolones may affect the developing cartilages of growing animals (Gough et al., 1992), treated lambs should not be maintained as replacement stock, but, after treatment and appropriate withdrawal period, they should be slaughtered, as was the case with the affected animals described in the current report. ■

REFERENCES

- Al-Qudah K, Al-Majali A (2003) Bacteriologic studies of liver abscesses of Awassi sheep in Jordan. *Small Rumin Res* 47:249-253.
- British Columbia Ministry of Agriculture Food and Fisheries (2006) Flock Health Guide for BC Sheep Producers. British Columbia Government, Vancouver, 51 pp.
- Chung YF, Tan YM, Lui HF, Tay KH, Lo RHG, Kurup A, Tan BH (2007) Management of pyogenic liver abscesses - percutaneous or open drainage? *Singapore Med J* 48:1158-1165.
- Dennis SM (1974) Perinatal lamb mortality in Western Australia. 4. Neonatal infections. *Aus Vet J* 50:511-514.
- Dubreuil L, Houcke I, Leroy I (1996) In vitro activity of a new fluoroquinolone, marbofloxacin (RO 09-1168), against anaerobes and some bacteria from the human gut. *Pathol Biol* 44:333-336.
- Foster AP, Otter A, Naylor R, Wessels ME, Veenstra B (2009) Hepatitis in a six-month-old lamb with *Fusobacterium varium* infection. *Vet. Rec.* 164:98.
- Gelasakis AI, Valergakis GE, Fortomaris P, Arsenos G (2010) Farm conditions and production methods in Chios sheep flocks. *J. Hell. Vet. Med. Soc.* 61:111-119.
- Gough AW, Kasali OB, Sigler RE., Baragi V (1992) Quinolone arthropathy: acute toxicity to immature articular cartilage. *Toxicol. Pathol.* 20:436-449.
- Hamada Y, Imaizumi H, Kobayashi M, Sunakawa K, Saigenji K, Yago K (2006): Liver abscess that responded well to pazufloxacin therapy. *J Infect Chemother* 12:42-46.
- Johannsen EC, Sifri CD, Madoff LC (2000) Pyogenic liver abscesses. *Inf Dis Clin North. Amer* 14:547-563.
- Papich MG, Riviere JE (2001) Fluoroquinolone antimicrobial drugs. In: Adams HR. (ed.) *Veterinary Pharmacology and Therapeutics*, 8th edn, Blackwell, Ames, pp. 898-917.
- Radostits OM, Gray CC, Blood DC, Hinchcliff KW (1999) *Veterinary Medicine. A Textbook on the Diseases of Cattle, Sheep, Pigs, Goats and Horses*, 9th edn. Elsevier, Philadelphia, 1831 pp.
- Rogers JA, Branine ME, Miller CR, Wray MI, Bartle SJ, Preston RL, Gill DR, Protchard RH, Stilborn RP, Bechtol DT (1995) Effects of dietary virginiamycin on performance and liver abscess incidence in feedlot cattle. *J Anim Sci* 73: 9-20.
- Scott PR, Sargison ND (2010) Ultrasonography as an adjunct to clinical examination in sheep. *Small Rumin Res* 92:108-119.
- Simpson KE (1969) Feeding Tylosin in attempting to control Liver Abscesses. MSc thesis, Texas Technological College, 34 pp.
- Van Metre DC, Tennant BC, Whitlock RH (2008) Infectious diseases of the gastrointestinal tract. In: T Divers, S Peek (eds) *Rebhun's Diseases of Dairy Cattle*. Saunders-Elsevier, St Louis. pp. 200-294.
- Watkins GH (2007) Arthritis. In: Aitken I. D. (ed.) *Diseases of Sheep*. Blackwell, Oxford. pp. 288-293.