ePublishing

Journal of the Hellenic Veterinary Medical Society

Vol 65, No 1 (2014)



Potential effect of Nigella sativa against Diethylnitrosamine-induced hepatocarcinogenesis in rats

S. E. AHMED, G. BRELLOU (Γ. ΜΠΡΕΛΛΟΥ), A. A. GAMEEL, P. LOUKOPOULOS (Π. ΛΟΥΚΟΠΟΥΛΟΣ), I. VLEMMAS (I. ΒΛΕΜΜΑΣ)

doi: 10.12681/jhvms.15511

To cite this article:

AHMED, S. E., BRELLOU (Γ. ΜΠΡΕΛΛΟΥ) G., GAMEEL, A. A., LOUKOPOULOS (Π. ΛΟΥΚΟΠΟΥΛΟΣ) P., & VLEMMAS (I. ΒΛΕΜΜΑΣ) I. (2017). Potential effect of Nigella sativa against Diethylnitrosamine-induced hepatocarcinogenesis in rats. *Journal of the Hellenic Veterinary Medical Society*, *65*(1), 35–42. https://doi.org/10.12681/jhvms.15511

https://epublishing.ekt.gr | **e-Publisher:** EKT | **Downloaded at:** 26/01/2026 03:37:27

J HELLENIC VET MED SOC 2014, 65(1): 35-42
ΠΕΚΕ 2014, 65(1): 35-42

Research article
Ερευνητικό άρθρο

Potential effect of *Nigella sativa* against Diethylnitrosamine-induced hepatocarcinogenesis in rats

Ahmed S.E.[1], Brellou G.[2], Gameel A.A.[3], Loukopoulos P.[2], Vlemmas I.[2]

[1]*Department of Molecular Biology, Veterinary Research Institute, Khartoum, Sudan.*
[2]*Department of Pathology, Faculty of Veterinary Medicine, Aristotle University of Thessaloniki, Thessaloniki, Greece.*
[3]*Department of Pathology, Faculty of Veterinary Medicine, University of Khartoum, Sudan.*

Μελέτη της επίδρασης της *Nigella sativa* σε αρουραίους, στους οποίους είχε προκληθεί πειραματικά καρκίνος του ήπατος μετά από χορήγηση διεθυλονιτροζαμίνης

Ahmed S.E.[1], Μπρέλλου Γ.[2], Gameel A.A.[3], Λουκόπουλος Π.[2], Βλέμμας Ι.[2]

[1]*Department of Molecular Biology, Veterinary Research Institute, Khartoum, Sudan.*
[2]*Εργαστήριο Παθολογικής Ανατομικής, Τμήμα Κτηνιατρικής, Σχολή Επιστημών Υγείας, Αριστοτέλειο Πανεπιστήμιο Θεσσαλονίκης, Θεσσαλονίκη.*
[3]*Department of Pathology, Faculty of Veterinary Medicine, University of Khartoum, Sudan.*

ABSTRACT. Objective of the investigation was the study of potential protective effects of the watery extract of *Nigella sativa* against diethylnitrosamine induced hepatocarcinogenesis in rats. *N. sativa* was administered to rats for protection against diethylnitrosamine-induced hepatocarcinogenesis. It was administered prior to, simultaneously with or after injection of diethylnitrosamine. Five groups of Wister rats were used. Group A was administered diethylnitrosamine and *N. sativa* simultaneously, group B was administered only diethylnitrosamine and group C received only *N. sativa*. These three groups were maintained for up to eight weeks. Group D received *N. sativa* six weeks after administration of diethylnitrosamine,while group E ("protective group") received *N. sativa* on day 1 and diethylnitrosamine six weeks later. These two groups were maintained for up to 12 weeks. All rats were subjected to partial hepatectomy to enhance carcinogenesis. P-isoform of glutathione s-transferase (GST-P) was detected in the cytoplasm and nuclei of hepatocytes. The number of GST-P positive foci was significantly smaller in test groups (A, D, E), particularly in groups A and E, when compared with to those in group B, indicating that *N. sativa* has protective effects against diethylnitrosamine induced liver cancer in rats, even in the very early stages of hepatocarcinogenesis.

Keywords: diethylnitrosamine, GST-P, hepatocarcinogenesis, *Nigella sativa*

Correspondence: G. Brellou,
Department of Pathology, School of Veterinary Medicine,
Aristotle University of Thessaloniki,
11 St. Voutyra str., 54627 Thessaloniki, Greece.
E-mail: mprellou@vet.auth.gr

Αλληλογραφία: Γ. Μπρέλλου,
Εργαστήριο Παθολογικής Ανατομικής, Τμήμα Κτηνιατρικής,
Σχολή Επιστημών Υγείας, Αριστοτέλειο Πανεπιστήμιο Θεσσαλονίκης,
Σταύρου Βουτυρά 11, 54627 Θεσσαλονίκη.
E-mail: mprellou@vet.auth.gr

Date of initial submission: 9 September 2013
Date of acceptance: 23 September 2013
Ημερομηνία αρχικής υποβολής: 9 Σεπτεμβρίου 2013
Ημερομηνία αποδοχής: 23 Σεπτεμβρίου 2013

ΠΕΡΙΛΗΨΗ. Στόχος της μελέτης ήταν η διερεύνηση της πιθανής προστατευτικής δράσης εκχυλίσματος του φυτού *Nigella sativa* σε αρουραίους, που εμφάνιζαν καρκίνο του ήπατος λόγω έκθεσής τους στη διεθυλονιτροζαμίνη. Αρουραίοι της φυλής *Wistar* χωρίστηκαν σε πέντε ομάδες στις οποίες χορηγήθηκαν, αντίστοιχα, N. sativa ταυτόχρονα με διεθυλονιτροζαμίνη (ομάδα Α), μόνον διεθυλονιτροζαμίνη (ομάδα Β), μόνον *N. sativa* (ομάδα C), *N. sativa* **έξι** εβδομάδες μετά από την ένεση διεθυλονιτροζαμίνη (ομάδα D) ή διεθυλονιτροζαμίνη έξι εβδομάδες μετά τη λήψη *N. sativa* (ομάδα Ε). Το πείραμα διήρκεσε οκτώ εβδομάδες για τα ζώα των ομάδων Α, Β και C και 12 εβδομάδες για αυτά των ομάδων D και Ε. Επιπλέον, εφαρμόστηκε ηπατεκτομή στο σύνολο των πειραματόζωων. Η αξιολόγηση της εξέλιξης της καρκινογένεσης στηρίχθηκε στη μελέτη της έκφρασης της ισομορφής Ρ της πρωτεΐνης γλουταθειόνη-S-τρανσφεράση (GST-P). Για την ανίχνευσή της, εφαρμόστηκαν ανοσοϊστοχημικές μέθοδοι σε ιστολογικές τομές ήπατος και διαπιστώθηκε η παρουσία του παραπάνω ενζύμου στο κυτταρόπλασμα ή/και τον πυρήνα των ηπατικών κυττάρων. Από τη μελέτη των ιστολογικών παρασκευασμάτων προέκυψε ότι ο αριθμός των εστιών στις οποίες ανιχνεύθηκε η GST-P ήταν μεγαλύτερος στα ζώα των ομάδων Α, D και Ε, ιδιαίτερα σε εκείνα των ομάδων Α και Ε, συγκριτικά με την ομάδα Β. Τα αποτελέσματα της μελέτης αυτής δείχνουν πως το εκχύλισμα *N. sativa* δρα προστατευτικά στους αρουραίους έναντι του καρκίνου του ήπατος μετά την χορήγηση διεθυλονιτροζαμίνη, ακόμα και στα πολύ πρώιμα στάδια της καρκινογένεσης στο ήπαρ.

Λέξεις ευρετηρίασης: διεθυλονιτροζαμίνη, καρκίνος ήπατος, GST-P, *Nigella sativa*

INTRODUCTION

Cancer is a major cause of death in both developed and developing countries and it is now only second to myocardial infarction in the former (Gruddy, 1991). A great majority of human cancers (about 80%-90%) is attributable to environmental factors (Benjamin et al., 1990). Many investigations have been carried out to discover naturally occurring compounds that can suppress or prevent carcinogenesis (Wargovich et al., 1988; Thapliyal et al., 2002), while several plant-base remedies have been traditionally used for treatment of cancer in many countries. These are usually cheap, widely available and easy to use preparations. One such example is a decoction prepared from *Nigella sativa* (*NS)*, *Hemidesmus indicus* roots and *Smilax glabra* rhizome. Previous studies have demonstrated that short-term (10 weeks) or long-term (Iddamaldeniya et al., 2006) treatment of rats with this decoction could protect them against DEN (a chemical that induces hepatocarcinogenesis in rats)-mediated expression of GST-P, an enzyme strongly expressed during the early stage of chemically induced hepatocacinogenesis (Iddamaldeniya et al., 2003).

In adult rats, GST-P is strongly expressed during the early stages of chemically induced hepatocacinogenesis (Iddamaldeniya et al., 2003). For rapid detection of carcinogenic agents in bioassays, GST-P positive foci can be measured as end point lesions (Sato et al., 1984; Tatematsu et al., 1985). However, it is known that only a small proportion of such foci actually progresses to liver tumors (Ogiso et al., 1990) and is clearly of interest to determine which foci are the most likely progenitors of neoplasms.

The seeds of *NS* are very rich and diverse in chemical composition. Among the chemical components of these seeds, thymoquinone (TQ) is the most abundant active principle and the most extensively investigated. The preparations from this plant have been demonstrated to have significant antineoplastic activity against various tumor cells in vitro (Salomi et al., 1991; Salomi et al., 1992). The antineoplastic activity of TQ in particular have been demonstrated against several cancers such as hepatocellular carcinoma, albeit only in vitro (Ahmed et al., 2008), human pancreatic adenocarcinoma, uterine sarcoma, Ehrlich ascites carcinoma and Dalton`s ascites lymphoma, while exerting minimal cytotoxicity to

normal lymphocytes (Worthen et al., 1998). In the present study, the anti-carcinogenic potential of *NS* seed extract was assessed on DEN-mediated GST-P expression in rat liver cancer. DEN was used as carcinogen because it is an established and specific carcinogen for hepatocarcinogenesis (Morimura et al., 1993).

MATERIALS AND METHODS

Preparation of *Nigella sativa* extract and diethylnitrosamine

Three hundred grams of dry seeds of *Nigella sativa* (*NS*) were boiled in 1.6 L of distilled water and the final volume was reduced to 200 mL by boiling. Diethylnitrosamine (DEN) was dissolved in normal saline (1 g in 25 mL). A single dose of 200 mg/kg-body weight was given to each animal to initiate hepatocarcinogenesis (Ito et al., 1988).

Experimental animals

This project was approved by the Ethics Committee of the Central Veterinary Research Laboratory (Soba, Khartoum, Sudan). Seventy five Wister rats were divided into the following five groups.

Group A rats were dosed with a single dose of 200 mg/kg DEN each intraperitoneally at day 1 and were then given NS extract orally at a dose of 6g/kg daily for 8 weeks, starting twelve hours after the administration of DEN.

Group B rats were administered with a single dose of 200 mg/kg DEN at day 1 only and were kept for 8 weeks.

Group C rats were administered with 6 g/kg/day of NS extract daily *per os* for 8 weeks.

Group D rats received a single dose of 200 mg/kg DEN at day 1. After 6 weeks they received 6g/kg of NS extract *per os* daily for another 6 weeks.

Group E rats were administered with 6 g/kg of NS extract daily for 6 weeks, and were then dosed with a single dose of 200 mg/ kg DEN. The rats were kept for another 6 weeks.

In all groups, rats were subjected to partial hepatectomy under anesthesia at day 14. The DEN-partial hepatectomy model has been proven to be a consistent bioassay for the detection of chemical hepatocarcinogenesis and for the assessment of the beneficial potential of chemopreventive agents (Ito et al., 1988; Moore et al., 1999). All animals were euthanized at the end of the experiments and subjected to full necropsy. Samples from the livers were collected and preserved in 10% neutral buffered formalin for histopathology and immunohistochemistry.

Histopathological and immunohistochemical examination

Samples from the livers were embedded in paraffin wax, cut in 5 μm thick sections and stained with hematoxynlin and eosin (HE). Serial sections from the same samples were mounted on positively charged slides and used for the immunohistochemical detection of GST-P, employing the EnVision method (Dako, Denmark). After deparafinization and rehydration, the sections were immersed in 3% H_2O_2 in phosphate buffered saline (PBS) to block endogenous peroxidase, followed by incubation with the primary antibody (GST-P rabbit anti-goat, Stressgen, USA) diluted in PBS (1:1000). Subsequently, sections were incubated with peroxidase labeled polymer (poly-HRP goat anti-mouse IgG, Dako) and 3,3 diaminobenzidine (DAB) was used as chromogen for signal detection. The slides were counterstained with Mayer`s Hematoxylin. In the negative controls the primary antibody was omitted. In preliminary experiments, several antigen retrieval methods (citrate buffer, Proteinase K, thrypsin) were evaluated and the conclusion was drawn that no antigen retrieval was required. Ten slides from each group were chosen randomly to determine the number of foci in medium magnification (x200).

Statistical analysis

The chi-square test was used to compare the number of cases with ≥3 or <3 GST-P foci in the different groups, while the One Way Analysis of Variance on Ranks was used to compare the number of number of GST-P foci in the different groups.

RESULTS

On histologic examination, hepatocyte granular and vacuolar degeneration of hepatocytes was observed that was more intense in the livers of group B and lower in sequence in groups D, A and E, while no changes were found in group C (Fig. 1). Immunolabeling of GST-P antigen was observed in single cells or foci that varied in size and staining intensity (Fig. 2, 3, 4). The number of GST-P positive foci observed per group is summarized in Table 1. The lowest number of foci was observed in group C while group B had the highest. Group D showed a high number of foci, almost similar to that in group B (55 and 56, respectively), however, the labeling intensity of hepatocytes was stronger in the latter. Both groups A and E had a similarly low number of foci (27 and 23 respectively). GST-P was localized in either the cytoplasm or the nuclei of hepatocytes.

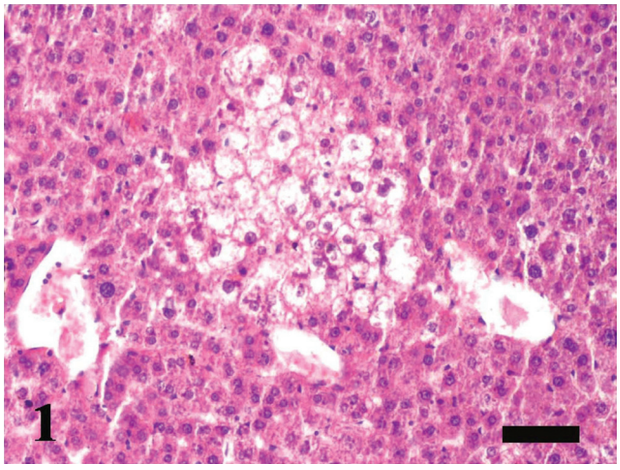

Fig. 1. Group D, liver: vacuolar degeneration is evident in numerous hepatocytes (HE, bar=50 μm).

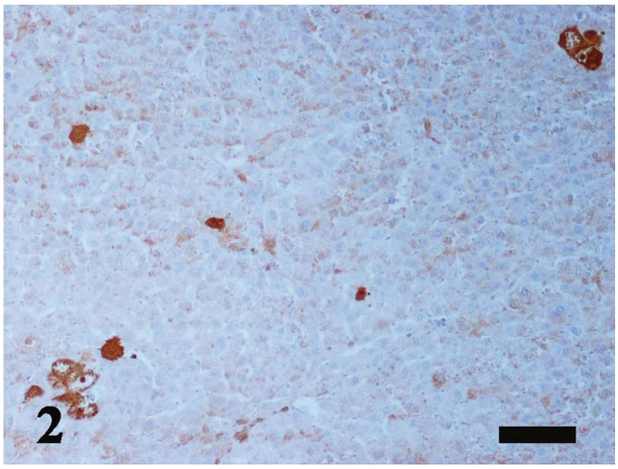

Fig. 2. Group B, liver: immunohistochemical demonstration of GST-P expression in the hepatocytes, with two small foci and scattered single cells positive for GST-P (EnVision, HRP, Mayer`s hematoxylin counterstain, bar=100μm).

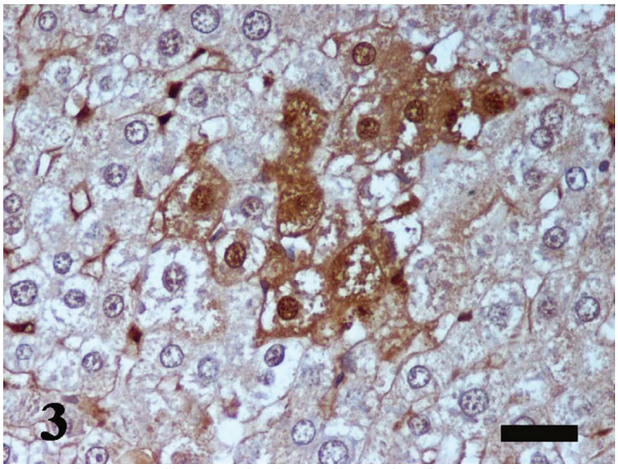

Fig. 3. Group D, liver: a single medium size focus with moderate nuclear and cytoplasmic immunolabeling for GST-P (EnVision, HRP, Mayer`s hematoxylin counterstain, bar=25μm).

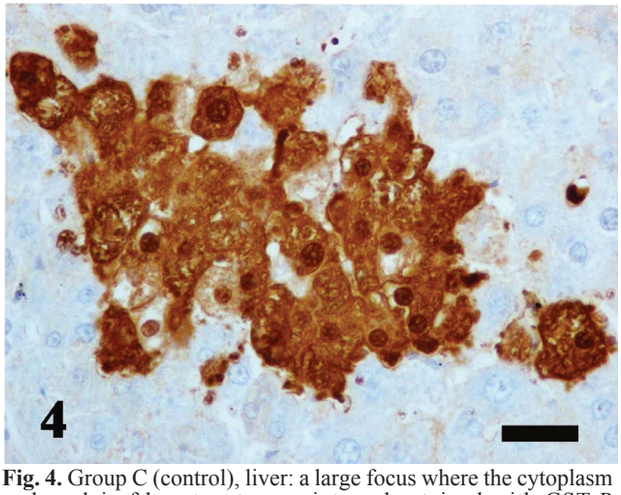

Fig. 4. Group C (control), liver: a large focus where the cytoplasm and nuclei of hepatocytes are intensely stained with GST-P (EnVision, HRP, Mayer`s hematoxylin counterstain, bar=25μm).

Table 1. Number of immunohistochemically positive GST-P foci in the experimental groups studied.

Slide no.	Positive foci (n)				
	Group A	Group B	Group C	Group D	Group E
1	3	8	1	5	2
2	2	3	0	4	2
3	5	11	1	3	5
4	3	2	0	2	3
5	5	3	3	9	3
6	4	4	0	4	3
7	3	8	0	10	2
8	2	3	0	12	3
9	3	7	0	3	5
10	2	7	0	3	0
Total	32	56	5	55	28
x±se	3.2±0.34	5.6±0.90	0.5±0.29	5.5±1.05	2.8±0.44

Results obtained by counting total number of foci in 10 randomly chosen slides from each animal group.

Significant differences in the number of GST-P positive foci were observed between groups A, B, D and E when compared to the control group C. Groups A and E had a lower number of GST-P positive foci compared to groups D and B. The results of the statistical analysis of the differences in the number of GST-P positive foci in the different experimental groups are shown in Tables 2 and 3.

DISCUSSION

Much attention has been focused on the morphological, histological and biochemical properties of preneoplastic lesions such as enzyme-altered foci and hyperplastic nodules induced at the early stages of chemical hepatocarcinogenesis (Pitot et al., 1978; Farber and Cameron, 1980). One of the enzymes altered in early hepatocarcinogenesis is GST-P. The rat GST-P, which is related to human GST-***π*** in enzymatic and immunological properties, is a detoxifying enzyme in the liver and has many isoforms. GST-P is present in small quantities and is weakly expressed in rat tissues such as the lung, kidney, testis, spleen and placenta, but is present only in trace, non-detectable amounts in normal livers (Sugioka et al., 1985; Sato, 1988), although it is markedly and specifically increased during the early stages of hepatocarcinogenesis. It can be detected in single liver cells as early as 2–3 days after the administration of a chemical (Farber, 1984; Sato 1989). The induction of GST-P occurs primarily at the transcriptional level (Suguoka et al., 1985). Therefore, this enzyme has been used as a reliable tumor marker for both chemically induced and spontaneously arising precancerous lesions and hepatomas in experimental carcinogenesis studies.

In the present investigation, the method of the medium-term bioassay proposed by Ito et al based on the two-step model of hepatocarcinogenesis was used (Ito et al., 1988), modified appropriately. This system was initially introduced in order to screen environmental and naturally occurring carcinogens and was later used successfully for identifying different anticarcinogens (Ito et al., 1989; Ogiso et al., 1990).

The high number of GST-P positive foci observed in groups B and D was, to a degree, expected. In the former group, the carcinogenic agent was

Table 2. Pairwise comparisons of the experimental groups studied for the number of samples with ≥3 or <3 GST-P positive foci per group detected immunohistochemically (chi-square test).

Comparisons	*P*
B *versus* D	1.000
A *versus* C	0.006
B *versus* C	<0.001
D *versus* C	<0.001
E *versus* C	0.019
B *versus* A	0.264
D *versus* A	0.264
A *versus* E	0.639
B *versus* E	0.121
D *versus* E	0.121

Table 3. Pairwise comparisons of the experimental groups studied for the number of GST-P positive foci detected immunohistochemically per case (one-way analysis of variance on ranks).

Group 1 (higher)	Group 2 (lower)	*P*
A	C	0.003
B	C	0.016
D	C	<0.001
E	C	0.062
B	A	0.022
D	A	<0.001
A	E	0.011
B	E	0.01
B	D	0.054
D	E	0.01
A+B+D+E	C	0.003
A+B+D	C	0.003
A+B+D	E	0.004
A+B+D	C+E	<0.001
B	A+D+E	0.022

given alone and its action was not controlled by the NS extract. In the latter group (D) NS appears to have no inhibitory effect on DEN-mediated GST-P expression. This is probably because NS was administered late (6 weeks after DEN), allowing the early stages of hepatocarcinogenesis to pass and foci to develop.

More importantly, our results revealed that NS has a significant inhibitory effect on DEN-mediated GST-P expression when administered a few hours after DEN or when DEN was given following six weeks' treatment with NS. This indicates that NS suppresses the early stages of DEN carcinogenesis and that the residual effect of NS, when given for a long period, may protect against DEN for some time after the cessation of NS treatment.

Two studies in rats have demonstrated a significant inhibitory effect against DEN by an indigenous medicine comprising *NS*, *Hemidesmus indicus* and *Smilax glabra* (Iddamaldeniya et al., 2003; Iddamaldeniya et al., 2006). Previous experiments have also shown the anti-tumor effects of *N. sativa* and Crocus sativus on chemical carcinogenesis in mice (Salomi et al., 1991). In addition, NS was found to be cytotoxic to several cancer cell lines (Salomi

et al., 1992) and its active ingredients thymoquinone and dithymoquinone were found to be cytotoxic to several multi-drug resistant human cell lines (Worthen et al., 1998). The findings of these studies are in agreement with the results of our study and support further investigations into the potential use of this plant in the treatment of cancer.

Besides, the low degree of GST-P expression observed after treatment only with NS (control group C) raises the issue that certain components of this plant may trigger subcellular events related to the above enzyme. The absence of such findings in previous reports may be attributed to the enrichment of treatment with other potent anticarcinogenic substances contained in plant extracts (Iddamaldeniya et al., 2003; Iddamaldeniya et al., 2006). The above hypothesis should be examined following further investigations on the properties of the individual NS components separately. Another explanation may be the action of a latent stimulus or the administration of NS itself (resulting in liver abnormalities) as has been reported previously (Suguoka et al., 1985; Sato 1989) indicating that GST-P can be expressed in normal or non-precancerous livers.

Regarding the localization of the GST-P enzyme, Guo et al (Guo et al., 2000) found that it is located in the cytoplasm, mitochondria, lysosomes and nucleus adjacent to the nuclear membrane of colorectal cancer cells. Intracytoplasmic and intranuclear presence of GST-P has also been detected in bladder carcinoma (Chen et al., 1998), although the latter has not been shown previously in liver cancer. Positive nuclear immunolabelling of another GST isotype, GST-O, has been shown in normal human liver (Yin et al., 2001). The above observations are consistent with our findings regarding the nuclear and cytoplasmic localization of GST-P detected in the present study, leading us to conclude that this enzyme, may also be expressed in both the cytoplasm and nucleus of neoplastic hepatocytes, in addition to the cancer cell types reported to date (colorectal cancer cell, bladder carcinoma). Further studies will be needed to investigate the cellular localization of GST-P in different cancer cell types.

The absence of histological findings compatible with tumor development was expected since our study was confined to the early stages of tumorigenesis (Iddamaldeniya et al., 2003). The mild to moderate hepatocytic vacuolation and neovascularization observed mostly in groups B and D is in concordance with previous reports, albeit concerning the investigation of long term carcinogenesis (Iddamaldeniya et al., 2006). The fact that these investigators observed the above lesions much later at the course of the experiments (at the end of 16 months), while in our study they were seen at 2 and 3 months is probably due to the different therapeutic agents used in each study.

CONCLUDING REMARKS

This study suggests that the administration of NS alone, ie not in combination with other agents, may have antineoplastic properties, that are both preventive and therapeutic, and warrants further investigations on the effects of the individual components of NS on carcinogenesis. It also showed that GST-P is expressed in both the cytoplasm and the nuclei of hepatocytes during hepatocarcinogenesis, the latter not shown previously.

CONFLICT OF INTEREST STATEMENT

The author(s) declared no potential conflicts of interest with respect to the research, authorship, and/or publication of this article.

ACKNOWLEDGEMENTS

We thank Professor E.Kaldrymidou for constructive comments on the project and the technical staff of the Department of Pathology, Faculty of Veterinary Medicine, University of Khartoum for their unlimited help in the preparation of sections.

REFERENCES

Ahmed WA, Hassan SA, Galeb FM, El-Taweel MA, Abu-Bedair FA (2008) The in vitro promising therapeutic activity of thymoquinone on hepatocellular carcinoma (HepG2) cell line. Global Vet 2:233-241.

Benjamin HSL, Padma PT, Jeffrey MT (1990) Allium sativum (garlic) and cancer prevention. Int J Vitam Nutr Res 10:937-948.

Chen M, Sui YG, You GC, Xu ZS, Feng SZ (1998) Localization of glutathione S-transferase π in human bladder neoplasmas. Zhonghua Miniao Waike Zazhi (Chin J Urol) 19:391.

Farber E (1984) The biochemistry of preneoplastic liver: a common metabolic pattern in hepatocyte nodules. Can J Biochem Cell Biol 62:486-494.

Farber E, Cameron R (1980) The sequential analysis of cancer development. Adv Cancer Res 31:125-226.

Gruddy SM (1991) Recent Nutrition Research, implications for foods of the future. Ann Med 23:187-193.

Guo WJ, Zhou GD, Wu HJ, Liu YQ, Wu RG, Zhang WD (2000) Ultrastructural localization of glutathione S-transferase-pi in human colorectal cancer cells. World J Gastroenterol 6(3):454-455.

Iddamaldeniya SS, Thabrew MI, Wickramasinghe SMDN, Ratnatunge N, Thammitiyagodage MG (2006) A long-term investigation of the anti-hepatocarcinogenic potential of an indigenous medicine comprised of Nigella sativa, Hemidesmus indicus and Smilax glabra. J Carcinog 5:11-17.

Iddamaldeniya SS, Wickramasinghe N, Thabrew I, Ratnatunge N, Thammitiyagodage M (2003) Protection against diethylnitrosoamine-induced hepatocarcinogenesis by an indigenous medicine comprised of Nigella sativa, Hemidesmus indicus and Smilax glabra: a preliminary study. J Carcinog 2:6-11.

Ito N, Imaida K, Hasagawa R, Tsuda H (1989) Rapid bioassay methods for carcinogens and modifiers of hepatocarcinogenesis. CRC Crit Rev Toxicol 19: 285-415.

Ito N, Tsuda H, Tatematsu M, Inoue T, Tagawa Y, Aoki T, Uwagawa S, Kagawa M, Ogiso T, Masui T, Imaida K, Fukushima S, Asamoto M (1988) Enhancing effect of various hepatocarcinogens on induction of preneoplastic glutathione S-transferase placental form positive foci in rats-an approach for a new mediumterm bioassay system. Carcinogenesis 9:387-394.

Moore M A, Tsuda H, Tamano S, Hagiwara A, Imaida K, Shirai T, Ito N (1999) Marriage of a medium-term liver model to surrogate markers - a practical approach for risks and benefit assessment. Toxicol Pathol 27: 237-242.

Morimura S, Susuki T, Hochi S, Yuki A, Nomura K, Kitagawa T, Muramatsu M (1993) Trans activation of glutathione transferase P gene during hepatocarcinogenesis of rat. Proc Natl Acad Sci USA 90:2065-2068.

Ogiso T, Tatematsu M, Tamano S, Hasegawa R, Ito N (1990) Correlation between medium-term liver bioassay system data and results of long-term testing in rats. Carcinogenesis 11:561–566.

Pitot H C, Barsness L, Goldsworthy T (1978) Nature (London) 261:456-457.

Salomi NJ, Nair SC, Jayawardhanan KK, Varghese CD, Panikkar KR (1992) Antitumour principles from Nigella sativa seeds. Cancer Lett. 63(1):41–46.

Salomi NJ, Satish C, Nair SC, Panikkar KR (1991) Inhibitory effects of Nigella sativa and Saffron (Crocus sativus) on chemical carcinogenesis in mice. Nutr Cancer 16:67–72.

Sato K (1988) Glutathione S-transferases and hepatocarcinogenesis. Jpn J Cancer Res 79:556-572.

Sato K (1989) Glutathione transferases as markers of preneoplasia and neoplasia. Adv Cancer Res 52:205-255.

Sato K, Kitahara A, Satoh K, Ichikawa T, Tatematsu M, Ito N (1984) The placental form of glutathione S-transferase as a new marker protein for preneoplasia in rat chemical carcinogenesis. Gann 75:199–202.

Sugioka Y, Fujii-Kuriyama Y, Kitagawa T, Muramatsu M (1985) Changes in polypeptide pattern of rat liver cells during chemical hepatocarcinogenesis. Cancer Res 45:365-378.

Suguoka Y, Kano T, Okuda A, Sakai, M, Kitagawa T, Muramatsu M (1985) Cloning and the nucleotide sequence of the rat glutathione S-transferease P cDNA. Nucleic Acids Res 13: 6049–6057.

Tatematsu M, Mera Y, Ito N, Satoh K, Sato K (1985) Relative merits of immunohistochemical demonstration of placental A, B and C forms of glutathione S-transferase and histochemical demonstration of γ-glutamyl transferase as marker of altered foci during liver carcinogenesis in rats. Carcinogenesis 6:1621–1626.

Thapliyal R, Deshpande SS, Maru GB (2002) Mechanism(s) of turmeric- mediated protective effects against benzopyrenederived adducts. Cancer Lett 175:79-88.

Wargovich MJ, Woods C, Eng VWS (1988) Chemoprevention of NNitrosomethyl benzyllamine-induced oesophageal cancer in rats by the naturally Cancer thiother, diallyl sulphide. Cancer Res 48:6872-6875.

Worthen DR, Ghosheh OA, Crooks PA (1998) The in vitro anti tumor activity of some crude and purified components of blackseed, Nigella sativa L. Anticancer Res 18:1527–1532.

Yin ZL, Dahlstrom JE, Le Couteur DG, Board PG (2001) Immunohistochemistry of omega class glutathione S-transferase in human tissues. J Histochem Cytochem 49(8): 983-987.