

Journal of the Hellenic Veterinary Medical Society

Vol 65, No 2 (2014)



Decreased production in broiler breeders due to tendon rupture by *Mycoplasma synoviae*

F. A. MOREIRA, L. CARDOSO, A. C. COELHO

doi: [10.12681/jhvms.15526](https://doi.org/10.12681/jhvms.15526)

To cite this article:

MOREIRA, F. A., CARDOSO, L., & COELHO, A. C. (2017). Decreased production in broiler breeders due to tendon rupture by *Mycoplasma synoviae*. *Journal of the Hellenic Veterinary Medical Society*, 65(2), 109–114. <https://doi.org/10.12681/jhvms.15526>

**Decreased production in broiler breeders due to tendon rupture
by *Mycoplasma synoviae***

Moreira F.A., Cardoso L., Coelho A.C.

*Department of Veterinary Sciences, School of Agrarian and Veterinary Sciences,
University of Trás-os-Montes e Alto Douro (UTAD), Veterinary and Animal Science Center (CECAV),
Vila Real, Portugal.*

ABSTRACT. An outbreak of lameness occurred in a broiler breeder flock (30,000 birds into four houses) of a multi-age farm, with a total of two broiler breeder flocks (60,000 birds in total). The leg lesions began soon after facilities transfer between 22 and 24 weeks of age and persisted for the rest of the flock's life, until 64 weeks of age. Post-mortem examination at the farm revealed arthritis lesions and synovitis affecting the hock joint and the foot pads. *Mycoplasma synoviae* was detected in birds from the affected flock by serologic and molecular techniques. Treatments with fluoroquinolones in drinking water reduced the number of cases, but morbidity continued and affected the standard production rates.

Keywords: broiler breeders, decreased production, *Mycoplasma synoviae*, tendon rupture

Correspondence: Moreira F.A.,
Department of Veterinary Sciences,
University of Trás-os-Montes e Alto Douro (UTAD),
Veterinary and Animal Science Center (CECAV),
Vila Real, Portugal.
E-mail: fernando.moreira@lusiaves.pt

Date of initial submission: 19 September 2013
Date of revised submission: 15 November 2013
Date of acceptance: 18 November 2013

Ημερομηνία αρχικής υποβολής: 19 Σεπτεμβρίου 2013
Ημερομηνία αναθεωρημένης υποβολής: 15 Νοεμβρίου 2013
Ημερομηνία αποδοχής: 18 Νοεμβρίου 2013

INTRODUCTION

In chickens, *Mycoplasma synoviae* infections most frequently occur as subclinical or inapparent infections of the upper respiratory tract (Vogl et al., 2008). Nevertheless, this agent can also cause infectious synovitis (Cobb, 2011). In both cases, infection with *M. synoviae* might result in significant losses due to decreased egg production, growth and hatchability rates, and downgrading of carcasses at slaughter due to airsacculitis and arthritis lesions (Fiorentin et al., 2003; Kleven, 2003; Noormohammadi, 2007; Peebles et al., 2011). In recent years, the occurrence of arthropathic and amyloidogenic strains of *M. synoviae*, as well as of strains that induce egg-shell apex abnormalities and egg production losses, has increased economic impact of this pathogen (Feberwee et al., 2008; Landman and Feberwee, 2008; Catania et al., 2010).

CASE DESCRIPTION

In late February 2013, an outbreak of lameness occurred in one of the two 30,000 bird broiler breeder flocks (30,000 birds divided into four houses per flock) of a multi-age farm with a morbidity of 5 to 10%. The leg lesions began soon after transfer from the rearing to the production houses, between 22 and 24 weeks of age, and persisted for the rest of the flock's life (until 64 weeks of age) with peaks of morbidity and mortality. A standard breeder vaccination program comprised live vaccines [Marek (HVT and Rispens) plus infectious bronchitis virus (Mass and 4/91) (hatchery), *Salmonella enteritidis* (day 0, weeks 6 and 16), coccidiosis (day 0), Newcastle disease (day 7, week 7), Gumboro disease (weeks 3 and 8), avian encephalomyelitis plus poxvirus plus infectious laryngotracheitis (week 10), avian pneumovirus (week 12)] and inactivated vaccines [infectious bronchitis virus plus Gumboro disease plus Newcastle

disease plus avian pneumovirus plus reovirus (week 18)], but excluded vaccines against *M. gallisepticum* or *M. synoviae*.

In the rearing period (between 10 and 18 weeks of age), serologic tests to *M. gallisepticum* and *M. synoviae* were negative. The second breeder flock in the farm was serologically negative for *M. gallisepticum* and *M. synoviae* at 30, 40, 50 and 59 weeks of age.

Post-mortem examination

Routine postmortem examination of 30 birds revealed a range of visible joint lesions, typically unilateral in distribution (Fig. 1). Arthritis lesions affected the hock joint in 40% of the examined birds and the foot pads in 30%. Of the affected birds, 5% exhibited femoral osteomyelitis. The lesions were evident by palpation of the hock and could be observed after the feathers were removed. The affected joints were warm and in some birds a greenish discoloration of the skin could be seen. Incised swollen hocks showed a viscous exudate involving the synovial membranes of the gastrocnemius, digital flexor and metatarsal extensor tendons, and progressing to caseous exudates. Half of the birds with swollen hock joint presented rupture of the gastrocnemius tendon (Fig. 2). The remainder of the examined birds (25%) didn't have any joint or tendon lesions.

After post-mortem examination, samples of gastrocnemius, digital flexor and metatarsal tendons, trachea and oviduct were collected for bacteriological culture and polymerase chain reaction (PCR) testing. Blood samples (2 mL per bird) for serological examination were randomly collected from 40 birds.

The other breeder flock in the same farm was 10 weeks older than the affected flock and didn't show any clinical or production signs at the time of the outbreak. Blood samples from another 40 birds were also collected for comparison.

Serological examination

Blood serum samples were tested for antibodies to *M. synoviae* (BioChek® Mycoplasma synoviae Antibody Test Kit, U.S.A.), infectious bronchitis virus (BioChek® Infectious Bronchitis Antibody Test Kit, U.S.A.) and reovirus (BioChek® Avian Reovirus Antibody Test Kit, U.S.A.), as well as to *M. gallisepticum* by a rapid serum agglutination test (X-Ovo© *M. gallisepticum*, stained S6 of Adler, U.S.A.).

Bacteriological examination

Samples were inoculated on PPLO (pleuro-pneumonia like organisms) agar plates and incubated for 7 days at 37 °C as described by Ferguson-Noel et al. (2011).

Polymerase chain reaction

Samples of tracheae, oviduct and leg tendons were collected from six affected birds, which died, and were prepared for polymerase chain reaction to test for *M. synoviae*, *M. gallisepticum* and reovirus.

Samples for *M. synoviae* PCR were prepared as described by Ramirez et al. (2006). Briefly, 900 mL of initial cell suspensions were centrifuged (12,000 g, 4 °C, 20 min) and the pellets were washed once in 500 µL of phosphate buffer saline (PBS) and re-suspended in 20 µL of PBS. Samples were heated at 95 °C for 2 min. The DNA of *M. synoviae* was quantified with a fluorometer (DyNA Quant™ 200, Hoefer, Pharmacia Biotech) following the manufacturer's instructions. Forward primer (Ms2FF 5'-TAA AAG CGG TTG TGT ATC GC-3') was used with a reverse primer (23SR 5'-CGC AGG TTT GCA CGT CCT TCA TCG-3') targeting the 5' end of the 23S rRNA gene. Reaction mixtures contained 2.5 U of *Taq* DNA polymerase (AB Gene), 0.2 µM of Ms2FF primer, 1× reaction buffer, 1.75 mM MgCl₂, 0.2 mM dNTPs, and water to a final volume of 50 µL. One microliter of the template was added. Amplification was achieved with a first step at 80 °C for 30 s, five denaturation cycles at 94 °C for 15 s, renaturation at 55 °C for 30 s, and elongation at 72 °C for 1 min, followed by 30 cycles as previously described, but with

an extension of 2 s per cycle in the elongation step. A 5 µL amount of each amplified product was separated by electrophoresis on a 1.5% agarose gel. Gels were stained with ethidium bromide (3 µg ml⁻¹) and observed with ultraviolet light.

For *M. gallisepticum* PCR, samples were prepared as described by Carli and Eyigor (2002). Briefly, a real-time PCR by LightCycler system (LC) was used. For each PCR run 2 mL from MG S6a strain and sterile PCR-grade deionized water were added to 18 µL of PCR mixture as an unknown (positive or negative control). The reaction mixture optimized for LC PCR contained 2 µL of 10× concentration LC DNA Master SYBR Green I ready to use reaction mix for PCR (*Taq* DNA polymerase, reaction buffer, deoxynucleoside triphosphate mix, SYBR Green I dye and 10 mmol⁻¹ MgCl₂), 2.4 µL of 25 mmol l⁻¹ MgCl₂, 1 µL of each 100 µmol L⁻¹ primers (MG1: GATTTCGAAG AATCAACTGT and MG2: TTCCCTAATT ATAAGGGTTG), 2 µL of template and 11.6 µL of deionized water. The amplification protocol included an initial denaturation step at 95 °C for 60 s and 80 cycles of denaturation at 95 °C for 0 s, annealing at 55 °C for 5 s, and 10 s of primer extension at 72 °C. Temperature transition rate was 20 °C s⁻¹. Fluorescence was measured automatically at the end of each extension step.

Samples were prepared for reovirus reverse transcriptase RT-PCR reaction and agarose gel electrophoresis as described by Bruhn et al. (2005). Briefly, the RT-PCR reactions were performed with the One Step RT-PCR Kit (Qiagen, Switzerland) using a standard 50 µL reaction mixture contained 10 µL 5× OneStep RT-PCR buffer, 2 µL dNTP mix (containing 10 mM of each deoxynucleoside triphosphate), 0.8 µM (2 µL) of each primer (ARV_S2_P4 (CCC ATG GCA ACG ATT TC), ARV_S2_P5 (TTC GGC CAC GTC TCA AC), ARV_S4_P4 (GTC CGT GTT GGA GTT TC) and ARV_S4_P5 (ACA AAG CCA GCC AT(G/A) AT)) (20 µmol L⁻¹), 2 µL of One Step RT-PCR Enzyme mix, 0.25 µL RNase inhibitor (40 U µL⁻¹, Promega); 2 µL of the extracted RNA or RNA/DMSO mix

were used in the RT-PCR reaction. In the reagent control, templates were replaced by RNase free-water. Target DNA was amplified in a 0.5 mL thin walled tube using a thermocycler equipped with a heat lid (Hybaid Omne, MWG-Biotech) or with the Mastercycler® gradient (Eppendorf Inc.). The temperature profile consist of an initial 50 °C for 30 min for reverse transcription, RT-PCR activation step of 95 °C for 15 min followed by 35 cycles for 30 s at 94 °C for denaturation, 30 s at 54 °C for annealing, 1 min at 72 °C for elongation and a final extension step of 10 min at 72 °C. A 100 bp double-stranded DNA ladder (Invitrogen Life Technologies, USA) served as molecular DNA size marker. 10 µL of RT-PCR products were analyzed by electrophoresis on 2% agarose gel (Sigma Chemicals, Switzerland) containing 0.3 µg mL⁻¹ ethidium bromide. The gels were run at 120 V for 1.2 h using 1× TBE buffer (44.6 mM Tris, 44.5 mM Boric acid, 1 mM EDTA) and examined with ultraviolet light.

RESULTS

The lesions in the tendons were suggestive of a *M. synoviae* infection and confirmation was made based on serological and PCR findings. In this study, diagnosis of *Mycoplasma* infection has not been made by bacteriological examination, since colonies of fried egg appearance on solid media were not observed. *M. synoviae* was detected in tendon and trachea samples by PCR, but not in oviduct samples. PCR for reovirus was negative in all samples. Results are summarized in Table 1.

As a result of these findings, treatment with performed with administration of 10% enrofloxacin oral solution in the drinking water. Dosage scheme was 15 mg kg⁻¹ bw per day, for 5 days and was repeated at the age of 40 and 50 weeks. After each medication, number of new cases reduced; however, increased morbidity rate persisted throughout the lifespan of the flock (64 weeks).

Final production outcomes, measured at the

Table 1. Results of laboratory tests performed in samples from broiler breeders with or without tendon rupture.

Tissue sampled	Test (agent)	Flock 1 (tendon rupture)	Flock 2 (clinically healthy)
Blood	ELISA (MS)	40/40 (MT: 6104, %CV 25)	0/40 (MT: 122, %CV 49)
Blood	RSA (MG)	0/40	0/40
Blood	ELISA (IBV)	40/40 (MT: 6071, %CV 49)	40/40 (MT: 9876 %CV 22)
Blood	ELISA (Reo) + (40/40)	40/40 (MT: 7195, %CV 33)	40/40 (MT: 8385, %CV 20)
Trachea	PCR (MS)	6/6	ND
Trachea	PCR (MG)	0/6	ND
Tendon	PCR (MS)	6/6	ND
Tendon	PCR (Reo)	0/6	ND
Oviduct	PCR (MS)	0/6	ND

MS: *M. synoviae*, MG: *M. gallisepticum*, IBV: infectious bronchitis virus, Reo: reovirus.
MT: mean titre, ND: not done.

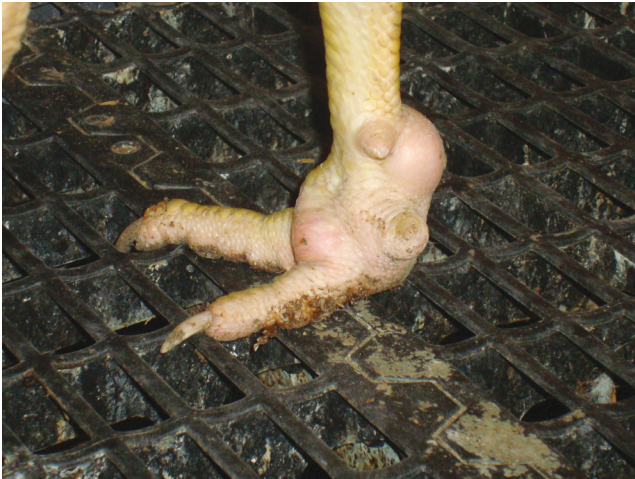

Fig. 1. Pathological findings in the foot pad of broiler breeders; visible joint lesion typically unilateral in distribution, with swelling and warm.

age of 60 weeks, were below the standards of that bird strain. Total egg production was 9% below that, hatchability 4% below that and total chick production was 15% below that. Total mortality rate in the flock was 15%.

DISCUSSION

Mycoplasmas are important avian pathogens, which can cause large economic losses worldwide (Kleven, 2008; Stipkovits et al., 2011). Tendon rupture in this flock could be directly correlated with *M. synoviae* infection, as shown by a) positive serological and tendon PCR findings for *M. synoviae* and b) negative PCR results for reovirus infection. Serological examination for infectious bronchitis and reovirus infection were positive in both flocks, compatible with the vaccination programs performed.

Broiler breeders, generally, have different sites for rearing and production. In this specific case, birds were transferred to the production site at 20 weeks of age. The transfer itself is presumed to be unrelated to the problem, but stress factors present in this phase can affect the immune system. In fact, stress factors in the production site, including aggression by male birds, intensive egg production and nutritional imbalance, can depress the immune system of hens, thus predisposing birds to be vulnerable to pathogens,

such as *M. synoviae* (Stanley et al., 2001).

It is not clear why the second flock appeared to be free of any disorder, with serological tests negative for *M. synoviae* until end of its production cycle, even if it was in near contact with the positive flock. Probably, this could be related to adequate levels of adaptation and good immune competence of the second flock.

Production results from the affected flock, in relation to the standards of the bird strain and the other flock at the same farm, were poor. Hatchability revealed values below the standards since the beginning. An effect on egg production and egg quality has been described with natural occurring *M. synoviae* infection of adult birds. There is also an abnormal mortality related to *M. synoviae*, which has been implicated as a contributing factor in the development of *E. coli* infections (Kleven, 2003).

The applied treatments reduced secondary infections and morbidity, but they were not effective throughout the life of the flock. Failure to eradicate *M. synoviae* in commercial poultry flocks is partly due to ability of this organism to establish lifelong infections in their hosts and also due to the physical design of the modern poultry premises, like construction of multi-age farms (farms with birds of different

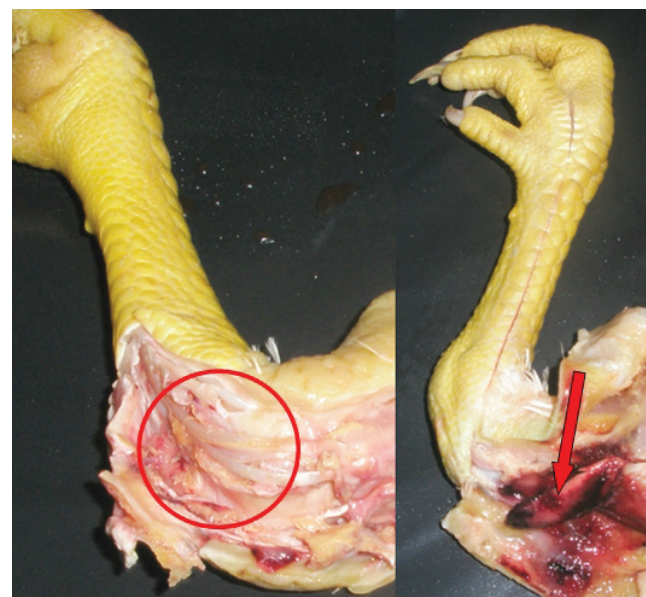


Fig. 2. Incised swollen hocks joints with caseous exudates and others showing rupture of the gastrocnemius tendon.

ages) (Marois et al., 2005). It is necessary to determine new and more effective strategies to reduce losses due to *Mycoplasma* infections (Kleven, 2003).

CONCLUDING REMARKS

Infection with *M. synoviae* found in broiler breeder flocks in Portuguese poultry farms dictates that investigation should be put into practice to determine prevalence and strategies to reduce economic impact of this pathogen.

ACKNOWLEDGEMENTS

The authors are grateful to Grupo Lusiaves and Controlvet for their support. This study was partially sponsored by the strategic research project Pest-OR/AGR/UI0772/2011 financed by the Foundation for Science and Technology (FCT, Portugal).

CONFLICT OF INTEREST STATEMENT

The authors declare that they have no conflict of interests.

REFERENCES

- Aoki ST, Settembre EC, Trask SD, Greenberg HB, Harrison SC, Dormitzer PR (2009) Structure of rotavirus outer-layer protein VP7 bound with a neutralizing Fab. *Science* 324:1444-1447.
- Bruhn S, Bruckner L, Ottiger HP (2005) Application of RT-PCR for detection of avian reovirus contamination in avian viral vaccines. *J Virol Meth* 123: 179-186.
- Carli KT, Eyigor A (2002) Real-Time polymerase chain reaction for detection of *Mycoplasma gallisepticum* in chicken trachea. *Avian Dis* 47:712-717.
- Catania S, Dania Bilato AC, Gobbo AF, Granato AA, Terregino AC, Iob AL (2010) Treatment of eggshell abnormalities and reduced egg production caused by *Mycoplasma synoviae* infection. *Avian Dis* 54:961-964.
- Cobb SP (2011) The spread of pathogens through trade in poultry hatching eggs: overview and recent developments. *Rev Sci Tech* 30:165-175.
- Feberwee A, Vries TS, Landman WJ (2008) Seroprevalence of *Mycoplasma synoviae* in Dutch commercial poultry farms. *Avian Pathol* 37:629-633.
- Ferguson-Noel N, Victoria AL, Farrar M (2011) Influence of swab material on the detection of *Mycoplasma gallisepticum* and *Mycoplasma synoviae* by real-time PCR. *Avian Dis* 56:310-314.
- Fiorentin L, Soncini RA, Costa JL, Mores MA, Trevisol IM, Toda M (2003) Apparent eradication of *Mycoplasma synoviae* in broiler breeders subjected to intensive antibiotic treatment directed to control *Escherichia coli*. *Avian Pathol* 32:213-216.
- Hammond PP, Ramírez AS, Morrow CJ, Bradbury JM (2009) Development and evaluation of an improved diagnostic PCR for *Mycoplasma synoviae* using primers located in the haemagglutinin encoding gene *vhA* and its value for strain typing. *Vet Microbiol* 136:61-68.
- Kleven SH (2003) *Mycoplasma synoviae* infection. In: (eds: Saif YA, Barnes HJ, Fadly AM, Glisson JR, McDougald LR, Swayne DE) *Diseases of Poultry*, 11th edn., Iowa State Press, USA, pp. 756-766.
- Kleven SH (2008) Control of avian mycoplasma infections in commercial poultry. *Avian Dis* 52:367-374.
- Landman WJ, Feberwee A (2008) Field studies on the association between amyloid arthropathy and *Mycoplasma synoviae* infection, and experimental reproduction of the condition in brown layers. *Avian Pathol* 30:629-639.
- Marois C, Picault JP, Kobisch M, Kempf I (2005) Experimental evidence of indirect transmission of *Mycoplasma synoviae*. *Vet Res* 36:759-769.
- Noormohammadi AH (2007) Role of phenotypic diversity in pathogenesis of avian mycoplasmosis. *Avian Pathol* 36:439-444.
- Peebles ED, Park SW, Branton SL, Gerard PD, Womack SK (2011) Dietary poultry fat, phytase, and 25-hydroxycholecalciferol influence in the digestive and reproductive organ characteristics of commercial layers inoculated before or at the onset of lay with F-strain *Mycoplasma gallisepticum*. *Poult Sci* 90: 797-803.
- Ramírez AS, Clive JN, Hammond PP, Bradbury JM (2006) Development and evaluation of a diagnostic PCR for *Mycoplasma synoviae* using primers located in the intergenic spacer region and the 23 rRNA gene. *Vet Microbiol* 118:76-82.
- Stanley WA, Hofacre C, Speksnijder AD, Kleven SH, Aggrey SE (2001) Monitoring *Mycoplasma gallisepticum* and *Mycoplasma synoviae* infection in breeder chickens after treatment with enrofloxacin. *Avian Dis* 45:534-539.
- Stipkovits L, Glavits R, Palfi V, Beres A, Egyed L, Denes B (2011) Pathologic lesions caused by coinfection of *Mycoplasma gallisepticum* an H3N8 low pathogenic Avian Influenza Virus in chickens. *Vet Pathol*. 0:1-11.
- Vogl G, Plaickner A, Szathmary S, Stipkovit L, Rosengarten R, Szostak MP (2008) *Mycoplasma gallisepticum* invades chicken erythrocytes during infection. *Infect Immun* 76:71-77.