

## Journal of the Hellenic Veterinary Medical Society

Vol 68, No 3 (2017)



### Morphometric evaluation of relevant radiographic parameters of the forefeet of clinically normal donkeys (*Equus asinus*)

E. A. EL-SHAFAEY, M. G. SALEM, E. MOSBAH, A. E. ZAGHLOUL

doi: [10.12681/jhvms.15543](https://doi.org/10.12681/jhvms.15543)

Copyright © 2018, EA EL-SHAFAEY, MG SALEM, E MOSBAH, AE ZAGHLOUL



This work is licensed under a [Creative Commons Attribution-NonCommercial 4.0](https://creativecommons.org/licenses/by-nc/4.0/).

#### To cite this article:

EL-SHAFAEY, E. A., SALEM, M. G., MOSBAH, E., & ZAGHLOUL, A. E. (2018). Morphometric evaluation of relevant radiographic parameters of the forefeet of clinically normal donkeys (*Equus asinus*). *Journal of the Hellenic Veterinary Medical Society*, 68(3), 467–478. <https://doi.org/10.12681/jhvms.15543>

## Morphometric evaluation of relevant radiographic parameters of the forefeet of clinically normal donkeys (*Equus asinus*)

El-Shafaey, E. A. <sup>1,2,\*</sup>, Salem, M. G. <sup>1</sup>, Mosbah, E. <sup>1</sup>, Zaghloul, A. E. <sup>1</sup>

<sup>1</sup> Department of Surgery, Anesthesiology and Radiology, Faculty of Veterinary Medicine,  
Mansoura University, Mansoura 35516, Egypt

<sup>2</sup> Department of Veterinary Medicine, College of Agriculture and Veterinary Medicine,  
Qassim University, Buraydah 51452, PO Box 6622, Qassim, Saudi Arabia

**ABSTRACT.** This study provides a standard database of morphometric evaluation of the digital bone and hoof parameters of the forefeet of clinically normal donkeys using Digital Imaging and Communications in Medicine (DICOM) software programme, as a means to improve diagnosis and clinical decision-making regarding foot lameness in equine practice. Thirty orthopedically sound donkeys were included in this study. For each donkey forefoot, lateromedial (LM) and dorsopalmar (DP) radiographs were obtained with the foot in a vertical position. A total of 26 digital bone and hoof parameters obtained from the LM and DP radiographs were evaluated through repeated measurements of the same digitalized radiograph by three operators using DICOM software. Data of the morphometric radiographic parameters of the forefeet were statistically analyzed for the frequency distribution and calculation of the intra-assay and interassay coefficients of variation (CVs) of the reproducibility of the measured parameters. Mean  $\pm$  SD of digital bone and hoof parameters were significantly different among the measurements obtained for the 26 parameters. However, intra-assay and interassay CVs for digital bone and hoof parameters measurements did not differ significantly between the three examiners. In conclusion, morphometric evaluation of the radiographic parameters of the forefeet in clinically normal donkeys, establishes a reference data base correspondingly for the donkey different to those accepted for the horse.

**Keywords:** DICOM, donkey, forefeet, morphometric, radiography

*Corresponding Author:*

El-Shafaey E.A., Department of Surgery,  
Anesthesiology and Radiology,  
Faculty of Veterinary Medicine,  
Mansoura University, Mansoura 35516, Egypt  
E-mail address: sayedelshafaey@yahoo.com

Date of initial submission: 29.6.2016  
Date of revised submission: 29.11.2016  
Date of acceptance: 11.1.2016

## INTRODUCTION

Donkeys (*Equus asinus*) represent an important component of Egyptian livestock and make a significant contribution to the agricultural economy; serving as draft animals. Importance of donkeys is also conferred upon them through their use in riding tourism and as eco-friendly economic means of pack and transportation when compared with horses (GOVS, 2006). Despite the donkey's popularity, information regarding various musculoskeletal conditions in this species, including reference limits for lameness variables and diagnostic tests for hoof affections, is limited (Reilly, 1997; Crane, 2007).

The foot represents an important structure for the sound movement of the equine limb during both support and swing phases of the stride. Any affliction that causes pain or reduction in the range of motion may seriously affect performance. (Redden, 2003; Anderson et al., 2004). Diagnosis of foot lameness is a challenging process and needs to be carried out in conjunction with the clinical examinations and different diagnostic imaging modalities (Tucker and Sande, 2001; Dyson and Murray, 2007).

Radiography is traditionally an important part of the subjective routine foot examination in equine lameness (Dyson et al., 2001; White et al., 2008). Recently, quantitative and objective measurement of digital bone and hoof parameters in equidae has evolved tremendously with the development of digital software programmes (Rocha et al., 2004; Read et al., 2012; Caldwell et al., 2016). Knowledge of these measurements in locomotor normal equidae is important for the diagnosis and monitoring of foot lameness such as laminitis, founder, navicular syndrome, ring bone and hoof affections (Redden, 2003; Vanderperren et al., 2009; Vali and Zakipour, 2014).

Many reports have described the radiographic anatomy of the foot in horses (Cripps and Eustace, 1999; Kummer et al., 2004; Vali and Zakipour, 2014). While in donkeys, there is scarce reference information for morphometric analysis of the relevant radiographic parameters of the foot; hence a horse model has been widely applied (Collins et al., 2011; 2012). On the contrary, Reilly (1997) and Collins et al. (2002) demonstrated anatomical variation between the donkey and horse along the digit and asked the validity of applying this model without verifying data.

Therefore, the present study was assumed to provide a standard database of morphometric evaluation of the digital bone and hoof parameters of the forefeet of normal donkeys using DICOM software programme, as a means to improve diagnosis and clinical decision-making regarding foot lameness in equine practice.

## MATERIALS AND METHODS

### Donkeys

Thirty donkeys (20 male and 10 female) at 4 to 8 years of age (Mean  $\pm$  SD:  $6.4 \pm 2.0$  years) and 120 to 180 kg of weight (Mean  $\pm$  SD:  $150 \pm 30$ ), were included in this study. Donkeys were purchased from different localities of Dakahlia governorate, Egypt. All donkeys were clinically sound without a previous history of lameness or feet abnormality. The study protocol was approved by the committee of animal welfare and ethics, Faculty of Veterinary Medicine, Mansoura University.

### Radiographic examinations

Radiographic evaluation of the forefeet was conducted using a 70 kVp, 2 mAs radiography unit (Samsung-dong, SY-31-100- P, Seoul, Korea) from a 70 cm focal distance. For this purpose, the shoes were removed from the feet which were thoroughly cleaned using a hoof pick and wire brush. For all feet, lateromedial (LM) and dorsopalmar (DP) standard radiographic views were obtained with the limb in a vertical position standing on a flat wooden block. The dorsal, medial and lateral hoof wall, bulbs and frog were marked with bands of a soft metal marker fixed in place by adhesive tape as described by Kummer et al., 2004. The LM view was taken with the central beam of the radiograph positioned 1 cm below the coronary band at a right angle to the middle of the line between the bulbs of the heel and the dorsal aspect of the hoof wall. The radiographic beam was aligned parallel to the ground and to the long axis of the distal sesamoid bone. While in the DP view, the radiographic beam was centered at the median of the hoof wall, parallel to the ground and at a right angle relative to the lateromedial radiographic plane. The resulting radiographs were performed and evaluated by a single operator (EE) to optimize reproducibility and control for repeatability effects.

### Morphometric examinations

All obtained forefeet's radiographs were subjected

for morphometric evaluation using Digital Imaging and Communications in Medicine (DICOM) programme. The length and width of the digital bones, founder distance, angles inside the foot, width of the joints, and length of medial and lateral hoof wall were measured. Using the DICOM software, a total of 15 parameters are computed from the LM radiograph and 11 parameters from the DP radiograph with < 5% variance (Appendix). The parameters are divided into digital bone parameters, hoof capsule parameters and hoof angles parameters in correlation to their clinical significance in the differentiation between normal and lame foot.

To expose possible variation between the obtained measurements, a total of 26 digital bone and hoof parameters obtained from the LM and DP radiographs were measured 10 times by the same operator (EE). After that, repeated measurements of the same digitalized radiographs were made by three examiners using DICOM software.

### Statistical analysis

The distribution of the morphometric radiographic parameters data was assessed by the Kolmogorov-Smirnov normality test and the data were determined to be normally distributed. The frequency distribution and the summary statistics (mean  $\pm$  SD, 95% CI, median, range, and 25th, and 75th percentiles) of the radiographic measurements for the digital bone and hoof parameters of donkeys were reported. The reproducibility of the digital bone and hoof pa-

rameters measurement was assessed by calculation of the intra-assay and interassay CVs. For each of the examiners that data were collected from, the intra-assay CV was calculated by dividing the SD of the measurements for that day by the mean of the measurements for that day. For each donkey, the interassay CV was calculated for each of the digital bone and hoof parameters obtained on each data collection day by dividing the SD for that particular measurement by the mean for that particular measurement.

### RESULTS

The frequency distribution of digital bone and hoof parameters measurement on the LM and DP radiographs in donkeys was summarized (Table 1 and 2). Data of the digital bone and hoof parameters measurement on the LM and DP radiographs in donkeys were summarized (Table 3 and 4).

#### Lateromedial view findings

Among 15 measured radiographic parameters of the lateromedial view, the mean of the LP3 was significantly lower than LP1 and LP2 in the digital bone parameters. Also, the mean  $\pm$  SD of the FD was 25.2  $\pm$  31.8 for orthopedic disease free mature donkeys. The tip of P3T was significantly lower than P3G of the hoof capsule parameters (Fig. 1). In addition, the P3BA and NA were significantly lower than the other hoof angle parameters (Fig. 2), Table 3.

**Table 1.** Frequency distribution of the digital bone and hoof parameters on the LM view in the cohort of donkeys.

Category	Digital bone parameters (mm)					Hoof capsule parameters (mm)					Hoof angles parameters (D)				
	LP1	LP2	LP3	FD	NW	P3G	P3T	FL	JH3	HP3	DWL	P3A	NA	HA	P3BA
1 to 11	70 (60)	50 (36)	30 (60)	20 (58)	10 (60)	20 (60)	10 (60)	10 (60)	40 (60)	10 (60)	80 (60)	50 (57)	30 (59)	50 (57)	20 (58)
> 11 to 22	0 (0)	0 (0)	0 (0)	200 (2)	0 (0)	0 (0)	0 (0)	0 (0)	0 (0)	0 (0)	0 (0)	0 (0)	0 (0)	0 (0)	0 (0)
> 22 to 33	0 (0)	0 (0)	0 (0)	0 (0)	0 (0)	0 (0)	0 (0)	0 (0)	0 (0)	0 (0)	0 (0)	0 (0)	270 (1)	0 (0)	0 (0)
> 33 to 44	0 (0)	0 (0)	0 (0)	0 (0)	0 (0)	0 (0)	0 (0)	0 (0)	0 (0)	0 (0)	0 (0)	0 (0)	0 (0)	0 (0)	0 (0)
> 44 to 55	0 (0)	0 (0)	0 (0)	0 (0)	0 (0)	0 (0)	0 (0)	0 (0)	0 (0)	0 (0)	0 (0)	480 (3)	0 (0)	540 (2)	0 (0)

Values represent the number (%) of measurements in that particular digital bone and hoof parameters category for the digit bones. The bone parameters measurements were 1 to 55 mm. For each donkey, 15 parameters were obtained on the 10 times measured LM radiographic projections for each digit and repeated by 3 examiners using DICOM programme. Thus, there were 450 measurements for each parameter of each digit.

### Dorsopalmar view findings

According to Table 4 which represents 11 measured radiographic parameters on the DP view, the JW2 was significantly lower than JW1 and JW3 of the digital bone joints width. Moreover, the BW1 was significantly lower than BW2 of the digital bone width. However, in the hoof wall length of the hoof capsule parameters, the LWL was significantly lower than MWL. Also, between the wall angles, the MWA was significantly lower than LWA of the measured hoof capsule parameters (Fig. 3).

The intra-assay CVs (Table 5 and 6) and inter-assay CVs (Table 7 and 8) for digital bone and hoof parameters measurement on the LM and DP radiographs in donkeys were analyzed. Neither the intra-assay CVs nor the inter-assay CVs differed significantly between the 3 examiners.

### DISCUSSION

Lameness in donkeys is usually related to foot problems that are frequently associated with chang-

**Table 2.** Frequency distribution of the digital bone and hoof parameters on the DP view in the cohort of donkeys

Category	Digital bone parameters (mm)					Hoof capsule parameters (mm)					
	JW1	JW2	JW3	BW1	BW2	LWL	MWL	FW	LWA	MWA	JH3
1 to 11	40 (60)	30 (60)	40 (59)	10 (53)	20 (42)	50 (60)	60 (60)	70 (60)	40 (49)	20 (60)	20 (58)
> 11 to 22	0 (0)	0 (0)	0 (0)	150 (1)	200 (4)	0 (0)	0 (0)	0 (0)	0 (0)	0 (0)	220 (2)
> 22 to 33	0 (0)	0 (0)	0 (0)	0(0)	0 (0)	0 (0)	0 (0)	0 (0)	0 (0)	0 (0)	0 (0)
> 33 to 44	0 (0)	0 (0)	350 (1)	0(0)	0 (0)	0 (0)	0 (0)	0 (0)	380 (1)	0 (0)	0 (0)
> 44 to 55	0 (0)	0 (0)	0 (0)	0(0)	0 (0)	0 (0)	0 (0)	0 (0)	0 (0)	0 (0)	0 (0)

Values represent the number (%) of measurements in that particular digital bone and hoof parameters category for the digit bones. The bone parameters measurements were 1 to 55 mm. For each donkey, 11 parameters were obtained on the 10 times measured DP radiographic projections for each digit repeated by 3 examiners using DICOM programme. Thus, there were 330 measurements for each parameter of each digit.

**Table 3.** Summary of the digital bone and hoof parameters on the LM view in the cohort of donkeys in Table 1.

Variable	Digital bone parameters (mm)					Hoof capsule parameters (mm)					Hoof angles parameters (D)				
	LP1	LP2	LP3	FD	NW	P3G	P3T	FL	JH3	HP3	DWL	P3A	NA	HA	P3BA
Mean ± SD	67.4±1.3	36.2±15.8	28.2±0.3*	25.2±31.8*	11.7±0.2	24.3±0.2	11.8±0.2*	95.4±0.2	37.3±0.2	13.0±0.2	77.4±0.2	70.2±95.4	31.2±31.5*	70.2±88.5	25.0±31.6*
95% CI	67.1-67.7	32.1-40.3	28.1-28.3	16.9-33.4	11.7-11.8	24.2-24.3	11.8-11.9	95.3-95.4	37.3-37.4	13.0-13.1	77.3-77.4	45.5-94.8	23.1-39.3	47.4-93.1	16.5-33.0
Median	67.0	28.4	28.2	19.3	11.7	24.2	11.9	95.4	37.4	13.0	77.4	48.5	27.1	54.1	19.0
Range	65.3-69.6	28.0-68.6	27.6-28.7	19.0-195.0	11.2-12.2	23.9-24.6	11.2-12.2	95.0-95.8	37.0-37.6	12.6-13.5	77.0-77.7	48.0-484.0	26.9-271.0	44.9-543.0	18.9-192.0
Percentile															
25th	66.4	28.2	28.0	19.1	11.6	24.1	11.7	95.2	37.2	12.9	77.3	48.4	27.0	54.0	18.9
75th	68.5	28.6	28.4	19.5	11.9	24.5	12.0	95.5	37.5	13.2	77.5	48.6	27.2	54.2	19.2

\*Value differs significantly ( $P < 0.05$ ) from the corresponding value for the digital bone and hoof parameters of donkeys. See Table 1 for remainder of key.

es in digital bone and hoof parameters (Reilly, 1997; Crane, 2007; Collins et al., 2012). Detection of anatomical change is dependent upon a priori knowledge of normality and subjective assessment alone may not identify modest change (Linford et al. 1993). Therefore, this study aimed to evaluate the digital bone and hoof parameters measurement on the LM and DP radiographs in clinically normal donkeys and assess the reproducibility of DICOM measurements in donkeys. Prior knowledge of these relevant parameters mea-

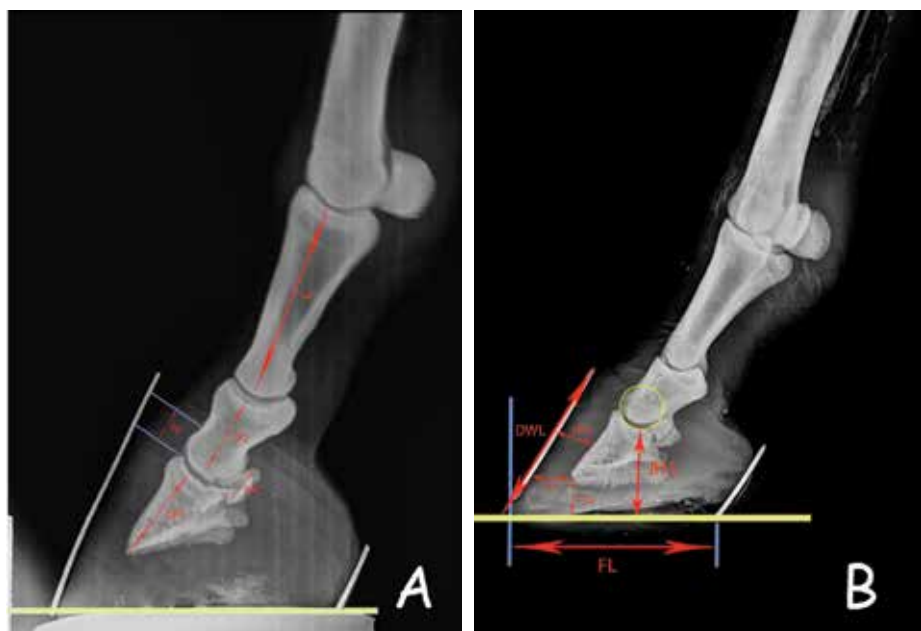
surement is important for the evaluation of the hoof health and will be beneficial in the early diagnosis and monitoring of hoof lameness in donkeys. The LM radiograph represents the gold-standard view for assessment of the equine foot with all the structures in it. At the same time, an increased number of different afflictions related to foot lameness require several radiographic measurements to effectively document the entire extent of these problems within an affected foot (Walker et al., 1995; Herthel and Hood, 1999; Becht et al., 2001; Collins et al., 2011). Thus, in the present

**Table 4.** Summary of the digital bone and hoof parameters on the DP view in the cohort of donkeys in Table 2.

Variable	Digital bone parameters (mm)					Hoof capsule parameters (mm)					
	JW1	JW2	JW3	BW1	BW2	LWL	MWL	FW	LWA	MWA	JH3
Mean ± SD	40.3±0.2	34.2±0.2*	40.8±41.1	16.9±16.9*	35.4±45.1	49.5±0.4*	55.3±0.2	68.6±0.4	43.8±44.7	20.2±0.1*	28.9±36.5
95% CI	40.3-40.4	34.2-34.3	30.1-51.2	12.5-21.3	23.8-47.1	49.4-49.6	55.3-55.4	68.4-68.7	32.3-55.4	20.1-20.2	19.4-38.3
Median	40.3	34.2	35.5	14.8	20.0	49.6	55.3	68.4	38.4	20.1	22.1
Range	40.0-40.6	34.0-34.7	35.0-354.0	14.3-146.0	19.6-199.0	49.0-50.0	55.0-55.7	68.0-69.4	34.4-384.0	19.9-20.4	21.9-224.0
Percentile											
25th	40.1	34.1	35.4	14.5	19.9	49.1	55.2	68.3	38.3	20.0	22.0
75th	40.5	34.4	35.6	14.9	20.3	49.8	55.5	68.6	38.5	20.3	22.3

\*Value differs significantly ( $P < 0.05$ ) from the corresponding value for the digital bone and hoof parameters of donkeys. See Table 2 for remainder of key.

**Figure 1.** Lateromedial radiographic view of a forefoot of donkey showed the digital bone parameter recorded by the DICOM. (A): LP1: length of the first phalanx (P1); LP2: length of the second phalanx (P2); LP3: Length of third phalanx (P3); NW: Navicular bone width; FD: Founder Distance. (B): P3G: Tip of P3 to the ground; P3T: Tip of P3 to toe; JH3: P2-P3 joint height; FL: Foot width; HP3: Hoof-P3 distance; DWL: Dorsal wall length.



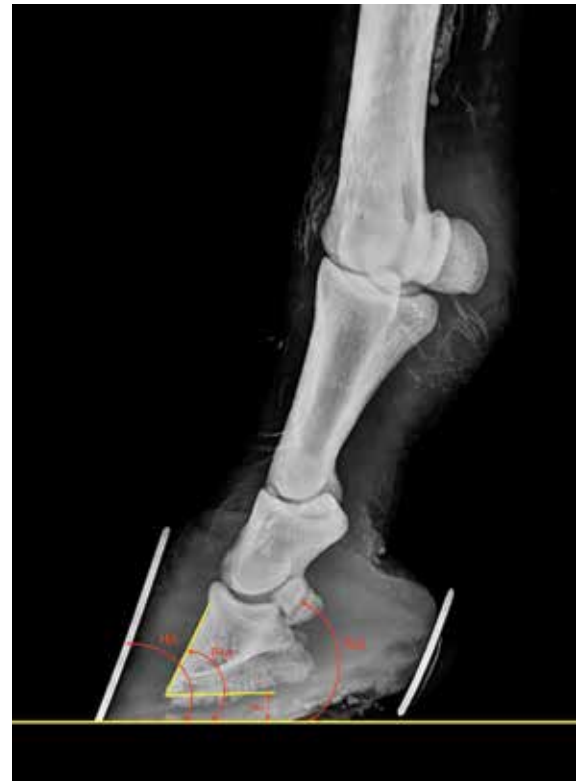study we used the LM radiograph in conjunction with the DP radiograph for accurate evaluation of the digital bone and hoof parameters in donkeys.

Prior to computerized measurements of radiographs, such measurements were formed by direct drawing on the film or on models placed on the initial radiographs. These methods did not provide important variation between operators. It is tremendously time consuming, and the drawing of the radiographs is another cause of inaccuracy (Rocha et al., 2004; Read et al., 2012). In the present study, we use the DICOM programme to morphometrically incorporate information from several radiographic measurements. Consequently, there is a need to find an alternative means of evaluating the combined information derived from several radiographic measurements.

In equine practice, multiple studies have been conducted to assess the reliability and reproducibility of digital bone and hoof parameters measurement obtained by single or multiple instruments (Kummer et al., 2004; Collins et al., 2012). Although, the CV is commonly used to determine the precision of a measurement instrument, to our knowledge this is the first occasion the CV was used to assess digital bone and hoof parameters in donkeys. The mean intra-assay and interassay CVs and the associated 95% CIs (Tables 5-8) were within acceptable limits and without clinical significance, which reveals the quality of the applied radiographic technique. In particular, results of this study indicate that these techniques can be used to successfully develop a robust means for evaluating the prevalent radiographic parameters of the forefeet, thus enabling early diagnosis of lameness in donkey foot on the basis of morphometric analysis of the LM and DP radiographic projections of the digital bone and hoof parameters. This represents a logical progression from previous methods of objective radiographic assessment and offers a means for the quantitative appraisal of donkey feet, thereby providing an important adjunct to traditional methods of subjective clinical assessments. These diagnostic capabilities are essential to ensure clinical intervention in response to anatomic change. These findings were in agreement with White et al., 2008; Collins et al., 2012 and Caldwell et al., 2016.

The present study challenges the feasibility of using the horse model to the normal radiographic anat-

**Figure 2.** Lateromedial radiographic view of a forefoot of donkey showed the hoof angle parameter recorded by the DICOM. P3A: P3 angle; NA: Navicular Angle; HA: Hoof Angle; P3BA: P3 bottom angle.



my of donkey forefeet. It provides new data regarding the digital bone and hoof parameters in sound donkeys. Thus, the diagnosis of anatomical change cannot be based on standard data previously assumed for the horse and should be evaluated correspondingly for the donkey. The mean  $\pm$  SD of the digital bone and hoof parameters in sound donkeys was different to that of horses, according to Rocha et al., 2004 and Masoudifard et al., 2014. This could be attributed to different occupation, anatomical variation in body size, height and weight, shoeing policies and genetics of horses and donkeys that can have an influence on hoof confirmation. In addition, the natural habitat in which the domestic donkey's ancestor's evolved (mountainous, arid areas with narrow paths) is well suited to the narrow, upright hoof anatomy. Thus, given that the digital bone and hoof parameters varies among equidae, it is important to establish a guideline interval for the digital bone and hoof parameters in each individual species.

The obtained radiographic measurements for the

**Table 5.** Intra-assay CVs of the digital bone and hoof parameters on the LM view in the cohort of donkeys in Table 1 for each of the repeated radiographs.

Variable	Operator (O)	Digital bone parameters (mm)						Hoof capsule parameters (mm)				Hoof angles parameters (D)				
		LP1	LP2	LP3	FD	NW	P3G	P3T	FL	JH3	HP3	DWL	P3A	NA	HA	P3BA
Mean ± SD	O1	2.2 ± 0.7	1.8 ± 1.9	1.7 ± 1.1	9.9 ± 5.1	1.9 ± 0.0	2.2 ± 2.4	2.0 ± 0.8	2.4 ± 1.4	3.1 ± 1.2	2.4 ± 1.4	2.4 ± 1.5	1.1 ± 1.6	1.8 ± 0.7	9.0 ± 5.1	9.7 ± 5.0
	O2	2.1 ± 0.9	1.8 ± 2.0	1.9 ± 1.3	10.2 ± 5.3	1.9 ± 0.3	3.0 ± 2.8	2.6 ± 1.0	1.8 ± 1.6	2.5 ± 1.8	3.0 ± 1.9	2.9 ± 1.7	1.8 ± 1.3	2.3 ± 1.1	8.7 ± 5.5	9.6 ± 7.0
	O3	1.9 ± 0.7	1.3 ± 1.2	1.4 ± 2.1	9.5 ± 4.9	1.7 ± 0.1	2.4 ± 2.0	2.0 ± 0.7	2.0 ± 1.9	2.7 ± 1.3	2.4 ± 1.7	2.1 ± 2.0	1.3 ± 1.0	1.7 ± 0.9	9.4 ± 6.0	8.9 ± 6.4
95% CI	O1	0.6 - 3.9	-2.9/ 6.5	-1.1/ 4.5	-2.8/ 22.7	1.9 - 2.0	-3.8/ 8.2	-0.0/ 4.1	-0.9/ 5.8	0.2 - 5.9	-1.2/ 5.9	-1.3/ 5.9	-2.9/ 5.2	0.0 - 3.6	-3.7/ 21.8	-2.6/ 22.5
	O2	0.5 - 3.7	-3/ 6.2	-1.1/ 4.4	-3.0/ 22.1	2.1 - 2.0	-4.0/ 8.0	-0.9/ 4.0	-1.0/ 4.9	0.7 - 4.3	-1.0/ 6.1	-1.2/ 6.0	-2.6/ 5.9	0.1 - 3.8	-4.0/ 19.4	-2.5/ 22.0
	O3	0.8 - 4.0	-2.7/ 6.0	-1.6/ 4.2	-2.6/ 23.0	1.4 - 1.9	-3.7/ 8.5	-0.5/ 3.7	-0.9/ 5.2	0.3 - 5.2	-1.5/ 4.8	-1.3/ 5.8	-2.0/ 6.1	0.6 - 4.2	-3.5/ 20.9	-3.0/ 21.7
Median	O1	1.9	0.7	1.1	12.9	1.9	0.8	1.6	1.9	3.0	1.5	1.9	0.2	2.0	12.0	12.7
	O2	2.0	0.3	1.6	12.5	1.3	0.8	1.9	1.8	0.1	2.0	2.2	0.5	1.7	12.1	11.9
	O3	1.6	0.8	0.9	12.9	2.1	0.5	2.1	1.3	0.6	1.8	1.5	0.3	2.4	12.0	12.6
Range	O1	1.9 - 3.0	0.7 - 4.0	1.1 - 3.0	4.0 - 12.9	1.9 - 2.0	0.8 - 5.0	1.6 - 3.0	1.4 - 4.0	2.0 - 4.3	1.5 - 4.0	1.2 - 4.0	0.2 - 3.0	1.0 - 2.4	3.1 - 12.0	3.9 - 12.7
	O2	2.0 - 3.5	1.0 - 4.8	1.0 - 3.5	4.0 - 11.8	1.7 - 2.4	1.0 - 5.9	1.5 - 3.1	1.2 - 5.0	2.1 - 4.5	2.0 - 4.8	1.0 - 4.6	0.1 - 3.1	1.5 - 2.9	3.0 - 11.8	3.9 - 12.4
	O3	1.6 - 3.2	0.7 - 3.6	1.4 - 2.9	4.2 - 12.6	2.1 - 3.0	0.6 - 4.8	1.8 - 3.5	1.8 - 4.7	2.6 - 5.3	1.2 - 3.7	2.0 - 3.8	0.2 - 2.7	1.7 - 3.4	2.9 - 12.6	3.5 - 11.8
Percentile	O1	1.9	0.7	1.1	4.0	1.9	0.8	1.6	1.4	2.0	1.5	1.2	0.2	1.0	3.1	3.9
	O2	2.0	1.0	1.0	4.0	1.7	1.0	1.5	1.2	2.1	2.0	1.0	0.1	1.5	3.0	3.9
	O3	1.6	0.7	1.4	4.2	2.1	0.6	1.8	1.8	2.6	1.2	2.0	0.2	1.7	2.9	3.5
Percentile	O1	3.0	4.0	3.0	12.9	2.0	5.0	3.0	4.0	4.3	4.0	4.0	3.0	2.4	12.0	12.7
	O2	3.5	4.8	3.5	11.8	2.4	5.9	3.1	5.0	4.5	4.8	4.6	3.1	2.9	11.8	12.4
	O3	3.2	3.6	2.9	12.6	3.0	4.8	3.5	4.7	5.3	3.7	3.8	2.7	3.4	12.6	11.8

Values are percentages.

See Table 1 for remainder of key.

**Table 6.** Intra-assay CVs of the digital bone and hoof parameters on the DP view in the cohort of donkeys in Table 2 for each of the repeated radiographs.

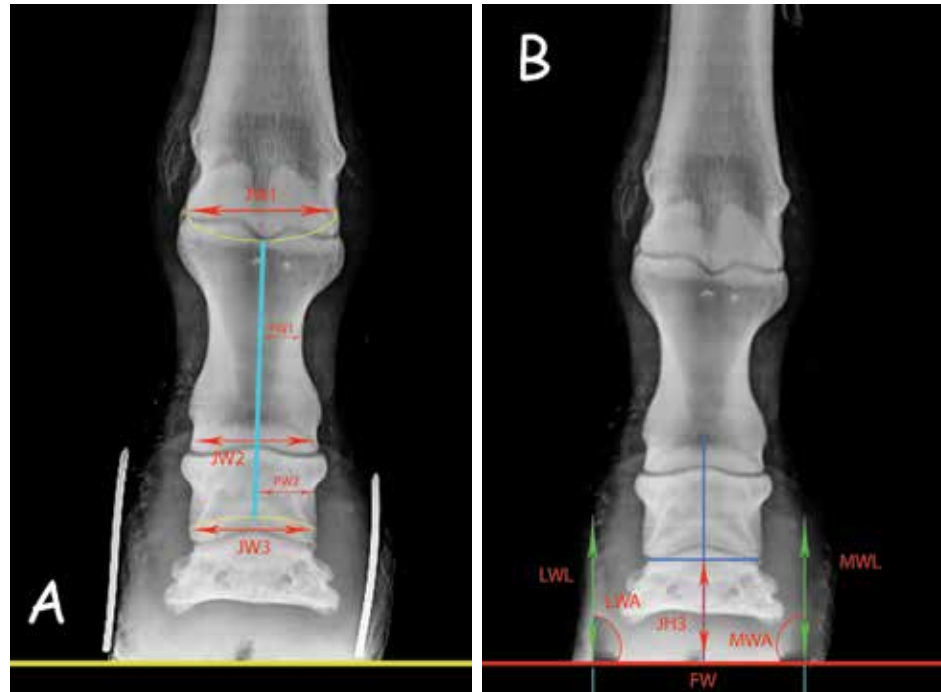
Variable	Operator (O)	Digital bone parameters (mm)					Hoof capsule parameters (mm)					
		JW1	JW2	JW3	BW1	BW2	LWL	MWL	FW	LWA	MWA	JH3
Mean ± SD	O1	1.0 ± 0.9	2.1 ± 0.9	12.4 ± 0.7	12.1 ± 0.3	27.8 ± 16.7	5.1 ± 4.5	7.7 ± 4.2	2.3 ± 0.6	3.7 ± 0.2	3.1 ± 1.2	13.1 ± 2.7
	O2	0.8 ± 1.1	3.0 ± 1.7	11.8 ± 0.9	12.1 ± 0.6	27.5 ± 15.6	3.8 ± 5.1	7.3 ± 3.8	3.4 ± 1.3	4.9 ± 1.5	4.5 ± 1.7	14.6 ± 3.3
	O3	1.4 ± 2.0	2.0 ± 1.2	13.0 ± 1.2	12.9 ± 1.0	28.0 ± 17.0	4.7 ± 5.0	8.1 ± 4.6	2.2 ± 0.9	3.2 ± 0.8	2.8 ± 0.6	13.1 ± 2.9
95% CI	O1	-1.2/ 3.2	-0.0/ 4.2	10.6 - 14.1	11.4 - 12.8	-13.7/ 69.3	-6.2/ 16.4	-2.7/ 18.0	0.9 - 3.8	3.3 - 4.2	0.2 - 5.9	6.4 - 19.7
	O2	-1.0/ 2.9	-1.3/ 5.1	11.2 - 13.7	11.3 - 13.0	-13.0/ 70.5	-6.2/ 15.8	-3.3/ 17.5	1.4 - 5.3	3.1 - 4.7	1.0 - 6.4	6.5 - 20.3
	O3	-1.7/ 3.4	-0.6/ 4.8	10.4 - 14.7	12.0 - 13.6	-12.4/ 68.2	-6.0/ 16.1	-2.4/ 18.6	2.0 - 4.7	2.6 - 5.1	0.7 - 4.8	5.7 - 19.4
Median	O1	0.5	2.0	11.9	11.9	23.0	3.0	9.0	2.0	3.6	3.0	14.6
	O2	0.9	2.6	12.2	11.4	24.6	5.1	10.8	2.7	4.0	4.7	12.4
	O3	0.3	2.1	13.1	12.6	23.0	2.7	9.6	2.9	3.8	3.5	13.9
Range	O1	0.4 - 2.0	1.3 - 3.0	11.9 - 13.2	11.9 - 12.4	14.0 - 46.4	2.0 - 10.3	3.0 - 11.0	2.0 - 3.0	3.6 - 3.9	2.0 - 4.3	10.0 - 14.6
	O2	0.3 - 1.7	1.2 - 3.5	12.1 - 11.8	11.3 - 13.0	15.8 - 44.3	1.8 - 11.4	3.5 - 11.8	2.7 - 4.1	3.2 - 4.1	2.8 - 5.3	10.4 - 13.1
	O3	0.5 - 2.6	2.4 - 3.7	11.6 - 12.4	11.8 - 12.5	13.7 - 42.5	2.6 - 10.9	3.0 - 10.6	1.9 - 3.6	3.4 - 3.7	2.1 - 4.7	11.2 - 14.7
Percentile	O1	0.4	1.3	11.9	11.9	14.0	2.0	3.0	2.0	3.6	2.0	10.0
	O2	0.3	1.2	12.1	11.3	15.8	1.8	3.5	2.7	3.2	2.8	10.4
	O3	0.5	2.4	11.6	11.8	13.7	2.6	3.0	1.9	3.4	2.1	11.2
Percentile	O1	2.0	3.0	13.2	12.4	46.4	10.3	11.0	3.0	3.9	4.3	14.6
	O2	1.7	3.5	11.8	13.0	44.3	11.4	11.8	4.1	4.1	5.3	13.1
	O3	2.6	3.7	12.4	12.5	42.5	10.9	10.6	3.6	3.7	4.7	14.7

Values are percentages.

See Table 2 for remainder of key.



**Figure 3.** Dorsopalmar radiographic view of a forefoot of donkey showed the digital bone and hoof parameter recorded by the DICOM. (A): JW1: fetlock joint width; JW2: pastern Joint width; JW3: coffin joint width; BW1: P1 bone width; BW2: P2 bone width. (B): LWL: Lateral wall length; LWA: Angle between the lateral wall and the ground; MWL: Medial wall length, from the hairline to the medial distal hoof rim; MWA: Medial wall angle, FW: Foot width; JH3: coffin Joint Height.



**Table 7.** Interassay CVs of the digital bone and hoof parameters on the LM view in the cohort of donkeys in Table 1 for each of the repeated radiographs.

Variable	Operator	Digital bone parameters (mm)						Hoof capsule parameters (mm)					Hoof angles parameters (D)				
		LP1	LP2	LP3	FD	NW	P3G	P3T	FL	JH3	HP3	DWL	P3A	NA	HA	P3BA	
Mean ± SD	O1	1.8 ± 0.0	0.7 ± 0.0	1.0 ± 0.0	8.9 ± 6.9	1.9 ± 0.0	0.8 ± 0.0	1.5 ± 0.1	0.2 ± 0.0	0.4 ± 0.0	1.4 ± 0.2	0.1 ± 0.0	0.2 ± 0.0	0.6 ± 0.3	9.0 ± 5.1	8.6 ± 6.7	
	O2	2.1 ± 0.3	1.3 ± 0.9	1.0 ± 0.3	9.2 ± 7.3	2.2 ± 0.7	1.1 ± 0.9	2.4 ± 1.6	0.7 ± 0.4	1.0 ± 0.8	2.5 ± 1.0	0.2 ± 0.6	0.5 ± 0.3	1.1 ± 0.9	10.2 ± 7.0	8.5 ± 7.2	
	O3	1.6 ± 0.9	2.0 ± 1.1	0.8 ± 0.6	8.5 ± 6.2	1.6 ± 0.5	0.6 ± 0.3	1.7 ± 0.8	0.2 ± 1.6	0.7 ± 1.3	1.3 ± 0.8	1.4 ± 0.7	0.1 ± 0.7	0.4 ± 0.7	9.4 ± 5.8	9.4 ± 6.1	
95% CI	O1	1.7 - 1.9	0.6 - 0.8	0.9 - 1.2	-8.2/26.0	1.9 - 2.0	0.7 - 0.9	1.1 - 1.8	0.2 - 0.3	0.4 - 0.5	0.8 - 2.0	0.1 - 0.2	0.1 - 0.2	-0.2/1.4	-3.7/21.8	-8.0/25.9	
	O2	2.0 - 1.5	0.3 - 1.9	1.4 - 2.6	-7.4/25.2	2.1 - 2.6	1.6 - 2.2	1.0 - 2.6	0.4 - 1.3	0.6 - 1.0	1.6 - 3.0	0.3 - 0.5	0.6 - 1.1	-0.0/2.1	-3.4/22.6	-6.9/26.4	
	O3	1.8 - 2.1	0.7 - 0.5	0.5 - 1.3	-8.1/27.6	1.8 - 3.0	0.8 - 1.4	1.9 - 2.5	0.2 - 0.7	0.8 - 1.4	0.5 - 1.7	0.8 - 1.4	0.3 - 0.8	-0.5/1.9	-3.7/19.5	-8.3/24.7	
Median	O1	1.9	0.7	1.1	12.9	1.9	0.8	1.6	0.2	0.4	1.5	0.1	0.2	0.5	12.0	12.7	
	O2	2.4	0.5	2.0	12.0	1.6	1.4	1.5	0.9	0.7	1.5	0.3	0.8	0.9	11.6	12.2	
	O3	1.6	0.4	1.8	12.8	1.2	0.7	1.3	0.5	1.0	1.2	0.7	0.3	0.4	12.4	11.8	
Range	O1	1.8 - 1.9	0.6 - 0.7	1.0 - 1.1	0.9 - 12.9	1.9 - 2.0	0.8 - 0.9	1.3 - 1.7	0.2 - 0.3	0.4 - 0.5	1.1 - 1.5	0.1 - 0.2	0.1 - 0.2	0.4 - 1.0	3.1 - 12.0	0.8 - 12.6	
	O2	2.0 - 2.6	0.5 - 1.2	1.1 - 0.5	1.0 - 11.5	1.8 - 1.5	1.4 - 1.7	1.5 - 2.1	0.6 - 1.4	0.7 - 0.9	1.8 - 2.6	0.9 - 1.3	0.6 - 0.4	0.5 - 0.8	3.4 - 11.6	1.0 - 13.1	
	O3	1.9 - 2.1	0.2 - 0.9	0.8 - 1.6	0.7 - 12.4	2.3 - 2.7	0.9 - 1.2	1.2 - 1.9	0.8 - 0.9	0.4 - 1.0	1.0 - 1.4	0.5 - 0.8	0.9 - 1.2	0.7 - 1.1	4.0 - 12.5	0.5 - 12.7	
Percentile	25th	O1	1.8	0.6	1.0	0.9	1.9	0.8	1.3	0.2	0.4	1.1	0.1	0.1	0.4	3.1	0.8
		O2	2.0	0.5	1.1	1.0	1.8	1.4	1.5	0.6	0.7	1.8	0.9	0.6	0.5	3.4	1.0
		O3	1.9	0.2	0.8	0.7	2.3	0.9	1.2	0.8	0.4	1.0	0.5	0.9	0.7	4.0	0.5
Percentile	75th	O1	1.9	0.7	1.1	12.9	2.0	0.9	1.7	0.3	0.5	1.5	0.2	0.2	1.0	12.0	12.6
		O2	2.6	1.2	0.5	11.5	1.5	1.7	2.1	1.4	0.9	2.6	1.3	0.4	0.8	11.6	13.1
		O3	2.1	0.9	1.6	12.4	2.7	1.2	1.9	0.9	1.0	1.4	0.8	1.2	1.1	12.5	12.7

Values are percentages. See Table 1 for remainder of key.

\*Value differs significantly (P < 0.05) from the corresponding value for the digital bone and hoof parameters of donkeys.

**Table 8.** Interassay CVs of the digital bone and hoof parameters on the DP view in the cohort of donkeys in Table 2 for each of the repeated radiographs.

Variable	Operator (O)	Digital bone parameters (mm)					Hoof capsule parameters (mm)					
		JW1	JW2	JW3	BW1	BW2	LWL	MWL	FW	LWA	MWA	JH3
Mean ± SD	O1	1.0 ± 0.9	1.4 ± 1.3	50.0 ± 65.9	49.7 ± 65.4	46.7 ± 0.6	0.7 ± 0.0	1.2 ± 1.5	1.0 ± 0.8	3.7 ± 0.2	1.5 ± 1.3	9.9 ± 8.1
	O2	1.9 ± 1.7	1.7 ± 2.0	50.1 ± 66.3	50.2 ± 66.1	47.0 ± 1.2	1.1 ± 0.5	1.2 ± 2.3	0.8 ± 1.3	3.3 ± 0.5	1.9 ± 2.6	10.2 ± 8.5
	O3	1.3 ± 2.1	1.2 ± 1.6	49.8 ± 65.4	49.9 ± 65.6	46.5 ± 0.8	0.9 ± 1.0	1.0 ± 1.6	1.6 ± 1.9	4.1 ± 1.1	1.5 ± 1.2	9.6 ± 9.4
95% CI	O1	-1.2/ 3.2	-2.1/ 4.9	-113.7/ 213.8	-112.7/ 212.0	45.3 - 48.1	0.6 - 0.8	-2.6/ 5.1	-1.0/ 3.1	3.3 - 4.2	-1.7/ 4.7	-10.2/ 30.1
	O2	-1.0/ 3.8	-2.2/ 5.3	-115.2/ 210.3	-112.5/ 212.9	44.7 - 47.5	0.5 - 1.0	-2.4/ 5.8	-0.9/ 3.7	3.1 - 4.5	-2.0/ 3.5	-10.1/ 31.0
	O3	-1.6/ 4.1	-1.6/ 5.5	-114.6/ 212.9	-111.8/ 212.6	45.1 - 48.0	0.9 - 1.4	-2.0/ 6.3	-1.2/ 2.8	3.2 - 5.0	-1.4/ 5.1	-9.9/ 30.7
Median	O1	0.5	0.6	11.9	11.9	46.4	0.7	0.3	0.6	3.6	0.8	14.6
	O2	0.4	0.3	11.8	11.7	46.0	1.2	0.8	0.4	4.1	1.0	15.0
	O3	0.7	1.0	11.5	11.4	45.9	0.6	0.1	0.6	3.5	0.3	14.7
Range	O1	0.4 - 2.0	0.6 - 3.0	11.9 - 126.2	11.9 - 125.1	46.4 - 47.4	0.7 - 0.8	0.3 - 3.0	0.5 - 2.0	3.6 - 3.9	0.7 - 3.0	0.6 - 14.6
	O2	0.5 - 2.3	0.5 - 2.8	13.0 - 128.1	11.8 - 126.2	46.9 - 48.0	0.9 - 1.0	0.1 - 2.6	0.8 - 3.1	3.6 - 4.1	1.1 - 3.8	0.8 - 15.0
	O3	0.8 - 3.1	0.3 - 2.9	12.7 - 127.4	12.3 - 127.5	46.5 - 47.3	0.4 - 1.6	0.5 - 1.8	0.7 - 2.4	3.0 - 3.2	0.9 - 2.4	0.3 - 14.1
	O1	0.4	0.6	11.9	11.9	46.4	0.7	0.3	0.5	3.6	0.7	0.6
Percentile	O2	0.5	0.5	13.0	11.8	46.9	0.9	0.1	0.8	3.6	1.1	0.8
	O3	0.8	0.3	12.7	12.3	46.5	0.4	0.5	0.7	3.0	0.9	0.3
Percentile	O1	2.0	3.0	126.2	125.1	47.4	0.8	3.0	2.0	3.9	3.0	14.6
	O2	2.3	2.8	128.1	126.2	48.0	1.0	2.6	3.1	4.1	3.8	15.0
Percentile	O3	3.1	2.9	127.4	127.5	47.3	1.6	1.8	2.4	3.2	2.4	14.1

Values are percentages. See Table 2 for remainder of key.

**Appendix.** Descriptive details of the radiographic and morphometric abbreviations of the digital bone and hoof parameters in the fore-foot of donkey's cohort.

Parameter	Symbol	Definition
Length of Phalanx	LP1	length of the first phalanx
	LP2	length of the second phalanx
	LP3	length of the third phalanx
Founder Distance	FD	Distance between two horizontal lines through the hairline and the top of extensor process of P3
Navicular Width	NW	The width of the navicular bone.
Tip of P3 to ground	P3G	Vertical distance from the tip of P3 to the horizontal line of the ground
Tip of P3 to toe	P3T	Horizontal distance from the tip of P3 to the dorsal hoof wall
Foot Width	FL	The length of the hard hoof support at ground
Joint Height	JH3	P2-P3 (From the coffin joint's center of rotation to the ground plane, minus the radius of the joint).
Hoof-P3 Distance	HP3	Minimum distance between the dorsal mid-line of P3 and the exterior hoof wall
Dorsal Wall Length	DWL	From the hair line to the contact point with ground of the dorsal hoof wall
P3 Angle	P3A	From the dorsal midline of P3 to the ground plane
Navicular Angle	NA	The angle between the axis of the navicular bone and the ground
Hoof Angle	HA	The angle between the dorsal hoof wall and the ground
P3 Bottom Angle	P3BA	The angle formed between the bottom (palmar surface) of P3 and the ground
Joint Width	JW1	Fetlock joint width
	JW2	Pastern Joint width
	JW3	Coffin Joint width
Bone Width	BW1	P1 bone width
	BW2	P2 bone width
Lateral Wall Length	LWL	From the hairline to the lateral distal hoof rim.
Medial Wall Length	MWL	From the hairline to the medial distal hoof rim
Foot Width	FW	Distance between medial and lateral hoof rim
Lateral Wall Angle	LWA	Angle between the lateral wall and the ground
Medial wall Angle	MWA	Angle between the medial wall and the ground
Coffin Joint Height	JH3	Vertical distance between the ground and line connecting the medial and lateral aspect of the coffin joint

digital bone and hoof capsule parameters of the clinically normal forefeet of donkey in this study were in close agreement with that of Collins et al. 2011. At the same time, it indicates that the radiographic parameters of normal donkey forefeet were different to those accepted for the horse. These include marked differences in the alignment of the phalanges (BW1, BW2 and MWA) and the position of the P3 in relation to the hoof wall (P3BA, P3T and MWA). This data supports the empirical observations by Reilly (1997) and Collins et al. (2011) that the P3 is positioned more distally within the donkey hoof capsule than it is in the equine hoof. Hence, the extensor process is not in alignment with the coronary band, as is the case in the horse.

Measuring the FD is a critical diagnostic parameter in evaluation of equine laminitis. In the present study, the P3T and HP3 introduced to measure the sinking occurrence of FD more accurately. The mean  $\pm$  SD of FD in this study was  $25.2 \pm 31.8$ mm which is seen to be lower than the amount of the previous reports in horse (Baxter, 1996; Cripps and Eustace, 1999; Rocha et al., 2004; Masoudifard et al., 2014). This circumstance could be explained by the anatomical variation in hoof between horse and donkey.

Based on the results of this study, the length of P3 is related to the angle of the hoof. Donkeys with long P3 tend to have flatter hooves. Also, donkeys with a large HP3 tend to have smaller HA and P3A. These findings could be interpreted by the increased tension on the laminae of the dorsal hoof wall in hooves with acute hoof angles, resulting in thickening of the soft-tissues dorsal to P3 (Balch et al., 1995; Collins et al., 2011).

Results of this study indicate that the donkey foot displays a unique radiographical parameters supports the assertion that the donkey should be viewed properly as a distinct equid species. Also, suggest that effective evaluation of these parameters in lame feet is essential to guide early veterinary and farriery intervention, where the prospects of treatment success and recovery are most favorable.

A limitation of the present study was its small sample size. Therefore, percentiles were reported to better describe the range of values for digital bone and hoof parameters in orthopedic sound donkeys. Further studies are necessary to include more animals with a wider age, sex and usage spectrum.

### CONCLUDING REMARKS

Based on the results of our study we conclude that, morphometric evaluation of the radiographic parameters of the forefeet in clinically normal donkeys, establishes a reference data base correspondingly for the donkey different to those accepted for the horse. Also, the DICOM screen measuring of these parameters enables early diagnosis of laminitis and hoof problems during complete hoof examinations.

### ACKNOWLEDGMENT

The authors are grateful to Professor Sabry El-Khodery for help in performing the statistical analysis of this paper.

### CONFLICT OF INTEREST STATEMENT

The authors do not have any conflict of interest. ■

---

**REFERENCES**

---

- Anderson TM, McIlwraith CW, Douay P (2004) The role of conformation in musculoskeletal problems in the racing Thoroughbred. *Equi Vet J* 26: 571-5.
- Balch, O, White K, Butler D, Metcalf S (1996) Hoof balance and lameness: improper toe length, hoof angle, and mediolateral balance. *The Compend* 17: 1275-1282.
- Baxter GM (1996) Diagnosing and treating acute laminitis. *Vet Med* 91: 940-952.
- Becht JL, Park RD, Kraft SL, Steyn F, Wrigley RH (2001) Radiographic interpretation of normal skeletal variations and pseudo lesions in the equine foot. *Vet Clin North Am: Equi Pract* 17: 1-18.
- Caldwell MN, Allan LA, Pinchbeck GL, Clegg PD, Kissick KE, Milner PI (2016) A test of the universal applicability of a commonly used principle of hoof balance. *The Vet J* 207: 169-176.
- Collins SN, Dyson SJ, Murray RC (2011) Radiological anatomy of the donkey foot: objective characterization of the normal and laminitic donkey foot. *Equi Vet J* 43: 478-486.
- Collins SN, Dyson SJ, Murray RC, Newton JR, Burden F, Trawford AF (2012) Development of a quantitative multivariable radiographic method to evaluate anatomic changes associated with laminitis in the forefeet of donkeys. *Am J Vet Res* 73: 1207-1218.
- Collins SN, Wealleans H, Hopegood L, Latham RJ, Newlyn HA Reilly JD (2002) Current studies on the donkey hoof. *Medicine and Surgery of the Donkey, Proceedings 2nd CPD Course, Glasgow*, pp 1-15.
- Crane M (2007) Hoof disorders of the donkey, in *Proceedings. 10Th Geneva Cong Equi Med Surg*: 153-156.
- Cripps PJ, Eustace RA (1999) Radiological measurements from the feet of normal horses with relevance to laminitis. *Equi Vet J* 31: 427-432.

- Dyson S, Murray R (2007) Verification of scintigraphic imaging for injury diagnosis in 264 horses with foot pain. *Equi Vet J* 39: 350-5.
- Dyson SJ, Tranquille CA, Collins SN, Parkin TH, Murray RC (2001) An investigation of the relationships between angles and shapes of the hoof capsule and the distal phalanx. *Equi Vet J* 43: 295-301.
- GOVS (2006) Technical Veterinary Report. General Organization of Veterinary Service, Cairo, Egypt.
- Herthel D, Hood DM (1999) Clinical presentation, diagnosis, and prognosis of chronic laminitis. *Vet Clin North Am: Equi Pract* 15: 375-394.
- Kummer M, Lischer C, Vargas J, Hugelshofer, J (2004) Evaluation of a standardized technique to take radiographs of the equine hoof. *Schw Arch Tierh* 11: 507-514.
- Linford RL, O'Brien TR, Trout DR (1993) Qualitative and morphometric radiographic findings in the distal phalanx and digital soft tissues of sound Thoroughbred racehorses. *Am J vet Res* 54: 38-51.
- Masoudifard M, Vajhi AR, Mansouri SH, Molazem M, Bahonar AR, Zehtabvar O (2014) Radiographic measurements of front feet of the sound Akhal-Teke horses. *Iran J Vet Med* 8: 21-25.
- Read RL, Duncan CG, Wallace AD, Perry JA, Duerr FM (2012) Assessment of on-screen measurements, magnification, and calibration in digital radiography. *J Am Vet Med Assoc* 241: 782-7.
- Redden RF (2003) Radiographic imaging of the equine foot. *Vet Clin North Am: Equi Pract* 19: 379-92.
- Reilly JD (1997) The donkey's foot and its care. In: Svendsen ED. *The professional handbook of the donkey*. 2nd ed., London: Whitter Books: 71-93.
- Rocha JV, Lischer CJ, Kummer M, Hässig M, Auer JA (2004) Evaluating the Measuring Software Package Metron-PX for Morphometric Description of Equine Hoof Radiographs. *J Equi Vet Sci* 24: 347-335.
- Tucker RL, Sande RD (2001) Computed tomography and magnetic resonance imaging in equine musculoskeletal conditions. *Vet Clin North Am: Equi Pract* 17: 145-157.
- Vali R, Zaki pour S (2014) Some Radiological Measurements from the Hind Feet of Sound Dareh shori Horses with Relevance to Laminitis and Founder. *Proceeding of the 4th International Symposium of Veterinary Surgery (ISVS), Mashhad, Iran: 92-95.*
- Vanderperren K, Raes E, Bree HV, Saunders JH (2009) Diagnostic imaging of the equine tarsal region using radiography and ultrasonography. Part 2; Bony disorders. *The Vet J* 179: 188-196.
- Walker M, Taylor TS, Slater M (1995) Radiographic appearance of the feet of mammoth donkeys and the findings of subclinical laminitis. *Vet Rad & Ultras* 35: 32-37.
- White JM, Mellor DJ, Duz M, Lischer CJ, Voute LC (2008) Diagnostic accuracy of digital photography and image analysis for the measurement of foot conformation in the horse. *Equi Vet J* 40: 623-628.