

## Journal of the Hellenic Veterinary Medical Society

Vol 67, No 1 (2016)



### Management of distal limb skin defects in dogs and cats

V. TSIOLI (B. ΤΣΙΩΛΗ), E. DERMISIADOU (E. ΔΕΡΜΙΣΙΑΔΟΥ)

doi: [10.12681/jhvms.15618](https://doi.org/10.12681/jhvms.15618)

Copyright © 2018, V TSIOLI, E DERMISIADOU



This work is licensed under a [Creative Commons Attribution-NonCommercial 4.0](https://creativecommons.org/licenses/by-nc/4.0/).

### To cite this article:

TSIOLI (B. ΤΣΙΩΛΗ) V., & DERMISIADOU (E. ΔΕΡΜΙΣΙΑΔΟΥ) E. (2018). Management of distal limb skin defects in dogs and cats. *Journal of the Hellenic Veterinary Medical Society*, 67(1), 5–16. <https://doi.org/10.12681/jhvms.15618>

## **Management of distal limb skin defects in dogs and cats**

**Tsioli V.<sup>1</sup>, DVM, PhD, Dermisiadou E.<sup>1</sup>, DVM**

<sup>1</sup>Clinic of Surgery, Faculty of Veterinary Medicine, University of Thessaly Greece

## **Αντιμετώπιση ελλειμμάτων δέρματος στο περιφερικό τμήμα των άκρων στο σκύλο και στη γάτα**

**Τσιώλη Β.<sup>1</sup>, DVM, PhD, Δερμισιάδου Ε.<sup>1</sup>, DVM**

<sup>1</sup>Χειρουργική Κλινική, Κτηνιατρική Σχολή Πανεπιστημίου Θεσσαλίας

**ABSTRACT.** Skin defects on the lower limb are common and their management is usually challenging. All trauma patients should be initially assessed for concurrent injuries and stabilized. Debridement and cleansing is performed in all wounds. The most important factors for decision making on wound closure are the wound size, the extent of soft tissue damage, the presence of contamination and impaired perfusion. Primary closure is the preferred choice although; it is seldom applicable in wounds on the distal limbs. Delayed primary closure, secondary closure or second intention healing can be undertaken under certain circumstances in such wounds. When these options are not feasible local pedicle flaps, axial pattern flaps, distant flaps, grafts, muscle or myocutaneous flaps and microvascular free tissue transfer can provide coverage.

**Keywords:** cat, dog, limbs, skin defects

**ΠΕΡΙΛΗΨΗ.** Τα ελλείμματα δέρματος στο περιφερικό τμήμα των άκρων είναι πολύ συχνά και η αντιμετώπισή τους αποτελεί πρόκληση για τον χειρουργό. Αρχικά, οι ασθενείς πρέπει να ελέγχονται για την ύπαρξη συνοδών τραυμάτων και να σταθεροποιούνται. Στη συνέχεια θα πρέπει να γίνεται νεαροποίηση και καθαρισμός όλων των τραυμάτων. Η επιλογή της κατάλληλης τεχνικής για τη σύγκλειση του τραύματος καθορίζεται κυρίως από τους εξής παράγοντες: το μέγεθος του τραύματος, τον βαθμό κάκωσης των μαλακών ιστών και την παρουσία επιμολύνσεων και διαταραχών της αιμάτωσης. Αν και η κατά πρώτο σκοπό σύγκλειση είναι η μέθοδος εκλογής σπάνια μπορεί να εφαρμοστεί σε τραύματα στο περιφερικό τμήμα των άκρων. Η καθυστερημένη κατά πρώτο σκοπό σύγκλειση, η κατά τρίτο σκοπό σύγκλειση και η επούλωση κατά δεύτερο σκοπό μπορούν υπό προϋποθέσεις να βρουν εφαρμογή σε ελλείμματα στο περιφερικό τμήμα των άκρων. Ωστόσο, σε περιστατικά όπου η παραπάνω επιλογές δεν είναι εφικτές μπορούν να εφαρμοστούν τοπικοί ή απομακρυσμένοι κρημνοί, αξονικοί κρημνοί, μυϊκοί ή μυοδερματικοί κρημνοί, μοσχεύματα και μεταφορά ιστών με μικροχειρουργική.

**Λέξεις ευρετηρίασης:** άκρα, γάτα, ελλείμματα δέρματος, σκύλος

*Correspondence:* Tsioli V.  
Clinic of Surgery, Faculty of Veterinary Medicine, University of Thessaly Greece  
224, Trikalon str., 43100 Karditsa, Greece  
Tel.: +30 2441066067, e-mail: vtsioli@vet.uth.gr

*Αλληλογραφία:* Τσιώλη Β.  
Χειρουργική Κλινική, Τμήμα Κτηνιατρικής Π.Θ. Τρικάλων 224, 43100 Καρδίτσα  
Τηλ: 2441066067, e-mail: vtsioli@vet.uth.gr

*Date of initial submission:* 10.07.2014  
*Date of acceptance:* 05.08.2014

## INTRODUCTION

Skin defects of the distal limbs in dogs and cats are very common and are usually caused by car accidents (shearing injuries), bites, lacerations from sharp objects, thermal injuries, bullet penetration, casts and bandages, surgical resection of neoplasms etc (Swaim, 1997). They are often presented with concurrent injuries or lesions of the subcutaneous and underlying tissues (muscles, tendons, and ligaments), orthopaedic problems (e.g. fractures, luxations) and peripheral nerve injuries (Beardsley and Schrader, 1995).

Management of wounds on the extremities poses a challenge to veterinary surgeons. Skin defects, especially on the distal extremities are more difficult to close due to the paucity of elastic skin, the absence of the panniculus muscle, the movement in the area which easily leads to dehiscence and their greater distance from potential donor areas (Pavletic, 2010; Fahie, 2012). In complex wounds or when skin loss approaches 50% of the circumference of an extremity, some form of skin, muscle or myocutaneous flap or grafting technique will be necessary in order to cover the defect (Corr, 2009; Pavletic, 2010). A major problem in managing wounds on extremities is tension. Excessive tension may cause dehiscence, circulatory compromise, skin necrosis, retarded wound healing or failure of healing (Mayhew, 2009; Pavletic, 2010; Stanley, 2012).

Small sized defects (skin loss less than 30% of the limb circumference) or loss of the upper layers of the skin may be left to heal by second intention (Fowler, 2006). On the contrary, second intention wound healing is not recommended for medium and large sized defects as epithelialization is insufficient for covering the deficit, the healing process may delay or fail because contraction cannot hold the skin edges in contact and chronic granulation tissue formation at the center of the wound may have not enough vascularity to support epithelialization (Pavletic, 2010). Thus, the underlying tissues remain exposed and restrictive scar tissue formation may result in decreased range of motion of joints and limited limb function (Friend, 2009). Additionally, second intention wound healing has an inferior cosmetic outcome and the formed scar tissue consists of a fragile epithelium, which makes its surface easily trau-

matized or prone to chronic ulcers (Pavletic, 2010).

There are many techniques for relieving skin tension in small and medium sized wounds thus, skin advancement can be achieved and wounds can be managed by primary or delayed primary closure. A variety of more complex reconstructive techniques provide options for skin defect coverage in large sized defects. This article reviews the existing techniques for managing all the aforementioned cases.

## CLOSURE TECHNIQUES

### Choice of technique

The surgeon must always consider that the technique chosen should be for the benefit of the patient. Planning of the treatment should take into consideration both the patient's and the wound's characteristics. Factors that affect the choice of methods or reconstructive techniques (table 1) include the following: the time that has elapsed since injury, the size of the wound, the degree of contamination, the extent of tissue damage, the extent of the required debridement, the wound's blood supply, the animal's health condition, the presence of tension or dead space and the wound location (Hosgood, 2012; MacPhail, 2013). Taking into consideration these factors the choice of the appropriate reconstructive closure technique should follow the principles of the 'reconstructive ladder' (Williams, 2009). Thus, if primary closure is not feasible, delayed primary closure, secondary closure or second intention healing can be undertaken. In the presence of tension simple tension-relieving techniques can be applied. Subdermal plexus and axial pattern flaps, grafts, muscle or myocutaneous flaps and microvascular free tissue transfer are the alternative options especially for large wounds on the extremities.

### Primary closure (First intention healing)

Wounds considered for primary closure include the following: recently created wounds, clean wounds with minimal tissue trauma, contaminated wounds that have been converted to clean ones with debridement and lavage, defects after complete excision of small contaminated or infected areas and when wound closure can be achieved without undue tension. Sutures, skin staples, tissue adhesives and fibrin sealants can

**Table 1:** Management options for traumatic wounds on the extremities

Size of the wound	Classification/infection	Classification	Method/Technique
Any size	Clean	Incisional	Primary closure
Small	Clean-contaminated	Puncture	Primary closure
Medium			Delayed closure*
Large			Delayed closure*
Medium	Clean-contaminated	Abrasions	Delayed closure*
Large			Flaps/grafts
Any size	Contaminated	Abrasions	Delayed closure Flaps/grafts
Medium/large	Contaminated	Degloving/shearing	Delayed closure Flaps/grafts
Medium/large	Dirty/infected	Degloving/shearing	Delayed closure Flaps/grafts
Any size	Contaminated	Avulsions	Delayed closure
Any size	Dirty/infected	Avulsions	Delayed closure Flaps/grafts

\*Combined with tension relieving techniques

be used for apposition of the wound edges (Williams, 2009). On limbs, primary closure can be applied on wounds caused by sharp instruments, when skin edges are in close apposition, for small sized defects where no excessive tension exists, and for medium sized defects combined with tension relieving techniques (Swaim, 1997).

### Delayed primary closure

In this technique, daily open wound management is performed until first appearance of granulation tissue and thus wound closure is delayed for 3 to 5 days after injury (Hosgood, 2012). Delayed primary closure is used in clean-contaminated or contaminated wounds, in wounds with substantial oedema, where there is questionable tissue viability, moderate degree of tissue trauma and in dirty wounds when staged debridement is required. Delayed primary closure provides to the wound adequate drainage, improves circulation and ensures inflammation subsides before closure. Indications for delayed closure on limb defects are penetrating wounds or avulsions, small sized defects where no excessive tension exists, and medium sized defects in combination with tension relieving techniques (Pavletic, 2010).

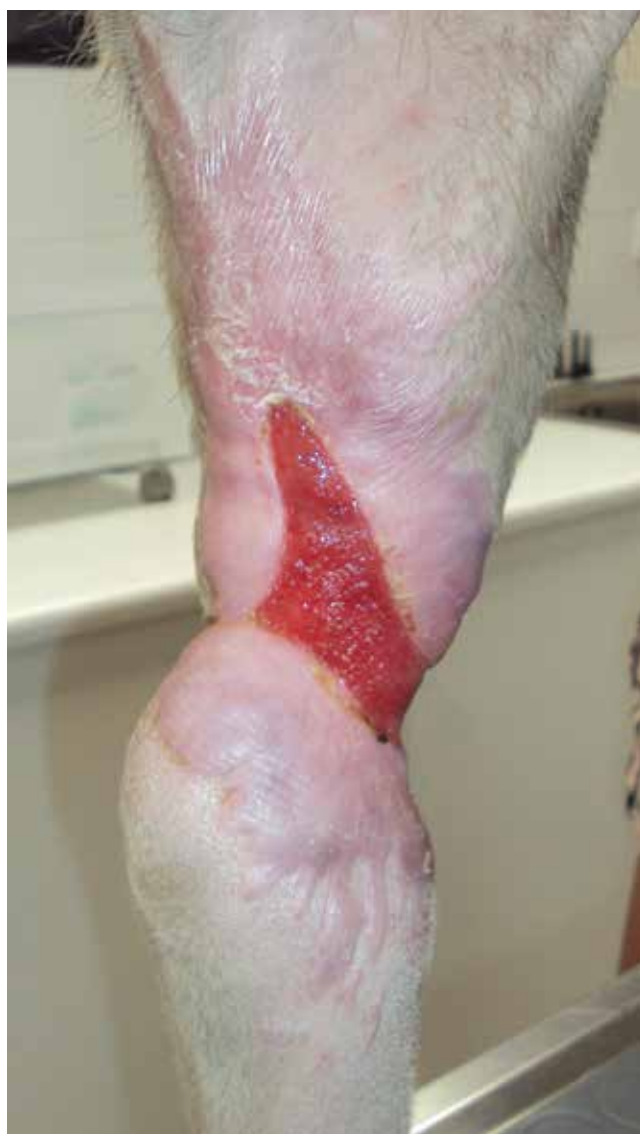### Secondary closure (Third intention healing)

Wound closure between the 5<sup>th</sup> and 10<sup>th</sup> day after injury is called secondary closure. During this period of open wound treatment granulation tissue has formed and covers the wound bed. Secondary closure is used in contaminated or dirty wounds and when serial debridement and wound cleansing beyond 5 days is required. Closure is accomplished by direct apposition of wound edges over the previously formed granulation tissue (healing by third intention) or after granulation tissue excision and primary closure (Pavletic, 2010; Hosgood, 2012). Indications for secondary closure on limb defects are penetrating wounds or avulsions, degloving injuries, small sized defects where no excessive tension exists, and medium sized defects in combination with tension relieving techniques or more often with an appropriate flap or graft.

### Second intention healing

Healing by second intention is an easy and inexpensive way to treat wounds which are left open and closure is achieved by contraction and epithelialization (Hosgood, 2012). Second intention healing is more

appropriate for dirty wounds with gross inflammation, presence of necrotic tissues and extensive soft tissue trauma. These wounds are unsuitable for primary or delayed primary closure (Hosgood, 2009; Pavletic, 2010). Second intention healing is better reserved for wounds located in areas with ample skin. Therefore, it is contraindicated in defects located in areas with skin paucity such as the middle to lower extremities and the tail. Especially, in large wounds on the extremities, tension to the wound edges may become equal to the contraction forces of myofibroblasts resulting in incomplete healing (Hosgood, 2006). Other contraindications are defects with concurrent muscle injuries



**Figure 1.** Second intention wound healing with contraction and thin epithelium adjacent to a joint.

or exposure of bones, joints or nerves. Potential complications include prolonged healing and wound care, epithelial surface that is more prone to injury, poor cosmesis, delayed or incomplete healing, excessive scarring and wound contraction. Contraction on a joint surface might restrict the range of motion (figure 1) and scar tissue adjacent to an anatomical opening may lead to stenosis or deformation.

### **Tension relieving techniques**

Small to medium sized wounds on the distal limbs can be closed primarily by various tension relieving techniques. Skin on the limbs can be mobilized to a limited degree in a craniocaudal plane whereas little skin can be elevated in a proximal – distal direction (Pavletic, 2010).

**Undermining:** is a simple and effective way to reduce tension. It is performed by blunt or sharp dissection beneath the panniculus muscle in order to keep the direct cutaneous vessels intact although, sharp dissection is more effective in the extremities (Swaim, 1997; Stanley, 2012). Undermining on the middle and distal portion of the extremities should be done in the areolar connective tissue above the fascia of the underlying muscle (e.g. antebrachium or tibial area) or including the superficial leaf of the fascia (e.g. lateral femoral surface) to preserve the subdermal plexus (Mayhew, 2009). It is necessary that skin adjacent to the wound is healthy in order to tolerate undermining. Undermining alone can achieve closure only to small defects on the extremities whereas it is ineffective for larger ones (Pavletic, 2010).

**Tension relieving sutures:** distribute tension in a larger area and should be used when there is motion at the suture line (over joints or footpads). Strong subcutaneous sutures (simple interrupted, cruciate, far-near-near-far and far-far-near-near), intradermal tension sutures, simple interrupted sutures (walking sutures, horizontal or vertical mattress), far-near-near-far and far-far-near-near sutures and stent sutures are used to facilitate skin advancement, reduce tension and preserve the safety of the skin sutures (Swaim, 1997; Pavletic, 2010; Stanley, 2012). Strong subcutaneous and intradermal tension sutures



should be placed in the deep areolar tissue above the fascia or in the deep fascia (Mayhew, 2009). Horizontal or vertical mattress and far-near-near-far or far-far-near-near sutures are better removed by the third and seventh postoperative day respectively. Tension relieving sutures should be used cautiously in the extremities and only to small defects.

**Skin stretching techniques:** rely on the phenomena of mechanical and biological creep and stress relaxation. They can be used pre- intra- or post-operatively. Pretensioning sutures and presuturing, externally applied skin stretching devices and skin expanders are used to achieve skin elongation in order to cover a defect. These techniques are effective in proximal and distal limb wounds (Keller et al., 1994; Pavletic, 2000; Stanley, 2012).

**Relaxing incisions:** allow apposition of skin edges and they are indicated for medium sized defects on the distal limbs or for wounds with exposure of tendons, ligaments vessels and nerves. A simple relaxing incision, of equal length to the defect, is made 3-10 cm from the wound edge, the skin is undermined and a bipedicle flap is created. Alternatively, multiple relaxing incisions 1cm long, are made parallel and 1-2 cm from the wound edges, on both sides of the defect. The incisions should be at least 1 cm apart. Skin is undermined and closure of the defect is achieved. Multiple relaxing incisions can be created circumferentially in order to close defects on limbs (Swaim and Scardino, 1998; Mayhew, 2009; Stanley, 2012). The newly created defects are left to heal by second intention. Pavletic (2010) describes a modification of the simple relaxing incision where the incision is made to the dermis via the hypodermis. This technique eliminates the need for resuturing and for open wound management.

**V -to- Y Plasty, Z - Plasty, M - Plasty:** are techniques which provide a modest reduction in tension. In these plasty techniques additional surgical incisions are made in a specific pattern, skin is undermined and small local subdermal flaps are harvested. They are used to alter tension direction and to augment the range of motion (Mayhew, 2009; Pavletic, 2010). They are useful for problematic wounds on joints, where linear scars restrict mobility and elas-

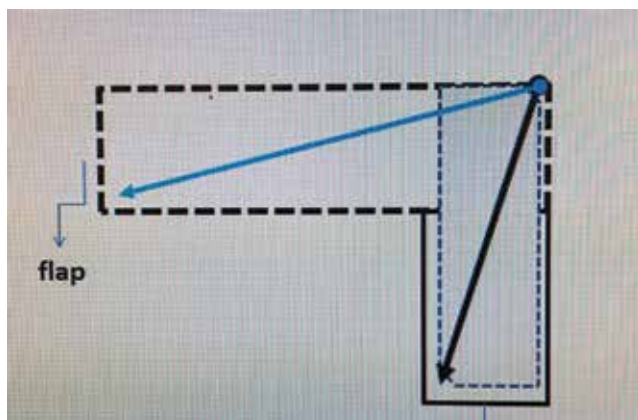
ticity, for small defects on the limbs but premise that adjacent skin is loose and mobile.

## Reconstructive techniques

### *i. Skin flaps*

Skin flap is a segment of skin and subcutaneous tissue partially dissected and elevated from a region (donor site) and transferred to another region (recipient site) in order to cover a skin defect. The base of the flap remains attached to the donor site and contains the vessels which provide the blood supply to the detached segment (Pavletic, 2010). Flap classification depends on their blood supply (random or subdermal plexus flaps and axial pattern flaps), on the distance between the donor and the recipient site (local and distant flaps), and on the followed method and the time of transfer (direct and indirect flaps) (Swaim, 1997). The size and the location of the defect are important factors in choosing the appropriate flap technique. A donor site with abundant and elastic skin should be selected in order to close the created defect primarily and without tension. This is assessed preoperatively by grasping the skin of the donor site between the thumb and index finger to determine if laxity is present (Mayhew, 2009; Pavletic, 2010). Precise preoperative measurements of the defect should be done and the flap should be outlined by a marking pen (Hunt, 2012).

The recipient site has to be free from necrotic or contaminated tissues and covered by healthy reddish granulation tissue. Chronic granulation tissue or epithelium should be removed. Strict aseptic technique and atraumatic tissue manipulation must be followed, in order to minimize infection and to preserve blood supply. To ensure the latter undermining below the panniculus muscle must be performed and tension both at the donor and recipient bed should be avoided. Patient's positioning may improve mobilization of skin and thus reduce tension. Flaps that have a potential use on extremities are: a) for forelimbs subdermal plexus flaps, skin fold flaps and axial pattern flaps and b) for pelvic limbs direct distant flaps, indirect (tubed) flaps and axial pattern flaps (Hunt, 1995; Mayhew, 2009; Pavletic, 2003; Pavletic, 2010; Hunt, 2012; MacPhail, 2013).



**Figure 2.** A 90 degrees transposition flap. The black arrows show that the length of the flap is equal to the length from the pivot point to the distal margin of the defect.

**Random or subdermal plexus flaps:** are local flaps that their blood supply relies on the subdermal plexus. Thus, it is important to elevate it by undermining deeper to the plexus. These flaps are further classified, according to the direction they are advanced towards the defect, to advancement, rotating, transposition and interpolation flap (Mayhew, 2009; Pavletic, 2010; Hunt, 2012; MacPhail, 2013). An advancement flap is created by advancing skin in a straight direction in order to cover an adjacent defect. If two parallel incisions of same size are made to harvest the flap, then a *single pedicle* flap is created. Single pedicle flap is as wide as the wound defect and has a base attached to the donor site. A *bipedicle* flap is developed after a single incision is made and the flap length equals the length of the defect. *Rotating* flaps are moved to another direction to approach the recipient site and they are subdivided into rotation, transposition and interpolation flaps. A *rotation* is a flap created after a curved surgical incision is made and the skin is undermined. This flap is rotated to cover an adjacent triangular defect while a secondary defect is not created. A *transposition* is a rectangular flap, which is rotated 45° to 90° to cover an adjacent defect (figure 2). As the degree of rotation increases, the length of the flap decreases. The width of the flap equals the width of the defect while the length of the flap is determined by measuring from the pivot point of the flap to the most distant point the defect. The measurements for such

flaps on the extremities must be accurate as even a small error can make primary suture of the donor site impossible (Pavletic, 2010). Transposition flaps can be used to medium sized defects of the limbs by developing the flap parallel to the longitudinal axis of the limb in order to exploit the circumferential skin laxity present. *Interpolation* flap is a variation of the transposition flap, which lacks a common border with the defect. After harvesting the flap it is rotated and placed at the deficit, by overpassing a region with normal skin tissue. *Skin fold flaps* are also considered subdermal plexus flaps. The mobile and loose skin from the axillary and flank fold has four attachments: lateral and medial forelimb and dorsal and ventral trunk. These triangular folds are extremely versatile depending on which attachments will be divided. A bridging incision might be needed to merge the deficit with the flap. Donor site has minimal tension, but the width of the remaining attachment should be sufficient to ensure flap survival. Skin fold flaps are transferred to cover wounds on lateral and medial upper limb; elbow, lateral thoracic area, lateral flank, inguinal and pectoral area, and lateral and medial stifle regions (Hunt et al., 2001; Hunt, 2012; Brinkley, 2007). The dimensions of a local flap and the presence of tension are important factors in preventing postoperative complications. Tension may cause dehiscence at the donor or the recipient site or excessive stretching of the flap. During flap development incisions should ideally be parallel to tension lines and patients should be properly positioned (Pavletic, 2010). Subdermal plexus flaps should have a wide base and a length sufficient to cover the defect. By reducing the width of the base blood perfusion decreases or the contrary, by increasing the width direct cutaneous vessels might be included and blood supply is improved (Hunt, 2012). It is advisable that the flap's length should be kept short in order to avoid necrosis of the free edges and wound dehiscence. When there is a need for longer flaps bipedicle or axial pattern flaps are a better option (Pavletic, 2010).

Complications of local skin flaps include seroma formation, dehiscence and distal flap necrosis. In large wounds where dead space is present prevention

of seroma formation is achieved by placement of a closed suction drain or by bandaging. Dehiscence usually results due to tension which can be avoided by using meticulous technique. Distal flap necrosis is due to decreased or ceased blood supply and becomes evident 2-5 days postoperatively (Mayhew, 2009). Prevention of necrosis requires good planning of the flap's dimensions and gentle handling of tissues.

**Distant flaps:** are flaps created far from the defect and they are used for reconstructing lower extremity wounds. The lateral thoracic or the abdominal area is used as donor sites, depending on the location of the defect (forelimb or hindlimb respectively). Distant flaps require multistaged surgical procedures and they are time - consuming and expensive. They are rarely used as grafts or axial pattern flaps are simpler and less demanding techniques. Distant flaps are subdivided into direct and indirect flaps (Lemarié et al., 1995; Swaim, 1997).

*Direct* flaps may be single pedicle (hinge) or bipedicle (pouch). The flap is harvested and the limb (recipient site) is moved and secured to the donor site so as the wound bed is covered by the flap (Lemarié et al., 1995). The transfer is completed after 3 weeks and during this period the limb is strictly immobilized. *Indirect flaps* are delayed tubed flaps. After careful planning, skin is incised and a bipedicle flap is created and tubed. The donor site is closed and 2-3 weeks later the distal tip of the tube is separated and sutured to the deficit. Indirect flaps may be rotated over 180° so they can be applied in distant defects, depending on their length (Hunt, 2012).

**Axial pattern skin flaps:** have a blood supply that relies at least on one direct cutaneous artery

and vein. They have rich perfusion and an increased rate of survival (96-100%) (Remedios et al., 1989; Aper and Smeak, 2003; 2005). When compared to subdermal plexus flaps with equal dimensions, they have 50% more possibilities for survival (Pavletic, 1980; 1993; Wardlaw and Lanz, 2012). Axial pattern flaps' design require a thorough knowledge of all the local anatomic structures and especially of vessels origination and direction, and also of the angiosomes (three dimensional areas of tissues vascularized by a major artery). Their viability relies on the direct cutaneous vessels which must remain intact (Chambers et al., 1998). Axial pattern flaps are classified into peninsular or island flaps. *Peninsular* flaps remain attached at their base to the donor site whereas; *island* flaps are attached to the donor site only by their direct cutaneous vessels (Remedios et al., 1989; Holt and Runge, 2011). Therefore island flaps have better mobility (they can be rotated up to 180°) than peninsular flaps. Axial pattern flaps have a rectangular or L shape so they can cover more asymmetric deficits (Pavletic, 1993). They usually serve as distant flaps and they can cover medium to large skin defects. However, they might be used as local flaps when there is insufficient skin for the creation of a subdermal flap or its survival is questionable (Chambers et al., 1990; Cornell et al., 1995). Cosmesis may not be as good as with local flaps as color, length and direction of hair might have differences with the regional hair growth. Glands and thickness of subcutaneous tissues may also differ. Reconstruction of wounds with axial pattern flaps is performed in a one-stage procedure although, their development and transfer requires careful planning.

**Table 2:** Axial pattern flaps on limbs

Artery	Potential uses
Thoracodorsal	Thoracic, shoulder, forelimb, elbow, axillary, flank, antebrachium, carpus (cats only) defects
Superficial brachial	Antebrachial, elbow defects
Caudal superficial epigastric	Caudal abdominal, flank, inguinal, preputial, perineal, thigh, stifle, crus, hock (depends on conformation in dogs), metatarsal and phalangeal (cats only) defects
Reverse saphenous conduit	Tarsometatarsal defects
Genicular	Medial stifle, tibial, hock (depends on conformation in dogs) defects



The width and length of axial pattern flaps is based on specific anatomical landmarks defined from the flap's design. Width should be equal to that of the defect and in cases where the latter is wider, an L-shaped flap should be considered. Use of the longest variation of a flap might cause necrosis of its tip (Kostolich and Pavletic, 1987). Necrosis may be partial or full-thickness. Debridement and resuturing is required in full-thickness skin loss whereas in partial thickness necrosis with survival of the dermis the flap is managed as open wound. The ability of axial pattern flaps to reach and cover a defect is affected by species, body conformation and skin elasticity (figures 3a and 3b). Compared to grafts, axial pattern flaps can survive even on poorly vascularized tissues such as contaminated wounds, or defects with exposed bones, cartilages or tendons; as they do not depend on the recipient site for vascularization.

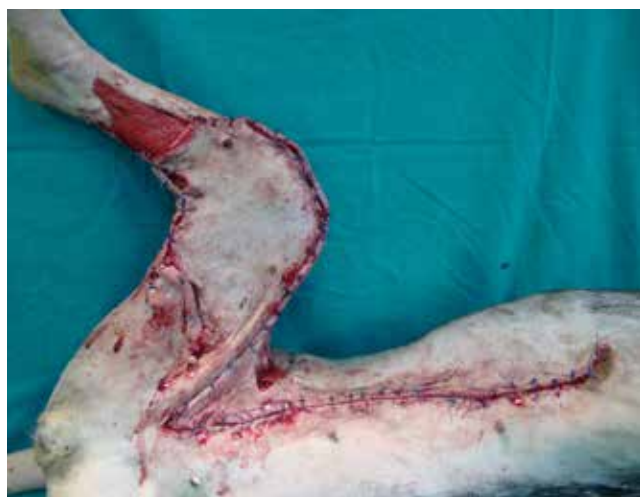The axial pattern flaps with potential use on distal limb defects are presented in table 2. Superficial brachial (figures 4a and 4b) and genicular axial pattern flap have limited use because their perfusion relies on small diameter arteries and skin necrosis is a common complication (Kostolich and Pavletic, 1987; Shields and Pavletic, 1988).

#### ii. *Skin grafts*

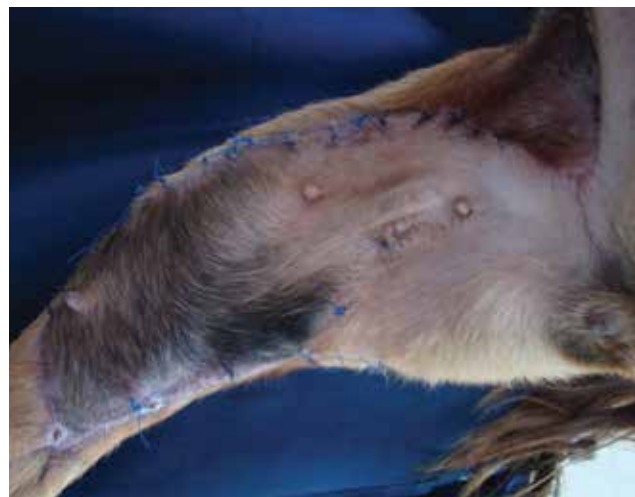
A *skin graft* is a segment of epidermis and dermis of variable thickness that is completely removed from the donor site and transferred to the recipient site. Skin graft's survival depends exclusively on the

revascularization from the recipient site which has to be healthy, without infections and well vascularized (Pope, 1998; Swaim, 2003). Therefore, wounds with healthy granulation tissue, fascia, muscle, peritoneum and periosteum may become an appropriate bed (White, 2009; Pavletic, 2010). Successful graft healing is depending on proper adherence and nutrition from the recipient site. Adherence starts 8 hours after transplantation where fibrin formation at the wound bed connects the graft with the underlying tissues. One week later fibrin is replaced by connective tissue. The 2<sup>nd</sup>-3<sup>rd</sup> day the nutrition processes starts with the graft receiving red cells and serum proteins from the recipient site. During this stage the flap appears to be swollen and dark colored. The 3<sup>rd</sup> day, vessels anastomoses take place between vessels of the recipient site and graft's vessels, in order to maintain perfusion. Finally, the 4<sup>th</sup>-5<sup>th</sup> day revascularization, with new capillaries and lymphatics formation, is established (Bohling and Swaim, 2012).

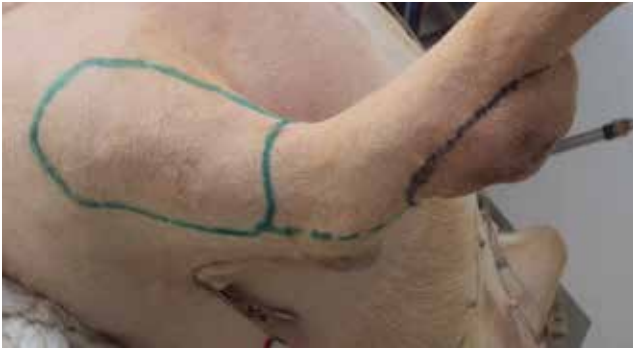Autografts are mainly used in veterinary surgery. According to their thickness they are divided into full thickness (composed of epidermis and entire dermis) and split-thickness (composed of the epidermis and a part of dermis). Small sized skin grafts provide partial cover of the defect and depending on their shape they are subdivided into pinch, punch, strip and stamp grafts (Swaim, 1990; Swaim, 2003; White, 2009). Mesh grafts are full or split-thickness grafts that may cover large skin defects (figures 5a, 5b and



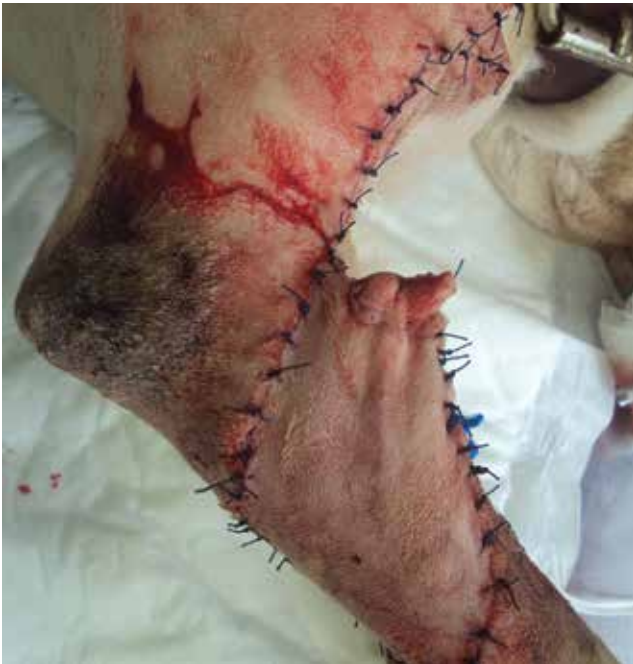**Figure 3a.** Caudal superficial epigastric axial pattern flap was used for the management of extensive bite wounds in a dog.



**Figure 3b.** Caudal superficial epigastric axial pattern flap 20 days postoperatively.

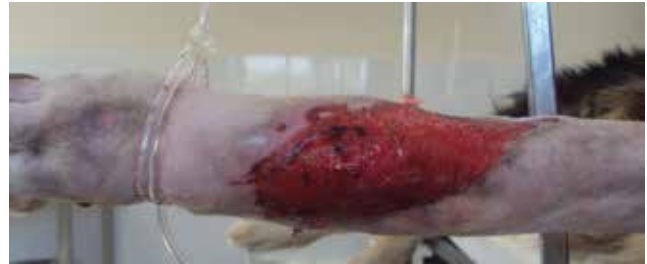

**Figure 4a.** Planning of a superficial brachial axial pattern flap.

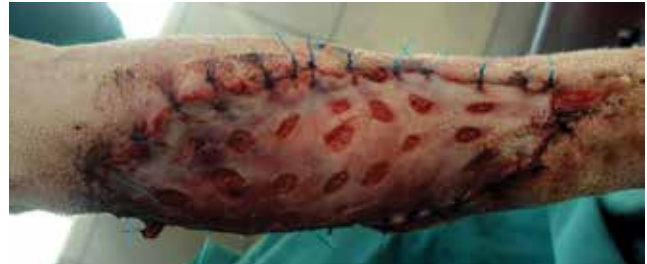

**Figure 4b.** Coverage of an antibrachial defect following tumour resection with a superficial brachial axial pattern flap.

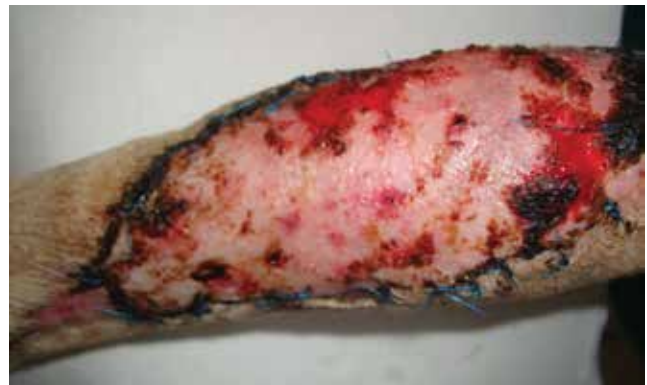5c). They have incisions-holes on their surface or they are completely cut by specialized instruments, so they allow drainage, are more expansible and make the graft-taking process easier (Pavletic, 2010; MacPhail, 2013). Unlike full thickness grafts split thickness grafts harvesting requires special instrumentation (dermatomes, expansion devices). The lateral thoracic or abdominal area is commonly used as donor sites. The recipient site must be well vascularized, free from infection, and covered by healthy granulation tissue (Swaim, 2003; MacPhail, 2013). Skin grafting requires strict aseptic technique, immobilization of the graft and minimal accumulation of fluids between the graft and the recipient bed (Pope, 1998; White,



**Figure 5a.** A large skin defect on the tarsus of a dog covered with healthy granulation tissue.



**Figure 5b.** A full-thickness meshed graft was used to cover the defect.



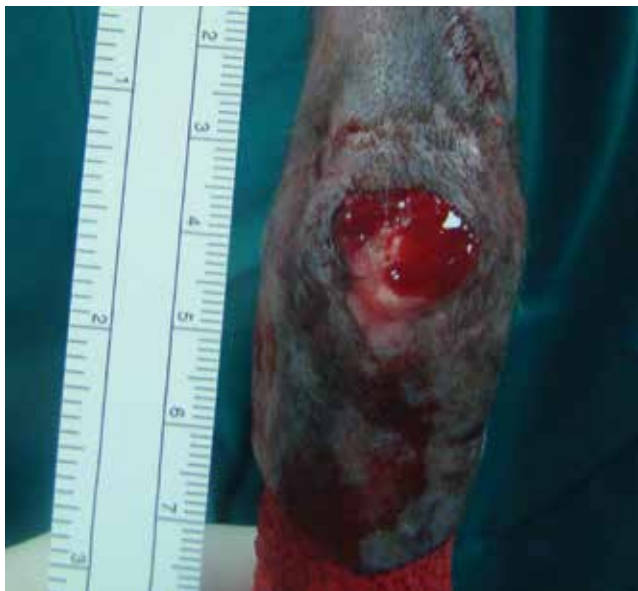**Figure 5c.** The skin graft 20 days postoperatively.

2009; Bohling and Swaim, 2012). Grafts are used in wounds on the extremities when other techniques (primary or secondary closure and flaps) are not feasible (Shahar and Shamir, 1999).

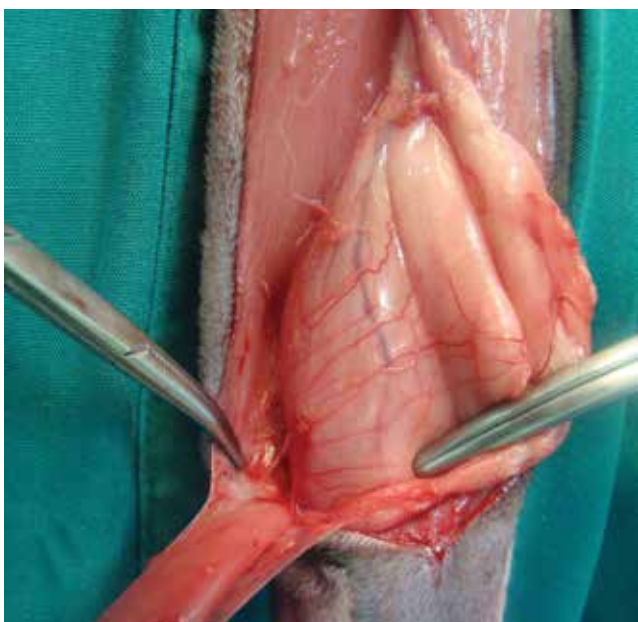
### *iii. Muscle and myocutaneous flaps*

Muscle flaps consist of a skeletal muscle while myocutaneous flaps consist of a skeletal muscle and the overlying skin (Baines, 2009; Wardlaw and Lanz, 2012; MacPhail, 2013). The latter are harvested simultaneously preserving their blood supply and innervation. Muscle and myocutaneous flaps are divided into five types according to their vascular patterns (Pavletic, 2010). Although, these flaps are

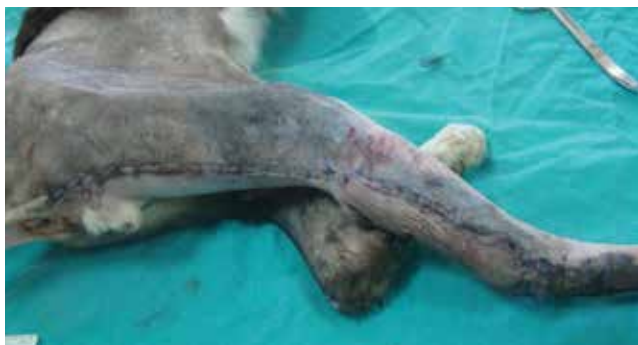



**Figure 6a.** A chronic non-healing wound on the hock of a cat.



**Figure 6b.** A semitendinosus myocutaneous flap was harvested to cover the wound.



**Figure 6c.** The surgical wound postoperatively.

popular in human medicine in small animal patients they are sparsely used as local flaps, axial pattern flaps and free grafts cover the demands for closure of various deficits (figures 6a, 6b and 6c). The advantages of treating large or complex distal limb defects with muscle and myocutaneous flaps are that they provide earlier wound repair, a lower rate of infection, coverage of exposed tissues including fractured bones and increased perfusion (Richards et al., 1987; Weinstein et al., 1988; 1989; Chambers et al., 1998; Chambers et al., 1990; Puerto and Aronso, 2004). Muscle and myocutaneous flaps with potential use on distal limb defects are presented in table 3.

#### *iv. Microvascular free tissue transfer*

Microvascular free tissue transfer is performed by microsurgery (Fowler et al., 1987; Fowler, 1998). These techniques allow one stage reconstruction by revascularization of the tissue through microvascular anastomosis of the main transplant's artery and vein to an artery and vein of the recipient site. Microvascular free flaps may include any tissue or combination of tissues (Philibert and Fowler, 1993). They permit one-stage reconstruction of challenging wounds of the distal limbs. However, training and skills, special equipment, prolonged operating times and high cost restricts their use (Fowler and Williams, 2009). In veterinary reconstructive surgery the success rate is reported to be 93%, which demonstrates that is a developing area with satisfactory results (Fowler et al., 1998).

### **CONCLUDING REMARKS**

Management of distal limb wounds is complicated by the paucity of local tissues, the presence of concurrent injuries and the compromised blood supply. Thus, small sized, superficial wounds with adequate skin can be closed primarily. In cases where primary closure is not applicable delayed primary closure, secondary closure or second intention healing alone or combined with tension relieving techniques can be undertaken. Conversely, large sized superficial wounds require reconstruction using subdermal plexus flaps or grafts. Large sized deep wounds with exposed musculoskeletal structures and reduced perfusion benefit from coverage with well vascularized tissues. Therefore, axial pattern flaps, muscle

or myocutaneous flaps or microvascular free tissue transfer are the techniques of choice for such cases.

### CONFLICT OF INTEREST STATEMENT

The authors declare that there is no conflict of interest of any author of this article.

### ACKNOWLEDGEMENTS

The authors wish to thank the undergraduate students of the Faculty of Veterinary Medicine, University of Thessaly, D. Katsaouni and V. Spiropoulou for the triggering for writing this paper.

**Table 3:** Muscle and myocutaneous flaps on limbs

Muscle/myocutaneous flap	Potential uses on limbs
Flexor carpi ulnaris muscle flap	Distal antebrachium, carpus, metacarpal defects
Ulnaris lateralis muscle flap	Proximally based: proximal-mid antebrachium defects Distally based: distal limb defects
Caudal sartorius muscle flap	Distal crus, tarsometatarsal defects
Rectus femoris muscle flap	Thigh, greater trochanter defects
Semitendinosus muscle/myocutaneous flap	Distally based: crus defects
Cranial border of the lateral head of the gastrocnemius muscle flap	Crus, stifle defects
Cranial tibial muscle flap	Mid-distal crus defects
Latissimus dorsi myocutaneous flap	Mid-antebrachium (depending on animal's conformation)

### REFERENCES

- Aper RL, Smeak D (2003) Complications and outcome after thoraco-dorsal axial pattern flap reconstruction of forelimb skin defects in 10 dogs (1989-2001). *Vet Surg* 32: 378-384.
- Aper RL, Smeak D (2005) Clinical evaluation of caudal superficial epigastric axial pattern flap reconstruction of skin defects in 10 dogs (1989-2001). *J Am Anim Hosp Assoc* 41: 185-192.
- Baines S (2009) Pedicled muscle flaps. In: BSAVA Manual of canine and feline wound management and reconstruction, 2nd ed, British Small Animal Veterinary Publications, Gloucester: pp 159-199.
- Beardsley SL, Schrader SC (1995) Treatment of dogs with wounds of the limbs caused by shearing forces: 98 cases (1975-1993). *J Am Vet Med Assoc* 207: 1071-75.
- Bohling MW, Swaim SF (2012) Skin Grafts. In: Tobias KM and Johnston SA, *Veterinary Surgery: Small Animal*, 1st ed, Elsevier, Missouri: pp 1271-1290.
- Brinkley CH (2007) Successful closure of feline axillary wounds by reconstruction of the elbow skin fold. *J of Small Anim Pract* 48: 111-115.
- Chambers JN, Purinton PT, Moore JL, Allen SW (1990) Treatment of trochanteric ulcers with cranial sartorius and rectus femoris muscle flaps. *Vet Surg* 19: 424-428.
- Chambers JN, Purinton PT, Allen SW, Schneider TA, Smith JD, (1998) Flexor carpi ulnaris (humeral head) muscle flap for reconstruction of distal forelimb injuries in two dogs. *Vet Surg* 27: 342-347.
- Cornell K, Salisbury K, Jakovljevic S, Bauer M, Petryk D (1995) Reverse saphenous conduit flap in cats: An anatomic study. *Vet Surg* 24: 202-206.
- Corr S (2009) Management of distal limb shearing injuries in cats. *J of Feline Med and Surg* 11: 747-757.
- Fahie MA (2012) Primary wound closure. In: Tobias KM and Johnston SA, *Veterinary Surgery: Small Animal*, 1st ed, Elsevier, Missouri: pp 1197-1209.
- Friend E (2009) Complications of wound healing. In: BSAVA Manual of canine and feline wound management and reconstruction, 2nd ed, British Small Animal Veterinary Publications, Gloucester: pp 254-270.
- Fowler JD, Miller CW, Bowen V, Johnston GH (1987) Transfer of free vascular cutaneous flaps by microvascular anastomosis results in six dogs. *Vet Surg* 16: 446-450.
- Fowler JD, Degner DA, Walshaw R, Walker D (1998) Microvascular free tissue transfer: results in 57 consecutive cases. *Vet Surg* 27: 406-412.
- Fowler JD (1998) Reconstructive microsurgical applications. In: Bojrab MJ, *Current techniques in Small Animal Surgery*, 4th ed, Williams & Wilkins, Baltimore: pp 607-622.
- Fowler D (2006) Distal limb and paw injuries. *Vet Clin of North Am: Small Anim Pract* 36: 819-845.
- Fowler D, Williams J (2009) Microsurgery. In: BSAVA Manual of canine and feline wound management and reconstruction, 2nd ed, British Small Animal Veterinary Publications, Gloucester: pp 200-222.
- Holt ED, Runge G (2011) Use of skin stretchers to elongate a peninsular thoracodorsal axial pattern flap for antebrachial wound closure in a dog. *Vet Surg* 40: 352-356.

- Hosgood G (2006) Stages of wound healing and their clinical relevance. *Vet Clin of North Am: Small Anim Pract* 36: 667-685.
- Hosgood G (2009) The biology of wound healing. In: BSAVA Manual of canine and feline wound management and reconstruction, 2nd ed, British Small Animal Veterinary Publications, Gloucester: pp 1-14.
- Hosgood G (2012) Open Wounds. In: Tobias KM and Johnston SA, *Veterinary Surgery: Small Animal*, 1st ed, Elsevier, Missouri: pp 1210-1220.
- Hunt GB (1995) Skin fold advancement flaps for closing large sternal and inguinal wounds in cats and dogs. *Vet Surg* 24: 172-175.
- Hunt GB, Tisdall PLC, Liptak JM, Beck JA, Swinney GR, Malik R (2001) Skin-Fold advancement flaps for closing large proximal limb and trunk defects in dogs and cats. *Vet Surg* 30: 440-448.
- Hunt G (2012) Local or subdermal plexus flaps. In: Tobias KM and Johnston SA, *Veterinary Surgery: Small Animal*, 1st ed, Elsevier, Missouri: pp 1243-1255.
- Keller WG, Aron DN, Rakich PM, Crowe DT, Marks MA (1994) Rapid tissue expansion for the development of rotational skin flaps in the distal portion of the hindlimb of dogs: an experimental study. *Vet Surg* 23: 31-39.
- Kostolich M, Pavletic MM (1987) Axial pattern flap based on the genicular branch of the saphenous artery in the dog. *Vet Surg* 16: 217-222.
- Lemarié RJ, Hosgood G, Read RA, Lewist DD, Bellaht JR, Salisbury SK, Goldsmid S (1995) Distant abdominal and thoracic pedicle skin flaps for treatment of distal limb skin defects. *J of Small Anim Pract* 36: 255-261.
- MacPhail CM (2013) Surgery of the integumentary system. In: Fossum TW, *Small Animal Surgery*, 4th edn, Mosby, St. Louis, Missouri: pp 190-288.
- Mayhew P (2009) Tension relieving techniques and local skin flaps. In: BSAVA Manual of canine and feline wound management and reconstruction, 2nd ed, British Small Animal Veterinary Publications, Gloucester: pp 69-99.
- Pavletic MM (1980) Vascular supply to the skin of the dog: a review. *Vet Surg* 9: 77-80.
- Pavletic MM (1980) Caudal superficial epigastric arterial pedicle grafts in the dog. *Vet Surg* 9: 103-107.
- Pavletic MM (2000) Use of an external skin-stretching device for wound closure in dogs and cats. *J Am Vet Med Assoc* 217: 350-354.
- Pavletic MM (2003) The integument. In: Slatter DH, *Textbook of small animal surgery*, 3rd ed, W.B. Saunders, Philadelphia: pp 250-259.
- Pavletic MM (2010) Atlas of small animal wound management and reconstructive surgery, 3rd ed, Wiley-Blackwell, Iowa.
- Philibert D, Fowler JD (1993) The trapezius osteomusculocutaneous flap in dogs. *Vet Surg* 22: 444-450.
- Pope ER (1998) Mesh skin grafting. In: Bojrab MJ, *Current techniques in Small Animal Surgery*, 4th ed, Williams & Wilkins, Baltimore: pp 603-607.
- Puerto DA, Aronson LR (2004) Use of a semitendinosus myocutaneous flap for soft tissue reconstruction of a grade IIIB open tibial fracture in a dog. *Vet Surg* 33: 629-635.
- Remedios AM, Bauer MS, Bowen CV (1989) Thoracodorsal and caudal superficial epigastric axial pattern skin flaps in cats. *Vet Surg* 18: 380-385.
- Richards RR, Orsini EC, Mahoney JL, Verschuren R (1987) The Influence of muscle flap coverage on the repair of devascularized tibial cortex. *Plast and Reconstr Surg* 79: 946-956.
- Shahar R, Shamir MH (1999) Free skin grafting for treatment of distal limb skin defects in cats. *J of Small Anim Pract* 40: 378-382.
- Shields Henney HL, Pavletic MM (1988) Axial pattern flap based on the superficial brachial artery in the dog. *Vet Surg* 17: 311-317.
- Stanley BJ (2012) Tension-Relieving techniques. In: Tobias KM and Johnston SA, *Veterinary Surgery: Small Animal*, 1st ed, Elsevier, Missouri: pp 1221-1242.
- Swaim SF (1990) Skin grafts. *Vet Clin of North Am: Small Animal Practice* 20: 147-175.
- Swaim SF (2003) Skin grafts. In: Slatter DH, *Textbook of small animal surgery*, 3rd ed, W.B. Saunders, Philadelphia: pp 321-338.
- Swaim SF (1997) Wound dressing materials and topical medications. In: Swaim SF and Henderson RA Jr, *Small animal wound management*, 2nd ed, Williams and Wilkins, Baltimore: pp 53-85, 143-190, 295-370.
- Swaim SF, Scardino S (1998) Paw and distal limb salvage and reconstructive techniques. In: Bojrab MJ, *Current techniques in Small Animal Surgery*, 4th ed, Williams & Wilkins, Baltimore: pp 625-639.
- Wardlaw LJ, Lanz IO (2012) Axial pattern and myocutaneous flaps. In: Tobias KM and Johnston SA, *Veterinary Surgery: Small Animal*, 1st ed, Elsevier, Missouri: pp 1256-1270.
- Weinstein JM, Pavletic MM, Boudrieau RJ (1988) Caudal sartorius muscle flap in the dog. *Vet Surg* 17: 203-210.
- Weinstein JM, Pavletic MM, Boudrieau RJ, Engler SJ (1989) Cranial sartorius muscle flap in the dog. *Vet Surg* 18: 286-291.
- White R (2009) Free skin grafting. In: BSAVA Manual of canine and feline wound management and reconstruction, 2nd ed, British Small Animal Veterinary Publications, Gloucester: pp 144-158.