

Journal of the Hellenic Veterinary Medical Society

Vol 67, No 1 (2016)



Ultrasonographic examination of the canine skin: a review

P. MANTIS (Π. ΜΑΝΤΗΣ), M. N. SARIDOMICHELAKIS (Μ.Ν. ΣΑΡΙΔΟΜΙΧΕΛΑΚΗΣ)

doi: [10.12681/jhvms.15619](https://doi.org/10.12681/jhvms.15619)

Copyright © 2018, P MANTIS, MN SARIDOMICHELAKIS



This work is licensed under a [Creative Commons Attribution-NonCommercial 4.0](https://creativecommons.org/licenses/by-nc/4.0/).

To cite this article:

MANTIS (Π. ΜΑΝΤΗΣ) P., & SARIDOMICHELAKIS (Μ.Ν. ΣΑΡΙΔΟΜΙΧΕΛΑΚΗΣ) M. N. (2018). Ultrasonographic examination of the canine skin: a review. *Journal of the Hellenic Veterinary Medical Society*, 67(1), 17-20. <https://doi.org/10.12681/jhvms.15619>

■ **Ultrasonographic examination of the canine skin: a review**

Mantis P.^{1,2}, Saridomichelakis M.N.²

¹*Department of Clinical Science and Services, Royal Veterinary College, Hawkshead Lane, North Mymms, Hatfield, Hertfordshire, AL9 7TA, UK*

²*Faculty of Veterinary Science, University of Thessaly, Trikalon Street 224, GR-43100, Karditsa, Greece*

■ **Υπερηχοτομογραφική Εξέταση του Δέρματος στο Σκύλο**

Μάντης Π.^{1,2}, Σαριδομιχελάκης Μ.Ν.¹

¹*Department of Clinical Science and Services, Royal Veterinary College, Hawkshead Lane, North Mymms, Hatfield, Hertfordshire, AL9 7TA, UK*

²*Τμήμα Κτηνιατρικής, Πανεπιστήμιο Θεσσαλίας, Τρικάλων 224, GR-43100, Καρδίτσα*

ABSTRACT. Real time B-mode ultrasonography is a non-invasive diagnostic imaging modality that does not use radiation and allows examination of various soft tissue structures. For many years it is used in human dermatology and in the last decade it has entered the canine dermatology arena. Based on the frequency employed, cutaneous ultrasonography may be classified as intermediate- (7-15 MHz) or high-frequency (20 MHz or higher). Using intermediate frequency, the ultrasonographic features of normal canine skin are consistent and three distinct visible layers can be seen. Using a 50 MHz transducer, the epidermis and hair follicles are also identified and accurate measurements of skin thickness can be obtained. The aim of this article is to review the available published knowledge regarding ultrasonographic examination of the canine skin.

Keywords: *Ultrasound, dog, skin, ultrasound biomicroscopy*

INTRODUCTION

The skin is the largest organ of the body. This organ has the capability to heal itself after wounding through sequential phases that include hemostasis, inflammation, proliferation and remodeling. Traditionally, the diagnosis of skin diseases is based on history taking, physical examination and various laboratory tests including histopathology of skin biopsies. Recent advances into ultrasonography have broadened the application of this diagnostic imaging modality to a large number of soft

tissue structures, including the skin. Ultrasonography is non-invasive and non-ionizing in nature and it allows visualization of these structures. For these abilities it lends itself as a useful tool for the evaluation of the skin that can be used to monitor the healing process and as an ancillary aid for diagnosis of skin diseases.

In comparison to other diagnostic modalities, ultrasonography has some advantages in the evaluation of the skin. Compared to histopathology, it allows good

Correspondence: Panagiotis Mantis,
Department of Clinical Science and Services, Royal Veterinary College, Hawkshead Lane, North Mymms, Hatfield, Hertfordshire AL9 7TA, UK.
E-mail: pmantis@rvc.ac.uk

Date of initial submission: 06.01.2015
Date of revised submission: 12.02.2015
Date of acceptance: 13.02.2015

discrimination of skin layers without the need for biopsy; however it does not allow visualization of inflammatory or neoplastic cells or a detailed characterization of their distribution pattern. Cutaneous ultrasonography is totally non-invasive as it does not require even the injection of contrast media into the skin. Clipping of the skin is necessary except when glabrous or alopecic areas of the skin are to be examined. The possibility to use various frequencies during the examination, allows the choice of optimal penetration and resolution depending on the depth of the tissue in question. In addition, ultrasonography uses portable equipment with the ability to perform the examination in the consultation room and quickly obtain valuable information regarding skin appearance, thickness and layer integrity. In contrast, magnetic resonance imaging and computed tomography have limited resolution for the discrimination between epidermis and dermis and low discrimination for cutaneous lesions that measure less than 3 mm (Wortsman and Wortman 2010; Wortsman and Jemec 2010). Dermoscopy is rarely used in veterinary medicine. It enables the clinician to perform direct microscopic examination of diagnostic features of the skin not seen by naked eye. In humans it is mainly used in pigmented lesions especially for the early detection of melanoma and has been proved more accurate than naked eye in suspicious skin lesions (Vestergaard et al. 2008). The aim of this article is to review the available published knowledge regarding ultrasonographic examination of the canine skin.

THE HISTORY

Cutaneous ultrasonography has been extensively used in human dermatology to study normal skin echogenicity, thickness and hydration status, as well as various pathologic conditions, including cutaneous or subcutaneous neoplasms, cysts, inflammatory lesions, post-radiation reactions, scleroderma, edema, wounds, and presence of foreign bodies (Alexander and Miller 1979; Miyauchi and Miki 1983; Fornage and Deshayes 1986; Fornage et al. 1993; Fornage 1993; Gniadecka 1996; Gniadecka and Quistorff 1996; Warszawski et al. 1997; Milner et al. 1997; Cammarota et al. 1998; Foster et al 2000; Eisenbeiss et al. 2001; Mirpuri et al. 2001; Dyson et al. 2003; Scope and Halpern 2003; Kong et al. 2008). Contrary to the situation in human medicine, in veterinary medicine only few studies on cutaneous ultrasonography of the canine skin are available (Diana et al. 2004; Mantis et al. 2005; Mantis et al. 2007; Diana et al. 2008; Zanna et al 2012; Mantis et al. 2014). The studies in veterinary medicine aimed at evaluating the application of high frequency ultrasound for the evaluation and

accurate measurement of the normal skin thickness in the dog (Diana et al. 2004, Zanna et al. 2012), the evaluation of wound healing in the dog (Mantis et al. 2005), the effect of an aliamide-containing topical gel on the reduction of wound volume (Mantis et al. 2007), and at evaluating the normal ultrasonographic appearance of the skin using ultrasound biomicroscopy (Mantis et al. 2014). These studies do not evaluate pathologic conditions, as it is the case with human studies.

TECHNICAL CONSIDERATIONS

Based on the frequency employed, cutaneous ultrasonography may be classified as intermediate- (7-15 MHz) or high-frequency (20 MHz or higher). (Scope and Halpern 2003) Although there are reports using lower frequency transducers, frequencies in excess of 15 MHz are generally recommended to get a better resolution and to identify the skin layers with higher clarity (Wortsman 2012). Ideally, frequencies of at least 50 MHz should be employed if the discrimination between epidermis and dermis is required (Mantis et al. 2014). Sedation is not normally required but it may be needed occasionally for an uncooperative dog. The skin should be shaved to improve contact between the transducer and the skin surface, thus providing a better image with reduced artifacts. Minimal pressure should be applied and transducer is placed perpendicularly to the skin.

NORMAL ANATOMY

The average thickness of the normal canine skin has been reported to range from 0.5 to 5 mm depending on body site, being higher dorsally than ventrally on the trunk and proximally than distally on the legs (Miller et al. 2013; Noli 2008). The skin of the forehead, dorsal neck, dorsal thorax, rump and tail base area is the thickest, whereas, skin of the ear pinnae, axillary, inguinal and perianal area is the thinnest (Miller et al. 2013). Thickness of the skin, excluding subcutis, is the sum of epidermal and dermal thickness. The former, if horny layer is not taken into account, ranges from 0.1 to 0.5 mm in haired skin but is substantially higher in footpads and nasal planum (up to 1.5 mm) (Noli 2008; Miller et al. 2013). Dermis, on the other hand, is the main determinant of normal canine haired skin thickness, which greatly depends on its fiber, ground substance and water content (Miller et al. 2013). Finally, it is reported that the thickness of the normal skin varies according to the breed and the age of the dog (Noli 2008; Miller et al. 2013). Besides epidermis and dermis, hair follicles and hair shafts are present in normal canine haired skin. Hair shafts reside within their follicles and transverse, usually obliquely, the epidermis and the dermis

(Noli 2008). Their diameter may range from 0.01 up to 0.14 mm depending on the type of hair (primary, intermediate or secondary) (Noli 2008). Epitricheal sweat glands and sebaceous glands are associated with the hair follicles and their ducts open into their lumen.

INTERMEDIATE FREQUENCY ULTRASONOGRAPHY

Using a 13 MHz linear array transducer, the ultrasonographic features of canine skin have a consistent appearance with 3 distinct layers visible (Figure 1). Initially, the interface between the coupling gel and the skin is visible as a hyperechoic line termed “epidermal entry echo”. The echogenicity of the epidermal entry echo depends on the amount of air trapped between the keratotic scales of the stratum corneum (Poziniak et al. 1989).

Immediately bellow this line, a hypoechoic, in comparison to the epidermal entry echo, layer is visible. This layer is thicker and corresponds to the epidermis and dermis. The axial resolution provided by a 13 MHz transducer, does not allow differentiation between the epidermis and dermis (Diana et al. 2004). This middle layer has variable achogenicity that probably depends on the various components of the dermis (e.g. collagenous fibers, dermal ground substance, water, and hair follicle adnexae like sebaceous glands) (Fornage and Deshayes 1986; Fornage et al. 1993; Szymanska et al. 2000).

A third deeper layer is also visible and has an inhomogeneous hypoechoic pattern with thick linear hyperechoic bands. This layer corresponds to subcutaneous fat. (Diana et al. 2004) Hair follicles, hair shaft and sebaceous glands are not visible using a 13 MHz frequency and a frequency above 20 MHz needs to be used in order to visualize these structures (Diana et al. 2004). It has been shown that scanning the canine skin with a 13 MHz transducer allows the evaluation of the hydration status of the skin (Diana et

al. 2008). Also, various studies (Diana et al. 2004; Zanna et al. 2012) have shown that there is high correlation between measurements of skin thickness with a 13 MHz transducer and histologic measurements, indicating that this frequency is adequate for measuring thickness of the canine skin.

HIGH FREQUENCY ULTRASONOGRAPHY

High frequency ultrasonography refers to the use of frequencies higher than 20 MHz. Today, commercially available scanners can provide frequencies up to 25 MHz; however they have a rather limited resolution of approximately 80 µm for axial and of 200 µm for lateral resolution (Schmid-Wendtner and Dill-Müller 2008). With such frequencies, skin structures up to 8 mm deep can be investigated (Hoffmann et al. 1992). In order to improve the resolution of the ultrasonographic images of the skin, higher frequency ultrasound machines have been developed for experimental use (El Gammal et al. 1999; Kumagai et al. 2012). They allow visualization of structures to a depth of 2mm bellow the skin surface.

For equipment that employs ultrasound frequencies between 50 and 100 MHz, the term ultrasound biomicroscopy (UB) is used. UB allows visualization of tissues at microscopic resolution. The technique is similar to real-time B-mode ultrasound examination but the main difference is that UB employs a moving transducer without covering membrane and uses a water bath technique.(El-Zawahry 2007).

Using a 50 MHz transducer, the epidermis is identified as a thin, slightly non-uniform, hyperechoic linear layer. Linear echogenicities, roughly parallel or at a slight angle to the skin surface, are visible within the dermis, while the hypoechoic to anechoic subcutaneous fat is visible bellow the dermis (Figure 2). The margin between epidermis and dermis is visible. Dermis appears

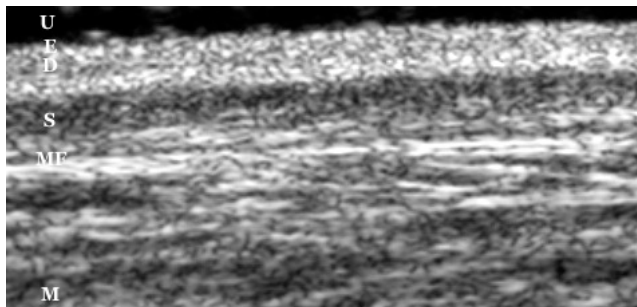


Figure 1: Ultrasonographic image of the skin of a normal dog from the center of the flank using 13 MHz frequency. The epidermal entry echo (E), epidermis and dermis (D) and subcutaneous fat (S) are visible. U= ultrasound gel; MF= muscle fascia; M= muscle

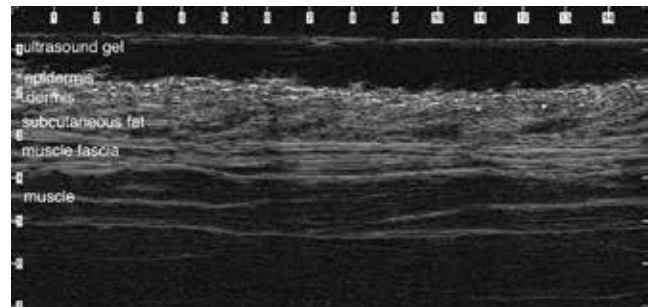


Figure 2: Ultrasonographic images of the skin of a normal dog corresponding to the dorsal thoracic area, over the upper palpable portion of the seventh rib using 50 MHz frequency. The epidermis, dermis and subcutaneous fat are clearly visible. The asterisks indicate hair follicles. The numbers indicate millimeters.

hypochoic to the epidermis and muscle fascia and hyperchoic to the subcutaneous layer. The superficial and deep dermis can be distinguished in some instances. The subcutaneous fat appears as an anechoic layer with sparse echogenicities. The hair follicles are visible as oblique, tubular hypoechoicities with faint echogenic linear areas at their margins. The ultrasonographic measurements performed with a 50 MHz transducer were almost identical to the histological measurements done in snap frozen skin biopsies (Mantis et al. 2014).

In conclusion, ultrasonography is applicable for the examination of the skin and it is safe and easy to use. The use of UB for the evaluation of canine skin has the potential to examine it at microscopic resolution and creates expectations for future clinical applications in canine dermatology. There are a limited number of studies describing ultrasonography of canine skin and more work, especially in various pathologic conditions, is needed before it can become a regular part of the daily clinical work-up.

REFERENCES

- Alexander H, Miller DL (1979) Determining skin thickness with pulsed ultra sound. *J Investig Dermatol* 72: 17-19.
- Cammarota T, Pinto F, Magliaro A, Sarno A (1998) Current uses of diagnostic high-frequency US in dermatology. *Eur J Radiol* 27 (Supplement 2): 215-223.
- Diana A, Preziosi R, Guglielmini C et al (2004) High-frequency ultrasonography of the skin of clinically normal dogs. *Am J Vet Res* 65: 1625-30.
- Diana A, Guglielmini C, Fracassi F et al (2008) Use of high-frequency ultrasonography for evaluation of skin thickness in relation to hydration status and fluid distribution at various cutaneous sites in dogs. *Am J Vet Res* 69: 1148-1152.
- Dyson M, Moodley S, Verjee L et al (2003) Wound healing assessment using 20 MHz ultrasound and photography. *Skin Res Technol* 9: 116-121.
- Eisenbeiss C, Welzel J, Eichler W, Klotz K (2001) Influence of body water distribution on skin thickness: measurements using high-frequency ultrasound. *Brit J Dermatol* 2001; 144: 947-951.
- El Gammal S, El Gammal C, Kaspar K, et al (1999) Sonography of the skin at 100 MHz enables in vivo visualization of stratum corneum and viable epidermis in palma skin and psoriatic plaques. *J Invest Dermatol* 113: 821-829.
- El-Zawahry MB, Abdel El-Hameed El-Cheweikh HM, et al. (2007) Ultrasound biomicroscopy in the diagnosis of skin diseases. *Eur J Dermatol* 17 (6): 469-75
- Fornage BD, Deshayes JL (1986) Ultrasound of normal skin. *J Clin Ultrasound* 14: 619-622.
- Fornage BD, McGavran MH, Duvic M, Waldron CA (1993) Imaging of the skin with 20-MHz US. *Radiology* 189: 69-76.
- Fornage BD (1993) Sonography of the skin and subcutaneous tissues. *La Radiologia Medica* 85 (Supplement 1): 149-155.
- Foster FS, Pavlin CJ, Harasiewicz KA et al (2000) Advances in ultrasound biomicroscopy. *Ultrasound Med Biol* 26: 1-27.
- Gniadecka M (1996) Localization of dermal edema in lipodermatosclerosis, lymphedema, and cardiac insufficiency. High-frequency ultrasound examination of intradermal echogenicity. *J Am Acad Dermatol* 35: 37-41.
- Gniadecka M, Quistorff B (1996) Assessment of dermal water by high-frequency ultrasound: comparative studies with nuclear magnetic resonance. *Brit J Dermatol* 135: 218-224.
- Hoffmann K, El Gammal S, Winkler K, et al (1992) Skin tumours in high frequency ultrasound. In (eds Altmeyer P, el Gammal S, Hoffmann K) *Ultrasound in Dermatology*, Springer-Verlag, Heidelberg, Germany, pp. 181-201
- Kong L, Caspall J, Duckworth M, Sprigle S (2008) Assessment of an ultrasonic dermal scanner for skin thickness measurements. *Med Eng Phys* 30: 804-807.
- Kumagai K, Koike H, Nagaoka R et al (2012) High-resolution ultrasound imaging of human skin in vivo by using three-dimensional ultrasound microscopy. *Ultrasound Med Biol*. 38(10):1833-1838.
- Mantis P, Lloyd DH, Pfeiffer D et al (2005) High-resolution ultrasonography of experimentally induced full-thickness canine skin wounds: Efficacy in imaging canine skin and comparison of 2 methods of measuring wound size. *Wounds* 17: 107-113.
- Mantis P, Lloyd DH, Pfeiffer D et al (2007) Assessment of the effect of an alamide-containing topical gel by evaluation of the reduction of wound volume measured by high resolution ultrasound biomicroscopy. *Wounds* 19 113-119.
- Mantis P, Tontis D, Church D et al (2014) High-frequency ultrasound biomicroscopy of the normal canine haired skin. *Vet Dermatol* 25: 176-e45.
- Milner SM, Memar OM, Gherardini G et al (1997) The histological interpretation of high frequency cutaneous ultrasound imaging. *Dermatol Surg* 23: 43-45.
- Miller WH, Griffin CE, Campbell KL (2013) Structure and function of the skin. In: (eds Mueller & Kirk's) *Small Animal Dermatology*, 7th edn. Elsevier Mosby, St. Louis, Missouri, pp. 1-56.
- Mirpuri NG, Dyson M, Rymer J et al (2001) High-frequency ultrasound imaging of the skin during normal and hypertensive pregnancies. *Skin Res Technol* 7: 65-69.
- Miyauchi S, Miki Y (1983) Normal human skin echogram. *Arch Dermatol Res* 275: 345-349.
- Noli C. (2008) Structure and physiology of skin and hair. In: (eds Guaguere E, Prelaud P, Craig M) *A Practical Guide to Canine Dermatology*, edn. Kallianxis, Italy, pp. 17-30.
- Poziniak MA, Crass JR, Zagzebsky J et al (1989) Clinical efficacy of Kitecko ultrasonic conductor. *Invest Radiol* 24:128-132.
- Schmid-Wendtner MH, Dill-Müller D (2008) Ultrasound Technology in Dermatology. *Semin Cutan Med Surg* 27:44-51
- Scope A, Halpern AC. Diagnostic procedures and devices (2003) In: (eds Wolff K, Goldsmith LA, Katz S, Gilchrist BA, Paller AS, Leffell DJ) *Fitzpatrick's Dermatology in General Medicine*, 7th edn McGraw Hill, New York, pp.40-43.
- Szymanska E, Nowicki A, Mlosek K et al (2000) Skin imaging with high frequency ultrasound—preliminary result. *Eur J Ultrasound* 12:9-16.
- Vestergaard ME, Macaskill P, Holt PE, Menzies SW (2008) Dermoscopy compared with naked eye examination for the diagnosis of primary melanoma: a meta-analysis of studies performed in a clinical setting. *Br J Dermatol* 159: 669-676.
- Warszawski A, Röttinger EM, Vogel R, Warszawski N (1997) 20 MHz ultrasonic imaging for quantitative assessment and documentation of early and late postradiation skin reactions in breast cancer patients. *Radiother Oncol* 47: 241-247.
- Wortsman X, Wortsman J (2010) Clinical usefulness of variable-frequency ultrasound in localized lesions of the skin. *J Am Acad Dermatol* 62:247-256.
- Wortsman X, Jemec G (2010) Common inflammatory diseases of the skin: from the skin to the screen. *Adv Psoriasis Inflammatory Skin Dis* 2:9-15.
- Wortsman X (2012) Common Applications of Dermatologic Sonography. *J Ultras Med* 31:97-111.
- Zanna G, Fondavila D, Ferrer L, Espada Y (2012) Evaluation of ultrasonography for measurement of skin thickness in Shar-Peis. *Am J Vet Res* 73:220-226.