

Journal of the Hellenic Veterinary Medical Society

Vol 66, No 4 (2015)



Bilateral rotation flaps for the closure of a wound at the tail base of a cat

J. SELTZA (Τ. ΣΕΛΤΣΑ), S. RABIDI (Σ. ΡΑΜΠΙΔΗ), E. ELEKIDOU (Ε. ΕΛΕΚΙΔΟΥ), C. DIDANGELOU (Χ. ΔΙΔΑΓΓΕΛΟΥ), L. G. PAPAZOGLU (Λ.Γ. ΠΑΠΑΖΟΓΛΟΥ)

doi: [10.12681/jhvms.15864](https://doi.org/10.12681/jhvms.15864)

Copyright © 2018, J SELTZA, S RABIDI, E ELEKIDOU, C DIDANGELOU, LG PAPAZOGLU



This work is licensed under a [Creative Commons Attribution-NonCommercial 4.0](https://creativecommons.org/licenses/by-nc/4.0/).

To cite this article:

SELTZA (Τ. ΣΕΛΤΣΑ) J., RABIDI (Σ. ΡΑΜΠΙΔΗ) S., ELEKIDOU (Ε. ΕΛΕΚΙΔΟΥ) E., DIDANGELOU (Χ. ΔΙΔΑΓΓΕΛΟΥ) C., & PAPAZOGLU (Λ.Γ. ΠΑΠΑΖΟΓΛΟΥ) L. G. (2018). Bilateral rotation flaps for the closure of a wound at the tail base of a cat. *Journal of the Hellenic Veterinary Medical Society*, 66(4), 211–214. <https://doi.org/10.12681/jhvms.15864>

Bilateral rotation flaps for the closure of a wound at the tail base of a cat

Seltza J.¹, Rabidi S.¹, Elekidou E.¹, Didangelou C.¹, Papazoglou L.G.²

¹ DVM, ² DVM, PhD, MRCVS Professor Small Animal Surgery

Department of Clinical Sciences, Faculty of Veterinary Medicine, School of Health Sciences,
Aristotle University of Thessaloniki

Κάλυψη δερματικού ελλείμματος της βάσης της ουράς σε γάτα με αμφοτερόπλευρο περιστροφικό κρημνό

Σέλτσα Τ.¹, Ραμπίδη Σ.¹, Ελεκίδου Ε.¹, Διδαγγέλου Χ.¹, Παπάζογλου Λ.Γ.²

¹ Κτηνίατρος DVM, ² Καθηγητής Χειρουργικής, Τμήμα Κτηνιατρικής Α.Π.Θ

ABSTRACT. A 2, 5 - year-old DSH female spayed cat was presented with a history of a tail base wound resulted from an abscess inflicted in a cat fight. The wound was managed initially as an open wound for 3 days and was covered with a bilateral rotation flap. One year after surgery the cat was reported to be in good health and the wound healed uneventfully.

Keywords: cat, wound, bite injury, rotation flap, tail base

ΠΕΡΙΛΗΨΗ. Γάτα ηλικίας 2,5 ετών προσκομίστηκε με ιστορικό τραύματος στη βάση της ουράς ως αποτέλεσμα αποστήματος από διαμάχη με άλλες γάτες. Το τραύμα αντιμετωπίστηκε ως ανοικτό για 3 ημέρες μετά την προσκόμιση και ακολούθως καλύφθηκε με αμφοτερόπλευρο περιστρεφόμενο δερματικό κρημνό. Ένα χρόνο μετά την επέμβαση η γάτα είναι υγιής και το τραύμα έχει επουλωθεί χωρίς επιπλοκές.

Λέξεις κλειδιά: γάτα, τραύμα, δήγμα, περιστρεφόμενος κρημνός, βάση ουράς

INTRODUCTION

Cat bite wounds are commonly encountered in clinical practice. Tail base is one of the usual locations subjected to injury following a cat fight (Malik et al., 2006). Many of these wounds may develop “cat bite” abscesses in this region and sometimes large wounds may result from these abscesses (Pope and

Swaim, 1986, Anderson and Langley-Hobbs, 2014). These wounds should better undergo a delayed primary healing procedure to allow for infection resolution, debridement and granulation tissue formation; second intention healing may also be an option (Pope, 1986, Anderson and Langley-Hobbs, 2014). Primary closure of large tail base wounds by skin undermining and apposition may not be possible because of the

Correspondence: Lysimachos Papazoglou,
11 Voutyra Street 54627 Thessaloniki, Greece
e-mail: makdvm@vet.auth.gr

Υπεύθυνος αλληλογραφίας: Γ. Παπάζογλου
Βουτυρά 11, 54627 Θεσσαλονίκη
e-mail: makdvm@vet.auth.gr

Date of initial submission: 03.07.2014
Date of acceptance: 07.08.2014

insufficient loose skin present in this particular region (Bellah, 2006). Options available for surgical reconstruction of large tail base wounds in cats include application of subdermal plexus flaps, axial pattern flaps or meshed grafts (Pope and Swaim, 1986, Bellah, 2006, Anderson and Langley-Hobbs, 2014). Only one case of a cat with a tail base wound treated with a bilateral rotation flap has been briefly reported in the literature (Pope and Swaim, 1986). The aim of the present report is to describe the technique and long term outcome of a bilateral rotation flap to close a large tail base wound in a cat.

CASE DESCRIPTION

A 2, 5 - year- old DSH female spayed cat weighing 4 kg was presented with a history of a tail base wound as a result of an abscess that was received in a cat fight three days before presentation. The cat was in good clinical condition and had a tail base rectangular wound measured 5 x4 cm. No other abnormalities were detected. Open wound management consisted of flushing with normal saline, application of non adherent sterile dressings twice daily and administration of amoxicillin- clavulanate 12 mg/kg bid and meloxicam 0,05 mg/kg sid for three days was performed.

Physical examination on day 3 revealed that the wound was covered with healthy granulation tissue. Wound manipulation showed that no sufficient loose skin was available to allow for centripetal closure. On day 4 a bilateral rotation flap was decided to enable wound closure.

Anesthesia was induced with propofol and maintained with isoflurane in oxygen. Cephazoline at a dose of 30 mg/kg intravenously was administered at anesthetic induction. Pethidine at a dose of 3 mg/kg intramuscularly was also given. The cat was placed in ventral recumbency and the lumbosacral region and tail base were clipped and prepared for surgery. A sterile skin marker was used to outline the proposed skin incisions. A curving skin incision was made commencing from the one corner of the rectangular wound and extending beyond the base of the rectangle so as the length of the flap to be approximately four times the width of the wound (Swaim and Henderson, 1997). The flap was undermined below the panniculus

muscle taking care to preserve cutaneous vasculature and the edge of the flap was rotated to cover half of the wound. The other half was closed by a flap elevated from the other end of the wound. The flaps were sutured together in the midline and to the skin of the tail with simple interrupted 3/0 poliglecaprone 25 suture material placed subcutaneously. Two other continuous sutures were placed subcutaneously between the wound sides and the flaps. The skin was closed with continuous 3/0 polyamide suture to complete the closure. No drain was placed. The cat made an uneventful recovery from anesthesia and discharged from the hospital 2 days after surgery. An Elizabethan collar was placed and postoperative

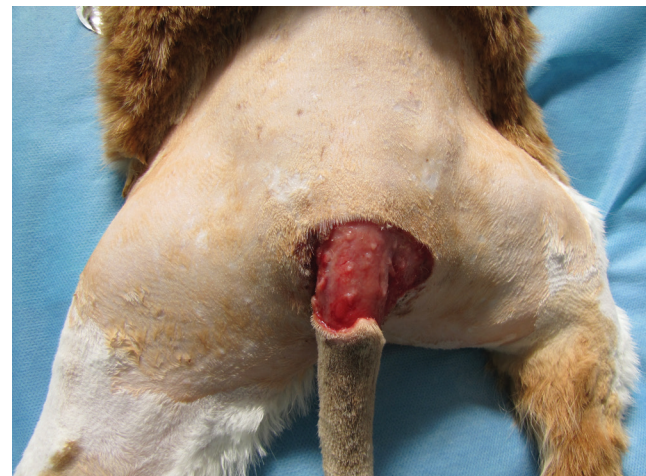

Figure 1. A rectangular wound measured 5 x4 cm at the base of the tail of a 2,5 year old DSH cat.

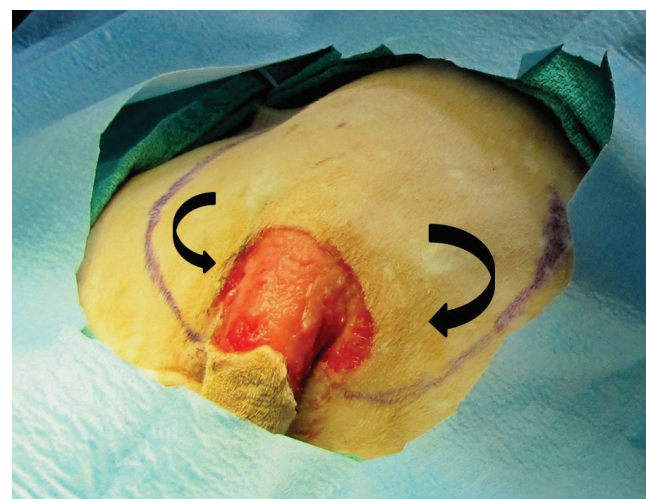


Figure 2. The proposed curving skin incisions were drawn in the skin of a 2,5 year old DSH cat using a sterile marker (arrows). The length of the two incisions was approximately four times the width of the wound.

analgesia was provided by oral meloxicam (0,05 mg/kg) for 3 days. Twelve days after surgery the cat was represented for suture removal. Physical examination revealed that the wound healed uneventfully. One year after surgery the cat was found to be in good health.

DISCUSSION

Large skin wounds at the tail base of the cat present special challenges to the surgeon. Healing by second intention may be an option for bite wounds in cats. In this particular case the size and location of the wound that made long-term bandaging and frequent bandage changes problematic, the high cost of the bandaging material, the poor cosmetic appearance of the healed wound and the slower wound healing that is described in cats in contrast to dogs made this option less appealing (Bohling et al., 2004, Bellah, 2006).

Square or rectangular skin wounds may be initially manipulated at the edges and sides to make sure that a centripetal closure is possible (Swaim and Henderson, 1997). In the case reported here centripetal closure of the wound was not possible due to the lack of loose skin and increased tension at the 4 edges of the wound.

Axial pattern flaps are pedicle flaps that incorporate a direct cutaneous artery and vein. The caudal superficial epigastric flap may be considered to cover tail base wound in cats; creation of a long epigastric flap with less distance needed to cover the tail base wound would be an option in our case (Remedios et al., 1989, Bellah, 2006). However, the extensive dissection of the donor side and the difference in cosmetic appearance of the recipient versus donor sides made this technique less desirable to close the wound in our case (Nelissen and White, 2014). Free

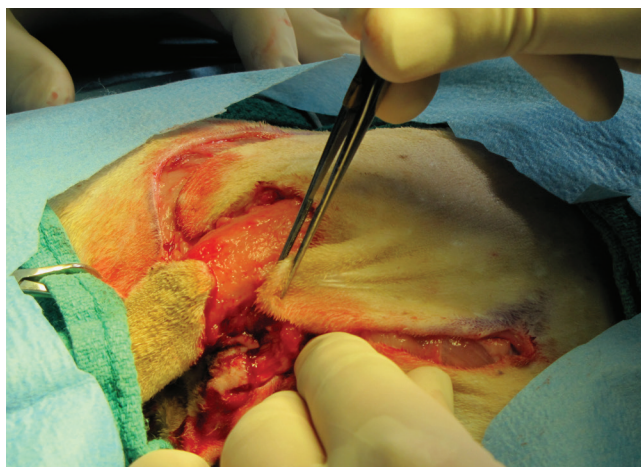

Figure 3. The two flaps were elevated and mobilized to cover the wound of the cat of figure 1.

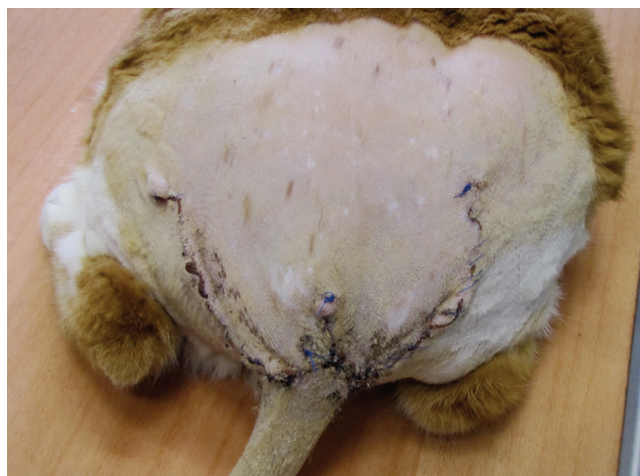

Figure 4. The wound of the cat of figure 1 twelve days after surgery at suture removal.

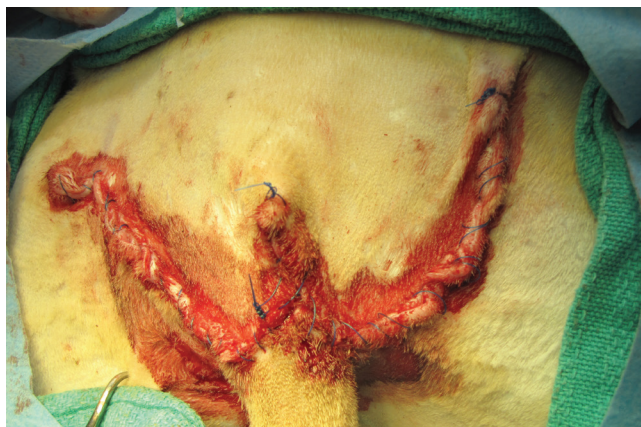

Figure 4. The wound of the cat of figure 1 was closed with continuous polyamide sutures



Figure 4. The lumbosacral and tail region of the cat of figure 1 12 months after surgery.

full thickness skin grafts have been used in covering limb defects in cats with very favorable results and could be considered for coverage tail base wounds (Shahar et al., 1999, Bellah, 2006). This technique requires long term hospitalization and bandaging, its proximity with the anus increases the likelihood of graft contamination and the cosmetic appearance of the graft is not as good as that of the flap and thus offered no advantage over the technique described in the present study.

Subdermal plexus flaps receive their blood supply from the terminal branches of direct cutaneous arteries but their survival is less consistent than axial pattern flaps (Pavletic, 2010, Nelissen and White, 2014). Rotation flaps are flaps that designed to rotate in a pivot point into the wound to be closed (Pavletic, 2010). Bilateral rotation flaps can be employed to close rectangular or square skin wounds that have loose and elastic skin available on 2 sides only and are not amenable for closure with other methods (Dixon, 1963, Twaddle, 1969, Stanley et al., 1991, Swaim and Henderson, 1997). Bilateral rotation flaps are take advantage of the loose redundant skin of the cat but

their use in this species is limited since large areas of skin should be recruited to cover the defect (Swaim and Henderson, 1997, Nelissen and White, 2014). A very short report of the technique to cover a tail base wound in a cat has been published; however, no detailed description of the technique and long term follow-up was provided (Pope and Swaim, 1986). In our case a bilateral rotation flap was elected for closure of a large tail base wound because the wound was not amenable for closure with other techniques; recruitment of sufficient skin was only achieved by bilateral incisions since the use of only one flap was not allowed to cover the whole wound (Swaim and Henderson, 1997). Bilateral rotation flaps may be the technique of choice for the closure of wounds located in the lumbosacral or tail base region. Bilateral rotation flap technique requires two rotation flaps that disseminate tension on two sides of the wound compared to one side of the unilateral rotation flap (Pope and Swaim, 1986, Swaim and Henderson, 1997). This technique was easy and simple to perform, with minimal hospitalization and postoperative care and with excellent cosmetic results.

REFERENCES

- Anderson DM, Langley-Hobbs SJ (2014) Wounds and wound management. In: *Feline Soft Tissue and General Surgery*. Langley-Hobbs SJ, Demetriou JL, Landlow JF (eds). Saunders Elsevier: Edinburgh, pp. 177-194.
- Bellah JR (2006) Tail and perineal wounds. *Vet Clin Small Anim Pract* 36: 913-929.
- Bohling MW, Henderson RA, Swaim SF, Kincaid SA, Wright JC (2004) Cutaneous wound healing in the cat: a macroscopic description and comparison with cutaneous wound healing in the dog. *Vet Surg* 33: 579-587.
- Dixon AC (1963) The secondary closure of wounds. *Vet Rec* 75: 1133-1142.
- Malik R, Norris J, White J, Jantulik B (2006) Wound cat. *J Feline Med Surg* 8: 135-140.
- Nelissen P, White D (2014) Flaps and grafts. In: *Feline Soft Tissue and General Surgery*. Langley-Hobbs SJ, Demetriou JL, Landlow JF (eds). Saunders Elsevier: Edinburgh, pp. 195-207.
- Pavletic MM (2010) Local flaps. In: *Atlas of Small Animal Wound Management and Reconstructive Surgery*. Pavletic MM (ed). 3rd edn. Wiley-Blackwell: Ames, pp. 307-335.
- Pope ER (1986) The important first steps: initial management of feline wounds. *Vet Med* 81: 504-505.
- Pope ER, Swaim SF (1986) Shifting tissue and using flaps. *Vet Med* 81: 512-522.
- Remedios AM, Bauer MS, Bowen CV (1989) Thoracodorsal and caudal superficial epigastric axial pattern skin flaps in cats. *Vet Surg* 18: 380-385.
- Shahar R., Shamir MH, Brehm DM, Johnston DE (1999) Free skin grafting for treatment of distal limb skin defects in cats. *J Small Anim Pract* 40: 378-382.
- Stanley BJ, Read RA, Eger CE, Shaw SE (1991) Bilateral rotation flaps for the treatment of chronic nasal dermatitis in four dogs. *J Am Anim Hosp Assoc* 27: 295-299.
- Swaim SF, Henderson RA (1997) Various shaped wounds. In: *Small Animal Wound Management*. Swaim SF, Henderson RA (eds). 2nd edn. Williams and Wilkins: Baltimore, pp. 235-274.
- Twaddle AA (1969) Rotational flap skin graft. *New Zealand Vet J* 17: 178-179.