

Περιοδικό της Ελληνικής Κτηνιατρικής Εταιρείας

Τόμ. 69, Αρ. 4 (2018)



The effect of intrastromal PRP and oral doxycycline in corneal wound healing after alkali burn

Glykeria Charalambidou, Evangelia Kofidou, Nikolaos Papaioannou, Vasileios Karampatakis, Anastasia Komnenou

doi: [10.12681/jhvms.16119](https://doi.org/10.12681/jhvms.16119)

Copyright © 2019, Glykeria Charalambidou, Evangelia Kofidou, Nikolaos Papaioannou, Vasileios Karampatakis, Anastasia Komnenou



Άδεια χρήσης [Creative Commons Αναφορά-Μη Εμπορική Χρήση 4.0](https://creativecommons.org/licenses/by-nc/4.0/).

Βιβλιογραφική αναφορά:

Charalambidou, G., Kofidou, E., Papaioannou, N., Karampatakis, V., & Komnenou, A. (2019). The effect of intrastromal PRP and oral doxycycline in corneal wound healing after alkali burn. *Περιοδικό της Ελληνικής Κτηνιατρικής Εταιρείας*, 69(4), 1213–1226. <https://doi.org/10.12681/jhvms.16119>

The effect of intrastromal PRP and oral doxycycline in corneal wound healing after alkali burn

G. Charalambidou¹, E. Kofidou², N. Papaioannou³, V. Karampatakis⁴, A. Komnenou⁵

¹*Clinic of Companion Animals, School of Veterinary Medicine, Faculty of Health Sciences, Aristotle University of Thessaloniki, Greece*

²*School of Veterinary Medicine, Faculty of Health Sciences, Aristotle University of Thessaloniki, Greece*

³*School of Veterinary Medicine, Faculty of Health Sciences, Aristotle University of Thessaloniki, Greece*

⁴*Laboratory of Experimental Ophthalmology, School of Medicine, Faculty of Health Sciences, Aristotle University of Thessaloniki, Greece*

⁵*Comparative Ophthalmology Unit, Clinic of Companion Animals, School of Veterinary Medicine, Faculty of Health Sciences, Aristotle University of Thessaloniki, Greece*

Γ. Χαραλαμπίδου¹, Ε. Κωφίδου², Ν. Παπαϊωάννου³, Β. Καραμπατάκης⁴, Α. Κομνηνού¹

¹*Τμήμα Οφθαλμολογίας, Κλινική Ζώων Συντροφιάς, Τμήμα Κτηνιατρικής, Σχολή Επιστημών Υγείας, Αριστοτέλειο Πανεπιστήμιο Θεσσαλονίκης*

²*Τμήμα Κτηνιατρικής, Σχολή Επιστημών Υγείας, Αριστοτέλειο Πανεπιστήμιο Θεσσαλονίκης*

³*Εργαστήριο Παθολογικής Ανατομικής, Τμήμα Κτηνιατρικής, Σχολή Επιστημών Υγείας, Αριστοτέλειο Πανεπιστήμιο Θεσσαλονίκης*

⁴*Εργαστήριο Πειραματικής Οφθαλμολογίας, Τμήμα Ιατρικής, Σχολή Επιστημών Υγείας, Αριστοτέλειο Πανεπιστήμιο Θεσσαλονίκης*

Corresponding Author:

Charalambidou Glykeria

Postal address: 11 Stavrou Voutira Street, 54627, Thessaloniki, Greece

Email: glykcharala@hotmail.com

Date of initial submission: 2-4-2019

Date of revised submission: 3-6-2018

Date of acceptance: 2-7-2018

ABSTRACT. Ocular chemical burns are among the most critical and true ocular emergencies in dogs and cats, with destructive consequences on the ocular surface and intraocular tissues. Platelet alpha granules are an important reservoir of growth factors that can stimulate chemotaxis of inflammatory cells, mitosis, migration and differentiation of cells. On the other hand, tetracyclines and their derivatives exhibit non-antimicrobial properties, such as affecting inflammation, immunomodulation, cell proliferation and angiogenesis. The objective of this study is to investigate the effect of intrastromal platelet rich plasma (PRP) in combination with oral doxycycline in the healing process of the cornea. Thirty six New Zealand rabbits were used in this experimental study. Alkali burns were created by applying a round filter paper soaked in NaOH. PRP was prepared by centrifugation of autologous blood. The rabbits were allocated to four groups (9 animals each). Group 1 served as the control group without any treatment. Group 2 received doxycycline (5 mg/kg b.w.) orally once a day throughout the study. Group 3 received an intrastromal injection of PRP (0.5 ml) in the cornea, and group 4 received intrastromal PRP combined with oral doxycycline. Treatments had varied levels of success, with PRP combined with oral doxycycline producing the best results regarding corneal healing. Animals in the control group had epithelial defects for the whole duration of the study, and 3 animals presented corneal perforation. Groups 3 and 4 had smaller mean defect area, compared to groups 1 and 2. On the 7th day, neovascularisation was lower in treatment groups compared to the control group. Groups 3 and 4 also had less corneal oedema compared to the control group on day 3 and 7. Group 4 exhibited the best wound healing, with less neovascularization and better collagen arrangement, as shown by the histopathological evaluation. To the authors' knowledge this is the first experimental study that intrastromal PRP is combined with oral doxycycline for the management of corneal chemical burns. This combination is a simple, safe and economical therapeutic approach that promotes corneal healing.

Keywords: Platelet rich plasma, PRP, doxycycline, corneal alkali burn, cornea

ΠΕΡΙΛΗΨΗ. Τα χημικά εγκαύματα του κερατοειδούς συγκαταλέγονται ανάμεσα στα πιο σοβαρά επείγοντα οφθαλμολογικά περιστατικά, ενώ συχνά έχουν καταστροφικά αποτελέσματα για την όραση και τον βολβό. Στα α-κοκκία των αιμοπεταλίων υπάρχουν μεγάλες ποσότητες αυξητικών παραγόντων, που ελέγχουν τη χημειοταξία των φλεγμονωδών κυττάρων, τη μίτωση, τη μετανάστευση και τη διαφοροποίηση των κυττάρων. Επιπλέον, οι τετρακυκλίνες και τα παράγωγά τους επηρεάζουν τη φλεγμονή, την ανοσορύθμιση, τον κυτταρικό πολλαπλασιασμό και την αγγειογένεση. Στην παρούσα μελέτη διερευνήθηκε πειραματικά η επίδραση του εμπλουτισμένου σε αιμοπετάλια πλάσματος (PRP) χορηγούμενου ενδοστρωματικά, σε συνδυασμό με συστηματικά χορηγούμενη δοξυκυκλίνη σε χημικά εγκαύματα κερατοειδούς σε κόνικλους. Χρησιμοποιήθηκαν συνολικά 36 κόνικλοι Νέας Ζηλανδίας. Σε όλα τα πειραματόζωα προκλήθηκε χημικό έγκαυμα με την εφαρμογή διηθητικού χαρτιού διαμέτρου 6 mm εμποτισμένο με NaOH στο κέντρο του κερατοειδούς. Η παρασκευή του PRP έγινε μετά από φυγοκέντρηση αυτόλογου αίματος. Τα πειραματόζωα χωρίστηκαν σε 4 ομάδες των 9 ζώων. Στην ομάδα 1, η οποία αποτελούσε την ομάδα ελέγχου, δεν δόθηκε καμία φαρμακευτική αγωγή. Στη ομάδα 2 χορηγήθηκε δοξυκυκλίνη στη δόση των 5 mg/kg, ημερησίως από το στόμα. Στη ομάδα 3 έγινε ενδοστρωματική έγχυση 0,5 ml PRP και στην ομάδα 4 έγινε ενδοστρωματική έγχυση PRP και παράλληλα χορηγήθηκε δοξυκυκλίνη (5 mg/kg). Οι ομάδες που έλαβαν θεραπευτική αγωγή παρουσίασαν βελτίωση σε μερικές από τις παραμέτρους που ελέγχθηκαν, ενώ η ομάδα που έλαβε συνδυασμό PRP και δοξυκυκλίνης είχε την καλύτερη εξέλιξη στην επούλωση του κερατοειδούς. Συγκεκριμένα, τα πειραματόζωα που ανήκαν στην ομάδα ελέγχου είχαν ελλείμματα στον κερατοειδή σε όλη τη διάρκεια του πειραματισμού και σε 3 από αυτά παρατηρήθηκε διάτρηση του κερατοειδούς. Οι ομάδες 3 και 4 παρουσίασαν ελλείμματα κερατοειδούς με μικρότερη έκταση σε σχέση με τις ομάδες 1 και 2. Την 7η μέρα μετά την πρόκληση του χημικού εγκαύματος, η νεοαγγείωση ήταν μικρότερης έκτασης στις ομάδες που έλαβαν θεραπευτική αγωγή συγκριτικά με την ομάδα ελέγχου. Στις ομάδες 3 και 4 παρατηρήθηκε λιγότερο οίδημα του κερατοειδούς σε σχέση με την ομάδα ελέγχου την 3η και 7η μέρα. Στην ομάδα 4, σύμφωνα με τα ευρήματα της ιστοπαθολογικής εξέτασης, παρατηρήθηκε καλύτερη επούλωση του κερατοειδούς, με μικρότερης

έκτασης νεοαγγείωση και καλύτερη διάταξη των ινών του κολλαγόνου. Η παρούσα εργασία αποτελεί την πρώτη πειραματική μελέτη της ενδοστρωματικής χορήγησης PRP σε συνδυασμό με συστηματικά χορηγούμενη δοξυκυκλίνη για την αντιμετώπιση ενός χημικού εγκαύματος κερατοειδούς. Ο συνδυασμός αυτός αποτελεί μία απλή, ασφαλή και αποτελεσματική θεραπευτική προσέγγιση, που προάγει την επούλωση του κερατοειδούς.

Keywords: Πλάσμα εμπλουτισμένο σε αιμοπετάλια, PRP, δοξυκυκλίνη, αλκαλικό έγκαυμα κερατοειδούς, κερατοειδής

INTRODUCTION

Ocular chemical burns represent potentially blinding ophthalmic injuries in humans (Dua et al., 2001), and could be among the most critical and true ocular emergencies in dogs (Christmas, 1991) and cats (Şenel and Ergİn, 2014). Alkali burns, that can be caused by ammonia, lye or potassium hydroxide (McCulley, 1987), are more common than acid ones since alkalis are components of commonly used cleaning products and civic construction materials (Wagoner, 1997; Williams et al., 2002; Busse et al., 2014), with soaps being the most common source in dogs and cats (Christmas, 1991).

Alkali agents can cause severe damage to the eye, as they have both hydrophilic and lipophilic properties, allowing them to quickly penetrate the cell membranes and enter the anterior chamber (Dua et al., 2001). The damage to the cornea is related to pH change, ulceration, proteolyses and collagen synthesis defects. Alkalis are deposited within the ocular surface and can cause saponification reaction. Besides, the damaged tissue secretes proteolytic enzymes as part of an inflammatory response, which leads to further damage (Singh et al., 2013). Moreover, the production of free radicals has been implicated in the pathogenesis of an alkali burn cornea damage and the cornea becomes more susceptible to the harmful effects of reactive oxygen radicals (Gunay et al., 2015).

After an ocular chemical burn, in dogs, the presenting signs include blepharospasm, conjunctival hyperaemia, chemosis and conjunctival ischemia in injured areas (Busse et al., 2014). Other symptoms include tear film deficiency, corneal neovascularization, ulceration and uveitis (Christmas, 1991). Limbal stem cell deficiency is also noticed, if the damage of the corneal and conjunctival epithelium involves the limbus. The loss of goblet cells and inflammation of conjunctiva can result in tear film inadequacy. In

addition, if the alkaline material penetrates the anterior chamber, the result may be cataract formation, and damage of the ciliary body and the trabecular meshwork (Singh et al., 2013). In general, chemical injuries of the cornea are followed by four phases: immediate, acute, early reparative and late reparative (McCulley, 1987). Limbus loss, inflammation and neovascularization take place during the acute phase and the clarity of the cornea is compromised by the slow epithelialisation, the persistent ulceration, corneal perforation and neovascularization (Kuo, 2004). In this phase, anti-inflammatory and anti-angiogenic treatments, as well as treatments that promote corneal healing are proposed (Bakunowicz-łazarczyk and Urban, 2016).

Various medical means such as sodium hyaluronate 1% (Chung et al., 1996), autologous serum (Salman and Gundogdu, 2010; Gunay et al., 2015), mesenchymal stem cells (Almaliotis et al., 2015), amniotic membrane therapy (Fish and Davidson, 2010), and platelet rich plasma (PRP) (Márquez-de-Aracena et al., 2007; Khaksar et al., 2013) have been proposed for the promotion of the biological healing process after a chemical burn. Furthermore, several collagenase inhibitors have been studied for the management of chemical burns, such as acetylcysteine (Khaksar et al., 2013), EDTA, synthetic peptides, tetracyclines, sodium citrate, cysteine (Burns et al., 1989), aprotinin (Stuart et al., 1989), ascorbic acid (Levinson et al., 1976) and citric acid (Pfister et al., 1988). Also a variety of anti-angiogenic agents have been recommended for the prevention of corneal neovascularization including steroids (Crum et al., 1985), angiostatin (Ambati et al., 2002), methotrexate (Joussen et al., 1999) and ascorbic acid (Peyman et al., 2007).

Healing of the cornea after a trauma is a complex biological process, in which growth factors play a critical role (Schultz et al., 1992). Corneal wound healing is a unique process due to the fact that cornea

is an avascular tissue. Stimulation and regulation of healing rely on growth factors which can reach the cornea through the tears, aqueous humor and the limbic vessels (Swank and Hosgood, 1996). Platelet alpha granules are an important reservoir of proteins and growth factors such as platelet-derived growth factor (PDGF), transforming growth factor- α (TGF- α), transforming growth factor- β (TGF- β), epidermal growth factor (EGF), insulin growth factor (IGF), fibroblast growth factor 2 (FGF-2), and vascular endothelial growth factor (VEGF). Growth factors can stimulate chemotaxis of inflammatory cells, mitosis, migration and differentiation of cells, angiogenesis, and the production and regulation of other growth factors (Nurden, 2011). Platelets can release growth factors upon activation (Borzini and Mazzucco, 2005) and it has been demonstrated that a great amount of growth and wound healing factors can be stored as concentrated in PRP. It has been found that nonactivated PRP to whole blood ratio is 4.6 for EGF and 1.9 for IGF-I (Frechette et al., 2005). PRP has been used experimentally and in clinical trials for the treatment of several ocular conditions, such as corneal epithelial wounds (Tanidir et al., 2010), chemical burns (Khaksar et al., 2013; Márquez-de-Aracena et al., 2007), dry eye (Alio et al., 2007b), corneal ulcers caused by neurotrophic keratitis or trauma (Geremicca et al., 2010) and other ocular surface disorders (Alio et al., 2015).

Apart from the antibiotic properties of tetracyclines and their derivatives, it is known that they exhibit non-antimicrobial properties, such as affecting inflammation, immunomodulation, cell proliferation and angiogenesis (Federici, 2011). It is suggested that tetracyclines can bind essential Zn^{2+} in collagenase and thus inhibit collagenase activity by this mechanism (Burns et al., 1989). Previous studies suggest that tetracyclines can inhibit the gene expression of neutrophil collagenase (Suomalainen et al., 1992) and epithelial gelatinase (Nip et al., 1993), and also reduce degradation of 1-antitrypsin (Sorsa et al., 1993). Additionally, tetracyclines can inhibit collagenase activity by the scavenging of reactive oxygen species thus diminishing the amount of neutrophil procollagenase that is activated (Ramamurthy et al., 1993). It has been reported that among tetracyclines, doxycycline is the most potent corneal collagenase

inhibitor (Burns et al., 1989). Other properties of tetracyclines are also their ability to inhibit the formation of arachidonic acid (Vadas et al., 1991) and the synthesis of prostaglandin E2 (El Attar et al., 1988).

Considering the destructive consequences of alkali chemical burns on the ocular surface and intraocular tissues (Singh et al., 2013), as well as the poor, already known treatment outcomes, there is a great interest for an effective, easy and safe treatment (Bakunowicz-Łazarczyk and Urban 2016). The aim of this study is to experimentally investigate the effect of intrastromal injection of PRP in combination with oral doxycycline, after an alkali burn, and to propose an alternative treatment acting directly to the lesion site, accelerating more sufficiently the healing process.

MATERIALS AND METHODS

Thirty six New Zealand rabbits, weighing 2.7-3.0 kg, were used in this experimental study, obtained from a licensed rabbit farm (EL08RAB8Y). All rabbits were kept in a well-ventilated room with a standard 12-hour light dark cycle and stable temperature and humidity. Animals had free access to food and water and everything was performed according to the ARVO Statement for the Use of Animals in Ophthalmic and Vision Research (ARVO, 2016). All procedures and experimental designs of the study were reviewed and approved by the Ethics Committee of the Aristotle University of Thessaloniki as well as by the local Committee of the Department of Veterinary Medicine of Thessaloniki (licence number: 74188/485, date issued: 30/3/2015). The study was conducted in the Companion Animal Clinic, Faculty of Veterinary Medicine, Aristotle University of Thessaloniki (facility licence number: EL54BIO18).

A complete and thorough ophthalmic examination was performed in all rabbits to ensure that they were free of any ocular pathologic conditions. The rabbits were then randomly allocated into four groups of nine animals each.

Preparation of PRP

For the preparation of PRP the method described by Gimeno et al. (2006) was followed. A 10 ml syringe, preloaded with 1.3 ml of Anticoagulant Citrate Dex-

trose solution (ACD citrate-dextrose solution, Sigma-Aldrich, U.S.A.) to avoid coagulation, was used to draw 8.7 ml of blood under strict aseptic conditions from the jugular vein. One millilitre was set apart for cell counting. Two centrifugations were made at 4°C. After centrifuging the whole blood at 72 g for 15 minutes, the 6 ml plasma layer was aspirated and centrifuged for a second time at 1006 g for 5 minutes. After removing the upper part (platelet poor plasma, PPP), the lower part consisting of 0.5 ml was the platelet rich plasma. PRP was aspirated in a sterile 1 ml syringe and kept at 4°C until use (Gimeno et al., 2006).

PRP that was prepared from animals that were allocated in the control group was used for platelet count that was performed using the ADVIA 120 haematology system (Siemens, Germany). A veterinary software package was run and “rabbit” was chosen as the default species in all cell-counting procedures. Enrichment percentage was calculated as described by Efeoglu et al. (2004).

Chemical burn

All animals were anaesthetized with dexmedetomidine (Dexdomitor, Zoetis Hellas) 0.075-0.1 mg/kg b.w., intramuscularly, and ketamine (Imalgene 1000, Merial, France) 15 mg/kg b.w., intramuscularly, and 1-2 drops of topical anaesthetic (proxymetacaine hydrochloride, Alcaine, Alcon Laboratories Hellas) were installed. The ocular surface and the conjunctival fornix were cleansed and disinfected with a mild antiseptic solution containing aqueous 0.5% povidone-iodine, and an eye lid retractor was placed. The alkali burn was induced only in one eye of each animal for ethical purposes, as described by Khaksar et al. (2013). A round filter paper, 6.0 mm in diameter, pre-soaked in sodium hydroxide (1 M NaOH) was placed on the central cornea for 60 seconds (Khaksar et al., 2013). After the disc removal, remnants of the corneal epithelium on the lesion were removed with a sterile swab and the ocular surface was rinsed with physiological saline for 2 minutes.

Treatment groups

The rabbits were allocated to four groups of 9 animals each. Group 1 was the control group and

received no treatment. Group 2 received doxycycline (Novadox oral suspension, AST Farma, Netherlands) at a dose of 5 mg/kg b.w. orally once a day throughout the study. Group 3 received 0.5 ml of PRP, which was injected with the aid of a 22mm, 30g sterile ophthalmic microsurgical cannula at 3 sites in the anterior corneal stroma, through pockets around the lesion, created by a 15° knife. Group 4 received both intrastromal PRP and oral doxycycline, as described above (Fig. 1).

All animals received tobramycin (Tobrex eye drops solution, Alcon Laboratories Hellas) every 6 hours for the first postoperative day, and meloxicam (Metacam, Boehringer Ingelheim, Germany) was given for 5 days (0.2 mg/kg b.w., subcutaneously, SID). Throughout the study, a tear film substitute with dexpanthenol (Corneregel eye gel, PharmaSwiss Hellas) was used three times a day and an Elizabethan collar was placed to prevent self-trauma.

On the 3rd and 7th postoperative days 2 animals of each group were euthanatized while the remaining 5 animals of each group were euthanatized on the 14th day. For euthanasia, a mixture of dexmedetomidine (0.1 mg/kg b.w., intramuscularly) and ketamine (15 mg/kg b.w., intramuscularly) followed by a high dose of iv propofol and potassium chloride was used. Enuclation was performed and the eye globes were fixed for histopathological analysis.

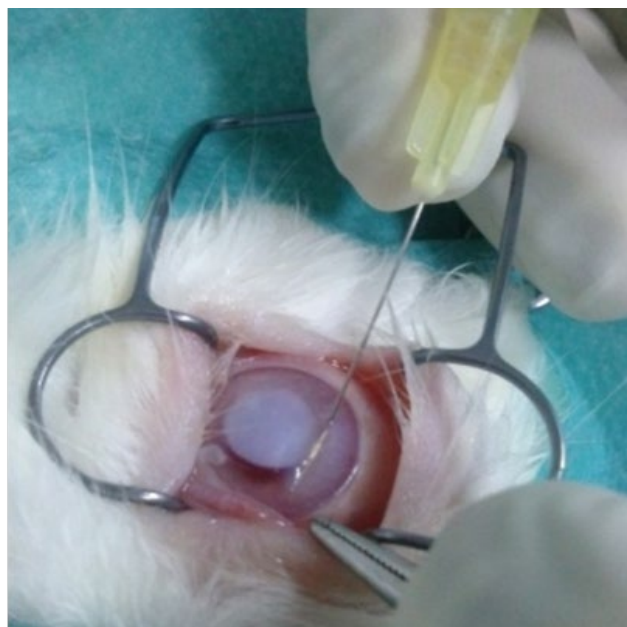


Figure 1. Intrastromal injection of PRP in groups 3 and 4

Clinical evaluation

The outcome was monitored daily by detailed clinical evaluation of the eyes, with the use of a portable slit lamp biomicroscope and photographs were taken. Corneal opacity and neovascularisation were recorded, and fluorescein dye test was performed to detect epithelial defects. Photographs were analyzed by ImageJ 1.31v (an image-processing software), examining the area of oedema, neovascularization and epithelial defect, and the lesion areas were determined in terms of mm or mm² on digitized photographs. Conjunctival congestion, ocular discharge and the presence of uveitis were scored using a scale from 0 to 3. Grade 0 represented no abnormalities (normal conjunctiva, absence of ocular discharge, and normal iris and anterior chamber), grade 1 represented mild symptoms (mild conjunctival congestion, serous discharge, mild iris hyperaemia and inflammation), grade 2 represented moderate symptoms (moderate conjunctival congestion, mucoid ocular discharge, miosis, iris hyperaemia and inflammation) and grade 3 represented severe symptoms (severe conjunctival congestion, copious purulent discharge, and miosis, aqueous flare and iris inflammation respectively). Corneal sensitivity was measured at the centre and the periphery of the cornea using a handheld Cochet-Bonnet esthesiometer (quantitative method). To determine the eye dryness, Schirmer tear test 1 (STT) was performed. Intraocular pressure was not measured due to the deleterious effects of local anaesthetics on the healing process (Bisla and Tanelian, 1992).

Histopathological examination

The enucleated eye globes were fixed in formaldehyde and prepared for paraffin embedding. Paraffin sections (5 mm thick) were obtained with a microkeratome and the samples were subjected to routine hematoxylin and eosin staining. Histopathological analysis was carried out by a single pathologist blinded to the experimental groupings.

Statistical evaluation

Data were analyzed using SPSS version 22.0 software. Statistical analysis between the groups for corneal oedema, corneal vascularisation, corneal

sensitivity and STT was performed by the nonparametric Kruskal-Wallis test. Pair-wise comparison between each group and control was performed using a Mann-Whitney U test. Chi-squared test was performed for corneal reepithelialisation, conjunctival congestion, ocular discharge and the presence of uveitis. P values of <0.05 were considered to be significant.

RESULTS

Platelet count

The mean value of platelet counts in venous blood was 642.330/ μ L, in PRP it was 4950.400/ μ L and in PPP it was 196.850/ μ L. The mean enrichment percentage was 670%.

Clinical evaluation

Corneas in all animals became cloudy immediately after the chemical burn, turned opaque with a ground-glass appearance and were distinct from the rest of the normal tissue of the cornea. Comparison between groups (Fig. 2) showed that groups 3 and 4 had statistically less corneal oedema compared to the control group on day 3 (P: 0.001 for group 3 and P: 0.003 for group 4) and 7 (P: 0.004 for group 3 and P: 0.018 for group 4). Corneal opacity revealed no significant differences on the 14th postoperative day between groups (P>0.05).

The new vessels were fine and superficial, and emerged from the limbus on the 3rd and 4th day after the chemical burn in most animals from all groups. Statistical analysis for corneal vascularisation (Fig. 3) between groups on days 3 and 7 showed significant difference (P<0.05), but there were not any statistical differences for day 14 (P>0.05). More specifically, on the 3rd day groups 1 (P: 0.012) and 3 (P: 0.012) had less vascularization compared to group 4, and on the 7th day vascularisation was lower in groups 2 (P<0.001), 3 (P<0.001) and 4 (P: 0.001) when compared to the control group; but comparison between treatment groups was not statistically significant.

Comparison between groups (Fig. 4) showed that groups 3 and 4 had smaller mean defect area and greater wound healing. When considering as "corneal healing" the healing of 80% of the initial wound

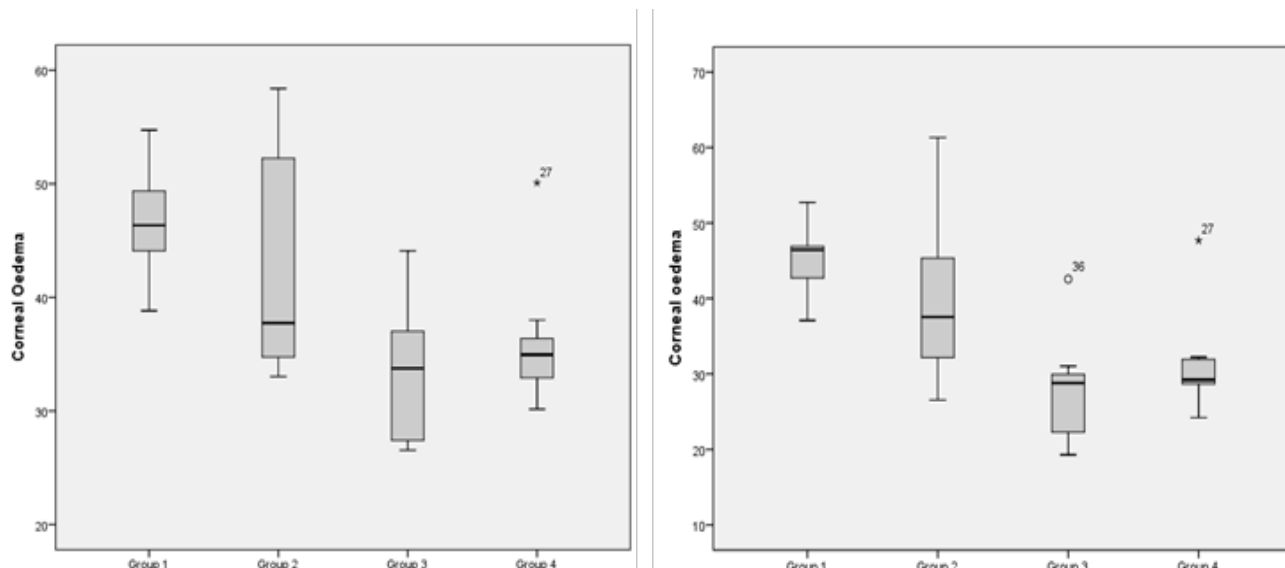


Figure 2. Corneal opacity measured in mm² on the 3rd (left) and 7th (right) day after the chemical burn in all groups.

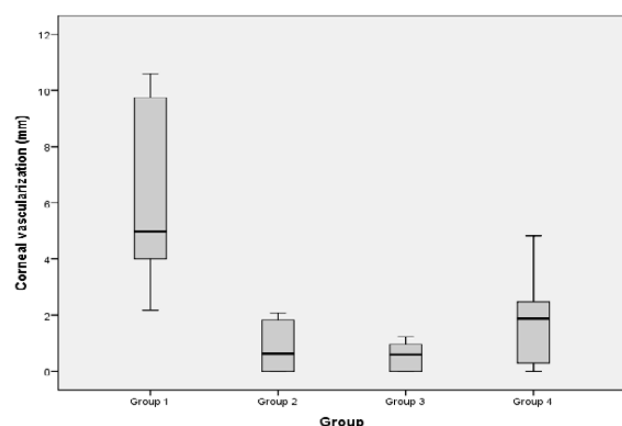


Figure 3. Corneal neovascularization (mm) on the 7th day after the chemical burn in groups 1, 2, 3 and 4.

surface (Table 1), there were statistically significant differences between all groups on days 3, 7 and 14 ($P < 0.05$). On the 3rd day 55% of the animals in group 3 and 77% of the animals in group 4 had a corneal

defect whose surface was less than 20% of the initial defect area on the 1st day. On the 7th and 14th all animals in group 3 and 4 had less than 20% of the initial defect area, compared to 20% of the animals in group 2. Animals in the control group had epithelial defects greater than the 20% of the initial surface for the whole duration of the study. Furthermore, corneal perforation was noticed only in 3 animals that belonged to the control group on the 10th ($N=2$) and on the 14th ($N=1$) day after the chemical burn.

Conjunctival congestion was significantly different ($P < 0.001$) on days 7 and 14, showing more intense congestion in animals in the control group compared to the treatment groups.

On the 3rd day, ocular discharge was statistically significantly ($P < 0.001$) less in group 3 compared to the other groups. On the 7th ($P: 0.01$) and 14th day ($P: 0.012$) control group had statistically significantly more discharge compared to the other groups.

For the presence of uveitis there were statistically

Table 1: Percentage (%) of corneal healing of the 80% of the initial wound surface on days 3, 7 and 14 after the chemical burn

Day	Wound healing	Group 1	Group 2	Group 3	Group 4
3rd	>80%		11.1	77.8	55.6
P: 0.002	<80%	100	88.9	22.2	44.4
7th	>80%			100	100
P: 0.000	<80%	100	100		
14th	>80%		20.0	100	100
P: 0.000	<80%	100	80.0		

Table 2: Percentage (%) of severity of uveitis on days 3, 7 and 14 after the chemical burn

Day	grade*	Group 1	Group 2	Group 3	Group 4
3rd P: 0.001	0	33.3	100	88.9	100
	1	22.2		11.1	
	2	44.4			
	3				
7th P: 0.000	0		100	85.7	100
	1				
	2	14.3		14.3	
	3	85.7			
14th P: 0.001	0		80.0	100	100
	1		20.0		
	2	20.0			
	3	80.0			

*grade 0: normal iris and anterior chamber, grade 1: mild iris hyperaemia and inflammation, grade 2: miosis, iris hyperaemia and inflammation, grade 3: miosis, aqueous flare, severe iris hyperaemia and inflammation.

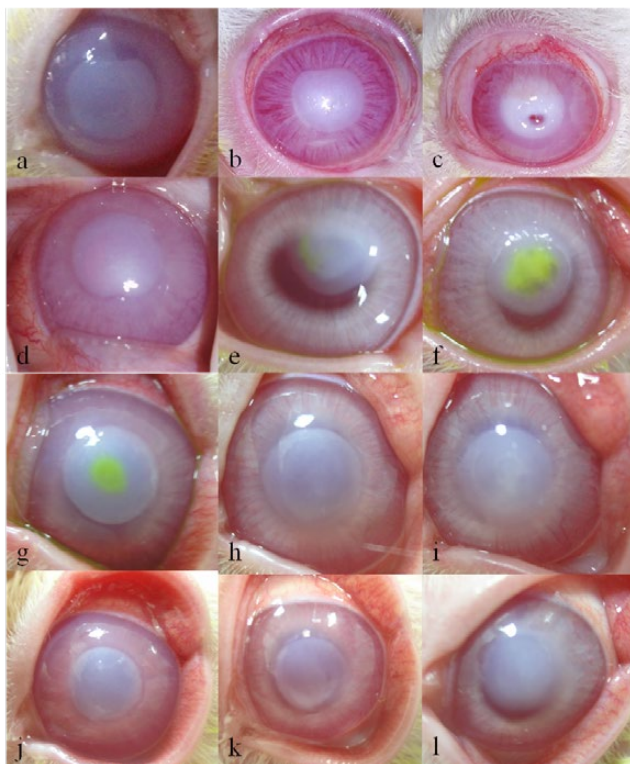


Figure 4. Postoperative photos in group 1 (a-c), group 2 (d-f), group 3 (g-i) and group 4 (j-l) at days 3, 7 and 14. In group 1 intense conjunctival congestion is seen, along with iris inflammation, corneal opacity, neovascularization and perforation. In group 2 conjunctival congestion and corneal opacity is shown. Group 3 had complete corneal healing and limited corneal opacity, as group 4, where conjunctival congestion was not present.

significant differences between groups ($P < 0.05$) for days 3, 7 and 14 (Table 2). More specifically, on the 3rd day 66.7% of the animals in the control group showed signs of uveitis, compared to 11.1% of animals in group 3 and none of the animals in groups 2 and 4. On the 7th day all animals in the control group had signs of uveitis, compared to 14.3% of animals in group 3 and none of the animals in groups 2 and 4. Lastly, on the 14th day all animals in the control group and 20% of animals in group 2 had uveitis, whereas none of the animals in groups 3 and 4 showed signs of uveitis.

Corneal sensitivity in the periphery of the cornea (Fig. 5) was significantly higher in groups 2 ($P: 0.03$) and 4 ($P: 0.045$) compared to the control group on the 3rd day. On the 7th and 14th day no statistically significant differences were noticed. Also, corneal sensitivity measurements in the centre of the cornea showed no statistically significant difference ($P > 0.05$) between groups.

The STT showed no statistically significant differences in tear production between groups for the whole duration of the study.

Histopathological evaluation

In the control group, histopathological evaluation on the 3rd day revealed superficial and deep neovascularization of the cornea, moderate corneal oedema,

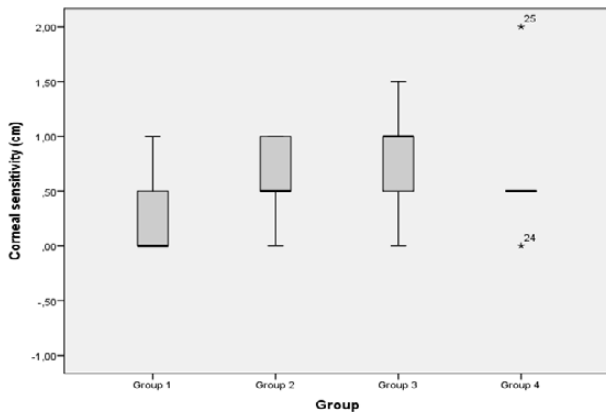


Figure 5. Corneal sensitivity (cm) in the periphery of the cornea, on the 3rd day after the chemical burn.

and infiltration of inflammation cells (mostly lymphocytes and some neutrophils). On the 7th and 14th day, intense neovascularization, corneal oedema and epithelial hyperplasia were noticed. In group 2, corneal oedema and infiltration were lower compared to

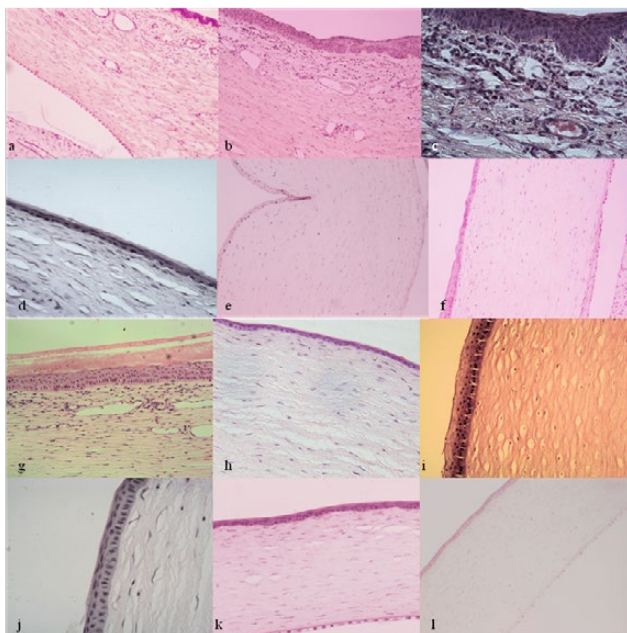


Figure 6. Histopathological examination in group 1 (a-c), group 2 (d-f), group 3 (g-i) and group 4 (j-l) at days 3, 7 and 14. In group 1 intense superficial and deep vascularization are noticed, along with epithelial hyperplasia, stromal oedema and the presence of inflammatory cells. In group 2 there is less corneal oedema, but neovascularization is present. In group 3, vascularization is seen on the 3rd day, and on the 7th and 14th mild corneal oedema is noticed. In group 4, mild corneal oedema, less vascularization and better collagen arrangement is recorded, without any epithelial hyperplasia.

the control group, but neovascularization was present on the 3rd, 7th and 14th day. In group 3 neovascularization and corneal oedema were lower compared to groups 1 and 2. On the 7th and 14th day mild corneal oedema was recorded. In group 4 superficial vascularization of the cornea was noticed on the 3rd day, but on days 7 and 14 it was limited. Corneal epithelium appeared normal, without any hyperplasia and with less corneal oedema; furthermore collagen arrangement was better when compared to the other groups (Fig. 6).

DISCUSSION

In the present study the therapeutic efficacy of intrastromal PRP injection, oral doxycycline treatment or combination of them were evaluated on corneal alkali burns in New Zealand rabbits.

In the present study, for the preparation of PRP the method described by Gimeno et al. (2006) was followed. The same method has been used in other experimental protocols in rabbits regarding ocular surface conditions (Gimeno et al., 2010; Tanidir et al., 2010; Khaksar et al., 2013). Intracardiac blood sampling was not performed, and blood was drawn from the jugular vein as it can be well tolerated by rabbits, no anaesthesia was required and the resulting blood collection was without clumps. The mean enrichment percentage was greater compared to previous studies (Efeoglu et al., 2004; Gimeno et al., 2006) resulting in greater platelet number in PRP, possibly due to the higher platelet concentration in the whole blood.

In previous studies PRP has been administered by subconjunctival application (Márquez-de-Aracena et al., 2007; Tanidir et al., 2010; Khaksar et al., 2013) or as topical eye drops (Alio et al., 2007a,b). In this experimental study PRP was delivered in the form of intrastromal injections, a route previously used in corneal chemical burns in rabbits for the administration of stem cells (Almaliotis et al., 2015). In our study intrastromal injections were preferred as they can increase the concentration of growth factors in the deep layers of the cornea in a minimally invasive way.

In corneal chemical burns one of the major treatment goals is control of the balance between collagen synthesis and collagenolysis (Singh et al., 2013). In

this study doxycycline was used as a MMP inhibitor. Among tetracyclines, doxycycline has been shown to be the most potent corneal collagenase inhibitor (Burns et al., 1989). Perry et al. (1993) examined the effects of orally administered doxycycline in rabbits after a chemical burn and their findings suggest that the dose of 5 mg/kg once a day of doxycycline can promote corneal reepithelization compared to 1.5 mg/kg. The same dosage was used in this study for groups 2 and 4.

It is noteworthy that animals that received PRP (groups 3 and 4) had less corneal oedema compared to the control group on the 3rd and 7th day after the chemical burn. In another study the effect of subconjunctival PRP in combination with topical acetylcysteine on corneal alkali burns in rabbits was investigated. The findings of that study revealed prominent corneal oedema in all groups for the first week (Khaksar et al., 2013). The reduction of corneal oedema in our study may be related to the more direct application of PRP, as an intrastromal route was used for the delivery of growth factors into the cornea. Furthermore, in the study of Khaksar et al. (2013) the group that received only PRP had smaller mean defect area and greater wound healing compared to the group that received PRP and acetylcysteine. The retarded healing effect in that group was due to acetylcysteine's poor ability to penetrate the corneal stroma and its relative toxicity (Wagoner, 1997). In our study, the collagenase inhibitor agent (doxycycline) was administered systemically to avoid any topical toxicity effects.

In a study carried out by Dan et al. (2008), the efficacy of oral doxycycline compared to oral and topical dexamethasone for inhibiting corneal neovascularization after an alkali burn in rats was investigated. In the group that was treated with oral doxycycline, corneal neovascularisation was less compared to the untreated control group, and the epithelial healing was significantly more rapid. It was concluded that oral doxycycline can inhibit neovascularization without the harmful side-effects associated with oral or topical dexamethasone use (Dan et al., 2008). These results are in accordance with our results concerning the significantly less neovascularization of the groups which received doxycycline compared to the control group. One possible explanation for the inhibition of neovascularization is the inhibition of MMPs, but

further investigation is needed (Dan et al., 2008).

Regarding the healing process, animals that received PRP (groups 3 and 4) had smaller defect area compared to control group and group 2. These findings are in accordance with a study by Tanidir et al. (2010), where the effect of PRP was examined in corneal epithelial wound healing in rabbits. After the creation of a 7-mm diameter central epithelial defect, a single dose of subconjunctival PRP was injected, with or without concurrent antibiotic treatment. Animals that received PRP had a better healing process compared to the control group (Tanidir et al., 2010). In our study topical antibiotics were used only for the 1st day after the chemical burn, to avoid any retarded healing effect. In the study of Tanidir et al. (2010), it was pointed out that the group that received PRP in combination with topical antibiotic had a delay in the epithelial healing, and it should be due to corneal toxicity caused by the antibiotic or the preservatives included in the antibiotic solutions, or by possible distraction on the balanced process during cornea healing (Tanidir et al., 2010).

In group 2 (where only doxycycline was administered), 20% of the animals had less than 20% of the group's initial defect area on the 14th day, and no corneal perforations were reported compared to the control group. This effect of doxycycline is probably related to the drug's ability to inhibit collagenase activity. Tetracyclines have been studied in corneal chemical burns in rabbits (Seedor et al., 1987; Perry et al., 1993) and rats (Dan et al., 2008) for their effect on corneal healing and angiogenesis. It is reported that corneal tetracycline levels are directly correlated to the dose administered systemically, and eyes with higher levels of tetracycline in ocular tissues are less likely to ulcerate (Seedor et al., 1987).

Animals that received only doxycycline (group 2) had less conjunctival congestion and less ocular discharge compared to the control group. Also, groups 2 and 4 (doxycycline and doxycycline+PRP groups) had fewer signs of uveitis when compared to the control group and the group that received PRP only. These findings may be the result of the anti-inflammatory and immunomodulatory properties of doxycycline (Federici, 2011).

In the present study corneal sensitivity was greater in groups that received oral doxycycline. Further-

more, animals that received combination of doxycycline and PRP (group 4) had increased corneal sensitivity on the 3rd day compared to the group that received only PRP (group 3). This effect can be due to the anti-inflammatory properties of doxycycline (Sapadin and Fleischmajer, 2006). Also doxycycline can have neuroprotective effect to the sensory (trigeminal) nerve fibers, like the neuroprotective features of tetracycline (Uckun et al., 2015) and minocycline (Sanchez Mejia et al., 2001) to the brain tissue, which can be attributed to the increased corneal sensitivity; however further studies are needed.

Among the late complications that occur usually three weeks after a chemical ocular injury are xerophthalmia and dry eyes (Singh et al., 2013). In the present study no statistically significant differences were noted among groups regarding tear production, maybe due to the relatively short duration of the study (14 days). On the other hand, normal STT values for rabbits may be useful only for the evaluation of increased values correlated with ocular irritation, rather than for the determination of decreased values associated with keratoconjunctivitis sicca (Abrams et al., 1990).

A study was carried out by Campos et al. (2003), with experimentally induced corneal chemical ulcers in dogs. For the treatment, topical applied autogenous serum and 10% acetylcysteine were used. It was noticed that when compared to the control group, no differences were found in the healing process of the cornea, whereas in the present study the animals that received PRP had smaller defect area and better wound healing. These results may be due to the fact that blood serum contains lower concentrations of growth factors compared to PRP (Frechette et al., 2005). Therefore, the efficacy of PRP and doxycy-

cline may have beneficial results in other species than rabbits, as dogs and cats experiencing ulcerative keratitis with MMP involvement.

CONCLUSIONS

This is the first experimental study that uses PRP with intrastromal injection to the cornea. We believe that despite the local destruction of the cornea's architecture, the close proximity of growth factors to the lesion site can have beneficial results to the outcome of a chemical burn, or other severe corneal lesions with collagenase activity. Despite the fact that PRP alone had better results in corneal healing on the 3rd day after the chemical burn, on the 7th and 14th day the combination of PRP and doxycycline resulted in better corneal healing, with better collagen arrangement and less corneal oedema in histopathological examination. Further studies are needed to examine the effect of intrastromal PRP in other corneal conditions. Doxycycline on the other hand, is a potent collagenase inhibitor, with minimal side effects and thus a safe additional treatment option for chemical burns. According to our findings, doxycycline can reduce the clinical symptoms caused by chemical burns, resulting in less intense uveitis, ocular discharge and conjunctival congestion. Therefore, the above combination is a simple, safe and more economical therapeutic approach to promote quick corneal healing, so anti-inflammatory agents can be used when the epithelium becomes intact without any undesirable side effects.

CONFLICT OF INTEREST STATEMENT

The authors declare that there is no conflict of interest.

REFERENCES

- Abrams KL, Brooks DE, Funk RS, Theran P (1990) Evaluation of the Schirmer tear test in clinically normal rabbits. *Am J Vet Res* 51(12):1912-1913.
- Alio J, Abad M, Artola A, Rodriguez-Prats JL, Pastor S, Ruiz-Collecha J (2007a) Use of Autologous Platelet-Rich Plasma in the Treatment of Dormant Corneal Ulcers. *Ophthalmology* 114(7):1286-1294.
- Alio J, Colecha JR, Pastor S, Rodriguez A, Artola A (2007b) Symptomatic dry eye treatment with autologous platelet-rich plasma. *Ophthalmic Res* 39(3):124-129.
- Alio J, Rodriguez AE, Wróbel-Dudzinska D (2015) Eye platelet-rich plasma in the treatment of ocular surface disorders. *Curr Opin Ophthalmol* 26(4):325-332.
- Almaliotis D, Koliakos G, Papakonstantinou E, Komnenou A, Thomas A, Petrakis S, Nakos I, Gounari E, Karampatakis V (2015) Mesenchymal stem cells improve healing of the cornea after alkali injury. *Graefes Arch Clin Exp Ophthalmol* 253(7):1121-1135.
- Ambati BK, Jousen AM, Ambati J, Moromizato Y, Guha C, Javaheerian K, Gillies S, O'Reilly MS, Adamis AP (2002) Angiostatin inhibits and regresses corneal neovascularization. *Arch Ophthalmol* 120(8):1063-1068.
- ARVO, Association for Research in Vision and Ophthalmology (2016) Statement for the use of animals in ophthalmic and visual research. Available at: <https://www.arvo.org/About/policies/statement-for-the-use-of-animals-in-ophthalmic-and-vision-research> [Accessed May 23 2017].
- Bakunowicz-lazarczyk A, Urban B (2016) Advances in Medical Sciences Assessment of therapeutic options for reducing alkali burn-induced corneal neovascularization and inflammation. *Adv Med Sci* 61(1):101-112.
- Bisla K, Tanelian DL (1992) Concentration-Dependent Effects of Lidocaine on Corneal Epithelial Wound Healing. *Investig Ophthalmol Vis Sci* 33(11):3029-3033.
- Borzini P, Mazzucco L (2005) Tissue regeneration and in loco administration of platelet derivatives: Clinical outcome, heterogeneous products, and heterogeneity of the effector mechanisms. *Transfusion* 45(11):1759-1767.
- Burns FR, Stack SM, Gray RD, Parerson CA (1989) Inhibition of Purified Collagenase from Alkali-Burned Rabbit Corneas. *Investig Ophthalmol Vis Sci* 30(7):1569-1575.
- Busse C, Hartley C, Kafarnik C, Pivetta M (2014) Ocular alkaline injury in four dogs - presentation, treatment, and follow-up - a case series. *Vet Ophthalmol* 18(2):127-134.
- Campos CF, Jorge AT, Talieri IC, Vicenti FAM, Toledo-Piza E, Laus JL (2003) Ocular alkali lesions in dogs. Acetylcysteine and blood serum effects. *Brazilian Journal Vet Res Anim Sci* 40(1):36-44.
- Christmas R (1991) Management of chemical burns of the canine cornea. *Can Vet J* 32(10):608-612.
- Chung JH, Kim HJ, Fagerholmb, Cho BC (1996) Effect of topically applied Na-hyaluronan on experimental corneal alkali wound healing. *Korean J Ophthalmol* 10(2):68-75.
- Crum R, Szabo S, Folkman J (1985) A new class of steroids inhibits angiogenesis in the presence of heparin or a heparin fragment. *Science* 230(4732):1375-1378.
- Dan L, Shi-long Y, Miao-li L, Yong-ping L, Hong-jie M, Ying Z, Xiang-gui W (2008) Inhibitory effect of oral doxycycline on neovascularization in a rat corneal alkali burn model of angiogenesis. *Curr Eye Res* 33(8):653-60.
- Dua HS, King AJ, Joseph A (2001) A new classification of ocular surface burns. *Br J Ophthalmol* 85(11):1379-83.
- Efeoglu C, Akçay YD, Ertürk S (2004) A modified method for preparing platelet-rich plasma: An experimental study. *J Oral Maxillofac Surg* 62(11):1403-1407.
- El Attar T, Lin HS, Shultz R (1988) Effect of minocycline on prostaglandin formation in gingival fibroblasts. *J Periodontal Res* 23(5):285-286.
- Federici TJ (2011) The non-antibiotic properties of tetracyclines: Clinical potential in ophthalmic disease. *Pharmacol Res* 64(6):614-623.
- Fish R, Davidson RS (2010) Management of ocular thermal and chemical injuries, including amniotic membrane therapy. *Curr Opin Ophthalmol* 21(4):317-321.
- Frechette JP, Martineau I, Gagnon G (2005) Platelet-rich plasmas: growth factor content and roles in wound healing. *J Dent Res* 84(5):434-439.
- Geremicca W, Fonte C, Vecchio S (2010) Blood components for topical use in tissue regeneration: Evaluation of corneal lesions treated with platelet lysate and considerations on repair mechanisms. *Blood Transfus* 8(2):107-112.
- Gimeno LF, Gatto SC, Croxatto JO, Ferro JI, Gallo JE (2010) In vivo lamellar keratoplasty using platelet-rich plasma as a bioadhesive. *Eye* 24(2):368-375.
- Gimeno LF, Gatto SC, Ferro J, Croxatto JO, Gallo JE (2006) Preparation of platelet-rich plasma as a tissue adhesive for experimental transplantation in rabbits. *Thromb J* 4(18):1-7.
- Gunay C, Sagliyan A, Yilmaz S, Kandemir FM, Han MC, Ozkaraca M, Kulualp K (2015) Evaluation of autologous serum eyedrops for the treatment of experimentally induced corneal alkali burns. *Rev Med Vet (Toulouse)* 166(3-4):63-71.
- Jousen AM, Kruse FE, Volcker HE, Kirchhof B (1999) Topical application of methotrexate for inhibition of corneal angiogenesis. *Graefes Arch Clin Exp Ophthalmol* 237(11):920-927.
- Khaksar E, Aldavood SJ, Abedi GR, Sedaghat R, Nekoui O, Zamani-ahmadmamdudi M (2013) The effect of sub-conjunctival platelet-rich plasma in combination with topical acetylcysteine on corneal alkali burn ulcer in rabbits. *Comp Clin Path* 22(1):107-112.
- Kuo IC (2004) Corneal wound healing. *Curr Opin Ophthalmol* 15(4):311-315.
- Levinson RA, Paterson CA, Pfister RR (1976) Ascorbic acid prevents corneal ulceration and perforation following experimental alkali burns. *Invest Ophthalmol* 15(12):986-993.
- Márquez-de-Aracena R, Montero-de-Espinosa I, Munoz M, Pereira G (2007) Subconjunctival application of plasma platelet concentrate in the treatment of ocular burns. Preliminary results. *Arch Soc Esp Oftalmol* 82:475-481.
- McCulley PJ (1987) Chemical injuries. In: Smolin G, Thoft AR eds. *The cornea*. Boston, Mass, Little, Brown and Co: pp 527-542.
- Nip LH, Uitto VJ, Golub LM (1993) Inhibition of epithelial cell matrix metalloproteinases by tetracyclines. *J Periodont Res* 28(5):379-385.
- Nurden AT (2011) Platelets, inflammation and tissue regeneration. *Thromb Haemost Suppl* 105(1):13-33.
- Perry HD, Hodes LW, Seedor JA, Donnenfeld ED, McNamara TF, Golub LM (1993) Effect of doxycycline hyclate on corneal

- epithelial wound healing in the rabbit alkali-burn model. Preliminary observations. *Cornea*, 12(5):379–382.
- Peyman GA, Kivilcim M, Morales AM, DellaCroce JT, Conway MD (2007) Inhibition of corneal angiogenesis by ascorbic acid in the rat model. *Graefe's Arch Clin Exp Ophthalmol* 245(10):1461–1467.
- Pfister RR, Haddox JL, Lank KM (1988) Citrate or ascorbate/citrate treatment of established corneal ulcers in the alkali-injured rabbit eye. *Investig Ophthalmol Vis Sci* 29(7):1110–1115.
- Ramamurthy NS, Vernillo AT, Greenwald RA, Lee HM, Sorsa T, Golub LM, Rifkin BR (1993) Reactive oxygen species activate and tetracyclines inhibit rat osteoblast collagenase. *J bone Miner Res* 8(10):1247–1253.
- Salman IA, Gundogdu C (2010) Epithelial healing in experimental corneal alkali wounds with nondiluted autologous serum eye drops. *Cutan Ocul Toxicol* 29(2):116–121.
- Sanchez Mejia RO, Ona VO, Li M, Friedlander RM (2001) Minocycline reduces traumatic brain injury-mediated caspase-1 activation, tissue damage, and neurological dysfunction. *Neurosurgery* 48(6):1393–1401.
- Sapadin AN, Fleischmajer R (2006) Tetracyclines: Nonantibiotic properties and their clinical implications. *J Am Acad Dermatol* 54(2):258–265.
- Schultz G, Chegini N, Grant M, Khaw P, MacKay S (1992) Effects of Growth Factors on Corneal Wound Healing. *Acta Ophthalmol* 70(S202):60–66.
- Seedor JA, Perry HD, McNamara TF, Golub LM, Buxton DF, Guthrie DS (1987) Systemic tetracycline treatment of alkali-induced corneal ulceration in rabbits. *Arch Ophthalmol* 105(2):268–271.
- Şenel OO, Ergün İ (2014) Medical and surgical treatment of severe corneal alkaline burn in a cat. *Vet Hekimler Dern Dergisi, J Vet Med Soc* 85(1):24–28.
- Singh P, Tyagi M, Kumar Y, Gupta KK, Sharma PD (2013) Ocular chemical injuries and their management. *Oman J Ophthalmol* 6(2):83–87.
- Sorsa T, Kontinen YT, Lindy O, Suomalainen K, Ingman T, Halinen S, Lee HM, Golub LM, Hall J (1993) Doxycycline protects serum alpha-1-antitrypsin from human neutrophil collagenase. *Agents Actions Suppl* 39:225–229.
- Stuart JC, Turgeon P, Kowalski RP (1989) Use of aprotinin in the treatment of pseudomonas corneal ulceration. *Trans Pa Acad Ophthalmol Otolaryngol* 41:823–826.
- Suomalainen K, Sorsa T, Ingman T, Lindy O, Golub LM (1992) Tetracycline inhibition identifies the cellular origin of interstitial collagenases in human periodontal diseases in vivo. *Oral Microbiol Immunol* 7(2):121–123.
- Swank A, Hosgood G (1996) Healing and the role of growth factors. *Compend Small Anim* 18(9):1007–1016.
- Tanidir ST, Yuksel N, Altintas O, Yildiz DK, Sener E, Caglar Y (2010) The effect of subconjunctival platelet-rich plasma on corneal epithelial wound healing. *Cornea* 29(6):664–669.
- Uckun OM, Alagoz F, Secer M, Karakoyun O, Ocakcioglu A, Yildirim AE, Yimaz F, Sahinoglu M, Divanlioglu D, Dalgic A, Daglioglu E, Belen AD (2015) Neuroprotective effects of tetracyclines on blunt head trauma: An experimental study on rats. *J Neurosci Rural Pract* 6(1):27–32.
- Vadas P, Greenwald RA, Stree RT, Pruzanski W (1991) Inhibition of synovial fluid phospholipase A2 activity by 2 tetracycline derivatives, minocycline and doxycycline. *Arthritis Rheum* 34(1):51–60.
- Wagoner MD (1997) Chemical injuries of the eye: Current concepts in pathophysiology and therapy. *Surv Ophthalmol* 41(4):275–313.
- Williams DL, Barrie K, Evans TF (2002) Cornea. In: *Veterinary Ocular Emergencies*. Butterworth-Heinemann, Edinburgh: pp 37–63.

