


## Journal of the Hellenic Veterinary Medical Society

Vol 69, No 3 (2018)



### New approach for medial patellar ligament splitting for treatment of upward fixation of patella

M. W. EL SHERIF

doi: [10.12681/jhvms.18873](https://doi.org/10.12681/jhvms.18873)

Copyright © 2018, M. W. EL SHERIF



This work is licensed under a [Creative Commons Attribution-NonCommercial 4.0](https://creativecommons.org/licenses/by-nc/4.0/).

### To cite this article:

EL SHERIF, M. W. (2018). New approach for medial patellar ligament splitting for treatment of upward fixation of patella. *Journal of the Hellenic Veterinary Medical Society*, 69(3), 1059–1062. <https://doi.org/10.12681/jhvms.18873>

## **New approach for medial patellar ligament splitting for treatment of upward fixation of patella**

**M.W. El Sherif**

*Department of Animal Surgery, Faculty of Veterinary Medicine, Assiut University, New Valley, Egypt.*

**ABSTRACT.** A new medial patellar ligament splitting technique in cattle and donkeys is presented. It has been successfully applied on thirteen alive animals affected with permanent upward fixation of patella (UFP). The technique is simple, quick and easily applicable. In contrast to other medial patellar desmotomy techniques the present approach is less invasive, the skin at the surgical site is not incised but punctured, the pericapsular fat and joint capsule are not invaded. Minimal tissue invasiveness limits the infection of surgical site, minimizes bleeding and decreases their related postoperative consequences.

**Keywords:** Upward fixation, patella, desmotomy.

*Corresponding Author:*  
Mohamed W. El Sherif  
E-mail: drmwel@hotmail.com

*Date of initial submission:* 2-7-2017  
*Date of acceptance:* 28-10-2017

## INTRODUCTION

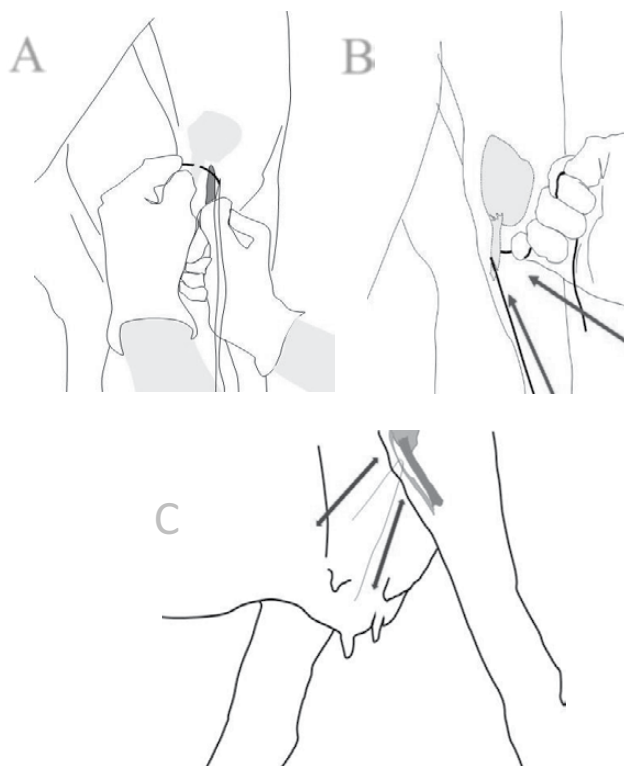Upward fixation of patella (UFP) has been reported with a higher incidence rate in equine than in cattle (Hanson and Peyton, 1987). This condition is believed to be due to poor conformation of the hind limb (Stick, 2006). The condition may occur temporarily which may spontaneously recover or permanently requiring surgical correction (Lacorix, 2005). Intermittent UFP is when the patella releases spontaneously, but locks again in variable intervals in forward movement (Brooks, 2007). Signs may disappear and normal steps are noticed after exercise (Curtis, 1961). Permanent dislocation of the patella leaves the limb in caudal extension and may even be dragged behind (Greenough, 2016). Affected animals are unable to protract the leg forward, or flex the affected limb causing the involved hind leg to drag behind. Jerky movement is observed at the walk when the MPL and its fibrocartilage disengage from the femoral trochlear ridge (Brooks, 2007). The condition is economically important as it reduces market value of the affected animal especially in riding animals like donkeys. Conservative treatments (Stashak, 2002; Brooks, 2007 and Peitzmeier et al, 2015) were reported. Surgical treatments including medial patellar ligament desmotomy (MPLD) and ultrasound-guided medial patellar ligament splitting (MPLS) were presented (Turner and McIlwraith, 1989; Stashak, 2002; Tnibar, 2002; Brooks, 2007; Madhu1 et al., 2012 and Singh et al., 2015). MPLD is usually performed while the animal is standing and under the effect of sedation and local anesthesia. MPLS required general anesthesia and animal positioned in dorsal recumbency. MPLD and MPLS are relatively invasive surgical approaches that require skin incision. Short and long term post-operative complications associated with these surgical treatments include swelling, pain, sever bleeding, wound infection and persistent low-grade lameness were reported (RamaKrishna, 1972; Sharma, 1980; Ali and Hashim, 1984 and Tnibar, 2002). The present study presents a new surgical technique for splitting of the MPL as a surgical choice for the treatment of irresponsive upward fixation of patella in cattle and donkeys which is thought to be minimal invasive, easy and more suitable for field conditions.

## MATERIALS AND METHODS

The study was approved by the animal welfare committee of the faculty of veterinary medicine, New Valley, Egypt. Ref. No. 1/2016.

Five donkeys (four males and one female, aging  $7 \pm 2$  years and weighing  $220 \pm 30$  kg) and eight cows (aging  $4 \pm 2$  years and weighting  $400 \pm 50$  kg) were admitted to the mobile surgery clinic of the faculty of veterinary medicine, New valley, Egypt, (2014-2016). They were diagnosed with permanent UFP. The donkeys and cows were sedated with xylazine HCl (Xylaject, ADWIA pharma, Egypt), (1mg/kg and 0.1mg/kg) administered intravenously.

The donkeys were secured with tying the front feet with ropes and kept in standing position while cows were positioned in lateral recumbency with the affected limb up. The stifle region of the operated limb was clipped and disinfected with absolute alcohol wipes followed by application of povidone iodine 10% solution (Betadine, Mondio, Switzerland). Ten milliliters of lidocaine HCl 2% (Depocaine, Depiky pharma, Egypt) was injected underneath the skin and deep between the middle and medial patellar ligaments, about 2 cm above the tibial tuberosity. Further disinfection was performed with alcohol wipes and povidone iodine solution. The medial patellar ligament was located with its insertion to the tibial tuberosity then held with the tips of thumb and index fingers. Instrument needed are half circle reverse cutting needle # 3, needle driver and silk strand (USP 1) in an appropriate length. Using aseptic technique, a sterile strand of silk mounted on a half circle reverse cutting needle is inserted through skin 2-3cm above the tibial crest at the medial aspect of the medial patellar ligament (at the tip of finger) and directed underneath the ligament to emerge on the opposite side (at the tip of the other finger) between the middle and medial patellar ligaments. The two ends of the silk strand were grasped with both hands and were used to transect the ligament with sawing action movements. The sawing action was discontinued when a "POP" sound was noted, indicating completion of the desmotomy. The silk strand was then removed and surgical site disinfected again with povidone iodine solution (Figure 1). Daily wound care with application of 10% povidone iodine antiseptic solution to the site of the procedure was performed for five successive days after surgery. Stable rest for 6 weeks was recommended. The surgical time (the time between the needle insertion and removal of silk strand from the



**Fig 1:** The surgical procedure in donkeys in standing position on the top; insertion of needle, A and splitting of the ligament, B, and in cattle in lateral recumbency with the affected limb above, at the bottom, C.

surgical site) for each procedure was recorded. Post-operative assessment was based on daily examination of animals for lameness signs, presence of gross signs of inflammation such as “swelling, hotness, pain and redness”.

## RESULTS

A pilot anatomical study performed on 10 donkey cadavers and bovine carcasses revealed the optimal site for the needle insertion was at the cranial aspect of the stifle, three fingers (2-3cm) proximal to tibial tuberosity. This site was found to be safe due to presence of periarticular fat while, proximal to this point, it is possible to damage the superficial branch of the saphenous nerve or to penetrate the medial extension of the femoropatellar joint capsule.

The surgical procedure was technically easy to perform and no intra-operative complications were recorded. The mean surgery time was  $3 \pm 1$  minutes.

Minor bleeding was noted at the points of needle insertion and exit point which stopped spontaneously.

“POP” sound was heard in all cases and indicated complete transection of tensed medial patellar ligament. All treated animals regain normal posture and were able to walk normally immediately after the procedure.

No post-operative complications were recorded over two months after the procedures in any of the treated animals. Daily examination of the animals in rest and motion revealed no signs of lameness. Minor, unnoticed scar points were present at the points of insertion and exit of the surgical needle. Signs of mild inflammation “mild swelling and redness” was noticed in one cow which subsides at the second day of the operation. Stifle of the treated animals was normal on manual palpation except for limited tissue movability which may indicate fibrosis.

## DISCUSSION

The procedure presented here is a new minimal MPLS technique. It was performed successively and described in cattle and donkeys. Open and closed MPLD techniques described (RamaKrishna, 1972; Sharma, 1980; Ali and Hashim, 1984; Hanson and Peyton, 1987; Turner and McIlwraith, 1989 and Naveen et al., 2013) are the most common performed techniques for treatment of UFP condition in large animals. Both techniques involve skin incision and stifle tissue invasion. The advantage of the present approach is the absence of skin incision, minimal tissue invasion, limited amount of surgical instrumentation needed and speed of execution.

Another technique which is the MPL splitting described by (Tnibar, 2002 and Andersen and Tnibar, 2016) was presented to avoid invasion of the femoro-patellar joint. The technique is more sophisticated and involves performing under general anesthesia, skin incision and percutaneous splitting the MPL with Bard Parker blade under direct visualization of ultrasound. The present technique was easily performed in the field, performed in standing or lateral recumbent positions with minimal physical or chemical securing, didn't require special instruments and performed under local anesthesia. Anatomical and ultrasonographic findings reported by (Uddin et al., 2009; Kassab and Badawy, 2011) declared that the medial patellar ligament is laying directly underneath the skin, have the smaller width and thickness than the middle and lateral patellar ligaments and the gap between the middle patellar ligament and other two ligaments is more wide and distinct than the groove lies between the

middle and lateral patellar ligaments. Determination of the medial patellar ligament and holding it between the thumb and index fingers with little pressure with the tips of the fingers within the grooves makes the ligament more distinct and facilitates direct insertion of the needle directly underneath the ligament and avoids invasion of the joint. The invasion of the femoro-patellar joint is thought not to occur. If occurs, it is thought to be minimal. Further Ultrasound based study should be established to evaluate the femoro-patellar joint invasion.

Incomplete severing of the ligament is a common intra-operative complication of the blind or closed technique (RamaKrishna, 1972), which necessitates several attempts to sever the ligament completely. The results of present technique showed complete transection of the medial patellar ligament in all treated animals. Bleeding, infection and swelling are common post-operative complications referred to skin incision and tissue invasion (Hanson and Peyton, 1987; Shettko and Trostle, 2000 and Stick, 2006). The present approach was minimally tissue invasive and the subsequent bleeding, infection and swelling were not noticed. The short term gross examination of treated animals showed immediate return of stifle function and

absence of post-operative inflammatory signs.

Placing the animal in lateral recumbency is a disadvantage but it was recommended in cattle in order to avoid sudden movement of the animal during the procedure and as it was easier to allocate the MPL in this position. Further long-term study is required to evaluate this technique with the aid of more advanced diagnostic methods and tools.

## CONCLUSIONS

Upward fixation of patella is a common lameness producing condition with a high incidence in cattle and equine. Surgical desmotomy of the medial patellar ligament is the most reliable treatment for this condition. Several surgical techniques were presented with a potential post-operative complications. The present technique was found to be easy, time and money saving, field applicable, accurate and associated with minor post-operative complications.

## CONFLICT OF INTEREST STATEMENT

All the authors declares that there is no conflict of interest for the presented case repost.

## REFERENCES

- Ali M.A. and Hashim M.A. (1984). Upward fixation of patella in cattle. *Bangladesh Vet. J.*, 18: 69-70.
- Andersen C. and Tnibar A. 2016. Medial patellar ligament splitting in horses with upward fixation of the patella: A long-term follow-up. *Equine Veterinary Journal* 48: 312-314.
- Brooks J.H. (2007). Intermittent Upward Fixation of Patella in the Horse: A Literature Review.
- Curtis RA. (1961). Momentary Upward Fixation of the Patella in a cow, and Treatment by Patellar Desmotomy. *Can. J. Comp. Med. Vet. Sci.* Vol. 25: 314-316.
- Greenough PR. (2016). Patellar Luxation in Cattle. *MSD veterinary manual*. <http://www.msdevetmanual.com/musculoskeletal-system/lameness-in-cattle/patellar-luxation-in-cattle>.
- Hanson R.R. and Peyton L.C. (1987). Surgical correction of intermittent upward fixation of patella in a Barhman cow. *Can. Vet. J.* 28: 675-677.
- Kassab A and Badawy A. (2011). Ultrasonographic anatomy of the patellar ligaments before and after medial patellar desmotomy in buffaloes (*Bos bubalis*). *Emir. J. Food Agric.* 23(5): 460-465.
- Lacorix J.V. (2005). Lauxation of patella. In, Lacorix J.V. editor, *Lameness of the horse*, 186171. *Kashvet E-learning*.
- Madhu1 D.N., Monsang S.W., Singh J. and Pawde A.M. (2012). Bilateral Medial Tibiopatellar Desmotomy in a Colt. *Intas. Polivet.* 13 (II): 264-266 Short Communication.
- Naveen M., Kumar D. D., Shivaprakash B.V., Usturge S.M., Pawar A., Patil N.A. (2013). Comparison of different methods of medial patellar desmotomy in bovines. *Indian Journal of Veterinary Surgery.* 34 (2): 94-96.
- Peitzmeier Maggie, Koontz Z. D., Lynch T. M., Hughes F. E., Slone D. E. (2015). Outcome of medial patellar ligament desmoplasty for treatment of intermittent upward fixation of the patella in 24 horses (2005-2012). *Can Vet J.* 56:193-195.
- Ramakrishna O. (1972). Comparative studies on treatment of chronic subluxation of the patella in buffaloes. *Indian Vet. J.*, 49(11): 1150-3.
- Sharma S.P. (1980). Medial tibiopatellar desmotomy as treatment of stringhalt in ponies. *Indian Vet. J.*, 57: 684-5.
- Shettko, D.L. and Trostle, S.S. (2000). Diagnosis and surgical repair of tibiopatellar luxation in a flock of sheep. *J. Vet. Med. Asso.* 216:564-66.
- Singh A.K., Gangwar A.K., Kh. Sangeeta Devi and Singh H.N. (2015). Studies on incidence and evaluation of the closed medial tibiopatellar desmotomy in lateral recumbency in bovines. *Veterinary world* 15: 221-224.
- Stashak T.S (2002). Upward tibiopatellar fixation. In: *Adam's lameness in horse*, 737-741, 5<sup>th</sup> ed. Lippincott, Williams and Wilkins.
- Stick A.A. (2006). Stifle, in *Aur and Stick editors*, *Equine surgery*. 1325-1326, 3<sup>rd</sup> ed., Saunders Elsevier.
- Tnibar M.A. (2002). Medial tibiopatellar ligament splitting for treatment of upward fixation of the patella in 7 equines. *Veterinary surgery* 31: 462-467.
- Turner A.S. and Mcllwraith C.W. (1989). Medial tibiopatellar desmotomy. In: *techniques in large animal surgery*, 2<sup>nd</sup> ed. Pp 133-135, Lea and Febiger.
- Uddin M.M., Reza, S.M., Islam, N.K., Miazzi, O.F. and Ahmed, S.U. (2009). Surgical anatomical measurements of patellar ligaments for blind method of medial patellar desmotomy of cattle during upward patellar fixation in Bangladesh. *Int. J. Morphol.*, 27(2):311-315.