

Journal of the Hellenic Veterinary Medical Society

Vol 69, No 3 (2018)



Is rumenocentesis a safe technique to collect rumen fluid in dairy cows?

N. PANOUSIS, G. KITKAS, G. E. VALERGAKIS

doi: [10.12681/jhvms.18886](https://doi.org/10.12681/jhvms.18886)

Copyright © 2018, N. PANOUSIS, G. KITKAS, G.E. VALERGAKIS



This work is licensed under a [Creative Commons Attribution-NonCommercial 4.0](https://creativecommons.org/licenses/by-nc/4.0/).

To cite this article:

PANOUSIS, N., KITKAS, G., & VALERGAKIS, G. E. (2018). Is rumenocentesis a safe technique to collect rumen fluid in dairy cows?. *Journal of the Hellenic Veterinary Medical Society*, 69(3), 1135–1140.
<https://doi.org/10.12681/jhvms.18886>

■ Is rumenocentesis a safe technique to collect rumen fluid in dairy cows?

N. Panousis¹, G. Kitkas¹, G.E. Valergakis²

¹*Clinic of Farm Animals, Faculty of Veterinary Medicine, School of Health Sciences,
Aristotle University of Thessaloniki, Thessaloniki, Greece*

²*Laboratory of Animal Husbandry, Faculty of Veterinary Medicine, School of Health Sciences,
Aristotle University of Thessaloniki, Thessaloniki, Greece*

■ Είναι η παρακέντηση της μεγάλης κοιλίας ασφαλής μέθοδος για τη λήψη στομαχικού περιεχομένου στις γαλακτοπαραγωγούς αγελάδες;

N. Πανούσης¹, Γ. Κίτκας¹, Γ.Ε. Βαλεργάκης²

¹*Κλινική Παραγωγικών Ζώων, Τμήμα Κτηνιατρικής, Σχολή Επιστημών Υγείας,
Αριστοτέλειο Πανεπιστήμιο Θεσσαλονίκης, Θεσσαλονίκη*

²*Εργαστήριο Ζωοτεχνίας, Τμήμα Κτηνιατρικής, Σχολή Επιστημών Υγείας,
Αριστοτέλειο Πανεπιστήμιο Θεσσαλονίκης, Θεσσαλονίκη*

ABSTRACT. Subacute ruminal acidosis is a major issue in dairy cattle and a definite diagnosis is only established by measuring the rumen fluid pH, most credibly collected by rumenocentesis. However, due to its invasive nature, there is still some debate whether it is a safe method or poses risks for cows' health and welfare. The aim of the study was to retrospectively evaluate the safety of rumenocentesis as a technique to obtain rumen fluid in dairy cows. Results were derived from 2 studies. In study 1, rumenocentesis was performed in 153 Holstein cows from 12 herds, once, between 10 and 90 days in milk (DIM). In study 2, 83 Holstein cows from a dairy farm were repeatedly subjected to rumenocentesis at 30, 90 and 150 DIM. From the 83 cows that were initially enrolled, 8 were culled before the end of the study for reasons irrelative to rumenocentesis; therefore, 236 rumenocenteses were actually performed in study 2 (3 times in 75

Corresponding Author:

N. Panousis, Clinic of Farm Animals, Faculty of Veterinary Medicine, School of Health Sciences, Aristotle University of Thessaloniki, 541 24 Thessaloniki, Greece.
E-mail: panousis@vet.auth.gr

Αλληλογραφία:

N. Πανούσης, Κλινική Παραγωγικών Ζώων, Τμήμα Κτηνιατρικής, Σχολή Επιστημών Υγείας, Αριστοτέλειο Πανεπιστήμιο Θεσσαλονίκης, 541 24 Θεσσαλονίκη.
E-mail: panousis@vet.auth.gr

Date of initial submission: 24-10-2017
Date of revised submission: 16-11-2017
Date of acceptance: 27-11-2017

cows, twice in 3 cows and once in 5 cows). All cows were monitored for 10 days after rumenocentesis for presence of complications. In addition, daily milk yield was automatically recorded for each cow in study 2 to detect any possible post-rumenocentesis short-term reduction of milk yield. Minor only complications were recorded in 7 cases: in 4/153 (2.61%) and 3/236 (1.27%) rumenocenteses in studies 1 and 2, respectively. Small diameter abscesses in 6 cows (3 in study 1 and 3 in study 2) and a larger one in 1 cow in study 1 were observed. The 3 small abscesses in study 2 were all recorded after the 1st rumenocentesis, at DIM 30. All 7 cases were resolved spontaneously within two weeks. Moreover, short-term daily milk yield of study 2 cows was not affected by rumenocentesis. The conclusion is that rumenocentesis is a safe technique to collect small volume of rumen fluid for SARA diagnosis, which does not compromise cows' health and welfare when appropriately performed.

Keywords: rumenocentesis, safety, complications, ruminal fluid, dairy cows

ΠΕΡΙΛΗΨΗ. Η υποξεία δυσπεπτική οξέωση είναι πολύ σημαντικό νόσημα των γαλακτοπαραγωγών αγελάδων και η διάγνωσή της στηρίζεται στη μέτρηση του pH του περιεχομένου της μεγάλης κοιλίας. Η παρακέντησή της είναι η μέθοδος επιλογής για τη λήψη του, αλλά επειδή αποτελεί μια μικρής έκτασης χειρουργική τεχνική, υπάρχουν ακόμη διαφωνίες ως προς την ασφάλειά της και τον κίνδυνο εμφάνισης επιπλοκών στις αγελάδες. Στόχος της εργασίας ήταν η διερεύνηση της ασφάλειας της παρακέντησης της μεγάλης κοιλίας ως μέθοδος λήψης στομαχικού περιεχομένου. Τα αποτελέσματα προέκυψαν από 2 μελέτες. Στην πρώτη, πραγματοποιήθηκε παρακέντηση σε 153 αγελάδες φυλής Holstein από 12 εκτροφές, μία φορά, μεταξύ της 10ης και της 90ης ημέρας της γαλακτικής περιόδου (DIM). Στη 2η μελέτη χρησιμοποιήθηκαν 83 αγελάδες Holstein από 1 εκτροφή, με στόχο να παρακεντηθούν 3 φορές η κάθε μία, στις 30, 90 και 150 DIM. Λόγω πρόωρης απομάκρυνσης 8 αγελάδων για λόγους άσχετους με την παρακέντηση, έγιναν τελικά 236 παρακεντήσεις: 3 φορές σε 75 ζώα, 2 φορές σε 3 και μία φορά σε 5 αγελάδες. Όλα τα ζώα παρακολουθούνταν επί 10 ημέρες μετά την κάθε παρακέντηση για την παρουσία επιπλοκών. Επιπλέον, στη μελέτη 2 καταγραφόταν καθημερινά η ατομική γαλακτοπαραγωγή για την καταγραφή τυχόν ελάττωσης της παραγόμενης ποσότητας λόγω της παρακέντησης. Επιπλοκές παρατηρήθηκαν μόνον σε 7 περιπτώσεις: σε 4/153 (2.61%) και 3/236 (1.27%) παρακεντήσεις από τις μελέτες 1 και 2, αντίστοιχα. Αφορούσαν σε αποστήματα μικρής (6 ζώα, από 3 στην κάθε μελέτη) και μεγαλύτερης (1 ζώο στη μελέτη 1) διαμέτρου. Τα 3 περιστατικά με αποστήματα της μελέτης 2 καταγράφηκαν μετά την 1η παρακέντηση (στις 30 DIM). Όλες οι 7 περιπτώσεις αποστημάτων υποχώρησαν αυθόρμητα εντός 15 ημερών. Το ύψος της γαλακτοπαραγωγής δεν επηρεάστηκε από την παρακέντηση. Συμπερασματικά, η παρακέντηση είναι ασφαλής μέθοδος για τη λήψη υγρού περιεχομένου από τη μεγάλη κοιλία των αγελάδων όταν πραγματοποιείται κατάλληλα.

Λέξεις ευρετηρίασης: παρακέντηση μεγάλης κοιλίας, επιπλοκές, γαλακτοπαραγωγές αγελάδες

INTRODUCTION

Animal health and welfare are of increased interest in recent years (Thompson, 2005; Lusk and Norwood, 2008). Diagnostic testing procedures could induce pain and fear, responses that could affect welfare status. Therefore, it is appropriate to investigate the potential of diagnostic techniques to adversely affect animal health and welfare relative to the benefit of obtaining diagnostic results (Gianesella et al., 2010).

Subacute ruminal acidosis (SARA) is an issue of major economic and physiological concern in dairy cattle (Nocek, 1997; Enemark, 2008), characterized by ruminal fluid pH between 5.0 and 5.5 (Kleen, 2003). Due to the lack of pathognomonic clinical signs, a definite SARA diagnosis in clinical practice is only established by measuring the rumen's fluid pH, either at a specific time-point after feeding (rumen fluid is collected by stomach tubing or, more credibly, by rumenocentesis) (Duffield et al., 2004) or continuously

(using rumen boluses and pH monitoring systems). The latter is the best method, but still too expensive.

Rumenocentesis is more accurate than rumen tubing because the collected rumen fluid samples are not “contaminated” with varying amounts of saliva (Dirksen and Smith, 1987), which results in inaccurate pH measurements (Nordlund and Garrett, 1994; Oetzel and Nordlund, 1998). Some practitioners may consider the procedure too difficult to use during clinical investigations but it is easy to perform by an experienced clinician. However, it remains a minor surgical procedure and, due to its invasive nature, there is still some debate whether it is a safe method or poses risks for cows' health and welfare. Some authors stated that rumenocentesis can cause complications in the area of the puncture site (Hollberg, 1984; Strabel et al., 2007) and therefore is not an appropriate procedure for obtaining rumen fluid from cows (Strabel et al., 2007), while others that it is a safe procedure with minimal adverse effects for health and milk production (Kleen, 2004; Nordlund, 2007; Giancesella et al., 2010).

Considering the significance of SARA and given the above controversy, the aim of the study was to retrospectively evaluate the safety of rumenocentesis as a technique to obtain rumen fluid in dairy cows.

MATERIALS AND METHODS

This research was conducted with the approval of the review board of the Faculty of Veterinary Medicine, Aristotle University of Thessaloniki. The farmers gave informed consent for the cows to be included in the study and the testing procedures.

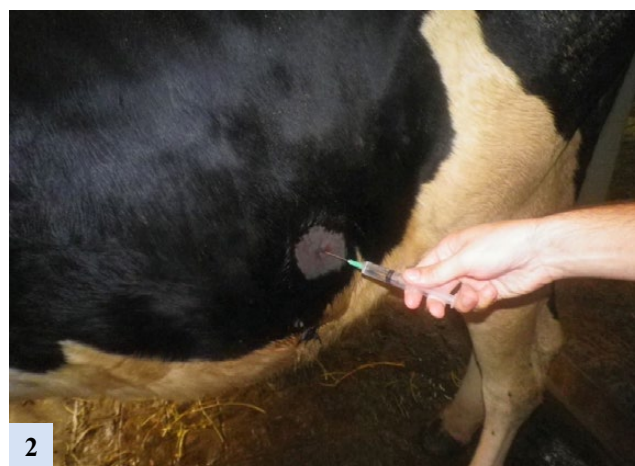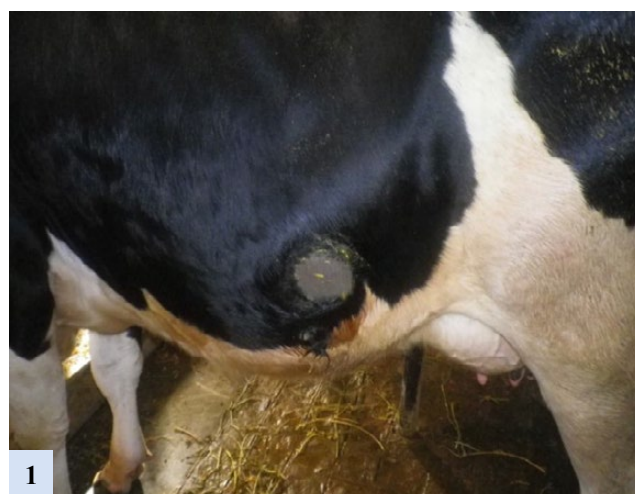
Data were derived from 2 studies. In study 1, rumenocentesis was performed in 153 Holstein cows from 12 herds of Central Macedonia region - Greece, once, between 10 and 90 days in milk (DIM), in order to collect rumen fluid for SARA prevalence assessment (Kitkas et al., 2013). Commencement of study 2 took place approximately 10 months after the completion of study 1. In study 2, which aimed to evaluate SARA prevalence as well as its effect on rumen fatty acids and milk parameters in different stages of lactation, 83 Holstein cows from a dairy farm located in the region of Thessaloniki, Greece, were overall used and repeatedly subjected to rumenocentesis at 30, 90 and 150 DIM. Farm selection was based on history of high SARA prevalence (farm #11, Kitkas et al., 2013). From the 83

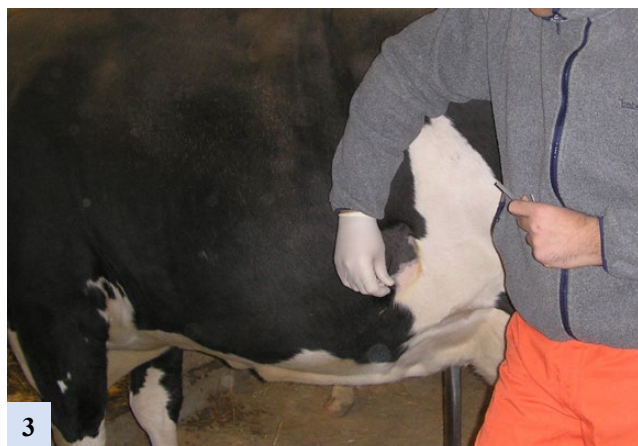cows that were initially enrolled, 8 were culled before the end of the study due to mastitis and/or lameness; therefore, 236 rumenocenteses were actually performed in study 2 (3 times in 75 cows, twice in 3 cows and once in 5 cows).

All cows were randomly chosen as long as they were clinically healthy, based on recent history and a clinical examination prior to each rumenocentesis. The same author performed all 389 rumenocenteses (153 in study 1 and 236 in study 2).

Rumenocentesis was consistently performed 5-8 hours after the morning feeding. Cows were restrained without sedation. The puncture site was located 10-15 cm, according to cow size, behind the last left rib on the horizontal line passing through the stifle. A small area (10 cm x 10 cm) was shaved and disinfected with 7.5% iodine povidone scrub solution (Figure 1).

Local anaesthesia was performed prior to rumenocentesis by injecting 4 mL of 2% Xylocaine





(AstraZeneka, Athens, Greece), containing 20 mg/mL lignocaine hydrochloride, at the puncture site (2 mL subcutaneously and 2 mL intramuscularly) (Figure 2).

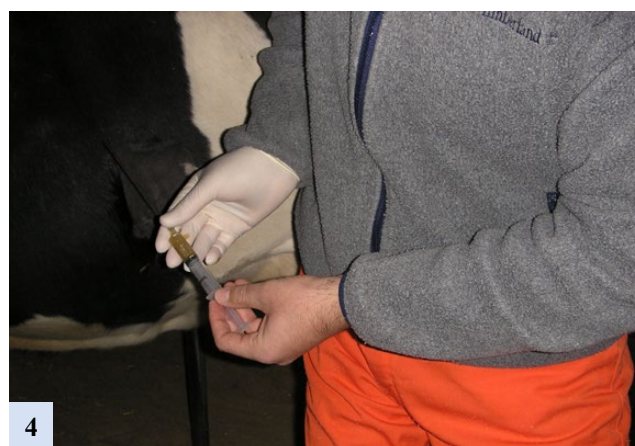Then, a 1.65 x 130 mm stainless steel needle (H. Hauptner & Richard Herberholz GmbH & Co. KG, Solingen, Germany) was inserted through the skin into the rumen (Figure 3). During this procedure, an assistant was raising the cow's tail vertically to her body for better restraint, while in extremely stressed animals a nose holder was additionally applied.

Approximately 2-3 mL of rumen fluid were carefully aspirated, within 20 sec, into a 5 mL plastic syringe (Figure 4).

All cows were monitored for 10 days after rumenocentesis for the presence of rumenocentesis-related complications like peritonitis, hematoma or abscess formation at the puncture site and any other health issue. In case of complication(s), monitoring period was extended until all lesion(s) resolved. In addition, daily milk yield was automatically recorded for each individual cow in study 2, using an automatic milk yield recording system (AfiFarm Herd Management Software®, Afimilk Ltd., Kibbutz Afikim, Israel), to detect any post-rumenocentesis short-term reduction of milk yield during the monitoring period.

RESULTS

Minor only complications were recorded in 7 cases: in 4/153 (2.61%) and 3/236 (1.27%) rumenocenteses in studies 1 and 2, respectively. Small abscesses (<3 cm in diameter) in 6 cows (3 in study 1 and 3 in study 2) and a larger one (ca. 10 cm in diameter) in 1 cow in study 1 were observed. The 3 small abscesses in study 2 were all recorded after the 1st rumenocentesis, at DIM 30. All



7 cases were resolved spontaneously within two weeks. Moreover, short-term daily milk yield of study 2 cows was not affected by rumenocentesis.

DISCUSSION

The objective of the current study was to evaluate whether rumenocentesis, the most accurate method to evaluate rumen pH values for SARA diagnosis, poses health risks for the cows. The disadvantage associated with the technique is that it is quite invasive and could theoretically result in peritonitis (Nordlund and Garrett, 1994; Kleen, 2004), haematoma and abdominal or ruminal wall abscessation at the puncture site (Nordlund and Garrett, 1994; Abdela, 2016).

Hollberg (1984) pathologically examined 47 cows that were slaughtered 1-6 days after rumenocentesis; hemorrhages in the ruminal wall, peritoneal adhesions, peritonitis and hematomas were diagnosed in the area of the puncture site in 41 out of the 47 (87%) cows. However, rumenocentesis in this study was done with a large needle (2.4 x 150 mm) with two side fenestrations at the tip, and a large volume of fluid (200 mL) was collected over a prolonged period (>100 sec). On the contrary, in the present study rumenocentesis technique was performed in a different way: the size of the needles was smaller (1.65 x 130 mm), they had not any side fenestrations, volume of the collected rumen fluid (2-3 mL) was smaller and the duration of the aspiration (<20 sec) was shorter. These differences could explain the low incidence and severity of complications recorded in our research.

In a Swiss study, the clinical status of 11 dairy cows that were subjected to rumenocentesis (using 1.8 x 130 mm needles) was daily evaluated; the preparation of the

puncturing site, the needle size, the technique applied to collect rumen fluid, and its quantity were almost similar with the present study. All cows were slaughtered and necropsied 7 days after rumenocentesis in order to detect possible complications (pathologic lesions) at necropsy (Strabel et al., 2007). The following abnormal clinical signs were diagnosed: increased respiration depth (3 cows), transient episode of hyperthermia (2 cows), increased tension of the abdominal wall (8 cows) and positive foreign body tests (3 cows). One cow was culled on day 7 because of severe generalized septic peritonitis, spreading from the site of rumenocentesis, and hematoma in the area of the puncture site was found in 9 out of 10 cows.

The authors concluded that the severe complications recorded do not legitimate rumenocentesis as a routine procedure for collection of rumen fluid in cows under Swiss conditions. However, besides the unfortunate case of generalized peritonitis, the severity of other signs and lesions recorded could be disputed. The results of the present study that included a large number of cows kept under field conditions showed only minor health complications, in only a few ones, and no adverse effects on milk production.

In contrast to the above studies, Nordlund and Garrett (1994) reported an incidence of subcutaneous abscess formation of only 1-2%, which is in accordance with the present findings of 1.79% abscessation incidence (7 abscesses in 389 rumenocenteses).

Kleen et al. (2004) collected rumen fluid with rumenocentesis from 164 Holstein cows of 19 farms in the Dutch province of Friesland. Local anesthesia with 2 mL of 2% lidocaine was provided to 119 out of the 164 cows. Puncturing site selection and preparation as well as restraint were similar with that applied in the present study. Rumenocentesis was made with 2.1 x 80 mm size needles. The average volume of the aspirated rumen fluid was 14.8 mL (SD 3.6). The proportion of cows not showing complications due to rumenocentesis was significantly higher in animals that received local anaesthesia. Concerning complications, swelling, hematomas and small diameter abscesses were diagnosed in 5/164 (3%) cows. Health status of other 3/164 (1.8%) cows was impaired as they showed depression and reduction of dry matter intake; 1 of those 3 had also elevated rectal temperature and another 1 of the 3 was diagnosed with

left abomasal displacement (LDA) the following of the rumenocentesis day. However, whether LDA is due to rumenocentesis is questioned even by the authors. The lower incidence of complications recorded in our study might be due to the smaller outside diameter of the needles (1.65 vs. 2.1), the smaller volume of aspirated fluid or the experience of the person performing the rumenocenteses.

Duffield et al. (2004) performed rumenocentesis in 16 Holstein cows repeatedly (4 times), at weeks 6, 8, 10 and 12 after calving, in order to compare ruminal pH value collected with different techniques. The puncturing site (left flank, at the level of the stifle and approximately 15 to 20 cm caudoventral to the costochondral junction of the last rib) was surgically prepared and the animals were sedated with xylazine, without application of local anesthesia. Rumenocentesis was done with 1.6 x 125 mm size needles and the aspirated ruminal fluid volume was 2-5 mL. Complications of rumenocentesis were limited to the development of 1 to 2 small (1 to 2 cm) nodular swellings at the puncturing site in approximately 33% of the cows, without any short- or long-term adverse consequences. The finding of the present study, including much more rumenocenteses and cows, that rumenocentesis is a safe technique to collect ruminal fluid is in agreement with the above.

In Italy, Giancesella et al. (2010) performed rumenocentesis in 6 cows and used another 6 as controls, to evaluate the effect of the technique on health, welfare status and milk production of lactating dairy cows. The puncturing site of all cows in both groups was sheared and disinfected, and the rumenocentesis was made without prior local anesthesia, with 2.4 x 105 mm needles. Milk yield and rectal temperature were daily recorded and they were not affected by rumenocentesis. Average superficial skin temperature at the puncturing site increased by 1.0 °C immediately after rumenocentesis and returned to normal level after 48 h, where it remained constantly until the end of the study. These results suggest that rumenocentesis has minimal adverse effects on cows health and production, which is in accordance with our findings.

It seems that the small needle size and volume of collected rumen fluid (enough to determine pH and ruminal fatty acids concentration), as well as the short duration of aspiration were the main underlying factors

responsible for the scarce post-puncture complications recorded in the present study. Additional supporting factors were the skills and experience of the person performing the technique and, possibly, the application of local anesthesia. The fact that this is the only accessible study in literature that uses data from so many observations (389 rumenocenteses in 236 dairy cows), including repeated ones in 75 cows, increases the soundness of the findings.

CONCLUSIONS

Rumenocentesis is a safe technique to collect small volume of rumen fluid for SARA diagnosis, which does not compromise cows' health and welfare when appropriately performed.

CONFLICT OF INTEREST STATEMENT

There is no conflict of interest. ■

REFERENCES

- Abdela N (2016) Sub-acute Ruminal Acidosis (SARA) and its Consequence in Dairy Cattle: A Review of Past and Recent Research at Global Prospective. *Achiev Life Sci* 10:187-196.
- Dirksen GU, Smith MC (1987) Acquisition and analysis of bovine rumen fluid. *Bovine Pract* 22:108-116.
- Duffield T, Plaizier JC, Fairfield A, Bagg R, Vessie G, Dick P, Wilson J, Aramini J, McBride B (2004) Comparison of techniques for measurement of rumen pH in lactating dairy cows. *J Dairy Sci* 87:59-66.
- Enemark JMD (2008) The monitoring, prevention and treatment of sub-acute ruminal acidosis (SARA): A review. *Vet J* 176:32-43.
- Gianesella M, Morgante M, Stelletta C, Ravarotto L, Giudice E, Van Saun RJ (2010) Evaluating the Effects of Rumenocentesis on Health and Performance in Dairy Cows. *Acta Vet Brno* 79:459-468.
- Hollberg W (1984) Vergleichende Untersuchungen von mittels SCHAMBYE-SØRENSEN-Sonde oder durch Punktion des kaudovertralen Pansensacks gewonnenen Pansensaftproben. *Dtsch Tierarztl Wochenschr* 91:317-320.
- Kitkas GC, Valergakis GE, Karatzias H, Panousis N (2013) Subacute ruminal acidosis: prevalence and risk G.E. factors in Greek dairy herds. *Iran J Vet Res* 14:183-189.
- Kleen JL, Hooijer GA, Rehage J, Noordhuizen JPT (2003) Subacute ruminal acidosis (SARA): A review. *J Vet Med A* 50:406-414.
- Kleen JL, Hooijer GA, Rehage J, Noordhuizen JP (2004) Rumenocentesis (rumen puncture): a viable instrument in herd health diagnosis. *Dtsch Tierarztl Wochenschr* 111:458-462.
- Lusk JL, Norwood FB (2008) A survey to determine public opinion about the ethics and governance of farm animal welfare. *J Am Vet Med Assoc* 233:1121-1126.
- Nocek JE (1997) Bovine acidosis: implications on laminitis. *J Dairy Sci* 80:1005-1028.
- Nordlund KV (2007) Questions and answers regarding rumenocentesis and the diagnosis of herd-based subacute rumen acidosis. In: *Preconference Seminar 7A: Dairy Herd Problem Investigation Strategies: Lameness, Cow Comfort, and Ruminal Acidosis. 40th Annual Conference of the American Association of Bovine Practitioners, Vancouver, BC, Canada.*
- Nordlund KV, Garrett EF (1994) Rumenocentesis: a technique for collecting rumen fluid for the diagnosis of subacute rumen acidosis in dairy herds. *Bovine Pract* 28:109-112.
- Oetzel GR, Nordlund KV (1998) Methods of evaluating ruminal pH in dairy cattle. In: *Proceedings of the 31st Annual Conference of the American Association of Bovine Practitioners, Rome, GA, USA, p. 203.*
- Strabel D, Ewy A, Kaufmann T, Steiner A, Kirchhofer M (2007) Rumenozentese: Eine geeignete Methode zur pH-Bestimmung im Pansensaft beim Rind? *Schweiz Arch Tierheilkd* 149:301-306.
- Thompson PB (2005) Animal agriculture and the welfare of animals. *J Am Vet Med Assoc* 226: 1325-1327.