


Journal of the Hellenic Veterinary Medical Society

Vol 69, No 3 (2018)



Sesamoid disease in two dogs

A. F. KARKANIS, N. N. PRASSINOS, G. KAZAKOS, M. KTORIS, K. ANTONOPOULOS, N. KRYSTALLI

doi: [10.12681/jhvms.18888](https://doi.org/10.12681/jhvms.18888)

Copyright © 2018, A.F. KARKANIS, N.N. PRASSINOS, G. KAZAKOS, M. KTORIS, K. ANTONOPOULOS, N. KRYSTALLI



This work is licensed under a [Creative Commons Attribution-NonCommercial 4.0](https://creativecommons.org/licenses/by-nc/4.0/).

To cite this article:

KARKANIS, A. F., PRASSINOS, N. N., KAZAKOS, G., KTORIS, M., ANTONOPOULOS, K., & KRYSTALLI, N. (2018). Sesamoid disease in two dogs. *Journal of the Hellenic Veterinary Medical Society*, 69(3), 1148–1154. <https://doi.org/10.12681/jhvms.18888>

Sesamoid disease in two dogs

A.F. Karkanis¹, N.N. Prassinos¹, G. Kazakos¹, M. Ktoris², K. Antonopoulos³, N. Krystalli¹

¹ *Companion Animal Clinic, School of Veterinary Medicine, Faculty of Health Sciences,*

Aristotle University of Thessaloniki, Greece

² *Limassol Veterinary Clinic, Limassol, Cyprus*

³ *Small Animal Clinic, Kalamata, Greece*

Νόσος των σησαμοειδών στον σκύλο.

Αναφορά σε δύο κλινικά περιστατικά

Καρκάνης Α.Φ.¹, Πράσινος Ν.Ν.¹, Καζάκος Γ.¹, Κτωρής Μ.², Αντωνόπουλος Κ.³, Κρυστάλλη Ν.¹

¹ *Κλινική Ζώων Συντροφιάς, Τμήμα Κτηνιατρικής, Σχολή Επιστημών Υγείας, Αριστοτέλειο Πανεπιστήμιο Θεσσαλονίκης*

² *Κτηνιατρική Κλινική Λεμεσού, Κύπρος*

³ *Κλινική Μικρών Ζώων, Καλαμάτα*

ABSTRACT. Two young dogs, a Rottweiler and an Épagneul Breton, presented with chronic forelimb lameness. Orthopaedic examination confirmed the mild lameness and revealed pain on deep palpation at the palmar aspect of the 5th metacarpal. Radiographic evaluation revealed fracture of the 7th metacarpophalangeal sesamoid at the 5th metacarpophalangeal joint. Based on these findings, diagnosis of sesamoid disease was achieved. Both cases had been treated conservatively with restricted activity and anti-inflammatory drugs without any success. Then, resection of the affected sesamoid was performed. The outcome was good and the dogs were free of lameness 1 year post-operatively.

Keywords: dog, metacarpophalangeal joint, sesamoid disease

Corresponding Author:

Karkanis Athanasios DVM, MRCVS

Polygyrou 20, 40 Ekklisies, GR-54636 Thessaloniki, Greece

E-mail: akarkanis@hotmail.com

Date of initial submission: 10-4-2017

Date of revised submission: 25-7-2017

Date of acceptance: 30-7-2-17

ΠΕΡΙΛΗΨΗ. Δύο νεαροί σκύλοι, φυλής Rottweiler και Éragneul Breton προσκομίστηκαν με χρόνια χωλότητα σε πρόσθιο άκρο. Η κλινική εξέταση επιβεβαίωσε την ήπια χωλότητα και αποκάλυψε άλγος στην ψηλάφηση της παλαμιαίας επιφάνειας του 5ου μετακαρπίου. Διενεργήθηκε ακτινολογικός έλεγχος και διαπιστώθηκε κάταγμα του 7ου σσημοειδούς της 5ης μετακαρπιοφαλαγγικής άρθρωσης. Με βάση τα παραπάνω τέθηκε η διάγνωση της νόσου των σσημοειδών. Σε αμφότερα τα περιστατικά είχε προηγηθεί ανεπιτυχής συντηρητική αγωγή, η οποία περιελάμβανε τον περιορισμό της κινητικότητας του ζώου και την ολιγοήμερη χορήγηση αντιφλεγμονωδών φαρμάκων. Ως εκ τούτου εφαρμόστηκε χειρουργική θεραπεία με αφαίρεση του προσβεβλημένου σσημοειδούς. Η έκβαση της χειρουργικής επέμβασης ήταν καλή και για 1 χρόνο μετεγχειρητικά η χωλότητα δεν είχε επανεμφανιστεί.

Λέξεις ευρετηρίασης: μετακαρπιοφαλαγγική άρθρωση, νόσος σσημοειδών, σκύλος

INTRODUCTION

Sesamoid disease (SD) of the metacarpophalangeal (MCP) joints is an uncommon clinical condition of large breed dogs. MCP's sesamoids bones sustain traumatic or degenerative changes (Davis et al. 1969, Berg 1972, Bennett and Kelly 1985, Nickel et al. 1986, Robins 1986, Robins and Read 1993, Weinstein et al. 1995, Mathews et al. 2001, Daniel et al. 2008, Fossum 2013, Evans and de Lahunta 2013, DeCamp et al. 2016). The aetiology of SD is not clear (Read et al. 1992); however, traumatic incidents (fracture, luxation) of the sesamoid bones have recorded in racing Greyhounds in United Kingdom and Australia during the last 30 years (Bateman 1959, Davis et al. 1969, Cannon 1972). The function of the digital flexor tendons on the sesamoid bones at high impact, in which MCP joints are hyperextend, may produce sesamoid's fractures in some dogs (Weinstein et al. 1995, Mathews et al. 2001). Greyhounds and Rottweilers may manifest various disturbances in sesamoid bones and are the most clinically affected breeds by the SD. In other breeds (e.g. Labrador Retriever) these disturbances can be an incidental finding during orthopaedic examination (Bateman 1959, Davis et al. 1969, Berg 1972, Bennett and Kelly 1985, Krooshof and Hazewinkel 1986, Read et al. 1992, Robins and Read 1993, Mathews et al. 2001).

Veterinary literature has restricted information on MCP sesamoid disease. This paper presents two young dogs with forelimb lameness, due to fragmented MCP sesamoid bone, that were treated successfully by sesamoidectomy.

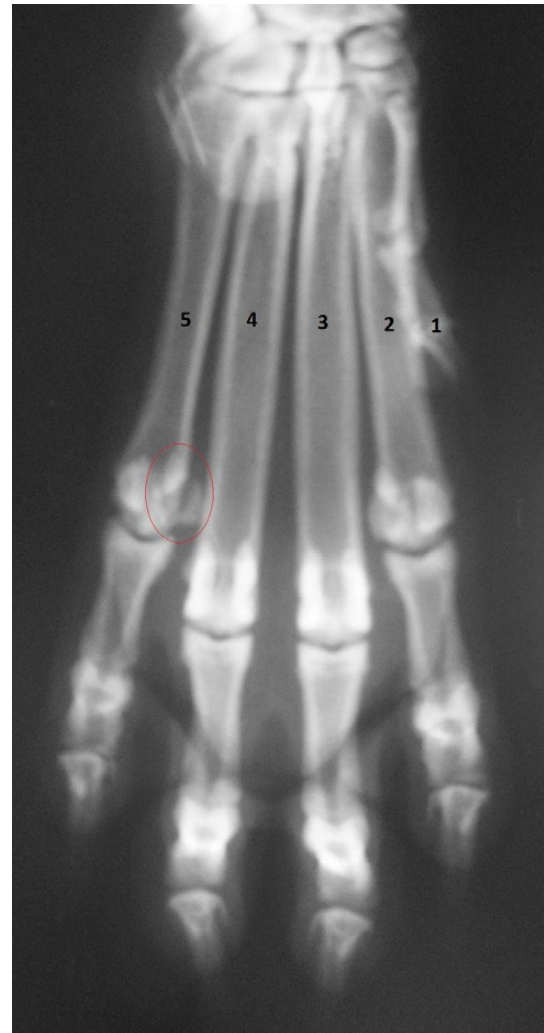

Fig 1: Dorsoventral radiographic view of a comminuted fracture with mild medial displacement of the 7th sesamoid bone at the 4th metacarpophalangeal joint (circled) (Case 1)

Anatomy

The canine forelimb has five MCP joints, one for each digit, numbered from the medial to lateral side. On each of the four main MCP joints there are two elongated, slightly curved palmar sesamoid bones on the ventral aspect and one osseous nodule on the dorsal aspect. Only a single osseous bead is located on the palmar side of the metacarpophalangeal joint of the first digit. The palmar sesamoids bones of the main digits (2nd -5th) are numbered from 1 to 8, from medial to lateral (Evans and de Lahunta 2013).

The shape of the palmar sesamoid bones varies. The tension that occurs on the 2nd and 7th sesamoid is excessive in contrast to the other sesamoids, due to the flat articular surface and the anatomic relation with the digital flexor tendons of the 2nd and the 5th digit (Nickel et al. 1986, Robins and Read 1993).

CASE HISTORY

Case 1

A female Rottweiler, of 37 kg body weight and 1-year-old, presented due to right forelimb lameness of 3 months duration. It was acute on onset and was getting progressively worse. Lameness improved after the administration of corticosteroids 3.5 weeks ago, due to anaphylactic reaction, but relapsed after treatment completion. The dog was being fed dry commercial food, raw meat and calcium supplements.

Orthopaedic examination revealed mild lameness (3/5) of the right forelimb and severe pain on deep palpation at the palmar aspect of the 5th distal metacarpal. The dorsoventral radiograph of the paw revealed a comminuted fracture of the 7th sesamoid bone with mild medial displacement (Figure 1).

The affected sesamoid was surgically removed (Figure 2) and a Robert Jones bandage was applied for 10 days. Amoxicillin plus clavulanic acid (Synulox, Zoetis, 15 mg/kg b.w., p.o., BID, for 6 days) and caprofen (Rimadyl, Zoetis, 2.2 mg/kg b.w., p.o., SID, for 5 days) were prescribed. Histopathology of the removed sesamoid showed the presence of callus consistent with old fracture(s) and no bone necrosis. This was insufficient to diagnose osteochondrosis or degenerative disease of the sesamoid bone.

Case 2

A 10-month-old, 18.5 kg body weight, male, hunting Épagneul Breton presented with left forelimb lameness. Six months ago, two episodes of acute lameness, 4 weeks apart, were recorded 2 days after hunting trial. Both were successfully treated with non-steroid anti-inflammatory drugs (NSAIDs) (Rimadyl, Zoetis, 2.2 mg/kg b.w., p.o., SID, for 15 days), but the lameness relapsed 4 months later. The dog was being fed only dry commercial food.

Orthopaedic examination revealed mild lameness (3/5) of the left forelimb and pain on the palpation at the palmar aspect of the left 5th distal metacarpal bone. The dorsoventral radiograph of the paw showed fracture and lytic areas of the 7th sesamoid bone with mild osteoarthritis in the 5th MCP joint.

Given the chronicity and relapses of the condition, sesamoidectomy was the choice of treatment. A Robert Jones bandage was applied for 10 days. Amoxicillin plus clavulanic acid (15 mg/kg b.w., p.o., BID, for 6 days) and caprofen (2.2 mg/kg b.w., p.o., SID, for 5 days) were given post-operatively.

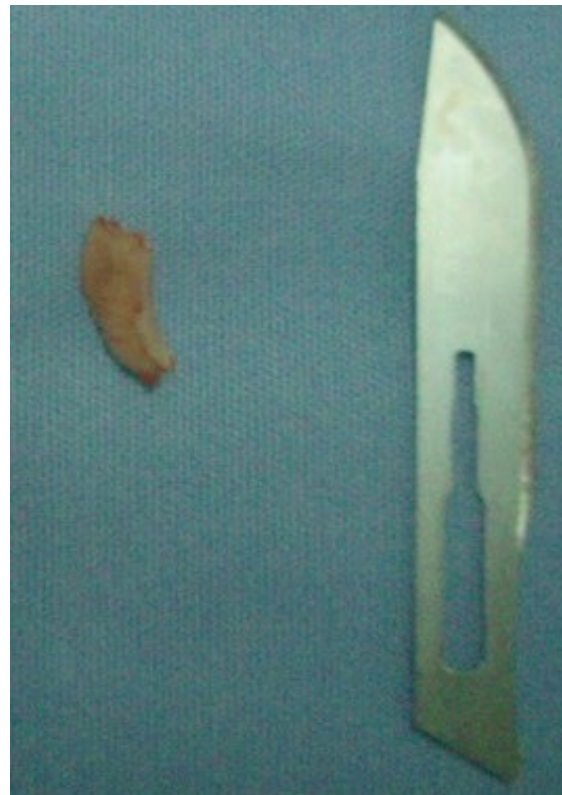

Fig 2: Fragment of the 7th metacarpophalangeal sesamoid after total sesamoidectomy (Case 2).

Two weeks after surgery, both dogs used their forelimb. A low grade lameness was still present, while on the 4th week no lameness was evident. One (case 2) or two (case 1) years post-operatively the dogs remained free of lameness, even after intense exercise.

DISCUSSION

This study reports two cases of canine MCP sesamoid disease that were treated successfully with sesamoidectomy.

Both dogs were young, working and belonged to medium or large breeds. All these data was similar to that published for other cases (Bennett and Kelly 1985), except the medium breed hunting dog No 2. Maybe the use of the dog (i.e. work) and the stress applied to the sesamoid of the MCP joints, was the crucial factor for initiating the disease. The breed that has been extensively studied during the past 30 years is the racing Greyhound, but lately, the Rottweiler breed is the one bringing the most interest results in SD (DeCamp et al. 2016). In a study of 25 dogs with clinical and radiographic findings of SD (mean age: 20 months, range: 7 months – 7.5 years), the breed distribution was 21 Rottweilers, two Greyhounds, one Labrador retriever and one Queensland cattle (Robins and Read 1993). The high incidence of the condition in the Rottweilers may suggest a predisposition for SD, although this may be due to over-representation in the survey sample. Many of them presented for investigation of other orthopaedic problems, such as medial coronoid disease or hip dysplasia (Robins and Read 1993). Predisposition of SD in Rottweilers also confirmed in another study (Read et al 1992). Rarely, this condition occurs in other breeds (DeCamp et al 2016). In our study, due to the small number of cases, the authors cannot deduce the frequency of SD in certain breeds. However, this is the first report of SD in an Épagneul Breton. SD seems to occur more frequently in the right forelimb and appears to be unrelated to the animal's gender (Bateman 1959, Berg 1972, Bennett and Kelly 1985, Robins 1986, Krooshof and Hazewinkel 1986, Vaughan and France 1986, Read et al. 1992, Robins and Read 1993). Our cases were equal distributed concerning these factors. As far as the age concerns, 7% of the dogs will present clinical signs of this condition until the age of 3 months, while 50% will present clinical signs after

the age of 9 months (Read et al. 1992).

The causes of SD in dogs could be traumatic, ossification disorders or degeneration of the MCP joints due to uneven stress distribution, and secondary osteonecrosis because of vascular impairment (Coke and Read 1995, Daniel et al. 2008). Fractures and degeneration disease are probably part of the same clinical problem (Robins 1986). Especially for Rottweilers, fracture of the MCP sesamoid bones is caused by congenital abnormalities, degenerative disease or trauma (Mathews et al. 2001). In our study, fracture of the sesamoids seems to be the cause of the SD, based on history, and histologic (case 1) and/or radiographic findings.

Épagneul Breton (case 2) was too young (approximately 4 months old) when its sesamoid bone fractured. It occurred during a hunting trial, as it is common for hunters to test the 'hunting instinct' of their puppies next to adult hunting dogs at an early age of 5-6 months old. However, this kind of trauma is unusual considering the roughness of the training at this age. Having in mind that fracture of the MCP sesamoids bones could be caused by their congenital abnormalities (i.e. Rottweilers) (Mathews et al. 2001), and lacking of histologic findings in our case 2, we could add in the differential diagnosis that this 'trauma' could potentially be part of a genetic weakness of the sesamoid bones making them more susceptible to injury.

The common presentation of these animals is acute or chronic lameness (Bennett and Kelly 1985), but they may also have no clinical signs (Read et al. 1992). In a study, 73% of Rottweiler puppies had lesions on the sesamoid bones, although only 22% of them presented lameness due to these lesions. The authors concluded that although SD is often sub-clinical, it could cause clinical lameness (Read et al. 1992). The type of lameness in SD varies in duration and severity (Read et al. 1992). Traumatic lesions of the sesamoid bones can cause acute onset, moderate forelimb lameness, and also oedema and pain at the site of trauma. In contrast, degenerative lesions can cause chronic and mild lameness, especially after exercise (Weinstein et al. 1995, Harasen 2009). Fractures and degenerative disease of sesamoid bones have the same clinical signs in chronic patients (Berg 1972, Bennett and Kelly 1985, Robins 1986, Read

et al. 1992, Robins and Read 1993, Cake and Read 1995, Mathews et al. 2001). In this study, cases were classified as chronic due to the initial favourable response to conservative treatment, followed by relapse prior to referral. However, in both dogs, the onset of lameness was acute, which reinforces the traumatic cause of SD. In chronic cases, dogs are weight bearing on the affected limb during exercise and non-weight bearing after it. In acute cases, lameness is moderate with a non-weight bearing lameness of the affected limb (Berg 1972, Bennett and Kelly 1985, Robins 1986, Read et al. 1992, Robins and Read 1993, Cake and Read 1995, Mathews et al. 2001, Fossum 2013). Our dogs presented mild lameness while walking and non-weight bearing on the affected limb while standing.

Palpation of the affected MCP joint reveals the painful area, although this might be subjective to interpretation given the intolerance presented by young dogs to manipulation of the extremities (Read et al. 1992). Especially in puppies, diagnosis of SD is difficult, given their lively behaviour during orthopaedic examination (Read et al. 1992). It is worth mentioning that in chronic cases, SD may cause joint effusion, synovial distention by increasing the volume of synovial fluid and significant reduction of joint flexion angle (Bennett and Kelly 1985, Robins 1986, Read et al. 1992, Cake and Read 1995, Mathews et al. 2001, Kapatkin et al. 2012). During flexion and extension of the affected MCP joint, pain and sometimes crepitus occur (Robins 1986). The only significant orthopaedic finding in our cases was the pain response on the deep palpation of the palmar aspect of the 5th digit. It is very important to consider concurrent subclinical diseases, as these are very common. Thus, in dogs presented with forelimb lameness, it is possible the main cause of lameness to be a concurrent orthopaedic condition and not the SD (Bennett and Kelly 1985, Read et al. 1992, Cake and Read 1995, Mathews et al. 2001).

For the radiographic assessment of the sesamoid bones, two views (dorsovental and mediolateral) of the distal limb are required (Cake and Read 1995), although in our study, the dorsovental view proved sufficient to establish diagnosis. It is always advised to radiograph the contra-lateral limb as the condition is often bilateral, and to have into consideration that

the disease is more obvious in dogs >12 months old (Robins 1986, Read et al. 1992, Robins and Read 1993, Fossum 2013). The abnormal findings at the orthopaedic examination may not correlate with the radiographic view before the age of 9-12 months, and so they cannot be used as markers for the progression of the SD (Read et al. 1992). The radiographic examination of the other forelimb in both cases revealed that the SD was unilateral.

Radiographic findings vary depending on the chronicity and cause of SD (Robins 1986). They might include two or more bone fragments, osteophytes, dorsal displacement of the fragments, calcification of the soft tissue (Cake and Read 1995) or bone necrosis (Robins and Read 1993). However, it is difficult to differentiate between degenerative SD and sesamoid fractures (Robins 1986). In the latter, in the acute cases, the edges of the fragments are sharp, well-defined with irregular or smooth outlines (Robins 1986). Some dogs are born with bipartite sesamoid bones as a congenital anomaly, particularly in the 2nd and 5th digit. This anomaly is not associated with lameness, but it can be misinterpreted at the radiological evaluation of the affected limb (Mathews et al. 2001, Harasen 2009). In other dogs, especially Rottweilers and Greyhounds (Robins 1986), sub-clinical trauma (fractures) or degenerative lesions of the sesamoid bones are incidental findings and likewise can mislead the investigation of the lameness (Harasen 2009). In our cases, the radiographic findings were focused at the 7th sesamoid bone of the 5th digit of the right forelimb. They could be incidental findings but orthopaedic examination did not reveal any other concomitant diseases or injuries to justify the lameness, and also therapeutic management was curative.

Over the last 10 years, several studies compare the results of conservative and surgical treatment of SD (Berg 1972, Bennett and Kelly 1985, Krooshof and Hazewinkel 1986, Vaughan and France 1986, Read et al. 1992, Robins and Read 1993, Mathews et al. 2001, DeCamp et al. 2016). In dogs with intermittent lameness with less than 6 months duration, the condition can be resolved with rest only and over 50% of the cases do not need any further treatment (Berg 1972, Robins and Read 1993, DeCamp et al. 2016). Also, conservative treatment is recommend-

ed for dogs with acute onset lameness, including a bandage on the affected limb, activity restriction (Berg 1972, Bennett and Kelly 1985, Krooshof and Hazewinkel 1986, Read et al. 1992, Robins and Read 1993, Mathews et al. 2001, Riera-Palou 2002, DeCamp et al. 2016) and local glucocorticosteroid injections (Riera-Palou 2002). In dogs with intermittent lameness of more than 6 months duration, the condition is unlikely to be resolved with conservative treatment and total sesamoidectomy is suggested (DeCamp et al. 2016). Also, surgical treatment is suggested for dogs with chronic lameness (Cannon 1972, Berg 1972, Bennett and Kelly 1985, Krooshof and Hazewinkel 1986, Read et al. 1992, Robins and Read 1993, Weinstein et al. 1995, Riera-Palou 2002, Harasen 2009, DeCamp et al. 2016), and when conservative treatment did not resolve the lameness or was just a temporary solution. Both cases presented in this study had received anti-inflammatory drugs before sesamoidectomy, as conservative treatment (case 2 – NSAIDs) or incidentally (case 1 - corticosteroids), but only temporary remission of lameness was achieved. Because lameness was persistent and conservative treatment had failed, sesamoidectomy was applied as definitive treatment. However, it must be pointed out that anti-inflammatory treatment of the first case was not sufficient for SD, as the medication was given for a very short period of time after the anaphylactic shock.

Generally, prognosis of SD is guarded. The results of sesamoidectomy are favourable (Berg 1972, Bennett and Kelly 1985, Robins 1986, Nickel et al. 1986, Fossum 2013, Evans and de Lahunta 2013, DeCamp et al. 2016), but even with this treatment lameness may relapse after intense exercise (Robins 1986). Failure of surgical treatment is due to adhe-

sions in multiple ligaments of the sesamoid bones that are responsible for the MCP joint stability. As a result, osteoarthritis of the MCP joint occurs (Fossum 2013) leading to thickening of the capsule and reduced range of motion (Robins 1986). Mathews et al. (2001) suggested that sesamoidectomy of the fragmented sesamoid, gradually will cause more advanced radiographic degenerative joint changes of the affected MCP joint and less clinical improvement than the conservative treatment, where the lameness will be resolved or improved clinically in most cases. According to these authors, the successful outcome of sesamoidectomy in our cases may be associated with the short clinical and radiographic follow-up, as the development of osteoarthritic changes in the affected MCP joint are more apparent in chronic cases. Whether and when the dog will develop degenerative joint disease of the affected MCP joint after sesamoidectomy is unknown.

CONCLUSIONS

In conclusion, regardless of the chronicity of the case, SD could be treated conservatively initially and if lameness persists or relapses, sesamoidectomy can be performed usually leading to a sound dog.

ACKNOWLEDGEMENTS

We would like to thank George Tsimopoulos (DVM) and Panagiotis Kosmas (DVM, PhD) for their contribution in data collection.

CONFLICT OF INTEREST STATEMENT

All the authors declares that there is no conflict of interest for the presented case report. ■

REFERENCES

- Bateman JK (1959) Fractured sesamoids in the Greyhound. *Vet Rec* 71: 101-105.
- Bennett D, Kelly DF (1985) Sesamoid diseases a cause of lameness in young dogs. *J Small Anim Pract* 26: 567-579.
- Berg JA (1973) Fractures of palmar and plantar sesamoid bones as a cause of lameness in the dog. *J Am Vet Med Assoc* 163: 968-970.
- Cake MA, Read RA (1995) Canine and human sesamoid disease. *Vet Comp Orthop Traumatol* 8: 70-75.
- Cannon JR (1972) Stress Fractures in the Greyhound. *Aust Vet J* 48: 244-250.
- Daniel A, Read RA, Cake MA (2008) Vascular foramina of the metacarpophalangeal sesamoid bones of Greyhounds and their relationship to sesamoid disease. *Am J Vet Res* 69: 716-721.
- Davis PE, Bellenger CR, Turner DM (1969) Fractures of the sesamoid bones in the Greyhound. *Aust Vet J* 45: 15-19.
- DeCamp CE, Johnson SA, Dèjardin LM, Schaefer SL (2016) Fractures and other orthopaedic conditions of the carpus, metacarpus, and phalanges. In: *Handbook of Small Animal Orthopaedics and Fracture Repair*, 5th ed. Elsevier, St Louis, pp. 427-433.
- Evans HE, de Lahunta A (2013) *Miller's Anatomy of the Dog*, 4th ed. WB Saunders, St Louis, pp. 136-140.
- Fossum TW (2013) Management of specific fractures. In: *Small Animal Surgery*, 4th ed. Mosby, St. Louis, pp. 1163-1168.
- Harasen G (2009) Sesamoid disease. *Can Vet J* 50: 10.
- Kapatkin AS, Garcia-Nolen T, Hayashi K (2012) Carpus, metacarpus, and digits. In: (Tobias KM, Johnston SA eds) *Veterinary Surgery. Small Animal*. WB Saunders, St. Louis, pp. 792-793.
- Krooshof Y, Hazewinkel HA (1986) Diagnosis and treatment of sesamoid bone fractures in the dog foot. *Tijdschr Diergeneesk* 111: 1167-1172.
- Mathews KG, Koblik PD, Whitehair JG, Kass PH, Bradley C (2001) Fragmented palmar metacarpophalangeal sesamoid in dogs: a long-term evaluation. *Vet Comp Orthop Traumatol* 14: 7-14.
- Nickel R, Schumer A, Seiferle E (1986) *The Anatomy of the Domestic Animals, the Locomotor System of the Domestic Mammals*. Verlag Paul Parey, Berlin, pp 169-231.
- Read RA, Black AP, Armstrong SJ, MacPherson GC, Peek J (1992) Incidence and clinical significance of sesamoid disease in Rottweilers. *Vet Rec* 130: 533-535.
- Riera-Palou G (2002) What is your diagnosis? *J Small Anim Pract* 43: 239, 254.
- Robins GM (1986) Sesamoid disease. *Aust Vet Pract* 16: 200.
- Robins GM, Read RA (1993) Diseases of the sesamoid bones. In: (Bojrab MJ ed) *Disease Mechanisms in Small Animal Surgery*, 2nd edn. Lea & Febiger, Philadelphia, pp. 1094-1101.
- Vaughan LC, France C (1986) Abnormalities of the volar and plantar sesamoid bones in Rottweilers. *J Small Animal Pract* 27:551.
- Weinstein MJ, Mongil CM, Smith GK (1995) Orthopedic conditions of the Rottweiler. Part I. *Compend Contin Educ Pract Vet* 17: 813-828.