

## Journal of the Hellenic Veterinary Medical Society

Vol 69, No 4 (2018)



### Thymoma associated exfoliative dermatitis in a rabbit with hepatic cirrhosis

A. Komnenou, J. Androulakis-Kess, R. Farmaki, D. Psalla, V. Psychas

doi: [10.12681/jhvms.19622](https://doi.org/10.12681/jhvms.19622)

Copyright © 2019, A. KOMNENOU, J. ANDROULAKIS-KESS, R. FARMAKI, D. PSALLA, V. PSYCHAS



This work is licensed under a [Creative Commons Attribution-NonCommercial 4.0](https://creativecommons.org/licenses/by-nc/4.0/).

### To cite this article:

Komnenou, A., Androulakis-Kess, J., Farmaki, R., Psalla, D., & Psychas, V. (2019). Thymoma associated exfoliative dermatitis in a rabbit with hepatic cirrhosis. *Journal of the Hellenic Veterinary Medical Society*, 69(4), 1309–1316. <https://doi.org/10.12681/jhvms.19622>

## **Thymoma associated exfoliative dermatitis in a rabbit with hepatic cirrhosis.**

**A. Komnenou<sup>1</sup>, J. Androulakis-Kess<sup>1</sup>, R. Farmaki<sup>2</sup>, D. Psalla<sup>3</sup>, V. Psychas<sup>3</sup>**

<sup>1</sup> *Department of Exotic and Wild Animals Medicine, Faculty of Veterinary Medicine, School of Health Sciences, Aristotle University of Thessaloniki, Greece.*

<sup>1</sup> *Department of Exotic and Wild Animals Medicine, Faculty of Veterinary Medicine, School of Health Sciences, Aristotle University of Thessaloniki, Greece.*

<sup>2</sup> *Companion Animal Clinic, Faculty of Veterinary Medicine, School of Health Sciences, Aristotle University of Thessaloniki, Greece.*

<sup>3</sup> *Department of Pathology, Faculty of Veterinary Medicine, School of Health Sciences, Aristotle University of Thessaloniki, Thessaloniki, Greece.*

<sup>3</sup> *Department of Pathology, Faculty of Veterinary Medicine, School of Health Sciences, Aristotle University of Thessaloniki, Thessaloniki, Greece.*

## **Αποφολιδωτική δερματίτιδα λόγω θυμώματος σε κουνέλι με κίρρωση του ήπατος.**

**A. Κομνηνού<sup>1\*</sup>, Ι. Ανδρουλάκης-Kess<sup>1\*</sup>, Ρ. Φαρμάκη<sup>2</sup>, Δ. Ψάλλα<sup>3</sup>, Β. Ψύχας<sup>3</sup>**

<sup>1</sup> *Κλινική Εξωτικών Ζώων και Αγρίας Πανίδας, Τμήμα Κτηνιατρικής, Σχολή Επιστημών Υγείας, Αριστοτέλειο Πανεπιστήμιο Θεσσαλονίκης, Θεσσαλονίκη.*

<sup>1</sup> *Κλινική Εξωτικών Ζώων και Αγρίας Πανίδας, Τμήμα Κτηνιατρικής, Σχολή Επιστημών Υγείας, Αριστοτέλειο Πανεπιστήμιο Θεσσαλονίκης, Θεσσαλονίκη.*

<sup>2</sup> *Κλινική Ζώων Συντροφιάς, Τμήμα Κτηνιατρικής, Σχολή Επιστημών Υγείας, Αριστοτέλειο Πανεπιστήμιο Θεσσαλονίκης, Θεσσαλονίκη.*

<sup>3</sup> *Εργαστήριο Παθολογικής Ανατομικής, Τμήμα Κτηνιατρικής, Σχολή Επιστημών Υγείας, Αριστοτέλειο Πανεπιστήμιο Θεσσαλονίκης, Θεσσαλονίκη.*

<sup>3</sup> *Εργαστήριο Παθολογικής Ανατομικής, Τμήμα Κτηνιατρικής, Σχολή Επιστημών Υγείας, Αριστοτέλειο Πανεπιστήμιο Θεσσαλονίκης, Θεσσαλονίκη.*

*Corresponding Author:*

A. Komnenou, J. Androulakis-Kess  
Department of Exotic and Wild Animals Medicine, Faculty of Veterinary Medicine,  
School of Health Sciences, Aristotle University of Thessaloniki, Greece.  
Email: natakomn@vet.auth.gr, jason.androulakis@hotmail.com

*Date of initial submission: 20-9-2017*  
*Date of revised submission: 23-10-2017*  
*Date of acceptance: 2-11-2017*

**ABSTRACT.** A 6.5-year-old, male, non-castrated pet rabbit was presented with generalized exfoliative dermatitis, depression and anorexia. Skin laboratory examinations were negative for ectoparasites, bacteria and fungi whereas thoracic radiography revealed a large mediastinal mass. Complete blood and biochemical examinations did not show anything abnormal. Thymoma was suspected and therapeutic options were discussed but the owner declined. Supportive and symptomatic therapy was of no avail and severe deterioration of systemic symptoms necessitated euthanasia. Necropsy revealed a whitish-gray mass on the anterior and lower part of the mediastinum and pale voluminous liver. Histopathology confirmed the presence of thymoma and the hypothesis of thymoma-associated exfoliative dermatitis along with hepatic cirrhosis.

**Keywords:** Rabbit, Thymoma, Dermatitis, Paraneoplastic, Cirrhosis

**ΠΕΡΙΛΗΨΗ.** Ένα κατοικίδιο κουνέλι 6.5 ετών, αρσενικό, ακέραιο προσκομίστηκε με γενικευμένη αποφολιδωτική δερματίτιδα, κατάπτωση και ανορεξία. Οι εργαστηριακές εξετάσεις του δέρματος ήταν αρνητικές για εξωπαράσιτα, βακτήρια και μύκητες, ενώ στην ακτινογραφία του θώρακος παρατηρήθηκε ευμεγέθης μάζα στο μεσοπνευμόνιο. Η γενική εξέταση αίματος και οι βιοχημικές εξετάσεις δεν εμφάνιζαν αποκλίσεις από τις φυσιολογικές τιμές. Υπήρξαν ισχυρές υποψίες για θύμωμα και οι θεραπευτικές επιλογές συζητήθηκαν, αλλά ο ιδιοκτήτης αρνήθηκε. Η υποστηρικτική και συμπτωματική θεραπεία αποδείχθηκαν αναποτελεσματικές, γεγονός το οποίο, και σε συνδυασμό με την σοβαρή επιδείνωση των συστηματικών συμπτωμάτων καθιστούσαν αναγκαία την ευθανασία του ζώου. Κατά τη νεκροψία παρατηρήθηκε μάζα λευκόφαιου χρώματος στο πρόσθιο και κοιλιακό τμήμα του μεσοπνευμόνιου, καθώς και ωχρο και διογκωμένο ήπαρ. Οι ιστοπαθολογικές εξετάσεις επιβεβαίωσαν την ύπαρξη θυμώματος και έθεσαν διάγνωση παρανεοπλασματικής αποφολιδωτικής δερματίτιδας λόγω θυμώματος, σε συνδυασμό με κίρρωση του ήπατος.

**Λέξεις ευρετηρίασης:** Κουνέλι, Θύμωμα, Δερματίτιδα, Παρανεοπλασματική, Κίρρωση

## INTRODUCTION

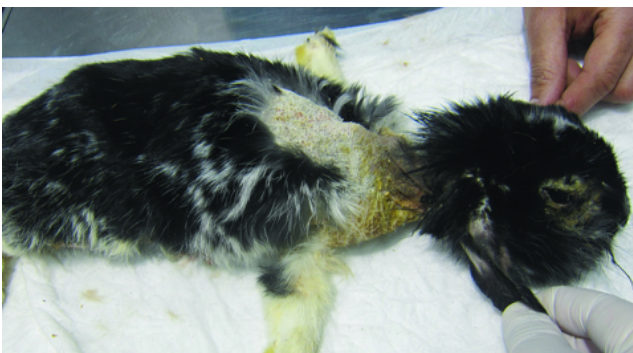Exfoliative dermatitis in rabbits is a challenging multifactorial disease that can be attributed to malnutrition, ectoparasitosis, dermatophytosis, cheyletiellosis, Malassezia dermatitis, sebaceous adenitis (Jassies-van der Lee et al., 2009; Miller et al., 2013), dermatosis with response to zinc (Bentley and Grubb, 1991), epitheliotropic lymphoma (White et al., 2000), erythema multiforme (Scott, 2010), or can be associated with mediastinal (Florizoone, 2005; Rostaher-Prélaud et al., 2013) and interface hepatitis (Florizoone et al., 2007). Paraneoplastic exfoliative dermatitis in rabbits is rare in veterinary medicine. Five cases have been reported to this point, from which only 4 were completely diagnosed with a post-mortem histopathological examination. One was consistent with thymic lymphoma (Rostaher-Prélaud et al., 2013) and the other 3 were thymomas (Florizoone, 2005; Rostaher-Prélaud et al., 2013). Thymoma, though uncommon, is the most

common mediastinal mass in rabbits (Clippinger et al., 1998; Morrissey and McEntee, 2005). Diagnostic approach requires a prompt history, a careful clinical and dermatological examination, imaging and biopsy to confirm diagnosis. Additionally, only two exfoliative dermatitis cases have been related to hepatitis; one was described as interface hepatitis and was comparable to autoimmune hepatitis in man (Florizoone et al., 2007), and the other was of non-immune-mediated origin (Isasi et al., 2012). To the authors' knowledge, this is the first case of paraneoplastic exfoliative dermatitis in rabbit related to thymoma along with hepatic disease.

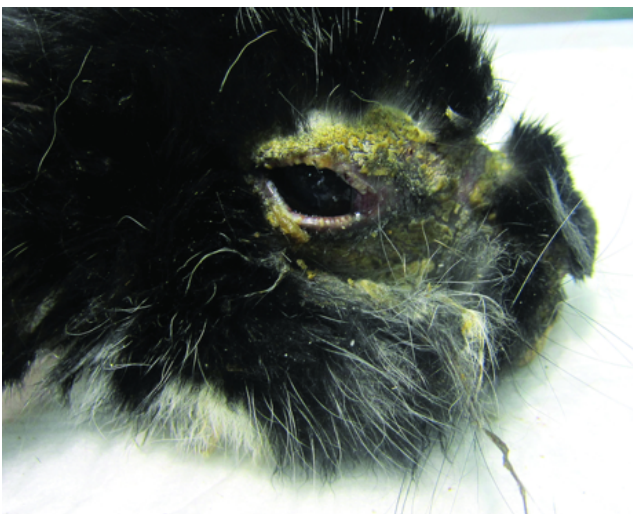
## CASE HISTORY

A 6.5-year-old, male, non-castrated pet rabbit, weighing 1.7 kg, was referred to our Clinic with a history of at least one month non pruritic scaly dermatitis and blepharitis, accompanied with anorexia and depres-

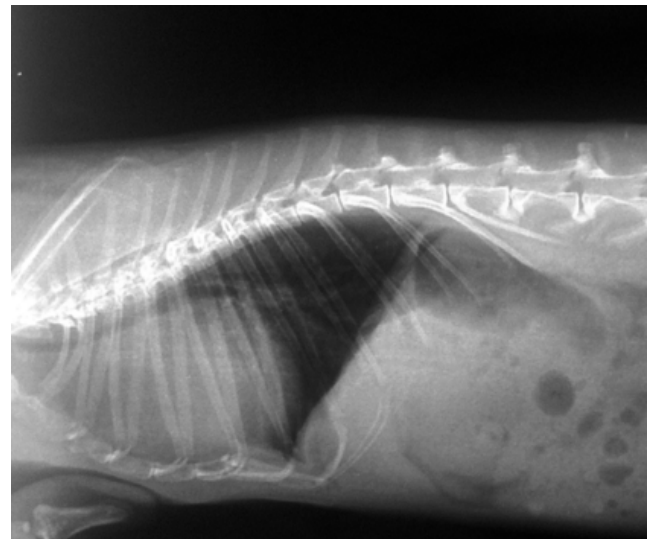sion the last week. The rabbit was not vaccinated or dewormed, fed a balanced diet, that included hay/pellet and fresh fruits and vegetables, and housed indoors with two other female rabbits, but in an individual enclosure. The other rabbits were clinically healthy, since they did not exhibit clinical signs of any type. According to the history demodicosis was suspected based on a positive skin scraping and antiparasitic therapy with ivermectin (Valaneq<sup>®</sup>, Merial) 0.4 mg/kg SC twice every 15 days was started. However, since no improvement was seen additional therapy was suggested by the referring veterinarian including fusidic acid eye ointment (Fucidin<sup>®</sup>, Leo Pharmaceutical Hellas S.A.) BID, dexpathenol cream (Bepanthol<sup>®</sup>, Bayer AG) BID and enrofloxacin (Baytril<sup>®</sup>, Bayer Animal Health GmbH) 5 mg/kg PO SID for the last three days but this also was of no avail. No medication had been given before the appearance of skin lesions.



**Fig 1:** Hypotrichosis in the base of ear pinnae, alopecia over the neck region along with erythema and scaling.



**Fig 2:** Symmetrical periocular lesions characterized by alopecia, crusting, scaling and erythema

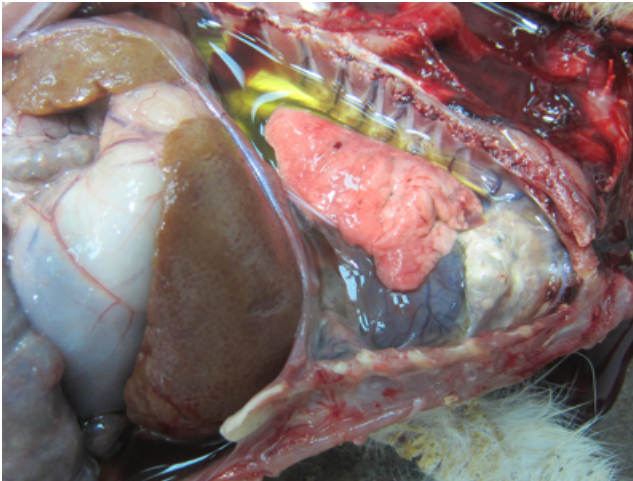


**Fig 3:** Lateral chest radiograph: Soft tissue mass in the cranial mediastinum. Notice the characteristic elevation of the trachea.

Upon clinical examination generalized non-pruritic dermatitis, depression, weight loss and reluctance to move were noticed. Skin lesions were characterized by hypotrichosis, alopecia, erythema, copious whitish scales, crusting and follicular casts. The main affected areas were the face, the neck, the sternum, the dorsum, the abdomen and the inner thighs (Figure 1). Severe bilateral erythroderma of the eyelids, blepharedema, periocular crusting and scaling dermatitis, blepharitis and mucopurulent ocular discharge were also observed, whereas a superficial corneal ulcer and cataract were also present in the left eye (Figure 2). Multiple superficial and deep skin scrapings from the lesional areas, acetate tape impression smears, trichograms and a DTM culture were negative for parasites, bacteria and fungi. Thorax auscultation as well as the palpation of the abdomen, appeared normal. Complete blood and biochemical examinations did not show anything abnormal. Lateral and ventrodorsal thoracic radiography revealed a space-occupying mediastinal mass in the cranial thoracic cavity (Figure 3).

A paraneoplastic exfoliative dermatosis due to systemic causes was suspected, whereas the differential diagnosis included thymoma, thymic lymphoma, epitheliotropic lymphoma and/or hepatitis. Multiple skin biopsies to confirm diagnosis and surgical removal of the mass were recommended, but the owner declined due to possible fatal side effects.

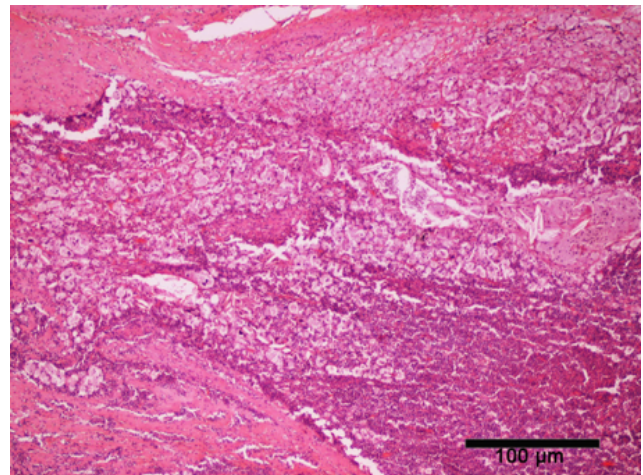
Symptomatic treatment and supportive therapy initiated



**Fig 4:** Non-homogeneous, greyish mass occupying the lower, anterior mediastinum, compatible with thymoma.

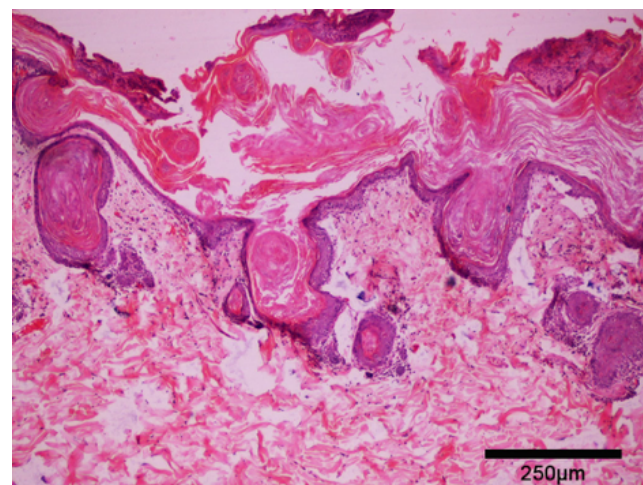
with rehydration fluids: Lactated Ringer's Solution iv, along with antibiotics: enrofloxacin (Baytril®, Bayer Animal Health) 5mg/kg PO BID for 15 days, meloxicam (Novacam®, AST Pharma) 0.25mg/kg SID for 7 days and probiotics (Florentero®, Candioli) 1 cc PO SID. Local ophthalmic treatment with azythromycin (Azyter® eye drops, Laboratoires Thea) in the left eye for 3 days and tobramycin (Tobrex® eye ointment, Alcon) TID for 7 days in both eyes were also administered. To improve the intense desquamation of the area, 30% propylene glycol, applications over the head were performed. Force feeding with critical care diet (Critical Care®, Oxbow), high-fiber supplements (Immune support®, Oxbow) 1tab PO SID, antiseborrheic shampoo (Douxo Séborrhée® Shampooing, Sogeval) once weekly as well as daily change of the substrate were also recommended. Upon re-examination 45 days later, severe deterioration of systemic signs and radiography findings along with severe dyspnea, necessitated euthanasia.

On necropsy, a non-homogeneous, whitish-gray mass measuring 3 x 3 x 2.5 cm was detected in the anterior and lower part of the mediastinum. Free flowing, clear liquid was present in the thoracic and abdominal cavity. The lungs were emphysematous and the liver appeared discoloured (Figure 4). Histopathology of the mass revealed a moderately cellular neoplasm composed of a dual population of polygonal and round cells arranged in small nests and trabeculae. Polygonal cells had distinct cell borders, abundant eosinophilic cytoplasm and basophilic nuclei. Round had indistinct cell borders, a variable amount of granular eosinophilic

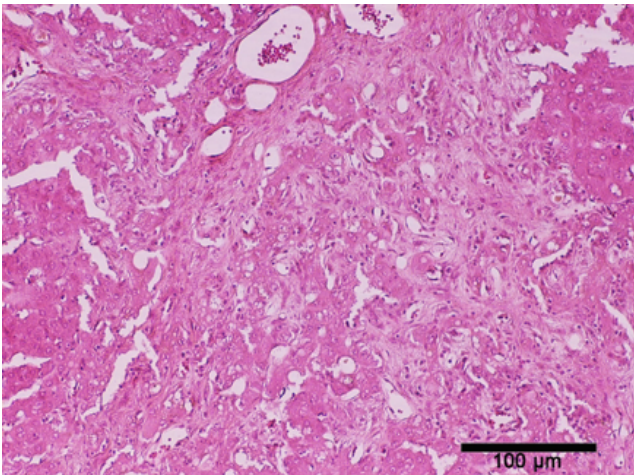


**Fig 5:** Histo thymus: neoplastic population of large epithelial cells arranged in small nests and trabeculae disrupt the normal thymic architecture. Haematoxylin-eosin staining, bar=100μm.

cytoplasm, round to oval nuclei with finely-stippled chromatin and one variably distinct nucleolus. Multifocally scattered throughout the neoplasm were many tingible body macrophages (Figure 5). Histopathological examination of skin samples showed transepidermal and follicular apoptosis with severe hyperkeratosis, mild to moderate lymphoplasmacytic dermatitis and generalized absence of sebaceous glands (Figure 6). Moreover, histological examination of the liver showed distortion of the hepatic architecture. Specifically, portal areas were markedly expanded and adjacent portal triads were bridged with bands of poorly cellular con-



**Fig 6:** Histo skin: severe hyperkeratosis and mild infiltration by lymphocytes and plasma cells. Haematoxylin-eosin staining, bar=250μm.



**Fig 7:** Histo liver: hepatic architecture is distorted due to severe fibrosis. Haematoxylin-eosin staining bar=100 $\mu$ m.

nective tissue, rich in collagen and blood vessels (bringing fibrosis). Multifocally, fibroblasts disrupted the limiting plate and extended into the adjacent periportal parenchyma and separated, surrounded, and replaced hepatocytes that were often degenerate with swollen vacuolated cytoplasm or necrotic with shrunken hyperosinophilic cytoplasm and karyolytic or karyorrhectic nuclei. Areas of fibrosis were multifocally infiltrated by scattered lymphocytes and neutrophils. Hepatocytes exhibited a degree of atypia (mild anisocytosis and anisocariosis, occasionally more than one prominent nucleolus) (Figure 7).

Based on the localization of the mediastinal mass and the histological findings, the diagnosis of mixed lymphoepithelial thymoma and thymoma-associated exfoliative dermatitis, along with hepatic cirrhosis was established.

## DISCUSSION

Thymomas and thymic lymphomas represent the primary mediastinal masses in rabbits (Clippinger et al., 1998; Florizoone, 2005; Morrisey and McEntee, 2005). To date, they appear to be more common than previously reported, though there is still not much information about their frequency of occurrence (Künzel et al., 2012; Snook et al., 2013). Signs of disease differ from those seen in other species such dogs, cats or humans (Clippinger et al., 1998; Florizoone, 2005). Main signals include dyspnea, fatigue, depression and characteristically bilateral exophthalmos as a result of

precaval syndrome (Clippinger et al., 1998; Morrisey and McEntee, 2005). Oedema of the neck, head, and forelimb, lack of appetite, coughing and bilateral prolapse of the third eyelid may also be present. Auscultation of the thorax may reveal muffled heart sounds or a heart murmur, and diminished lung sounds, due to the decreased compressibility of the chest (Florizoone, 2005; Künzel et al., 2012). Even though many of the above symptoms were present in our case, thymoma was not in the first line, since there was absence of exophthalmos, no dyspnea and auscultation findings on admission. Only upon re-examination, further distention of the mediastinal mass resulted in severe dyspnea.

Radiographs, ultrasonography and CT are used for the diagnostic imaging of mediastinal masses in rabbits. In thoracic radiographs, a soft-tissue mass in the cranial mediastinum is visualised, which causes a characteristic elevation of the trachea, findings compatible with our case. Its consistency can be verified via ultra-sonography. Ultrasound-guided FNA may be diagnostic and give good information about the mass origin, unless there are too few cells for an evaluation (Künzel et al., 2012). Cross-sectional imaging with CT provides the most detailed information regarding the full extent of the disease and consistency of the mass (Weisbroth, 1994). Diagnostic cytology may reveal variably sized well-differentiated lymphocytes and epithelial cells, as well as mast cells, eosinophils, macrophages, melanocytes, plasma cells and neutrophils (Zitz et al., 2008). Definite diagnosis of lymphoma requires fine needle aspiration or biopsy. In lymphoma, which is the primary differential for a cranial mediastinal mass in a rabbit, small, mature lymphocytes are dominant (Florizoone et al., 2005; Rostaher-Prélaud et al., 2013). In our case diagnosis was guided only by radiographs, since the owner declined any more exams in the first place.

Liver disease has been also incriminated to cause exfoliative dermatitis in rabbits. More specifically, this has been observed in one rabbit with interface hepatitis comparable to human autoimmune hepatitis (Florizoone et al., 2007), and another in a rabbit with bacterial chronic hepatitis (Isasi et al., 2012). The mechanisms of this condition are still under speculation. It appears to be related to an immune-mediated response in which T-cells, originating from the internal organs, affect the cells in the dermis and epidermis (Isasi et al., 2012). In our case hepatic cirrhosis could be attributed to several

causes. However, post mortem and histopathological examination excluded parasitic and bacterial disease as well as neoplasia and liver lipidosis. Interface hepatitis can be associated with hepatocytic damage, necrosis and progressive fibrosis that ultimately leads to liver cirrhosis. Nevertheless, at this point the cause of the fibrotic process of the liver is difficult to establish.

In affected with thymoma rabbits there aren't any significant changes in hematology, serum and biochemistry tests (Künzel et al., 2012). Hypercalcemia has been previously discussed, but a possible influence of diet and Ca metabolism on the serum concentration of calcium in rabbits has not been taken into consideration (Weisbroth, 1994; Rosenthal et al., 1995). Hyperglycemia may be present but it is considered to be stress-induced (Künzel et al., 2012). Thus far, immune disorders have not been described in rabbits with these tumours. In addition, hepatic disorders can be challenging to diagnose via basic serum biochemistry findings, as there are no liver-specific enzymes in the rabbit (Vennen and Mitchell, 2009). In our case complete blood and biochemical examinations were not conclusive. Total bilirubin and  $\gamma$ -GT may be useful combined with ultrasonography (Harkness et al., 2010). However, they are usually not part of a basic serum biochemistry profile and were therefore not included in this case.

Thymomas have the potential to cause significant morbidity and mortality (Clippinger et al., 1998). Various treatment options are available depending on the case, including surgery, chemotherapy, and radiation therapy (Clippinger et al., 1998; Morrisey and McEntee, 2005; Künzel et al., 2012). They are generally considered to be benign; and there is great potential for treatment to be curative. Metastasis can occur but is quite rare (Morrisey and McEntee, 2005); only one case is reported with metastasis to thoracic organs and abdominal lymph nodes in a rabbit with a thymoma (Heatley and Smith, 2004). Consequently, the sooner the mass is detected, the better the potential outcome (Clippinger et al., 1998; Florizoone, 2005; Künzel et al., 2012). Surgical removal is the treatment of choice, with good long-term postoperative survival rates (Clippinger et al., 1998; Morrisey and McEntee, 2005; Künzel et al., 2012). The most common complication after surgical resection of thymoma in rabbits is acute perioperative death (Turek, 2003).

Survival time without treatment has been documented in only 3 cases with an average survival period of 6 months (Künzel et al., 2012). In the present report, no metastasis was observed and therefore the prognosis looked fair, with the anaesthetic risk being the primary concern. The therapeutic options were discussed, but the owner hesitated due to possible fatal side effects. Later, euthanasia was recommended, since the clinical signs and radiography findings worsen.

Based on the predominant cells, thymomas are categorized as lymphocyte predominant (>50% lymphocytes), epithelial predominant (>50% epithelial cells) and mixed lymphoepithelial (50:50 cells) (Künzel et al., 2012), the latter being the category of which our case came under. It seems possible that abnormal antigen presentation of neoplastic thymic epithelial cells triggers a T-cell mediated process, resulting in autoimmune disease (Carpenter and Holzworth, 1982; Rottenberg et al., 2004).

Thymoma has a key role in causing exfoliative dermatitis in several species. The pathophysiology of thymoma-associated exfoliative dermatitis in cats has yet to be completely determined. A number of theories have been hypothesized and are focused on the role of the normal thymus in the development of the immune system (Rottenberg et al., 2004). In dogs and cats, an association is present between thymoma and myasthenia gravis and in cats between thymoma and exfoliative dermatitis (Carpenter and Holzworth, 1982; Kesler et al., 2004; Gross et al., 2005). In rabbits, the latter, though rare, is possible (Florizoone, 2005). The present case shares many characteristics with exfoliative dermatitis in cats. The lesions in cats appear as non-pruritic white scales with focal areas of alopecia, sometimes with erythema. Histologically a cell-poor interface dermatitis is found (mild lymphocytic exocytosis, apoptosis of keratinocytes in the basal cell layer and to a lesser extent in the stratum spinosum). Areas of cell-rich interface dermatitis as well as loss of sebaceous glands are typical findings (Carpenter and Holzworth, 1982). In addition, two cases of exfoliative dermatitis have been described in cats, in which no evidence of internal disease or neoplasia was found after necropsy, suggesting that this disease was an indicative reaction pattern of immunity driven by non-exclusive feline thymoma T cells (Gross et al., 2005). In human dermatology, exfoliative

dermatitis has been described very well and related to paraneoplastic syndromes (lymphoma and leukemia, but not as a thymoma-associated), adverse reactions to drugs, cutaneous manifestations of Sezary syndrome and idiopathic causes (Boyce and Harper, 2002; Isasi et al., 2012).

Demodex cuniculi is rarely found in skin scrapings taken from rabbits (Harvey, 1990). Even though its pathological significance is unknown, this parasite is considered a normal resident of the epidermis and hair follicle of rabbits (Harvey, 1990). Affected rabbits can show variable levels of pruritus (Paterson, 2006), or can be completely normal (Jenkins, 2001). On the other hand, adult onset demodectic mange in dogs and cats has been associated with systemic disease and with the administration of immunosuppressive chemicals (White et al., 1987; Mueller, 2004). In our case the absence of repetitive positive skin scrapings and the absence of parasitic elements in the histopathology preparations further support previous reports that its

can be incidental. However further research is required to better understand its aetiopathogenesis in rabbits.

Conclusively, thymomas though relatively uncommon, have been related to exfoliative dermatitis in rabbits. Autoimmune interface hepatitis and non-immune-related hepatitis, have also been reported in cases with exfoliative dermatitis. Both hepatic disorders and thymic neoplasia in rabbits are challenging conditions to diagnose. Generalized scaling disorders, coupled with concurrent histologic changes of lymphocytic mural, interface dermatitis and absence of sebaceous glands should induce the clinician to search for a systemic cause, and include thymic neoplasia on the top and/or hepatic disorders in differential diagnosis.

#### **CONFLICTS OF INTEREST AND SOURCES OF FUNDING**

The authors declare no conflict of interest or specific sources of funding for the work presented here. ■



## REFERENCES

- Bentley PJ, Grubb BR (1991) Effects of a zinc-deficient diet on tissue zinc concentration in rabbits. *J of Anim Science* 69:4876–4882.
- Boyce S, Harper J (2002) Paraneoplastic dermatoses. *Dermatol Clin* 20:523–532.
- Carpenter JL, Holzworth J (1982) Thymoma in 11 cats. *J Am Vet Med Assoc* 181:248–251
- Clippinger TL, Bennett RA, Alleman AR, et al (1998) Removal of a thymoma via median sternotomy in a rabbit with recurrent appendicular neurofibrosarcoma. *J Am Vet Med Assoc* 213: 1140–1143.
- Florizoone K (2005) Thymoma-associated exfoliative dermatitis in a rabbit. *Vet Derm* 16:281–284.
- Florizoone K, Van der Luer R, Van den Ingh T (2007) Symmetrical alopecia, scaling and hepatitis in a rabbit. *Vet Dermatol* 18:161–163.
- Gross TL, Ihrke PJ, Walder EJ, et al (2005) Interface diseases of the dermal–epidermal junction. In: *Skin diseases of the dog and the cat. Clinical and histopathologic diagnosis*. 2nd ed, Blackwell Science Ltd, Oxford: pp 68–70.
- Harkness JE, Turner PV, Woude SV, et al (2010) Clinical Procedures. In: *Harkness and Wagner's Biology and medicine of rabbits and rodents*. 5th ed, Willey-Blackwell, Ames, pp: 118–121.
- Harvey RG (1990) Demodex cuniculi in dwarf rabbits (*Oryctolagus cuniculus*). *J Small Anim Pract* 31:204–207.
- Heatley JJ, Smith AN (2004) Spontaneous neoplasms of lagomorphs. *Vet Clin North Am Exot Anim Pract* 7(3) (Sept):561–577, v.
- Isasi I, Muñoz G, Ramírez G, et al (2012) Dermatitis exfoliativa y alopecia asociada a hepatitis en un conejo (Hepatitis-associated exfoliative dermatitis and alopecia in a rabbit). *Clin Vet Peq Anim* 32(3):175–179.
- Jassies–Van Der Lee A, Van Zeeland Y, Kik M, et al (2009) Successful treatment of sebaceous adenitis in a rabbit with ciclosporin and triglycerides. *Vet Dermatol* 20:67–71.
- Jenkins JR (2001) Skin disorders of the rabbit. *Vet Clin North Am Exotic Anim Pract* 4:543–563.
- Kesler KA, Wright CD, Loehrer PJ (2004) Thymoma: Current medical and surgical management. *Semin Neurol* 24:63–73.
- Künzel F, Hittmair KM, Hassan J, et al (2012) Thymomas in Rabbits: Clinical Evaluation, Diagnosis, and Treatment. *J Am Anim Hosp Assoc* 48:2(Mar/Apr):97–104.
- Miller WH, Griffin CE, Campbell KL (2013) Dermatoses of Exotic Small Mammals. In: *Muller and Kirk's Small Animal Dermatology*. 7th ed, Elsevier/Mosby, St. Louis: pp 869–870.
- Morrisey JK, McEntee M (2005) Therapeutic options for thymoma in the rabbit. *Sem Avian Exotic Pet Med* 14(3):175–181.
- Mueller RS (2014) Canine demodicosis. In: *Kirk's Current Veterinary Therapy XV*. 15th ed, Elsevier/Saunders, Philadelphia: pp 432–434, 2014.
- Paterson S (2006) Skin Diseases and Treatment of Rabbits. In: *Skin Diseases of Exotic Pets*. Blackwell Science Ltd, Oxford: pp 302.
- Rosenthal K, Hoefler H, Quesenberry K, et al (1995) Question cause of hypercalcemia in a rabbit. *J Am Vet Med Assoc* 206(11):1675–1677.
- Rostaher-Prélaud A, Jassies-van der Lee A, Mueller RS, et al (2013) Presumptive paraneoplastic exfoliative dermatitis in four domestic rabbits. *Vet Rec* 172:155.
- Rottenberg S, von Tscharnher C, Roosje PJ (2004) Thymoma-associated exfoliative dermatitis in cats. *Vet Path* 41:429–433.
- Scott, DW (2010) Erythema multiforme in dogs and cats <http://veterinarycalendar.dvm360.com/erythema-multiforme-dogs-and-cats-proceedings> [Accessed 20 July 2017]
- Snook TS, White SD, Hawkins MG, et al (2013) Skin diseases in pet rabbits: a retrospective study of 334 cases seen at the University of California at Davis, USA (1984–2004). *Vet Derm* 24:613–e148.
- Turek MM (2003) Cutaneous paraneoplastic syndromes in dogs and cats: a review of the literature. *Vet Derm* 14:279–296.
- Vennen KM, Mitchell MA (2009) Hematology/Chemistry Panels in Rabbits. In: *Manual of Exotic Pet Practice*, Saunders/Elsevier, St. Louis: pp 381–382.
- Weisbroth SH (1994) Neoplastic Diseases. In: *The Biology of the Laboratory Rabbit*. 2nd ed, Academic Press, San Diego: pp 259–292.
- White SD, Carpenter JL, Moore FM, et al (1987) Generalised demodicosis associated with diabetes mellitus in two cats. *J Am Vet Med Assoc* 191:448–450.
- White SD, Campbell T, Logan A, et al (2000) Lymphoma with cutaneous involvement in three domestic rabbits (*Oryctolagus cuniculus*). *Vet Dermatol* 11:61–67.
- Zitz JC, Birchard SJ, Couto GC, et al (2008) Results of excision of thymoma in cats and dogs: 20 cases (1984–2005). *J Am Vet Med Assoc* 232:1186–1192.