

Journal of the Hellenic Veterinary Medical Society

Vol 23, No 4 (1972)

Υπεύθυνος σερφόνας τῆς νόμῳ :

ΙΔΙΟΚΤΗΤΗΣ : ΕΛΛΗΝΙΚΗ
ΚΤΗΝΙΑΤΡΙΚΗ
ΕΤΑΙΡΕΙΑ

Ἐπιστημονικὸν Σωματεῖον ἀνεγναρ-
σμένων, ἀριθ. ἀποφ. 5410/19.2.1925
Προτοδικείου Ἀθηνῶν.

Πρόεδρος διὰ τὸ ἔτος 1972:
Ἰωάννης Καρδάσης,
Κηφισίας 56, Ἀθήναι.

ΕΚΔΟΤΗΣ: Ἐκδίδεται ἐπὶ αἰρετῆς πεν-
ταμελὸς συντακτικῆς ἐπιτροπῆς (Σ.Ε.)
μελὸν τῆς Ε. Κ. Ε.

Δ/ΝΤΗΣ ΣΥΝΤΑΞΕΩΣ: Ὁ Πρόεδρος
τῆς Σ.Ε. Παντελῆς Ν. Δραγῶνας
Ὁδ. Βαζαντίου 5—Νέα Σμύρνη
Μέλη Συν/κῆς ἑπ.: Ε. Ν. Σπορόρος
Κ. Χ. Σαϊταρῆς
Μ. Μαστρογιάννη - Κορκολοπούλου
Δ. Χ. Μπρόβας

ΠΡΟ-ΓΕΤΑΜΕΝΟΣ ΤΥΠΟΓΡΑΦΕΙΟΥ
Αἰὲλ Κοβάνη
Θεσσαλονίκης 65 - Μοσχάτον

ΤΟΠΟΣ ΕΚΔΟΣΕΩΣ: Ἀθήναι
ΗΜΕΡ. ΤΥΠΩΣΕΩΣ: Ἰανουάριος 1973


Ταχ. Διεύθυνσις:
Ταχ. θυρίς 546
Κεντρικὸν Ταχυδρομεῖον
Ἀθῆναι

Συνδρομαί:
Ἐτησίᾳ ἐσωτερικοῦ δρχ. 200
Ἐτησίᾳ ἐξωτερικοῦ δρχ. 300
Ἐτησίᾳ φοιτητῶν ἡμεδαπῆς δρχ. 50
Ἐτησίᾳ φοιτητῶν ἀλλοδαπῆς δρχ. 100
Τιμὴ ἐκαστοῦ τεύχους δρχ. 50

Address: P.O.B. 546
Central Post Office
Athens - Greece

Redaction: Dr. P. N. Dragonas
Vyzantiou str. 5
Nea Smyrni, Athens.
Greece.

Subscription rates:
(Foreign Countries)
\$ U. S. A. 10 per year.



Δελτίον

ΤΗΣ ΕΛΛΗΝΙΚΗΣ
ΚΤΗΝΙΑΤΡΙΚΗΣ ΕΤΑΙΡΕΙΑΣ

ΤΡΙΜΗΝΙΑΙΑ ΕΚΔΟΣΙΣ
ΠΕΡΙΟΔΟΣ Β
ΤΟΜΟΣ 23 Ὀκτώβριος - Δεκέμβριος
ΤΕΥΧΟΣ 4 1972

Bulletin

OF THE HELLENIC
VETERINARY MEDICAL SOCIETY

QUARTERLY
SECOND PERIOD
VOLUME 23 October - December
No 4 1972

POSTHTIS AND VULVITIS IN EXPERIMENTALLY INDUCED ZINC DEFICIENT LAMBS

Π. Ν. ΔΕΜΕΡΤΖΗΣ

doi: [10.12681/jhvms.20086](https://doi.org/10.12681/jhvms.20086)

Copyright © 2019, Π. Ν. ΔΕΜΕΡΤΖΗΣ



This work is licensed under a [Creative Commons Attribution-NonCommercial 4.0](https://creativecommons.org/licenses/by-nc/4.0/).

To cite this article:

ΔΕΜΕΡΤΖΗΣ Π. Ν. (1972). POSTHTIS AND VULVITIS IN EXPERIMENTALLY INDUCED ZINC DEFICIENT LAMBS. *Journal of the Hellenic Veterinary Medical Society*, 23(4), 254–258. <https://doi.org/10.12681/jhvms.20086>

POSTHITIS AND VULVITIS IN EXPERIMENTALLY INDUCED ZINC DEFICIENT LAMBS*

By

P. N. DEMERTZIS* B. V. M., M. Sc.

ΠΕΙΡΑΜΑΤΙΚΗ ΠΟΣΘΙΤΙΣ ΚΑΙ ΑΙΔΟΪΤΙΣ ΕΙΣ ΑΜΝΟΥΣ ΕΞ ΕΛΛΕΙΨΕΩΣ ΨΕΥΔΑΡΓΥΡΟΥ

Υπό

Π. Ν. ΔΕΜΕΡΤΖΗ

ΠΕΡΙΛΗΨΙΣ

Κλινική εξέταση εξ πασχόντων εκ πειραματικής ψευδαργυροπενίας αμνών, απέδειξε ότι άπασαι αι τέσσαρες θήλεις έπασχον εξ αιδοιτίτιδος, άμφότεροι δέ οι άρρενες εκ ποσθίτιδος. Τ' άνωτέρω συμπτώματα δέν ύπήρχον εις τρεις θήλεις και έν άρρεν των όποιών τό σιτηρέσιον περιείχεν κανονικήν ποσότητα ψευδαργύρου και οι όποιοι έχρησίμευον ώς μάρυτες.

Ίστολογική εξέταση του δέρματος πόσθης και αιδοίου, εκ των πασχόντων εκ ψευδαργυροπενίας αμνών απέδειξε υπερτροφίαν των σμηγματογόνων αδένων οι όποιοι άλλωστε είναι εύαριθμοι εις τά όργανα ταύτα.

Τά εύρήματα ταύτα συζητούνται έν συνδυασμώ προς την εμφάνισιν μη μολυσματικής ποσθίτιδος και αιδοιτίτιδος εις τά ζώα.

INTRODUCTION

The symptomatology of artificially made zinc deficient lambs and calves has been described in details by C. F. Mills, A. C. Dalgarno, R. B. Williams and J. Quarterman (1967).

Although very few reports exist on naturally occurring zinc deficiency in farm animals, S. P. Legg and L. Sears (1960), S. Haaranen (1963), the possibility that zinc deficiency is more wide—spread among those animals, contrary to the general belief, cannot be ruled out. As far as we know there is no report describing the effect of zinc deficiency on the prepuce and vulva of sheep.

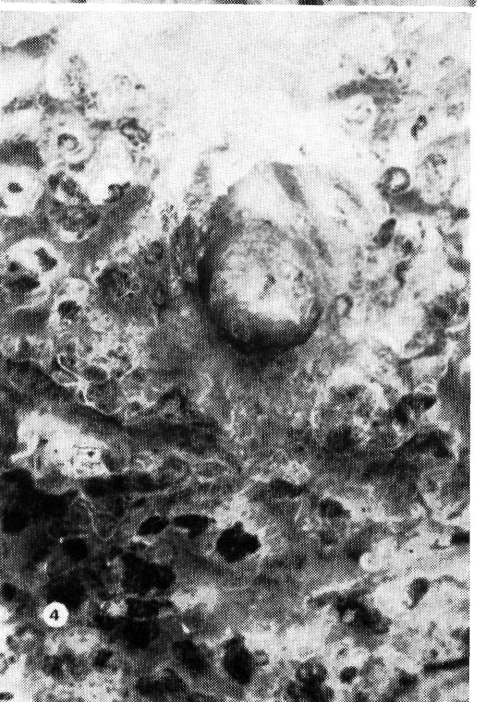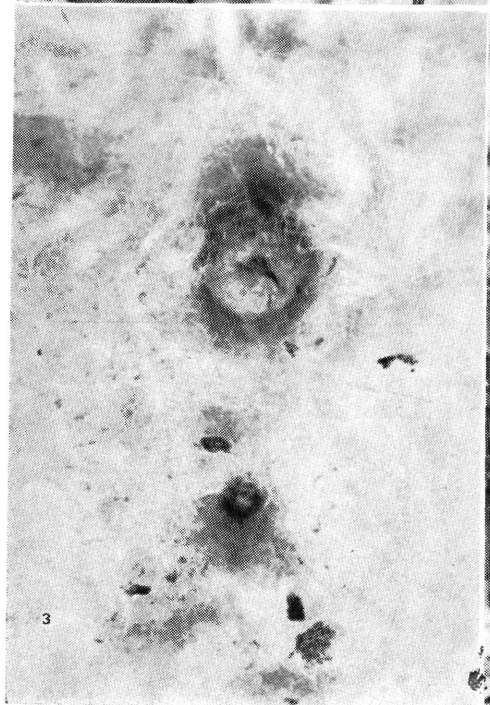
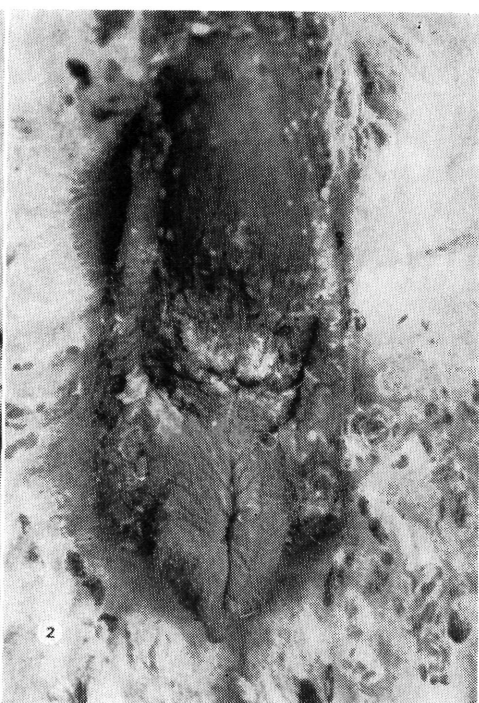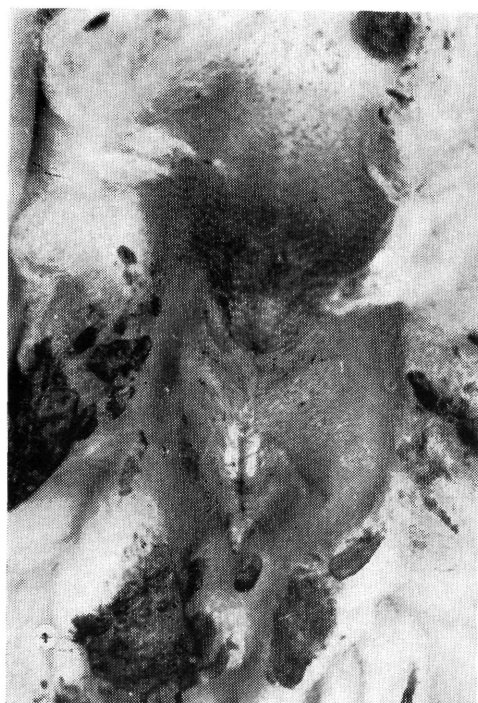EXPERIMENTAL

Six zinc deficient lambs (four females, two males) and four control, zinc supplemented, animals (three females, one male), of the Dorset Horn

* Received for publication October 30, 1972.

** Research Laboratory of Physiopathology of Animal Reproduction, Aghia Paraskevi, Attikis, Greece.

Έργαστήριον Έρεύνης Φυσιοπαθολογίας Άναπαραγωγής Ζώων. Άγία Παρασκευή, Άττικής.



breed, were made for the purposes of another experiment. The composition of the diet, the age and management of animals was similar to that described by C. F. Mills et al (1967).

RESULTS

Control animals. No abnormality whatever was present in the prepuce or vulva in animals of this group after a five week period (Photo 1 and 3). **Zinc deficient animals.** The four zinc deficient female lambs at the same period (Photo 2) presented a reddening of the vulval lips and the visible vaginal mucosa. This was accompanied by an enlargement of the vulval lips while small superficial, discrete, yellow incrustations developed on the labial cutaneous surfaces, similar to those described by C. H. R. Dent (1971). The two zinc deficient male lambs presented, (Photo 4), two to three fold enlargement of the prepuce, the skin surface was covered with incrustations similar to that of the vulva. The prepuce took a pear-like shape, while the skin pigmentation was lessened in both male and female lambs. The symptomatology was more severe in male than in female lambs suggesting an increased sensitivity to zinc deficiency of the male compared to the female lamb. In fact males died long before females and while males died at the peak of their symptomatology in the females a regression of the skin lesions was observed before death.

Histological examination of the skin from vulva and prepuce revealed hypertrophy of the subepithelial sebaceous glands.

DISCUSSION

Enlargement of the sebaceous glands were observed since the early experiments with zinc deficient animals, M.J. Millar, M. I. Elcoate and C. A. Mawson (1958).

The skin of both, prepuce and vulva, in ruminants has numerous glands. The observed enlargement of prepuce and vulval lips can be attributed to the hypertrophy of the sebaceous glands, hypertrophy which evidently is followed by an increased secretion of sebum.

In regard to the observed inflammation of the prepuce and vulval lips this could be attributed to overproduction of fatty acids by enzymatic transformation of sebum triglycerides, J. A. Cotterill, W. J. Cunliff, B. Williamson and L. Bulusu (1972) which acids is known to be irritative to the skin.

If a similar mechanism is valid for ruminants, this could well explain the inflammatory processes of the prepuce and vulva in zinc deficiency and should suggest zinc containing enzyme(s) involvement in the physiology of the sebaceous gland, with very interesting extensions in man, J. L. Bar-

ton, W. J. Cunliff and S. Shuster (1970), M. J. Krant, C. S. Brandrup, R. S. Green, P. E. Pochi and J. S. Strauss (1968). Furthermore, the yellow deposit in hair in the prepuceal orifice in wethers in Australia, W. I. B. Beveridge and I. L. Johnstone (1953) could not be anything else but sebum.

SUMMARY

Clinical examination of six zinc deficient sheep has shown that all four females had vulvitis and both males severe posthitis. These syndromes were not present in the three females and one male fed zinc supplemented diet.

Histological examination of skin showed enlargement of the sebaceous glands. This finding is discussed in connection with the incidence of non contagious Posthitis and Vulvitis in animals.

ΒΙΒΛΙΟΓΡΑΦΙΑ

1. BARTON J. L., W. J. CUNLIFF and S. SHUSTER (1970) : Brit. Med. J., 1., 665.
2. BEVERIDGE W. I. B. and I. L. JOHNSTONE (1953) : Aust. vet. J., 29, 269 and 329.
3. COTTERILL J. A., W. J. CUNLIFFE, B. WILLIAMSON and L. BULUSU (1972) : Brit. Med. J., 3, 444.
4. DENT C. H. R. (1971) : Vet. Bull., 41, 719.
5. HAARANEN S. (1963) : Nord. Vet. Med. 15, 536.
6. KRANT M. J., C. S. BRANDRUP R. S., GREEN P. E., POCHI and T. S. STRAUSS (1968) : Nature London, 217, 463.
7. LEGG S. P. and L. SEARS (1960) : Nature London, 186, 1061.
8. MILLAR M. J., M. I. FISCHER, P. V. ELCOATE and C. A. MAWSON (1958) : Canad. J. Biochem. Physiol. 36, 557.
9. MILLS C. F., A. C. DALGARNO, R. B. WILLIAMS and J. QUARTERMAN (1967) : Br. J. Nutrition, 21, 751.