


## Journal of the Hellenic Veterinary Medical Society

Vol 70, No 1 (2019)



### Laparoscopic castration in stallions with two different testicular blood vessels occluding techniques

A, N, EL-KHAMARY, M. W. EL-SHERIF

doi: [10.12681/jhvms.20351](https://doi.org/10.12681/jhvms.20351)

Copyright © 2019, A, N, EL-KHAMARY, M. W. EL-SHERIF



This work is licensed under a [Creative Commons Attribution-NonCommercial 4.0](https://creativecommons.org/licenses/by-nc/4.0/).

#### To cite this article:

EL-KHAMARY, A. N., & EL-SHERIF, M. W. (2019). Laparoscopic castration in stallions with two different testicular blood vessels occluding techniques. *Journal of the Hellenic Veterinary Medical Society*, 70(1), 1429–1434. <https://doi.org/10.12681/jhvms.20351>

## **Laparoscopic castration in stallions with two different testicular blood vessels occluding techniques**

**A.N. El-Khamary<sup>1</sup>, M.W. El-Sherif<sup>2\*</sup>**

*<sup>1</sup>Department of Surgery, Anesthesiology and Radiology, Faculty of Veterinary Medicine, Damanshour University, Damanshour, Egypt.*

*<sup>2</sup>Department of Surgery, Anesthesiology and Radiology, Faculty of Veterinary Medicine, Assiut University, New Valley, Egypt.*

**ABSTRACT.** Castration of horses is indicated for many reasons and could be performed with variable techniques. Laparoscopic castration is an improved choice. Laparoscopic castrated horses have better cosmetic appearance, return rapidly to normal physical status and have little postoperative complications. The main challenges during laparoscopic castration are obtaining an optimal visualization of the internal inguinal orifices and their content of vas deferens and testicular blood vessels and appropriate occlusion and transection of the testicular blood vessels to obtain avascular atrophy of the testicles that remains in situ within scrotum. Laparoscopic castration was performed in horses lied in lateral recumbency for better visualization of the target structures and two methods for vascular occlusion were compared. Endo-clipping is effective testicular vessels occluding method and more reliable than bipolar cauterization. Lateral recumbency layout decreased risks of hemodynamic changes during surgery and provided optimal visualization of the surgical field.

**Keywords:** Laparoscopy, Castration, Horses, Clipping.

*\* Correspondence:*  
*M.W. El-Sherif*  
*Email address: drmwat@hotmail.com*

*Date of initial submission: 25-01-2018*  
*Date of revised submission: 03-07-2018*  
*Date of acceptance: 10-03-2018*

## INTRODUCTION

Care complications accompanying equine castration are the most common cause for searching more reliable techniques. Unlike traditional castration techniques, which possess tissue damage and followed by variable complications, laparoscopic surgery is performed through small incisions had shown minimal tissue invasiveness, short hospitalization and minimal post-operative complications (Searle et al., 1999). Laparoscopic castration techniques have been reported in horses (Fischer, 1991; Fischer & Vachon, 1992; Wilson et al., 1996; Fischer & Vachon, 1998; Ragle, 1998; Walmsley, 1999; Walmsley, 2003; El-Khamary et al., 2017). Improvements dedicated to laparoscopic techniques involves finding better performing position and accurate testicular vessels occluding techniques. Laparoscopic castration performed in standing position (Davis, 1997; Hendrickson & Wilson, 1997), dorsal recumbency (Wilson et al., 1996). Placing the horses in lateral recumbency during laparoscopic castration surgery had shown high efficiency (El-Khamary et al., 2017). The key point of castration is occlusion of the testicular blood vessels and prohibition of the blood supply to the testicles followed by removing or keeping the testicles in situ are both reported (Fischer & Vachon, 1998; El-Khamary et al., 2017). Electrocoagulation monopolar and bipolar techniques, pre-tied ligating loops and clipping are the most common laparoscopic vessel occluding techniques (Alsafy et al., 2013). The aim of the present study was to a) describe laparoscopic castration technique in lateral recumbency as a modified layout and to b) compare two laparoscopic vessel occluding approaches; bipolar cauterization and new laparoscopic clipping method.

## MATERIALS AND METHODS

The present study was performed on nine premature horses (6-8 months), all horses were healthy and submitted for castration in order to avoid unwanted masculine behavior. Four horses were referred from one single farm the other five horses were sporadic. Surgeries were performed at the era between 2014 and 2017.

Food was withheld 36 hours prior surgery and the

flanks and ventral abdomen were clipped and prepared for aseptic surgery. All horses received sedative (Xylazine; Xylaject, ADWIA Pharma, Egypt, 0.5 mg/kg) administered intravenously, then, generally anesthetized (ketamine; Ketamine 5%, Sigmatech Pharma, Egypt, 2.2 mg/kg) administered intravenously. Anesthesia was maintained with repeated half dose bolus when required via intravenous rout according to (Staffieri & Driessen, 2007).

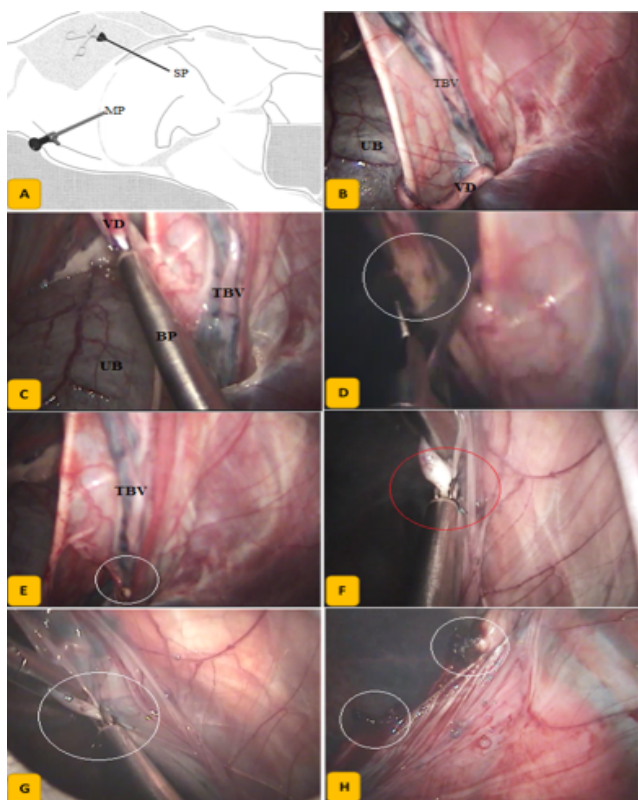
Member horses were lied in lateral recumbent position and secured to the surgery table with the uppermost hind limb abducted and elevated outward. Infiltration of 10 ml of local anesthetizing solution (Lidocaine; Depocaine 2%, DEPIKY PHARMA, Egypt) into two points; umbilicus and ventral inguinal region, the main and secondary portal points according to (El-Khamary et al., 2017). Standard laparo-insufflation was created to maintain sufficient intraabdominal space for surgery. Main port 10-mm cannula was introduced via an incision through the umbilicus and used to incorporate the laparoscope. Another 10-mm secondary portal cannula is inserted into the abdominal cavity at the ventral inguinal point. The uppermost abdominal and pelvic cavities were explored and the ipsilateral testicular vessels were located.

### *Laparoscopic castration by bipolar cauterization of TBV:*

Laparoscopic castration with bipolar cauterization of the TBV was applied to four horses. Bipolar forceps used to coagulate and cut the TBV by applying frequent jets of high frequency (150 watts) bipolar current. Continuous bipolar dissection of the TBV from peritoneum and complete severing of the vas deferens was performed (figure 1).

### *Laparoscopic castration by clipping of TBV:*

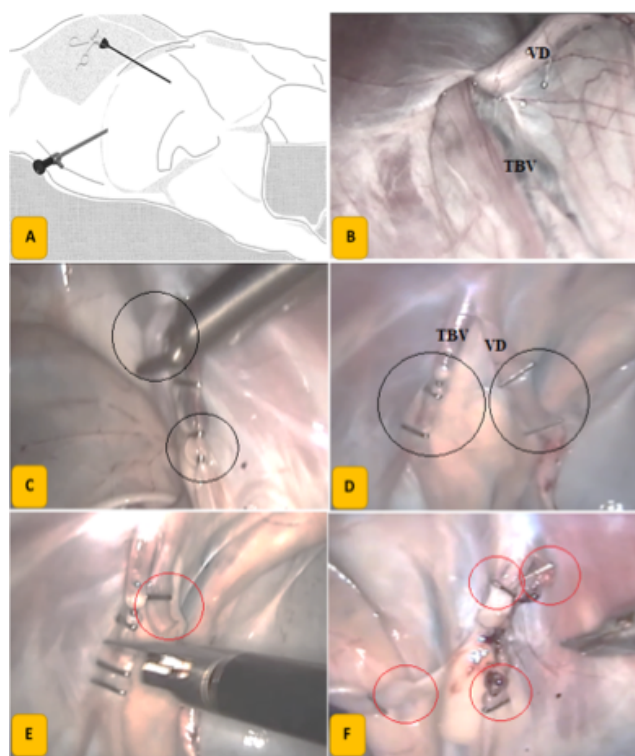
Laparoscopic castration by clipping of the TBV and vas deference was performed in five horses according to (El-Sherif, 2013). Four medium-large titanium clips mounted on 10-mm endo-clip applicator applied over the course of the testicular blood vessels, then, transected in between with scissors. Further application of two clips over the course of the vas deferens and transection with scissors (Figure 2).



**Figure 1.** Laparoscopic castration by bipolar cauterization of TBV. Horse layout in lateral recumbency; main port for laparoscope in umbilicus (MP), secondary port for instrument (SP) (A), inspection of the testicular blood vessels (TBV) and vas deferens (VD) (B), bipolar cauterization of VD by bipolar electrode (BP) (C), severing of the VD (white circle) (D), severed stump (white circle) (E), bipolar cautery of TBV (red and white circles) (F&G), after complete severing of TBV, stumps in white circles (H).

*Intra and Post-operative evaluation:*

Instant exploration for bleeding was performed in all animals. Feasibility and surgical rating was assessed to scale inspired from that build by Martini et al., 2014 (table, 1), operative time, tools required, degree of visibility and easiness were documented for each procedure, final judgement was marked down. Reliability of the laparoscopic technique was evaluated according to scale grading the surgeon skills that mimic scale reported by Vassiliou et al., (2006) (table, 2). Three months follow up for all horses including; disappearance of masculine behavior, presence of genital or testicular disorders, general health status and periodic ultrasonographical evaluation of the testis, inguinal and ventral abdomen regions. Animal value/ cost effectiveness was also evaluated.



**Figure 2.** Laparoscopic castration with clipping and severing of TBV and VD. Horse layout in lateral recumbency (A), anatomical identification of TBV and VD (B), direct application of medium/ large titanium clips on the course of TBV and VD by endo-clip applicator (C), complete clipping (D), severing of TBV and VD by endo-scissors (E), complete transection of TBV and VD (F).

**Table 1:** Surgical feasibility rating scale.

Parameter	score
Disability of surgery due to patient related causes (movements, pain manifestation or orientation)	Poor/ good/ optimal
Ability to obtain visible surgical field	optimal
Enough working field for performing surgery	

**Table 2:** Surgical reliability rating scale.

Parameter	score
Ability to handle structures	
Ability to apply monopolar cauterization and ascertain of process	Poor/ good/ excellent
Ability to apply titanium clips and ascertain process	



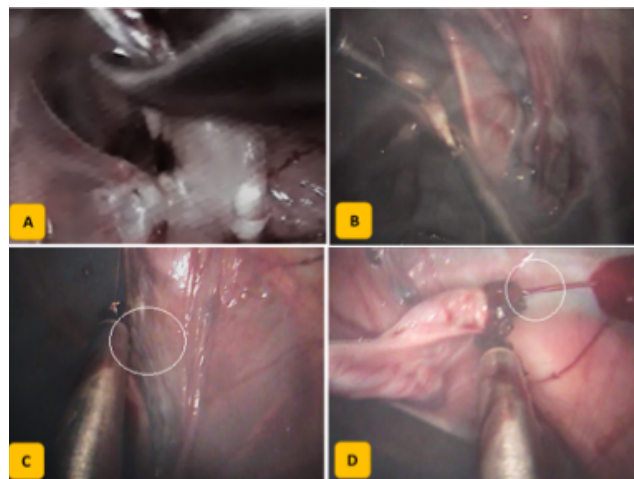
## RESULTS

Xylazine-Ketamine general anesthesia was adequate for all nine surgeries. The mean surgical time was  $39 \pm 4$  minutes for laparoscopic castration with bipolar cauterization and  $14 \pm 2$  minutes for laparoscopic castration with clipping of the TBV. Laying animals in lateral recumbency was easy and comfortable for the operator. Trendelenburg position was not required, lateral recumbency with up to  $-10$  mm/hg- pneumoperitoneum provided suitable operating space for performing surgery. Laparoscope at the umbilicus was optimal to visualize the entire pelvic cavity and internal inguinal region.

### *Laparoscopic castration with bipolar cauterization of TBV:*

Trials to grasp and cauterize the TBV or VD through a single tool failed, another secondary port was inserted through the abdomen five cm distal to the inguinal secondary portal. The uppermost portal used to introduce endoscopic Allis grasper and the lower used to introduce the bipolar electrode. Several attempts were done to cauterize the VD, effective coagulation was determined visually by complete dryness and changing the color into fade white. Bipolar current was optimized for coagulation to avoid cutting of improperly occluded vessels. Otherwise, cutting was performed using endo-scissors alternatively after coagulation. Intraoperative complications were improper foggy vision of the operative field due to smokes generated as a result of tissue burn within sealed abdomen. Operators needed about 4 minutes to retain visualization for the next attempt of cautery or cutting. Tissue adhesion to the metallic shaft of the bipolar electrode was recorded in two horses and caused extra peritoneal damage. Bleeding from the TBV was recorded in 3 cases due to improper coagulation. After further attempts, bleeding was controlled. The VD was coagulated and severed in fewer cautery turns and easier than the TBV. Intra-operative complications are grouped in figure 3.

Although further administration of anesthetic booster doses in all horses of the group, there were no disabilities related to the animals during the surgery. Visualization of the surgical field was optimal before starting bipolar cauterization and changed to poor



**Figure 3.** Intra-operative complications associated with bipolar cautery of TBV and VD. Some are technical; haziness of visual field during current incorporation (A), foggy vision of the operative field due to smokes generated from tissue burn (B), and some are related to faulty use; adhesion between the electrode and adjacent tissue (C), bleeding due to improper coagulation of large diameter TBV (D).

after each cautery attempt to good after about 3-4 minutes later. Ability to handle structures with one tool was poor.

### *Laparoscopic castration with clipping of the TBV:*

Application of medium/ large endo-titanium clips to the course of both the VD and TBV was easy and reliable. There was no need to use other secondary portal for supporting or grasping tool. Severing of the VD and TBV was performed using endo-scissors after complete clipping of both structures. The procedure was reliable, feasible, accurate and time saving. There were no intra-operative complications.

The overall reliability and feasibility evaluation of laparoscopic castration with bipolar cauterization or clipping are summarized in table 3.

## DISCUSSION

Although diagnostic laparoscopic surgery in veterinary field in Egypt had been introduced in mid ninetens, clinical interventional applications of laparoscopy were not implicated until the second millennium (El-Sherif, 2008; El-Khamary, 2011; El-Sherif, 2013; El-Sayad, 2016; El-Khamary et al., 2017). Due to the high importance of that field, the present

**Table 3:** Reliability and feasibility of laparoscopic castration.

Parameter	Laparoscopic castration with bipolar cautery	Laparoscopic castration with clipping
Disability of surgery due to patient related causes	<i>Optimal</i>	<i>Optimal</i>
Ability to obtain visible surgical field	<i>Optimal -poor- good</i>	<i>Optimal</i>
Enough working field for performing surgery	<i>Good</i>	<i>Optimal</i>
Ability to handle structures		
Ability to apply monopolar cauterization and ascertain of process	<i>Good - poor</i>	----
Ability to apply titanium clips and ascertain process	----	<i>Optimal</i>

study similar to all previous trials is related to gynecological laparoscopic applications. To our knowledge, this is the first study reports clinical nonexperimental application of interventional laparoscopy in horses in Egypt.

Laparoscopic surgery is performed under the effect of sedation and local infiltration anesthesia in standing horses (Fischer, 1991) and under general inhalant anesthesia in dorsal recumbency layout (Fischer & Vachon, 1992). Successful attempts to perform under the effect of total intravenous anesthesia (TIA) were reported (El-Sherif, 2013). In order to reserve the hemodynamic balance and decrease the pressure on thorax during TIA, animal layout was changed to lateral recumbency (El-Sherif, 2013; El-Khamary et al., 2017). Gathering fast performing by skilled well-trained surgeon and putting the animal in lateral recumbency resulted in feasible, safe and reliable laparoscopy. Another one advantage is proper visibility of the pelvic contents especially the ipsilateral uppermost region where the inguinal canal lies. Fasting of the animals for 36-72 hours is a must to avoid entrapment of large intestines within the surgical field (El-Khamary et al., 2017). In adequate intestinal emptying results in occupation of the surgical field and need to put the horse into anterior Trendelenburg position with the head down. Thirty-six hours fasting was adequate to empty intestines in young horses aging up to 8 months. The ability to visualize both inguinal areas was possible in all horses, otherwise, shaking the animal and tilting the abdomen into cranial Trendelenburg with 15° was required almost in all horses before starting surgery to provide better

visualization of the surgical field.

Bipolar electrode is provided with 5mm outer diameter shaft, so, the 10-mm secondary port should be provided with an extra adaptor. It was hard to cauterize the target blood vessels without grasping them away from the neighboring tissue. First attempt to use bipolar electrode alone without assistant tool resulted in adhesion between the outer metallic shaft of the tool and peritoneum (figure, 3-C). insertion of extra 5-mm secondary portal made cauterization easier. Alike results reported by (El-Khamary, 2011 and Alsafy et al., 2013) the bipolar current could not achieve reliable coagulation of testicular blood vessels. Otherwise good coagulation of vas deference and its accompanying blood vessel was obtained after two or three shots. Further frequent shots were needed after severing the TBV to control bleeding. Endoscopic clipping is a reliable occluding method of large tubulated structures. It is used to occlude cystic duct and cystic blood vessels during human laparoscopic cholecystectomy (Troidl et al., 1992). Endoscopic clipping was used effectively to occlude the TBV to induce in-situ castration in dogs (El-Sherif, 2008) and in equines (El-Khamary et al., 2017). Applying four titanium clips to the course of the TBV and two on the course of the VD was feasible through a single port at the inguinal region, easy, reliable and effective. There was no bleeding after severing the TBV or VD. Another theoretical advantage of endo-clipping is complete prohibition of blood streaming to the testicles either of suggested revascularization of the TBV.

## CONCLUSIONS

Laparoscopic castration is an effective alternate to conventional methods that is reliable and more cosmetically acceptable. Endo-clipping is a reliable and accurate large vessel occluding method that may be used safely in laparoscopic castration procedures. Laying horses in lateral recumbency during laparoscopic castration provide the operator with a wide

visible field and permits good manipulation of target structures with minimal effects on the hemodynamic balance. Laparoscopic experimental studies should be applied and evaluated in clinical studies.

## CONFLICT OF INTEREST

The authors have no conflict of interest to declare for this manuscript. ■

## REFERENCES

- Searle D, Dart AJ, Dart M, Hodgson DR (1999) Equine castration: review of anatomy, approaches, techniques and complications in normal, cryptorchid and monorchid horses. *Australian Veterinary Journal*, 77, 428-434.
- Davis EW (1997) Laparoscopic cryptorchidectomy in standing horse. *Veterinary Surgery*, 26, 326-331.
- Elsayad A (2016) Laparoscopic intrauterine insemination in sheep, PhD thesis, Kafrelsheikh Univesity, Egypt.
- El-Sherif M. (2008) Laparoscopic sterilization of dogs. MS thesis. Kafrelsheikh University, Egypt.
- El-Sherif M. (2013) Studies on laparoscopic surgery of some male urogenital organs of equine, PhD thesis. Damanhour University, Egypt.
- Fischer AT, Vachon AM (1992) Laparoscopic cryptorchidectomy in horses. *Journal of American Veterinary Medical Association*, 201, 1705-1708.
- Fischer AT, Vachon AM (1998) Laparoscopic intra-abdominal ligation and removal of cryptorchid testes in horses. *Equine Veterinary Journal*, 30, 105-108.
- Fischer AT (1991) Standing laparoscopy surgery. *Veterinary Clinics, North American Equine Practice*, 7, 641-647.
- Hendrickson DA, Wilson DG (1997) Laparoscopic cryptorchid castration in standing horses. *Veterinary Surgery*, 26, 335-339.
- Vassiliou MC, Ghitulescu GA, Feldman LS, Stanbridge D, Leffondre' K, Sigman HH, Frie GM (2006) The MISTELS program to measure technical skill in laparoscopic surgery; Evidence for reliability. *Surgical Endoscopy*, 20, 744-747.
- Alsafy MA., H. E. Mahmoud HE, Kassem MM, ElGendy SA, EL-Khamary A (2013) Laparoscopic Anatomy of the Abdomen and Laparoscopic Ligating Loops, Electrocoagulation, and a Novel Modified Electroligation Ovariectomy in Standing Mare. *Journal of Equine Veterinary Science*, 33, 912-923.
- Ragle CA, Southwood LL, Howlett MR (1998) Ventral abdominal approach for laparoscopic cryptorchidectomy in horses. *Veterinary Surgery*, 27, 138-142.
- Staffieri F, Driessen B (2007) Field Anesthesia in the Equine. *Clinical Techniques in Equine Practice*, 6, 111-119.
- Troidl H, Spangenberge W, Langen R, et al. (1992) Laparoscopic cholecystectomy: technical performance, safety and patient's benefit. *Endoscopy*, 24, 252-261.
- Walmsley JP (2003) Advantages and limitations of laparoscopy in the horse. *Proceedings of the 12th ECVS meeting Glasgow, Scotland*, pp 74-79.
- Walmsley JP (1999) Review of equine laparoscopy and analysis of 158 laparoscopies in the horse. *Equine Veterinary Journal*, 31, 456-464.
- Wilson DG, Hendrickson DA, Cooley AJ, et al. (1996) Laparoscopic methods for castration of equids. *Journal of American Veterinary Medical Association*, 209, 112-114.