

Journal of the Hellenic Veterinary Medical Society

Vol 70, No 1 (2019)



A case of Amidostomosis in a racing pigeon (*Columba livia*) in Greece

V. TSIOURIS, A. STARRAS, I. GEORGOPOULOU, A.
ANGELOU, E. PAPADOPOULOS

doi: [10.12681/jhvms.20353](https://doi.org/10.12681/jhvms.20353)

Copyright © 2019, V. TSIOURIS, A. STARRAS, I. GEORGOPOULOU,
A. ANGELOU, E. PAPADOPOULOS



This work is licensed under a [Creative Commons Attribution-NonCommercial 4.0](https://creativecommons.org/licenses/by-nc/4.0/).

To cite this article:

TSIOURIS, V., STARRAS, A., GEORGOPOULOU, I., ANGELOU, A., & PAPADOPOULOS, E. (2019). A case of Amidostomosis in a racing pigeon (*Columba livia*) in Greece. *Journal of the Hellenic Veterinary Medical Society*, 70(1), 1443-1448. <https://doi.org/10.12681/jhvms.20353>

A case of Amidostomosis in a racing pigeon (*Columba livia*) in Greece

V. Tsiouris¹, A. Starras², I. Georgopoulou¹, A. Angelou³, E. Papadopoulos³

¹Unit of Avian Medicine, Clinic of Farm Animals, Faculty of Veterinary Medicine, School of Health Sciences,
Aristotle University of Thessaloniki, Greece

²Military Veterinarian, Hellenic Airforce, Chania, Greece

³Laboratory of Parasitology and Parasitic Diseases, Faculty of Veterinary Medicine, School of Health Sciences,
Aristotle University of Thessaloniki, Greece

Περιστατικό αμιδοστόμωσης σε ταχυδρομικό περιστέρι (*Columba livia*) στην Ελλάδα

Β. Τσιούρης¹, Α. Στάρρας², Ι. Γεωργοπούλου¹, Α. Αγγέλου³, Η. Παπαδόπουλος³

¹ Μονάδα Παθολογίας Πτηνών, Κλινική Παραγωγικών Ζώων, Τμήμα Κτηνιατρικής, Σχολή Επιστημών Υγείας,
Αριστοτέλειο Πανεπιστήμιο Θεσσαλονίκης, Θεσσαλονίκη, Ελλάδα

² Πολεμική Αεροπορία, Χανιά, Ελλάδα

³ Εργαστήριο Παρασιτολογίας και Παρασιτικών Νοσημάτων, Τμήμα Κτηνιατρικής, Σχολή Επιστημών Υγείας,
Αριστοτέλειο Πανεπιστήμιο Θεσσαλονίκης, Θεσσαλονίκη, Ελλάδα

ABSTRACT. A dead pigeon (*Columba livia*) was submitted to the Unit of Avian Medicine, Clinic of Farm Animals, Faculty of Veterinary Medicine, Aristotle University of Thessaloniki, Greece. It derived from a pigeon flock consisted of approximately 100 racing birds of various ages between 4 months to 5 years old. The flock was kept on a terrace indoors in 4 cages of 3 m² each. Near this flock, there were also two other pigeon flocks in a distance of 20 and 30 meters, respectively. The pigeons' health problem had been present in this flock for approximately 3 years before this delivery. Lack of appetite, poor growth of young birds, weakness, depression, vomiting, diarrhea and emaciation were the most important clinical signs of the pigeons in the flock. During necropsy, discoloration and atrophy of liver, spleen and kidneys, edema of gizzard, necrosis in the koilin layer of the gizzard and under this, presence of small parasites, dilatation in the anterior

Corresponding Author:

V. Tsiouris, Staurou Voutyra 11, 54627, Thessaloniki, Greece, biltsiou@vet.auth.gr

Αλληλογραφία:

Βασίλειος Σ. Τσιούρης

Τμήμα Κτηνιατρικής, Στ. Βουτυρά 11, 54627, Θεσσαλονίκη, Ελλάδα

Ηλεκτρονικό ταχυδρομείο: biltsiou@vet.auth.gr

Date of initial submission: 04-04-2018

Date of revised submission: 02-08-2018

Date of acceptance: 10-08-2018

small intestine (duodenum, jejunum) and finally hemorrhagic content in the second half of the small intestine and the rectum were observed. According to the findings of the postmortem and laboratory examination, amidostomosis was determined to be the cause of the pigeon's death. Although pigeon infection by *Amidostomum* spp. is reported around the world, so far, amidostomosis has not been reported in pigeons in Greece. Pigeon owners should take all the appropriate treating and managing measures to control the spread of this parasite and its consequences on their flocks.

Keywords: Amidostomosis, pigeons, gizzard, Greece

ΠΕΡΙΛΗΨΗ. Αγρονιστικό περιστέρι (*Columba livia*) ηλικίας 2 ετών προσκομίστηκε για νεκροτομική εξέταση στη μονάδα Παθολογίας Πτηνών του τμήματος Κτηνιατρικής, ΑΠΘ. Το περιστέρι προερχόταν από ένα σμήνος 100 περιστεριών αγώνων, ηλικίας από 4 μηνών μέχρι 5 ετών. Ο περιστερώνας ήταν τοποθετημένος στην ταράτσα, σε κτίσμα που περιελάμβανε 4 κλουβιά των 3m² το καθένα, ενώ σε απόσταση 20 και 30 μέτρων, αντίστοιχα, υπήρχαν ακόμη δυο περιστερώνες. Με βάση τα στοιχεία του ιστορικού, η νοσολογική οντότητα πρωτοεμφανίστηκε στο σμήνος 3 χρόνια πριν την προσκόμιση του συγκεκριμένου περιστεριού. Η συμπτωματολογία της νόσου περιελάμβανε κυρίως συμπτώματα από το πεπτικό, όπως ανορεξία, καθυστέρηση της ανάπτυξης στα νεαρά πτηνά, αδυναμία, έμετοι, διάρροια και αφυδάτωση. Κατά την νεκροτομική εξέταση, παρατηρήθηκαν αποχρωματισμός και ατροφία του ήπατος, της σπλήνας και των νεφρών, οίδημα και αλλοιώσεις του μυώδους στομάχου, παρουσία παρασίτων κάτω από τον επιδερμικό χιτώνα του μυώδους στομάχου, οίδημα στη πρόσθια μοίρα του λεπτού εντέρου (δωδεκαδάκτυλο και νήστιδα) και τέλος, αιμορραγικό περιεχόμενο στο δεύτερο μισό του λεπτού εντέρου και του απευθυσμένου. Η παρασίτωση από *Amidostomum* spp. τέθηκε ως αιτιολογική διάγνωση σύμφωνα με τα νεκροτομικά και εργαστηριακά ευρήματα, και αποτελεί την πρώτη αναφορά για την Ελλάδα. Οι ιδιοκτήτες περιστεριών οφείλουν να λάβουν τα απαραίτητα μέτρα θεραπείας και ελέγχου για να περιορίσουν την ενδεχόμενη επέκταση της νόσου και τις πιθανές επιπτώσεις της.

Λέξεις ευρητηρίας: Αμιδοστόμωση, περιστέρια, μυώδης στόμαχος, Ελλάδα

INTRODUCTION

Amidostomosis is a chronic parasitic disease of the gizzard in birds (Haralampidis, 2003). The disease is mainly associated with waterfowls (Kavetska et al., 2015), such as geese, ducks and swans (Papazahariadou et al., 1994; Tuggle and Friend, 1999; Papazahariadou et al., 2008). However, the relevant parasites have also been secluded from other species of birds, such as pigeons, chicken (experimental infection) and many other migratory birds (Bowman, 1999; Cole and Friend, 1999; Saif et al., 2008). Mammals are not infected (Bowman, 1999). The nematodes of the genus *Amidostomum* spp. are the causative agent of amidostomosis. In Europe, there are six common species of this genus i.e. *Amidostomum acutum*, *A. anseri*, *A. cygni*, *A. fulicae*, *A. henryi*, *A. spatulatum* (Tuggle and Friend, 1999). There are also other species, such as *A. boschalis* (Haralampidis, 2003). These parasites infect the upper alimentary tract of the birds, particularly, the solid layer of a carbohydrate-protein complex called

the koilin layer of the gizzard and less frequently the proventriculus (S. van Riper and C. van Riper, 1985; Taylor et al., 2007).

The life cycle is similar among the *Amidostomum* species (Saif et al., 2008). More precisely, it is direct, which means that the infective parasitic larva (L3) invades a single host animal and it develops until its reproductive maturity (Tuggle and Friend, 1999). The infection takes place when the bird ingests the L3 larva which is found in the surface of greens and in ponds or when the L3 larva invades the skin of the bird during its swimming. Subsequently, in the first case the infective larva reaches the gizzard through the alimentary tract, whilst in the second case migration of the L3 larva takes place via the lungs and the liver. The larva reaches in reproductive maturity under the gizzard stratum corneum in approximately 15-28 days (in chicks) or in up to 33 days (in adult birds). The parasitic eggs, which are already embryonated are shed through the feces in the outer environment. Subsequently, after its formation,

the L1 larva develops to L3 larva inside the egg in 2-6 days (in 16-27°C) and after that the egg hatches and the L3 larva comes to the outer environment (Haralampidis, 2003; Taylor et al., 2007).

The infective larva survives in the environment for 30 days (in 25°C) or even for 3 months (in 2°C) (Haralampidis, 2003). What is more, it can swim actively in water of ponds for up to 30 days (in 5-10°C) and it is able to reach the surface from depths of up to 10cm (Enigk and DeyHazra, 1970).

During the life cycle, the *Amidostomum* spp, attack the koilin layer of the gizzard of their hosts' (Macklin, 2013). Particularly, the migration and the development of L3 larva as well as the feeding of the blood-sucking adult worm (0.1-0.4 ml blood/adult *A. anseris*/day) lead to hemorrhage in gizzard and severe erosions of gizzard lining (Beynon et al., 1996; Tuggle and Friend, 1999; Haralampidis, 2003). Large amounts of worms (greater than 35) may denude the whole surface lining of the gizzard, making the edges of the grinding pads degenerate and finally separate from the underlying tissue (Tuggle and Friend, 1999). In addition, enteritis is quite possible to happen, too (Beynon et al., 1996).

There are no pathognomonic signs of amidostomosis in birds, indicating the gizzard parasitism. However, in cases of heavy infection of young birds some symptoms may appear, such as poor growth, loss of appetite, dullness, emaciation, diarrhea, anemia due to blood loss, change of expected liver size and even considerable mortality (Kobulej, 1983; Beynon et al., 1996; Tuggle and Friend, 1999; Jordan et al., 2001; Saif et al, 2008).

In other words, the heavy parasitism can induce a chronic debilitating disease and the weakness can be so intense that the aquatic birds cannot hold their neck above water (MacNeil, 1970). Furthermore, birds of all ages may be subject to emaciation and general weakness, too (Tuggle and Friend, 1999). However, according to Herman and Wehr (1954), *A. anseris* itself is not a primary source of loss but rather an important contributing factor (van Riper and van Riper, 1985).

Consequently, amidostomosis may be an important risk factor in some countries and it should not be neglected (Kobulej, 1983).

CASE HISTORY

This report describes a case of amidostomosis in a pigeon derived from a pigeon flock, which was located in Neapoli, a region of the western part of Thessaloniki. The pigeon (*Columba livia*) was submitted for necropsy to the Unit of Avian Medicine, Clinic of Farm Animals, Faculty of Veterinary Medicine, Aristotle University of Thessaloniki, Greece. It was a male bird aging 3 years and hatched in this flock. The flock consisted of approximately 100 racing pigeons of various ages from 4 months to 5 years old. These birds were placed on a terrace indoors, in 4 big cages of 3m² each. Near this flock, there were also 2 other pigeon flocks in a distance of 20 meters and 30 meters respectively. An adequate ration special for racing pigeons as well as fresh water were provided to these birds twice per day. Moreover, cleaning of their environment used to take place on a daily basis. What is more, during autumn 2014 these pigeons participated in racing competitions and the last vaccination against *Paramyxovirus* took place a year before the submission of the dead pigeon to the clinic of Avian Medicine. The pigeons' health problem had been present in this flock for approximately 3 years before this submission. The symptoms manifested in this flock were not typical of any particular disease. Lack of appetite, poor growth of young birds, weakness, vomiting, diarrhea and emaciation were the most important of them. Furthermore, it should be mentioned that 30 birds had died the previous month.

Post mortem examination of the pigeon revealed discoloration and atrophy of the liver, spleen and kidneys, edema of the gizzard, necrosis in the koilin layer of the gizzard and under this, presence of small parasites. Furthermore, dilatation was also observed in the anterior small intestine (duodenum, jejunum), whilst the second half of small intestine and the rectum were full of hemorrhagic content. Macroscopic lesions were not found in other organs, while the bacteriological examination of liver and spleen was negative. Direct microscopy of smears was negative for *Histomonas* spp.

The parasites and the relative infected tissues were transferred to the Laboratory of Parasitology, Veterinary Faculty of Aristotle University of Thessaloniki for parasite recovery. The nematodes

were collected, cleaned with saline and identified under the stereoscope using morphological identification keys provided by Taylor et al (2007). The worms were identified to be *Amidostomum* spp. According to the findings of the postmortem and laboratory examination, amidostomosis was determined to be the cause of the pigeon's death.

DISCUSSION

Amidostomosis is arguably a common infection in birds, such as geese (Kobulej, 1983), ducks (Borgsteede, 2005) and other aquatic birds (Taylor et al., 2007). In Greece the parasite has been found in swans (Papazahariadou et al., 1994), geese and ducks (Papazahariadou et al. 2008), but not in pigeons, so far. Therefore, taking into account 1) that the infection by *Amidostomum* spp. is more common in aquatic birds and 2) that the pigeon examined derived from a racing pigeons flock in a terrace potentially in contact with aquatic birds which travel to the lakes around the region of Thessaloniki, it is readily understood that this contact maybe a major risk factor of this case of pigeon amidostomosis.

In addition, seasonality is not normally associated with this parasitism in migratory aquatic birds, because these birds become firstly exposed on breeding grounds and then they continue to be exposed throughout their lives (Tuggle and Friend, 1999). However, the problems of this pigeon flock and the case of the pigeon amidostomosis happened during autumn, which is the main period of migration for many aquatic species. In other words, this is also the most possible period for the contact between pigeons and wild aquatic birds. Thus, migration period of aquatic birds could be another possible risk factor of our amidostomosis case.

In order to deal with this case of pigeon amidostomosis, both chemotherapeutics and managing practices should be taken. The treatment of clinical or suspected subclinical cases of amidostomosis can be based on medical substances, such as cambendazole (60 mg/kg) against adult worms and larvae, pyrantel (100 mg/kg) against adult worms, citarin (40mg/kg), mebendazole (10mg/kg) and fenbendazole. However, toxicity has been reported in pigeons that received fenbendazole per os at the rate of 30 mg/kg for 5 days. Furthermore,

flubendazole and ivermectin have been proven to be effective against this parasitic infection as well as albendazole and piperazin (Baker, 2007; Islam et al. 2012; Macklin, 2013).

However, apart from chemotherapeutic treatment, the control of amidostomosis depends on managing practices, as well. Particularly, these practices should focus on the disruption of the parasite's life cycle. In detail, the possibility of the parasite transmission is greater in crowded and continuously used habitat, because the combination of accumulative fecal contamination and warm ambient temperatures (20-25o C) promote the quick larval development. Additionally, newly hatched birds are least resistant to infection and birds of all ages are susceptible to reinfection. Hence, proper sanitation and good managing practices are of the utmost importance (Tuggle and Friend, 1999; Baker, 2007).

Although, human health considerations have not been reported so far, people who eat gizzards of relative birds (including pigeons) should cook them thoroughly, discard pigeons' appearing relative clinical signs or lesions and take all the appropriate treating and managing measures to control the prevalence of the parasite and its consequences in their flocks (Tuggle and Friend, 1999).

Although *Amidostomum* spp. has been reported in aquatic birds in Greece, this is the first case of *Amidostomum* spp. in racing pigeons. Therefore, further epidemiological studies are needed, in order to estimate its prevalence in pigeon flocks in different regions of Greece and to elucidate the route of transmission to pigeons.

CONFLICT OF INTEREST

The authors of this paper certify that they have no affiliations with or involvement in any organization or entity with any financial interest, or non-financial interest in the subject matter or materials discussed in this manuscript.

ETHICAL CONSIDERATIONS

On behalf of all authors it is certified that legal and ethical requirements have been met with regards to the humane treatment of animals described in the study. ■

Figure 1: Edema of the gizzard, necrosis in the koilin layer and presence of numerous parasites in a racing pigeon (*Columba livia*).

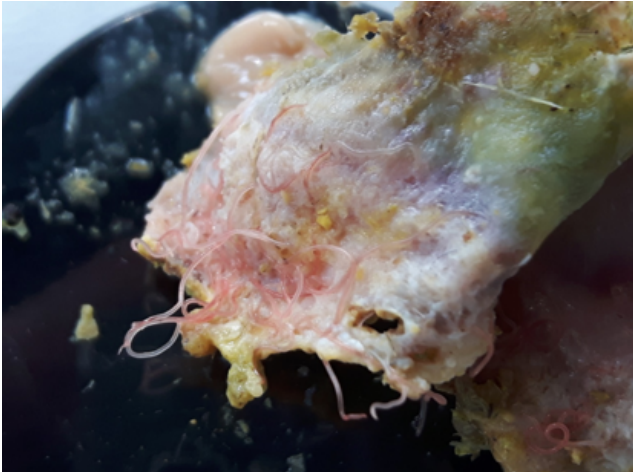
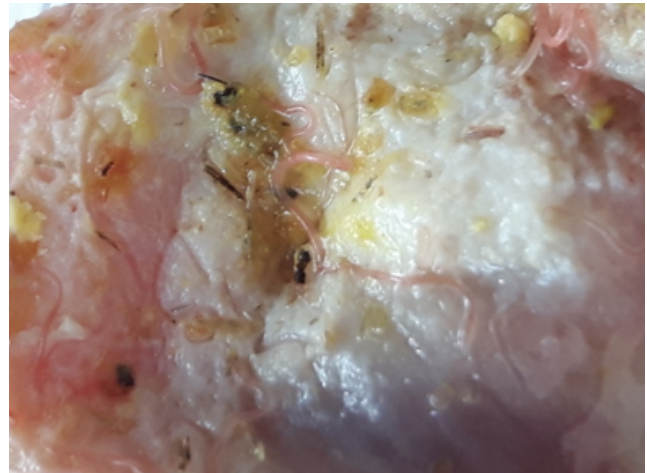


Figure 2. Necrosis and presence of numerous parasites under the koilin layer of the gizzard in a racing pigeon (*Columba livia*).



REFERENCES

- Baker DG (2007) Parasites of birds. In: Flynn's Parasites of Laboratory Animals. 2nded, Blackwell Publishing, Ames: pp. 246-247.
- Beynon PH, Forbes NA, Harcourt-Brown NH (1996) Weight Loss and Enteritis. In: Manual of Raptors, Pigeons and Waterfowls. BSAVA, Shurdington.
- Borgsteede FHM (2005) The gizzard worm, *Amidostomum acutum* (Lundahl, 1848) Seurat, 1918 in common eiders (*Somateria mollissima* L) in the Netherlands *Helminthologia* 42 (4): 215 – 218.
- Bowman DD (1999) Helminths In: Georgis' Parasitology for Veterinarians. 7thed, WB Saunders Company, Philadelphia.
- Enigk K and Dey Hazra A (1970) The behavior of exogenous stages of *Amidostomum anseris* (Strongyloidea, Nematoda). In: Srivastava Commemoration Volume, Indian Veterinary Research Institute, Izatnagar, India: pp 603-619.
- Haralampidis ST (2003) Birds' Parasitism. In: Parasitic diseases of animals and humans: Protozoosis, Helminthiasis, Arthropodosis. University Studio Press, Thessaloniki: pp 472-473.
- Herman CM and Wehr EE (1954) The occurrence of gizzard worms in Canada geese. *Journal of Wildlife Management* (18): 509-513.
- Islam A, Anisuzzaman, Majumder S, Islam MA, Rabbi AKMA, Rahman MH (2012) Efficacy of anthelmintics against nematodes in naturally infected free range ducks. *Eurasian Journal of Veterinary Science* 28 (4): 229-232.
- Jordan F, Pattison M, Alexander D, Faragher T (2001) Intestinal Nematodes. In: Poultry diseases. 5thed, W B Saunders, London: pp 426-429.
- Kavetska KM, Polasik D, Dzierzba E, Jędrzejczak M, Kalisińska E, Rząd I (2015) Revision of the species complex *Amidostomum acutum* (Lundahl, 1848) (Nematoda: Amidostomatidae) by use of molecular techniques. *Ann Parasitol*: 61(1):43-8.
- Kobulej T (1983) *Amidostomosis*. *Parasitology hungarica* (16): 5-22.
- Macklin KS (2013) http://www.merckvetmanual.com/mvm/poultry/helminthiasis/overview_of_helminthiasis_in_poultry.html [accessed 20 December 2015].
- MacNeill AC (1970) *Amidostomum anseris* infection in wild sawns and goldeneye ducks. *Canadian Veterinary Journal* 11 (8): 164-167.
- Papazachariadou M, Georgopoulou I, Iordanidis P, Antoniadou-Sotiriadou K (1994) Cases of death in swans (*Cygnus olor*). *Journal of the Hellenic Veterinary medical Society* 45 (1): 51-54.
- Papazachariadou M, Diakou A, Papadopoulos E, Georgopoulou I, Komnenou A, Antoniadou-Sotiriadou K (2008) Parasites of the digestive tract in free-ranging birds in Greece. *Journal of Natural History* (42): 381–398.
- Saif YM (2008) Internal parasites. In: Diseases of Poultry. 12thed, Blackwell Publishing, Ames: pp 1033-1034.
- Taylor M, Coop R and Wall R (2007) *Veterinary Parasitology*. 3rded, Blackwell Publishing Ltd, 9600 Garsington Road, Oxford, OX4 2DQ, UK.
- Tuggle BN and Friend M (1999) Gizzard Worms. In: Field Manual of Wildlife Diseases: Birds: USGS, Madison: pp 235-240.
- Van Riper SG and Van Riper III C (1985) A summary of known parasites and diseases recorded from the Avifauna of the Hawaiian islands. In: Hawaii's Terrestrial Ecosystems: Preservation and Management Cooperative National Park Resources Studies Unit, University of Hawaii, Manoa, (10): 298-371.