

Journal of the Hellenic Veterinary Medical Society

Vol 70, No 2 (2019)



First Report of *Saprolegnia parasitica* from a Marine Species: Gilthead Seabream (*Sparus aurata*) in Brackish Water Conditions

E. DINÇTÜRK, T. T. TANRIKUL, S. S. BIRINCIOĞLU

doi: [10.12681/jhvms.20825](https://doi.org/10.12681/jhvms.20825)

Copyright © 2019, E. DINÇTÜRK, T.T. TANRIKUL, S.S. BIRINCIOĞLU



This work is licensed under a [Creative Commons Attribution-NonCommercial 4.0](https://creativecommons.org/licenses/by-nc/4.0/).

To cite this article:

DINÇTÜRK E., TANRIKUL, T. T., & BIRINCIOĞLU, S. S. (2019). First Report of *Saprolegnia parasitica* from a Marine Species: Gilthead Seabream (*Sparus aurata*) in Brackish Water Conditions. *Journal of the Hellenic Veterinary Medical Society*, 70(2), 1503–1510. <https://doi.org/10.12681/jhvms.20825>

First Report of *Saprolegnia parasitica* from a Marine Species: Gilthead Seabream (*Sparus aurata*) in Brackish Water Conditions

E. Dinçtürk¹, T.T. Tanrikul¹, S.S. Birincioğlu²

¹ Izmir Katip Celebi University Faculty of Fisheries Department of Aquaculture, Turkey

² Adnan Menderes University Faculty of Veterinary Medicine Department of Pathology, Turkey

ABSTRACT. Saprolegniosis is a serious fungal disease that mostly affects freshwater fish species and eggs. It has a cotton wool-like appearance on the body of amphibians, crustaceans and several fish species. Infected gilthead seabream (*Sparus aurata*) were subjected to clinical, microbiological, parasitological and pathological investigation. On the infected skin samples, grey-white cotton-like patches, erosion of the skin and scale affusion were detected. Lesions covered the whole body of *S. aurata* in the advanced stages. Bacterial growth and parasitic symptoms were not observed in microbiological examination. Microscopic examination showed hyphae carrying cysts that were long and branched. In scanning electron microscopy overviews fungal zoospores were observed. In histopathological observations of sections of skin, erosive-ulcerative dermatitis and mycelium of *Saprolegnia parasitica* were seen in the muscle tissue. Gene sequence-based identification found *Saprolegnia parasitica*. *S. parasitica* has not until now been detected in *S. aurata*. The low salinity of the brackish water is believed to be the predisposing factor of Saprolegniosis in sea bream in this case.

Keywords: Fish disease, fungal disease, *Saprolegnia parasitica*, *Sparus aurata*

Corresponding Author:

Ezgi Dinçtürk, Izmir Katip Celebi University Faculty of Fisheries Department of Aquaculture, TURKEY, Balatçık Mahallesi Havaalanı Şosesi No:33/2 Balatçık 35620 Çiğli İZMİR
E-mail address: ezgi.dincturk@ikc.edu.tr

Date of initial submission: 03-07-2018

Date of revised submission: 19-08-2018

Date of acceptance: 18-09-2018

INTRODUCTION

Saprolegniosis is an acute infection and a worldwide mycotic freshwater disease affecting fish. It is widely distributed and all freshwater fish and eggs are susceptible to this infestation (Gaikowski et al., 2003). It is indicated in amphibians, crustaceans and several fish species : (channel catfish (*Ictalurus punctatus*) (Howe et al., 1999); cultured pike (*Sander lucioperca*) (Willoughby, 1985); elver (*Anguilla rostrata*) and suckers (*Catostomus commersonii*) (Roberts, 1989)) and especially in salmonids, tilapia species and carps ((*Oncorhynchus kisutch*) Hatai and Hoshiai, 1993; (*Salmo trutta*) Pickering and Christie, 1990 ; (*Tilapia nilotica*) Zaki et al., 2008; (*Carassius auratus*) Parra-Laca et al., 2015). It has also caused serious production losses (Alderman and Polglase, 1985; Post 1987). In Scottish, Norwegian and Chilean salmon hatcheries and farms in particular, Saprolegnia infections have been reported as causing losses of more than 10% (Langvad, 1994; Phillips et al., 2008; Van den Berg, 2013).

It usually starts with cotton wool-like growth on the head and dorsal fin region then spreads all over the body as focal patches (Abdel-Aziz et al., 2002; Bangyakkun et al., 2003; Osman et al., 2008; Roberts, 2012). In particular, cool and warm water fish eggs are reported to be at risk because their incubation temperatures are generally the same or near the optimum temperature range for zoospore growth (Gaiokowski et al., 2003). Stress factors such as abrasions, poor water quality, malnutrition, overcrowdedness, handling, spawning or any bacterial or parasitic infections lead to the presence of this mycotic disease (Noga, 1993; Pickering, 1994; Hussien et al., 2010). Temperature stress, especially cold temperatures, block immune system activity and reduce defenses against invading disease organisms, causing osmotic stress and mortality (Knights and Lasee, 1996; Hussien et al., 2010). It has been claimed that the final stages of this infection cause impairment of osmoregulation, failure of the respiratory system and, in some cases, of organs (Pickering and Willoughby, 1982; Van den Berg et al., 2013). The oomycete pathogen usually establishes itself focally, invading the stratum spongiosum of the dermis and then extending laterally over the epidermis, eroding it as it spreads. A relatively superficial invasion of the dermis rapidly leads to fluid imbalance and peripheral circulatory failure (shock) due to an inability to maintain blood circulation (Roberts, 2012).

In aquaculture, Saprolegniosis is observed mostly as *Saprolegnia parasitica* in numerous freshwater fish species (Van den Berg et al., 2013). *S. parasitica* was isolated from seabass (Cook and Unwin, 1985, press communication) and meagre (Abou El-Atta and Saleh, 2010) in brackish water conditions. Saprolegnia isolates were found not to develop any sexual stage in in vitro cultures and therefore cannot be identified (Grandes et al., 2000). The difference in radial growth rate, some biochemical characteristics and variation in the esterase isoenzyme pattern are used for the identification of some saprolegnia isolates (Beakes and Ford 1983; Hatai et al., 1990; Welsh and McClelland, 1990), but molecular methods have recently been used to characterise this infection (Van den Berg et al., 2013).

Formalin is the only drug currently approved by FDA for treatment as it has a strong effect and is relatively cheap. It is recommended to use 150-300 mg L⁻¹ for the ova and fish (Marking et al., 1994; Taylor Francis et al., 1994). Malachite green was previously used to control Saprolegniosis, but it is now banned because of its carcinogenic, mutagenic and teratogenic characteristics (Gaikowski et al., 2003). In addition, hydrogen peroxide has been used against Saprolegniosis but is not recognized by the FDA (Barnes et al., 1998; Howe et al., 1999; Gaiokowski et al., 2003).

In the present study, *Saprolegnia parasitica* was isolated from gilthead seabream (*Sparus aurata*). In general, Saprolegniosis has been reported from fresh water fish species, especially in rainbow trout eggs in Turkey, but in the present water conditions, the fish were in brackish water, which is believed to be the reason for this first observation from sea bream.

MATERIALS AND METHODS

Fish

Infected gilthead seabream (*Sparus aurata*) from the university ponds at Katip Çelebi University Fisheries Research and Training Center which had a fungal infection were studied. A total of 48 fish weighing nearly 100 g were examined during the infestation. Fish were subjected to clinical, microbiological, parasitological and pathological investigation.

Water

During the outbreak, the water parameters of the ponds were monitored. Temperature, salinity, oxygen and pH parameters were determined to be 10 °C, 3.93‰, 10.07 mg/L and 7.7, respectively.

Microbiological examination

External examination was conducted on the skin, abdomen, fins, scales, and internal organs such as the gills, kidney, spleen, intestine and liver were also investigated. Bacteriological examination was carried out according to Austin and Austin (2007). Bacterial isolates from the kidneys and spleen of infected fish were streaked on Tryptic Soy Agar (TSA, Oxoid) and Tryptic Soy Agar supplemented with 5% defibrinated sheep blood (BTSA) and incubated at 25 °C for 72 hours.

Pure cultures were provided by inoculation of the samples through taking a small tuft of mycellum from the fish skin and grown on Sabouraud Glucose Agar (SGA) and Malt Extract Agar (MEA) at 21 °C for 3-4 days. Inoculation occurred in a Haier Bio-Medical Biological Safety Cabinet. After incubation, unstained and colored examination was conducted with an Olympus BX53 Light Microscope. Colorization of the fungus was conducted with Giemsa staining (Arda, 2006) in order to identify the fungi samples. Identification was performed according to Dvarak and Atanoesk (1969) both from wet samples from skin ulcers and growth on SGA and MEA (Dvarak and Atanoesk, 1969).

Histopathological examination

For histological examination, infected tissues of the skin with muscles, gills, liver and kidney were fixed in 10% buffered formalin after the necropsy. The tissue was then processed routinely and prepared into paraffin blocks. The blocks of the tissues were cut to 5 µm thickness and stained with Haematoxylin and Eosin (H-E) and periodic acid schiff (PAS) and examined under a light microscope (Culling et al., 1985).

Scanning electron microscopic examination

Samples were sputtered with gold by QUORUM Q150 RES and examined in a Carl Zeiss 300 VP scanning electron microscope in the Central Research Laboratory, Izmir Katip Celebi University.

Molecular Identification

DNA isolation was conducted using the GeneMATRIX Tissue and Bacterial DNA Purification Kit. For PCR amplification of the 5.8S rRNA gene, ITS1 and ITS4 primers were used. Amplified products of the template DNA were sent to the Macrogen direct sequencing service (Macrogen, Holland) for sequence determination. Samples were sequenced in two directions from opposite strands and the results were compared. Sequences were then checked with the BLASTN 2.6.1. database.

RESULTS

Infected fish were found to be stunned while swimming near the surface of water, with a loss of balance and reduced feed intake during the outbreak. The mortality rate was calculated to be 15% in that period. For treatment, formalin (containing approximately 37% formaldehyde by weight) was used to control the infection following a 30 min exposure at 2 ml/L every other day. On the infected skin samples, grey-white cotton-like patches, erosion of the skin and scale affusion were shown (Figure 1). Mycelial growth was detected especially on the head, eyes, gills, fins and body surface. In advanced stages lesions covered the whole body of *S. aurata* (Figure 2). The results of bacteriological and parasitological studies showed that neither pathogenic bacterial growth nor parasites were present in infected fish.




Figure 1. Infected gilthead sea bream (*Sparus aurata*) in university ponds.

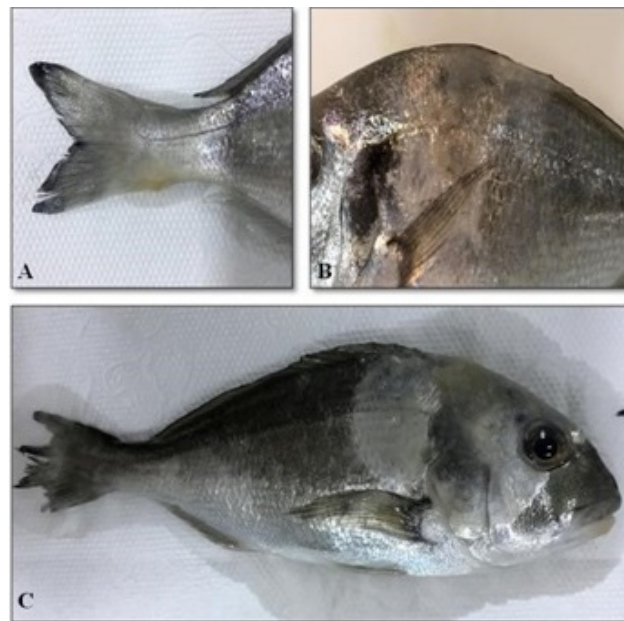


Figure 2. Infected gilthead sea bream (*Sparus aurata*). On the skin, grey-white cotton like *Saprolegnia parasitica* mycelium. A. On the pedicel. B. Dorsolateral. C. Dorsolateral, caudal and on the head localized.

Microbiological results

Isolation of *Saprolegnia parasitica* was conducted on SGA and MEA. In four days complete growth was observed.

Microscopic examination of *Saprolegnia parasitica* from native and colored samples is shown in Figures 3 and 4. The hyphae carrying the cysts are shown to be long and branched. Fungal zoospores from the scanning electron microscopy overviews are displayed (Figure 5).

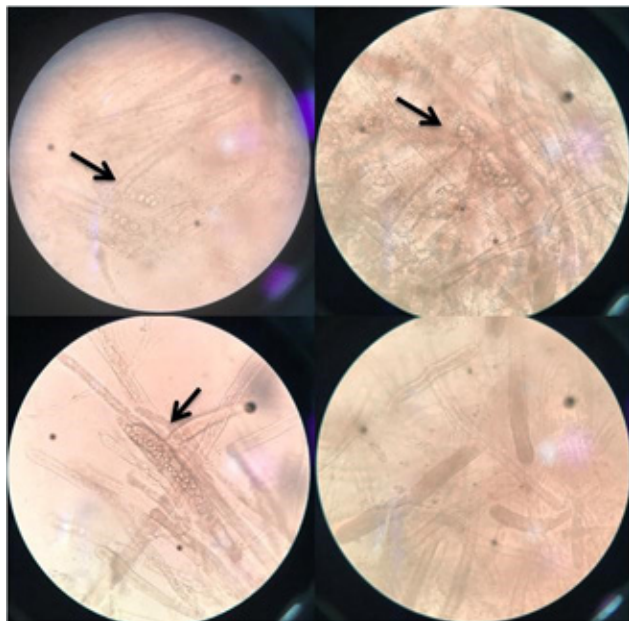


Figure 3. Unstained images *Saprolegnia parasitica* that shows zoosporematogoniums (arrows) (x400).

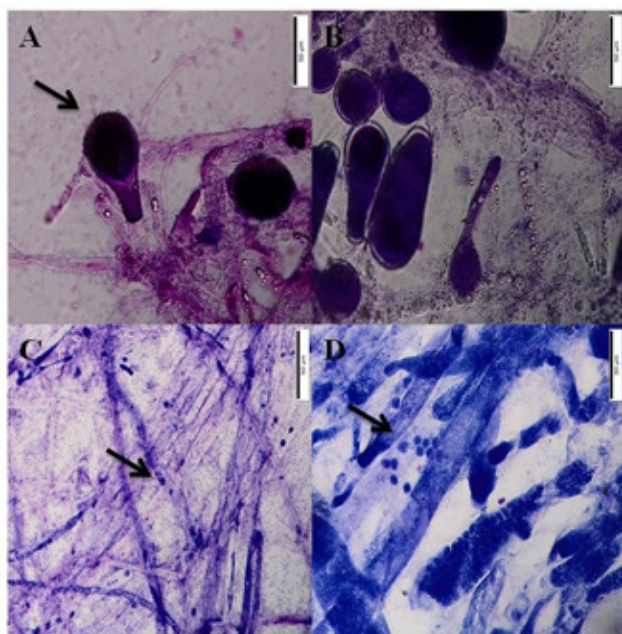


Figure 4. *Saprolegnia parasitica*. A-B. Zoosporematogoniums (arrow). C-D. Primer sporematogoniums (arrows) (Giemsa, x 200).

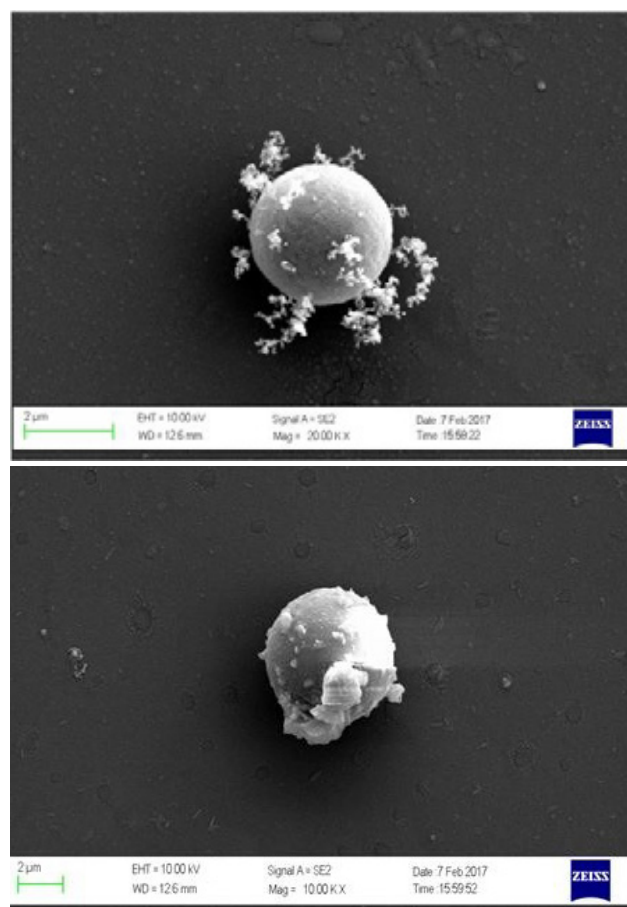


Figure 5. The zoospores of *Saprolegnia parasitica*. SEM. Bar. 2 µm scale.

Histopathological results

Erosive-ulcerative dermatitis was seen in skin sections. In epidermis and hypodermis necrosis, there were regenerations in intact epithelium. Dense filamentous mycelium was detected on the surface. This reacted positively to PAS staining. Mycelium and leukocyte infiltration were observed in dilate flake pockets (Figure 6). Liquefaction necrosis was detected in the muscles of the same area. A small number of mycelia was found among these muscles (Figure 7). Hepatocytes were moderately fatty in the liver, while histopathological findings were not found in other organs.

Molecular Identification Results

The PCR amplification of 18S rRNA gene sequence was checked in the BLASTN 2.6.1 database. The FASTA homology resulted in 100% nucleotide identity between the current isolate and *Saprolegnia parasitica* (accession number AM228725.1)

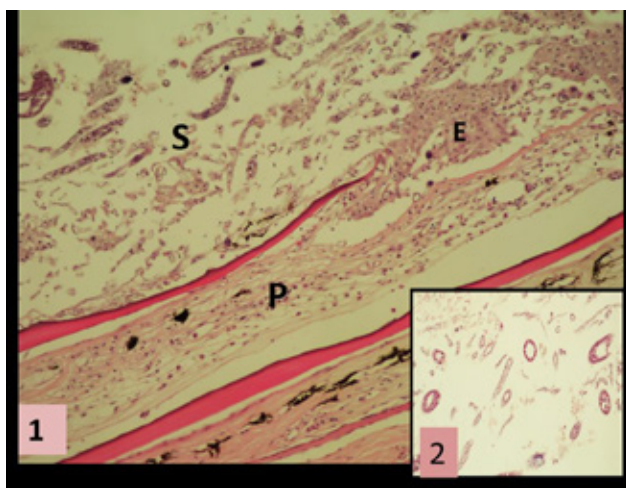


Figure 6. Intensive *Saprolegnia parasitica* hyphae and zoospores on skin surface (S). 1. Dilatation on epidermis and scale pockets (P), cell infiltration. Lateral section of zoosporangium (H.E. x 200).

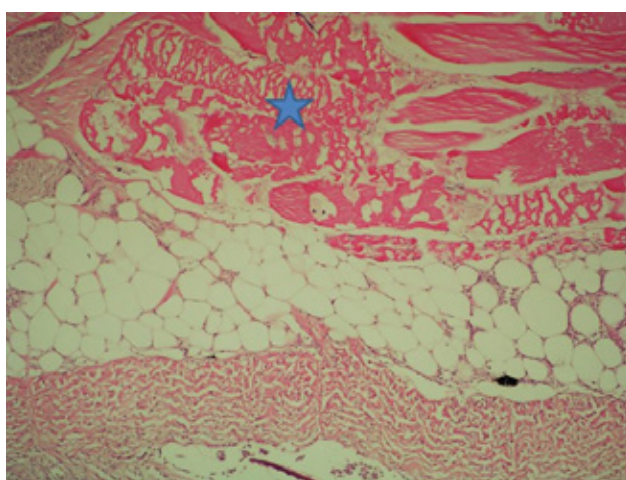


Figure 7. Liquefaction necrosis in subcutaneous muscles (star). H.E. x100).

DISCUSSION

Saprolegniosis, which is caused by *S. parasitica*, is a worldwide disease that mostly affects freshwater fish and eggs and cause great economic losses to the aquaculture industry (Duboon et al., 2006). Countries like Norway, Ireland, Japan and the UK have reported mass mortalities based on salmon aquaculture (Bruno et al., 2011). Eggs are particularly susceptible to this infestation because of incubation systems that allow close contact and attachment of zoospores, although infertile and dead eggs are also convenient substrate for zoospore colonization (Gaikowski et al., 2003).

Throughout the outbreak, the water parameters of the ponds were observed. Temperature, salinity, oxygen and pH parameters were determined to be 10 °C, 3.93‰, 10.07 mg/L and 7.7, respectively. Elatta

(2013) reported a fungal disease (*Aphanomyces* sp.) in *Sparus aurata* with nearly the same salinity, 3‰. In research on Norwegian salmon hatcheries, Thoen et al (2015) claimed that water temperatures higher than 6 °C did not result in an increase in the number of *Saprolegnia* spp. spores, and this was also the case in regard to oxygen pressure and water flow. Chauhan (2014) isolated some fungi species from the pond culture of *Tilapia mossambicus* and identified two of them as *Saprolegnia diclina* and *Saprolegnia parasitica*. During the study, the water temperature was recorded as 16 ± 2 °C, pH 7.9 ± 1.6 and dissolved oxygen 6.8 ± 3.0 mg/l. These parameters are similar to those found to be suitable for Saprolegniosis reproduction in the current study.

Temperature stress may slow immune system activity and reduce the defense against pathogens (Knights and Lasee, 1996). Temperature shock and poor water quality are also inductors of Saprolegniosis (Yanong, 2003; Gieseke et al., 2006). Howe and Stehly (1998) claimed that during the winter months, fungal infections cause major losses. Bly et al (1992) explained this as the rapid decrease of the water temperature leading to immunosuppression that crosses over with the presence of fungal zoospores. In this study, the Saprolegniosis outbreak occurred after the rapid decrease of water temperature, from 13° C to 10° C, with an increase of turbidity which are also contributing factors along low salinity, in January 2017.

Saprolegniosis has been reported in rainbow trout eggs (Diler, 1992), fry (Kubilay et al., 2008) and adult individuals from different commercial companies in Turkey (Aydın and Küçükgül, 2014). Aydın and Küçükgül (2014) published results showing that in four rainbow trout farms Saprolegniosis was determined in half of these at times in the year when the water temperature was 10-14 °C. During these periods of time mortality rates were calculated to be 8% and 13.3% as a result of these infestations. In the current study, Saprolegniosis was isolated in a marine species, gilthead sea bream, in nearly the same temperature conditions and caused 15% mortality during the outbreak.

Hussien et al (2010) observed focal greyish-white patches on the skin, fins, gills and head region of *Mu-gel cephalus* which were caused by the Saprolegniosis infection. Similarly, Das et al (2012) noted visible red or grey patches of filamentous mycelium in Indian major carp fingerlings. Cotton-like patches characteristically reported for Saprolegniosis on macroscopic

examination (Chauhan et al., 2014) were observed on the skin surface of all gilthead sea bream in this study. Localizations were more pronounced in the dorsal and caudal regions, as mentioned above.

Bruno et al (1999) considered Saprolegniosis as a secondary infection arising from bacterial infections, immunosuppression, parasite infestations and poor husbandry. It reduces osmoregulation and often leads to death (Pickering and Willoughby 1988). Kubilay et al (2008) reported Saprolegnia spp. from rainbow trout fry that were infected with *Flavobacterium columnare*. On the contrary, Pottinger and Day (1999) observed no secondary disease problems with the same species. In this study, neither pathogenic bacteria nor parasites were detected in gilthead sea bream during the infestation.

The primary zoosporangias and mycelia, as described by Mueller (1992), were formed as clusters with PAS stain made from skin-scraping samples. Among these, primer zoospores in the form of free spots were also observed. The predominant clinical and histopathological feature in all cases is the extensive ulcerative lesion, which overlies a penetrat-

ing myopathy extending deep into the muscle. It has a greyish-white necrotic superficial covering of degenerating tissue and fungal hyphae (Roberts, 2012; Hussein et al., 2013). Similar findings were observed in this study, but fungal lesions reported in internal organs were not found in sea bass (Chauhan et al., 2014). Lesions and fungi were limited to the skin only. The reason for this is related to the differences between the water and the fish species.

CONCLUSIONS

S. parasitica has not yet been detected in cage farms of *S. aurata*. The reason for the absence of the infestation in cage farms is the high salinity that does not allow any zoospore growth in sea water. Brackish water salinity tends to let both marine and freshwater species exist, as it also does the zoospores of the Saprolegnia species. In this case, the low salinity parameters and the rapid decrease of water temperature caused stress and led to Saprolegniosis in sea bream.

CONFLICT OF INTEREST

The authors declare no conflict of interest.

REFERENCES

- Abdel Aziz ES, Yonis AA, Ali MNM (2002) Effect of water temperature upon the response of cultured *Clarias Lazera* to *Saprolegnia* infection and the consequent haematological changes. *Egyptian Journal of Comparative and Clinical Pathology* Vol 15 No. 2pp 108-125.
- Abou El Atta ME, Saleh OA (2010) Study on some diseases problems facing the culturing of Meagre (*Argyrosomus regius*) fish in Domietta Governorate. *Abbassa Int. J. Aqua.* Vol. 3 No.(1)2010: 231 – 245.
- Alderman DJ, Polglase JS (1984) A comparative investigation of the effects of fungicides on *Saprolegnia parasitica* and *Aphanomyces astaci*. *Transactions of the British Mycological Society* 83:313– 318. [https://doi.org/10.1016/S0007-1536\(84\)80153-9](https://doi.org/10.1016/S0007-1536(84)80153-9)
- Arda M (2006) *Temel Mikrobiyoloji*, Medisan Yayınevi, Ankara.
- Austin B, Austin A (2007) Bacterial Fish Pathogens, Diseases of Farmed and Wild Fish, Fourth Edition. *Springer-Praxis Publishing, Chichester*. 978-1-4020-6068-7.
- Aydın U, Küçükgül A (2014) Elazığ Bölgesi Alabalık İşletmelerinde Merkezi Kayıt Sistemi. *Bilim ve Gençlik Dergisi*, Cilt 2, Sayı 2, 2014 / Vol. 2, Issue 2, 2014 ISSN: 2148-0273
- Bangyeekhun E, Pylkkö P, Vennerström P, Kuronen H, Cerenius L (2003) Prevalence of a Single Fish-pathogenic *Saprolegnia* sp. Clone in Finland and Sweden. *Diseases of Aquatic Organisms*, 53(1), 47-53. doi:10.3354/dao053047
- Barnes ME, Ewing DE, Cordes RJ, Young GL (1998) Observations on Hydrogen Peroxide Control of *Saprolegnia* spp. During Rainbow Trout Egg Incubation. *The Progressive Fish-Culturist*, 60(1), 67-70. [https://doi.org/10.1577/1548-8640\(1998\)060<0067:OOHPCO>2.0.CO;2](https://doi.org/10.1577/1548-8640(1998)060<0067:OOHPCO>2.0.CO;2)
- Beakes G, Ford H (1983) Esterase Isoenzyme Variation in The Genus *Saprolegnia*, with Particular Reference to The Fish-pathogenic *S. diclina-parasitica* Complex. *Microbiology*, 129(8), 2605-2619. doi: 10.1099/00221287-129-8-2605
- Bly JE, Lawson LA, Dale DJ, Szalai AJ, Durborow RM, Clem LW (1992) Winter Saprolegniosis in Channel Catfish. *Diseases of Aquatic Organisms*, 13, 155– 164. doi : 10.3354/dao013155
- Bruno DW, Wood BP (1999) *Saprolegnia* and Other Oomycetes, p. 599-659. In P. T. K. Woo and D. W. Bruno (ed.), *Fish Diseases and Disorders*, vol. 3. CAB International, Wallingford, United Kingdom.
- Chauhan R (2014) Fungal Attack on *Tilapia mossambicus* in Culture Pond, Leading to Mass Mortality of Fishes. *International Journal of Pharma Sciences and Research (IJPSR)*.
- Chauhan R, Beigh A, Hand MH, Bhat MH (2014) Histopathological Manifestations in Commercially Important Fish, *Clarias batrachus* (L) Found Infected With *Saprolegnia diclina*. *Indo American Journal of Pharmaceutical Research*, 4(2) ; 1168-1172.
- Culling AF, Allison TR, Barr TW (1985) *Cellular Pathology Technique*, 4th Edition, London: *Butterworth and Co.(Publ.) Ltd*, p.269-270
- Das SK, Murmu K, Das A, Shakuntala I, Das RK, Ngachan SV, Majhi SK (2012) Studies on the identification and control of pathogen *Saprolegnia* in selected Indian major carp fingerlings at mid hill altitude. *Journal of Environmental Biology*. 2012 May; 33(3): 545-549.
- Diler Ö (1992) *Saprolegniosis Hastalığının Patogenesi ve Isparta Bölgesi Balık İşletmelerindeki Dağılımı Üzerinde Bir Araştırma* (Doctoral dissertation, Akdeniz Üniversitesi Fen Bilimleri Enstitüsü).
- Duboon AHA, Mukhtar MAA, Jassim AAR, Bader SQ, Zawar JMA (2006) Saprolegniosis of *Barbus sharpeyi*, Gunther (Bunnei Fish) in Basrah/ IRAQ, Iraq: *Iraqi Journal of Aquaculture*, 2006, 1,pp. 25-29.
- Dvarak J, Atanoesk M (1969) Mycological Diagnosis of Animal Dermato-phytosis. *Academic Pp.* 213.dvorak
- Elatta MEA (2013) Some Bacterial and Fungal Affections Causing Disease Problems in Cultured Seabream *Sparus aurata* in Damietta Governorate and Trials for Control.
- Gaikowski MP, Rach JJ, Drobish M, Hamilton J, Harder T, Lee LA, Moen C, Moore A (2003) Efficacy of hydrogen peroxide in controlling mortality associated with saprolegniosis on walleye, white sucker, and paddlefish eggs. *North American Journal of Aquaculture*, 65(4), 349-355.
- Gieseker CM, Serfling SG, Reimschuessel R (2006) Formalin treatment to reduce mortality associated with *Saprolegnia parasitica* in rainbow trout, *Oncorhynchus mykiss*. *Aquaculture*, 253(1), 120-129. <https://doi.org/10.1016/j.aquaculture.2005.07.039>
- Grandes JMF, Diez MF, Gancedo JMA (2000) Ultrastructural Analysis of *Saprolegnia* Secondary Zoospore Cyst Ornamentation From Infected Wild Brown Trout, *Salmo trutta* L., and River Water Indicates Two Distinct Morphotypes Amongst Long-Spined Isolates. *Journal of Fish Diseases* 23, 147–160. DOI: 10.1046/j.1365-2761.2000.00239.x
- Hatai K, Hoshiai G (1993) Characteristics of Two *Saprolegnia* Species Isolated From Coho Salmon with Saprolegniasis. *Journal of Aquatic Animal Health* 1993. 5, 115-118. [https://doi.org/10.1577/1548-8667\(1993\)005<0115:COTSSI>2.3.CO;2](https://doi.org/10.1577/1548-8667(1993)005<0115:COTSSI>2.3.CO;2)
- Hatai K, Willoughby LG, Beakes GW (1990) Some Characteristics of *Saprolegnia* Obtained From Fish Hatcheries in Japan. *Mycological Research* 94, 182–190. [https://doi.org/10.1016/S0953-7562\(09\)80611-4](https://doi.org/10.1016/S0953-7562(09)80611-4)
- Howe GE, Gingerich WH, Dawson VK, Olson JJ (1999) Efficacy of Hydrogen Peroxide for Treating Saprolegniasis in Channel Catfish. *Journal of Aquatic Animal Health*, 11(3): 222-230.
- Howe GE, Stehly GR (1998) Experimental Infection of Rainbow Trout with *Saprolegnia parasitica*. *Journal of Aquatic Animal Health*, v. 10, no. 4, p. 397-404.
- Hussien AM, Ahmed IE, Waled SE, Omima A (2010) A trial for Induction of Saprolegniosis in *Mugil cephalus* with Special Reference to Biological Control. *Journal of American Science*, 6(6), 6.
- Knights BC, Lasee BA (1996) Effects of Implanted Transmitters on Adult Bluegills at Two Temperatures. *Transactions of the American Fisheries Society*, 125(3), 440-449.
- Kubilay A, Altun S, Diler Ö, Ekici S (2008) Isolation of *Flavobacterium columnare* from Cultured Rainbow Trout (*Oncorhynchus mykiss*) fry in Turkey. *Turkish Journal of Fisheries and Aquatic Sciences*, 8(1).
- Langvad F (1994) Saprolegnia in Norwegian fish farming. In: Salmon Saprolegniasis (ed. by G.J. Mueller), pp. 188–201. *Bonneville Power Administration, Div. Fish and Wildlife, Portland, OR*.
- Marking LL, Rach JJ, Schreier TM (1994) Evaluation of antifungal agents for fish culture. *Progressive Fish-Culturist* 56:225–231.
- Mortada Hussein MA, Hassan WH, Mahmoud MA (2013) Pathogenicity of *Achlya proliferoides* and *Saprolegnia diclina* (Saprolegniaceae) Associated with Saprolegniosis Outbreaks in Cultured Nile Tilapia (*Oreochromis niloticus*). *World Journal of Fish and Marine Sciences*, 5 (2): 188-193.
- Mueller GJ (1992) Proceedings The Symposium Saprolegnia in Salmon Held at the 1992 Annual Meeting of The Mycological Society of America on August 8, 1992, in the Portland Convention Center, Portland, Oregon.
- Noga EJ (1993) Water Mold Infections of Freshwater Fish: Recent Advances. *Annual Review of Fish Diseases* 3, 291–304. [https://doi.org/10.1016/0959-8030\(93\)90040-I](https://doi.org/10.1016/0959-8030(93)90040-I)
- Osman HAM, Solman WE, Noor El Deen AE, Lada AM (2008) Induction of Saprolegniosis in *Oreochromis niloticus* with Special Reference to its Biological. *Control. Global Veterinaria* 2 (1):pp 32-37.
- Parra-Laca R, Hernández-Hernández FC, Lanz-Mendoza H, Enriquez BL, Gil GF (2015) Isolation and Identification of *Saprolegnia* Sp from Fresh Water Aquarium Fishes and the Hemolymph Immune Response of *Dactylopus coccu* Costa de 1835 (Homoptera: Coccoidea: Dactylopidae) against this Oomycete. *Entomology, Ornithology and Herpetology*, 4(2), 1.
- Phillips AJ, Anderson VL, Robertson EJ, Secombes CJ, van West P (2008) New insights into animal pathogenic oomycetes. *Trends in Microbiology* 16, 13e19. <https://doi.org/10.1016/j.tim.2007.10.013>
- Pickering AD, Willoughby LG (1982) Saprolegnia Infections of Salmonid Fish. In: Roberts, R.J. (Ed.), *Microbial Diseases of Fish*. Academic Press, London, pp. 271–297.
- Pickering AD, Willoughby LG (1988) Saprolegnia of Salmonid Fish. 15th Annual Report, U.S. Fish and Wildlife Service. (38–48 pp.).
- Pickering AD, Christie P (1990) Sexual Differences in the Incidence and

- Severity of Ectoparasitic Infestation of the Brown Trout, *Salmo trutta* L. *Journal of Fish Biology*, 16, 669-683.
- Pickering AD (1994) Factors Which Predispose Salmonid Fish to Saprolegniasis. *Edited by G. J. Mueller*. U.S. Department of Energy, Bonneville Power Administration, Portland, Oregon. pp. 67-84.
- Post GW (1987) *Textbook of Fish Health*, 2nd edition. TFH Publications, Neptune City, New Jersey
- Pottinger TG, Day JG (1999) A *Saprolegnia parasitica* Challenge System for Rainbow Trout: Assessment of Pyceze as an Anti-fungal Agent for Both Fish and Ova. *Diseases of Aquatic Organisms*, 36, 129–141.
- Roberts RJ (2012) *Fish Pathology*, 4.Edition. Blackwell Publishing, United Kingdom, pp.387-390.
- Taylor Francis PB, Walser CA, Phelps RP (1994) The Use of Formalin and Iodine to Control Saprolegnia Infections on Channel Catfish, *Ictalurus punctatus*, Eggs. *Journal of Applied Aquaculture* 3, 269. https://doi.org/10.1300/J028v03n03_05
- Thoen E, Evensen Ø, Skaar I (2015) Factors Influencing Saprolegnia spp. Spore Numbers in Norwegian Salmon Hatcheries. *Journal of Fish Diseases*.
- Van Den Berg AH, McLaggan D, Diéguez-Urbeondo J, Van West P (2013) The Impact of The Water Moulds *Saprolegnia diclina* and *Saprolegnia parasitica* on Natural Ecosystems and The Aquaculture Industry. *Fungal Biology Reviews*, 27(2), 33-42. <https://doi.org/10.1016/j.fbr.2013.05.001>
- Welsh J, McClelland M (1990) Fingerprinting Genomes Using PCR with Arbitrary Primers. *Nucleic Acids Research*, 18(24), 7213-7218. <https://doi.org/10.1093/nar/18.24.7213>
- Willoughby LG (1985) Rapid Preliminary Screening of *Saprolegnia* on Fish. *Journal of Fish Diseases* 8: 473-476. doi: 10.1111/j.1365-2761.1985.tb01282.x
- Yanong PE (2003) Fungal Diseases of Fish. *Veterinary Clinics of North America Exotic Animal Practice* 6(2):377-400. doi: 10.1016/S1094-9194(03)00005-7
- Zaki MS, Fawzi OM, Jackey JE (2008) Pathological and biochemical studies in *Tilapia nilotica* infected with *Saprolegnia parasitica* and treated with potassium permanganate. *J. Agric. Environ. Sci.*, 3, 677-680.