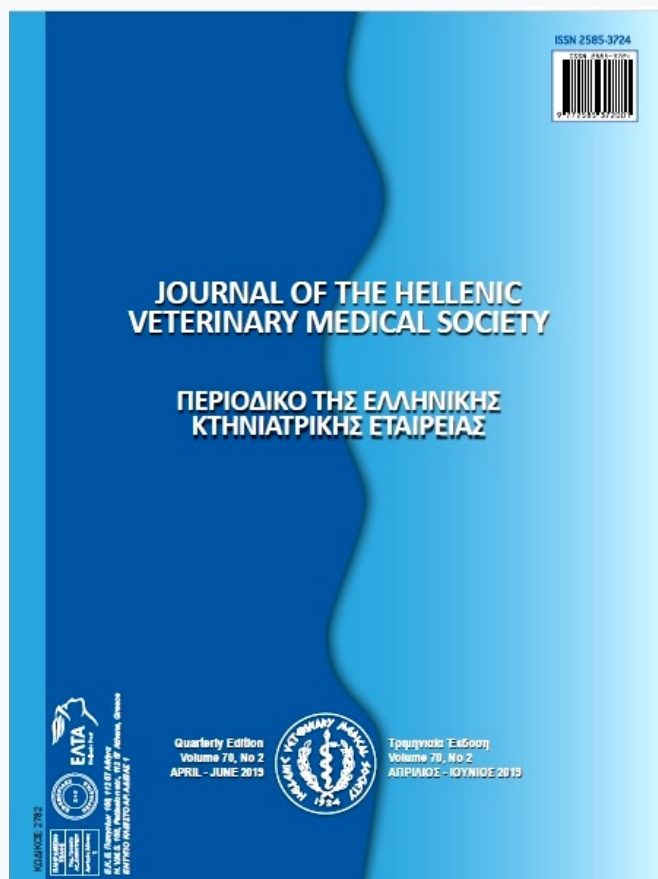


Περιοδικό της Ελληνικής Κτηνιατρικής Εταιρείας

Τόμ. 70, Αρ. 2 (2019)



Αδενοκαρκίνωμα κολοβώματος μήτρας σε σκύλα με υπόλειμμα ωοθήκης: Αναφορά περιστατικού

P. KOKKINOS, CH. VERVERIDIS, M. PATSIKAS, M. KRITSEPI-KONSTANTINOU, G. M. KAZAKOS, D. PSALLA

doi: [10.12681/jhvms.20865](https://doi.org/10.12681/jhvms.20865)

Copyright © 2019, P. KOKKINOS, CH. VERVERIDIS, M. PATSIKAS, M. KRITSEPI-KONSTANTINOU, G.M. KAZAKOS, D. PSALLA



Άδεια χρήσης [Creative Commons Αναφορά-Μη Εμπορική Χρήση 4.0](https://creativecommons.org/licenses/by-nc/4.0/).

Βιβλιογραφική αναφορά:

KOKKINOS, P., VERVERIDIS, C., PATSIKAS, M., KRITSEPI-KONSTANTINOU, M., KAZAKOS, G. M., & PSALLA, D. (2019). Αδενοκαρκίνωμα κολοβώματος μήτρας σε σκύλα με υπόλειμμα ωοθήκης: Αναφορά περιστατικού. *Περιοδικό της Ελληνικής Κτηνιατρικής Εταιρείας*, 70(2), 1583–1588. <https://doi.org/10.12681/jhvms.20865>

**Uterine stump adenocarcinoma in a bitch with an ovarian remnant:
A case report**

**P. Kokkinos¹, Ch. Ververidis², M. Patsikas², M. Kritsepi-Konstantinou²,
G.M. Kazakos², D. Psalla²**

¹*Animal Health Trust, Lanwades Park, Kentford, Newmarket, Suffolk, CB8 7UU, UK*

²*School of Veterinary Medicine, Faculty of Health Sciences, Aristotle University of Thessaloniki, Greece*

**Αδενοκαρκίνωμα κολοβώματος μήτρας σε σκύλα με υπόλειμμα ωοθήκης:
Αναφορά περιστατικού**

**Π. Κόκκινος¹, Χ. Βερβερίδης², Μ. Πατσίκας², Μ. Κριτσέπη-Κωνσταντίνου²,
Γ.Μ. Καζάκος², Δ. Ψάλλα²**

¹*Animal Health Trust, Lanwades Park, Kentford, Newmarket, Suffolk, CB8 7UU, UK*

²*Τμήμα Κτηνιατρικής, Σχολή Επιστημών Υγείας, Αριστοτέλειο Πανεπιστήμιο Θεσσαλονίκης*

Corresponding Author:
Charalampos Ververidis, StavrouVoutira 11, 54627 Thessaloniki, Greece
E-mail address: harisver@vet.auth.gr

Date of initial submission: 10-06-2018
Date of revised submission: 14-11-2018
Date of acceptance: 18-12-2018

ABSTRACT. A 3-year-old female spayed dog was presented with a history of sanguineous vaginal discharge of 2 month duration. The dog was spayed 1.5 years before presentation. Clinical examination revealed a large, solid, ovoid mass in the caudal abdomen, recognized by diagnostic imaging as an enlargement at the top of the uterine stump. Additionally, high serum progesterone concentration was measured, confirming the presence of functional ovarian tissue in dioestrus. With a suspicion for a related uterine stump pyometra or less likely, for other enlargements, a coeliotomy was performed. A mass at the apex of the uterine body and a right side ovarian remnant were found. Both structures and the remaining uterine stump were excised. The uterine remnant mass was histologically diagnosed as uterine adenocarcinoma, herein detected for the first time at the uterine stump in the bitch. Unsuccessful, incomplete ovariohysterectomy may permit even neoplastic transformation of uterine stump tissues.

Keywords: adenocarcinoma, uterine stump, ovarian remnant

ΠΕΡΙΛΗΨΗ. Θηλυκός σκύλος, ηλικίας 3 ετών, προσκομίστηκε 1,5 χρόνο μετά από υποτιθέμενη στείρωση, διότι παρουσίαζε επί 2 μήνες αιμορραγικό έκκριμα από το αιδοίο. Στην κλινική εξέταση ψηλαφήθηκε ευμεγέθες, συμπαγές, ωοειδές μórφωμα στην οπίσθια κοιλία, το οποίο στην απεικονιστική διερεύνηση προσδιορίστηκε ως διογκωμένο κολόβωμα μήτρας. Επιπλέον διαπιστώθηκε υψηλή συγκέντρωση προγεστερόνης στον ορό του αίματος, αποδεικτική παρουσίας λειτουργικού ωοθηκικού ιστού σε δίοιστρο. Με υποψία πυομήτρας του κολοβώματος της μήτρας και λιγότερο άλλων ειδών μορφώματος πραγματοποιήθηκε μέση λαπαροτομή. Βρέθηκε μórφωμα – μάζα στο πρόσθιο άκρο του κολοβώματος το οποίο εξαιρέθηκε μαζί με το υπόλοιπο σώμα της μήτρας, καθώς και υπόλειμμα δεξιάς ωοθήκης. Το μórφωμα προσδιορίστηκε ιστοπαθολογικά ως αδενοκαρκίνωμα και διαπιστώθηκε για πρώτη φορά σε κολόβωμα μήτρας σκύλας. Η αποτυχημένη, μερική ωοθηκυστερεκτομή μπορεί να επιτρέψει ακόμη και την εξαλλαγή των ιστών του κολοβώματος της μήτρας.

Λέξεις κλειδιά: αδενοκαρκίνωμα, κολόβωμα μήτρας, παραμονή ωοθηκικού ιστού

CASE HISTORY

A 3-year-old female spayed Labrador retriever weighing 29 kg was presented with a 2-month history of persisting sanguineous vaginal discharge following a recent copulation. The dog underwent a complete ovariohysterectomy (OHE) 1.5 years prior presentation. The dog was bright and alert at presentation. Clinical examination revealed a palpable mass in the caudal abdomen and no further abnormalities were noted. Vaginoscopy confirmed the presence of sanguineous secretions and a moderate wrinkling of the vaginal wall; a smear obtained from the mucosa had cytological characteristics suggestive of dioestrus. Routine blood tests results were within normal limits. Serum hormonal analysis showed oestradiol-17 β concentration of 5.00 pg/ml and progesterone concentration of 17.37ng/ml (reference values: basal levels: <0.6 ng/ml, ovulation levels: 4.0-6.0 ng/ml) revealing functional ovarian tissue in dioestrus.

Plain abdominal radiography revealed a well-defined, oval-shaped soft tissue opacity at the caudal aspect of the abdominal cavity (**Figure 1**), compatible with a stump pyometra. Subsequent ultrasonographic assessment showed a mass, isoechoic to adjacent muscles, spotted by some hyperechoic foci, which casted clear shadows (**Figure 2**). No ovaries were identified during ultrasonographic examination. No lymph nodes enlargement was evident. Given the

diagnostic imaging results, the dog was directly prepared for surgery.

Thirty minutes after premedication with acepromazine (Acepromazine, Alfasan) 0.02 mg/kg b.w., intramuscularly, morphine (Morphine 1 mg/ml, EFET-HFA) 0.1 mg/kg b.w., intramuscularly and meloxicam (Loxicom, Norbrook) 0.1 mg/kg b.w., intravenously, anaesthesia was induced with propofol (Propofol MCT/LCT Fresenius 1%, Fresenius Kabi) 3 mg/kg b.w., intravenously and maintained with isoflurane ~ 2% (Isoflo®, Zoetis) in oxygen and constant rate infusion of fentanyl (Fentanyl®, Janssen) 0.05 μ g/kg/min, intravenously. A midline coeliotomy was performed. Findings included the absence of both uterine horns, the presence of a sizeable (2.7 x 2 x 1.8 cm) remnant tissue on the right mesovarium with an active vascular bed, a tiny remnant tissue on the left mesovarium with poor vascular supply and a large, almost ovoid, encapsulated mass (size: 6.3 x 4.5 x 4.3 cm) associated with the uterine stump. Extensive adhesions of the mass with the adjacent organs were present (**Figure 3**). The caudal vagina and the uterine cervix were not affected. The tissues suspected as ovarian remnants and the mass including the uterine body and cervix were excised. Following mass resection, several slide imprints were taken and the mass was submitted for histopathological examination. Cytological examination revealed numerous round cells

with neoplastic characteristics including anisokaryosis, nucleoli presence, euchromatin, and scanty plasma cells and neutrophils with phagocytosed bacteria (**Figure 4**). Histopathological examination confirmed the presence of adenocarcinoma arising from the uterine stump, where a neoplastic population was organized in arbitrary lobules separated by thin bundles of fibrovascular stroma. The mass was moderately cellular, consisted by epithelial cells arranged in branched cords supported by a delicate fibrous net. Neoplastic cells had variable distinct cell borders, small amount of eosinophilic cytoplasm, oval or round nuclei with coarsely clumped chromatin and one variably distinct nucleolus. Anisokaryosis was moderate and 4 mitoses per High Power Field (HPF) were detected. The neoplastic mass was multifocally infiltrated by foamy macrophages, lymphocytes and plasma cells (**Figure 5**). Histopathological examination also showed that the tissue excised from the right mesovarium was an almost anatomically complete ovary with four corpora lutea, a small follicular cyst and at least two developing follicles. The tissue excised from the left mesovarium proved to be granulation tissue with fibroblasts and dense collagen stroma, infiltrated by few lymphocytes and plasma cells. No ovarian structures were found.

The dog recovered uneventfully from anaesthesia and was discharged from the clinic 2 days after surgery. On re-examination 1, 4 and 13 months post-surgery the dog was clinically healthy. The results of radiographic and ultrasonographic re-examination at 13 months post-surgery were unremarkable, since neither recurrence nor metastatic disease was noted.

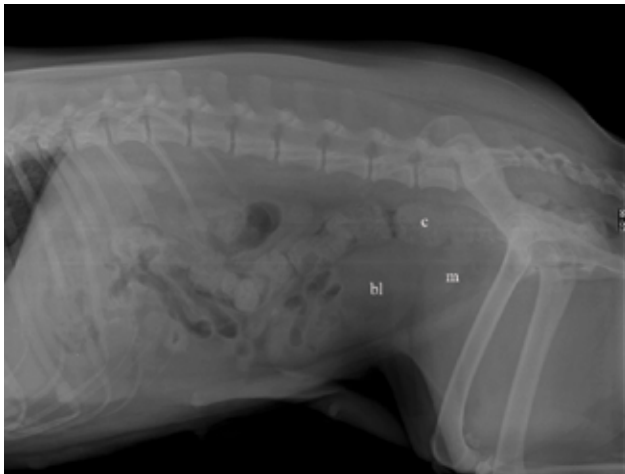

Figure 1. Plain abdominal radiograph of a 3-year-old bitch. Well-defined, oval-shaped soft tissue opacity (m) measured 72x57 mm (LxH) was detected at the caudal aspect of the abdominal cavity, dorsal to the urinary bladder (bl) and ventral to the descending colon (c).

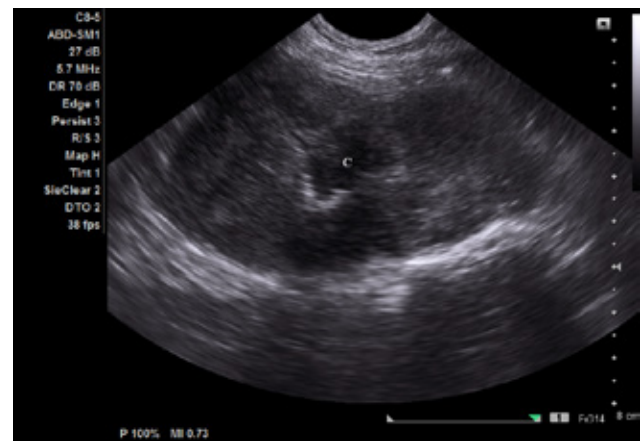


Figure 2. Abdominal ultrasound of the dog of fig 1 shows an isoechoic mass with hypoechoic center (c), compatible with fluid accumulation. Some hyperechoic foci throughout the mass casting a clear shadow were also evident.

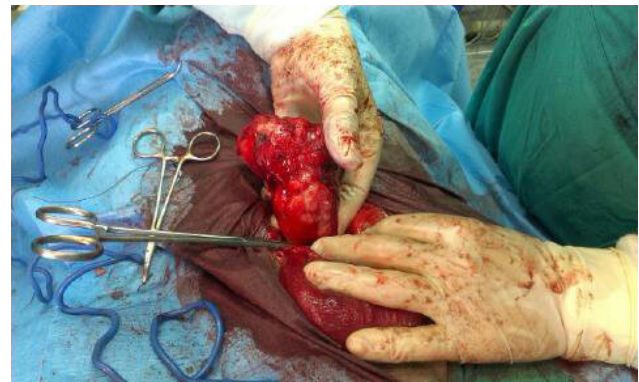

Figure 3. Intraoperative view of the dog of fig 1 following coeliotomy, showing that the mass (s) was associated with the uterine stump. Urinary bladder (bl), cervix (c).

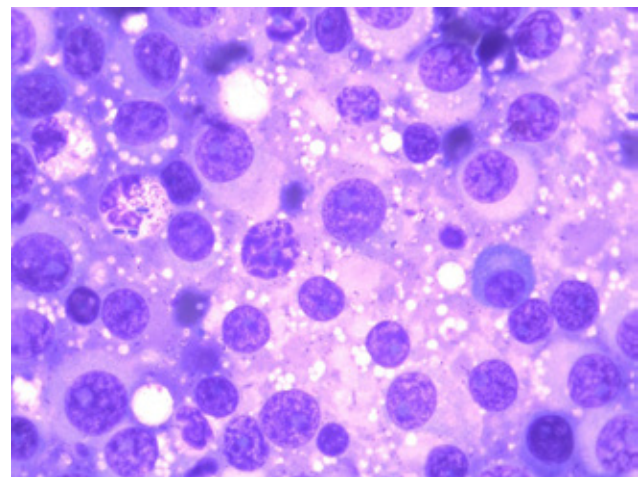


Figure 4. Microphotograph of a stained impression smear from the mass of fig 3 was indicative of a round cell tumour (quick staining technique). Neoplastic cell (nc), plasmacyte (p), neutrophil (n).

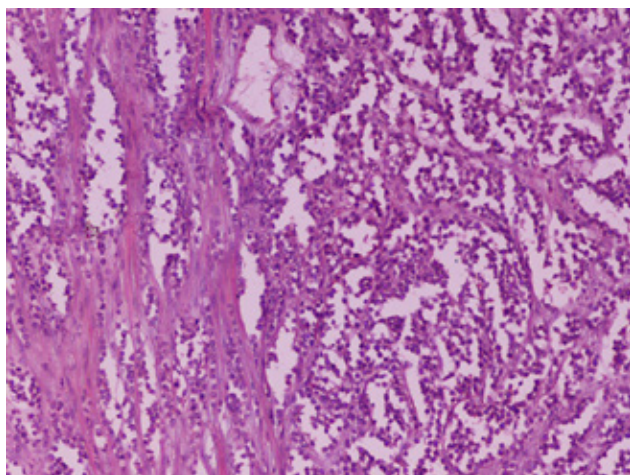


Figure 5. Histopathological section of the mass of fig 3 was compatible with uterine stump adenocarcinoma (magnification x100). Stain H-E.

DISCUSSION

Surgical neutering of companion animals is considered to be the most common, reliable, effective and the least controversial contraception method (Cannan and Meyers-Wallen, 1991). However, complications may occur and affect the reproductive system itself, including ovarian remnant syndrome (ORS) and stump pyometra (Pearson, 1973). The ORS is an iatrogenic long term complication of OHE, occurring when the ovarian cortex is not fully removed. Signs of ORS typically mimic those of proestrus or oestrus and occasionally pseudopregnancy or pyometra (Ball et al., 2010). Ovarian cortex presence can be confirmed by assaying serum hormones concentration (Wallace, 1991), as in our case.

In some studies, the residual ovary or ovarian tissue was more often seen at the right side (Pearson, 1973; Wallace, 1991; Ball et al., 2010), as in our case. The sizable ovarian remnant found in our case, raises some suspicion about a voluntary deposit, which might be considered helpful for the bitch to avoid weight gain and express a normal inter-dog social behaviour, although the unintentional, accidental deposit seems more probable, since some difficulty in fully retracting the right ovary is often encountered, especially when the ovarian ligament is not torn (Ball, 2010).

The interval between previous OHE and the onset of signs of oestrus in bitches has been reported to range from three months to five years (Miller, 1995). In our case, sanguineous vaginal discharge was noticed by the owner 13 months after OHE. However, in a retrospective study of Ball et al. (2010), dogs with

ORS and reproductive system tumours had a significantly longer interval between OHE and diagnosis of ORS (47 to 120 months), compared with the respective interval of animals without neoplasms (1 to 60 months). In contrast, in our case the dog manifested clinical signs earlier, at 13 months after OHE.

Uterine tumours in the bitch occur rarely, representing 0.4% of all canine tumours, reflecting widespread neutering practices in bitches. Of those reported, leiomyoma accounts for 85-90% and the most common malignant neoplasm is leiomyosarcoma (Murphy et al., 1994). Other mesenchymal and epithelial tumours are less frequently seen (Taylor, 2010). Very few reports of canine uterine carcinoma exist in the literature mainly affecting middle-aged or geriatric bitches (Vos 1988; Pena et al., 2006; Patsikas et al., 2014); however, it has been seen in a 2-year-old bitch treated with combined sex hormones, but the cause-and-effect association was not confirmed (Payne-Johnson et al., 1986) and in a 10-month-old entire golden retriever (Cave et al., 2002). Recently, the immunohistochemical characteristics of a canine endometrial adenocarcinoma were studied (Pires et al., 2010). No predilections have been reported for uterine tumours in other dog breeds apart from a hereditary neoplastic syndrome in the German shepherd dog where renal cystadenocarcinomas, nodular dermatofibrosis and multiple leiomyomas are seen (Moe and Lium, 1997); a mutation of the canine Birt-Hogg-Dubé gene has been associated with the condition (Lingaas et al., 2003).

Several cases of ORS have been reported in combination with various neoplasms of the reproductive tract (Ball et al., 2010; Rota et al., 2013; Perez-Marin et al., 2014), but only a haemangiosarcoma has been associated with uterus (Wenzlow et al., 2009). Therefore, our case is the first report of uterine adenocarcinoma in a bitch with ORS. We did not detect any evident carcinogenic factor in the history of our case. Similar to our case, one cat with uterine stump adenocarcinoma and ORS, but with abdominal metastases as well, has been reported in the literature (Anderson and Pratschke, 2011). Additionally, a completely spayed cat with a uterine stump adenocarcinoma has also been reported (Miller et al., 2003).

According to the relevant literature, OHE is the treatment of choice for uterine tumours in dogs (Saba and Lawrence, 2013). The use of adjunctive chemotherapy is sporadically reported, though its efficacy is questioned (Cave et al., 2002; Pires et al., 2010).

In our case surgical excision of the neoplastic mass and ovarian remnant resulted in resolution of clinical signs, since the dog has been clinically healthy 13 months after surgery.

Conclusively, uterine carcinoma is an uncommon canine neoplasm and to the author's knowledge, this is the first case of uterine stump adenocarcinoma in an incompletely ovariectomised bitch, reported

in the literature. Prompt surgical intervention was curative and preventive of any further neoplastic growth and spreading.

CONFLICT OF INTEREST

All the authors declare that there is no conflict of interest for the presented case report.

REFERENCES

- Aderson C, Pratschke K (2011) Uterine adenocarcinoma with abdominal metastases in an ovariohysterectomized cat. *J Fel Med Surg* 13:44-47.
- Ball R, Bichard S, May L, Threlfall W, Young G (2010) Ovarian remnant syndrome in dogs and cats: 21 cases (2000-2007). *J Am Vet Med Assoc* 236:548-553.
- CaveT, Hine R, Howie F, Thompson H, Argyle D (2002) Uterine carcinoma in a 10-month-old golden retriever. *J Small Anim Pract* 43:133-135.
- Concannon P, Meyers-Wallen V (1991) Current and proposed methods for contraception and termination of pregnancy in dogs and cats. *J Am Vet Med Assoc* 198:1214-1225.
- Lingaas F, Comstock KE, Kirkness EF, Sorensen A, Aarskaug T, Hitte C, Nickerson ML, Moe L, Schmidt LS, Thomas R, Breen M, Galibert F, Zbar B, Ostrander EA (2003) A mutation in the canine *BHD* gene is associated with hereditary multifocal renal cystadenocarcinoma and nodular dermatofibrosis in the German shepherd dog. *J Human Mol Gen* 12(23):3043-3053.
- Miller M (1995) Ovarian remnant syndrome in dogs and cats: 46 cases (1988-1992). *J Vet Diagn Invest* 7:572-577.
- Miller MA, Ramos-Vara JA, Dickerson MF, Johnson GC, Pace LW, Kreeger JM, Turnquist SE, Turk JR (2003) Uterine neoplasia in 13 cats. *J Vet Diagn Invest* 15:515-522.
- Moe L, Lium B, (1997) Hereditary multifocal renal cystadenocarcinomas and nodular dermatofibrosis in 51 German shepherd dogs. *J Small Anim Pract* 38:498-505.
- MurphyS, Kruger J, Watson G (1994) Uterine adenocarcinoma in the dog: a case report and review. *J Am Anim Hosp Assoc* 30:440-444.
- Patsikas M, Papazoglou L, Jakovjevic S, Papaioannou N, Papadopoulos P, Soultani CB, Chrysogonidis IA, Kouskouras KA, Tziris NE, Charitanti AA (2014) Radiographic and ultrasonographic findings of uterine neoplasms in nine dogs. *J Am Anim Hosp Assoc* 50:330-337.
- Payne-Johnson C, Kelly D, Davies P (1986) Endometrial carcinoma in a young dog. *J Comp Pathol* 96:463-7.
- Pearson H (1973) The complications of ovariohysterectomy in the bitch. *J Small Anim Pract* 14:257-266.
- Pena F, Gines J, Duque J, Vieitez V, Martinez-Perez R, Madejon L, Nunez Martinez I, Moran JM, Fernandez-Garcia S (2006) Endometrial adenocarcinoma and mucometra in a 6-year-old Alaska Malamute Dog. *Reprod Dom Anim* 41:189-190
- Perez-Marin C, Molina L, Vizuete G, Sanchez J, Zafra R, Bautista M (2014) Uterine and ovarian remnants in an incorrectly spayed bitch. *Veterinari Medicina* 59:102-106.
- Pires M, Seixas F, Palmeira C, Payan-Carreira R (2010) Histopathologic and immunohistochemical exam in one case of canine endometrial adenocarcinoma. *Reprod Dom Anim* 45:545-549.
- Rota A, Tursi M, Zabbarino S, Appino S (2013) Monophasic teratoma of the ovarian remnant in a bitch. *Reprod Dom Anim* 48:26-28.
- Saba CF, Lawrence JA (2013) Tumors of the Female Reproductive Tract. In: Withrow and MacEwen's Small Animal Clinical Oncology. 5th ed, Elsevier, pp 532-537.
- Taylor KH (2010) Tumours of the Abdominal Cavity (Section E: Female Reproductive Tumours). In: Cancer Management in Small Animal Practice. 1st ed, Elsevier, Canada pp 268-274.
- Vos J (1988) Uterine and cervical carcinomas in five dogs. *J Am Vet Med Assoc* 35:385-390.
- Wallace M (1991) The ovarian remnant syndrom in the bitch and queen. *Vet Clin North Am Small Anim Pract* 21:501-507.
- Wenzlow N, Tivers MS, Selmic L, Scurrill E, Baines S, Smith K (2009) Haemangiosarcoma in the uterine remnant of a spayed female dog. *J Small Anim Pract* 50:488-491.