

Journal of the Hellenic Veterinary Medical Society

Vol 70, No 4 (2019)



Immunological and pathological adverse effects of avian influenza virus subtype H9N2 infection in aflatoxicated-broiler chickens

H.F. ELLAKANY, H.S. ABD-ELHAMID, L.A. TANTAWY, H.A. ELSAMADONY, A.R. ELBESTAWY, A.R. GADO, Y.S. EL-SAYED, H.S. ISMAEL

doi: [10.12681/jhvms.22241](https://doi.org/10.12681/jhvms.22241)

Copyright © 2020, H.F. ELLAKANY, H.S. ABD-ELHAMID, L.A. TANTAWY, H.A. ELSAMADONY, A.R. ELBESTAWY, A.R. GADO, Y.S. EL-SAYED, H.S. ISMAEL



This work is licensed under a [Creative Commons Attribution-NonCommercial 4.0](https://creativecommons.org/licenses/by-nc/4.0/).

To cite this article:

ELLAKANY, H., ABD-ELHAMID, H., TANTAWY, L., ELSAMADONY, H., ELBESTAWY, A., GADO, A., EL-SAYED, Y., & ISMAEL, H. (2020). Immunological and pathological adverse effects of avian influenza virus subtype H9N2 infection in aflatoxicated-broiler chickens. *Journal of the Hellenic Veterinary Medical Society*, 70(4), 1889–1900. <https://doi.org/10.12681/jhvms.22241>

Immunological and pathological adverse effects of avian influenza virus subtype H9N2 infection in aflatoxicated-broiler chickens

H.F. Ellakany¹, H.S. Abd-Elhamid¹, L.A. Tantawy², H.A. Elsamadony², A.R. Elbestawy^{1*},
A.R. Gado¹, Y.S. El-Sayed^{3†}, H.S. Ismael²

¹ Department of Poultry and Fish Diseases, Faculty of Veterinary Medicine, Damanshour University, Damanshour 22511, Egypt

² Department of Poultry, Animal Health Research Institute, Dokki, Egypt

³ Department of Forensic Medicine and Toxicology, Faculty of Veterinary Medicine, Damanshour University 22511, Egypt

ABSTRACT. Aflatoxin B1 (AFB1) is a metabolic product of the *Aspergillus* spp. of molds, which grow on several feedstuffs stored in hot moist conditions. It is one of the immunosuppressive agents that might influence the pathogenesis of avian influenza virus (AIV) subtype H9N2 in broilers, which can exacerbate the disease outcomes. The immunological, biochemical and pathological adverse health effects of an interaction between low levels of dietary aflatoxins (AFs) and H9N2 infection in broiler chickens were investigated. One hundred and eighty of unvaccinated 1-day-old COBB chicks were, therefore, raised for 35 days in the following treatment groups: control, AFs, AFs+H9N2, and H9N2. AFs in the basal diet was added at 200 ppb starting from the first day of age, while H9N2 virus was intra-nasally installed at a dose of 100 µl of 10⁶ EID₅₀/bird of allantois fluid at 23rd day. Humoral and cell-mediated immune responses were evaluated. Evidence of H9N2-AIV viral shedding was also detected. It has been observed that concurrent exposure of AFs and H9N2 virus negatively affected chicken performance traits *i.e.* lowered feed intake and body weights with exaggerated respiratory and digestive disturbances, and 20% mortality rate. Ten days' post H9N2 infection, significant ($p \leq 0.05$) increment in serum transaminases (AST and ALT) and falling in cell-mediated immunity *i.e.* total leukocyte count, lymphocyte transformation activity and macrophage phagocytic activity were detected. Additionally, AFs+H9N2 significantly ($p \leq 0.05$) lowered H9N2-HI titers (5.5 Log₂) than H9N2 alone (6.3 Log₂). Pathologically, aflatoxicated chickens showed hydropic degeneration, hepatocytic vacuolation and necrosis of liver tissues with nephrosis and urates deposition in ureters, as well as bursal and thymic lesions, which were potent in H9N2-inoculated chickens. AFs exposure increased the incidence and titer of H9N2 viral shedding. It could be concluded that dietary contamination with AFs even at very low levels has explanatory effect in H9N2-inoculated broilers, and *vice versa*.

Keywords: Aflatoxins, AIV subtype H9N2, Immunological, Pathological, Broilers

Corresponding Authors:

A.R. Elbestawy, Department of Poultry and Fish Diseases, Faculty of Veterinary Medicine, Damanshour University, Damanshour 22511, Egypt.
E-mail address: ahmed.elbestawy@vetmed.dmu.edu.eg

Y.S. El-Sayed, Department of Forensic Medicine and Toxicology, Faculty of Veterinary Medicine, Damanshour University.
E-mail address: elsayed-ys@vetmed.dmu.edu.eg; yasser_tf@yahoo.com

Date of initial submission: 28-05-2019
Date of revised submission: 29-08-2019
Date of acceptance: 31-08-2019

INTRODUCTION

In developing countries, due to a lack of biosecurity, management practice and regulatory systems, free-range chickens are more regularly exposed to the risk of immunosuppressants like aflatoxins (AFs). Aflatoxins, difuranocoumarin compounds, are secondary toxic metabolites produced by toxigenic fungi; mostly *Aspergillus flavus* and *Aspergillus parasiticus* (Diener et al. 1987). Almost any feed, grains or their ingredients for poultry and livestock are able to favor fungal growth and AFs formation, causing health impairment and economic losses (Iheshiulor et al. 2011). Aflatoxin B1 (AFB1) is a potent hepato-toxicant causing acute liver damage; hepatocellular hyperplasia, necrosis, cirrhosis, and biliary hyperplasia in affected chickens. Secondary to the liver disease, the immunosuppressive activity of AFB1 is intimately linked to its toxicity (Yunus et al. 2011). It suppressed the development of bursa of Fabricius and thymus, reduced the weight and function of immune organs (Chen et al. 2014; Ellakany et al. 2011; Peng et al. 2015; Sur and Celik 2003), lowered the splenic T cell subsets percentages (Chen et al. 2014; Peng et al. 2014) and plasma cell counts (Celik et al. 2000), and arrest the B-cell cycle (Hu et al. 2018), immunoglobulin contents (He et al. 2014) as well as cytokines production (Jiang et al. 2015). Moreover, AFB1 induced oxidative stress and lipid peroxidation (Liu et al. 2016; Yuan et al. 2016), and mitochondria damage (Peng et al. 2016; Yuan et al. 2016) in the lymphoid organs. Aflatoxicosis, therefore, impairs humoral and cellular-mediated immune responses, which *in turn* increases the susceptibility of chicken to diseases *i.e.* avian influenza (AI) and infectious bursal disease (IBD), and causes vaccination failure (Bakshi et al. 2000; Gabal and Azzam 1998).

Avian influenza virus H9N2 is a low pathogenic panzootic pathogen that in spite of causing mild to moderate enteric and respiratory signs, it has been recently associated with high morbidity and considerable mortality with potential to infect human population (Ahad et al. 2013; Alexander 2003). H9N2 infection could decrease growth rate and feed conversion rate (FCR) in broilers due to co-infection with other pathogens as IBV, *Staphylococcus* exacerbates H9N2 influenza A virus infection in chickens (Kishida et al. 2004). Host cell-mediated immune response is important in the pathogenesis of avian influenza viruses and plays an important role in recovery from viral infection (Wells et al. 1981). As one of the immunosuppressive agents that influences the patho-

genesis of H9N2 virus in broilers, aflatoxins, even in very low levels, can disturb the immune system of birds and thus can exacerbate the disease outcomes of H9N2-AIV (El Miniawy et al. 2014). In turkeys, aflatoxin delayed influenza virus clearance and lead to decreased IFN- γ mRNA expression and increased pathogenicity of H9N2 LPAI viruses under field conditions (Umar et al. 2015). Consequently, this work aimed to study the effect of H9N2-AIV virus co-infection with simultaneous aflatoxins addition in the feed of commercial broilers chickens.

MATERIALS AND METHODS

Aspergillus flavus strain and aflatoxin production

Standard aflatoxigenic *Aspergillus flavus* strain was obtained from the Department of Mycology, Animal Health Research Institute, Agriculture Research Center, Ministry of Agriculture, Egypt. Aflatoxins were produced by growing standard aflatoxigenic strains on sterile polished rice (West et al. 1973). Aflatoxins were detected quantitatively in rations by using affinity column chromatography (Aflatest 10, Narencoco, Springfield, IL, USA) and fluorometry (Sequicia Tuner Model 450 with a 360 nm excitation filter and a 450 nm emission filter) (Nabney and Nesbitt 1965). All reagents were of the highest analytical grade.

Challenge virus

Avian influenza A H9N2 virus strain (A/Chicken/Egypt/93/2015 with Genbank accession No: KY872759). This challenge strain was isolated from a broiler chicken flock and identified in the Department of Poultry and Fish Diseases, Faculty of Veterinary Medicine, Damanhour University, Egypt (Abd El-Hamid et al. 2018).

Animals experimentation and procedures

One hundred and eighty unvaccinated one-day-old healthy Cobb 500 broilers obtained from a commercial local hatchery and grown over a 35-d experimental period. The broiler chicks were floor-reared, weighed and randomly allocated with equalized initial body weights into four groups of three replicates (15 chick/replicate). (I) Control group; chicks received the AFs-free ration and served as a negative control. (II) AFs group; chicks received the AFs-containing basal diet. (III) AFs+H9N2 group; chicks received the AFs-containing diet and were inoculated with H9N2-AIV. (IV) H9N2 group; chicks received the control basal diet with no AFs but were inoculated with H9N2-AIV. The AFs-containing ration (200

ppb) was fed to chicks starting from the first day of age to the end of the experiment at 35 days. On the 23rd day of age, AIV-H9N2 inoculated groups were directly inoculated with 100 μ l of 10^6 EID₅₀ per bird of allantois fluid via intranasal route. Weekly, all birds were individually weighed starting from the 1st week until the end of the experiment. Performance traits including body weight as well as mortality, postmortem lesions, hematological and biochemical parameters, and pathological examinations were assessed.

The use of broilers and all mandatory laboratory health and safety experimental procedures involving animals had been complied by the Damanhour University Animal Care and Use Committee, Egypt. Nutritional requirements were adequate according to the National Research Council. All killed birds were euthanized by chloroform at a high dose to induce respiratory failure.

Estimation of liver function indices

At 10-day post-inoculation (dpi), twenty blood samples were collected from wing vein of chickens using appropriate sterile needles, syringes, and falcon tubes without anticoagulants. The samples were centrifuged at 1000 \times g for 10 min, and the sera were separated and then stored at -20°C until the assessment of liver function enzymes; aspartate aminotransferase (AST) and alanine aminotransferase (ALT) using supplied detection kits (BioMérieux, Lyon, France).

Estimation of cell-mediated immune response

Another heparinized blood samples were collected at 14, 27 (4 dpi) and 33 (10 dpi) days of age to evaluate the total and differential leukocyte counts (Jain 2000), lymphocyte transformation activity (Kumar and Das 1996) and macrophages phagocytic activity (Salaberria et al. 2013).

Estimation of humoral-mediated immune response

Hemagglutination inhibition (HI) test was done at day one of age according to the standard protocols of the World Health Organization (WHO 2002) for detection of maternal antibodies against H9N2-AIV, and then at 10 dpi for detection of H9N2 infection immune response. The HI titer (\log_2) was evaluated using 96-well microtiter plates, doubling dilution in phosphate buffer, 0.5% RBCs (v/v), and 4 hemagglutinating units (HAU) of AIV-H9N2 antigen. Positive groups had at least one serum sample with titer >4 .

Histopathological examination

Immediately following euthanasia at 35 days old, chicken trachea, lungs, liver, kidney, bursa and thymus specimens were fixed in 10% neutral buffered formalin, dehydrated in ascending grades of ethyl alcohol, cleared in xylene, blocked in paraffin and cut into 5- μ m-thick sections using a rotary microtome (Bancroft and Gamble 2002). The obtained tissue sections were stained with hematoxylin and eosin (H&E) for light microscopy examination.

Detection of viral shedding

Viral shedding was detected using 10 tracheal swabs collected at 3 and 5 dpi and inoculated in SPF chicken eggs (9 days old) via allantoic sac route (Reed and Muench 1938). Slide hemagglutination (HA) test was used to confirm the positivity of the allantois fluid and the mean viral titer of pooled allantoic fluid was calculated.

Statistical analyses

Statistical analysis of raw data was performed using SAS[®] software by one-way analysis of variance (ANOVA) followed by Duncan's multiple range test (DMRT) to detect differences between the groups. The experimental data are expressed as the mean \pm SEM, and significant differences among the groups were set at a value of $p \leq 0.05$.

RESULTS

Clinical observations, mortalities and body weight

Clinically, H9N2-inoculated chickens (Group IV) showed clinical signs of depression, anorexia, respiratory manifestation as facial edema (sinusitis), sneezing and mild conjunctivitis. In addition, tracheal exudates and air sacculitis were more pronounced. Compared with control, AFs-intoxicated chickens displayed a marked decrease in feed consumption with stunted growth. Internally, AFs-intoxicated broilers showed marked enlargement of the liver with abnormal discoloration and ureters distended with uric acid. There were no mortalities in the control and H9N2-inoculated chicks, although there were 11% in AFs-treated chickens (Group II) and 20% in AFs-treated H9N2-inoculated chickens (Group III). The average body weight of broiler chicks was recorded on a weekly basis until the end of the experiment. Initially, there were no significant differences in the body weight among different groups at day 1 of the experiment. However, from day 7, aflatoxicated broilers challenged with H9N2 virus (Group III),

then AFs-treated chicks (Group II) and from day 28, H9N2-inoculated birds (Group IV) exhibited a significant ($p \leq 0.05$) reduction in body weight compared with controls.

Hepatic enzymes and cell-mediated immunity

Liver function: Compared with the controls, the activities of serum AST and ALT enzymes were significantly ($p \leq 0.05$) enhanced in aflatoxicated broilers (Groups II, III) (Table 1).

Total leukocyte count (TLC): At 27 days (4 dpi), TLC was significantly lowered ($p \leq 0.05$) in AFs-intoxicated H9N2-challenged ($687.2 \times 10^3/\mu\text{l}$), and AFs-treated broilers ($708.8 \times 10^3/\mu\text{l}$) compared with control values ($1005.3 \times 10^3/\mu\text{l}$). At 33 days (10 dpi), it was still significantly ($p \leq 0.05$) lowered in AFs-intoxicated ($949.2 \times 10^3/\mu\text{l}$), and AFs-intoxicated H9N2-challenged broilers ($1407.7 \times 10^3/\mu\text{l}$) compared with control values ($1717.9 \times 10^3/\mu\text{l}$). However, it was significantly ($p \leq 0.05$) increased in H9N2-challenged chickens ($1270.8 \times 10^3/\mu\text{l}$) compared to control birds and AFs-intoxicated birds at 4 dpi, which was returned to control at 10 dpi (Table 2).

Differential leukocyte count (DLC): Leukocytic cells were differentiated into lymphocytes, heterophils, monocytes and eosinophils as percentages of TLC. Table 2 shown that DLC reflected significant ($p \leq 0.05$) increase in the percentage of lymphocyte and heterophile (lymphocytosis and heterophilia) in experimental AFs and/or H9N2-exposed chickens (Groups II-IV) at 4 dpi compared with control. H9N2-challenged chickens (Groups III, IV) showed significant ($p \leq 0.05$) increment in eosinophilic % (eosinophilia). As well, monocytes % were significantly ($p \leq 0.05$) increased in AFs-intoxicated H9N2-challenged chickens only as compared with other experimental groups. At 33 days (10 dpi), lymphocyte was significantly lowered ($p \leq 0.05$) by 69.6% in AFs-intoxicated chicks (Group II), while there was a significant ($p \leq 0.05$) increment in heterophile by 27.2% compared with other experimental groups. H9N2-challenged chickens (Group IV) showed significantly higher ($p \leq 0.05$) eosinophil (1.8%) compared with other groups. There were no significant changes observed in monocytes.

Lymphocytes transformation activity: Compared to control, lymphocytes transformation activity was significantly ($p \leq 0.05$) lowered in AFs-treated chickens (Groups II, III) throughout the experiment, with no significant change in H9N2-inoculated chickens

at 14 and 27 days (4 dpi) old. Although, it had been significantly increased ($p \leq 0.05$) in all chicken groups at 33 days old (10 dpi), particularly in H9N2-challenged chickens (Group IV) (Table 3).

Macrophages phagocytic activity: At 14 days old, aflatoxicated chickens (Groups II, III) expressed significantly ($p \leq 0.05$) higher macrophage phagocytic activity compared to control and H9N2-challenged chickens. However, at 27 and 33 days old (4 and 10 dpi, respectively), they had significantly lower ($p \leq 0.05$) macrophage phagocytic activity, with the lowest activity in AFs+H9N2-challenged chickens at 4 dpi, and AFs-intoxicated chickens at 10 dpi compared with the control. Generally, there is no significant changes had been observed in macrophage phagocytic activity between H9N2-challenged chickens and control (Table 3).

Humoral-mediated immunity (HI)

At day 1, there was no significant difference in maternal antibodies titer among all chicken groups. At 33 days (10 dpi), it was noticed that chickens non-inoculated with H9N2 virus (Control and AFs-intoxicated chickens) had no HI antibodies. Meanwhile, H9N2-challenged chickens expressed HI antibody titer, that was significantly lower ($p \leq 0.05$) in AFs+H9N2 than H9N2-challenged chickens (5.5 and 6.3 Log₂, respectively) (Table 3).

Histopathologic assessment (Table 4)

Liver: The severity of hepatic lesion varied between treated chicken groups that were apparently normal livers in the control group (Fig. 1Aa), mild-est in H9N2-inoculated chickens (Group IV). More severe lesions appeared in AFs-intoxicated chickens (Group II), where severe granulocytes infiltration within atrophied hepatocytes were seen (Fig. 1Ab). However, the most severe hepatic lesions; severe granulocytes infiltration with destructed hepatocytes, severe ballooning degeneration of hepatocytes with fatty changes and hyperplasia of stellate cells were seen in AFs+H9N2 group (Fig. 1Ac, d).

Kidneys: Kidneys of control birds revealed normal histological appearance (Fig. 1Ba). However, both AFs (Group II, Fig. 1Bb) and H9N2 (Group IV, Fig. 1Bc) exerted a harmful effect on kidneys; tubular cast, pronounced intertubular congested blood vessels with degenerated tubular epithelium. This effect was exaggerated by their combination, which exhibits focal intertubular-histocyte aggregations (Fig. 1Bd).

Table 1. Effect of aflatoxins (200 ppb) and/or infection with AIV-H9N2 (10^6 EID₅₀/ml) on the mortality incidence, weekly average body weight (g) and serum liver function biomarkers of broiler chickens

Groups	Mortality (%) ^a (n= 45)	Average body weight (g) (n= 45)						Liver enzymes (n= 20)	
		0 day	7 days	14 days	21 days	28 days	35 days	AST (IU/ml)	ALT (IU/ml)
CTR	0	39.2±0.58 ^a	164.0±1.18 ^a	290±7.41 ^a	876.4±22.40 ^a	1532±20.83 ^a	1850±35.35 ^a	35.0±1.14 ^b	25.2±1.15 ^b
AFs	11 (5/45)	40.0±0.70 ^a	120.4±2.13 ^b	148±24.72 ^b	324.0±72.42 ^b	482±34.26 ^c	560±36.74 ^c	41.4±1.88 ^a	29.2±1.50 ^a
AFs+H9N2	20 (9/45)	40.8±0.58 ^a	123.0±1.41 ^b	158±18.54 ^b	302.0±52.66 ^b	500±41.83 ^c	530±25.49 ^c	41.0±2.30 ^a	29.8±1.20 ^a
H9N2	0	40.2±0.86 ^a	162.2±0.81 ^a	298±6.63 ^a	879.0±21.93 ^a	1020±25.49 ^b	1240±43.01 ^b	35.4±1.12 ^b	24.8±1.43 ^b

Values have different superscripts within the same columns are significantly different at $p \leq 0.05$.

^a At the end of the experimental period.

Table 2. Effect of aflatoxins (200 ppb) and/or infection with AIV-H9N2 (10^6 EID₅₀/ml) on the total and differential leucocytes of broiler chickens

Groups	Total leucocytes count ($10^3/\mu\text{l}$)	Differential leucocytes percent			
		Lymphocytes (%)	Heterophils (%)	Monocytes (%)	Eosinophils (%)
4 dpi					
CTR	1005.3±31.8 ^b	62.2±2.75 ^a	36.2±2.85 ^a	1.6±0.24 ^b	0.0±0.00 ^c
AFs	708.8±27.1 ^c	75.8±0.58 ^b	22.6±0.60 ^b	1.6±0.24 ^b	0.0±0.00 ^c
AFs+H9N2	687.2±7.8 ^c	77.5±1.04 ^b	19.3±1.25 ^b	2.3±0.25 ^a	1.0±0.00 ^b
H9N2	1270.8±81.0 ^a	74.6±0.67 ^b	22.4±0.81 ^b	1.4±0.24 ^b	1.8±0.37 ^a
10 dpi					
CTR	1717.9±61.9 ^a	72.4±1.65 ^b	24.8±0.20 ^b	1.8±0.21 ^a	1.0±0.00 ^a
AFs	949.2±29.17 ^c	69.6±1.56 ^a	27.2±1.39 ^a	2.0±0.00 ^a	1.2±0.22 ^a
AFs+H9N2	1407.7±66.78 ^b	73.2±0.37 ^b	23.0±0.31 ^b	2.0±0.01 ^a	1.8±0.21 ^b
H9N2	1560.5±62.4 ^{ab}	73.5±0.64 ^b	23.0±0.40 ^b	2.0±0.03 ^a	1.5±0.20 ^a

Values have different superscripts within the same column are significantly different at $p \leq 0.05$ ($n = 20$).

Table 3. Effect of aflatoxins (200 ppb) and/or infection with AIV-H9N2 (10^6 EID₅₀/ml) on the lymphocytes transformation and macrophages phagocytic activities, and HI antibody titer (Log₂) of broiler chickens

Groups	Lymphocytes transformation activity (optical density)			Macrophages phagocytic activity ($\mu\text{M}/\text{ml}$)			Log ₂ HI GMT titers	
	14 days	27 days (4 dpi)	33 days (10 dpi)	14 days	27 days (4 dpi)	33 days (10 dpi)	Maternally-derived antibodies	33 days (10 dpi)
CTR	2.35±0.06 ^a	1.42±0.03 ^a	1.86±0.06 ^a	12.6±0.80 ^a	12.42±0.40 ^a	12.10±0.22 ^a	5 ^a	0 ^a
AFs	1.59±0.08 ^b	1.11±0.05 ^b	1.39±0.05 ^b	29.1±0.49 ^b	9.90±0.27 ^b	6.05±0.13 ^b	5 ^a	0 ^a
AFs+H9N2	1.53±0.05 ^b	0.97±0.03 ^b	3.32±0.01 ^d	29.1±0.46 ^b	6.12±0.20 ^c	8.77±0.12 ^c	5 ^a	5.5±0.34 ^b
H9N2	2.34±0.05 ^a	1.41±0.06 ^a	4.33±0.08 ^c	12.5±0.84 ^a	10.33±0.22 ^a	12.99±0.29 ^a	5 ^a	6.3±0.26 ^c

Mean values have different superscript letter within the same column are significantly different between experimental groups at $p \leq 0.05$ ($n = 20$).

Table 4. The severity of histopathological lesions in experimental chickens

Groups	Liver	Kidneys	Lungs	Trachea	Bursa of Fabricius	Thymus
CTR	0	0	0	0	0	0
AFs	3	3	3	0	2	1
AFs+H9N2	4	3	4	1	3	2
H9N2	2	2	2	1	2	1

(0) no lesions; (1) mild lesions; (2) moderate lesions; (3) severe lesions and (4) very severe lesions

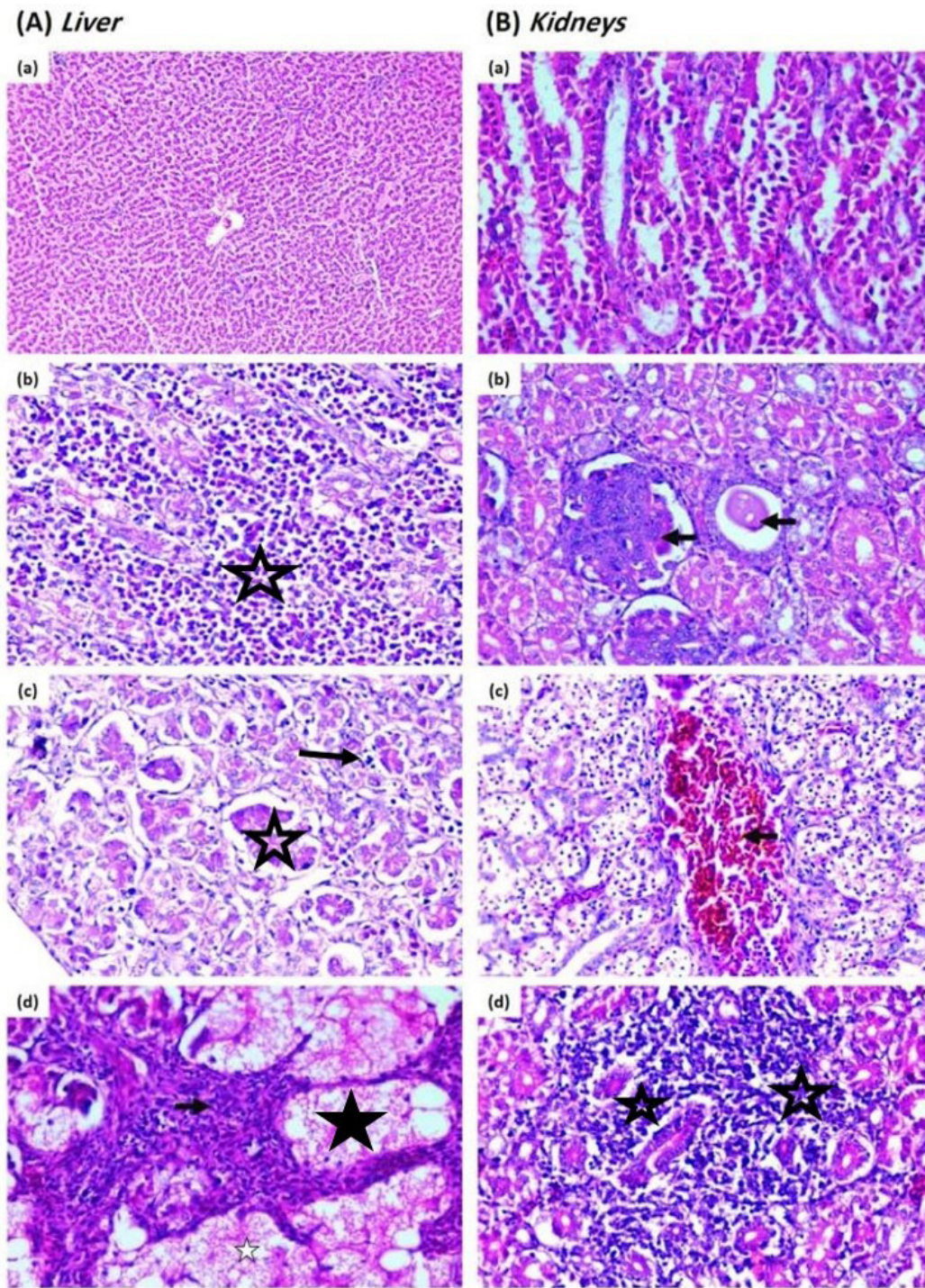


Figure 1: Representative photomicrographs of H&E-stained liver and kidneys tissues following aflatoxins and/or H9N2-AIV challenge.

Light microscopy of hepatic tissues from control (a) shows the normal histologic structure of liver tissues. AFs (200 mg/kg ration)-treated broiler chicks (b) exhibited granulocytes infiltration within atrophied hepatocytes ($\times 400$). AFs (200 mg/kg ration) + H9N2 (100 μ l of 10^6 EID₅₀/bird)-challenged broiler chicks showed granulocytes infiltration with destructed hepatocytes, ballooning (c) and degeneration of hepatocytes with fatty changes (arrow) and hyperplasia of stellate cells (stars) (d, H&E $\times 400$).

Light microscopy of renal tissues from control (a) shows the normal histologic structure of renal tissues ($\times 100$). AFs (200 mg/kg ration)-treated broiler chicks (b) exhibited showed tubular cast (arrows, $\times 400$). AFs (200 mg/kg ration) + H9N2 (100 μ l of 10^6 EID₅₀/bird)-challenged broiler chicks (c) showed pronounced intertubular congested blood vessels with degenerated tubular epithelium (arrow, $\times 400$). H9N2 (100 μ l of 10^6 EID₅₀/bird)-challenged broiler chicks (d) showed focal intertubular histocytes aggregations ($\times 400$).

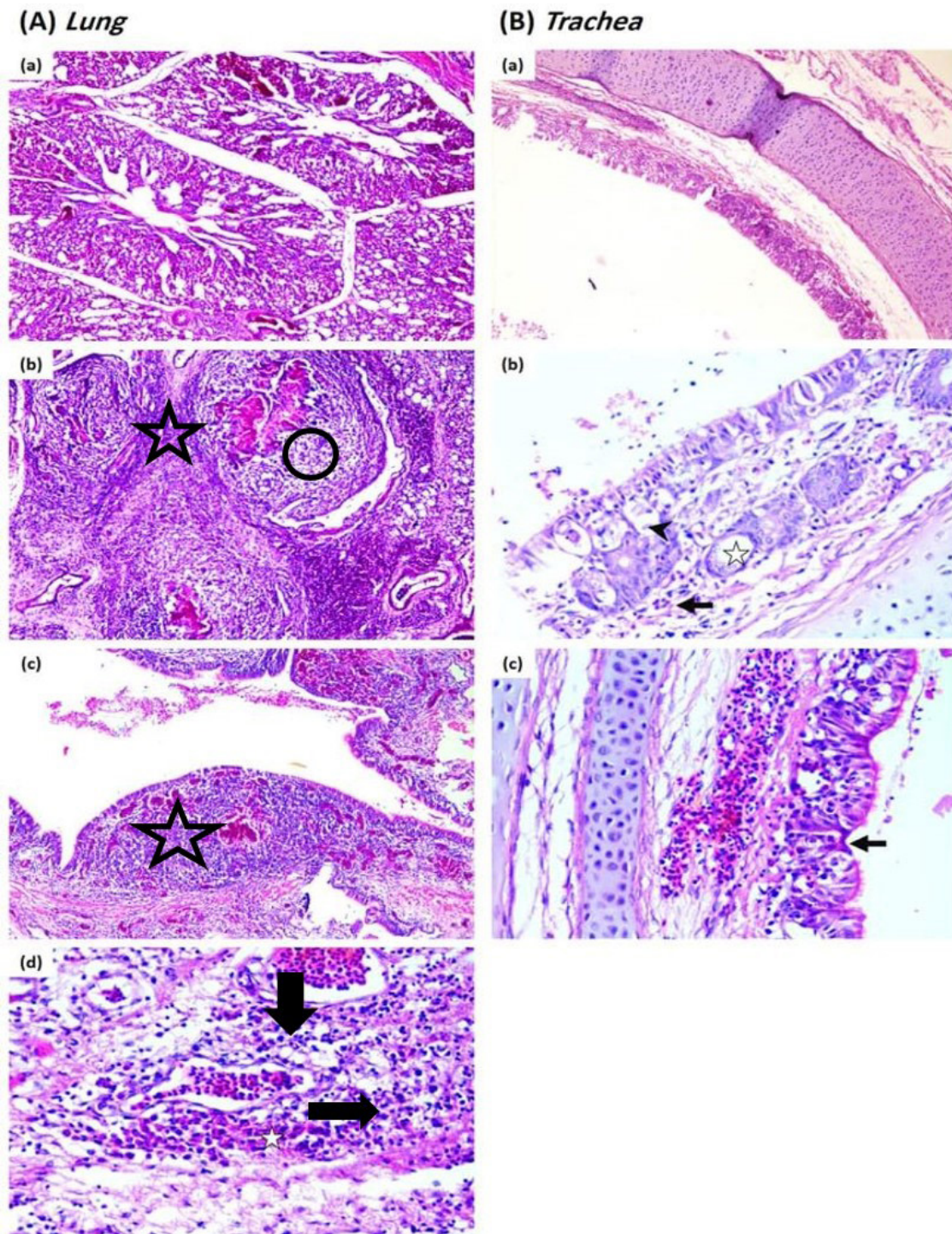


Figure 2: Representative photomicrographs of H&E-stained lung and tracheal tissues following aflatoxins and/or H9N2-AIV challenge.

Light microscopy of pulmonary tissues from control (a) shows apparently normal histologic structure ($\times 100$). AFs (200 mg/kg ration)–treated broiler chicks (b) showed bronchioles surrounded by heterophils, macrophages, epithelioid cells (star) and multinucleated giant cells and connective tissue (arrow) ($\times 400$). AFs (200 mg/kg ration) + H9N2 (100 μ l of 10^6 EID₅₀/bird)–challenged broiler chicks (c) showed thickening of bronchial lining due to mononuclear cells infiltration (star), congestion and hemorrhage ($\times 100$). H9N2 (100 μ l of 10^6 EID₅₀/bird)–challenged broiler chicks (d) showed interstitial granulocytes and mononuclear cells infiltration (star) ($\times 400$).

Light microscopy of tracheal tissues from control (a) and AFs (200 mg/kg ration)–treated broiler chicks show apparently normal histologic structure ($\times 100$). AFs (200 mg/kg ration) + H9N2 (100 μ l of 10^6 EID₅₀/bird)–challenged broiler chicks (b) showed vacuolation of lining epithelium (star), increased mucous glands (arrowhead) with inflammatory cell infiltration (arrow) ($\times 400$). H9N2 (100 μ l of 10^6 EID₅₀/bird)–challenged broiler chicks (c) showed focal deciliation with submucosal hemorrhage (arrow) ($\times 400$).

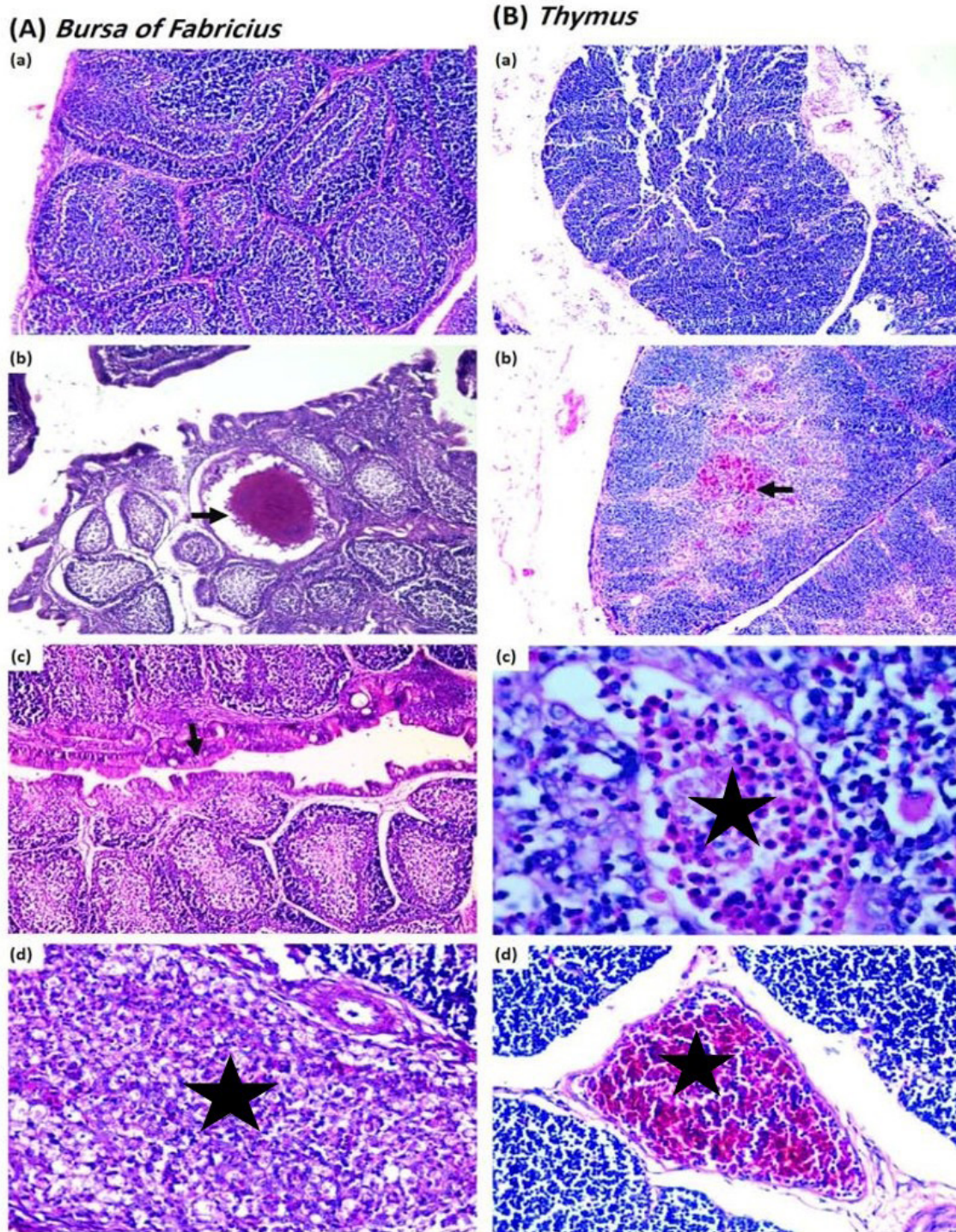


Figure 3: Representative photomicrographs of H&E-stained bursa of Fabricius and thymus tissues following aflatoxins and/or H9N2-AIV challenge.

Light microscopy of bursa of Fabricius tissues from control (a) shows apparently normal histologic structure ($\times 100$). AFs (200 mg/kg ration)-treated broiler chicks (b) showed granuloma (arrow) within bursal follicle cyst ($\times 100$). AFs (200 mg/kg ration) + H9N2 (100 μ l of 10^6 EID₅₀/bird)-challenged broiler chicks (c) showed hyperplasia of lining epithelium with depletion of lymphocytes (arrow) ($\times 100$). H9N2 (100 μ l of 10^6 EID₅₀/bird)-challenged broiler chicks (d) showed interstitial granulocytes and mononuclear cells infiltration (star) ($\times 400$).

Light microscopy of thymus tissues from control (a) shows apparently normal histologic structure ($\times 100$). AFs (200 mg/kg ration)-treated broiler chicks (b) showed focal hemorrhage in the medulla (arrow) ($\times 100$). AFs (200 mg/kg ration) + H9N2 (100 μ l of 10^6 EID₅₀/bird)-challenged broiler chicks (c) showed widening of Hussal's corpuscles forming cysts containing necrotic debris and granulocytes (star) ($\times 400$). H9N2 (100 μ l of 10^6 EID₅₀/bird)-challenged broiler chicks (d) showed congested blood vessels (star) ($\times 100$).

Lungs: Pulmonary tissues from control show apparently normal histologic structure (Fig. 2Aa), while AFs-treated broiler chicks showed bronchioles surrounded by heterophils, macrophages, epithelioid cells and multinucleated giant cells and connective tissue (Fig. 2Ab). Severe thickening of bronchial lining appeared due to mononuclear cells infiltration, congestion and hemorrhage were seen in AFs+H9N2-exposed chickens (Fig. 2Ac), while H9N2-inoculated chickens showed a moderate degree of pneumonia exhibited as thickening of bronchial lining due to mononuclear cells infiltration (Fig. 2Ad).

Trachea: The tracheal tissues from control (Fig. 2Ba) and AFs-treated broiler chicks show apparently normal histologic structure. They also were mild in other groups; vacuolation of lining epithelium and increased mucous gland with inflammatory cell infiltration in chickens of AFs+H9N2-inoculated chickens (Group III) (Fig. 2Bb) and focal deciliation in H9N2-challenged chickens (Group IV) (Fig. 2Bc).

Bursa of Fabricius: The control chickens (Group I) showed apparently normal bursa (Fig. 3Aa). The severity of lesions in bursa was moderate in chickens in AFs-intoxicated chickens (Group II) – granuloma within bursal follicle cyst (Fig. 3Ab), followed by H9N2-inoculated chickens (Group IV), which appeared as hyperplasia of lining epithelium with depletion of lymphocytes (Fig. 3Ac). There was severe necrosis of plical lymphocytes in AFs+H9N2 group (Fig. 3Ad).

Thymus: Thymus of control chickens showed normal architecture (Fig. 3Ba). The severity of lesions in the thymus was mild – focal hemorrhage in the medulla in AFs (Fig. 3Bb) and H9N2 (Fig. 3Bd). They are exaggerated to moderate thymic lesions in AFs+H9N2 group (Fig. 3Bc).

H9N2-avian influenza viral shedding

As shown in Table 5, all examined tracheal swabs from H9N2-inoculated chickens (Groups III, IV) at 3 dpi, were positive for virus isolation in ECE, which confirmed by HA and HI test using H9N2 antiserum. The H9N2-AIV virus was isolated from 5 of 10 tracheal swabs with a mean viral titer of pooled allantois fluid of $10^{5.6}$ EID₅₀/ml at 5 dpi, from H9N2-inoculated chickens (Group IV), meanwhile in AFs+H9N2 group, the virus was isolated from 7 of 10 tracheal swabs with a mean viral titer of $10^{7.8}$ EID₅₀/ml.

Table 5. H9N2 avian influenza virus shedding in tracheal swabs in experimental chickens at 3 and 5 days post-infection (dpi)

Groups	3 dpi	5 dpi	Mean viral Titer
			at 5 dpi (EID ₅₀ /ml)
CTR	0/20	0/20	-
AFs	0/20	0/20	-
AFs+H9N2	20/20	10/20	$10^{7.8a}$
H9N2	20/20	14/20	$10^{5.6b}$

Values have different scripts at the same row are significantly different at $p \leq 0.05$ ($n = 20$)

DISCUSSION

The productivity of poultry farms was scarcely affected by feed contaminated with AFs and their subsequent impacts on broiler performance. Aflatoxicosis and AIV are not only lead to huge economic losses in the poultry industry but also cause serious public health threats worldwide. In broiler, AFs in the diet can act as a stress factor to increase the susceptibility to, or severity of, AIV subtype H9N2 (El Miniawy et al. 2011; Umar et al. 2015). Increased susceptibility of AFs-intoxicated broilers to various bacteria and viruses indicates an impaired immune response and a failure of vaccinal immunity (Subler et al. 2006; Umar et al. 2015). In the pathogenesis of AIV subtype H9N2 in broilers intoxicated with AFs, there was a detrimental clinical picture of respiratory distress involving impairment of chicken performance in addition to hemato-biochemical, histopathological and immunological changes.

The current data indicated that AFs and/or AIV subtype H9N2 caused a reduction in body weight (Afzal and Zahid 2004; Gharaibeh 2008; Hablolvarid et al. 2004; Marchioro et al. 2013; Raju and Devegowda 2000; Yunus et al. 2011), thereby leading to losses in performance and productivity. These effects in broilers may be due to the greater effect of AFs in the initial growth phase, particularly during the first 21 days of age, when the negative impact on weight gain is irreversible due to inhibition of protein synthesis, reduced absorption of nutrients and lower rate of pancreatic enzymes release (Azizpour and Moghadam 2015; Oguz et al. 2000; Safamehr 2008). In additions, AFs provoked a nutritional deficiency and hence, inhibition of weight gain, hepatomegaly and increased weights of visceral organs (Kubena et al. 1990). The suppressed appetite in aflatoxicated groups is due to the impaired liver and kidneys metabolic activity subsequently to the impaired hepato-renal structure (Or-

tatatli et al. 2005; Verma et al. 2010), which appeared clearly in the histopathological deterioration and the elevation of liver enzymes (AST and ALT), however, both enzymes didn't show much high significant increase as the low dose of AFs (200 ppb) induced toxicity to the cell-mediated immunity more than liver (Giambrone et al. 1985). The nephrotoxic effect of AFs may be due to interference with transport function in collecting tubule cells together with diffused impairment of the function of the proximal tubule (Ortatatli et al. 2005). Herein, the mortality began after 14 days of age, which could be attributed to the cumulative effect of AFs.

Infection with LPAI subtype H9N2 is usually mild and localized to the respiratory and intestinal tracts due to the restriction of trypsin-like proteases. However, one of the indicators of pathogenicity after H9N2 experimental infection is the daily observed clinical signs with special attention to feed consumption, body weight and FCR (Gharaibeh 2008). Also, H9N2 infection is associated with edema in the head and neck, conjunctivitis as well as tubulointerstitial nephritis, turbidity of the thoracic and abdominal air sacs, mild congestion of the trachea and lung, mild accumulation of fibrinous exudate on the tracheal mucosa and all these lesions should have a direct negative effect on feed consumption and FCR (Hadipour et al. 2011). Also, decrease in feed consumption, depression and diarrhea, hemorrhage in small intestine and pancreas as well as swollen kidneys with no mortalities were reported (Hs et al. 2016; Somayeh Asadzadeh 2011). Moreover, it appeared that the H9N2 was more pathogenic in aflatoxicated-chicken, which caused more severe clinical signs and pathologic changes in the liver, kidneys, lungs and trachea compared with AFs-treated chickens (Hadipour et al. 2011), leading to potent decrease in feed intake as well as body weight. Also, the mortality rate in AFs+H9N2 exposed chickens (Group III) increased by about 50% than AFs-intoxicated chickens (Group II) (>11%), however, this was not highly significant to be reflected on the estimated liver enzymes (AST and ALT), which may be attributed to the delayed H9N2 infection at 23rd day of age in the AFs-intoxicated birds (from first day of age) that might affect the mortality rate more than the liver enzymes at 27 and 33 days of age (only 4 and 10 dpi) as the respiratory tract is the main target tissue during the pathogenesis or acute infection of H9N2. Previous studies found that H9N2 AIV infections could decrease growth rate and FCR in broilers due to co-infection with other pathogens as IBV, *Staphylo-*

coccus aureus, *Avibacterium paragallinarum* and *E. coli* or immune suppression, which exacerbates H9N2 infection in chickens (Kishida et al. 2004).

It is well known that the suppression of immune function has led to an increase in the susceptibility to a variety of bacterial or viral diseases in chickens (Subler et al. 2006). Previously available data on the pathogenesis of LPAI viruses in chickens suggested that the H9N2 LPAI viruses in poultry flocks resulted in diverse clinical syndromes of varying severity depending on the viral strain, as well as the co-infection with immunosuppressive diseases (Bano et al. 2003; Kishida et al. 2004). It was indicated that aflatoxicosis has an immunosuppressive effect in broiler chickens reflected by lower activity of lymphocyte transformation in all stages of the experiment. Hatori et al. (1991) found that the immune responses mediated by T cells appeared to be sensitive to AFs. Even the very low levels of AFs can disturb the immune system of birds, and thus in association with other pathogens (Ellakany et al. 2011) it can exacerbate disease outcomes. Many studies conducted in poultry showed that exposure to AFs-contaminated feed resulted in suppression of the cell-mediated immune responses, thymic aplasia, reduction of the function and number of T-lymphocyte, suppressed phagocytic activity and reduced complement activity. Impairment of cellular function by AFs seems to be due to its effects on the production of lymphokines and antigen processing by macrophages, as well as a decrease in or lack of the heat-stable serum factors involved in phagocytosis (Cusumano et al. 1996; El Miniawy et al. 2014; Raisuddin et al. 1990; Theumer et al. 2010). The immunosuppressive effect of AFs was further clearly noticed by the lower macrophage phagocytic activity and TLC (Abdel-Wahhab et al. 2002; Basmacioglu et al. 2005; Celik et al. 2000; Oguz et al. 2000), particularly after challenge with H9N2. Lymphocytes and WBC were decreased and heterophils were increased without any noticeable influence on monocyte and eosinophil in male broiler chickens exposed to mycotoxins naturally contaminated diets (Mohaghegh et al. 2016). The possibility of phagocytic depression during mycotoxicosis may be due to inhibition of DNA, RNA and protein synthesis in macrophages after mycotoxins exposure; or due to alterations in metabolic processes, principally glycolysis essential for phagocytosis (Qureshi and Hagler 1992). Moreover, it may be attributed to an alteration in the macrophage membrane. These functional alterations may affect RNA function on actin and myosin formation that

are essential for chemotaxis and phagocytosis (Aderem and Underhill 1999). Neldon-Ortiz and Qureshi (1991) pointed out that morphological change in chicken peritoneal macrophages after AFs exposure included a decline in adherence ability, blebbing formation on the cellular surface, and nuclear disintegration. AFs may interfere with the lipopolysaccharide (LPS) binding to protein on CD14 causing down-regulation of its expression decreasing the induction of cytokines (Wright et al. 1990).

H9N2-avian influenza viral shedding results figured out the role of aflatoxicosis in increasing the number of birds shedding the H9N2 virus and increased virus titer ($10^{7.8}$ EID₅₀/ml) in the AFs-treated chickens than the only H9N2-inoculated birds ($10^{5.6}$ EID₅₀/ml), further indicating the immunosuppressive effect of the aflatoxicosis. In turkeys, Umar et al. (2015) reported that H9N2 virus infection during aflatoxicosis characterized by a higher level in viral shedding in oropharyngeal swabs. In addition, AFs can induce immunosuppression in the form of impaired T or B lymphocytes performance, decreased

antibody synthesis, and decreased interferon and macrophages activity (Umar et al. 2012). Generally, aflatoxicosis decreases the resistance to common infectious diseases because of impairment of humoral and cellular immune responses (Bakshi et al. 2000). The immunosuppression induced by aflatoxicosis led to increased H9N2 pathogenicity (Kwon et al. 2008), which in turn can lead to mortality in H9N2-inoculated chickens.

CONCLUSION

From all the previous data we can conclude that AFs and H9N2 virus had an immunosuppressive effect. It was clearly appeared in their pathological changes exaggerated during their combination in broiler chickens. AFs contaminations promoting the pathogenesis of H9N2 infection to produce more pronounced clinical signs, histopathological lesions, and mortalities.

CONFLICT OF INTEREST

The authors declare that they have no conflict of interest.

REFERENCES

- Abd El-Hamid H, Ellakany H, Elbestawy A, Gado A (2018) Molecular Characterization of H9N2 Avian Influenza Viruses Isolated from Commercial Broiler Chickens in Egypt during 2014-2015 Alexandria Journal of Veterinary Sciences 56:54 doi:10.5455/ajvs.220473
- Abdel-Wahhab MA, Nada SA, Khalil FA (2002) Physiological and toxicological responses in rats fed aflatoxin-contaminated diet with or without sorbent materials Animal Feed Science and Technology 97:209-219 doi:10.1016/s0377-8401(01)00342-x
- Aderem A, Underhill DM (1999) Mechanisms of Phagocytosis in Macrophages Annual Review of Immunology 17:593-623 doi:10.1146/annurev.immunol.17.1.593
- Afzal M, Zahid S (2004) Effects of Addition of a Mycotoxin Detoxifier in Poultry Feed Containing Different Levels of Aflatoxins on the Performance of Broilers Asian Austral J Anim 17:990-994 doi:10.5713/ajas.2004.990
- Ahad A et al. (2013) Serosurveillance to H9 and H7 Avian Influenza Virus among Poultry Workers in Punjab Province, Pakistan Pakistan Veterinary Journal 33:107-112
- Alexander DJ (2003) Report on Avian Influenza in the Eastern Hemisphere During 1997–2002 Avian Dis 47:792-797 doi:10.1637/0005-2086-47.s3.792
- Azizpour A, Moghadam N (2015) Assessment of serum biochemical parameters and pathological changes in broilers with chronic aflatoxicosis fed glucomannan-containing yeast product (Mycosorb) and sodium bentonite Bulletin of the Veterinary Institute in Pulawy 59 doi:10.1515/bvip-2015-0031
- Bakshi CS, Asikdar T, Johri S, Malik M, Singh R (2000) Effect of grade dietary levels of aflatoxin on humoral immune response in commercial broilers Indian Journal of Comparative Microbiology, Immunology, and Infectious Diseases 21 163-164
- Bancroft JD, Gamble M (2002) Theory and Practice of Histological Techniques. 5th edn. Churchill Livingstone, Edinburgh ; New York
- Bano S, Naem K, Malik SA (2003) Evaluation of pathogenic potential of avian influenza virus serotype H9N2 in chickens Avian Dis 47:817-822 doi:10.1637/0005-2086-47.s3.817
- Basmacioglu H, Oguz H, Ergul M, Col R, Birdane YO (2005) Effect of dietary esterified glucomannan on performance, serum biochemistry and haematology in broilers exposed to aflatoxin Czech Journal of Animal Science 50:31-39
- Celik I, Oguz H, Demet O, Donmez HH, Boydak M, Sur E (2000) Efficacy of polyvinylpyrrolidone in reducing the immunotoxicity of aflatoxin in growing broilers British poultry science 41:430-439 doi:10.1080/713654954
- Chen K et al. (2014) Effects of dietary selenium on histopathological changes and T cells of spleen in broilers exposed to aflatoxin B1 International journal of environmental research and public health 11:1904-1913 doi:10.3390/ijerph110201904
- Cusumano V et al. (1996) Immunobiological activities of mould products: functional impairment of human monocytes exposed to aflatoxin B1 Research in Microbiology 147:385-391 doi:10.1016/0923-2508(96)84713-9
- Diener UL, Cole RJ, Sanders TH, Payne GA, Lee LS, Klich MA (1987) Epidemiology of aflatoxin formation by *Aspergillus flavus* Annual Review of Phytopathology 25:249-270 doi:10.1146/annurev.py.25.090187.001341
- El Miniawy HMF, Ahmed KA, El-Sanousi AA, Khattab MSM (2014) Effect of Aflatoxin Induced Immunosuppression on Pathogenesis of H9N2 Avian Influenza Virus Pakistan Veterinary Journal 34 234-238
- El Miniawy HMF, El-Sanousi AAG, Ahmed KAA, Khattab MMSE (2011) Pathogenesis of low pathogenic strain of avian influenza virus H9N2 in chickens fed on diet containing aflatoxins Toxicology Letters 205:S147 doi:10.1016/j.toxlet.2011.05.520
- Ellakany HF, Abuakkada SS, Oda SS, El-Sayed YS (2011) Influence of low levels of dietary aflatoxins on Eimeria tenella infections in broilers Trop Anim Health Prod 43:249-257 doi:10.1007/s11250-010-9685-0
- Gabal MA, Azzam AH (1998) Interaction of aflatoxin in the feed and immunization against selected infectious diseases in poultry. II. Effect on one-day-old layer chicks simultaneously vaccinated against Newcastle disease, infectious bronchitis and infectious bursal disease Avian Pathol 27:290-295 doi:10.1080/03709459808419338
- Gharaibeh S (2008) Pathogenicity of an avian influenza virus serotype H9N2 in chickens Avian Dis 52:106-110 doi:10.1637/8108-090907-Reg

- Giambone JJ, Diener UL, Davis ND, Panangala VS, Hoerr FJ (1985) Effects of purified aflatoxin on broiler chickens *Poult Sci* 64:852-858 doi:10.3382/ps.0640852
- Hablolvarid MH, Sohraby Haghdoost I, Pourbakhsh SA, Gholami MR (2004) Histopathological Study of Intratracheally Inoculated A/Chicken/Iran/259/1998 (H9N2) Influenza Virus in Chicken *Archives of Razi Institute* 58:51-62
- Hadipour MM, Farjadian SH, Azad F, Sheibani N, Olyae A (2011) Histologic Lesions of Thymus and Bursa of Fabricius in Commercial Broiler Chickens Inoculated with H9N2 Avian Influenza Virus *International Journal of Animal and Veterinary Advances* 3:186-188
- Hatori Y, Sharma RP, Warren RP (1991) Resistance of C57B1/6 mice to immunosuppressive effects of aflatoxin B1 and relationship with neuroendocrine mechanisms *Immunopharmacology* 22:127-136 doi:10.1016/0162-3109(91)90037-y
- He Y et al. (2014) Effects of sodium selenite on aflatoxin B1-induced decrease of ileal IgA+ cell numbers and immunoglobulin contents in broilers *Biological trace element research* 160:49-55 doi:10.1007/s12011-014-0035-3
- Hs A, Hf E, Ha H, Ar E, Km A (2016) Pathogenicity of an Avian Influenza H9N2 Virus isolated From Broiler Chickens in Egypt *Alexandria Journal of Veterinary Sciences* 51:90 doi:10.5455/ajvs.236275
- Hu P et al. (2018) The molecular mechanism of cell cycle arrest in the Bursa of Fabricius in chick exposed to Aflatoxin B 1 *Sci Rep* 8:1770 doi:10.1038/s41598-018-20164-z
- Iheshiulor OOM, Esonu BO, Chuwuka OK, Omede AA, Okoli IC, Ogbuewu IP (2011) Effects of mycotoxins in animal nutrition: A review *Asian Journal of Animal Sciences* 5:19-33 doi:10.3923/ajas.2011.19.33
- Jain NC (2000) *Schalm's Veterinary Haematology*. 5th edn. Lea and Febiger, Philadelphia
- Jiang M, Peng X, Fang J, Cui H, Yu Z, Chen Z (2015) Effects of aflatoxin b1 on T-cell subsets and mRNA expression of cytokines in the intestine of broilers *Int J Mol Sci* 16:6945-6959 doi:10.3390/ijms16046945
- Kishida N, Sakoda Y, Eto M, Sunaga Y, Kida H (2004) Co-infection of *Staphylococcus aureus* or *Haemophilus paragallinarum* exacerbates H9N2 influenza A virus infection in chickens *Arch Virol* 149:2095-2104 doi:10.1007/s00705-004-0372-1
- Kubena LF, Harvey RB, Huff WE, Corrier DE, Phillips TD, Rottinghaus GE (1990) Efficacy of a hydrated sodium calcium aluminosilicate to reduce the toxicity of aflatoxin and T-2 toxin *Poult Sci* 69:1078-1086
- Kumar PA, Das SK (1996) A colorimetric assay to evaluate the cytotoxic activity of the intestinal intraepithelial lymphocytes of chickens *Vet Res Commun* 20:513-518
- Kwon JS et al. (2008) Immune responses and pathogenesis in immunocompromised chickens in response to infection with the H9N2 low pathogenic avian influenza virus *Virus Res* 133:187-194 doi:10.1016/j.virusres.2007.12.019
- Liu T, Ma Q, Zhao L, Jia R, Zhang J, Ji C, Wang X (2016) Protective Effects of Sporoderm-Broken Spores of *Ganderma lucidum* on Growth Performance, Antioxidant Capacity and Immune Function of Broiler Chickens Exposed to Low Level of Aflatoxin B(1) *Toxins (Basel)* 8:278 doi:10.3390/toxins8100278
- Marchioro A et al. (2013) Effects of Aflatoxins on Performance and Exocrine Pancreas of Broiler Chickens *Avian Dis* 57:280-284 doi:10.1637/10426-101712-Reg.1
- Mohaghegh A, Chamani M, Shivazad M, Sadeghi AA, Afzali N (2016) Effect of esterified glucomannan on broilers exposed to natural mycotoxin-contaminated diets *J Appl Anim Res* 45:285-291 doi:10.1080/009712119.2016.1174122
- Nabney J, Nesbitt BF (1965) A spectrophotometric method for determining the aflatoxins *The Analyst* 90:155 doi:10.1039/an9659000155
- Neldon-Ortiz DL, Qureshi MA (1991) Direct and microsomal activated aflatoxin B1 exposure and its effects on turkey peritoneal macrophage functions in vitro *Toxicology and applied pharmacology* 109:432-442
- Oguz H, KeÇeci T, Birdane YO, ÖNder F, Kurtoglu V (2000) Effect of clinoptilolite on serum biochemical and haematological characters of broiler chickens during aflatoxicosis *Research in Veterinary Science* 69:89-93 doi:10.1053/rvsc.2000.0395
- Ortatlati M, Oguz H, Hatipoglu F, Karaman M (2005) Evaluation of pathological changes in broilers during chronic aflatoxin (50 and 100 ppb) and clinoptilolite exposure *Res Vet Sci* 78:61-68 doi:10.1016/j.rvsc.2004.06.006
- Peng X, Bai S, Ding X, Zeng Q, Zhang K, Fang J (2015) Pathological changes in the immune organs of broiler chickens fed on corn naturally contaminated with aflatoxins B1 and B2 *Avian Pathol* 44:192-199 doi:10.1080/03079457.2015.1023179
- Peng X et al. (2016) The mitochondrial and death receptor pathways involved in the thymocytes apoptosis induced by aflatoxin B1 *Oncotarget* 7:12222-12234 doi:10.18632/oncotarget.7731
- Peng X et al. (2014) Histological lesions, cell cycle arrest, apoptosis and T cell subsets changes of spleen in chicken fed aflatoxin-contaminated corn *International journal of environmental research and public health* 11:8567-8580 doi:10.3390/ijerph110808567
- Qureshi MA, Hagler WM (1992) Effect of Fumonisin-B1 Exposure on Chicken Macrophage Functions in vitro *Poultry Sci* 71:104-112 doi:10.3382/ps.0710104
- Raisuddin, Singh KP, Zaidi SIA, Saxena AK, Ray PK (1990) Effects of aflatoxin on lymphoid cells of weanling rat *Journal of Applied Toxicology* 10:245-250 doi:10.1002/jat.2550100404
- Raju MVLN, Devegowda G (2000) Influence of esterified-glucomannan on performance and organ morphology, serum biochemistry and haematology in broilers exposed to individual and combined mycotoxicosis (aflatoxin, ochratoxin and T-2 toxin) *British poultry science* 41:640-650 doi:10.1080/713654986
- Reed LJ, Muench H (1938) A Simple Method of Estimating Fifty Per Cent Endpoints *American Journal of Epidemiology* 27:493-497 doi:10.1093/oxfordjournals.aje.a118408
- Safamehr A (2008) The Performance and Hematological Characters in Broiler Chicks Fed Ammonia-Treated Aflatoxin Contaminated Feed *Journal of Animal and Veterinary Advances* 7:331-336
- Salaberria C, Muriel J, de Luna M, Gil D, Puerta M (2013) The PHA test as an indicator of phagocytic activity in a passerine bird *PLoS One* 8:e84108 doi:10.1371/journal.pone.0084108
- Somayeh Asadzadeh M (2011) Detection of H9N2 avian influenza virus in various organs of experimentally infected chickens *Afr J Microbiol Res* 5 doi:10.5897/ajmr11.214
- Subler KA, Mickael CS, Jackwood DJ (2006) Infectious Bursal Disease Virus-Induced Immunosuppression Exacerbates *Campylobacter jejuni* Colonization and Shedding in Chickens *Avian Dis* 50:179-184 doi:10.1637/7434-090705r.1
- Sur E, Celik I (2003) Effects of aflatoxin B1 on the development of the bursa of Fabricius and blood lymphocyte acid phosphatase of the chicken *British poultry science* 44:558-566 doi:10.1080/00071660310001618352
- Theumer MG, Cánepa MC, López AG, Mary VS, Dambolena JS, Rubinstein HR (2010) Subchronic mycotoxicoses in Wistar rats: Assessment of the in vivo and in vitro genotoxicity induced by fumonisins and aflatoxin B1, and oxidative stress biomarkers status *Toxicology* 268:104-110 doi:10.1016/j.tox.2009.12.007
- Umar S, Arshad A, Ahmad B, Arshad M (2012) Clinic-biochemical and haematological changes in broilers induced by concurrent exposure to aflatoxin b1 and ochratoxin *Journal of Public Health and Biological Sciences* 1:79-85
- Umar S et al. (2015) Role of aflatoxin toxicity on transmissibility and pathogenicity of H9N2 avian influenza virus in turkeys *Avian Pathol* 44:305-310 doi:10.1080/03079457.2015.1046813
- Verma J, Johri TS, Swain BK, Ameena S (2010) Effect of graded levels of aflatoxin, ochratoxin and their combinations on the performance and immune response of broilers *British poultry science* 45:512-518 doi:10.1080/00071660412331286226
- Wells MA, Ennis FA, Albrecht P (1981) Recovery from a viral respiratory infection. II. Passive transfer of immune spleen cells to mice with influenza pneumonia *J Immunol* 126:1042-1046
- West S, Wyatt RD, Hamilton PB (1973) Improved yield of aflatoxin by incremental increases of temperature *Appl Microbiol* 25:1018-1019
- WHO (2002) WHO manual on animal influenza diagnosis and surveillance. Department of Epidemic and Pandemic Alert and Response, Geneva, World Health Organization
- Wright S, Ramos R, Tobias R, Ulevitch R, Mathison J (1990) CD14, a receptor for complexes of lipopolysaccharide (LPS) and LPS binding protein *Science* 249:1431-1433 doi:10.1126/science.1698311
- Yuan S et al. (2016) The mitochondrial and endoplasmic reticulum pathways involved in the apoptosis of bursa of Fabricius cells in broilers exposed to dietary aflatoxin B1 *Oncotarget* 7:65295-65306 doi:10.18632/oncotarget.11321
- Yunus AW, Razzazi-Fazeli E, Bohm J (2011) Aflatoxin B(1) in affecting broiler's performance, immunity, and gastrointestinal tract: a review of history and contemporary issues *Toxins (Basel)* 3:566-590 doi:10.3390/toxins3060566