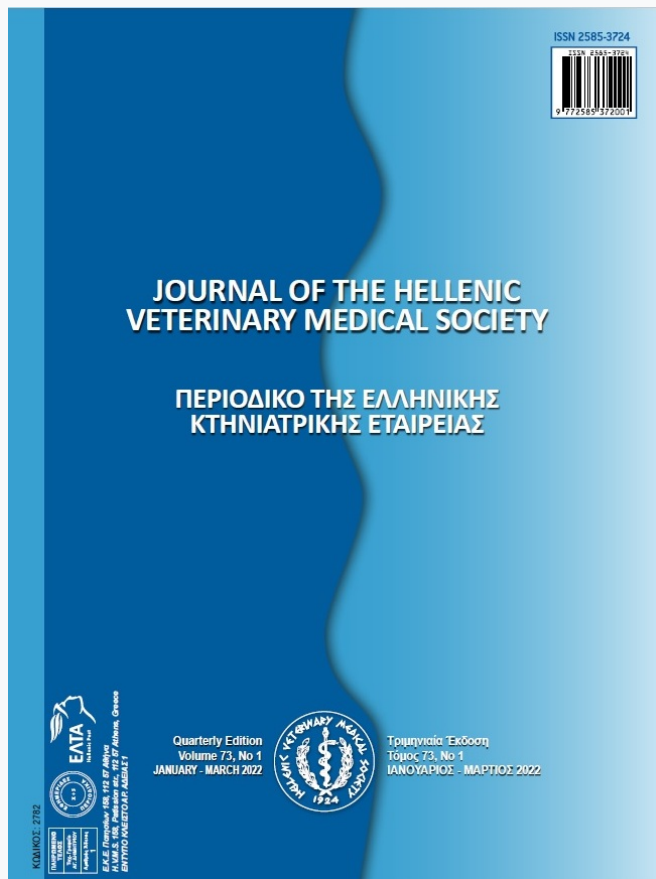

Journal of the Hellenic Veterinary Medical Society

Vol 73, No 1 (2022)



Polypoid Cystitis in a dog. A case report.

NIKOLAOS KLEANTHI PAPADOPOULOS

doi: [10.12681/jhvms.24464](https://doi.org/10.12681/jhvms.24464)

Copyright © 2022, NIKOLAOS KLEANTHI PAPADOPOULOS



This work is licensed under a [Creative Commons Attribution-NonCommercial 4.0](https://creativecommons.org/licenses/by-nc/4.0/).

To cite this article:

PAPADOPOULOS, N. K. (2022). Polypoid Cystitis in a dog. A case report. *Journal of the Hellenic Veterinary Medical Society*, 73(1), 3897–3900. <https://doi.org/10.12681/jhvms.24464>

Polypoid Cystitis in a dog - A case report

N. K. Papadopoulos¹, E. Karavanis²

¹ *Laboratory of Pathology, Military Center of Biological Researches (KVIRES), Camp "Koutsoukou", Penteli, Greece*

² *Laboratory of Pathology, 3rd Veterinary Hospital of the Hellenic Army, Camp "Makris" Thermi, Greece*

ABSTRACT: Polypoid cystitis is a rare disease of younger male dogs. The aim of this article is to report a case of polypoid cystitis, first in Greece, which was observed in a dog. The 11-year-old dog had a 3-month history of hematuria. Upon surgical approach to the retroperitoneal area an irregularly thickened wall was revealed, and additionally six (6) cysts 1-6 mm in diameter protruded from the mucosal surface. Histological examination confirmed transitional cell hyperplasia covering a core of proliferating connective tissue, edema and a neutrophilic inflammatory cell infiltrate with areas of ulceration and hemorrhage. These lesions are consisted with polypoid cystitis which is a rare-benign disease, histopathology is the means of definitive diagnosis and it is best treated with surgical cystotomy.

Keywords: polypoid cystitis, urinary bladder

Corresponding Author:
N. Papadopoulos, 1 Konstantinou Pyrrou str., 15351 Pallini, Attiki, Greece
E-mail address: npapadovet@yahoo.gr

Date of initial submission: 10-03-2020
Date of acceptance: 14-12-2021

CASE HISTORY

A 11-year-old intact male German shepherd dog (GSD) was presented with 3-month history of hematuria. Urine culture was not performed as the dog had previously undergone broad spectrum antibiotic therapy, however clinical signs returned after discontinuation. Ultrasound and X-ray imaging was not elucidative, therefore, exploratory surgery was scheduled.

Upon surgical approach to the retroperitoneal area, the bladder wall was revealed to be irregularly thickened. Six (6) cysts 1-6 mm in diameter protruded from the mucosal surface. Surgical biopsy samples from the bladder polypoid masses of dog were obtained. The other organs were normal.

Tissues were fixed in 10% buffered formalin, embedded in paraffin, sectioned at 4 µm and stained with Hematoxylin and Eosin (H-E stain).

Histological examination confirmed transitional cell hyperplasia covering a core of proliferating connective tissue and polypoid projections were detected into the lumen. In addition to these findings, there was edema and an inflammatory cell infiltrate (neutrophils) with areas of ulceration and hemorrhage. All the above, which compose the mentioned criteria by Martinez et al. (2003) for establishing a definitive diagnosis of PC, along with the fact that the basement membrane was intact, very rarely are seen all together in the same specimen, hence the rarity of our case, which is the first reported PC case in dog in Greece. The latter is attributed usually to the unacceptable condition of the sample as the proliferating tissue, obtained during cystoscopy is very delicate and tiny. After an 8 month period the dog was free of symptoms, confirming our diagnosis.

DISCUSSION

Polypoid cystitis (PC) is a rare disease of the urinary bladder in dogs and grossly, in tangential sections, or in case where only small surgical specimens are obtained for biopsy, may be incorrectly taken for urothelial carcinoma - transitional cell carcinoma (UC/TCC), which stands as the most commonly diagnosed tumor in the urinary bladder of domestic animals. The predominant patient group are male medium aged dogs (D.J. Meuten and T.L.K. Meuten, 2017).

Of all reported malignancies in the dog, urinary bladder cancer accounts for about 2%, with invasive

urothelial carcinoma (UC) being the most common form. Differentiation of the non-UC conditions (such as PC) from UC is of major importance, since the treatment and prognosis vary in a great degree (Fulkerson and Knapp, 2020). The similar gross morphologic appearance of a great number of neoplasms is the reason why PC cannot be easily diagnosed macroscopically. The golden standard of definitive diagnosis is histopathology. The obtained biopsies during cystoscopy will confirm in most cases the diagnosis of polypoid cystitis (Martinez et al., 2003), while in other cases conflicting results may require rediagnosis (Butty et al., 2021). Confirmation of UC when dealing with cases that are not definitive can be accomplished with the aid of immunohistochemistry (IHC) (uropodkin III, GATA-3) (Fulkerson and Knapp, 2020).

UC is mostly located at the bladder neck or trigone region, although such lesions can be found in all anatomical parts of the canine bladder (Martinez et al., 2003; Fulkerson and Knapp, 2020). In a study of 17 dogs with polypoid cystitis, the most favorable location is the cranioventral bladder mucosa (apex) and the ventral mucosa (Martinez et al., 2003).

The causative agents of polyp formation in dogs is still unknown. It can be induced from a chronic mucosal irritation of the urinary bladder, which is due to UTI (Urinary Tract Infection) or cystic calculi. Chronic irritation can be caused by cystic calculi and, as a result a polyp formation is enhanced even without the presence of UTI. Up to this day remains unknown whether UTI is a cause or effect of polyp formation. Another fact that needs to be clarified in the future is the role of some bacteria, such as *Proteus spp.*, in the pathogenesis of polypoid cystitis. In human medicine, the use of indwelling urinary catheters and the resulted chronic bladder irritation is implicated in the presence of PC. One study even suggested that the main cause of all these might be the drainage conditions, implying as a key factor the associated negative pressure in the bladder (Martinez et al., 2003).

Macroscopically, the surface of the mucosal bladder is elevated by one or multiple nodular to polypoid lesions that protrude into the lumen with a ranging diameter, from 5 mm to 4 cm according to Martinez et al. (2003), or 2-3 cm as reported by D.J. Meuten and T.L.K. Meuten (2017). Also edema and inflammation may cause the thickening of the bladder wall. Microscopically, the polyp consists of urothelial cell hyperplasia (Figures 1-2) that covers a core of proliferating connective tissue. Hyperplasia induce the

formation of Brunn's nests (varying sized foci of urothelium-Figure 3). Mucoid degeneration and dysplastic or even metaplastic foci can be found at the mucus-secreting glands (cystitis glandularis-Figure 4) along with edema, congestion, ulceration, hemorrhage and inflammation (D.J. Meuten and T.L.K. Meuten, 2017). All the above findings were observed in our case simultaneously which is rather not very common.

The histological criteria to establish a definitive diagnosis of polypoid cystitis are (1) microscopically detectable polypoid projections of mucosa and stroma into the lumen, (2) evidence of epithelial proliferation (thickening, mitotic figures, or down-growth of epithelial cords into the stroma), (3) stromal edema, (4) inflammation, and (5) stromal hemorrhage and hemosiderin accumulation. Apart from these, intraepithelial lumina often filled with proteinaceous secretions, ulcerations, erosions, granulation tissue, or epithelial atypia, also constitute characteristic lesions. These

criteria are mentioned by Martinez et al. (2003) and were confirmed in our study. In 2009, a Korean essay by Im et al. reported the same histological findings also. One additional criterion of major importance is that the basement membrane must be intact, without infiltrations along the entire length. In our case the basement membrane had not been penetrated and all lesions were confined to the mucosa of the bladder.

The most common clinical sign of PC is hematuria, as a result of hemorrhage from the polyp mucosa due to chronic irritation (Martinez et al., 2003).

PC shares the same clinical signs with other conditions such as neoplasia (other than UC), chronic cystitis, fibroepithelial polyps, granulomatous cystitis/urethritis, gossypiboma, calculi, inflammatory pseudotumor and UC (Fulkerson and Knapp, 2020). The biologic behavior of PC warrants further study as malignant transformation into TCC cannot be ruled out (Butty et al., 2021).

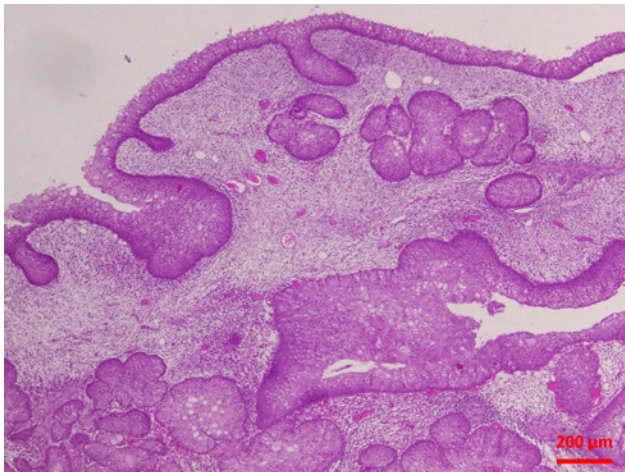


Figure 1.

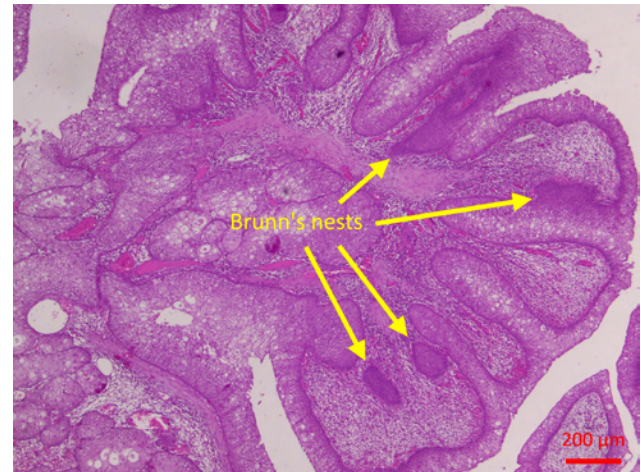


Figure 3.

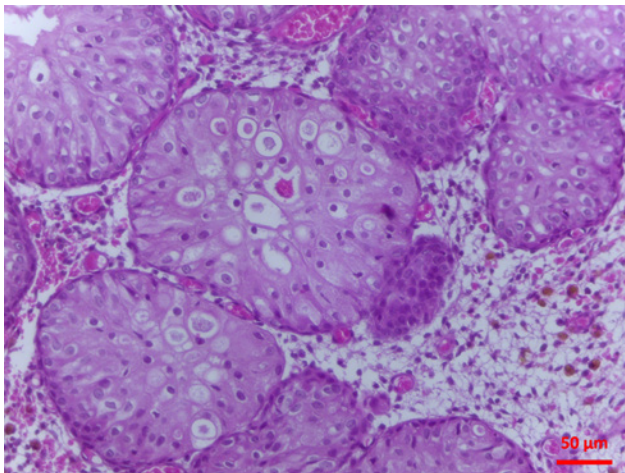


Figure 2.

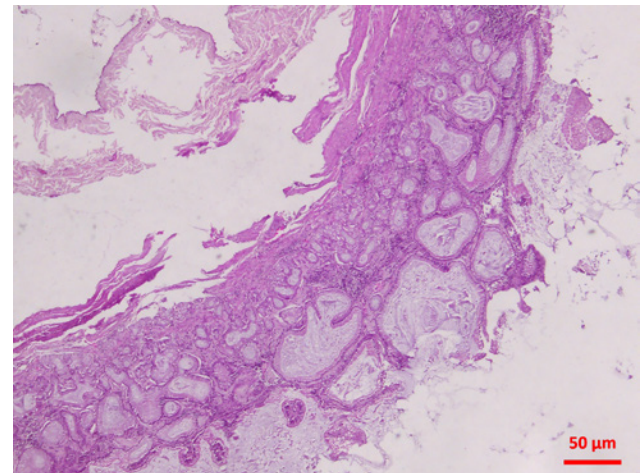


Figure 4.

The best way to evaluate the urinary bladder is surgical cystotomy. In case of cystic calculi, these are composed of struvite, apatite plus struvite and calcium oxalate. Antibiotics such as amoxicillin [alone or in combination with clavulanic acid (Augmentin®, GlaxoSmithKline)] and cephalexin (Ceporex®, Intervet/Schering-Plough Animal Health) are the most common primary selected. Aggressive medical management can even sometimes cause polyps complete

regression and gives the chance to control clinical signs (Martinez et al., 2003).

In conclusion, PC is an uncommon disease, very similar with urothelial carcinoma (UC) concerning clinical and macroscopical findings. Histopathologic examination using certain criteria is the most accurate way to differentiate from UC and treat and prognose accordingly. In our best knowledge, this is the first report of PC in dog in Greece.

REFERENCES

- Butty E. M., Hahn S., Labato M. A. (2021) Presumptive malignant transformation of chronic polypoid cystitis into an apical transitional cell carcinoma without BRAF mutation in a young female dog. *J Vet Intern Med* 2021; 35:1551-1557
- Fulkerson C. M., Knapp D. W. (2020) Tumors of the Urinary System. In: Withrow & MacEwen's Small Animal Clinical Oncology. 6th ed, Elsevier, Missouri: pp 645-656.
- Im E.J., Kang S.C., Jung J.Y., Jeon J.N., Kim J.H. (2009) A case of polypoid cystitis in a dog. *Korean J Vet Res* 2009; 49 (2) :163-166
- Martinez I, Mattoon J. S., Eaton K. A., Chew D. J., DiBartola S. P. (2003) Polypoid Cystitis in 17 Dogs (1978-2001). *J Vet Intern Med* 2003; 17:499-509
- Meuten D. J., Meuten T.L.K. (2017) Tumors of the Urinary System. In: Tumors in Domestic Animals. 5th ed, John Wiley & Sons, Inc., Raleigh, North Carolina (NC), USA: pp 632-688.