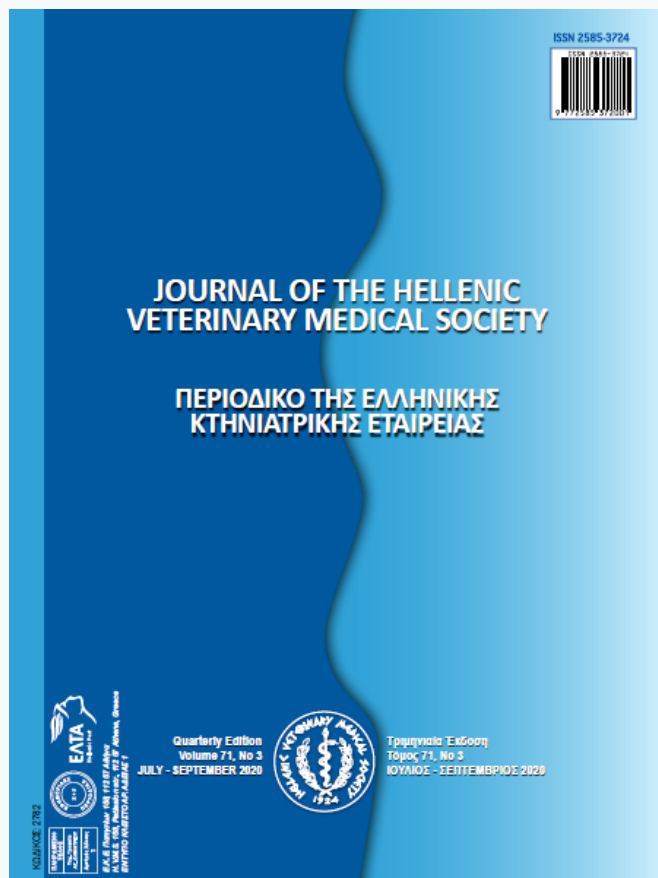

Journal of the Hellenic Veterinary Medical Society

Vol 71, No 3 (2020)



Feline Hypertrophic Osteopathy Associated with Congenital Megaesophagus: Two Case Reports and Literature Review

A.M. ABU-SEIDA, F.A. TORAD, E.A. HASSAN, K.M. ALI

doi: [10.12681/jhvms.25106](https://doi.org/10.12681/jhvms.25106)

Copyright © 2020, A.M. ABU-SEIDA, F.A. TORAD, E.A. HASSAN, K.M. ALI



This work is licensed under a [Creative Commons Attribution-NonCommercial 4.0](https://creativecommons.org/licenses/by-nc/4.0/).

To cite this article:

ABU-SEIDA, A., TORAD, F., HASSAN, E., & ALI, K. (2020). Feline Hypertrophic Osteopathy Associated with Congenital Megaesophagus: Two Case Reports and Literature Review. *Journal of the Hellenic Veterinary Medical Society*, 71(3), 2413–2418. <https://doi.org/10.12681/jhvms.25106>

Feline Hypertrophic Osteopathy Associated with Congenital Megaesophagus: Two Case Reports and Literature Review

A.M. Abu-Seida*, F.A. Torad, E.A. Hassan, K.M. Ali

Department of Surgery, Anesthesiology and Radiology, Faculty of Veterinary Medicine, Cairo University. Giza, Egypt

ABSTRACT: This report describes two cases of feline hypertrophic osteopathy (HO) associated with congenital megaesophagus (ME). The diagnosis was based upon case history, physical examination, radiography and laboratory investigations. The clinical signs of both cats included; regurgitation, weakness and reluctance to walk since birth. Physical examination revealed painful and thickened long bones, swollen joints, difficult flexion of all four limbs and normal urination, defecation, appetite as well as heart and respiratory rates. The abnormal laboratory findings were thrombocytosis, leukocytosis with lymphocytosis and monocytosis. Survey and contrast thoracic radiography showed generalized esophageal dilatation. Radiography of appendicular skeleton revealed symmetrical and massive subperiosteal new bone formation of the affected long bones and pelvis. In conclusion, radiography of extremities is highly recommended for cats admitted with congenital ME and lameness to investigate the possibility of HO. Moreover, the HO should be listed during the differential diagnosis of thickened limbs in cats.

Keywords: Domestic shorthair cat, Hypertrophic osteopathy, Lameness, Megaesophagus, Periosteal proliferation.

Corresponding Author:

Ashraf M. Abu-Seida, Department of Surgery, Anesthesiology & Radiology, Faculty of Veterinary Medicine, Cairo University, PO 12211, Giza, Egypt
E-mail address: ashrafseida@cu.edu.eg, ashrafseida@yahoo.com

Date of initial submission: 05-01-2020
Date of revised submission: 25-02-2020
Date of acceptance: 07-03-2020

INTRODUCTION

Congenital megaesophagus (ME) or esophageal hypomotility is a rare disease in cats affecting mostly Siamese cats (Hoenig et al., 1990). Acquired ME can be seen in all cat breeds. It is characterized by a decreased or absent esophageal motility. The most common clinical signs include; poor body condition, weight loss, regurgitation, changes in eating habits and difficulty in swallowing. Respiratory distress, aspiration pneumonia, excessive salivation, halitosis, coughing, nasal discharge and fever are the most common complications of ME (Forbes and Leishman, 1985). Megaesophagus may be congenital, due to ill-developed signaling pathway of the esophagus, acquired due to numerous causes (Hoenig et al., 1990).

Hypertrophic osteopathy (HO) is a diffuse periosteal proliferative disease particularly affecting the appendicular long bones (Hime et al., 1972). Most of the reported cases of HO are secondary to pulmonary or abdominal neoplasms or inflammatory disease of unknown pathogenesis (Rohr 2003; Johnson and Lenz, 2011).

According to the available literature, several cases of feline HO have been reported over the years (1971-2019) as a secondary to several disorders disease such as pulmonary, digestive and renal lesions as well as kidney, adrenal gland and injection site neoplasms as shown in table (1). Moreover, four reports of idiopathic HO have been recorded (Table 1). The prognosis of HO in cats is poor as most of the recorded cases were died shortly afterwards (Richards, 1977; Gram et al., 1990)

or euthanized at the owner's request at the time of diagnosis (Carr, 1971; Roberg, 1977; de Melo et al., 2006; Guizelini et al., 2019). However, medical and surgical treatments were successful six months after their initiation in few cases of HO (Becker et al., 1999; Grierson et al., 2003; Huang et al., 2010; Mills 2010).

In addition, HO has been previously reported in canine, equine, bovine, wild animals and human secondary to thoracic neoplasms, sarcoma of the urinary bladder, bacterial endocarditis and infection by *Spirocerca lupi* or *Dirofilaria immitis* (Brodey 1971; Ndikwere and Hill, 1989; Masegi et al., 1994; Mair et al., 1996, Hassan et al., 2019).

Secondary HO is presented with lameness, long-bone pain and symptoms from the primary thoracic or abdominal lesions. The diagnosis of such cases is based upon radiography that detects the primary lesions and hypertrophic changes of long bones (Nafe et al., 1981; Gram et al., 1990; Rohr, 2003). Computed tomography (Johnson and Lenz, 2011), Magnetic Resonance Imaging (Salguero et al., 2015) and histopathology (Grierson et al., 2003; Salguero et al., 2015) have also been used in the diagnosis of HO in cats.

Nutritional and supportive treatment such as suitable fluid therapy and electrolyte correction according to the abnormalities in laboratory test results were recommended for treatment of feline HO (Huang et al., 2010).

This study aims to present two cases of feline congenital megaesophagus associated with HO.

Table 1. The primary lesions and prognosis of the recorded feline hypertrophic osteopathy

Primary lesion	No of cases	Outcome	References
Pulmonary lesion	One	Euthanized at the time of diagnosis	Carr (1971)
Pulmonary neoplasia	One	Died shortly afterwards	Richards (1977)
Pulmonary neoplasia	One	Euthanized at the time of diagnosis	Roberg (1977)
Renal papillary adenoma	One	Euthanized at the time of diagnosis	Nafe et al. (1981)
Pulmonary carcinoma	One	Died shortly afterwards	Gram et al. (1990)
Adrenocortical carcinoma	One	Recovered after 4 months of surgery	Becker et al. (1999)
Pulmonary sarcoma	One	Recovered after 6 months of surgery	Grierson et al. (2003)
Pulmonary lesion	One	Died shortly afterwards	Rohr (2003)
Megaesophagus	One	Recovered after medical therapy	Mills (2010)
Renal adenoma	One	Euthanized at the time of diagnosis	Johnson and Lenz (2011)
Injection-site sarcoma	One	Euthanized at the time of diagnosis	Salguero et al. (2015)
Cardiac interventricular septal defect	One	Euthanized at the time of diagnosis	De Sousa et al. (2019)
Idiopathic	Seven	6 cats recovered after medical therapy and one died shortly afterwards	Huang et al. (2010)
Idiopathic	One	Euthanized at the time of diagnosis	De Melo et al. (2006)
Idiopathic	One	Euthanized at the time of diagnosis	Ocarino et al. (2006)
Idiopathic	One	Euthanized at the time of diagnosis	Guizelini et al. (2019)

CASE HISTORY OF THE FIRST CAT

A 3-month-old female intact domestic shorthair kitten was admitted to the surgery clinic at Faculty of Veterinary Medicine, Cairo University, Egypt with a history of intermittent regurgitation since birth, stiffness and weakness (Fig 1). The case history revealed

that the kitten was an orphan stray animal and fed on cat milk until weaning at the age of 2 months. The appetite remained normal despite the intermittent regurgitation and defecation and urination pattern was unremarkable.

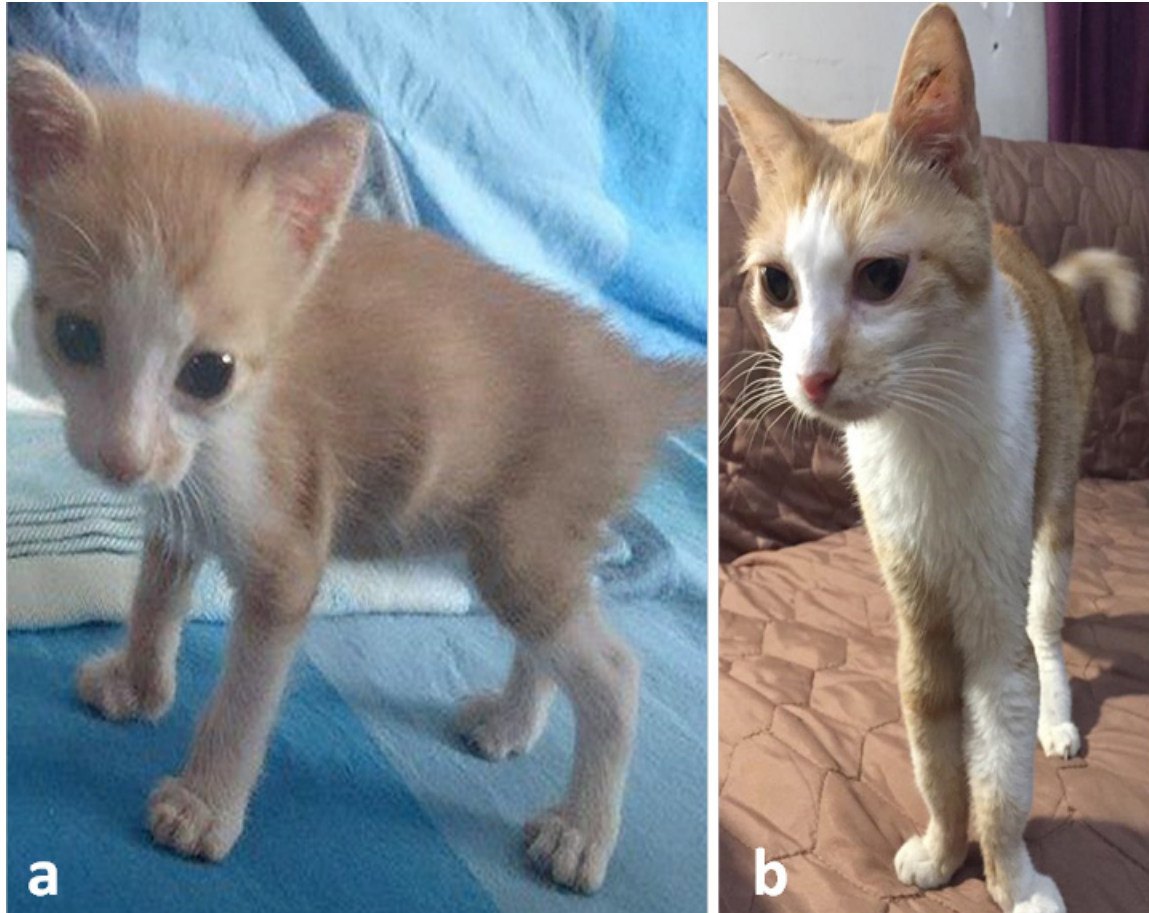

Figure 1. (a) A 3-month-old female domestic shorthair kitten with megaesophagus and hypertrophic osteopathy showing poor body condition and slight thickening of both forearms. (b) The same cat at the age of 4 years showing marked thickening of the limbs.

The kitten had also dental malocclusion, changes in eating habits, stiffness and poor condition at the age of 3 months. A thorough physical examination was unremarkable. Symptomatic and supportive therapeutic measures for presumed gastritis were initially performed in the form of intravenous injections of Dextrose 5% solution as boluses (40 mL daily) and 0.3 mg/kg of metoclopramide (Primperan®, Sanofi Aventis) as an antiemetic drug twice daily for 3 days. Three months after initial presentation, the kitten with poor body condition was readmitted for intermittent regurgitation. Plain lateral thoracic radiography and positive contrast esophagography barium sulfate paste (E-Z-Paste® Barium sulphate esophageal cream (60% w/w), Bracco Diagnostics Inc., USA) dosed as

5–10 mL oral bolus together with the previous case history confirmed severe generalized congenital megaesophagus (Fig 2). The owner was advised to administer a liquid diet from an elevated position and hold the kitten in upright position after each meal. Over the following months, the general clinical status improved yet occasional regurgitation still occurred.

At the age of one year, the cat was re-admitted for investigation of weakness, thickening of all four limbs, reluctance to walk, stiffness in gait and occasional regurgitation. Palpation of the long bones elicited slight pain and showed hard thickening of the humerus, radius, ulna, femur, tibia and fibula. Flexion of all limbs was difficult, particularly the forelimbs.

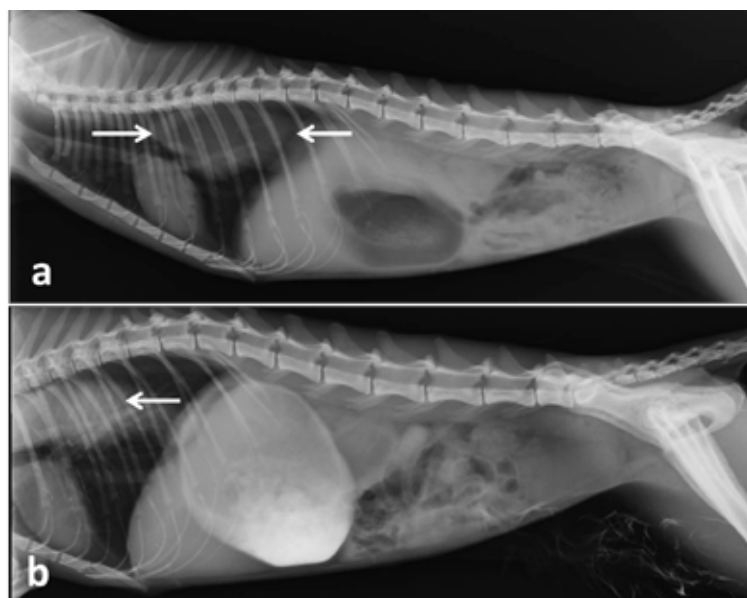


Figure 2. (a) Lateral plain and positive contrast (b) thoracic radiographs of the same cat in figure (1) showing severe esophageal dilatation (White arrows).

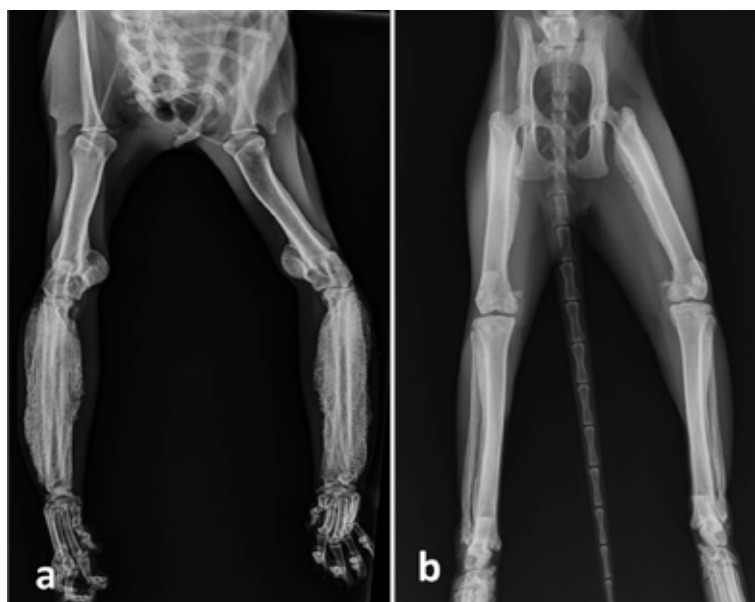


Figure 3. (a) Ventrodorsal radiographs of both forelimbs and hindlimbs (b) of the same cat in figure (1) showing marked periosteal proliferation particularly on the radius, ulna and femur bones.

Routine complete blood count (CBC) revealed thrombocytosis ($915 \times 10^3/\mu\text{L}$, reference interval [RI]: $300-800 \times 10^3/\mu\text{L}$), leukocytosis ($25.3 \times 10^3/\mu\text{L}$, RI: $5.5-19.51 \times 10^3/\mu\text{L}$) with lymphocytosis ($9.5 \times 10^3/\mu\text{L}$, RI: $1.5-7 \times 10^3/\mu\text{L}$) and monocytosis ($1.3 \times 10^3/\mu\text{L}$, RI: $0.0-0.9 \times 10^3/\mu\text{L}$). Radiographic examinations of the appendicular skeleton showed extensive subperiosteal new bone proliferation suggesting HO. Radiographic changes included intense and symmetric formation of new subperiosteal bone through all diaphyses and metaphyses of the affected bones (Fig 3). The new bone formation had uniform opacity and a 'palisading' pat-

tern in some areas. The most affected bones were radius, ulna and femur in both limbs. Interestingly, the new bone formation was more clearly seen in forelimbs than hind limbs. Oral treatment with meloxicam 0.1 mg q24h (Metacam; Boehringer Ingelheim, Germany) was given for pain control.

The animal's weight was 2 kg, 2.6 kg, 2.7 kg, 2.2 kg and 2.5 kg at the age of 6, 12, 18, 30 and 48 months, respectively. After puberty, the cat exhibited abnormal and scarce estrus cycle that lasted for 2-3 days without any obvious signs. CBC was carried out

again at the age of 2.5 and 3 years and revealed the same previous abnormal findings.

Serum biochemistry tests including albumin, creatinine, urea, alkaline phosphatase, alanine aminotransferase, aspartate aminotransferase and γ -glutamyltransferase tests revealed high urea level, 49 mg/dL (reference range 10-30 mg/dL) as the only abnormality. Serum creatinine was 0.9 mg/dL (reference range <1.6 mg/dL). Urinalysis was unremarkable with inactive sediment. Until this writing (Four years after the initial presentation), in periodic follow up examinations, the cat remains in stable condition, presenting occasional regurgitation episodes.

CASE HISTORY OF THE SECOND CAT

A one-year-old female intact domestic shorthair cat was admitted with a history of intermittent regurgitation, thickened limbs, weakness and reluctance to walk. Physical examination was unremarkable. Palpation of the limbs showed hard thickening of all four

limbs with slight pain. Plain lateral thoracic radiography and positive contrast esophagography (E-Z-Paste® Barium sulphate esophageal cream (60% w/w), Bracco Diagnostics Inc., USA) dosed as 5–10 mL oral boluses revealed dilated esophagus. Radiographic examination of all limbs showed periosteal proliferation in humeri, femurs and tibiae (Fig 4). It was not known how long periosteal proliferation had been present prior to initial presentation. Feline hypertrophic osteopathy associated with congenital megaesophagus was confirmed. The owner was advised to feed the cat 5-6 times daily small amounts of liquid diets (such as; beef/chicken broth, baby cereals, blend soft cat food with broth or commercial feline liquid diets) from a high position that resulted in marked improvement in the regurgitation episodes.

The owners of both cases refused any surgical treatment (Percutaneous endoscopic gastrostomy tube placement or esophagectomy) for megaesophagus and we could not follow up the second case.

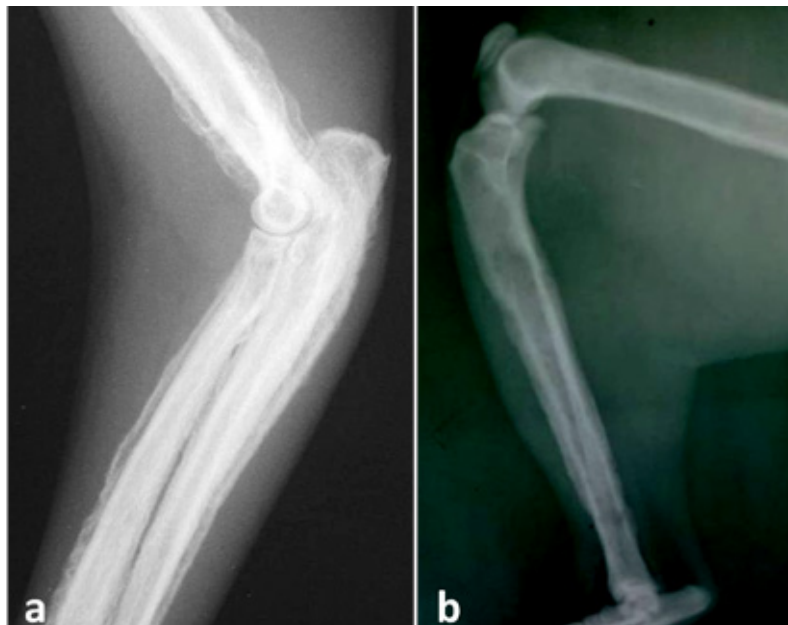


Figure 4. (a) Latero-medial radiographs of a one-year-old female domestic shorthair cat showing marked periosteal proliferation in humerus, radius and ulna in the forelimb as well as femur and tibia in hindlimb (b).

DISCUSSION

Hypertrophic osteopathy also known as Marie's disease is a rare disease of uncertain pathogenesis in cats (Langley-Hobbs, 2012). Several suggestions have been mentioned such as periosteal irritation by circulating toxins originated from the primary disease, disturbance in peripheral blood flow to the limbs, neurogenic stimuli, vagal and intercostal nerves stimulations, distal vascular production of platelet-derived

growth factor and vascular endothelial growth factor (Richards, 1977; Gram et al., 1990; Salguero et al., 2015). In our recorded cases, the pathogenesis of HO development due to ME was not determined; however, one or more of the aforementioned theories could have contributed. The increase of blood flow to the limbs is one of the most important factors responsible for development of bone lesions. According to the neuron theory, ME may stimulate the vagus nerve

and increase the peripheral blood flow with less tissue oxygen stimulating periosteal proliferation (Roberg, 1977; de Melo et al., 2006; Huang et al., 2010). In addition, we couldn't exclude the possibility of simultaneous independent occurrence of idiopathic HO and congenital ME in the recorded cases. Both idiopathic HO and HO secondary to ME were previously reported in cats as shown in table (1). We recommend further studies to identify the exact association between HO and ME in cats.

The recorded cases in this report were young adult female cats. No age, breed or sex predisposition has been reported in literature so far (Huang et al., 2010).

The weakness, poor body condition and reluctance to walk were attributed to deficient nutrition as a result of the intermittent regurgitation. Moreover, the pain, difficult flexion, enlarged joints and hard thickening of all four limbs could be attributed to the massive subperiosteal new bone proliferation. Regurgitation is the most common clinical sign noted with ME. Frequency and timing of regurgitation after feeding may vary considerably. The hematological abnormalities presented by the cats were compatible with those reported in the literature (Ocarino et al., 2006; Salgüero

et al., 2015).

Medical treatment of ME includes small, frequent meals from an upright position in order to facilitate passage of the food through the esophagus into the stomach. The decrease in the frequency of regurgitation in our recorded cases could be attributed to the improvement of esophageal function with age due to maturation of the esophageal neuromuscular system after the first year of age. Similar findings were recorded in dogs (Brodey, 1971).

Resolution of the HO after surgical removal of the primary lesion has been reported in several studies (Becker et al., 1999; Grierson et al., 2003; Mills, 2010). Although medical treatment of ME decreased regurgitation episodes in both recorded cases, it did not improve HO. This may be due to severity of both cases and the absence of complete resolution of ME in both cats.

CONFLICT OF INTEREST

The authors declare no conflict of interests regarding publishing of this article.

REFERENCES

- Becker TJ, Perry RL and Watson GL (1999) Regression of hypertrophic osteopathy in a cat after surgical excision of an adrenocortical carcinoma. *J Am Anim Hosp Assoc* 35, 499-505.
- Brodey RS (1971) Hypertrophic osteoarthropathy in the dog: a clinicopathologic survey of 60 cases. *J Am Vet Med Assoc* 159, 1242-1256.
- Carr SH (1971) Secondary hypertrophic pulmonary osteoarthropathy in a cat. *Feline Pract* 1, 25-26.
- de Melo ON, Fukushima FB, Gomes A, Bueno DF, Oliveira TS and Serakides R (2006) Idiopathic hypertrophic osteopathy in a cat. *J Feline Med Surg* 8, 345-348.
- de Sousa FAB, Bianchi MV, Taunde PA, Bandinelli MB, Fett RR, Driemeier D, Pavarini SP (2019) Hypertrophic osteopathy in a cat with cardiac interventricular septal defect. *J Vet Sci* 20, e52.
- Forbes DC and Leishman, DE (1985) Megaesophagus in a Cat. *Can Vet J* 26, 354-356.
- Gram WD, Wheaton LG, Snyder PW, Losonsky JM and Whiteley E (1990) Feline hypertrophic osteopathy associated with pulmonary carcinoma. *J Am Anim Hosp Assoc* 26, 425-428.
- Grierson JM, Burton CA and Brearley MJ (2003) Hypertrophic osteopathy secondary to pulmonary sarcoma in a cat. *Vet Comp Oncol* 1, 227-231.
- Guizelini C, Mattei DR, Pupin RC, Martins TB, and Gomes DC (2019) Hypertrophic Osteopathy in a Cat. *Acta Sci Vet* 47 (Suppl 1), 373.
- Hassan E, Torad FA, Abu-seida AM and Hassan A (2019) Mandibular hypertrophic osteodystrophyfibrosa in a German shepherd puppy. *Kafkas Univ Vet Fak Derg* 25, 883-886.
- Hime JM, Keymer IF and Appleby EC (1972) Hypertrophic pulmonary osteoarthropathy in an Orang-Utan (*Pongopygmaeus*). *Vet Rec* 91, 334-337.
- Hoenig M, Mahaffey MB, Parnell PG, Styles ME (1990) Megaesophagus in two cats. *J Am Vet Med Assoc* 196, 763-765.
- Huang CH, Jeng CR, Lin CT and Yeh LS (2010) Feline hypertrophic osteopathy: a collection of seven cases in Taiwan. *J Am Anim Hosp Assoc* 46, 346-352.
- Johnson R and Lenz S (2011) Hypertrophic Osteopathy Associated with a Renal Adenoma in a Cat. *J Vet Diagn Invest* 23, 171-175.
- Langley-Hobbs S (2012) Musculoskeletal oddities in the cat. An overview of some curious causes of lameness. *J Feline Med Surg* 14, 31-42.
- Mair TS, Dyson SJ, Fraser JA, Edwards GB, Hillyer MH and Love S (1996) Hypertrophic osteopathy (Marie's disease) in Equidae: a review of twenty-four cases. *Equine Vet J* 28, 256-262.
- Masegi T, Yani T, Sakai T, Matsumoto C, Yamazoe K, Nukaya A, Kunimune Y and Ueda K (1994) Hypertrophic pulmonary osteoarthropathy in a raccoon dog (*Nyctereutes procyonoides*) with chronic pulmonary inflammatory lesions. *J Wildl Dis* 30, 612-615.
- Mills J (2010) Hypertrophic osteopathy and megaesophagus in a cat. *Vet Comp Orthop and Traum* 23, 218-222.
- Nafe LA, Herron AJ and Burk RL (1981) Hypertrophic osteopathy in a cat associated with renal papillary adenoma. *J Am Anim Hosp Assoc* 17, 659-662.
- Ndikuwere J and Hill FWG (1989) Hypertrophic osteopathy in a dog associated with bronchopneumonia. *Zimbabwe Vet J* 20, 23-27.
- Ocarino M, Fukushima MB, Gomes AM, Bueno DF, Oliveira TS, Serakides R (2006) Idiopathic hypertrophic osteopathy in a cat. *J Feline Med Surg* 8, 345-348.
- Richards CD (1977) Hypertrophic osteopathy in a cat. *Feline Pract* 7, 41-43.
- Roberg J (1977) Hypertrophic Pulmonary Osteoarthropathy. *Feline Pract* 7, 18-22.
- Rohr S (2003) Pulmonary origin feline hypertrophic osteopathy. *Point Vet* 34, 62-64.
- Salgüero R, Demetriou J, Constantino-Casas F and Herrtage M (2015) Hypertrophic osteopathy in a cat with a concurrent injection-site sarcoma. *J Feline Med Surg Open Rep* 1: 2055116915593968.