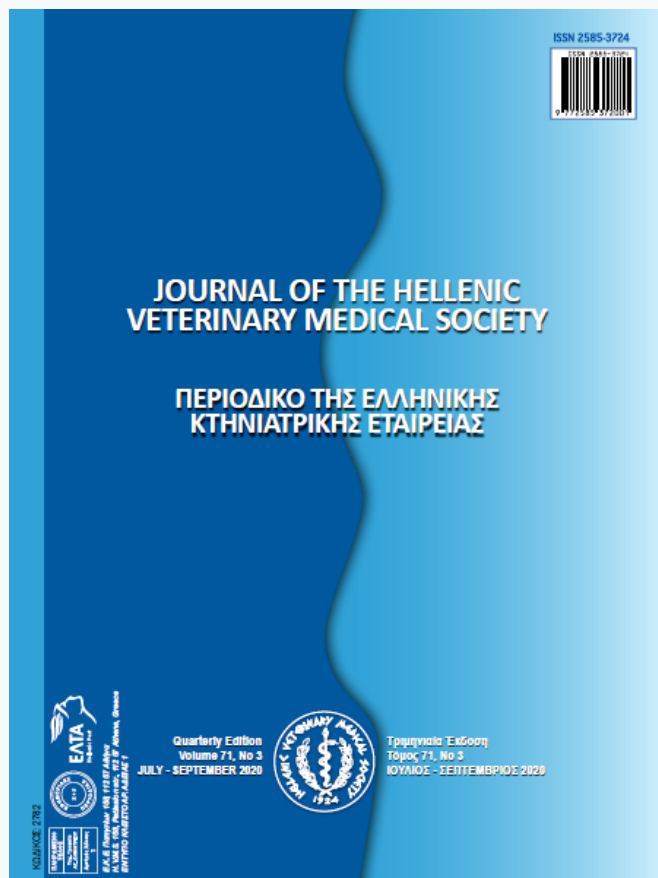

Journal of the Hellenic Veterinary Medical Society

Vol 71, No 3 (2020)



Whole issue

Ελληνική Κτηνιατρική Εταιρεία

doi: [10.12681/jhvms.25161](https://doi.org/10.12681/jhvms.25161)

Copyright © 2020, Ελληνική Κτηνιατρική Εταιρεία



This work is licensed under a [Creative Commons Attribution-NonCommercial 4.0](https://creativecommons.org/licenses/by-nc/4.0/).

To cite this article:

Εταιρεία Ε. Κ. (2020). Whole issue. *Journal of the Hellenic Veterinary Medical Society*, 71(3), 2243–2418.
<https://doi.org/10.12681/jhvms.25161>



JOURNAL OF THE HELLENIC VETERINARY MEDICAL SOCIETY

ΠΕΡΙΟΔΙΚΟ ΤΗΣ ΕΛΛΗΝΙΚΗΣ ΚΤΗΝΙΑΤΡΙΚΗΣ ΕΤΑΙΡΕΙΑΣ



Ε.Κ.Ε. Πατησίων 158, 112 57 Αθήνα
H.V.M.S. 158, Patission str., 112 57 Athens, Greece
ΕΝΤΥΠΟ ΚΛΕΙΣΤΟ ΑΡ. ΑΔΕΙΑΣ 1

Quarterly Edition
Volume 71, No 3
JULY - SEPTEMBER 2020



Τριμηνιαία Έκδοση
Τόμος 71, Νο 3
ΙΟΥΛΙΟΣ - ΣΕΠΤΕΜΒΡΙΟΣ 2020

JOURNAL OF THE HELLENIC VETERINARY MEDICAL SOCIETY

ΠΕΡΙΟΔΙΚΟ ΤΗΣ ΕΛΛΗΝΙΚΗΣ ΚΤΗΝΙΑΤΡΙΚΗΣ ΕΤΑΙΡΕΙΑΣ

CODE: 2782



Quarterly Scientific Journal
6th Period, Volume 71, Issue no.3
JULY - SEPTEMBER 2020

Τριμηνιαίο Επιστημονικό Περιοδικό
Περίοδος ΣΤ', Τόμος 71, Νο.3
ΙΟΥΛΙΟΣ - ΣΕΠΤΕΜΒΡΙΟΣ 2020

ΚΩΔΙΚΟΣ: 2782



J Hellenic Vet Med Soc is covered by THOMSON REUTERS
Science Citation Index Expanded & Journal Citation Reports/Science Edition
ISSN 2585-3724

Publisher

Hellenic Veterinary Medical Society
Patission 158, 11257 Athens, Greece
Tel.: +30.210.8642284
Fax: +30.210.8645744
www.hvms.gr
E-mail: secretary@hvms.gr

Εκδότης

Ελληνική Κτηνιατρική Εταιρεία
Πατισίων 158, 11257 Αθήνα
Tel.: 210.8642284
Fax: 210.8645744
www.hvms.gr
E-mail: secretary@hvms.gr

Executive board of the HVMS

President: M. Linou
Vice-President: Z. Polizopoulou
Hon. Secretary: K. Chandras
Dep. Hon. Secretary: N. Solomakos
Treasurer: D. Vourvidis
Member: N. Papaioannou
Member: S. Vlachopoulos
Member: E. Papadopoulos
Member: G. Fthenakis

Διοικητικό Συμβούλιο ΕΚΕ

Πρόεδρος: Μ. Λινού
Αντιπρόεδρος: Ζ. Πολιζοπούλου
Γεν. Γραμματέας: Κ. Χανδράς
Ειδ. Γραμματέας: Ν. Σολωμάκος
Ταμίας: Δ. Βουρβίδης
Μέλος: Ν. Παπαϊωάννου
Μέλος: Σ. Βλάχοπουλος
Μέλος: Η. Παπαδόπουλος
Μέλος: Γ. Φθενάκης

Managing editors

Z. Polizopoulou
A. Tyrpenou
Patission 158, 11257 Athens, Greece
Tel.: +30.210.8642284
Fax: +30.210.8645744

Υπεύθυνοι έκδοσης

Z. Πολιζοπούλου
Α. Τυρπένου
Πατισίων 158, 11257 Αθήνα.
Tel.: 210.8642284
Fax: 210.8645744

Editorial Board

G. Arsenos, V. Bampidis, I. Dontas, D. Fletouris,
A. Galatos, N. Giadinis, E. Kiossis, A. Lymberopoulos,
L. Papazoglou, M. Saridomichelakis, N. Soultos,
N. Solomakos, P. Fortomaris, Th. Tsiligianni

Συντακτική Επιτροπή

Γ. Αρσένος, Α. Γαλάτος, Ν. Γιαδίνης, Ι. Δοντά, Ε. Κιόσσης,
Α. Λυμπερόπουλος, Β. Μπαμπίδης, Λ. Παπάζογλου,
Μ. Σαριδομιχελάκης, Ν. Σούλτος, Ν. Σολωμάκος,
Δ. Φητούρης, Π. Φορτομάρης, Θ. Τσιλιγιάννη

Redaction

Rotonda Publications
8 Kamvounion Str, 54621
Thessaloniki, Greece
Tel: +30210212212

Επιμέλεια έκδοσης

Εκδόσεις Ροτόντα
Καμβουνίων 8, 54621
Θεσσαλονίκη
Τηλ: 2310212212

Annual subscription

Europe: € 150
Other countries: € 180
Price per issue: € 50

Ετήσιες συνδρομές

Ελλάδα και Κύπρος
Μέλη ΕΚΕ: € 30
Μη μέλη ΕΚΕ: € 40
Φοιτητές: € 15
Νομικά πρόσωπα: € 100
Τιμή τεύχους: € 15

Cheques and remittances

D. Vourvidis
P.O. Box 3546, 10210 Athens, Greece

Επιταγές και εμβάσματα

Δ. Βουρβίδης
Τ.Θ. 3546, 10210 Αθήνα


Mailing address

J Hellenic Vet Med Soc (M. Zafiropoulou)
Hellenic Veterinary Medical Society
Patission 158, 11257 Athens, Greece

Ταχυδρομική διεύθυνση

ΠΕΚΕ (Μ. Ζαφειροπούλου)
Ελληνική Κτηνιατρική Εταιρεία
Πατισίων 158, 11257 Αθήνα

**EUROPEAN COLLEGES OF VETERINARY SPECIALISTS
ΕΥΡΩΠΑΪΚΑ ΚΟΛΕΓΙΑ ΕΙΔΙΚΕΥΜΕΝΩΝ ΚΤΗΝΙΑΤΡΩΝ**

				Number of specialist veterinarians active in Greece Αριθμός ειδικευμένων κτηνιάτρων εργαζόμενων στην Ελλάδα
1		ECAR	European College of Animal Reproduction	2
2		ECAWBM	European College of Animal Welfare and Behavioural Medicine	2
3		ECAAH	European College of Aquatic Animal Health	3
4		ECBHM	European College of Bovine Health Management	3
5		ECEIM	European College of Equine Internal Medicine	0
6		ECLAM	European College of Laboratory Animal Medicine	0
7		ECPHM	European College of Porcine Health Management	3
8		EPVS	European College of Poultry Veterinary Science	4
9		ECSRHM	European College of Small Ruminant Health Management	12
10		ECVAA	European College of Veterinary Anaesthesia and Analgesia	1
11		ECVCN	European College of Veterinary Comparative Nutrition	0
12		ECVCP	European College of Veterinary Clinical Pathology	1
13		ECVD	European College of Veterinary Dermatology	3
14		ECVDI	European College of Veterinary Diagnostic Imaging	2
15		ECVECC	European College of Veterinary Emergency and Critical Care	0
16		ECVIM-ca	European College of Veterinary Internal Medicine-companion animals	0
17		ECVN	European College of Veterinary Neurology	2
18		ECVO	European College of Veterinary Ophthalmology	0
19		ECVP	European College of Veterinary Pathology	0
20		ECVPH	European College of Veterinary Public Health	5
21		ECVPT	European College of Veterinary Pharmacology and Toxicology	1
22		ECZM	European College of Zoological Medicine	1
23		ECVS	European College of Veterinary Surgery	1
24		EVDC	European Veterinary Dentistry College	0
25		EVPC	European Veterinary Parasitology College	3

JOURNAL OF THE HELLENIC VETERINARY MEDICAL SOCIETY

ΠΕΡΙΟΔΙΚΟ ΤΗΣ ΕΛΛΗΝΙΚΗΣ ΚΤΗΝΙΑΤΡΙΚΗΣ ΕΤΑΙΡΕΙΑΣ



ΕΛΛΗΝΙΚΗ ΚΤΗΝΙΑΤΡΙΚΗ ΕΤΑΙΡΕΙΑ (ΕΚΕ)
HELLENIC VETERINARY MEDICAL SOCIETY (HVMS)



REPRESENTATIONS / ΕΚΠΡΟΣΩΠΗΣΕΙΣ

Organisation / Οργανισμός	Representative / Εκπρόσωπος	Alternative representatives (alphabetically) / Αναπληρωτές εκπρόσωποι (με αλφαβητική σειρά)
World Veterinary Association (WVA)	N. Papaioannou	S. Ramantanis
International Sheep Veterinary Association (ISVA)	G.C. Fthenakis	G. Arsenos, V.S. Mavrogianni
World Association for Buiatrics (WAB)	G.C. Fthenakis	G.S. Amiridis, N. Panousis
World Small Animal Veterinary Association (WSAVA)	Z. Polizopoulou	C. Chandras
European Federation of Food Science and Technology (EFFOST)	S. Ramantanis	D.J. Fletouris, A. Govaris
Federation of European Companion Animal Veterinary Association (FECAVA)	Z. Polizopoulou	M. Flarakos, A. Michopoulos
Balkan and Black Sea Veterinary Association (BABSEVA)	K. Marinou	M. Linou
Ελληνική Ζωοτεχνική Εταιρεία (ΕΖΕ)	G. Arsenos	J. Menegatos
International Association of Veterinary Editors (IAVE)	A. Tyrpenou	Z. Polizopoulou



Contents

Περιεχόμενα

REVIEW ARTICLE

A Review on Rabbit Hemorrhagic Disease with a Special Reference to Egyptian Situation

Wafaa A. Abd El-Ghany

2243

RESEARCH ARTICLES

Surgical Management of Orbital Abscesses in Domestic Rabbits (*Oryctolagus cuniculus*): A report of seven cases

A.L.N. Thomas, G.M. Kazakos, D. Pardali, M.N. Patsikas, A.Th. Komnenou

2251

Blood Metabolic Profile in Barki Ewes during Transition Period

A. El-Sayed, M. El-Ashker, H. Ibrahim, S. Shoieb, F. Ibrahim, M. Youssef, S. El-Khodery

2261

***In vitro* anticoccidial activity of *Vitis vinifera* extract on oocysts of different *Eimeria* species of Broiler Chicken**

R.Z. Abbas, A. Abbas, Z. Iqbal, M.A. Raza, K. Hussain, T. Ahmed, M.U. Shafi

2267

Comparative efficacy of Amprolium, Garlic oil (*Allium sativum*) and Ginger oil (*Zingiber officinale*) against Coccidiosis in common quail (*Coturnix coturnix*)

M. Asghar, U.F. Durrani, R. Hussain, K. Matloob, A.K. Mahmood, M. Anees, M. Oneeb

2273

First isolation of *Mycobacterium bovis* SIT 482 BOV from beef cattle in Turkey

M. L. Avsever, C. Çavuşoğlu, İ. Çamkerten

2279

Association of herd management with the infestation of ticks in domestic goats

M.S. Sajid, H.M. Rizwan, M.K. Khan, A. Qudoos, F.A. Atif, M.A. Malik, M. Maqbool

2283

Determination of the ciprofloxacin-resistant *Escherichia coli* isolated from chicken meat in Turkey

S. Sahin

2291

ΑΝΑΣΚΟΠΗΣΗ

A Review on Rabbit Hemorrhagic Disease with a Special Reference to Egyptian Situation

Wafaa A. Abd El-Ghany

ΕΡΕΥΝΗΤΙΚΑ ΑΡΘΡΑ

Surgical Management of Orbital Abscesses in Domestic Rabbits (*Oryctolagus cuniculus*): A report of seven cases

A.L.N. Thomas, G.M. Kazakos, D. Pardali, M.N. Patsikas, A.Th. Komnenou

Blood Metabolic Profile in Barki Ewes during Transition Period

A. El-Sayed, M. El-Ashker, H. Ibrahim, S. Shoieb, F. Ibrahim, M. Youssef, S. El-Khodery

***In vitro* anticoccidial activity of *Vitis vinifera* extract on oocysts of different *Eimeria* species of Broiler Chicken**

R.Z. Abbas, A. Abbas, Z. Iqbal, M.A. Raza, K. Hussain, T. Ahmed, M.U. Shafi

Comparative efficacy of Amprolium, Garlic oil (*Allium sativum*) and Ginger oil (*Zingiber officinale*) against Coccidiosis in common quail (*Coturnix coturnix*)

M. Asghar, U.F. Durrani, R. Hussain, K. Matloob, A.K. Mahmood, M. Anees, M. Oneeb

First isolation of *Mycobacterium bovis* SIT 482 BOV from beef cattle in Turkey

M. L. Avsever, C. Çavuşoğlu, İ. Çamkerten

Association of herd management with the infestation of ticks in domestic goats

M.S. Sajid, H.M. Rizwan, M.K. Khan, A. Qudoos, F.A. Atif, M.A. Malik, M. Maqbool

Determination of the ciprofloxacin-resistant *Escherichia coli* isolated from chicken meat in Turkey

S. Sahin



Contents

Περιεχόμενα

- | | | |
|--|-------------|--|
| Concurrent occurrence of <i>Anaplasma phagocytophilum</i> and <i>A. marginale</i> in bovine peripheral blood samples from southwest of Iran
S. Bahrami, H. Hamidinejat,
M.R. Haji Hajikolaie, S. Kavianifar | 2301 | Concurrent occurrence of <i>Anaplasma phagocytophilum</i> and <i>A. marginale</i> in bovine peripheral blood samples from southwest of Iran
S. Bahrami, H. Hamidinejat,
M.R. Haji Hajikolaie, S. Kavianifar |
| First occurrences of <i>Nerocila bivittata</i> on Dusky Grouper (<i>Ephinephelus marginatus</i>) and Mottled Grouper (<i>Mycteroperca rubra</i>)
S. Y. Çelik, J. Korun, M. Gökoğlu | 2309 | First occurrences of <i>Nerocila bivittata</i> on Dusky Grouper (<i>Ephinephelus marginatus</i>) and Mottled Grouper (<i>Mycteroperca rubra</i>)
S. Y. Çelik, J. Korun, M. Gökoğlu |
| Effect of N-acetyl cysteine on the quality of blastocyst formation rate using cultured vitrified murine embryos
S. Sigüenza, I.S. Álvarez, E. Matilla | 2315 | Effect of N-acetyl cysteine on the quality of blastocyst formation rate using cultured vitrified murine embryos
S. Sigüenza, I.S. Álvarez, E. Matilla |
| Apoptotic Cell Death in Ewe Endometrium during the Oestrous Cycle
S. Benbia, Y. Belkhir, M. Yahia | 2323 | Apoptotic Cell Death in Ewe Endometrium during the Oestrous Cycle
S. Benbia, Y. Belkhir, M. Yahia |
| Effect of iron oxide and silver nanoparticles on boar semen CASA motility and kinetics
A. Basioura, I. Michos, A. Ntemka,
I. Karagiannis, C.M. Boscos* | 2331 | Effect of iron oxide and silver nanoparticles on boar semen CASA motility and kinetics
A. Basioura, I. Michos, A. Ntemka,
I. Karagiannis, C.M. Boscos* |
| Biochemical composition and biometric parameters of <i>Mytilus galloprovincialis</i> from Boka Kotorska Bay in Southern Adriatic Sea
N. Grković, V. Teodorović, V. Djordjević, N. Karabasil,
S. Stajković, D. Vasilev, I. Zuber Bogdanović,
S. Janković, B. Velebit, M. Dimitrijević | 2338 | Biochemical composition and biometric parameters of <i>Mytilus galloprovincialis</i> from Boka Kotorska Bay in Southern Adriatic Sea
N. Grković, V. Teodorović, V. Djordjević, N. Karabasil,
S. Stajković, D. Vasilev, I. Zuber Bogdanović,
S. Janković, B. Velebit, M. Dimitrijević |
| Effect of trans-resveratrol or ubiquinol supplementation on the sperm morphology of CD-1 mice subjected to forced swimming
D. Vaamonde, A. Sánchez de Medina,
B. Cortés, A. Díaz, I. Rodríguez | 2349 | Effect of trans-resveratrol or ubiquinol supplementation on the sperm morphology of CD-1 mice subjected to forced swimming
D. Vaamonde, A. Sánchez de Medina,
B. Cortés, A. Díaz, I. Rodríguez |
| Neosporosis and toxoplasmosis are two prevalent and important protozooses in dairy cows in small farms from Thessaly, Central Greece
M. Lefkaditis, G. Evagelopoulou,
A. Sossidou, K. Spanoudis | 2357 | Neosporosis and toxoplasmosis are two prevalent and important protozooses in dairy cows in small farms from Thessaly, Central Greece
M. Lefkaditis, G. Evagelopoulou,
A. Sossidou, K. Spanoudis |



Contents

Περιεχόμενα

Effect of Purslane powder and Zinc supplementation on the performance, egg quality, antioxidant system and liver histopathology of lead-exposed laying Quails
S. Faryadi, A. Sheikhamadi, A. Sadeghi

Molecular prevalence of *Toxoplasma gondii* in sheep from Isfahan, Iran as detected in heart samples by loop-mediated isothermal amplification (LAMP)
H. Raieszadeh, V. Noaman, G. Razmi, A. Jamshidi

Seroprevalence of *Coxiella burnetii* among ewes and associated risk factors in Constantine (Northeastern Algeria)
S. Hireche, A. Agabou, O. Bouaziz

Effect of glauconite, sepiolite and oil supplementation on pellet quality parameters in poultry compound feed
G. Yıldız, Ö. Durna Aydın

CASE REPORTS

Squamous Cell Carcinoma (SCC) in Brown meagre (*Sciaena umbra* Linnaeus, 1758), a new candidate species for aquaculture in Mediterranean
M.N. Kolygas, E. Lampou, D. Doukas, D. Tontis, I. S. Pappas, E. Gourzioti, V. Bakopoulos, E. Kakava, F. Athanassopoulou

Malignant fibrous histiocytoma in a budgerigar (*Melopsittacus undulatus*)
H. Özen, S. Dağ, E. Karakurt, E. Büyük

Feline Hypertrophic Osteopathy Associated with Congenital Megaesophagus: Two Case Reports and Literature Review
A.M. Abu-Seida, F.A. Torad, E.A. Hassan, K.M. Ali

2363 Effect of Purslane powder and Zinc supplementation on the performance, egg quality, antioxidant system and liver histopathology of lead-exposed laying Quails
S. Faryadi, A. Sheikhamadi, A. Sadeghi

2375 Molecular prevalence of *Toxoplasma gondii* in sheep from Isfahan, Iran as detected in heart samples by loop-mediated isothermal amplification (LAMP)
H. Raieszadeh, V. Noaman, G. Razmi, A. Jamshidi

2383 Seroprevalence of *Coxiella burnetii* among ewes and associated risk factors in Constantine (Northeastern Algeria)
S. Hireche, A. Agabou, O. Bouaziz

2391 Effect of glauconite, sepiolite and oil supplementation on pellet quality parameters in poultry compound feed
G. Yıldız, Ö. Durna Aydın

ΚΛΙΝΙΚΑ ΠΕΡΙΣΤΑΤΙΚΑ

2399 Squamous Cell Carcinoma (SCC) in Brown meagre (*Sciaena umbra* Linnaeus, 1758), a new candidate species for aquaculture in Mediterranean
M.N. Kolygas, E. Lampou, D. Doukas, D. Tontis, I. S. Pappas, E. Gourzioti, V. Bakopoulos, E. Kakava, F. Athanassopoulou

2407 Malignant fibrous histiocytoma in a budgerigar (*Melopsittacus undulatus*)
H. Özen, S. Dağ, E. Karakurt, E. Büyük

2413 Feline Hypertrophic Osteopathy Associated with Congenital Megaesophagus: Two Case Reports and Literature Review
A.M. Abu-Seida, F.A. Torad, E.A. Hassan, K.M. Ali



History of the Hellenic Veterinary Medical Society

The Hellenic Veterinary Medical Society (HVMS) is one of the oldest Scientific Societies in our Country. It was founded in 1924 and its first scientific journal was published in 1926. Prompter, Founder and Animating Spirit of HVMS was the General Ioannis D. Petridis (1870-1947), first President and for many years Honorary President of the HVMS. Among the 49 founding members of the HVMS there was also the memorable professor Konstantinos Livadas, the founder of the Veterinary School of the Aristotelian University in Thessaloniki. In spite of the disagreements, the HVMS contributed greatly to the foundation of Veterinary School.

During that time there was only one Scientific Society in Greece, the Medical Society of Athens, which was founded in 1835 and published its first scientific journal in 1922. The HVMS dealt not only with scientific but also with professional topics, like the establishment of the invoices for the veterinarians' payment, taxes, insurance etc. Also, at that period, the accession of the Veterinary Branch in the Hygienists' Pension and Self Insurance Treasury (TSAY) was achieved.

The first post-war assembly of the HVMS took place in the private medical office of Petros Kiappe, on Peta Street in Athens. With its post-war first president Konstantinos Melanidis, the HVMS has been working by implementing its old memorandum of association and has been located in the premises of the Veterinary Microbiological Institute of Votanicos, from where all members of the Governing Board and the Editorial Board of the Journal of the HVMS, were coming from. There, the first «nucleus» of the Library of the HVMS, has been created. That is the reason, this second period of the HVMS successor of the «Petridis period», used to be called «Votanikos period, 1944-1965».

Because HVMS's income was very small, it will remain homeless for many years. Looking for a meeting place the HVMS will find positive response from several services and societies (State Veterinary Offices, Greek Chemical Society, Hellenic Agricultural Society, Medical Society of Athens, Institute of Agricultural Studies, State Veterinary Service of Athens, National Organization of Greek Handwork), which during the following years are going to offer its premises, while in the mid 1958 and for a short period, depending on its financing capabilities, the HVMS will rent its own room.

In 1944, the HVMS writes down its first post-war Member Book and in 1948 has already acquired its first 74 regular members. Also, HVMS is actively working with scientific subjects during regular meetings and public seminars, analyzing current veterinary issues, members' proposals and so on. On 29th May 1947 Mr Petridis presented in the Academy of Athens an issue for veterinary science and its contribution to the progress of the agricultural production and safeguard of Public Health. Also, it should be pointed out, that because there was no professional body, the HVMS is also dealing with issues related to the execution of the veterinary profession.

Furthermore, the role of the HVMS has been determinative on the decision making of the Ministry of Agriculture on veterinary legislation, on the organization of the Veterinary Service in the Ministry of Agriculture as well as on livestock topics. In the decade of 30s the Supreme Veterinary Advisory

Council was created mainly dealing with scientific issues and other aims like promotion, publicity and consolidation of the veterinary science and the veterinary profession in our country and internationally.

The Hellenic Veterinary Medical Society publishes a quarterly scientific journal called Journal of the Hellenic Veterinary Medical Society (J Hellenic Vet Med Soc), as well as other scientific publications, organizes Congresses, Symposiums, Meetings, Lectures etc and generally and almost exclusively it has undertaken for life the Continuing Education of the Greek veterinarians and the students of the two Veterinary Schools.

Nowadays, the Hellenic Veterinary Medical Society is governed by a 9 member Governing Board which is elected every 3 years and has 3 branches:

- **Branch of Companion Animals**
- **Branch of Food Hygiene and Public Health**
- **Branch for Farm Animals**

The HVMS collaborates with the Supreme Educational Foundations, the Technological Educational Institutes, the Veterinary Services, and the Veterinary Associations as well as with Scientific Societies and the Greek and Foreign Chambers.

- **The HVMS is member of the:**
- **Worldwide Veterinary Society**
- **Worldwide Veterinary Society for Companion Animals**
- **Federation of European Veterinary Societies for Companion Animals (founding member)**
- **Veterinary Society of the Balkan and the Black Sea (founding member)**

The HVMS has a total of 1220 members many of which have been distinguished in the scientific field (University Professors, Researchers), in the Public Administration, in the Army as well as in the Professional Veterinary Societies and Chambers, in Greece and abroad.

Since 29 May 2001, having signed the contract and since 15 December 2002 the date on which the official opening celebration took place, the Hellenic Veterinary Medical Society is housed in its private premises in a beautiful and majestic one-floor apartment, on the 7th floor of a building in the centre of Athens at 158, Patission street, of 265m² area, including main lobby (14m²), secretary (13m²), lecture room (91m²), the President's office (22m²), the Governing Board meeting room & library (44m²), the kitchen (18m²), two big baths, a storage room and a large veranda. All the actions performed for possessing this new private office for the HVMS were performed during the presidency of Dr Theodoros Cl. Ananiadis and the following Governing Board:

President:	Theodoros Cl. Ananiadis†
Vice-President:	Veniamin Albalas
General Secretary:	Athanassios E. Tyrpenou
Spec. Secretary:	Konstantinos Chandras
Treasurer:	Olga Sabatakou
Member:	Emmanuel Archontakis
Member:	Apostolos Rantsios

A Review on Rabbit Hemorrhagic Disease with a Special Reference to Egyptian Situation

Wafaa A. Abd El-Ghany

Poultry Diseases Department, Faculty of Veterinary Medicine, Cairo University, 12211 Giza, Egypt,

ABSTRACT: Rabbit hemorrhagic disease (RHD) is considered as one of the most important viral diseases that affects and threatens rabbit's flocks. This disease has affected rabbits since mid-1980. Two epidemics of RHD had been discovered; the first was in mid-1980 and known as classical RHD virus (RHDV), while the second was in 2011 and described as variant virus (RHDVb/RHDV2). Domestic and wild rabbits are susceptible to RHD. All ages can be affected, but adults are more susceptible to young kitten. RHD is presented in three forms; per-acute, acute and sub-acute or chronic form. Mortality rate is usually high especially in per-acute and acute stages and it is associated with disseminated intravascular coagulopathy and necrotic hepatitis. The main lesions have been observed in the liver, lungs and spleen. Diagnosis of RHD is based on the clinical picture and detection of RHDV or specific antibodies. The prevention and control strategies depend mainly on using of preventive inactivated vaccine together with adoption of hygienic measures. However, there is no specific treatment of RHDV infection. So, this review article puts a spot light on RHD regarding the epidemiology, the clinical and laboratory diagnosis as well as the prevention and control strategies with a special reference to Egyptian situation.

Keywords: RHD, Epidemiology, Diagnosis, Control, Egypt

Corresponding Author:
Wafaa A. Abd El-Ghany
Poultry Diseases Department, Faculty of Veterinary Medicine, Cairo University,
12211 Giza, Egypt
E-mail address: wafaa.ghany@yahoo.com

Date of initial submission: 17-07-2020
Date of revised submission: 28-07-2020
Date of acceptance: 10-09-2020

INTRODUCTION

Egypt is considered as the fourth largest country that produce rabbit meat worldwide (FAO, 2019). Egyptians prefer rabbit's meat for its great benefits and for the characteristics of carcass traits (Albogh-dady and Alashry, 2010). An improvement of rabbit industry is a goal to solve the shortage of meat after poultry industry.

Rabbits are highly susceptible to many serious diseases problems that have adverse effects on rabbits industry in Egypt (Hamed et al., 2013). One of these diseases is rabbit hemorrhagic disease (RHD) which has been considered as fetal, highly contagious, and world-wide viral disease. This disease was also previously named as rabbit viral sudden death, hemorrhagic septicemia syndrome, viral hemorrhagic pneumonia and rabbit viral hemorrhagic disease (Mitro and Krauss, 1993). RHD induces great and significant economic importance in terms of high mortality and morbidity as well as great losses in meat and fur production of Egypt (Mohamed, 2009; Fahmy et al., 2010). RHD is notifiable as authorities should be immediately reported in case of outbreaks (OIE, 2018). RHD is caused by RHD virus (RHDV) which is belonging to Calicivirus family and *Lagovirus* genus. There is only one serotype for all classical pathogenic strains of RHDV, however, two subtypes, RHDV and RHDVa, have been found (CFSPH, 2006). In 2011, other variant virus (RHDVb/RHDV2) have also been recorded. Acute RHD infection is characterized by sudden respiratory and nervous manifestations as well as by high mortality due to disseminated intravascular coagulopathy. There is no specific treatment, however, prevention of RHD is based mainly on using of vaccines as well as adoption of hygienic measures (ITAVI, 2019).

Serious studies have been conducted in Egypt to update the epidemiological situation of RHD among rabbit farms (Awad and Kotb, 2018; Magouzi et al., 2019; Erfan and Shalaby, 2020) and to spotlight on vaccine production trials (Abd El-Motelib et al. 1998; Khodeir and Daoud, 2002; Eid and Ibraheem, 2006).

Thus, this article review focuses on rabbit hemorrhagic disease regarding the epidemiology, the clinical and laboratory diagnosis as well as the prevention and control strategies with a special reference to Egyptian situation.

HISTORY AND INCIDENCE

The first clinical report of RHD was in 1980s in China where the disease killed 14 million of European Angora rabbits within 9 months (Liu et al., 1984). A year later in China, Xu (1991) recorded death of 140 million domestic rabbits due to RHD. Later, the disease showed rapid spread to Italy (Cancellotti and Renzi, 1991) and became endemic in several European, Australian, New Zealand, Asian and African countries (Berninger and House, 1995; Kovalisk, 1998; Le Gall-Recule et al., 2003; Alda et al., 2010; Abrantes et al., 2012).

The first record of RHDV in Egypt was in spring of 1991, in El-Sharkia governorate, where the virus was associated with 90% mortality rate (Ghanem and Ismail, 1992). Later, RHD was recorded in El-Kalubia governorate (Sharawi, 1992). Salem and El-Ballal (1992) detected presence of RHDV in Upper Egypt (Assiut) governorate in winter of 1992. In 1993, RHDV was isolated from 14-16 week-old rabbits with 26.7%-100% losses in El-Minya, Assiut and Sohag governorates (El-Zanaty, 1994). Since this time, subsequent disease outbreaks have been recorded in different Egyptian governorates. During the period from 1994 to 1996, about 25 outbreaks of circulating RHDV were demonstrated in Cairo, Giza, El-Kalubia, Kafr-El-Sheikh, El-Dakahlia, El-Gharbia and Marsa-Matroh governorates (El-Mongy, 1998). Both RHDV and *Pasteurella multocida* (*P. multocida*) had been found in three cases of rabbits in Alexandria governorate (Ibrahim et al., 1999). In 2000, in Assuit governorate, clinical picture of epistaxis, incoordination of the gait, convulsion and vaginal bloody exudate were observed in rabbit flocks with RHDV (Abd El-Ghafar et al., 2000). Although presence of restricted regimen program for vaccination of Egyptian rabbit flocks against RHDV, several outbreaks of the disease were reported (Mostafa, 2001; Abd El-Lateff, 2006; Ewees, 2007; El-Sissi and Gafer, 2008). At Kafr El-Sheikh governorate, 15 outbreaks of vaccinated rabbit flocks with signs and lesions similar to that of RHDV were investigated (Metwally and Madbouly, 2005). Recently, the nucleotide sequencing of viral protein (VP60) gene of RHDV was characterized from outbreaks of non-vaccinated rabbit flocks in different Egyptian governorates (Awad and Kotb, 2018; Magouzi et al., 2019; Erfan and Shalaby, 2020).

Infection and transmission

Infection by RHDV occurs mostly through oral, nasal, and conjunctival routes. The specific receptors of the virus are mainly found in the upper respira-

tory and digestive tract of susceptible animal (Ruvoen-Clouet et al., 2000). Transmission of RHDV is usually happen through faecal-oral route (Morisse et al., 1991). Close contact animals may gain the virus through aerosol (Campagnolo et al., 2003). Direct and indirect contact with the excreta of infected and dead animals are also possible routes of disease transmission (Ohlinger et al., 1993). The virus remains viable for long periods in urine, feces and respiratory secretions (Ohlinger et al., 1993) as well as fur (Mitro and Krauss, 1993). The viral RNA of RHDV may persist in the environment for 15 weeks, and the recovered animal can shed the virus for months. Contaminated bedding with urine and feces of infected animals may also be considered as a source of RHDV (Cooke, 2002). Furthermore, it has been found that RHDV can remain viable and infective on decomposed or dead carcass for 12 weeks under harsh environmental conditions (McColl et al., 2002). The lengthy persistence of infective RHDV on dead animals may help the disease spread and outbreaks in the wild (Henning et al., 2005). The virus can be excreted in the feces of predators or scavengers that fed on dead infected carcass (Merchán yet al., 2011).

Chilled and frozen rabbit carcasses can carry RHDV for several months. An outbreak of RHDV in Mixco has been reported due to imported infected carcasses from China (Belz, 2004). Due to high stability of the RHDV and resistance to environmental condition, the virus can spread via fomites and contaminated food, water, clothes, cages, and equipment (Chasey, 1997).

In addition, insects or flies may play a role in transmission of infection as the virus can persist in flies for 9 days (Asgari et al., 1998; OIE, 2008). Rodents (Broja and Larios 1990; Xu, 1991), while wild animals (Cooke, 2002) are also very important mechanical vectors of RHDV. Workers in contact with RHDV infected rabbits or with their excretions act also as mechanical vectors (CFSPH, 2006).

Susceptibility and clinical disease picture

Domestic (especially European species; *Oryctolagus Cuniculus*) and wild rabbits are susceptible to RHD (Gould et al., 1997; Muller et al., 2009; Miao et al., 2019; Urakova et al., 2019). Infection of hares with variant strain of RHDV (European brown hare syndrome virus) has been recorded. However, susceptibility of other leporid species to the virus has not been reported (Gregg et al., 1991). Pregnant and lac-

tating does are more susceptible to RHDV infection (El-Sissi and Gafer, 2008).

The susceptibility age of rabbits to RHDV is still contradicted. The virus can cause higher mortality in adults than young kittens as deaths are not common in rabbits less than 4-weeks- old. This may be related to the presence of specific receptors in adults but not in young animals (Dalton et al., 2012). Resistance to RHD infection decreases at ages 4-12 weeks.

The incubation period of RHDV varies from 16 to 48 hours and deaths appear after 2 to 3 days post infection. The disease course may last up to 30 days (CFSPH, 2006). The severity of clinical signs differs according to the breed of animal, age, immunity, geographical location, the infecting viral dose and the route of infection.

Sub-clinical infection of RHD is possible in young kittens less than 4-8 weeks old. In per-acute stage, animals in a good health conditions, die suddenly without prior clinical signs within 12 to 36 hours of the disease onset (Belz, 2004). Severe clinical manifestations were seen in adults as well as rabbits older than 40-50 days of age (Capucci et al., 1991). Acute stage of RHD in rabbits is characterized by fever, depression, anorexia, conjunctivitis, frothy bloody nasal discharge, epistaxis, vulvar hemorrhages in pregnant does, severe respiratory distress (cough and dyspnea) and finally nervous manifestations (ataxia, convulsion, opisthotonos and paralysis) (Xu and Chen, 1989; Marcato et al., 1991; Trzeciak-Ryczek et al., 2015). Clinical picture associated with variant strains of RHDV is similar to classical strains, however the mortality rate may be comparatively lower (Le Gall-Recule et al., 2013). Severe jaundice, emaciation, lethargy, constipation or diarrhea and abdominal distension followed by death within few weeks have been observed in sub-acute and chronic stages of RHD (Capucci et al., 1991; CFSPH, 2006). Animals with sub-acute infection showed mild or minor signs with resistance to RHDV re-infection due to development of specific antibodies (Patton, 1989; Mitro and Krauss, 1993).

The morbidity rate of RHDV varies from 30-100%, and the mortality rate ranges from 40-100% within a period of 2-3 days after infection (Abrantes et al., 2012). High morbidity and mortality rates have been recorded mainly in adult animals and those kept in groups (Mitro and Krauss, 1993). Deaths occur as a result of disseminated intravascular coagulopathy

resulting in extensive hemorrhages in most organs as well as due to necrotizing hepatitis (Marcato et al., 1991; Plassiart et al., 1992).

Post-mortem lesions of RHDV infection in rabbits have been represented as generalized congestion and haemorrhages (Ueda et al., 1992; Marques et al., 2010), and acute and necrotizing hepatitis (Park et al., 1995; Alonso et al., 1998; Abrantes et al., 2012). Congestion and ulceration of nasal mucosa, haemothorax, frothy exudates in trachea, haemorrhages with multiple abscesses in lungs and pneumonia, splenomegaly, subcutaneous abscesses and congestion of the brain have also been observed (Eid and Ibraheem, 2006; Lavassa and Capucci 2008; Embury-Hyatt et al., 2012). Severe lesions of RHD appeared in liver, lungs and trachea (OIE, 2010). Animals died in sub-acute stage showed catarrhal enteritis and icterus. Hamed et al. (2013) estimated that severely affected organs as liver, lungs, spleen and kidneys in RHD outbreaks are the main causes of high mortality.

Histopathological lesions of RHD cases revealed severe congested visceral organs, dilated liver sinusoids with diffuse and focal hemorrhages and inflammatory cells infiltration, severe interstitial pneumonia and hemorrhagic alveoli, glomerulonephritis with haemorrhages, hemorrhagic tracheitis with sloughed mucosal epithelium and hemorrhagic myocarditis (Ramiro-Ibáñez et al., 1999; Ferreira et al., 2006; Soliman et al., 2016). Suppression of immune response in RHD infected animals is related to severe decrease in number of B and T lymphocytes of the liver and spleen (Marques et al., 2010).

Laboratory diagnosis

The diagnosis of RHD depends mainly on the clinical picture, histopathological lesions, detection of the virus using electron microscopy, immunostaining and molecular characterization and detection of antibodies using haemagglutination (HA) inhibition test and Enzyme-Linked Immuno-Sorbent Assay (ELISA) (Lavazza and Capucci, 1996).

The first step of laboratory diagnosis of RHDV is HA test using human type "O" (Liu et al., 1984; Pu et al., 1985; OIE, 2008) or Guinea pig and sheep erythrocytes (Sahar et al., 2011). The sensitivity as well as specificity of HA test appear to be inadequate. In Egypt, since 2007, variant strains of RHDV are circulating in rabbit's flocks with typical signs, lesions and mortality rate similar to classical RHDV strains

but these variants are non-haemagglutinating (Ewees, 2007; El-Sissi and Gafer, 2008). So, the diagnosis of RHD may not depend on the HA characters of RHDV as some variant strains showed changeable HA as negative HA strains have been turned into positive ones when passaged in susceptible rabbits (Abd El-Moaty et al., 2014).

RHD virus is ether and chloroform resistant due to lacking of the fatty envelope. The polypeptide of 60 KDa is enough to classify RHDV as Calicivirus (Clouet et al., 1995). The virus of RHD is non-enveloped, single-stranded ribonucleic acid (RNA) with icosahedral symmetry capsid and diameter 32-44 nm (Wang et al., 2013). The virus capsid is containing a protein (VP60), that encoded by RHDV genome contains specific antigenic epitope (hypervariable region E) (Capucci et al., 1998). The domain P of the virus is important for binding to host cells while P2 sub-domain is responsible for genetic variation (Wang et al., 2013). The virus also is a positive-sense RNA that contains extra structural proteins (sub-genomic RNA) of approximately 2.2 kb which is required for infection in later stages (Abrantes et al., 2012; Ismail et al., 2017). The genetic variation between viruses of RHD is mainly depends on the sequence of VP60 protein (Le Gall-Recule et al., 2003; Forrester et al. 2006' McIntosh et al., 2007; Forrester et al. 2008; Wang et al., 2013).

Strains of RHDV belong to one serotype but the virus has a high genetic mutation rate (Gould et al., 1997). New variant strains of RHDV were detected in vaccinated rabbits for the first time in Italy and Germany in 1998 and 1999 (Capucci et al., 1998; Schirmeier et al., 1999). The phylogenetic analysis of the strains belonging to RHDV can be classified into three groups; classical RHDV with geno-groups G1-G5, the antigenic variant RHDVa/G6 (Le Gall-Recule et al., 2003) and the new type RHDV2/RHDVb (Le Gall-Recule et al., 2013).

The liver is considered as the organ of choice for detection of RHDV where the highest virus concentration was demonstrated especially in acute or peracute disease (Abd El-Motelib, 1993; Ahmad et al., 2011). High amounts of the virus may also present in the secretions and excretions of the infected animals as well as the blood. In chronic prolonged stage of infection, the virus could be detected in spleen.

Culturing of RHDV on the tissue cultures is difficult, so detection of the viral gene or antibody are

very important for diagnosis (OIE, 2012). Reverse Transcriptase-Real Time polymerase Chain Reaction (RT-PCR) is considered as a rapid and sensitive method for characterization of specific nucleic acid of RHDV (Guittre et al., 1995; Soliman et al., 2016) as well as detection of the viral RNA in the animals's serum (Moss et al., 2002). About 98.7% homology in N-terminal part of the capsid protein which is conserved portion of RHDV has been detected by RT-PCR (Guittre et al., 1995). *In situ* hybridization or RT-Loop-Mediated Isothermal Amplification (RT-LAMP) assay also was described for detection of RHDV RNA in blood, feces and urine.

Inoculation of susceptible animals with RHDV can be used experimentally detection of the pathogenicity of the isolated strains.

Prevention and control

Management of RHD outbreaks depends on the epidemiological situation of the disease in the region and the monitoring process of the field viruses to detect any new genetic and antigenic variants (Abrantes et al., 2012).

Supplementation with hyper-immune antiserum used only for prevention of RHD and induces protection for a short time. Passively acquired immunity using hyper immune anti-serum was documented in 1993 in Egypt, where 4-months-old rabbits were inoculated intramuscularly either simultaneously with RHDV or before the virus infection. This treatment induced protection rate of 100% against RHD (Abd El Motelib, 1993). Hyper immune anti-serum may be effective only in case of absence of clinical signs of infection.

Globally, RHDV vaccines have been developed from infected animals 'tissues followed by chemical inactivation (Arguello Villares, 1991, Huang, 1991; Smid et al., 1991). They have been proved protective against variant RHDVa in domestic and wild rabbits (Capucci et al., 1998). Due to that the used vaccines have many disadvantages like variation of their efficacy according to the physiological conditions of the animal (Cabezas et al., 2006) and relatively short period of immunity which is not more than 12 months (OIE, 2010), so many modified vaccines have been developed.

The prepared RHDV vaccines may be given for animals either orally (Bertagnoli et al., 1996a; Pla-

na-Duran et al., 1996; Martin-Alonso et al., 2003; Farnos et al., 2005) or intra-nasal (Farnos et al., 2006). Moreover, bivalent vaccines against myxomatosis (Bertagnoli et al., 1996b; Barcena et al., 2000) and pasteurellosis (Peshev and Christova, 2003) have been also used.

Initial trial for production of RHDV vaccine was conducted in Egypt by Salem and El-Ballal (1992) as inactivated formalized tissue vaccine was produced. In this trial, inactivated suspensions of liver and lung of RHDV infected animals succeeded in protection of inoculated animals 7 days post-vaccination and the immunity lasted for more than 2 months. As well, Salem and El-Zanaty (1992) tried inactivated tissue derived RHDV vaccine for prevention of animals against the infection. Other trials were conducted for preparation of formalin inactivated, aluminum hydroxide adjuvanted RHDV vaccine from the Egyptian local strain (Egypt 96) (Daoud et al., 1998a) and also preparation of rabbit pasteurellosis-RHD combined vaccines (Daoud et al., 1998b). It has been showed that cell culture (Vero cell) inactivated RHDV vaccine is more potent than tissue (liver suspension) derived vaccine (Khodeir and Daoud, 2002). A bivalent RHDV and *P. multocida* lipopolysaccharides vaccine was also developed (Khodeir and Daoud, 2002). Although, there are different effective vaccination schedules for RHDV prevention, the virus is still circulating in rabbitries of Egypt (Abd El-Motelib et al., 1998; Metwally and Madbouly, 2005; Abd El-Lateff, 2006; Ewees, 2007; El-Sissi and Gafer, 2008; El-Bagoury et al., 2014). The local commercial Egyptian vaccines (IZOVAC-MEVAX) and (SVRS-Vac) that had been used for vaccination of 1.5-months old rabbits against RHDV offered 100% protection (Eid and Ibraheem, 2006). As a result of the endemic situation of the RHD among rabbits flocks in Egypt as well as early infection of young kittens (40 days old), it has been recommended starting vaccination at 1-1.5-months of age, followed by another booster dose 15 days later and then repeating the vaccination every 4-6 months (Eid and Ibraheem, 2006).

Moreover, due to inadequate application of RHD vaccine, non-hemagglutinating RHDVa variant strains are circulating in Egyptian rabbits field and infect all ages of rabbits (Ewees, 2007; El-Sissi and Gafer, 2008; Awad and Kotb, 2018). These strains were found to cause clinical disease as well as morbidity and mortality rates similar to classical RHDV, but without HA activity of the virus. Erfan and Shalaby

(2020) concluded that there are some limitations regarding the effectiveness of currently applied RHDV vaccine strains as the vaccine formulation may not cover all the circulating strains of the virus in Egypt.

Application of genetically engineered Virus Like particle (VLP) of RHDV as a therapeutic strategy for treatment of the disease have been studied (El Mehdaoui et al., 2000; Young et al., 2006; Peacey et al., 2007, 2008; Crisci et al., 2009; Win et al., 2011). The protein of the capsid accumulates in VLP that is differ from original virions and doesn't contain the viral RNA (Nagesha et al., 1995). This treatment strategy considers VLP as immunogenic antigen that stimulate both humoral and cell mediate immune responses of infected animals (Crisci et al., 2009; Win et al., 2011).

Thorough cleaning and disinfection are a requirement for RHDV prevention and control strategies. It has been found that the virus can be inactivated using disinfectants as 1-2% formalin, 1.0-1.4% formaldehyde, 0.2-0.5% beta-propiolactone, 1% sodium hypochlorite, 10% sodium hydroxide or 10 ppm chlorine dioxide (Eleraky et al., 2002).

All mechanical sources of RHDV infection should be also taken into consideration. Field rats and flies eradication program should be applied for RHD control.

In conclusion, to overcome RHD infection in any region, constant monitoring of the epidemiological status of the disease as well as updating the development of local or autogenous vaccines are crucial issues that should be thoroughly considered.

CONFLICT OF INTEREST

The author declares that there are no conflicts of interest.

REFERENCES

- Abd El-Ghaffar SK, Fatma A, Aly M, Mahmoud AZ (2000) Pathological studies on the rabbit viral hemorrhagic disease. *Assiut Vet Med J* 43: 251-274.
- Abd El-Lateff AA (2006) Clinicopathological studies on rabbit hemorrhagic disease vaccines. (Ph.D. Thesis), Fac Vet Med, Cairo Univ, Egypt.
- Abd El-Moaty DAM, El-Bagoury GF, El-Zeedy SAR, Salman OGA (2014) Egyptian non-hemagglutinating isolates of rabbit hemorrhagic disease virus can change to variable HA Profile. *Benha Vet Med J* 26: 71-83.
- Abd El-Motelib TY (1993): Role of hyperimmune serum in protection against viral hemorrhagic disease of rabbits. *Assiut Vet Med J*, 28 (56): 297-307.
- Abd El-Motelib TY, Abd El-Gawad AM, Azzaz HH (1998) Viral hemorrhagic disease of rabbit: Comparative study between the immune response of local and imported vaccine. *Assiut Vet Med J* 40 (79): 150-156.
- Abrantes J, van der Loo W, Le Pendu J, Esteves PJ (2012) Rabbit hemorrhagic disease (RHD) and rabbit hemorrhagic disease virus (RHDV): A review. *Vet Res* 43(1): 12.
- Ahmad ST, El-Samadony HA, Mahgoub KM (2011) Immunological and virological studies on rabbit hemorrhagic disease virus. *Global Vet* 7: 545-556.
- Alboghady MA, Alashry MK (2010) The demand for meat in Egypt: An almost ideal estimation. *Afr J Agric Resour Econ* 4(1): 70-81.
- Alda F, Gaitero T, Suarez M, Merchan T, Rocha G, Doadrio I (2010) Evolutionary history and molecular epidemiology of rabbit hemorrhagic disease virus in the Iberian Peninsula and Western Europe. *BMC Evol. Biol* 10(1): 347.
- Alonso C, Oviedo JM, Martin-Alonso JM, Diaz E, Boga JA, Parra F (1998) Programmed cell death in the pathogenesis of rabbit hemorrhagic disease. *Arch Virol* 143(2): 321-332.
- Arguello Villares JL (1991) Viral hemorrhagic disease of rabbits: vaccination and immune response. *Rev Sci Tech* 10: 471-480.
- Asgari S, Hardy JR, Sinclair RG, Cooke BD (1998) Field evidence for mechanical transmission of rabbit hemorrhagic disease virus (RHDV) by flies (*Diptera: Calliphoridae*) among wild rabbits in Australia. *Virus Res* 54(2): 123-132.
- Awad NF, Kotb GK (2018) Genetic characterization of rabbit hemorrhagic disease virus from naturally infected rabbits in Sharkia governorate, Egypt. *J Virol Sci* 3: 10-19.
- Barcena J, Morales M, Vazquez B, Boga JA, Parra F, Lucientes J, Pages-Mante A, Sanchez-Vizcaino JM, Blasco R, Torres JM (2000) Horizontal transmissible protection against myxomatosis and rabbit hemorrhagic disease by using a recombinant myxoma virus. *J Virol* 74: 1114-1123.
- Belz K (2004) Rabbit hemorrhagic disease. *Seminars in Avian and Exotic Pet Medicine*, 13(2): 100-104.
- Berninger ML, House C (1995) Serologic comparison of four isolates of rabbit hemorrhagic disease virus. *Vet Microbiol* 47 (1-2): 157-165.
- Bertagnoli S, Gelfi J, Le Gall G, Boilletot E, Vautherot JF, Rasschaert D, Laurent S, Petit F, Boucraut-Baralon C, Milon A (1996b) Protection against myxomatosis and rabbit viral hemorrhagic disease with recombinant myxoma viruses expressing rabbit hemorrhagic disease virus capsid protein. *J Virol* 70: 5061-5066.
- Bertagnoli S, Gelfi J, Petit F, Vautherot JF, Rasschaert D, Laurent S, Le Gall G, Boilletot E, Chantal J, Boucraut-Baralon C (1996a) Protection of rabbits against rabbit viral hemorrhagic disease with a vaccinia-RHDV recombinant virus. *Vaccine* 14: 506-510.
- Broja G, Larias OMD (1990) Determination de la viabilidad del virus de la EHV cen alfalfa, alimento balanceado commercial costales paraalimento ratas. (Thesis). *Fac Vet Med, Unam, Mexico*.
- Cabezas S, Calvete C, Moreno S (2006) Vaccination success and body condition in the European wild rabbit: applications for conservation strategies. *J Wild Manage* 70: 1125-1131.
- Campagnolo ER, Ernst MJ, Berninger ML, Gregg DA, Shumaker TJ, Boghossian AM (2003) Outbreak of rabbit hemorrhagic disease in domestic lagomorphs. *J Am Vet Med Assoc* 223(8): 1151-1128.
- Cancellotti FM, Renzi M (1991) Epidemiology and current situation of viral hemorrhagic disease of rabbits and the European brown hare syndrome in Italy. *Re Sci Tech* 10: 409-422.
- Capucci L, Scicluna MT, Lavazza A (1991) Diagnosis of viral hemorrhagic disease of rabbits and the European brown hare syndrome. *Rev Sci Tech* 10: 347-370.
- Capucci L, Fallacara F, Grazioli S, Lavazza A, Pacciarini ML, Procchi E (1998) A further step in the evolution of rabbit hemorrhagic disease virus: the appearance of the first consistent antigenic variant. *Virus Research*, 58, 115-126. CFSPH, Center for Food Security and Public Health, Iowa State University (2006). Rabbit Hemorrhagic Disease. Technical Factsheet. www.cfsph.iastate.edu
- Chasey D (1997) Rabbit hemorrhagic disease: the new scourge of *Oryctolagus cuniculus*. *Lab. Anim* 31: 33-44.
- Clouet RN, Blanchard D, Andre FG, Song B, Ganiere JP (1995). Detection of antibodies to RHDV: as immuno-blotting method using coated human erythrocyte membrane. *J Vet Med* 42 (4): 197-204.
- Cooke BD (2002) Rabbit hemorrhagic disease: field epidemiology and the management of wild rabbit populations. *Rev Sci Tech* 21: 347-

- 358.
- Crisci E, Almanza H, Mena I, Cordoba L, Gomez-Casado E, Caston JR, Fraile L, Barcana J, Montoya M (2009) Chimeric calicivirus-like particles elicit protective anti-viral cytotoxic responses without adjuvant. *Virology* 387: 303-312.
- Dalton KP, Nicieza I, Balseiro A, Muguerza MA, Rosell JM, Casais R, Parra F (2012) Variant rabbit hemorrhagic disease virus in young rabbits, Spain. *Emerg Infect Dis* 18: 2009-2012.
- Daoud AM, Khodeir MH, Abbass AM, Ibrahim SI (1998a) Preparation of a specific inactivated vaccine against RHDV. In: 4th Sci Conf, Fac Vet Med, Zagazig Univ, Egypt, p. 230-234.
- Daoud AM, Khodeir MH, Abbass AM, Ibrahim SI, Gergis SM (1998b): Preliminary study for preparation of rabbit pasteurellosis and rabbit hemorrhagic disease virus combined vaccine. In: 4th Sci Conf, Fac Vet Med, Zagazig Univ, Egypt, p. 191-198.
- Eid AAM, Ibraheem OK (2006) Sudden death among rabbits in Sharkia Province, Egypt. *Zagazig Vet J* 34: 108-119.
- El-Bagoury GF, Abd El-Moaty DA, El-Zeedy SA, El-Nahas EM, Youssif AA (2014) Molecular identification of RHDV Egyptian strains based on the highly variable region of VP60 gene, Benha Vet Med J 26: 84-100.
- Eleraky NZ, Potgieter LN, Kennedy MA (2002) Virucidal efficacy of four new disinfectants. *J Am Anim Hosp Assoc* 38(3): 231-234.
- El Mehdaoui S, Touze A, Laurent S, Sizaret P-Y, Rasschaert D, Coursaget P (2000) Gene transfer using recombinant rabbit hemorrhagic disease virus capsids with genetically modified and encapsidation capacity by addition of packaging sequences from the 11 or 12 protein of human papillomavirus type 16. *J Virol* 74: 10332-10340.
- El-Mongy FA (1998) Studies on viral hemorrhagic disease of rabbits (Ph.D. Thesis), Fac Vet Med, Zagazig Univ, Egypt.
- El-Sissi FA, Gafer JA (2008) Preliminary diagnosis of non haemagglutinating strain of rabbit hemorrhagic disease virus in Egypt. *Egypt J Comp Pathol Clin Pathol* 21:161-175.
- El-Zanaty K (1994) Some investigation on rabbit viral haemorrhagic disease in Upper Egypt. *Assiut Vet Med J* 30(60): 293-305.
- Embury-Hyatt C, Postey R, Hisanaga T, Lynn B, Hooper-McGrevy K, McIntyre L, Millar L, Pasick J (2012) The first reported case of rabbit hemorrhagic disease in Canada. *Canad Vet J* 53: 998-1002.
- Erfan AM, Shalaby AG (2020) Genotyping of rabbit hemorrhagic disease virus detected in diseased rabbits in Egyptian provinces by VP60 sequencing. *Vet World* 13(6): 1098-1107.
- Ewees GAS (2007) Further studies on hemorrhagic viral disease in rabbit. (Ph.D. Thesis), Fac Vet Med, Cairo Univ, Egypt.
- Fahmy HA, Arafa A, Mahmoud AH (2010) Molecular diagnosis of rabbit hemorrhagic disease virus (RHDV). *Egypt J Comp Pathol Clin Pathophysiol* 23: 85-101.
- Farnos O, Boue O, Parra F, Martin-Alonso JM, Valdes O, Joglar M, Navea L, Naranjo P, Leonart R (2005) High-level expression and immunogenic properties of the recombinant rabbit hemorrhagic disease virus VP60 capsid protein obtained in *Pichia pastoris*. *J Biotechnol* 117: 215-224.
- Farnos O, Rodriguez M, Chiong M, Parra F, Boue O, Lorenzo N, Colas M, Leonart R (2006) The recombinant rabbit hemorrhagic disease virus VP60 protein obtained from *Pichia pastoris* induces a strong humoral and cell mediated immune response following intranasal immunization in mice. *Vet Microbiol* 114: 187-195.FAO, Food and Agriculture Organization of the United Nations Database (2019) Available from: <http://www.faostat.fao.org>. Retrieved on 05-03-2019.
- Ferreira PG, Costa ESA, Monteiro E, Oliveira MJ, Aguas AP (2006) Liver enzymes and ultrastructure in rabbit hemorrhagic disease (RHD). *Vet Res Commun* 30: 393-401.
- Forrester NL, Abubakr MI, Abu Elzein EM, al Afaleq AI, Housawi FM, Moss SR, Turner SL, Gould EA (2006) Phylogenetic analysis of rabbit hemorrhagic disease virus strains from the Arabian Peninsula: did RHDV emerge simultaneously in Europe and Asia? *Virology* 344: 277-282.
- Forrester NL, Moss SR, Turner SL, Schirrmeier H, Gould EA (2008) Recombination in rabbit hemorrhagic disease virus: possible impact on evolution and epidemiology. *Virology* 376: 390-396.
- Ghanem IA, Ismail AN (1992) Occurrence of rabbit hemorrhagic disease in Sharkia province. *Zag Vet Med J* 20(4): 491-502.
- Gould AR, Kattenbelt JA, Lenghaus C, Morrissy C, Chamberlain T, Collins BJ, Westbury HA (1997) The complete nucleotide sequence of rabbit haemorrhagic disease virus (Czech strain V351): use of the polymerase chain reaction to detect replication in Australian vertebrates and analysis of viral population sequence variation. *Virus Res* 47: 7-17.
- Gregg DA, House C, Meyer R, Berninger M (1991) Viral haemorrhagic disease of rabbits in Mexico: epidemiology and viral characterization. *Rev Sci Tech* 10: 435-451.
- Guittre CI, Baginski G, Gall LE (1995) Detection of rabbit hemorrhagic disease virus isolates and sequence comparison of the N-terminus of the capsid protein gene by the polymerase chain reaction. *Res Vet Sci* 58: 128-132.
- Hamed AM, Eid AAM, El-Bakrey RMM (2013) A review of rabbit diseases in Egypt. *WARTAZOA* 23 (4): 185-194.
- Henning J, Meers J, Davies PR, Morris RS (2005) Survival of rabbit haemorrhagic disease virus (RHDV) in the environment. *Epidemiol Infect* 133: 719-730.
- Huang HB (1991) Vaccination against and immune response to viral haemorrhagic disease of rabbits: a review of research in the People's Republic of China. *Rev Sci Tech*, 10: 481-498.
- Ibrahim IS, Abbass AM, ElKholy AA, Safia TK, Hussein AZ (1999) Simultaneous infection with rabbit haemorrhagic disease virus and rabbit pasteurellosis in rabbit farms in Egypt. *Alex J Vet Sci* 15 (3): 567-578.
- Ismail MM, Mohamed MH, ElSabagh IM, Al-Hammadi MA (2017) Emergence of new virulent rabbit hemorrhagic disease virus strains in Saudi Arabia. *Trop Anim Health Prod* 49: 295-301.
- ITAVI Institut Technique de l'Aviculture (2019) Fiches de Biosécurité en Élevage de Lapins. Available online: <https://www.itavi.asso.fr/content/fiches-de-biosecurite-en-elevage-de-lapins> (accessed on 11 May 2019).
- Khodeir MH, Daoud AM (2002). Preparation and evaluation of an inactivated cell culture rabbit hemorrhagic disease virus vaccine. *SCOV M J* 1: 75-94.
- Kovalisk J (1998) Monitoring the spread of rabbit hemorrhagic disease virus as a new biological agent for control of wild European rabbits in Australia. *J Wildl Dis* 34(8): 421-428.
- Lavazza A, Capucci (1996) Viral hemorrhagic disease of rabbits. In: Manual of Standards for Diagnostic Tests and Vaccines, 3rd Ed., Reichard, rd R. Paris, France, Office International des Epizooties, Chapter, 3: 7-3.
- Lavassa A, Capucci L (2008) How many caliciviruses are there in rabbits. A review on RHDV and correlated viruses. In: *LagomorphBiology: Evolution, Ecology and Conservation*. Springer-Verlag Berlin Heidelberg 263-278.
- Le Gall-Recule G, Zwingelstein F, Laurent S, de Boisseson C, Portejoie Y, Rasschaert D (2003) Phylogenetic analysis of rabbit haemorrhagic disease virus in France between 1993 and 2000, and the characterisation of RHDV antigenic variants. *Arch Virol* 148(1): 65-81.
- Le Gall-Recule G, Lavazza A, Marchandau S, Bertagnoli S, Zwiigens-taein F, Cavadini P, Martinelli N, Lombardi G, Guerin JL, Lemaitre E, Décors A, Boucher S, Le Normand B, Capucci L (2013) Emergence of a new lagoon virus related to rabbit haemorrhagic disease virus. *Vet Res* 44(1): 81.
- Liu SJ, Xue HP, Pu BQ, Qian NH (1984) A new viral disease in rabbits. *Anim. Husbandry Vet Med* 16 (6): 253- 255.
- Marcato PS, Benazzi C, Vecchi G, Galeotti M., Salda LD, Sarli G, Lucidi P (1991) Clinical and pathological features of viral haemorrhagic disease of rabbits and the European brown hare syndrome. *Rev Sci Tech Off Int Epizoot* 10: 371-392.
- Magouzi AF, Elsayed EA, Metwally AY (2019) Detection and characterization of rabbit hemorrhagic disease virus strains circulating in Egypt. *Bulg J Vet Med* 22(4): 409-418.
- Marques RM, Costa ESA, Aguas AP, Teixeira L, Ferreira PG (2010) Early acute depletion of lymphocytes in calicivirus-infected adult rabbits. *Vet Res Commun* 34(8): 659-668.
- Martin-Alonso JM, Castanon S, Alonso P, Parra F, Ordas R (2003) Oral immunization using tuber extracts from transgenic potato plants expressing rabbit hemorrhagic disease virus capsid protein. *Transgenic Res* 12: 127-130.
- McColl KA, Morrissy CJ, Collins BJ, Westbury HA (2002) Persistence

- of rabbit haemorrhagic disease virus in decomposing rabbit carcasses. *Aust Vet J* 80: 298-299.
- McIntosh MT, Behan SC, Mohamed FM, Lu Z, Moran KE, Burrage TG, Neilan JG, Ward GB, Botti G, Capucci L, Metwally SA (2007) A pandemic strain of calicivirus threatens rabbit industries in the Americas. *Virol J* 4: 96-10.
- Metwally AY, Madbouly HM (2005) Study on a new isolate of rabbit haemorrhagic disease virus. *Bani-suef Vet Med J* 15(2): 283-243.
- Merchán T, Rocha G, Alda F, Silva E, Thompson G, Hidalgo de Trucios S, Pagès-Manté A (2011) Detection of rabbit haemorrhagic disease virus (RHDV) in nonspecific vertebrate hosts sympatric to the European wild rabbit (*Oryctolagus cuniculus*). *Infect Genet Evol* 11: 1469-1474.
- Meyers G, Wirblich C, Thiel HJ (1991) Rabbit hemorrhagic disease virus-molecular cloning and nucleotide sequencing of a calicivirus genome. *Virology* 184(2): 664-676.
- Miao O, Qi R, Veldkamp L, Ijzer J, Kik ML, Zhu JM, Tang A, Dong D, Shi Y, Van Oers MM, Liu G, Pijlman GP (2019) Immunogenicity in rabbits of virus-like particles from a contemporary rabbit haemorrhagic disease virus Type 2 (GL2/RHDV2/b) isolated in the Netherlands. *Viruses* 11(6): 553.
- Mitro S, Krauss H. (1993). Rabbit hemorrhagic disease: a review with reference to its epizootiology. *Europ J Epidemiol* 9(1): 70-78.
- Mohamed FO (2009). Clinic pathological studies on the effect of viral hemorrhagic disease (VHD) in rabbits (Master Thesis). Zagazig University, Egypt.
- Morisse JP, Le Gall G, Boilletot E (1991) Hepatitis of viral origin in Leporidae: introduction and aetiological hypotheses. *Rev Sci Tech* 10:283-295.
- Moss SR, Turner SL, Trout RC, White PJ, Hudson PJ, Desai A, Armesto M, Forrester NL, Gould EA (2002) Molecular epidemiology of rabbit haemorrhagic disease virus. *J General Virol* 83: 2461-2467.
- Mostafa AA (2001) Characterization and pathogenicity of locally isolated virus of hemorrhagic disease in rabbits. (Ph.D. Thesis), Fac Vet Med, Beni-Suef Univ, Egypt.
- Moussa A, Chasey D, Lavazza A, Capucci L, Smid B, Meyers G, Rossi C, Thiel HJ, Vlasak R, Ronsholt L, Nowotny N, McCullough K, Gavi-er-Widenm D (1992) Haemorrhagic disease of lagomorphs: Evidence for a calicivirus. *Vet Microbiol* 33(1-4): 375-381.
- Muller A, Freitas J, Silva E, Le Gall-Reculé G, Zwingelstein F, Abrantes J, Esteves PJ, Alves PC, van der Loo W, Kolodziejek J, Nowotny N, Thompson G. (2009) Evolution of rabbit haemorrhagic disease virus (RHDV) in the European rabbit (*Oryctolagus cuniculus*) from the Iberian Peninsula. *Vet Microbiol* 135: 368-373.
- Nagesha HS, Wang LF, Hyatt AD, Morrissey CJ, Lenghaus C, Westbury HA (1995) Self-assembly, antigenicity, and immunogenicity of the rabbit haemorrhagic disease virus (Czechoslovakian strain V-351) capsid protein expressed in baculovirus. *Arch Virol* 140: 1095-1108.
- Ohlinger VF, Haas B, Thiel HJ (1993) Rabbit haemorrhagic disease (RHD): Characterization of the causative calicivirus. *Vet Res* 24(2): 103-116.
- OIE Office of International Epizootics (2008) Terrestrial Manual. Viral hemorrhagic disease of rabbits. Chapter 2.6.2. P. 947-961.
- OIE Office of International Epizootics (2010) Terrestrial Manual. Viral hemorrhagic disease of rabbits. 1-15
- OIE Office of International Epizootics (2012) Terrestrial Manual. Viral hemorrhagic disease of rabbits, Rabbit Calcivirus disease. Chapter 2.6.2 pp. 1-15.
- OIE Office of International Epizootics (2018) Terrestrial Animal Health Code. 2018. Available online: <http://www.oie.int/en/standard-setting/terrestrial-code/access-online/> (accessed on 19 May 2019).
- Patton NM (1989) Viral hemorrhagic disease. A major new disease problem of rabbits. *Rabbit Res* 12: 64-67.
- Park JH, Lee YS, Itakura C (1995) Pathogenesis of acute necrotic hepatitis in rabbit hemorrhagic disease. *Lab Anim Sci* 45(4): 445-449.
- Peacey M, Wilson S, Baird MA, Ward VK (2007) Versatile RHDV virus-like particles: incorporation of antigens by genetic modification and chemical conjugation. *Biotechnol Bioeng* 98: 968-977.
- Peacey M, Wilson S, Perret R, Ronchese F, Ward VK, Young V, Young SL, Baird MA (2008) Virus-like particles from rabbit hemorrhagic disease virus can induce an anti-tumor response. *Vaccine* 26: 5334-5337.
- Peshev R, Christova L (2003) The efficacy of a bivalent vaccine against pasteurellosis and rabbit haemorrhagic disease virus. *Vet Res Commun* 27: 433-444.
- Plana-Duran J, Bastons M, Rodriguez MJ, Climent I, Cortes E, Vela C, Casal I (1996) Oral immunization of rabbits with VP60 particles confers protection against rabbit hemorrhagic disease. *Arch Virol* 141: 1423-1436.
- Plassiart G, Guelfi JF, Ganiere JP, Wang B, Andre-Fontaine G, Wyers M (1992) Hematological parameters and visceral lesions relationships in rabbit viral hemorrhagic disease. *J Vet Med (B)* 39: 443-53.
- Pu BQ, Quian NH, Cui S (1985) Micro HA and HI tests for the detection of antibody titres to so-called 'haemorrhagic pneumonia' in rabbits [in Chinese]. *Chin J Vet Med* 11: 16-17.
- Ramiro-Ibáñez F, Martín-Alonso JM, García Palencia P, Parra F, Alonso C (1999) Macrophage tropism of rabbit hemorrhagic disease virus is associated with vascular pathology. *Virus Res* 60: 21-28.
- Ruvoen-Clouet N, Ganiere JP, Andre-Fontaine G, Blanchard D, Le Pendu J (2000) Binding of rabbit hemorrhagic disease virus to antigens of the ABH histo-blood group family. *J Virol* 74: 11950-11954.
- Sahar TA, Hanaa AE, Khalid MM (2011) Immunological and virological studies on rabbit hemorrhagic disease virus. *Global Vet* 7 (6): 545-556.
- Salem B, El-Ballal SS (1992) The occurrence of rabbit hemorrhagic disease (RHVD) in Egypt. *Assiut Vet Med J* 27(53): 295-304.
- Salem B, El-Zanaty K (1992) Tissue-derived inactivated vaccine against rabbit viral haemorrhagic disease. In: *Proc 5th Sci Conf, Fac Vet Med, Assiut Univ, Egypt*.
- Schirmmeier H, Reimann I, Kollner B, Granzow H (1999) Pathogenic, antigenic and molecular properties of rabbit haemorrhagic disease virus (RHDV) isolated from vaccinated rabbits: detection and characterization of antigenic variants. *Arch Virol* 144: 719-735.
- Sharawi SSA (1992) Studies on the virus causing haemorrhagic septicemia in rabbits (Master Thesis). *Fac Vet Med, Zagazig Univ, Egypt*.
- Smid B, Valicek L, Rodak L, Stepanek J, Jurak E (1991). Rabbit haemorrhagic disease: an investigation of some properties of the virus and evaluation of an inactivated vaccine. *Vet Microbiol* 26: 77-85.
- Soliman MA, Abdel Rahman MA, Samy MM, Mehana O, Nasef SA (2016) Molecular, clinical and pathological studies on viral rabbit hemorrhagic disease. *Alex J Vet Sci* 48: 20-26.
- Trzeciak-Rydzek A, Tokarz-Deptuła B, Deptuła W (2015) The importance of liver lesions and changes to biochemical and coagulation factors in the pathogenesis of RHD. *Acta Biochimica Polonica* 62: 169-171.
- Ueda K, Park JH, Ochiai K, Itakura C (1992) Disseminated intravascular coagulation (DIC) in rabbit haemorrhagic disease. *Jpn J Vet Res* 40(4): 133-141.
- Urakova N, Hall R, Strive T, Frese M (2019) Restricted host specificity of rabbit hemorrhagic disease virus supported by challenge experiments in immune-compromised mice (*Mus musculus*). *J Wildl Dis* 55(1): 218-222.
- Wang X, Xu F, Liu J, Gao B, Liu Y, Zhai Y, Ma J, Zhang K, Baker TS, Schulten K, Zheng D, Pang H, Sun F (2013) Atomic model of rabbit hemorrhagic disease virus by cryo-electron microscopy and crystallography. *PLoS Pathogens*. 9(1): e1003132.
- Xu WY (1991) Viral hemorrhagic disease of rabbits in the people's republic of China: Epidemiology and virus characterization. *Rev Sci Tech* 10(2): 393-408.
- Xu ZJ, Chen WX (1989). Viral haemorrhagic disease in rabbits: a review. *Vet Res Commun* 13: 205-212.
- Win SJ, Ward VK, Dunbar PR, Young SL, Baird MA (2011) Cross-presentation of epitopes on virus-like particles via the MHC I receptor recycling pathway. *Immunol Cell Biol* 89: 681-688.
- Young SL, Wilson M, Wilson S, Beagley KW, Ward V, Baird MA (2006) Transcutaneous vaccination with virus-like particles. *Vaccine* 24: 5406-5412.

Surgical Management of Orbital Abscesses in Domestic Rabbits (*Oryctolagus cuniculus*): A report of seven cases

A.L.N. Thomas¹, G.M. Kazakos¹, D. Pardali², M.N. Patsikas¹, A.Th. Komnenou¹

¹ Companion Animal Clinic, School of Veterinary Medicine, Faculty of Health Sciences, Aristotle University of Thessaloniki, Greece.

² Diagnostic Laboratory, School of Veterinary Medicine, Faculty of Health Sciences, Aristotle University of Thessaloniki, Greece.

ABSTRACT: A case series of seven domestic rabbits with profound exophthalmos and epiphora are presented. Appetite and physical activity of the animals were mildly or severely reduced. Clinical and detailed ophthalmic examination including intraocular pressure measurements were performed, along with radiographic and ultrasonographic examination. In all animals retrobulbar masses were diagnosed forcing the globe to protrude. Teeth malocclusion was also noticed in most of the animals. Surgical intervention under general anaesthesia, included abscess drainage, flushing and teeth removal. During surgery, samples for bacterial culture and cytology examination were obtained. *Pasteurella multocida*, *Staphylococcus* spp and *Pseudomonas* spp were isolated, while cytology confirmed the clinical diagnosis of abscess formation. Surgical management resulted in retropulsion of ocular bulbi and infection elimination. Marsupialization of the abscesses facilitated flushing and topical antibiotic application postoperatively. Animals were treated postoperatively with antibiotics for at least one month, analgesics, daily wound flushing by the owner and regular debridement. Six months after surgery three rabbits had no ocular symptoms while two died in the first two months post surgically, one was lost to follow up and the other died due to unrelated cause. In conclusion, treatment of retrobulbar abscesses in rabbits may be challenging and unrewarding. Surgical management of retrobulbar abscesses without enucleation is a feasible approach, permitting vision-retaining, whereas a multimodal approach consisting of a combination of surgical and medical treatment is often necessary for a successful outcome. The owner should be informed for the long lasting postoperative care as well as the high percentage of relapse.

Keywords: abscess, rabbit, retrobulbar, surgery.

Corresponding Author:
Angelos L.N. Thomas, Companion Animal Clinic, School of Veterinary Medicine,
Faculty of Health Sciences, Aristotle University of Thessaloniki, Greece
E-mail address: plato@vet.auth.gr

Date of initial submission: 20-09-2018
Date of revised submission: 22-04-2020
Date of acceptance: 13-06-2020

ΠΕΡΙΛΗΨΗ. Στην παρούσα εργασία μελετήθηκαν 7 κατοικίδια κουνέλια, τα οποία παρουσίαζαν οπισθοβολβικό απόστημα. Όλα τα κουνέλια προσκομίστηκαν με εξόφθαλμο και επιφορά, ενώ παράλληλα εμφάνιζαν ήπια έως σοβαρή μείωση της όρεξης και της φυσικής δραστηριότητας. Διενεργήθηκε κλινική και λεπτομερής οφθαλμολογική εξέταση με έμφαση στη μέτρηση της ενδοφθάλμιας πίεσης, καθώς και ακτινολογική και υπερηχογραφική εξέταση. Σε όλα τα ζώα διαπιστώθηκε η παρουσία οπισθοβολβικών μαζών, ενώ στα περισσότερα ζώα παρατηρήθηκε και ανώμαλη ανάπτυξη των δοντιών. Σε όλα τα ζώα πραγματοποιήθηκε, υπό γενική αναισθησία, χειρουργικός καθαρισμός και παροχέτευση των αποστημάτων, πλύσεις και εξαγωγές δοντιών. Κατά τη διάρκεια της χειρουργικής επέμβασης, λήφθηκαν δείγματα για καλλιέργεια και κυτταρολογική εξέταση. Τα βακτήρια που απομονώθηκαν ήταν *Pasteurella multocida*, *Staphylococcus* spp και *Pseudomonas* spp, ενώ η κυτταρολογική εξέταση επιβεβαίωσε την κλινική διάγνωση των αποστημάτων. Η χειρουργική αντιμετώπιση είχε ως αποτέλεσμα την οπισθοχώρηση των οφθαλμικών βολβών και την αντιμετώπιση της λοίμωξης. Η μαρσιποποίηση των αποστημάτων διευκόλυνε τις πλύσεις και την τοπική χορήγηση αντιβιοτικών μετεγχειρητικά. Στα ζώα χορηγήθηκαν αντιβιοτικά για τουλάχιστον ένα μήνα, αναλγητικά, ενώ πραγματοποιούνταν καθημερινές πλύσεις από τον ιδιοκτήτη και τακτικοί καθαρισμοί στο ιατρείο. Έξι μήνες μετά, τρία κουνέλια δεν είχαν οφθαλμικά συμπτώματα, ενώ τρία πέθαναν τους πρώτους δύο μήνες μετά από τη χειρουργική επέμβαση και σε ένα η έκβαση δεν είναι γνωστή. Συμπερασματικά, η χειρουργική παροχέτευση και καθαρισμός των οπισθοβολβικών αποστημάτων χωρίς εξόρυξη του οφθαλμού είναι μια θεραπευτική προσέγγιση που επιτρέπει τη διατήρηση της όρασης στα κατοικίδια κουνέλια. Ο συνδυασμός φαρμακευτικής και χειρουργικής θεραπείας είναι συχνά απαραίτητος για την επιτυχή έκβαση. Η μετεγχειρητική θεραπεία διαρκεί συχνά αρκετές εβδομάδες και η πιθανότητα υποτροπών είναι υψηλή, πράγμα για το οποίο ο ιδιοκτήτης πρέπει να είναι ενήμερος

Λέξεις κλειδιά: απόστημα, κουνέλι, οπισθοβολβικό, χειρουργείο.

CASES HISTORY

Orbital abscesses are a challenging surgical condition in domestic rabbits regarding rabbits regarding its clinical signs, therapeutic approach and outcome, since it may lead to visual deterioration and it is potentially life-threatening. In this case series, seven domestic rabbits were presented in a private referral practice. Signalment and historical data of the animals are presented in Table 1.

Presenting complaints included exophthalmos (1), epiphora (1), ocular trauma (1), nasal discharge (1) and ocular discharge (4) (Table 2). Appetite was retained in most cases with mild fluctuations, while only one rabbit appeared anorectic. Physical activity was characterized as normal in all cases by the owners. In all animal ophthalmic examination included inspection of the bulbi and adnexa, fluorescein and lissamine green corneal stain application, tonometry and ophthalmoscopy. During ophthalmic examination profound exophthalmos was confirmed in all cases.

Intraocular pressure and corneal diameter measurements were normal when compared to the contralateral eye, excluding glaucoma and buphthalmos (Figure 1). Central corneal lesions were present in all animals with ulceration in three of them. Eyelid movements were limited in all cases. Anterior uveitis was also noticed in one case (Table 2).

Plain radiographs of the skull were obtained in 5 animals. In three animals (No 1, 2, 3) abnormal radiologic findings were evident (Fig. 2). In one animal (No 5) no abnormalities were found. Ultrasonographic examination of the eye and retrobulbar space was performed in 2 animals (No 1,2). A hypoechoic to anechoic retrobulbar well defined mass was revealed, with hyperechoic foci within the mass that were not casting any shadow, findings compatible with the presence of a retrobulbar abscess (Fig. 3). Fine needle aspiration was performed in those 2 cases under ultrasound guidance. Clinical examination findings of the animals are presented in Table 2.

Table 1. Epidemiological data of seven rabbits presented with retrobulbar abscesses.

No	Age (years)	Weight (Kg)	Sex	Breed	Previous ADD†
1	3	1.4	Male	ND‡	Incisor and upper cheek teeth left and right
2	5	1.5	Male	ND	Incisor and upper cheek teeth left
3	unknown	1.2	Male	ND	Unknown
4	2	3	Female	Mixed	None
5	3	3	Female	Mixed	None
6	3	1.5	Male	ND	Two premolars extraction
7	5.5	2	Male	ND	None

†ADD= Acquired Dental Disease

‡ND= Netherland dwarf

Table 2. Clinical appearance and examination findings of seven rabbits presented with retrobulbar abscesses.

No	Presenting complaints	Main clinical manifestation	Eye	Radiology/	Ocular symptoms	ADD
1	Exophthalmos	Exophthalmos-Inappetence	OS*	excessive elongation of the maxillary and mandibular cheek teeth, spur formation, widened of interproximal spaces, root deformity, diffuse irregular mineralization of the adjacent alveolar bone and cheek teeth malocclusion / anechoic well defined retrobulbar mass	Corneal abrasions	Malocclusion of P**+M***
2	Epiphora, nasal discharge	Exophthalmos	OS	excessive elongation of the maxillary and mandibular cheek teeth, spur formation, widened of interproximal spaces, root deformity, diffuse irregular mineralization of the adjacent alveolar bone and cheek teeth malocclusion/ hypoechoic well defined retrobulbar mass	Dacryocystitis, Corneal abrasions	Malocclusion of P+M
3	Ocular discharge	Exophthalmos	OS	excessive elongation of the maxillary and mandibular cheek teeth, spur formation, widened of interproximal spaces, root deformity, diffuse irregular mineralization of the adjacent alveolar bone and cheek teeth malocclusion	Corneal ulcer, iridocyclitis	Malocclusion of upper+lower P+M
4	Ocular discharge	Exophthalmos	OS	None taken	Corneal ulcer, lens luxation, proptosis, dacryocystitis	Malocclusion of P+M
5	Ocular trauma	Exophthalmos	OS	Normal	Corneal melting, lens luxation, staphyloma, dacryocystitis	None
6	Ocular discharge	Exophthalmos	OS	Radiopaque material laterally to OS and periapical to P+=M	Corneal abrasions, edema	Malocclusion of P+M,+ incisors
7	Ocular discharge	Exophthalmos	OS	None taken	Corneal abrasions, edema	Malocclusion of P+M,+ incisors

* OS= Oculus sinister

** P= Premolar

*** M= Molar

ADD= Acquired Dental Disease

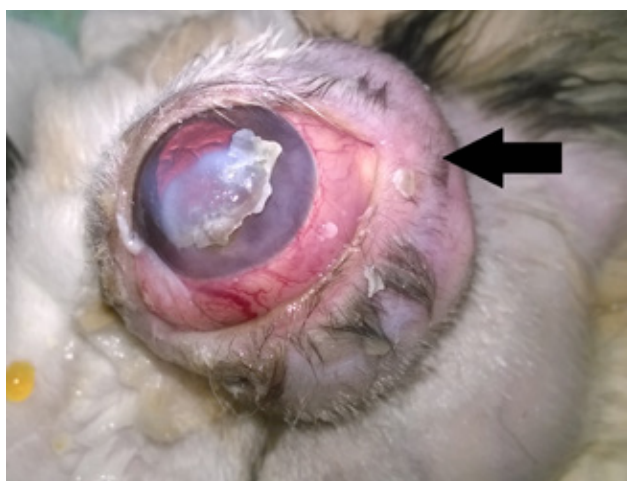

Figure 1. Exophthalmos in a rabbit related to a retrobulbar abscess (arrow).

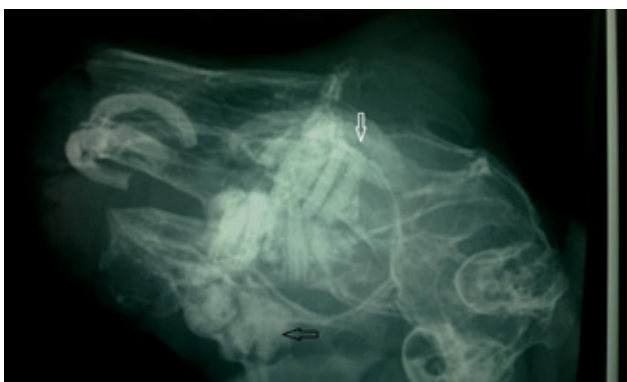

Figure 2. Lateral oblique radiograph of the skull of a rabbit (case 1) demonstrating a radiolucent area of the alveolar bone associated with the upper molar teeth (white arrow), severe deformity of the maxillary and mandible cheek teeth, diffuse irregular mineralization of the adjacent alveolar bone (black arrow) and cheek teeth malocclusion. Malformation of the upper incisor teeth is also evident.

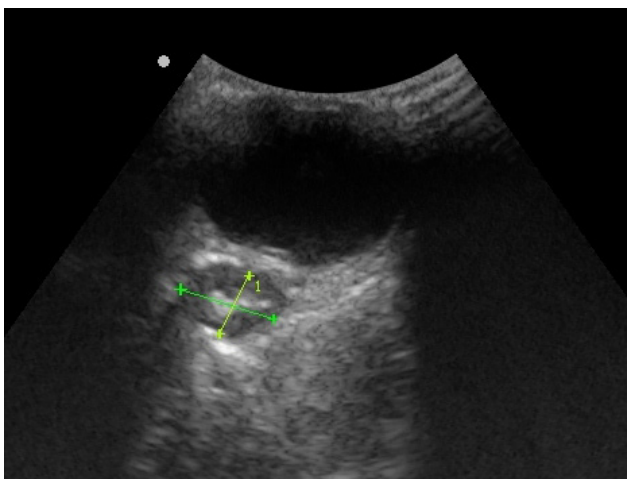


Figure 3. Transverse ultrasonographic section of the eye of a rabbit showing a well-defined 6,16 x 9,24 mm mass hypoechoic retrobulbar mass with echogenic foci in the center of the mass that not casting a shadow (callipers measure the dimensions of the mass).

Surgical intervention was considered curative for 5 animals. In one of them spontaneous abscess drainage took place and, in another animal, no surgical intervention was performed as the owner declined any treatment. All animals were premedicated with medetomidine (Domitor®, Zoetis), (50 µg/kg, intramuscularly) and butorphanol (Butomidor®, Richter pharma) (0.3 mg/kg, intramuscularly). Fluids were administered via an intravenous catheter placed in the auricular marginal vein at a rate of 5 mg/kg/h throughout the surgical procedure. Meloxicam (Metacam®, Boehringer Ingelheim) (0.3 mg/kg, subcutaneously) was administered at the same time. Anaesthesia was induced 10 minutes later with ketamine (Imalgene®, Merial) (10 mg/kg, intramuscularly). Oxygen was provided with a nasal catheter throughout the surgical procedure. After dental care completion, anaesthesia was continued with isoflurane (IsoFlo®, Zoetis) 2-3 % in 100% oxygen provided with a face mask. Reverse of anaesthesia after surgery completion, was achieved with atipamezole (Antisedan®, Zoetis), (0.5 mg/kg, intramuscularly) and was uneventful.

Abscess drainage was the treatment of choice in most cases following teeth trimming and teeth extraction. A skin incision was performed, based on radiographic, ultrasonographic and ocular palpation findings just above the zygomatic arch (Fig.4) and the abscess cavity was lanced exposing its content (Fig.5). Thick pus was removed with a curette, the abscess cavity was flushed and debrided thoroughly (Fig. 6). At this point exophthalmos was markedly reduced. An intraoral approach and the initial skin incision were both used for teeth extraction avoiding trauma to the adjacent teeth roots (Fig.7, 8). Following abscess flushing, 5-7 sutures were placed in order to keep wound edges apart and enable post-surgical debridement and cleaning (marsupialization). Details concerning abscess location and surgical intervention are presented in Table 3.

Fine needle aspiration of the abscess under ultrasonographic guidance or during surgery yielded a highly viscous, whitish fluid. Cytological smears were prepared using a compression (squash) technique or by rolling a cotton swab along the glass slide. All glass slides were air-dried and stained with modified Wright – Giemsa stain. Microscopic examination of the smears showed accumulation of amorphous, necrotic, eosinophilic, granular material mixed mostly with degenerative heterophils, and lower numbers of macrophages with phagocytized debris (Fig.9). Lym-

phocytes were occasionally observed. No microorganisms were detected. In most of the smears dense extracellular mineral accumulation was also found (Table 3, Fig.10).

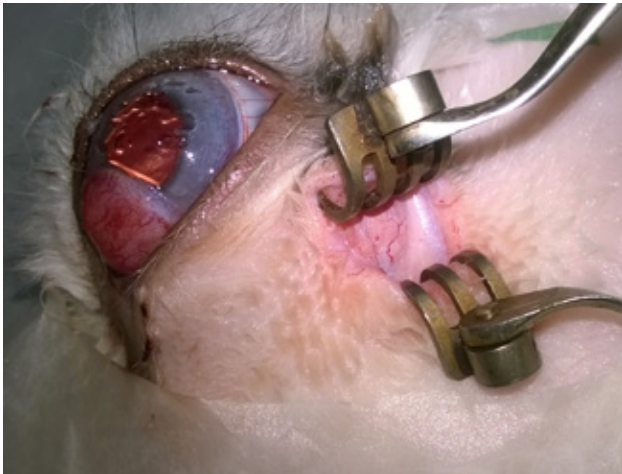


Figure 4. A skin incision was performed just above the zygomatic arch revealing abscess capsule.

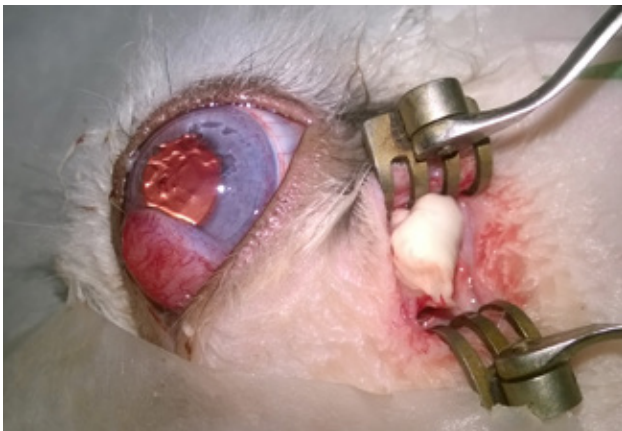


Figure 5. An incision of the abscess's capsule exposing its content.

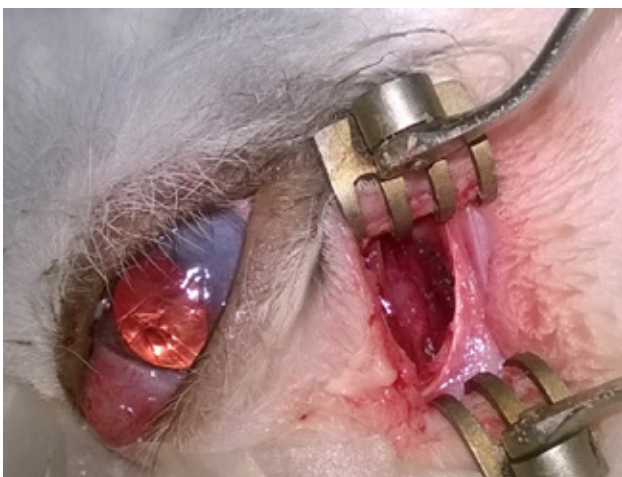


Figure 6. Following pus removal, the abscess cavity was flushed and thoroughly debrided.

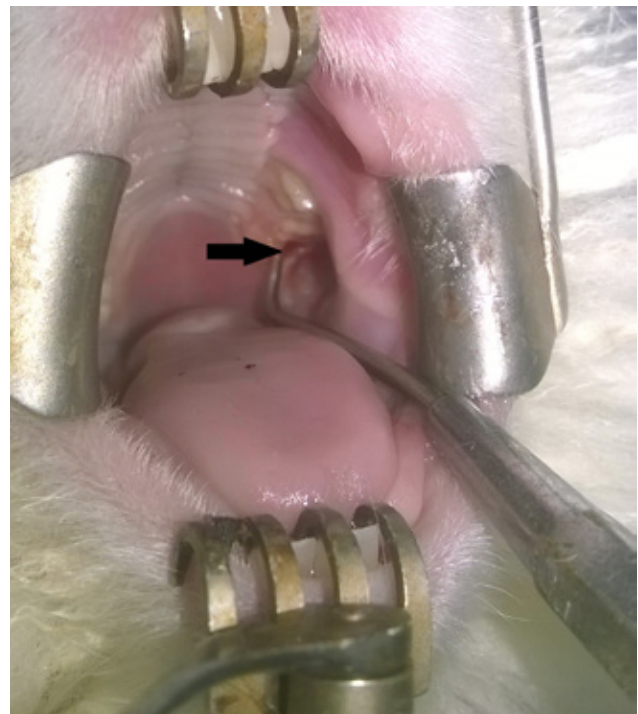


Figure 7. For teeth extraction an intraoral approach, along with the initial skin incision was used.

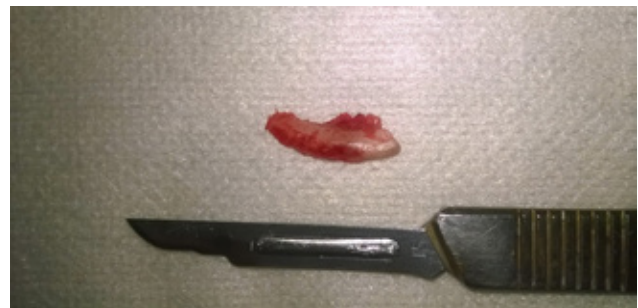

Figure 8. An extracted molar.

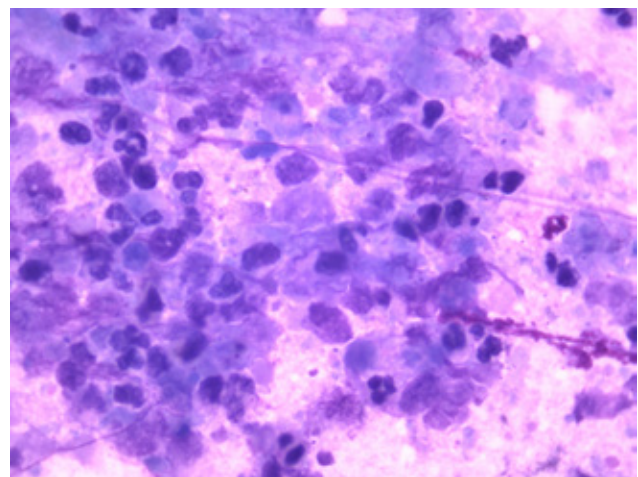


Figure 9. Cytological smear from the orbital abscess in a rabbit. Note the amorphous necrotic eosinophilic granular material mixed mostly with degenerative heterophils, and lower numbers of macrophages with phagocytized debris (Wright – Giemsa x100).

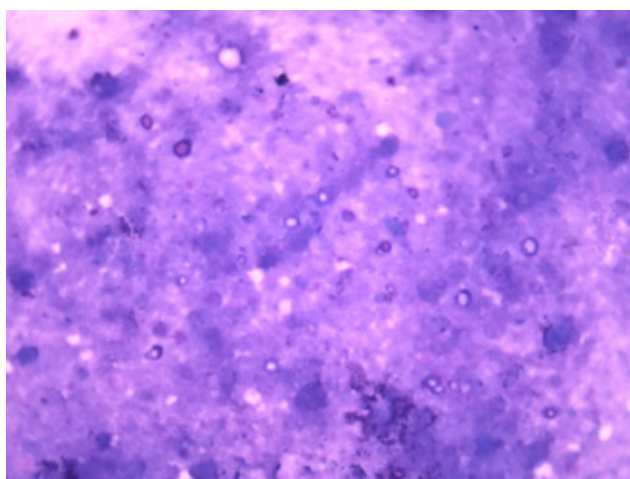


Figure 10. Cytological smear from the orbital abscess in a rabbit. Note the extracellular mineral depositions along with necrotic eosinophilic granular material (Wright – Giemsa x100).

Bacterial cultures obtained during surgery revealed *Pasteurella multocida* in two cases, *Staphylococcus aureus* in one and *Pseudomonas* spp in one case while in another case culture was negative. In two cases the animals died before sampling. Antibiotics were used based on sensitivity test in a few cases or they were used empirically in those with no bacterial cultures available. Enrofloxacin (Baytril® 0.5%, Bayer), (10mg/Kg, per os, SID) or azithromycin (Zithromax®, Pfizer) (15 mg/Kg, per os, SID) were administered for 1 month combined with topical preparations. Prebiotic supplements were administered simultaneously with antibiotic per os and force feeding in anorectic animals (Tab.3). Post surgically, analgesia was achieved using meloxicam (Metacam®, Boehringer Ingelheim), (0.1mg/Kg, per os, SID) for at least 1 week. The owners were advised to flush the abscess cavity with normal saline daily, while debridement was performed by the referring veterinarian every 4-7 days for a month period to control the infection. Two animals died soon after presentation, one in 2 months after surgery and in an animal, relapse was noted one year later. In two animal no relapse was noticed 6 months post surgically and one was lost to follow up (Table 3).

DISCUSSION

Orbital abscess is usually a chronic condition, which may also affect other organs through vascular or lymphatic bacterial dissemination. Rabbits are usually presented with normal to reduced appetite and physical activity, related to the degree of pain and chewing abnormalities presented. Other possible systemic symptoms may also be noticed, including

pain related to pressure exerted to the affected site, anorexia, feeding habits alterations, reluctance to play or move. Pain in rabbits is not so obvious, so it is not always easy for the owner to understand early stages of the disease (Varga and Harcourt-Brown, 2014; Capello, 2016). In our study appetite was reduced only in one case, and was attributed to pain. Physical activity deterioration was not mentioned by the owner; thus, pain should have been of low degree.

Complications related to teeth malocclusion are commonly encountered. Elongated crowns of upper premolars, which may penetrate the buccal mucosa is a possible cause of the disease. Most of the affected animals showed premolar and molar malocclusion, highlighting dental involvement. Incisor malocclusion in two cases was considered secondary. Periapical infections of cheek teeth may result in multiple abscesses formation affecting alveolar bones and extending into the orbit (Ward, 2006; Papadimitriou et al., 2008; Capello, 2016; Benato, 2017).

Orbital abscesses are usually characterized by mild to severe exophthalmos, epiphora, ocular surface disorders and dacryocystitis (Williams, 2007). Corneal abrasions and ulceration may be present due to profound exophthalmos and consequent corneal desiccation. Eyelid inability of complete blinking may leave central cornea unprotected (Williams, 2007). In the present study corneal abrasions were evident in most of the animals, while three of them were suffering from severe ulcers (Table 2).

Dacryocystitis may also predispose to orbital abscess and is commonly associated to *Neisseria* sp., *Moraxella* sp., *Bordetella* sp., *Streptococcus viridans*, *Oligella urethralis* or *Pseudomonas* spp (Marini et al., 1996). It is commonly presented with epiphora accompanied by blepharitis, florid conjunctivitis of the nasolacrimal punctum and facial dermatitis in many cases. Pathogenesis of dacryocystitis involves molar arcades malocclusion with retropulsion of the tooth and incisor malocclusion, causing nasolacrimal duct occlusion. In three dacryocystitis cases presented, this mechanism may explain orbital abscess formation. Dacryocystitis may be also secondary to orbital abscessation via infection dissemination (Jones and Carrington, 1988; Harcourt-Brown, 1996). In one dacryocystitis case of our study (No2), *Pasteurella multocida* was isolated and surgical intervention in molar teeth and orbital abscess reduced clinical signs (Tab. 1).

Table 3. Abscesses position, surgical intervention and post-surgical treatment and outcome of seven rabbits presented with retrobulbar abscesses

No	Abscesses location	Surgical intervention	Dental intervention	Bacterial culture results	Cytology of abscess	Post-surgical treatment	Outcome
1	Medial to OS*+ Periapical to P**+M***	Two incisions medial+ventral OS	Removal of 3 rd P+1 st M	<i>Pseudomonas</i> spp	Amorphous necrotic eosinophilic granular material with degenerative heterophils, a few macrophages. Lymphocytes occasionally observed. No microorganisms were detected. Dense extracellular mineral accumulation.	Fucidic acid eye oint, Enrofloxacin, Meloxicam PO [‡] , Debridement	Relapse 1 year later
2	Lateral OS	Two incisions lateral+ventral to OS and in ipsilateral mandibular	Extraction of 1 st + 2 nd M	<i>aPasterella multocida</i>	Amorphous necrotic eosinophilic granular material with degenerative heterophils, and few macrophages. Lymphocytes occasionally observed. No microorganisms were detected. Dense extracellular mineral accumulation.	Fucidic acid eye oint, Enrofloxacin, Meloxicam PO, Debridement	Death after two months (possibly unrelated)
3	Lateral OS	One incision lateral+ventral to OS	Extraction of 2 nd M	<i>Staphylococcus</i> spp	Amorphous necrotic eosinophilic granular material with degenerative heterophils, and few macrophages. Lymphocytes occasionally observed. No microorganisms were detected.	Fucidic acid eye oint, Enrofloxacin, Meloxicam PO, Debridement	No relapse 6 months later
4	Lateral OS	One incision lateral+ventral to OS	Extraction of 3 rd P + 1 st M	-	Amorphous necrotic eosinophilic granular material with degenerative heterophils, and few macrophages. Lymphocytes occasionally observed. No microorganisms were detected.	Azyter eye drops, Zithromax oral syrup, Florentero oral paste	Unknown
5	Lateral OS	Automatic abscess drainage	None	-	Amorphous necrotic eosinophilic granular material with degenerative heterophils, and few macrophages. No microorganisms were detected. Dense extracellular mineral accumulation.	Baytril oral syrup, Meloxoral oral syrup, Oxatrex eye drops, Vit-a-dEx eye gel	Death
6	Lateral OS, Periapical to P+M	Two incisions lateral+ventral OS and dorsal to cheek teeth	Total incisors extraction, P+M grinding	<i>Pasterella multocida</i>	Amorphous necrotic eosinophilic granular material with degenerative heterophils, a few macrophages. No microorganisms were detected.	Zithromax oral syrup, Meloxoral oral syrup, Florentero, Critical Care feeding formula	No relapse 6 months later
7	Lateral OS	None	None	-	Amorphous necrotic eosinophilic granular material with degenerative heterophils, a few macrophages. Lymphocytes occasionally observed. No microorganisms were detected. Dense extracellular mineral accumulation.		Death

* OS= Oculus sinister

** P= Premolar

*** M= Molar

‡ PO= per os

Diagnostic imaging techniques are useful to detect the lesion. Computed tomography is considered the method of choice in order to demonstrate the exact anatomic location and extension of the lesion. Radiographic findings of the skull in our cases were also informative showing radiolucent area of the alveolar bone associated with the upper molar teeth (Silverman and Tell, 2005; Capello and Lennox, 2008; Capello, 2016). The location of the above lesion may suggest that the retrobulbar abscess, as demonstrated by ultrasonography, had a tooth root origin. Ultrasonography is also a valuable, fast and safe technique for imaging the retrobulbar space as it may determine preoperatively the exact location and extent of the abscess. The well-defined, hypoechoic or anechoic mass revealed in two cases in our study were compatible with an abscess, even though retrobulbar neoplasms may share similar ultrasonographic signs. The hyperechoic foci in the mass that were not casting a shadow may reflected the presence of necrotic tissue in the abscess (Ward, 2006). The use of specialised ophthalmic ultrasound devices is preferable as they can detect multiple or multilobular abscesses more accurately. In addition to imaging, axial globe direction is helpful clinically in identifying the site of the abscess.

Cytology is a low cost, safe, quick and easy to perform procedure in awake animals (Garner, 2007). Rabbits are good candidates for cytological evaluation, as surgery decision in this species is not undertaken easily, due to their small size and high anaesthetic risk. Cytological characteristics of the material derived from abscesses were similar to those of other companion animal with the exception of heterophils replacing neutrophils. Otherwise, cytological findings were similar of a susceptible or non-susceptible inflammatory lesion in mammals. Absence of bacteria or cocci in the cytological smears was found in 3 of our cases (Table 3), a common finding in the literature (Jenkins, 2001). Facial soft tissues abscesses are common in rabbits. Veterinarians practicing rabbit medicine are familiar with this condition and they usually do not proceed to cytological evaluation and/or culture (Jenkins, 2001). However, other skin and/or subcutaneous lesions may mimic abscesses and should be included in the list of differentials such as basal cell tumour, squamous cell carcinoma, lymphoma, soft tissue sarcoma, lipoma or squamous papilloma, nodular dermal fibrosis and cutaneous treponemiasis. Such lesions can be differentiated using cytology, preventing aimless, expensive and risky diagnostic and surgical procedures (Capello, 2016).

The most common isolated pathogens in this case series, as expected, were *Pasteurella multocida* followed by *Pseudomonas* spp. and *Staphylococcus* spp., while the rest of the animals were tested negative. The negative results were attributed to the method of material collection, as swabbing the purulent content versus swabbing the interior wall of the abscess cavity may result to false negative results. All of our animals were also receiving antibiotic therapy in the time of surgery. Despite negative results broad spectrum antibiotics were administered post surgically in all cases. Pathogens most commonly isolated in rabbit abscesses include *Pasteurella multocida*, *Staphylococcus* spp., *Proteus* spp., *Bacteroides* spp., and *Pseudomonas* spp., as well as some anaerobic species, such as *Fusiformis* spp. (Deed, 1993; Capello, 2016; Gardhouse et al., 2017). Rational antibiotic therapy was elected based on antibiotic safety, penetrating ability and most commonly bacterial chlorea affecting rabbits. Enrofloxacin is the most commonly used antibiotic agent in rabbits, administered in four of the presented cases as it is licensed and is considered a safe choice for prolonged oral use and it was administered in four of the presented cases. Azithromycin which was selected in two cases is another safe antibiotic for parenteral use, indicated for abscesses and osteomyelitis (Varga and Harcourt-Brown, 2014). Ocular antibiotic administration was considered essential for eliminating local infection and preventing dissemination to the globe and conjunctiva. The antibiotics chosen have proved to be safe and effective in ocular infections.

Rabbit anaesthesia protocols were based on animal health status, which were estimated by history and clinical examination findings. Pre-anaesthetic stabilization included hydration, gut motility regulation and efficient food intake and was accomplished by appropriate medical and nutritional support. Oxygen and fluid administration were essential and were administered intraoperatively to maintain appropriate cardiovascular function, especially due to α -2 adrenergic agonists significant cardiovascular side effects. Ketamine was essential for undertaking dental intervention since inhalational anaesthesia via intubation or laryngeal mask would have disturbed intraoral manipulations. Its administration minimized required doses and side effects of other drugs (Meredith and Flecknell, 2006). Inhalational anaesthesia was induced during abscess surgical intervention and was gradually increased to prevent breath holding, a common complication in rabbits (Harcourt-Brown, 2002).

In order to gain direct retrobulbar abscess access in this species, skin incisions are much easier to be performed compared to dogs and cats. This may be explained by the shallower orbit and the higher globe/orbit ratio in rabbits compared to dogs and cats. The abscess capsule was easily detected through the skin incision since it was located directly under the skin. Orbital morphology and abscess location were helpful landmarks to follow to avoid periocular tissue trauma. Appropriate abscess capsule drainage was crucial for eliminating inflammation and preventing relapse, especially when vision was still relapse. Pus material and capsule removal were performed paying great attention not to damage the globe, optic nerve and large venous sinus associated with the orbit glands. When the abscess was located deeper in the orbit, pus removal was more challenging, as the lesion was partially visible. However, if aggressive surgical debridement could not be employed, exenteration might have been an option (Ward, 2006; Papadimitriou et al., 2008; Capello, 2016; Benato, 2017). In one animal relapse occurred within the first year, something commonly observed following local infection dissemination (Spiess, 2007; Varga and Harcourt-Brown, 2014; Capello, 2016).

In the study presented here if dental involvement was suspected prior to surgery, dental extraction facilitated abscess drainage and infection elimination. Teeth extraction of the upper cheek teeth were essential for periapical abscess treatment. This was accomplished through an oral or extraoral approach through the initial or a second skin incision. Extraoral approach was easier when the maxillary bone was debrided and teeth roots were visible. Intraoral teeth removal carried the risk of incomplete root removal. Cheek teeth were evaluated intraorally in all cases for signs of infection as this contributed in abscess formation.

Postoperative flushing was performed daily at home in our study, followed by application of a topical antibiotic preparation. Owners were trained to perform open wound management at home. Re-examinations continued weekly for at least 1 month. Systemic and topical antibiotics should be administered for 1 month along with prebiotic preparations per os. Appropriate diet and supportive nutrition (Herbivorous Critical care, Oxbow®) is mandatory, while force feeding may be necessary in anorectic cases to maintain proper gastrointestinal flora, motility and function (Papadimitriou et al., 2008; Varga and

Harcourt-Brown, 2014). Alternatively, antibiotic-impregnated-polymethylmethacrylate (PMMA) beads usually used as a bone cement in orthopaedic surgery, could have been elected. PMMA was not used as in its commercial form is combined with certain antibiotics that may not be effective to certain bacteria and no positive effect will be noticed. Another limitation was the impossible post-surgical debridement and flushing of the wound when PMMA is used (Tobias et al., 1996; Ethell et al., 2000). Another alternate topical preparation used is honey due to its hygroscopic and bactericidal properties (Oryan, and Zaker, 1998). In cases of skull abscesses, especially when bones or teeth are involved, rabbits require powerful analgesia. Meloxicam was chosen as it is effective in rabbits and was considered a safe option as long as animals are not debilitated or do not have renal insufficiency (Meredith and Flecknell, 2006; Papadimitriou et al., 2008). Buprenorphine administered orally is an alternative analgesic agent commonly used, but it is not commercially available in our country. Butorphanol may be used as well, but its analgetic action is short and should be given subcutaneously (Meredith and Flecknell, 2006).

Several diseases may lead to a retrobulbar abscess formation in a later stage of the disease, being not always easy to differentiate them. In case No 2, a para-bulbar abscess was suspected due to its location. Para-bulbar abscesses have similar clinical signs, affecting the main or the accessory lacrimal gland. A profound exophthalmos may be evident in such cases, displacing the globe laterally and caudally. In contrast to retrobulbar abscesses, in such cases pus material does not involve the orbital fossa. The treatment is similar to retrobulbar abscesses although, a shorter incision is required, pus removal is easier and marsupialization is not necessary. Post-surgical flushing may be also helpful through a small opening in the incision line and repositioning of the eye should be faster in these cases (Capello, 2016). Infection of the accessory lacrimal gland was not observed in case No 2 during surgical drainage, but it cannot be totally excluded. Other types of facial abscesses may also coexist, such as empyema of the alveolar bulla or the maxillary recess. In the former, medical treatment may be effective, while in the later rhinostomy and pararhinostomy are performed (Ward, 2006; Capello, 2016).

The outcome of appropriately treated cases (No. 1, 2, 3, 6) was satisfactory. In case No 1 an abscess in-

volving a neighbouring area was noted 1 year later and was attributed to recurrence of infection in the area of the second premolar, which had been removed. This rabbit was also the only infected with *Pseudomonas* spp. The outcome of this case was considered satisfactory as it remained free of clinical signs for a year a relatively long period for a rabbit. Case 4 was lost to follow up, while in case No 7 no intervention was attempted as it died soon after presentation. In case No5 owners were reluctant to proceed to any therapeutic intervention. In this case, a probably incomplete automatic abscess drainage occurred few days later, no dental intervention was undertaken and despite medical treatment the outcome was not satisfactory.

Pasteurella multocida infection resulted in encapsulated abscesses which were difficult to cure. Produced pus was thick and caseous and antibiotics usually do not penetrate the abscess cavity due to poor vascularization. Surgical treatment in soft tissue abscesses demands an en bloc removal, as surgical drainage may not be effective. (Deed, 1993; Tyrrell et al., 2002; Varga and Harcourt-Brown, 2014; Benato,

2017; Gardhouse et al., 2017). Sugar or honey preparations are currently used for their bacteriostatic and wound healing properties (Oryan and Zaker, 1998; Gardhouse et al., 2017). Post-surgical treatment has to be prolonged.

Prevention of retrobulbar abscesses in rabbits should include regular teeth inspection every six months or one year, maintaining of normal feeding habits with unlimited hay, grass and a good selection of vegetables offered daily. Selecting breeding stock without congenital teeth disease is also meaningful. The signs of dacryocystitis or globe protrusion may aid the veterinarian to make an early diagnosis of retrobulbar abscessation before severe complications arise.

In conclusion, treatment of retrobulbar abscesses in rabbits may be challenging and unrewarding. A multimodal approach consisting of a combination of surgical and medical treatment is often necessary for a successful outcome. Postoperative care may last for several weeks and the owner should be informed for the high relapse possibility.

REFERENCES

- Benato, L (2017) Odontogenic abscesses in pet rabbits. *Vet Rec* 181(20): 536-537.
- Capello, V (2016) Diagnostic Imaging of Dental Disease in Pet Rabbits and Rodents. *Vet Clin North Am Exot Anim Pract* 19(3): 757-782.
- Capello, V (2016) New Perspectives on Dentistry and Oral Disorders of Exotic Companion Animals. *Vet Clin North Am Exot Anim Pract* 19(3): xi-xii.
- Capello, V (2016) Surgical Treatment of Facial Abscesses and Facial Surgery in Pet Rabbits. *Vet Clin North Am Exot Anim Pract* 19(3): 799-823.
- Capello, V and Lennox A (2008). Clinical radiology of exotic companion mammals. Wiley-Blackwell, Ames, Iowa.
- Deed, B (1993) Update for veterinary practitioners on pasteurellosis in rabbits. *J. Small Exotic Anim. Med.* 2: 112-113.
- Ethell, MT, Bennett RA, Brown MP, Merritt K, Davidson JS and Tran T (2000) In vitro elution of gentamicin, amikacin, and ceftiofur from polymethylmethacrylate and hydroxyapatite cement. *Vet Surg* 29(5): 375-382.
- Gardhouse, S, Sanchez-Migallon Guzman D, Paul-Murphy J, Byrne BA and Hawkins MG (2017) Bacterial isolates and antimicrobial susceptibilities from odontogenic abscesses in rabbits: 48 cases. *Vet Rec* 181(20): 538.
- Garner, MM (2007) Cytologic diagnosis of diseases of rabbits, guinea pigs, and rodents. *Vet Clin North Am Exot Anim Pract* 10(1): 25-49.
- Harcourt-Brown, F (2002). Textbook of Rabbit Medicine, Butterworth-Heinemann, Oxford.
- Harcourt-Brown, FM (1996) Calcium deficiency, diet and dental disease in pet rabbits. *Vet Rec* 139(23): 567-571.
- Jenkins, JR (2001) Skin disorders of the rabbit. *Vet Clin North Am Exot Anim Pract* 4(2): 543-563.
- Jones, SM and Carrington SD (1988) *Pasteurella* dacryocystitis in rabbits. *Vet Rec* 122(21): 514-515.
- Marini, RP, Foltz CJ, Kersten D, Batchelder M, Kaser W and Li X (1996) Microbiologic, radiographic, and anatomic study of the nasolacrimal duct apparatus in the rabbit (*Oryctolagus cuniculus*). *Lab Anim Sci* 46(6): 656-662.
- Meredith, A and Flecknell P (2006). BSAVA manual of rabbit medicine and surgery. 2nd ed. Quedgeley, Glouce: British Small Animal Veterinary Associat.
- Ollivier, FJ, Plummer, C.E., Barrie, K.P. (2007) Ophthalmic Examination and Diagnostics, Part I: The Eye Examination and Diagnostic Procedures In: *Veterinary Ophthalmology*. 4th Blackwell Pub. Ames, Iowa: pp: 438-483.
- Oryan, A and Zaker SR (1998) Effects of topical application of honey on cutaneous wound healing in rabbits. *Zentralbl Veterinarmed A* 45(3): 181-188.
- Papadimitriou, S, Thomas ALN and Kouki M (2008) Dental problems in rabbits and rodents. *Journal of the Hellenic Veterinary Medical Society* 59(3): 225-238.
- Silverman, S and Tell L (2005). Radiology of the rodents, rabbits and ferrets. St Louis Missouri,.
- Spieß, BM (2007) Diseases and Surgery of the Canine Orbit. In: *Veterinary Ophthalmology*. 4th, Blackwell Pub. Ames, Iowa.
- Tobias, KM, Schneider RK and Besser TE (1996) Use of antimicrobial-impregnated polymethyl methacrylate. *J Am Vet Med Assoc* 208(6): 841-845.
- Tyrrell, KL, Citron DM, Jenkins JR and Goldstein EJ (2002) Periodontal bacteria in rabbit mandibular and maxillary abscesses. *J Clin Microbiol* 40(3): 1044-1047.
- Varga, M and Harcourt-Brown F (2014). Textbook of rabbit medicine: revised and edited. Edinburgh; Elsevier, New York.
- Ward, ML (2006) Diagnosis and management of a retrobulbar abscess of periapical origin in a domestic rabbit. *Vet Clin North Am Exot Anim Pract* 9(3): 657-665.
- Williams, DM (2007) Laboratory Animal Ophthalmology. *Veterinary Ophthalmology*. 4th Blackwell Pub. Ames, Iowa.

Blood Metabolic Profile in Barki Ewes during Transition Period

A. El-Sayed^a, M. El-Ashker^b, H. Ibrahim^{b*}, S. Shoieb^c, F. Ibrahim^a, M. Youssef^b,
S. El-Khodery^b

^a Department of Animal Health and Poultry, Desert Research Center, Matariya, Cairo, Egypt

^b Department of Internal Medicine, Infectious, and Fish Diseases, Faculty of Veterinary Medicine, Mansoura University, Mansoura, Egypt

^c Veterinary Teaching Hospital, Faculty of Veterinary Medicine, Mansoura University, Mansoura, Egypt

ABSTRACT: This technical research article investigated the changes in the hemato-biochemical profile in Barki ewes during the transition period. A total of 15 healthy pregnant Barki ewes (age, 4.9 ± 0.7 years old; weight, 38.5 ± 4.9 Kg) were randomly selected for the current study. Blood samples were collected from the selected ewes via jugular vein puncture during the transition period at five different time points; 4 and 2 weeks prior the estimated date of delivery (EDD), at the parturition time, then at 2 and 4 weeks post-partum. Red blood cells (RBCs) count and packed cell volume (PCV) were significantly ($P < 0.05$) decreased 2 weeks before the EDD and at the parturition time. Mean corpuscular volume (MCV) was significantly ($P < 0.05$) decreased 4 weeks post-partum. The neutrophil count and neutrophil/lymphocyte ratio were significantly ($P < 0.05$) increased 2 weeks post-partum. The level of β -hydroxy butyric acid (BHBA) and concentration of non-esterified fatty acid (NEFA) in the serum were significantly ($P < 0.05$) increased 2 weeks before EDD, at the parturition time, and 2 weeks post-partum. Both cholesterol and triglyceride levels increased significantly ($P < 0.05$) 2 weeks before EDD and at the parturition time. Leptin level was significantly ($P < 0.05$) decreased at 2 weeks and 4 weeks post-partum. Glucose level increased significantly ($P < 0.05$) at the parturition time then decreased significantly ($P < 0.05$) at 2 weeks post-partum, after which it increased again 4 weeks post-partum. Total protein level was significantly ($P < 0.05$) increased 2 weeks post-partum. The level of both calcium and inorganic phosphorus was significantly ($P < 0.05$) decreased at the parturition time and 2 weeks post-partum. The results revealed that Barki ewes showed profound physiological alterations during the transition period which are not necessarily indicative of a disease, but reflect physiological variations. Therefore, metabolic profile test was needed to determine the nutritional status of Barki ewes, and to take the possible preventive measures that increase ewes' productivity and predict health disorders.

Keywords: Hemato-biochemical profile; Transition period; Barki sheep.

Corresponding Author:

Hussam Ibrahim, Department of Internal Medicine, Infectious, and Fish Diseases,
Faculty of Veterinary Medicine, Mansoura University, Mansoura, Egypt
E-mail address: hussam-habosha@mans.edu.eg

Date of initial submission: 27-11-2018
Date of revised submission: 12-03-2020
Date of acceptance: 26-05-2020

INTRODUCTION

Transition period in ewes, 4 weeks around the time of lambing, is physiologically stressful and is considered as a crucial stage in the production cycle of sheep (Pastrana et al., 1991). During that period, significant metabolic and immunological challenges occur to meet the requirements of the animal, as approximately 75 – 80% of the fetal growth occurs in the last 4-6 weeks of pregnancy, with consequent significant productive and reproductive disorders (Sormunen-Cristian and Jauhiainen, 2001; Overton and Waldron, 2004; Balıkcı et al., 2007).

The stress of parturition, the onset of lactation, and the high turnover of fluids, salts and soluble organic materials, are the main stressful conditions for ewes at the transition period (Sormunen-Cristian and Jauhiainen, 2001; Guo et al. 2007; Constable et al., 2017). Thus, minerals' metabolism particularly calcium and phosphorus, undergoes substantial changes to maintain colostrum and milk synthesis (Yokus et al., 2004). During peri-partum period and lactation, the maternal stores are in charge for providing energy needed for production, reducing the feed intake with a negative energy balance, mobilizing the body fat, and increasing both non-esterified fatty acid (NEFA) and ketone bodies in plasma (Maas and Pearson 2009; Rukkwamsuk 2010). This information is very crucial to guarantee the metabolic and nutritional needs of ewes during early lactation (Antunović et al., 2002). Therefore, blood metabolic profile, a rapid diagnostic test, helps to monitor the nutritional and metabolic states of transitional ewes and mitigate the resulting metabolic and hormonal alterations (Van Saun, 2000).

Leptin, the hormone of energy expenditure, acts on regions of the brain involved in the regulation of energy metabolism. It participates in the co-ordination of metabolism during transition period because of its role in regulating food intake and energy deposition. The low level and/or absence of leptin in blood at transition period signals to the central nervous system that a state of energy insufficiency prevails in the periphery. Thus, many adaptations are shared, including depressed reproductive and immune functions and increased metabolic efficiency (Vernon et al., 2002).

Barki sheep, named after the Libyan province Baraka, plays a vital role in the livelihood of peoples in North-Western Coastal Zone of Egypt, which is the home tract of this breed in the country. This breed extends from the eastern provinces of Libya to the west of Alexandria in Egypt. It dominates the north west-

ern desert of Egypt with population of 470,000 heads and is known to adapt well to the harsh desert conditions and scarce vegetation, including poor feeding, and heat stress (Ahmed, 2008).

The data regarding blood metabolic profile and significance of monitoring the serum leptin in Barki ewes during transition period are still lacking. Most of the available data describing the metabolism during the transition period was carried out in other sheep breeds and not in Barki ewes. Thus, more studies are required to capture the dynamic changes in the transition period in such breed. Hence, the present study was designed to gain detailed information on the changes in the hemato-biochemical profile of the healthy Barki ewes during the transition period.

MATERIALS AND METHODS

Animals

A total of fifteen healthy pregnant Barki ewes (age, 4.9 ± 0.7 years old; weight, 38.5 ± 4.9 Kg) were selected for the current study. The selected ewes were raised in semi-open shaded pens at Mariut Research Station, Desert Research Center, Alexandria, Egypt in February 2018. The investigated ewes were subjected to thorough clinical examination according to the standard protocols (Constable et al., 2017). Accordingly, all ewes were selected to fulfill the following criteria: they were considered clinically healthy after clinical examination, were free from any nutritional and metabolic disorders or any evidence of other systemic diseases. All studied ewes were regularly dewormed twice a year, prior to spring turn out and again in the fall, according to an effective worming program. The last deworming was carried out 3 months before the start of the study using Doramectin (Dectomax Injectable solution 1 % m/v, Zoetis, Zoetis South Africa Ltd., 6th Floor, North Wing, 90 Rivonia Road, Sandton, 2196) at a dose rate of $200 \mu\text{g kg}^{-1}$ body weight as a subcutaneous injection. The pregnancy status of the selected ewes was assessed using abdominal ultrasonography. The ewes were fed green fodder (green herbage, grass and remnant of plant, berseem and darawa), when available in addition to a concentrate ration (cottonseed cake, maize, wheat or rice bran, calcium carbonate, and sodium chloride). At two months of pregnancy, each ewe received 250 gm of concentrate twice a day, and increased up to 375 gm twice a day during the last 4 weeks of pregnancy according to National Research Council (NRC, 1985), while water was always available *ad libitum*.

All investigation procedures were performed in accordance with the guidelines of Mansoura University, Mansoura, Egypt and approved by Animal Welfare and Ethical Committee, Faculty of Veterinary Medicine, Mansoura University, code No. R/13.

Blood samples

Three blood samples (5 mL each) were collected from investigated ewes at each of the five different time points; 4 and 2 weeks prior the estimated date of delivery (EDD), then at the parturition time, then 2 and 4 weeks post-partum via jugular vein puncture. The first blood sample was collected in EDTA containing vacutainer tube to assess the complete blood picture using automatic blood cell counter (Exigo—Veterinary Hematology system, Boule Medical AB, Sweden). The second blood sample was collected in sodium fluoride containing vacutainer tube and centrifuged at 3000 rpm for 15 minutes to separate the plasma for determination of the concentration of glucose by spectrophotometer using a commercial test kits (Chronolab chemicals, Barcelona, Spain). The third blood sample was collected in a plain tube and centrifuged at 3000 rpm for 15 minutes to separate the serum, which was kept frozen at -20°C for subsequent biochemical analysis. The serum biochemical parameters were spectrophotometrically analyzed using commercial test kits according to standard protocol of supplier; cholesterol and triglycerides (Chronolab chemicals, Barcelona, Spain); β -hydroxybutyrate (BHBA) (Ben Chemicals, Pakistan); total protein, albumin, calcium, inorganic phosphorus, and magnesium (BioMed, Egypt). Leptin was analyzed using sheep leptin ELIZA test kits supplied by SinoGeneclon (SinoGeneclon, Hangzhou, China). The serum NEFA was determined chemically according to the standard method (Schuster, 1979).

STATISTICAL ANALYSIS

Statistical analyses were carried out using a statistical software program (SPSS, version 21, Inc., Chicago, USA). Normal distribution of variables was tested with the Shapiro Wilks test. Data were normally distributed; therefore, mean and standard deviation were statistically analyzed and presented. Repeated measures ANOVA was used to check the assumption of sphericity using Mauchly's test of sphericity, where the P-value was > 0.05 , indicating that sphericity was met. Thus, the Sphericity Assumed in tests of within-subjects effects was used to assess the statistical significant effect of time for the different five time

points. For this test, the results were considered statistically significant at $P < 0.05$.

RESULTS AND DISCUSSION

Clinically, the investigated ewes demonstrated normal laboring of a single lamb for each and didn't express any detectable clinical alterations throughout the study period and remained clinically healthy.

In the investigated Barki ewes, red blood cells (RBCs) count and packed cell volume (PCV) were significantly ($P < 0.05$) decreased at 2 weeks before the EDD as well as at the parturition time when compared with other time points (Table 1). These findings may be caused by the stress related to parturition and lactation (Tharwat et al., 2015; Manat et al., 2016). On the other side, mean corpuscular volume (MCV) was significantly ($P < 0.05$) decreased at 4 weeks post-partum in comparison with other time points (Table 1), indicating a state of iron deficiency (microcytosis), where the cell undergoes an extra division due to insufficient hemoglobin concentration (Tharwat et al., 2015). Neutrophil count and neutrophil/lymphocyte ratio were significantly ($P < 0.05$) increased at 2 weeks post-partum when compared with other time points (Table 1), which may be attributed to lambing and lactation stress. Such stress stimulates the secretion of adrenocorticotrophic hormone, which in turn induces the adrenal cortex to produce glucocorticoids that participate in the mobilization of granulocytes from body pool into peripheral circulation. These findings were in agreement with those previously reported in goats (Adenkola et al., 2011; Tharwat et al., 2015) and dairy cattle (El-Ghoul et al., 2000). Meanwhile, the white blood cells (WBCs) count, hemoglobin (Hb) level, mean corpuscular hemoglobin (MCH), mean corpuscular hemoglobin concentration (MCHC), lymphocytes count, monocytes count, eosinophils count, and band cells count showed non-significant changes among the five different time points (Table 1).

The level of BHBA and concentration of NEFA increased significantly at 2 weeks before EDD, at the parturition time, and 2 weeks post-partum when compared to 4 weeks before EDD then returned to the basal level at 4 weeks post-partum (Table 2). This may be attributed to the disturbance of carbohydrate and fat metabolism that occurs at transition period, with a subsequent hypoglycemia and tissue lipolysis, releasing long chain fatty acids which are converted by the liver into ketone bodies (LeBlanc, 2006). In the period of early lactation, increased lipolysis occurs at

high rates with the help of insulin resistance. Thus, the net quantity of NEFA is substantially higher than the amount that can be converted in the liver (Dopel et al., 2002; Roche et al., 2013). Furthermore, dry matter intake decreased gradually in studied ewes during the last days of pregnancy with the associated negative energy balance and body fat mobilization, resulting in an increase in the level of ketone bodies,

including BHBA as well as in the concentration of NEFA in plasma (Bertics et al., 1992; Maas and Pearson 2009; Rukkwamsuk 2010; Manat et al., 2016). Moreover, the increased concentration of NEFA, at early lactation period, is beneficial for the animals to maximize milk synthesis with less glucose consumption (Mathews et al., 2016).

Table 1. Complete blood count (Mean \pm SD) in Barki ewes (n=15) during transition period

	Before EDD		At parturition time	Post-partum		P - value
	4 Weeks	2 Weeks		2 Weeks	4 Weeks	
WBCs ($\times 10^9/L$)	9.6 \pm 1.5	9.9 \pm 2.2	10.6 \pm 3.6	9.7 \pm 1.4	9.4 \pm 1.3	0.693
RBCs ($\times 10^{12}/L$)	8.9 \pm 0.5	7.0 \pm 0.9 **	7.1 \pm 0.6 **	8.9 \pm 0.7	8.5 \pm 0.9	0.003
Hb (g/dl)	10.3 \pm 0.7	9.9 \pm 0.6	10.4 \pm 0.7	9.8 \pm 1.0	10.0 \pm 0.8	0.184
PCV%	31.5 \pm 1.5	28.4 \pm 2.0 **	26.1 \pm 3.5 **	31.3 \pm 2.1	32.5 \pm 2.2	0.001
MCV (fL)	34.4 \pm 2.0	34.6 \pm 2.3	35.5 \pm 2.0	34.4 \pm 1.8	32.0 \pm 2.4 **	0.001
MCH (pg)	11.2 \pm 0.3	11.2 \pm 0.6	11.2 \pm 0.5	11.0 \pm 0.5	11.1 \pm 0.4	0.817
MCHC (g/dl)	32.9 \pm 0.9	32.3 \pm 1.0	32.2 \pm 1.0	32.1 \pm 1.4	32.3 \pm 1.2	0.337
Lymphocyte ($\times 10^9/L$)	7.1 \pm 1.2	7.2 \pm 1.6	6.3 \pm 1.9	6.3 \pm 1.6	6.3 \pm 1.5	0.255
Monocyte ($\times 10^9/L$)	0.2 \pm 0.0	0.2 \pm 0.1	0.2 \pm 0.0	0.2 \pm 0.1	0.2 \pm 0.0	0.331
Neutrophil ($\times 10^9/L$)	2.1 \pm 1.0	2.3 \pm 1.1	2.6 \pm 1.1	3.7 \pm 1.7 **	1.9 \pm 0.7	0.001
Eosinophil ($\times 10^9/L$)	0.3 \pm 0.1	0.3 \pm 0.1	0.4 \pm 0.4	0.3 \pm 0.1	0.2 \pm 0.0	0.341
Band cells	0.2 \pm 0.0	0.6 \pm 0.7	0.2 \pm 0.1	0.2 \pm 0.1	0.1 \pm 0.0	0.431

EDD, expected date of delivery; WBCs, white blood cells; RBCs, red blood cells; Hb, hemoglobin; PCV, packed cell volume; MCV, mean corpuscular volume; MCH, mean corpuscular hemoglobin; MCHC, mean corpuscular hemoglobin concentration.

Table 2. Blood metabolic profile parameters (Mean \pm SD) in Barki ewes (n=15) during the transition period

	Before EDD		At parturition time	Post-partum		P - value
	4 Weeks	2 Weeks		2 Weeks	4 Weeks	
BHBA (mmol/l)	0.8 \pm 0.1	1.4 \pm 0.5 *	1.4 \pm 0.3 *	1.3 \pm 0.3 *	0.8 \pm 0.2	0.021
NEFA (mmol/l)	1.6 \pm 0.3	2.1 \pm 0.1 *	2.2 \pm 0.1 *	2.1 \pm 0.1 *	1.7 \pm 0.2	0.035
Cholesterol (mmol/l)	2.8 \pm 0.2	3.3 \pm 0.1 *	3.4 \pm 0.1 *	2.8 \pm 0.1	2.8 \pm 0.0	0.027
Triglyceride (mmol/l)	0.7 \pm 0.1	1.0 \pm 0.1 **	0.9 \pm 0.1 **	0.4 \pm 0.2	0.4 \pm 0.2	0.001
Leptin (ug/l)	17.0 \pm 1.9	16.6 \pm 2.2	16.1 \pm 1.9	12.4 \pm 1.1 **	12.3 \pm 1.4 **	0.001
Glucose (mmol/l)	3.6 \pm 0.6	4.2 \pm 0.1	5.1 \pm 1.3 *	3.2 \pm 0.1 *	4.2 \pm 0.1	0.021
Total protein (g/l)	61.6 \pm 5.7	63.3 \pm 6.3	65.7 \pm 4.9	77.8 \pm 6.4 *	74.6 \pm 7.4 *	0.015
Albumin (mmol/L)	30.5 \pm 2.3	31.3 \pm 2.6	33.6 \pm 5.3	38.2 \pm 6.1 *	39.6 \pm 4.3 *	0.012
Calcium (mmol/L)	2.3 \pm 0.4	2.2 \pm 0.5	1.2 \pm 0.2 *	1.1 \pm 0.2 *	2.2 \pm 0.5	0.028
Inorganic phosphorous (mmol/L)	2.4 \pm 0.1	2.6 \pm 0.3	1.8 \pm 0.2 **	1.7 \pm 0.2 **	2.8 \pm 0.2	0.005
Magnesium (mmol/L)	1.4 \pm 0.7	1.2 \pm 0.6	1.2 \pm 0.7	1.1 \pm 0.9	1.2 \pm 0.9	0.128

EDD, expected date of delivery; BHBA, β -hydroxybutyric acid; NEFA, non-esterified fatty acid.

The level of both cholesterol and triglyceride increased 2 weeks before EDD and at the parturition time when compared with 4 weeks before EDD, then returned to the basal level at 2 weeks and 4 weeks post-partum (Table 2). These results reflect their increased hepatic synthesis as a result of an increase in the activities of both lipoprotein lipase and hepatic lipase, which are responsible for the catabolism of the very low density lipoprotein (Watson et al., 1993).

The leptin level showed a significant ($P<0.05$) decrease at both 2 weeks and 4 weeks post-partum compared to other time points (Table 2). This may be attributed to the energetic cost of lactation by delivering milk, together with negative energy balance as previously reported (Block et al., 2001). Therefore, undernourished animals alleviate the level of leptin, while increasing the level of cortisol, which contributes to metabolic adaptations and feeding behavior (Vernon et al., 2002; Chilliard et al., 2005).

Plasma glucose level increased significantly ($P<0.05$) at the parturition time, then decreased significantly ($P<0.05$) 2 weeks post-partum when compared with other 3 time points (Table 2). The increased glucose level at the parturition time may be attributed to the metabolic changes towards gluconeogenesis as a result of the hormonal changes that occur at such time, promoting gluconeogenesis and glycogenolysis (Vazquez-Annon et al., 1994). On the other side, the decreased glucose level at 2 weeks post-partum can be attributed to the high energy demands needed for lactation (Mohammadi et al., 2016). The glucose level increased again 4 weeks post-partum and returned to the basal level, which could be attributed to the recovery of feed intake and the decreased state of negative energy balance (Cal-Pereyra et al., 2015).

Total protein level increased significantly ($P<0.05$) at both 2 weeks and 4 weeks post-partum when compared with other time points (Table 2). In late pregnant ewes, the total protein level tends to decrease as all fetal protein was synthesized from amino acids derived from dam and the growth of fetus increases exponentially, reaching a highest level, especially the muscles (Jainudeen and Hafez, 2000). However, at early lactation period in studied ewes, total protein level increased significantly ($P<0.05$) due to the increase in immunoglobulin needed for synthesis of colostrum (Shetaewi and Daghash, 1993; Tharwat et al. 2012). In the studied Barki ewes, albumin level tends to decrease during the peri-partum period in comparison with those recorded at the parturition time and at

both 2 and 4 weeks post-partum (Table 2), suggesting a case of altered hepatocellular function and fatty liver in response to negative energy balance (Nehra et al., 2001; Tharwat et al., 2015). Moreover, a proportion of the presenting albumin in the circulating blood is correlated with calcium level. Thus, the decreased calcium level in the studied ewes may be another explanation for the low albumin level (Goff, 2000).

Calcium and inorganic phosphorus levels decreased significantly ($P<0.05$) at the parturition time and at 2 weeks post-partum when compared with other time points (Table 2), indicating profound physiological changes in both elements, but are not necessarily indicative of a disease. The decreased calcium level at transition period is a physiological state that reflects the onset of colostrum/milk production. Furthermore, the absorption of both calcium and phosphorous may be decreased from the intestine due to a fatty liver and a decrease in the number of 1,25-dihydroxyvitamin D receptors (Goff, 2000). However, the magnesium level showed non-significant changes among the five different time points (Table 2).

CONCLUSION

Barki ewes showed profound physiological alterations in certain analytes during transition period particularly β -hydroxy butyric acid (BHBA), non-esterified fatty acid (NEFA), cholesterol, triglyceride, leptin, glucose, total protein, albumin, calcium, and inorganic phosphorus, reflecting physiological variations. The results indicated that the metabolic profile test was required to determine the nutritional status of Barki ewes, and to take the potential preventive measures that increase ewes' productivity and predict health disorders.

CONFLICT OF INTEREST

None of the authors of this paper have a financial or personal relationship with other people or organizations which could inappropriately influence or biased the content of the paper.

STATEMENT OF ANIMAL RIGHTS

All Institutional and National Guidelines for the care and use of animals were followed.

REFERENCES

- Adenkola AY, Agbendeh J, Okpe J (2011) Comparative assessment of erythrocyte osmotic fragility of apparently healthy goat and cattle during the hot-dry and harmattan season in Makurdi, Nigeria. *J Anim Plant Sci* 11:1474–1480.
- Ahmed AM (2008) Biological evaluation of barki sheep under two different breeding seasons. *Egypt J Anim Prod* 45:15–24.
- Antunović Z, Senčić Đ, Šperanda M, Liker B (2002) Influence of the season and the reproductive status of ewes on blood parameters. *Small Rumin Res* 45:39–44.
- Balıkcı E, Yıldız A, Gürdoğan F (2007) Blood metabolite concentrations during pregnancy and post-partum in Akkaraman ewes. *Small Rumin Res* 67:247–251.
- Bertics SJ, Grummer RR, Cadorniga-Valino C, Stoddard EE (1992) Effect of prepartum dry matter intake on liver triglyceride concentration and early lactation. *J Dairy Sci* 75:1914–1922.
- Block S, Butler W, Ehrhardt R, Bell A, Van Amburgh M, Boisclair Y (2001) Decreased concentration of plasma leptin in periparturient dairy cows is caused by negative energy balance. *J Endocrinol* 171:339–348.
- Cal-Pereyra L, Benech A, González-Montaña JR, Acosta-Dibarrat J, Da Silva S, et al. (2015) Changes in the metabolic profile of pregnant ewes to an acute feed restriction in late gestation. *New Zeal Vet J* 63:141–146.
- Chilliard Y, Delavaud C, Bonnet M (2005) Leptin expression in ruminants: nutritional and physiological regulations in relation with energy metabolism. *Domest Anim Endocrinol* 29:3–22.
- Constable PD, Hinchcliff KW, Done SH, Grünberg W (2017) Abdominocentesis for Peritoneal Fluid. In: *Veterinary Medicine: A textbook of the diseases of cattle, horses, sheep, pigs and goats*. 11th Edition, Volume 1. Diseases of the Alimentary Tract: Non-ruminant. Missouri, United States: Elsevier Ltd. PP. 186–190.
- Doepel L, Lapierre H, Kenney J J (2002) Peripartum performance and metabolism of dairy cows in response to prepartum energy and protein intake. *J Dairy Sci* 85:2315–2334.
- El-Ghoul W, Hofmann W, Khamis Y, Hassanein A (2000) Relationship between claw disorders and the periparturient period in dairy cows. *Prakt Tierarzt* 81:862–868.
- Goff JP (2000) Pathophysiology of calcium and phosphorus disorders. *Metabolic disorders of ruminants*. *Vet Clin North Am Food Anim* 16:319–337.
- Guo J, Peters RR, Kohn RA (2007) Effect of a transition diet on production performance and metabolism in periparturient dairy cows. *J Dairy Sci* 90:5247–5558.
- Jainudeen M, Hafez E (2000) Gestation, prenatal physiology, and parturition. *Reproduction in Farm Animals*, 7th Edition, PP. 140–155.
- LeBlanc S (2006) Monitoring programs for transition dairy cows. In: *Proceedings of the 26th World Biometrics Congress, Nice*, pp. 460–472.
- Manat TD, Chaudhary SS, Singh VK, Patel SB, Puri G (2016) Hematobiochemical profile in Surti goats during post-partum period. *Vet World* 9:19–24.
- Mathews AT, Rico JE, Sprengle NT, Lock AL, McFadden JW (2016) Increasing palmitic acid intake enhances milk production and prevents glucose-stimulated fatty acid disappearance without modifying systemic glucose tolerance in mid-lactation dairy cows. *J Dairy Sci* 99:8802–8816.
- Maas J, Pearson EG (2009) Hepatic lipidosis. In: *Smith BP (Eds.) Large animal internal medicine*. 4th ed. St. Louis, USA: Mosby Elsevier 912–918.
- Mohammadi V, Anassori E, Jafari S (2016) Measure of energy related biochemical metabolites changes during peri-partum period in Makouei breed sheep. *Vet Res Forum* 7:35–39.
- Nehra V, Angulo P, Buchman AL, Lindor KD (2001) Nutritional and metabolic considerations in the etiology of nonalcoholic steatohepatitis. *Dig Dis Sci* 46:2347–2352.
- NRC (1985) Nutrient requirements of sheep. 6th Revised Edition. Subcommittee on Sheep Nutrition, Committee on Animal Nutrition, Board on Agriculture and Natural Resources, National Research Council, National Academy Press, Washington, D.C.
- Overton TR, Waldron MR (2004) Nutritional management of transition dairy cows: Strategies to optimize metabolic health. *J Dairy Sci* 87:E105–E119.
- Pastrana R, McDowell L, Conrad J, Wilkinson N (1991) Macromineral status of sheep in the Paramo region of Colombia. *Small Rumin Res* 5:9–21.
- Roche JR, Bell AW, Overton TR, Loores J.J (2013) Invited review: Nutritional management of the transition cow in the 21st century – a paradigm shift in thinking. *Anim Product Sci* 9, 1000–1023.
- Rukkamsuk T (2010) A field study on negative energy balance in periparturient dairy cows kept in small-holder farms: Effect on milk production and reproduction. *Afr J Agric Res* 5:3157–3163.
- Schuster G (1979) Estimation of free fatty acids. *Clin Biochem* 10:24.
- Shetaewi M, Daghash H (1993) Effects of pregnancy and lactation on some biochemical components in the blood of Egyptian coarse-wool ewes. *Assiut Vet Med J* 30:64–64.
- Sormunen-Cristian R, Jauhiainen L (2001) Comparison of hay and silage for pregnant and lactating Finnish Landrace ewes. *Small Rumin Res* 39:47–57.
- Tharwat M, Oikawa S, Buczinski S (2012) Ultrasonographic prediction of hepatic fat content in dairy cows during the transition period. *J Vet Sci Technol* 3:111.
- Tharwat M, Ali A, Al-Sobayil F (2015) Hematological and biochemical profiles in goats during the transition period. *Comp Clin Path* 24:1–7.
- Van Saun R (2000) Blood profiles as indicators of nutritional status. *Proceedings of the 18th Annual Western Canadian Dairy Seminar*, March 1–20, 2000, Alberta, Canada, pp 1–6.
- Vernon RG, Denis RG, Sorensen A, Williams G (2002) Leptin and the adaptations of lactation in rodents and ruminants. *Horm Metab Res* 34:678–685.
- Watson T, Burns L, Packard C, Shepherd J (1993) Effects of pregnancy and lactation on plasma lipid and lipoprotein concentrations, lipoprotein composition and post-heparin lipase activities in Shetland pony mares. *J Reprod Fertil* 97:563–568.
- Yokus B, Cakir DU, Kurt D (2004) Effects of seasonal and physiological variations on the serum major and trace element levels in sheep. *Biol Trace Elem Res* 101:241.

***In vitro* anticoccidial activity of *Vitis vinifera* extract on oocysts of different *Eimeria* species of Broiler Chicken**

R.Z. Abbas¹, A. Abbas^{*2}, Z. Iqbal², M.A. Raza², K. Hussain², T. Ahmed³, M.U. Shafi³

¹*Department of Parasitology, University of Agriculture, Faisalabad, Pakistan*

²*Department of Veterinary and Animal Sciences, Muhammad Nawaz Sharif University of Agriculture Multan, Pakistan*

³*Department of Clinical Medicine, Bahauddin Zakriya University, Multan*

⁴*Department of Animal Breeding and Genetics, University of Agriculture, Faisalabad, Pakistan*

ABSTRACT: In the current experiment, the *in vitro* anticoccidial effect of *Vitis vinifera* (grape seed) extract was evaluated. For this purpose, an *in vitro* sporulation inhibition assay was used. Collected oocysts of four *Eimeria* species (*E. tenella*, *E. necatrix*, *E. brunetti* and *E. mitis*) were exposed to six different concentrations (w/v) of *Vitis vinifera* extract (VVE) in 10% Dimethylsulphoxide solution (DMSO), while Dimethylsulphoxide (DMSO) and Potassium dichromate solution ($K_2Cr_2O_7$) served as control groups. The results of the present study revealed that *V. vinifera* extract showed inhibitory effect on sporulation (%) and damage (%) of *Eimeria* oocysts in a dose dependent manner as compared to both control groups. *V. vinifera* extract also damaged the morphology of oocysts in terms of shape, size and number of sporocysts.

Keywords: *Vitis vinifera*, *in vitro*, *Eimeria*, oocysts

Corresponding Author:

A. Abbas, Department of Veterinary and Animal Sciences, Muhammad Nawaz Sharif University of Agriculture Multan, Pakistan
E-mail address: abbasasghar255@gmail.com

Date of initial submission: 14-12-2018
Date of revised submission: 14-12-2018
Date of acceptance: 24-04-2020

INTRODUCTION

Coccidiosis is an important disease infecting the intestine of chicken, which is caused by *Eimeria* (protozoa) species (Alzahrani *et al.*, 2016; Abbas *et al.*, 2019a). Coccidiosis causes heavy economic losses to poultry farming in different parts of world (Bachaya *et al.*, 2015; Abbas *et al.*, 2017). Disease has various clinical features such as poor weight gain, high mortality and bloody feces (Masood *et al.*, 2013). Oocysts of *Eimeria* sporulate rapidly in soil having high multiplication rate due to which its prevention is difficult once its outbreak has occurred at poultry farm (Zaman *et al.*, 2012). Poultry coccidiosis has been controlled by using synthetic anticoccidial drugs but, due to their frequent and irrationale use resistance has been developed due to which this method is ineffective in controlling of disease (Alzahrani *et al.*, 2016; Abbas *et al.*, 2017).

So, in matter of achieving success in controlling this severe disease other options and protocols are effectively used in different countries of world (Zhang *et al.*, 2018; Bakr *et al.*, 2019; Sarwar *et al.*, 2019). Among other options plant-derived compounds and their products have shown better anticoccidial effects (Gadelhaq *et al.*, 2018; Farieha *et al.*, 2019; Zhang *et al.*, 2020). Botanicals such as *Camellia sinensis* (Abbas *et al.*, 2017), *Ageratum conyzoides* (Nweze and Obiwulu, 2009), *Vitis vinifera* (Wang *et al.*, 2008), *Saccharum officinarum* (Abbas *et al.*, 2015) are reported to have excellent anticoccidial and immunomodulatory activity against coccidiosis.

Vitis vinifera commonly known as grape is one of the most abundant cultivated plants all over the world and is rich with various usefull antioxidant compounds including flavanoids, anthocyanins, catechin and epicatechins. These antioxidant compounds are well known for their therapeutic, health beneficial and immunomodulatory effects in poultry and other livestock (Kara *et al.*, 2016; Kasapidou *et al.*, 2016). Due to its availibilty in large quantity and its content in bioactive compounds contained in it is a suitable candidate for improving poultry production.

Based on the various therapeutic and health beneficial effects of *V. vinifera* and very limited published research on its effect against *Eimeria*, the current experiment was conducted to evalaute *in vitro* anticoccidial potential of *V. vinifera* extract a on oocysts of four *Eimeria* species of broiler chicken.

MATERIALS AND METHODS

Preparation of *Vitis vinifera* extract

Seeds of *V. vinifera* were obtained from local market in Faisalabad, Pakistan. The plant material were authenticated by botanist of University of Agriculture Faisalabad and were dried and converted in powder form using an electric grinder. Aqueous methanolic extract of *V. vinifera* (seeds) was prepared using using Soxhlet's apparatus (Velp Italy) following method described by Abbas *et al.* (2015). Prepared *V. vinifera* extract (VVE), was stored at 4°C untill further use.

Collection of *Eimeria* oocysts

Oocysts of four *Eimeria* species were collected from the caeca of infected broilers from different reported cases in Faisalabad. Collected oocysts were preserved in potassium dichromate solution (2.5%) following the procedure as described by Ryley *et al.* (1976).

Experimental design

The experiment was reviewed and approved by Research and Ethics Committee of Department of Parasitology, University of Agriculture Faisalabad, Pakistan. *In vitro* efficacy of *V. vinifera* extract (VVE) was evaluated by a sporulation inhibition assay. For this purpose, unsporulated oocysts (100 oocysts/5ml) of four *Eimeria* species (*E. tenella*, *E. brunetti*, *E. necatrix* and *E. mitis*) were exposed to different concentrations (w/v; 10, 5, 2.5, 1.25, 0.625 and 0.31%) of VVE in 10% Dimethylsulfoxide (DMSO) solution in 5cm petri dishes by making two fold serial dilutions. DMSO and potassium dichromate solution ($K_2Cr_2O_7$) served as control groups. Incubation of *Eimeria* oocysts was done for 48 hours at 27-29°C and 60% humidity. Three replications were made for each concentration. The sporulation process of *Eimeria* oocysts was checked under light microscope at 40x. A total of 40 oocysts for each *Eimeria* species were counted in all treatment and control groups. The oocysts with 4 sporocysts was considered sporulated regardless the shape and size of the sporocysts. *Eimeria* oocysts having damaged wall and misshapen were considered damaged. The Percentage of sporulation and damaged of each *Eimeria* species was determined out of total counted oocysts. Sporulation inhibition (SI) and damage of *Eimeria* oocysts was determined in percentage by following the method by You (2014).

Statistical analysis

Data were analyzed by Analysis of Variance

(ANOVA) and significance among groups was determined at $P < 0.05$. For comparisons of means Duncan's multiple range test was used.

RESULTS

The statistical analysis showed that all dilutions of *V. vinifera* extract (VVE) significantly affected the sporulation process of *Eimeria* oocysts of all the four species (*E. tenella*, *E. necatrix*, *E. brunetti* and *E. mitis*) as compared to both control groups (Control 1: DMSO, Control 2: Potassium dichromate solution ($K_2Cr_2O_7$)) Figure 1. Effect of *Vitis vinifera* on percent damage of *Eimeria* oocysts is shown in Figure 2. *V. vinifera* extract damaged internal and external the morphology of of *Eimeria* oocysts in concentration-de-

pendent manner as compared to both control groups (Control 1: DMSO, Control 2: Potassium dichromate solution ($K_2Cr_2O_7$)). Among all tested *Eimeria* species *V. vinifera* extract at higher dose significantly reduced sporulation process and damaged oocysts of *E. tenella* and *E. necatrix*. Oocysts of four *Eimeria* species (*E. tenella*, *E. necatrix*, *E. brunetti* and *E. mitis*) were differentiated on the basis of their morphology following method as described Abbas *et al.* (2019b). Photomicrographs of normal *Eimeria* oocysts and damaged *Eimeria* oocysts by *V. vinifera* extract in terms shape and wall are shown in Figure 3. It can be clearly seen in Figure 3 that *V. vinifera* extract inhibited sporulation and also damaged the morphology of *Eimeria* oocysts.

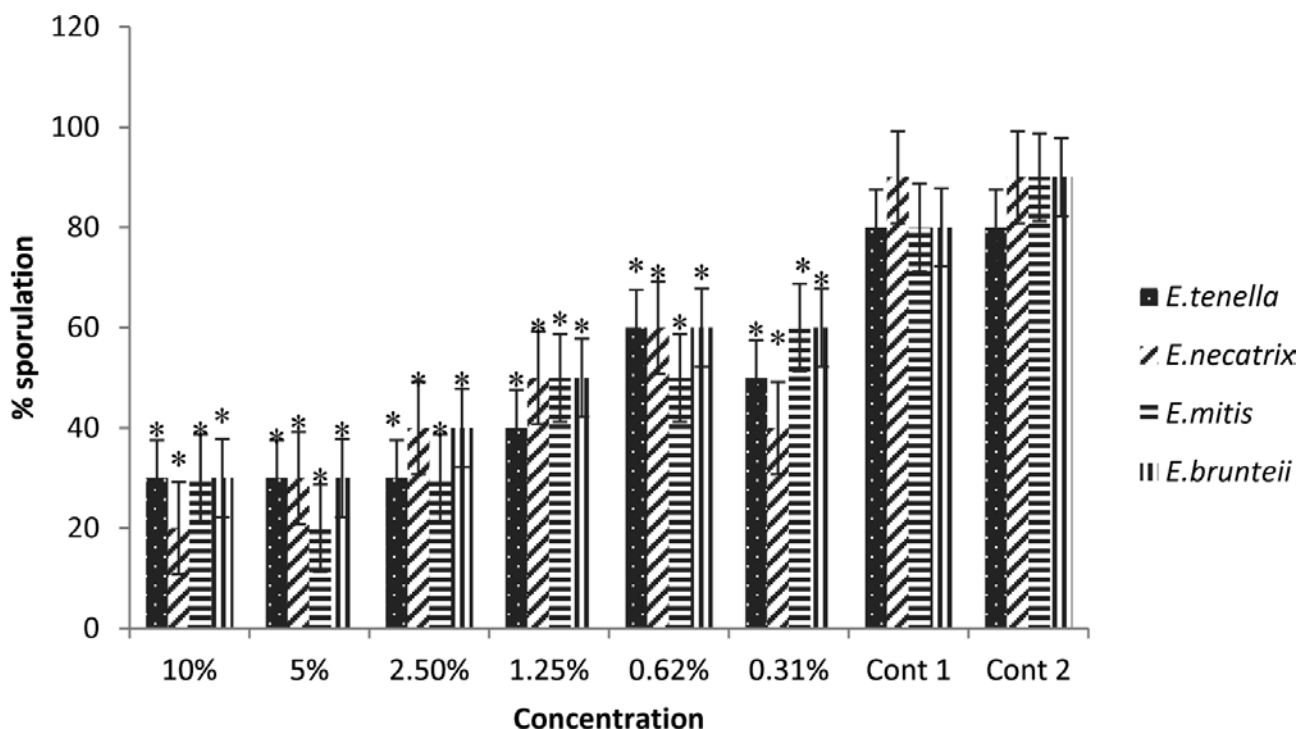


Figure 1: Effect of *V. vinifera* extract on % sporulation of oocysts of four *Eimeria* species Control-1 (DMSO) and Control-2 ($K_2Cr_2O_7$). Asterisks (*) indicate a difference from the control groups

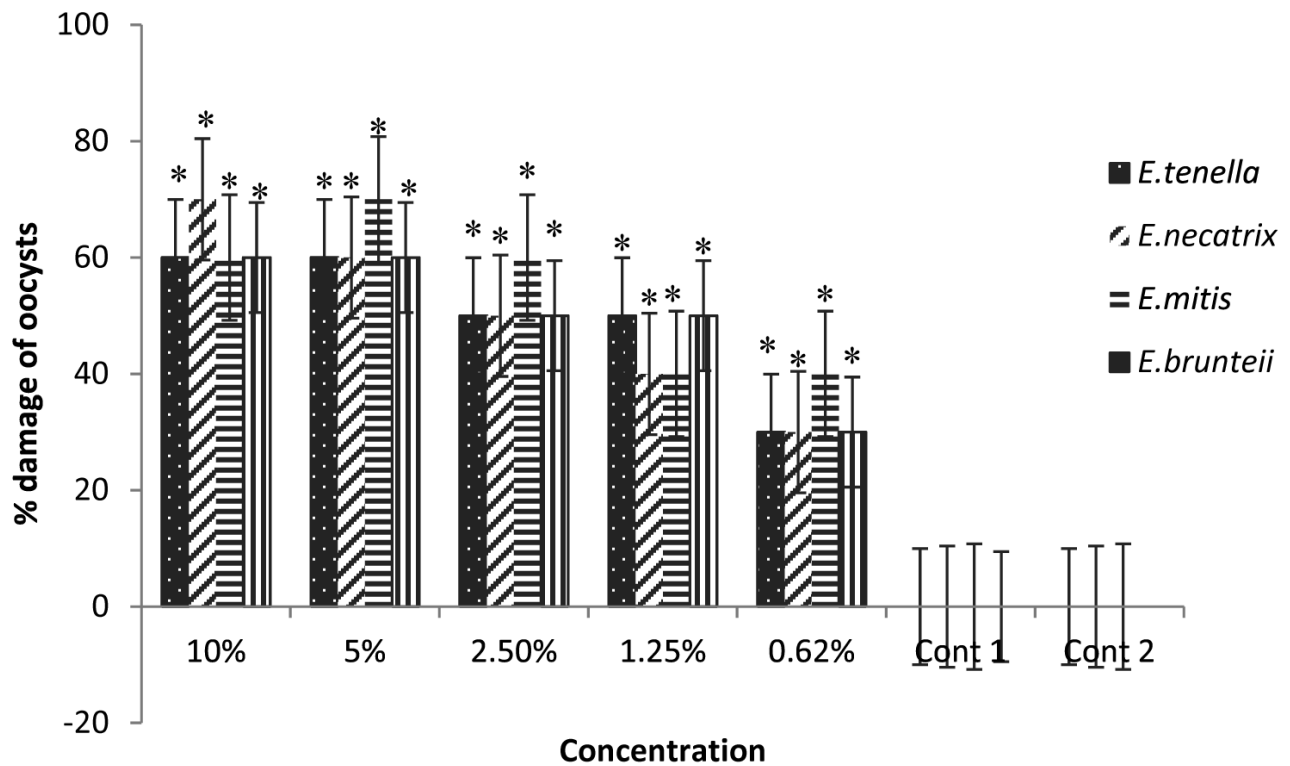


Figure 2: Effect of *Vitis vinifera* extract on percent damage of oocysts of four *Eimeria* species. Control-1 (DMSO) and Control-2 ($K_2Cr_2O_7$). Asterisks (*) indicate a difference from the control groups




Figure 3: Photomicrographs of *Eimeria* oocysts

A: Normal sporulated oocysts of *Eimeria*.

B & C: Damaged *Eimeria* oocysts by *V. Vinifera* extract in terms shape and wall

DISCUSSION

Many botanicals and their products are reported to have excellent anticoccidial activity as proven by different *in vitro* and *in vivo* studies (Abbas *et al.*, 2015, 2017). In the present, as well as in previous studies (Zaman *et al.*, 2012; Gadelhaq *et al.*, 2018; Mujahid *et al.*, 2019), the *in vitro* anticoccidial effect of *V. vinifera* extract was measured in terms of percent sporulation inhibition and damage of *Eimeria* oocysts. The results showed an inhibitory effect on sporulation and damage of *Eimeria* oocysts in dose dependent manner.

In addition, *V. vinifera* extract also affected the morphology of *Eimeria* oocysts in terms of abnormal shape of oocysts and sporocysts. Likewise, an aqueous extract of pine bark also showed a similar effect on sporulation of *Eimeria* oocysts (Molan *et al.*, 2009). In a recent study, Gadelhaq *et al.* (2018) have reported the *in vitro* anticoccidial effects of chemicals and natural products. They concluded that commonly used disinfectants such as formalin and ethanol (70%) are the most effective in inhibition of sporulation process of different *Eimeria* species.

Abbas *et al.* (2019b) has reported *in vitro* anticoccidial effects of *Trachyspermum ammi* extract on oocysts of four *Eimeria* species of chickens. *T. ammi* inhibited sporulation of *Eimeria* oocysts and also damaged them. *T. ammi* effect was in dose dependent manner against *Eimeria* oocysts.

Abbas *et al.* (2015) have reported a similar, dose-dependent, *in vitro* anticoccidial effect of *S. officinarum* (sugar cane) extract on inhibition sporulation of *Eimeria* oocysts in dose dependent manner. Such high *in vitro* anticoccidial potential of *V. vinifera* extract might be due to action of its antioxidant compounds against *Eimeria*.

Somewhat similar *in vitro* effects of *Camellia sinensis* on the sporulation of various *Eimeria* species

has been reported previously and a significant reduction in sporulation rate of *Eimeria* oocysts was observed after exposure to *C. sinensis* extract (Molan and Thomas, 2007).

In another study, *in vitro* destruction of *Eimeria* oocysts by essential oils has been reported (Remmal *et al.*, 2013).

In the present study *V. vinifera* showed an *in vitro* anticoccidial potential against *Eimeria* oocysts which might be due to the action of its various flavonoids so-called antioxidant compounds including anthocyanins, catechin and epicatechins. However further studies and *in vivo* trials are needed to understand its anticoccidial effect in poultry.

CONCLUSION

It was concluded from the results of the present study that *V. vinifera* (grape seed) extract have *in vitro* anticoccidial potential against four *Eimeria* species. *V. vinifera* extract damaged the morphology and inhibited the sporulation process of *Eimeria* oocysts of all tested species. *In vitro* results of this study can help in future to explore and develop effective herbal remedy based on antioxidant compounds of *V. vinifera* by conducting *in vivo* trials for treating poultry coccidiosis.

ACKNOWLEDGEMENTS

All Authors acknowledge the financial support for this work from Punjab Agricultural research board (PARB), Pakistan.

CONFLICT OF INTEREST

The authors have no conflict of interest with this publication.

REFERENCES

- Abbas A, Z Iqbal, Abbas RZ, Khan MK, Khan JA (2017) Immunomodulatory activity of *Pinus radiata* extract against coccidiosis in broiler chicken. Pak Vet J 37: 145-149.
- Abbas A, Abbas RZ, Khan MK, Raza MA, Mahmood MS, Saleemi MK, Hussain T, Khan JA, Sindhu ZD (2019a) Anticoccidial Effects of *Trachyspermum ammi* (Ajwain) in broiler chickens. Pak Vet J 39: 301-304.
- Abbas A, Abbas RZ, Raza MA, Khan MK, Saleemi MK, Saeed Z (2019b) *In vitro* anticoccidial activity of *Trachyspermum ammi* (Ajwain) extract on oocysts of *Eimeria* species of Chicken. Adv Life Sci 7: 44-47.
- Alzahrani F, Al-Shaebi EM, Dkhil MA, Al-Quraishy S (2016) *In vivo* anti-*Eimeria* and *in vitro* anthelmintic activity of *Ziziphusspina-christi* leaf extracts fares, Pak J Zool 48: 409-413.
- Abbas A, Iqbal Z, Abbas RZ, Khan MK, Khan JA (2015) *In-vitro* anticoccidial potential of *Sacharrumofficinarum* extract against *Eimeria* Oocysts. Bollatinoam. Caribe Plantas Med Aromát14: 456-46.
- Bachaya HA, Abbas RZ, Raza MAM, Iqbal Z, Rehman TU, Baber W, Hussain R (2015). Existence of coccidiosis and associated risk factors in broiler chickens in Southern Punjab, Pakistan. Pak Vet J 35: 81-84.
- Bakr AF, Abdelgayed SS, EL-Tawil OS, Bakeer AM (2019) Assessment of ginger extract and ginger nanoparticles protective activity against acetaminophen-induced hepatotoxicity and nephrotoxicity in rats. Pak Vet J 39: 479-486.
- Faricha, Jahan N, Rehman KU and Ali S (2019) Effect of herbal mixture as Angiotensin converting enzyme inhibitor in Angiotensin-II dependent hypertension. Pak Vet J 39: 25-30.
- Gadelhaq SM, Arafa WM, Abolhadid SM (2018) *In vitro* activity of natural and chemical products on sporulation of *Eimeria* species oocysts of chickens. Vet Parasitol 251:12-6.
- Kara K, Guclu BK, Baytok E, Senturk M (2016) Effects of grape pomace supplementation to laying hen diet on performance, egg quality, egg lipid peroxidation and some biochemical parameters. J Appl Animal Res 44: 303-10.
- Kasapidou E, Soddidou EN, Zdragas A, Papadaki C, Vafeas G, Mtianga P (2016) Effect of grape pomace supplementation on broiler meat quality characteristics. Eur Poult Sci 80:135-42
- Mujahid H, Hashmi AS, Khan MZ, Tayyab M, Shezad W (2019) Protective effect of yeast sludge and whey powder against ochratoxigenesis in broiler chicks. Pak Vet J 39: 588-592.
- Masood S, Abbas RZ, Iqbal Z, Mansoor MK, Sindhu ZD, Zia MA, Khan JA (2013) Role of natural antioxidants for the control of coccidiosis in Poultry. Pak Vet J 33: 401-407.
- Molan AL, Thomas DV (2007) Green tea water extracts inhibit the sporulation of *Eimeria* oocysts *in vitro*. Advancing Poultry Production – Proceedings of the Massey Technical Update Conference. 9: 89–97.
- Molan AL, Zhuojian L, De S (2009) Effect of pine bark (*Pinusradiata*) extracts on sporulation of coccidian oocysts. Folia Parasitol 56: 1–5.
- Nweze NE, Obiwulu IS (2009) Anticoccidial effects of *Ageratum conyzoides*. J Ethnopharmacol 122: 6–9
- Remmal A, Sanaa A, Latifa B, Fouzia C, Najat C (2013) Oocysticidal Effect of Essential Oil Components against Chicken *Eimeria* Oocysts. Int J Vet Med 2: 133-139.
- Ryley JF, Meade R, burst JH, Robinson TE (1976) Methods in coccidiosis research: Separation of oocysts from faeces. J Parasitol 73: 311-326.
- Sarwar N, Mehmood A, Sheraz A, Noman M (2019) Protective effect of probiotics in combination with vaccination on antibody response, biochemical and hematological indices in broilers. Pak Vet J 39: 451-454.
- You MJ (2014) Suppression of *Eimeria tenella* sporulation by disinfectants. Korean J Parasitol 52: 435–438.
- Wang MI, Suo X, , Gu JH, Zhang WW, Fang Q, Wang X (2008) Influence of grape seed proanthocyanidin extract in broiler chickens: effect on chicken coccidiosis and antioxidant status. Poult Sci 87:2273-2280.
- Zaman MA, Iqbal Z, Abbas RZ, Khan MN (2012) Anticoccidial activity of herbal complex in broiler chickens challenged with *Eimeria tenella*. Parasitology 139: 237-243.
- Zhang QH, Nie FH, Wang XN, Lin HY, Wang HCR, Gooneratne R, Chen JJ (2018) Effect of flavonoids from *Eupatorium odoratum* L. on immunoglobulins and cecal microflora in broilers. Pak Vet J 38: 296-300.
- Zhang K, Li X, Na C, Abbas A, Abbas RZ, Zaman MA (2020) Anticoccidial effects of *Camellia sinensis* (green tea) extract and its effect on Blood and Serum chemistry of broiler chickens. PakVet J 40: 77-80

Comparative efficacy of Amprolium, Garlic oil (*Allium sativum*) and Ginger oil (*Zingiber officinale*) against Coccidiosis in common quail (*Coturnix coturnix*)

M. Asghar¹, U.F. Durrani¹, R. Hussain¹, K. Matloob¹, A.K. Mahmood¹, M. Anees²,
M. Oneeb³

¹Pet Centre, University of Veterinary and Animal Sciences, Lahore, Pakistan.

²Veterinary Research Institute, Zarar Shaheed Road, Lahore, Pakistan.

³Department of Parasitology, University of Veterinary and Animal Sciences, Lahore, Pakistan.

ABSTRACT: In birds, *Eimeria species* are commonly reported coccidian parasites that cause anorexia, debilitation, bloody diarrhea, mortalities and economical losses. This study was conducted on 30 clinical cases of common quails presented at Pet Centre, University of Veterinary and Animal Sciences, Lahore, suffering from coccidiosis. The aim of this study was to evaluate *in vivo* comparative anti-coccidial efficacy of amprolium, garlic oil and ginger oil. Drinking water of affected birds was supplemented with amprolium (130 mg/1000 mL), garlic oil (150µL/100 mL) and ginger oil (150µL/100 mL) for 15 days and fecal sample screening for coccidia oocyst count was performed on days 0, 3, 5, 7, 11 and 15 using direct microscopy with fecal floatation method and McMaster chamber counting technique. Data was statistically analyzed which revealed that amprolium showed highest and rapid efficacy against coccidiosis with complete disappearance of oocysts and improved activity level with better health, increased feed intake and normal feces on day 11, followed by garlic oil that showed recovery from oocysts on day 15, whereas in ginger oil treated birds oocysts were present till the end of study. It was concluded that amprolium is highly effective against coccidiosis followed by garlic oil; on the other hand, ginger oil was not clinically effective for the treatment of coccidiosis in quails.

Keywords: Quail, Coccidiosis, Garlic oil, Amprolium, Ginger oil.

Corresponding Author:

Uzma Farid Durrani
Pet Centre, University of Veterinary and Animal Sciences, Outfall Road,
Lahore-54000, Pakistan
E-mail address: ufdurrani@uvas.edu.pk

Date of initial submission: 10-06-2019
Date of revised submission: 10-03-2020
Date of acceptance: 07-06-2020

INTRODUCTION

Coccidiosis is a subclinical to clinical cosmopolitan protozoal disease of birds causing cachexia and mortality in severe cases (Bozkurt et al. 2014, Akhtar et al. 2012). As spores enter the body, they cause intestinal epithelial damage which leads to abdominal pain, anorexia, cachexia, impaired absorption of nutrients and diarrhea that may contain mucous and blood (Bello et al.). Different drugs are recommended against coccidiosis in birds but potential hazard of drug resistance with noxious results on bird's fitness hinders their use every time. Modern therapeutic preferences against coccidian include herbal medicines which do not have any harmful effect on end consumer. Among various herbal remedies garlic has anti-bacterial, anti-viral and anti-parasitic effects mainly because of high concentration of sulfur compounds (Gebreyohannes and Gebreyohannes 2013). Similarly, ginger also has anti-parasitic and anti-protozoal activities whereas; on commercial scale, amprolium is the most commonly used anti-coccidial drug. The present study was designed to evaluate in vivo efficacy of commercially used amprolium with herbal products viz. garlic and ginger oils against coccidiosis in quail.

MATERIALS AND METHODS

The study was conducted on different clinical cases of diarrhea in common quail (*Coturnix coturnix*) reported at Pet Centre, University of Veterinary and Animal Sciences (UVAS), Lahore, Pakistan. Suspected cases were isolated for laboratory investigation through double fecal examination at Pet Centre diagnostic Laboratory, till the random selection of 30 adult quails. The recruitment took 1 month and 17 days¹. No control group was included due to welfare and ethical restrictions for diseased birds. The selected birds were acquired from the owners for this study (after confirmation for oocysts in fecal samples). After completion of count of 10 birds, they were labeled; oocysts were enumerated from each individual's fecal sample and then shifted together, treatment protocols were started soon afterwards.

1. Management of selected birds

The quails were housed in bird cages (10 quails in a cage measuring 43 cm x 38 cm x 27 cm) in well ventilated and lit area. Prior to the shifting of birds all

cages were cleaned with Bectol Plus (Chlorhexidine Gluconate Soln. I.P. 1.5%) solution through spraying followed by fumigation with potassium permanganate 1gm/liter and 10% formalin solutions in 1 liter of water. All birds had ad-libitum access to fresh clean water and commercial feed (National Feed Pakistan, no. 14).

2. Grouping of study birds:

The selected quails were equally divided into 3 groups (A, B, C) having 10 birds each. Treatment was provided for 15 days. Pre and post treatment fecal samples were collected on days 0, 3, 5, 7, 11, and 15.

3. Laboratory processing:

Each fecal sample was processed in Pet Centre diagnostic laboratory as per following protocol:

i. Floatation Technique

- Saturated solution of sodium chloride was prepared and the specific gravity of solution was adjusted at 1.18 using hydrometer.
- One gram of fecal sample was mixed with 14 mL tap water in 100 mL beaker.
- Mixture was thoroughly mixed, sieved and shifted to another beaker.
- The mixture was centrifuged at 1500 rpm for 2 minutes.
- After centrifugation, supernatant was discarded and packed sediment was stirred together and shifted in a test tube.
- Saturated NaCl solution was added in the test tube up to the complete fill. The sample was turned upside down several times to mix the sediment.
- A cover slip was placed onto the test tube so that it touched the surface of the contents of test tube for 5 minutes.
- The cover slip was removed and placed on a glass slide and observed under microscope under magnification 4X, 10X to confirm the presence of *Eimeria species* oocysts.

ii. McMaster Technique

It is a quantitative technique for measuring the number of oocysts in one gram of fecal sample. The technique was performed as follows:

¹ Coccidiosis is endemic in Pakistan, with frequent temporal and spatial epidemics. As the sample patients were recovered from quail farms, and other bird markets during an epidemic in 2019, that's why there was no issue in collection or maintaining the study groups.

- One gram of fecal sample was mixed with 14 mL tap water in 100 mL beaker.
- Mixture was mixed thoroughly, sieved and shifted to another beaker.
- The mixture was centrifuged at 1500 rpm for 2 minutes.
- A 0.15 mL of the sediment was collected using pipette, and added to both compartments of McMaster slide. The system was left undisturbed for 5 minutes.
- McMaster chambers were observed under microscope at 10X, and oocysts were counted inside the lined area of both chambers.
- Total oocytes calculation in one gram of sample was calculated using the following formula:

$$\frac{\text{Number of oocysts per gram of feces} \times X}{0.15} \times 15 \times 1$$

OR

$$\text{Number of oocysts per gram of feces} = X \times 100$$

Where,

$$\frac{X}{0.15} = \frac{\text{Average number of oocysts in counting chamber}}{\text{Volume of sample in 1 cm}^2 \text{ of chamber}}$$

15: Total volume of sample (14mL water + 1g of sample)

01: correction factor for 1g of fecal sample

4. Protocol of Medication

Group A: 130 mg/1000mL in drinking water.

Group B: Pure garlic oil @ 150µL/100mL in drinking water.

Group C: Pure ginger oil @ 150µL/100mL in drinking water.

5. Parameters of Study:

Following were the parameters of this study.

- Oocysts count
- Feed intake Body weight
- Activity level
- Mortality

6. Statistical Analysis:

The research data were analyzed statistically using analysis of variance (ANOVA) and chi square test (where applicable) on SPSS version 16.0.

RESULTS

At the beginning of this study all birds were showing weight loss, ruffled feathers, huddling, depression, anorexia, and watery/bloody diarrhea. After initiation of the treatment improvement was observed in general health status that included decreased oocyst count, increased feed intake, weight gain and activity level.

Oocysts Count:

A decrease in oocysts count was observed during a period of 0-15 days in group A. Statistically, multivariate analysis revealed significant difference ($P < 0.05$) in oocyst count per gram of fecal sample from days 0-15 in all treated birds. In group B, a significant lowering ($P < 0.05$) of infection load in all birds was observed. In group C, a decrease in number of oocysts from days 0-15 was observed but all birds were positive for coccidia till the end of study and no significant improvement was observed in overall health status or oocyst count reduction ($P > 0.05$). (Fig. 1)

Feed Intake and body weight:

In group A, statistical analysis revealed a significant difference ($P < 0.05$) of quantity of feed intake with improved health between days 0 and 15. In group B, there was significant increase in feed intake from day 5 to 10 but both these parameters were non-significant between days 10 to 15 ($P > 0.05$). In group C, there was non-significant ($P > 0.05$) increase in feed intake from day 5 to 15 and showed a constant level of feed intake from days 5 to 15, weight gain responded the treatment same way around (Fig. 2 & 3). Respectively, among group A, B and C statistical analysis revealed a significant difference of quantity of feed intake ($P < 0.05$).

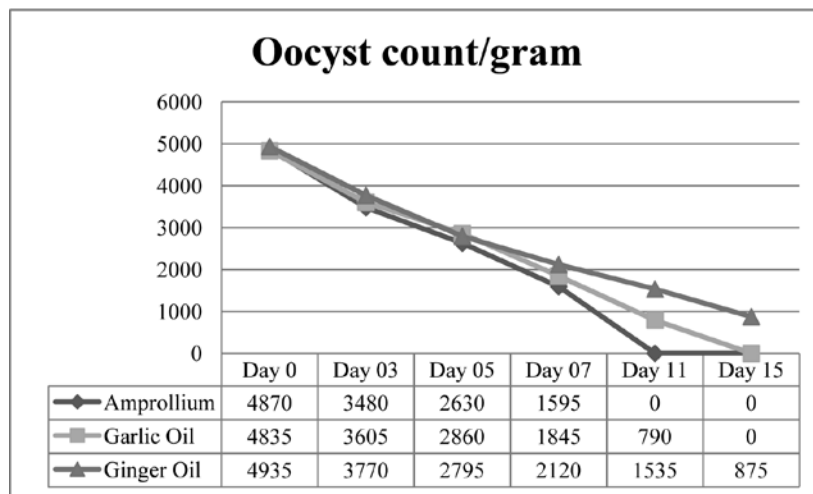


Figure 1: Oocyst count per gram during treatment (overall trend indicating efficacy of Amprolium, Garlic oil and Ginger oil)

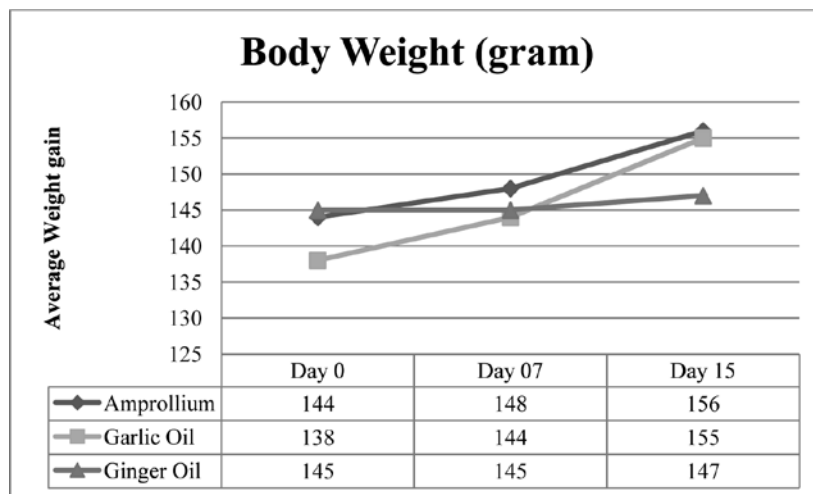


Figure 2: Body weight (overall trend between groups during treatment)

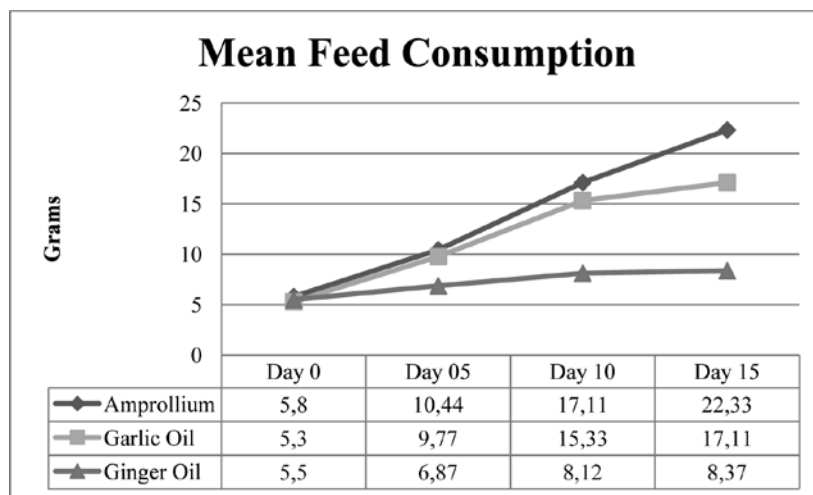


Figure 3: Mean feed consumption in all groups during treatment

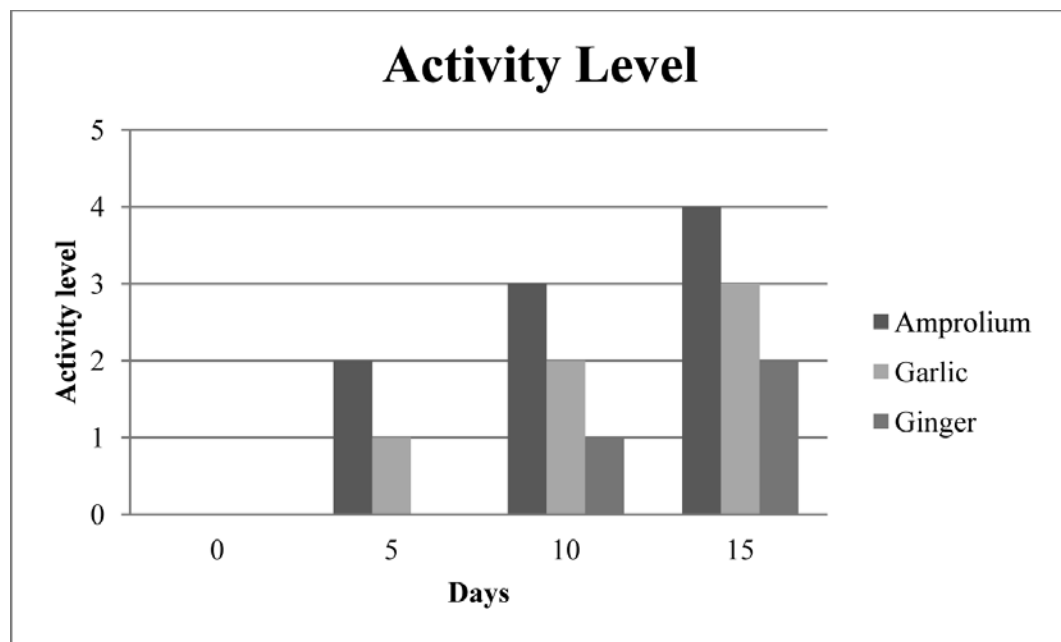


Figure 4: Activity level of birds during treatment

Activity level of birds and mortality:

All the birds in group A, B and C were presenting signs of general dullness and depression on day 0 but with the passage of time and treatment there was significant increase ($P < 0.05$) in general activity level of all birds in group A, B with slight improvement of birds in group C from days 0-15. The activity levels are presented in Fig. 4, in which “1” was marked as no to very less activity followed by “2” which demonstrated mild activity but huddling was still present whereas, “3” denoted as active and bright with less huddling and almost normal activities and “4” described as the optimal activity pattern.

In group A and B, acute mortalities were observed on day 02 of study. The clinical signs of those birds included severe dehydration and emaciation. On post-mortem examination, there was emphysemation of intestines and after the removal of contents, mucosal sloughing and diffused, multifocal mucosal necrotic foci were observed. No further mortality was observed in these groups. Two mortalities were observed in group C, on days 02 and 05 of study. Postmortem findings were as same as in groups A and B.

DISCUSSION

Coccidiosis is an important imperative peculiarity in the fowl production around the World. In present study amprolium, garlic oil and ginger oil showed their effect on body weight of all birds in varying degree.

Study was performed by Ali et al. (2019), in which the author evaluated the comparative efficacy of garlic, ginger and amprolium against coccidiosis in broiler chicken and found that the oocysts reduction was highest in amprolium treated group followed by garlic and ginger treated groups. Same trend was observed in mean body weight in which amprolium treated group gained highest weight followed by garlic and ginger till the end of the study. Both the parameters had same results as of the present study but a different trend of feed intake was observed in which feed intake remained highest in amprolium treated group, followed by ginger and garlic treated groups.

As garlic oil has sulphur comprising compounds, 17 amino acids, enzymes, minerals and alkaloids (e.g. allicin). The rise in body weight may be result of these compounds in garlic. Allicin also helps to recover and redevelop the functional structure of the epithelium layer of intestines, increases height of villus and depth of crypt cells, that finally helps the digestive ability through better absorption of valuable nutrients (Adibmoradi et al. 2006). Garlic is also well reputed for immunogenic effects i.e. production of antibodies, white blood cells and increased phagocytosis of pathogenic organisms (Khan et al. 2012). All these qualities of garlic play therapeutic role as anti-coccidial drug. Kim et al. (2013) described that the treatment of energetic ingredients of garlic oil (propyl thiosulphinate and propyl thiosulphinate oxide) had reduced fecal oocysts defecation and also increased

antibody reaction against *Eimeria acervulina* in broiler chicks. Garlic also contains sulphur compounds in large amounts due to which it has anti-parasitic effects (Gebreyohannes and Gebreyohannes 2013). In another study conducted by Waqas et al. (2018) on broiler bird using different forms of garlic viz., garlic powder, ethanol extract, aqueous solution used at dosage 2-4 mg/kg body weight, it was observed that anti-coccidial efficacy of garlic with the highest efficacy recorded for aqueous solution of garlic. Allicin also possesses antiparasitic and antioxidant properties and activates the immunity by increasing profilin antibody reaction, it also increases the cytoplasmic permeability of *Eimeria* cells which damages the cellular framework leading to destruction of the sporozoites (Khan et al. 2012, Kim et al. 2013). The decreased oocysts number is also the result of different phenolic compounds naturally present in garlic oil which affect the cytoplasmic membrane of *Eimeria* and cause alteration in their risk avoidance permeability and ultimately lead to the death of *Eimeria* (Tanweer et al. 2014). The lesser mortality (greater survival percentage) in garlic oil treated group was most probably associated with the antioxidant properties of garlic which results oxidative stress in contradiction of parasites and nullify oxygen reactive species.

Ginger also has numerous essential pharmacological compounds that include shogaols, gingerol, gingerdione, and gingerdiol have antioxidant properties due to which it possesses coccidiostat properties (Raza et al. 2016). Although no study data are available on the effect of ginger in quail coccidiosis but Nasution et al. (2018) found it efficacious coccidiostat against *Eimeria tenella* in broilers. Ali et al. (2014) also found aqueous extracts to be effective against coccidia in pigeons. Slight improvement in body weight gain in common quails treated with ginger oil was due to increased palatability and digestibility leading to increased body weight (Khan et al. 2012).

CONCLUSION

On the basis of findings of this study it was concluded that anti-coccidial activity of amprolium is higher than garlic oil whereas ginger oil is not found to be effective as amprolium and garlic oil.

ACKNOWLEDGMENTS

The study was partially funded by Pet Centre, University of Veterinary and Animal Sciences, Lahore, Pakistan.

CONFLICT OF INTEREST

The study confers no conflict of interest.

REFERENCES

- Adibmoradi M, Navidshad B, Seifdavati J, Royan M. 2006. Effect of dietary garlic meal on histological structure of small intestine in broiler chickens. *The Journal of Poultry Science*. 43: 378-383.
- Akhtar M, Hai A, Awais MM, Iqbal Z, Muhammad F, ul Haq A, Anwar MI. 2012. Immunostimulatory and protective effects of Aloe vera against coccidiosis in industrial broiler chickens. *Veterinary parasitology*. 186: 170-177.
- Ali M, Chand N, Khan RU, Naz S, Gul S. 2019. Anticoccidial effect of garlic (*Allium sativum*) and ginger (*Zingiber officinale*) against experimentally induced coccidiosis in broiler chickens. *Journal of Applied Animal Research*. 47: 79-84
- Ali J, Swadi H, Alewi H. 2014. Experimental infection of pigeon birds with *Giardia lamblia* parasite isolated from human and treatment of infected birds with ginger extract. *journal of kerbala university*. 12: 62-66.
- Bello K, Akanji A, Irekhore O, Lala A. Anti-Endo Parasitic Effects of Garlic (*Allium sativum*) as Supplement in the Diets of Rabbits Reared under Deep Litter System
- Bozkurt M, Aysul N, Küçükylmaz K, Aypak S, Ege G, Çatli A, Akşit H, Çöven F, Seyrek K, Çınar M. 2014. Efficacy of in-feed preparations of an anticoccidial, multienzyme, prebiotic, probiotic, and herbal essential oil mixture in healthy and *Eimeria* spp.-infected broilers. *Poultry science*. 93: 389-399
- Gebreyohannes G, Gebreyohannes M. 2013. Medicinal values of garlic: A review. *International Journal of Medicine and Medical Sciences*. 5: 401-408
- Khan R, Naz S, Nikousefat Z, Tufarelli V, Javdani M, Qureshi M, Laudadio V. 2012. Potential applications of ginger (*Zingiber officinale*) in poultry diets. *World's Poultry Science Journal*. 68: 245-252
- Khan R, Nikousefat Z, Tufarelli V, Naz S, Javdani M, Laudadio V. 2012. Garlic (*Allium sativum*) supplementation in poultry diets: effect on production and physiology. *World's Poultry Science Journal*. 68: 417-424
- Kim DK, Lillehoj HS, Lee SH, Lillehoj EP, Bravo D. 2013. Improved resistance to *Eimeria acervulina* infection in chickens due to dietary supplementation with garlic metabolites. *British Journal of Nutrition*. 109: 76-88
- Nasution E, Tafsir M, Hanafi N. 2018. The response of red ginger (*Zingiber officinale* var *rubra*) with various processing in broilers were infected by *Eimeria tenella*. In *IOP Conference Series: Earth and Environmental Science*, Volume 122. (IOP Publishing), p. 012117
- Raza T, Chand N, Khan RU, Shahid MS, Abudabos AM. 2016. Improving the fatty acid profile in egg yolk through the use of hempseed (*Cannabis sativa*), ginger (*Zingiber officinale*), and turmeric (*Curcuma longa*) in the diet of Hy-Line White Leghorns. *Archives Animal Breeding*. 59: 183-190
- Tanweer AJ, Saddique U, Bailey C, Khan R. 2014. Antiparasitic effect of wild rue (*Peganum harmala* L.) against experimentally induced coccidiosis in broiler chicks. *Parasitology research*. 113: 2951-2960
- Waqas M, Akhtar R, Akbar H, Lateef M, Rashid I, Ijaz M. 2018. Evaluation of Anti-Coccidial Activity of Different Extraction Products of *Allium sativum* (Garlic) in Broilers. *Journal of the Hellenic Veterinary Medical Society*. 69: 1055-1058

First isolation of *Mycobacterium bovis* SIT 482 BOV from beef cattle in Turkey

M. L. Avsever^{1*}, C. Çavuşoğlu², İ. Çamkerten³

¹Aksaray University, Eski Vocation of High School, Laboratory and Veterinary Sciences. Aksaray-Turkey

²Ege University, Faculty of Medicine, Mycobacteria Laboratory, İzmir- Turkey

³Manisa Celal Bayar University, Akhisar Vocation of High School, Plant and Animal Production Department, Manisa-Turkey

ABSTRACT: Bovine tuberculosis is a zoonotic disease which should be emphasized in our country as in many countries. A large number of genotypes have been revealed by spoligotyping method of *M. bovis* in the world. *M. bovis* SIT 482. BOV is one of these genotypes and it is also *M. bovis* genotype in which BCG vaccine is administered in humans. The BCG vaccine is obtained through multiple passages of this genotype. However, this genotype, like other genotypes, can cause serious infections in humans and animals. There are data on the isolation of *M. bovis* SIT 482 BOV from animal and human tuberculosis cases in the world. In our country, the isolation of this genotype has been reported only in humans and no data have been found in the animals. In this study, *M. bovis* SIT 482. BOV was isolated from the samples of six cattle with internal organ samples obtained from licensed slaughterhouses in Aksaray. While isolation is carried out with BACTEC MGIT 960 liquid media, spoligotyping was carried out according to the manufacturer's with kit (Isogen LifeScience, The Netherlands). This study aims to report *M. bovis* SIT 482 BOV from cattle in Turkey for the first time, to draw attention a very limited number reported in *M. bovis* cases in Turkey, highlight the importance of genotyping of tuberculosis factors and contribute to epidemiological studies. These and similar studies will contribute to the creation of genetic maps for eradication of *M. bovis* from cattle in our country. The study was also conducted to investigate whether *M. bovis* SIT 482. BOV isolated from cattle in Aksaray province is BCG strain or another strain giving the same pattern.

Keywords: Cattle; *Mycobacterium bovis* SIT 482. BOV; Turkey

Corresponding Author:

M.L. Avsever, Manisa Celal Bayar University, Akhisar Vocation of High School, Plant and Animal Production Department, Manisa-Turkey
E-mail address: lutfiavsever@gmail.com

Date of initial submission: 07-07-2019
Date of revised submission: 18-05-2020
Date of acceptance: 10-06-2020

INTRODUCTION

Mycobacterium bovis is a pathogen within the *Mycobacterium Tuberculosis* Complex (MTC) that causes tuberculosis in animals and humans (Rodwell et al., 2008). *M. bovis*, the causative agent of bovine tuberculosis, has the widest host range among the MTC members (Wei et al., 2004), and infects animals, especially cattle, and sometimes humans (Mignard et al., 2006).

Among the cattle, *M. bovis* is mostly transmitted by the airway, but by ingestion of the contaminated material, the infection may also occur. When the bacterium enters the lungs it begins to multiply and usually spreads to the lymph nodes of the lungs (Menzies and Neill, 2000). The transmission of *M. bovis* from the cattle to the people is the most contaminated, non-pasteurized milk consumption, but it is observed by direct contact with infected animals (Lari et al., 2006) or by inhalation of infectious aerosols extracted from the sick animals (Mignard et al., 2006).

On the other hand, in many cases, the clinical and pathological features of *M. bovis* cannot be distinguished from *M. tuberculosis* infection (Rodwell et al., 2008; Lari et al., 2006) and the incidence of *M. bovis* in human infections is unknown, as many laboratories provide general diagnoses under the name MTC. Therefore, identification and genotyping of the mycobacterial agents are important in diagnosing humans. Again, considering the presence of multi-drug resistant *M. bovis* strains and *M. bovis* co-infection with HIV, *M. bovis* studies are also gaining value (Rodwell et al., 2008). The American General Health Organization and World Health Organization state that in South America every year, 7,000 new cases of human tuberculosis caused by *M. bovis* have been reported and the actual incidence is estimated to be eight times higher (Wei et al., 2004).

M. bovis BCG was obtained by passaging *M. bovis* 230 times over 13 years and is used as a vaccine strain throughout the world (Keating et al., 2005). *M. bovis* SIT 482. BOV has the same spoligotype patterns as the BCG vaccine strain and can cause infections in humans and animals. *M. bovis* SIT 482 BOV was isolated from humans (Lari et al., 2016; Mokrousov et al., 2010) and cattle (Sahraoui et al., 2009; Munyeme et al., 2009; Parreiras et al., 2012) in the World. *M. bovis* SIT 482 BOV has been reported in humans in our country (Çavuşoğlu et al., 2007; Aslan et al., 2009) but data from this genotype was not detected from animals in Yurkey. Knowing which genotypes are available to

combat *M. bovis* in our country will be of great benefit.

In the diagnosis of *M. bovis*, isolation is the gold method and identification is usually made by geneticaly based methods. Although the Restriction Fragment Lenth Polymorphism (RFLP) method is commonly used in genotyping the agents, Spoligotyping (Spacer Oligonucleotide Type Analysis) method based on PCR amplification of the Direct Repeat (DR) region of MTC has been preferred in recent years for identification (Kamerbeek et al. 1997; Schlossberg, 2017). Spoligotyping is a method based on the polymorphism of DR regions in mycobacterial DNA. The DR regions were formed by the spacing of non-repetitive spacers between a number of repetitive sequences specific to mycobacteria belonging to the member of the MTC. In this method, all DR regions are amplified by PCR following DNA extraction. The resulting amplicons are hybridized with membrane-bound separator oligonucleotides and made visible by streptavidin-peroxidase autoradiography (Marchetti et al., 1997). Spoligotyping results are in the form of numbers and are converted into number series that define the hybridization model.

This study aims to report *M. Bovis* SIT 482 BOV from the slaughterhouse samples of cattle in Turkey for the first time, to draw attention to a very limited number reported in *M. bovis* cases, highlight the importance of genotyping of tuberculosis factors and contribute to epidemiological studies. This and similar studies will contribute to the creation of genetic maps necessary for eradication of *M. bovis* from cattle in the World.

MATERIALS AND METHODS

Samples

This study performed during wintger months (January and February), after the permission received from the Ministry of Food, Agriculture and Livestock. In this research, a sample of the internal organs (lung and related lymph nodes) of six cattle obtained from the licensed slaughterhouses in Aksaray province was used. These samples were transported in hazardous material transport containers and in the cold chain to the Mycobacteria laboratory of Ege University Medicine Faculty. The laboratory work was done.

Bacterial examination

Isolation

Sterile samples (weight 5 to 10 g) were homogenized using the stomacher and the homogenate was taken to the decontamination process. For this purpose, tissue homogenate in 0.375-0.75% hexade-

cylpyridiniumchloride (HPC, detergent) was shaken at room temperature for 10-15 minutes. Sieves were thawed from BACTEC MGIT 960 liquid media which were thawed for primary isolation and the cultivated media were incubated at 37 ° C for 8 weeks. (Arda et al., 1997, Songer and Post, 2011). The BACTEC MGIT 960 automatic mycobacteria detection system was detected by stimulation in the liquid media.

Spoligotyping

Spoligotyping was performed as described by the manufacturer of the kit. In summary; DNA was obtained from the isolates and *M. tuberculosis* H37Rv and *M. bovis* BCG strains used as positive control and DNA was obtained by ultrasonic bath method. 5% of the DNA obtained was used as template DNA in PCR process. The PCR procedure was determined by DRa 5'-GGTTTGGGTCTGACGAC-3 and biotin labeled DRb 5AC-CCGAGAGGGGACG-GAAAC-3 'primers used by Kamerbeek et al. (1997). These primers were used in the amplification of the DR region to be spoligotyped. DH₂O was used as the negative control in PCR. PCR mix with a total volume of 50 ml were 3 U Hot Star Taq DNA polymerase (0.6 µl), 10X buffer (5 µl), 25 mM MgCl₂ (5 µl), 20 pM DRa primer (4 µl), 20 pM DRb primer (4 µl), molded DNA (5 µl), a mixture of 2.5 mM dNTP (4 µl), and nuclease purified dH₂O (22.4 µl). Amplification conditions was in the form of after 15 min pre-denaturation at 95° C, 30 cycles of amplification at 95° C for 1 min denaturation, connecting for 1 min at 55°C and elongation for 45 sec at 72°C and 10 min final elongation at 72°C. The amplified PCR product was hybridized with the nitrocellulose membrane attached to the oligonucleotide with the help of the mini blotter. Hybridized DNA was detected by chemiluminescence. Following incubation with streptavidin-peroxidase followed by detection with ECL (Enhanced Chemo-luminescence), the hybridized regions were visualized as black squares on the film. Spoligotypes were entered into the SpolDB4 spoligotyping database at <http://www.pasteur-guadeloupe.fr> in the form of a binary format and converted to a 15-digit octal code and compared with the strains recorded in the database

RESULTS AND DISCUSSION

In this study, *Mycobacterium bovis* SIT 482 BOV was isolated from the specimens (lungs and related lymph nodes) of the six cattle obtained from licensed slaughterhouses in Aksaray province BACTEC MGIT 960 automatic mycobacteria detection system showed

positive signal In three weeks ago after planting in BACTEC MGIT 960 fluid medium. Macroscopic image samples of organ are given in **Figure 1**. The study was also conducted to research whether *M. bovis* SIT 482 BOV isolated from cattle in Aksaray province was BCG strain or another strain giving the same pattern.

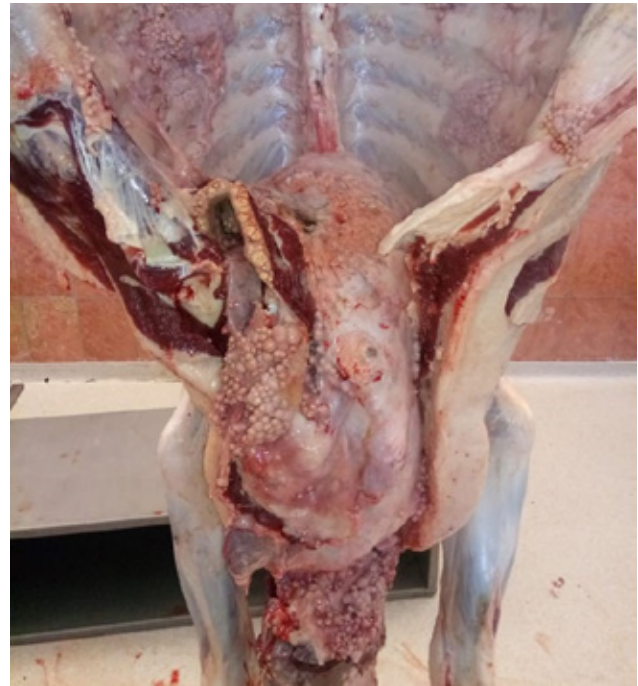

Figure 1. Macroscopic image of organs with tuberculosis nodules

Mycobacterium bovis SIT 482 BOV was isolated from humans (Lari et al., 20016; Mokrousov et al., 2010) and cattle (Sahraoui et al., 2009; Munyeme et al., 2009; Parreiras et al., 2012) in the world. In our country, although it was reported by Çavuşoğlu et al. (2007) and Aslan et al. (2009). *M. bovis* SIT 482 BOV isolation data were not found from the animals. The reason of the fact that the agent is not bitten in animals in our country is that *M. bovis* is one of the least studied pathogens in our country due to the difficulties such as zoonosis, isolation and identification difficulties and a level three laboraztories required to work.

Çavusoglu and Yilmaz (2017) spoligotyped in the Aegean region of 13 *M. bovis* isolates 9 (63.6%) *M. bovis* SIT 685 BOV, 1 (7.7%) *M. bovis* SIT 1118 BOV, 1 (7.7%) *M. bovis* SIT 820 was determined and found no strains registered in the database for two isolates. Avsever et al. (2017) isolated *M. bovis* SIT 685 BOV from the goats in the same region. Again, Çavusoğlu et al. (2007) and Aslan et al. (2009) isolated *M. bovis* SIT 482. BOV from humans.

In this study, *M. bovis* SIT 482. BOV was isolated

from cattle. These data indicate that at least *M. bovis* SIT 482. BOV and SIT 685 BOV in our country can be widespread from animals to humans. This and similar studies are important in terms of understanding which genotypes are a more important problem in humans and animals in our country and which are more contagious.

In the study, BACTEC MGIT 960 fluid media and BACTEC MGIT 960 automated mycobacteria detection system for the isolation of bacteria has multiple advantages over the conventional method using Löwenstein-Jensen (LJ) solid media (Saini et al. 2017) The first advantage is that fewer bacteria can be produced in a faster time, the other advantage is that the system gives a warning and that the first growth is understood in the fastest time and that the human eye is not mistaken.

Tuberculosis disease is a holistic problem that does not distinguish between human or animal in our country. In order to solve this problem, veterinary and medical microbiologists should work together and support multidisciplinary studies. Neither the solution of tuberculosis alone or human tuberculosis alone will provide an effective remedy.

As a result, Mycobacterium of the slaughterhouse samples of cattle in Turkey in this study *M. bovis* SIT 482 BOV reported for the first time, the country has drawn attention to the very limited number of reported *M. bovis* cases, it highlighted the importance of genotyping of tuberculosis agent and has tried to contribute to epidemiological studies. This and similar studies will contribute to the creation of genetic maps for the eradication of *M. bovis* from cattle in our country. Finally, this is multidisciplinary study among veterinarians and human doctors.

ACKNOWLEDGEMENT

This study was carried out under Aksaray University Scientific Research Project (No: 2017-054).

CONFLICT OF INTEREST

On behalf of all authors, the corresponding author states that there is no conflict of interest.

REFERENCES

- Arda M, Minbay A, Leloğlu N, Aydın N, Akay Ö (1997) Özel Mikrobiyoloji, 180, 4. baskı, Medisan Yayın Serisi No: 26, Ankara.
- Aslan G, Kuyucu N, Çalıkoglu M, Ersöz G, Ülger M, Günel G, Emekdaş G (2009): *Mycobacterium bovis*'in etken olduğu tüberküloz olguları, Ankem Derg 23(4): 182-187
- Avsever ML, Çavuşoğlu C, Yazıcıoğlu Ö, Eskiizmirli S, Erdal G, Günen M.Z, Tunalgil S, Alparslan B, Aksoy A (2017) New spoligotyping pattern of *Mycobacterium bovis* isolates from farm animals in Turkey, Ankara Univ Vet Fak Derg 64: 37-43.
- Çavuşoğlu C, Akıncı P, Söyler İ, Bayram N, Vardar F (2007) Yaygın *Mycobacterium bovis* BCG enfeksiyonunun laboratuvar tanısı, Enfeksiyon Derg 1(1): 39-44.
- Çavuşoğlu C, Yılmaz FF (2017) Ege Bölgesi'nde İnsan *Mycobacterium bovis* Enfeksiyonlarının Moleküler Epidemiyolojisi Mikrobiyol Bul. 51(2): 165-170
- Kamerbeek J, Schouls L, Kolk A, Van Agterveld M, Van Soolingen D, Kuijper S, Bunschoten A, Molhuizen H, Shaw R, Goyal M, Van Embden J (1997) Simultaneous detection and strain differentiation of *Mycobacterium tuberculosis* for diagnosis and epidemiology. J Clin Microbiol 35: 907-14
- Keating LA, Wheeler PR, Mansoor H, Inwald JK, Dale J, Hewinson RG, Gordon SV (2005) The pyruvate requirement of some members of the *Mycobacterium tuberculosis* complex is due to an inactive pyruvate kinase: implications for in vivo growth, Mol Microbiol 56 (1):163-74
- Lari N, Rindi L, Bonanni D, Tortoli E, Garzelli C (2006) Molecular analysis of clinical isolates of *Mycobacterium bovis* recovered from humans in Italy, J Clin Microbiol 44(11): 4218-21
- Varma-Basil M, Kumar S, Arora J, Angrup A, Zozio T, Banavaliker JN, Singh UB, Rastogi N, Bose M (1997) Comparison of spoligotyping vs RFLP DNA Fingerprinting analysis in *M. tuberculosis* epidemiological typing. 4. Conference on Retroviruses and Opportunistic Infections, Washington DC, p.184.
- Menzies FD, Neill SD (2000) Cattle-to-cattle transmission of bovine tuberculosis. Vet J 162 (2): 92-106.
- Mignard S, Pichat C, Carret G (2006) *Mycobacterium bovis* infection, Lyon, France, Emerg Infect Dis 12(9) : 1431-3
- Mokrousov I, Vyazovaya A, Potapova Y, Vishnevsky B, Otten T, Narvskaya O (2010) *Mycobacterium bovis* BCG-Russia Clinical Isolate with Noncanonical Spoligotyping Profile, J Clinical Microbiol 48 (12): 4686-4687
- Munyeme M, Rigouts L, Shamputa IC, Muma JB, Tryland M, Skjerve E, Djønne B (2009) Isolation and characterization of *Mycobacterium bovis* strains from indigenous zambian cattle using spacer oligonucleotide typing technique, BMC Microbiology 9: 144
- Parreiras PM, Andrade GL, Nascimento TDF, Oelemann MC, Gomes HM, Alencar AP, Assis RA, Mota PM, Pereira MA, Lobato FC, Lage AP, Suffys PN (2012) Spoligotyping and variable number tandem repeat analysis of *Mycobacterium bovis* isolates from cattle in Brazil, Memorias do Instituto Oswaldo Cruz, 7 (1): 64-73
- Rodwell TC, Moore M, Moser KS, Brodine SK, Strathdee SA (2008) Tuberculosis from *Mycobacterium bovis* in binational communities, United States, Emerg Infect Dis 14(6): 909-16.
- Sahraoui N, Müller B, Guetarni D, Boulahbal F, Yala D, Ouzrout R, Berg S, Smith NH, Zinsstag J (2009) Molecular characterization of *Mycobacterium bovis* strains isolated from cattle slaughtered at two abattoirs in Algeria, BMC Veterinary Research 5: 4.
- Saini D, Singh A, Kumar A, Rawat R, Verma RK, Singh D. (2017) Comparison of BACTEC MGIT with conventional methods for detection of Mycobacteria in clinically suspected patients of extra pulmonary tuberculosis in a tertiary care hospital, Int J Res Med SCI 5(8): 3530-3533
- Schlossberg DL (2017). Tuberculosis and Nontuberculous Mycobacterial Infections (ASM Books). 7th Edition.
- Songer JG, Post KW (2011). Veteriner Hekimlik Mikrobiyolojisi. Nobel Tıp Bilimleri.
- Wei CY, Hsu YH, Chou WL, Lee CP, Tsao WL (2009) Molecular and histopathologic evidence for systemic infection by *Mycobacterium bovis* in a patient with tuberculous enteritis; peritonitis; and meningitis: a case report; Kaohsiung J Med Sci 20(6): 302-7.

Association of herd management with the infestation of ticks in domestic goats

M.S. Sajid^{*1,2}, H.M. Rizwan^{**3}, M.K. Khan¹, A. Qudoos⁴, F.A. Atif⁵, M.A. Malik¹, M. Maqbool¹

¹Department of Parasitology, University of Agriculture, Faisalabad, Pakistan

²One health Laboratory, Centre for Advanced Studies in Agriculture and Food Security, University of Agriculture, Faisalabad, Pakistan

³Section of Parasitology, Department of Pathobiology, KBCMA College of Veterinary and Animal Sciences, Narowal, Sub Campus UVAS, Lahore, Pakistan

⁴Central Hi-Tech Laboratory, University of Agriculture, Faisalabad, Pakistan

⁵Department of Clinical Sciences, Medicine Section, College of Veterinary and Animal Sciences, Jhang, Sub Campus UVAS, Lahore, Pakistan.

ABSTRACT: Three-stage cluster random sampling was done for determination of the association of herd management with the prevalence of tick (Acari: Ixodidae) infestation in goats (*Capra hircus*) in southern Punjab, Pakistan. A total of 136 nomadic goat herds and settled farms were screened for ticks and related information like nature of herds, herd size, farming pattern, animal keeping, housing, floor pattern and hygienic measures and documented on a pre-structured questionnaire. In addition, participatory epidemiological tools were used to document trends of consultancy and therapy, choice of drugs and therapeutic approaches. A significant tick infestation (56.30%) was found in all the settled farms or nomadic herds irrespective of the herd size; however, herds having 40-60 goats showed highest infestation. Among 109 (80.1%) settled farms and 27 (19.8%) nomadic herds, highest infestation was found in nomadic herds. No significant association of tick infestation was found with the goat herds reared with large ruminants or separately. Association of tick infestation with goat herds reared in closed housing system was found to be significantly higher as compared to partially-closed or open. Tethered goats showed significantly higher rate of tick infestation than free living. Uncemented (Kacha) floor was a higher risk factor for tick infestation as compared to cemented and bricked. The goats of the settled farms were more prone to tick infestation whose owner neglected the tick infestation, consulted with quacks, used ethnoveterinary medicine and petroleum for control of ticks. The findings of present study will be helpful in devising appropriate extension services for the control of tick infestation in the selected region in specific and in resource-poor countries with similar livestock husbandry systems, in general.

Keywords: Herd management, *Capra hircus*, Determinants, Ticks, Pakistan

Corresponding Authors:

M.S. Sajid*, Department of Parasitology, University of Agriculture, Faisalabad, Pakistan
E-mail address: drsohailuaf@hotmail.com

H.M. Rizwan**, Section of Parasitology, Department of Pathobiology, KBCMA College of Veterinary and Animal Sciences, Narowal, Sub Campus UVAS, Lahore, Pakistan
E-mail address: hm.rizwan@uvas.edu.pk

Date of initial submission: 08-08-2019
Date of revised submission: 20-03-2020
Date of acceptance: 21-04-2020

INTRODUCTION

Tick (Acari: Ixodidae) infestation is one of the serious threats to the livestock population all around the world especially in resource-poor countries like Pakistan. Directly, tick infestation is responsible for damaging the quality of hides and skin which ultimately reduce their economic value in leather industry. Indirectly, tick infestation is related to reduced milk production (Sajid et al., 2007), increased mortality (Jongejan & Uilenberg, 2004), transmission of serious diseases (such as anaplasmosis, babesiosis and theileriosis), causation of allergy, severe irritation and toxicosis (Khan et al., 2013; Peckle et al., 2013; Palomar et al., 2014; Rojas et al., 2014; Sajid et al., 2018). Livestock sector is an integral part of the economy of Pakistan as a considerable number of people depend upon keeping livestock for their sustenance. In Pakistan, investigations regarding tick abundance and distribution, taxonomy, ecology of the pest complex, acaricidal efficacy (Kakar & Kakar-sulemankhel, 2008; Durrani & Shakoori, 2009; Perveen et al., 2010) as well as functional genomics of ticks have gained currency since last decade (Karim et al., 2017). Ticks have been well-documented from almost all regions of Pakistan including Sindh (Soomro et al., 2014), Khyber Pakhtunkwa (KPK) (Ali et al., 2019), Balochistan (Kakar et al., 2017), Punjab (Sajid et al., 2008; 2009; 2011) and northern areas of Pakistan including Gilgit-Baltistan (Sajid et al., 2017). Many risk factors are associated with tick infestation in farm animals which have a direct impact on the epidemiology of tick-borne diseases (Karim et al., 2017; Sajid et al., 2018; Hassan et al., 2018; Rashid et al., 2019; Rizwan et al., 2019). Small ruminant population particularly goats (called as the poor man's cow) contribute a major share in the livestock population of the country (Afzal and Naqvi, 2003). However, in spite of immense significance of goats in the livestock economy of Pakistan, along with other animal health issues, information regarding the ticks and tick-borne disease dynamics in nomadic and settled farming systems and trends of the small holder goat farming community/ nomads about tick management in the country is lacking. The present study determined the possible risk factors relating to the tick infestation in goat population of the selected districts; Layyah and Muzaffargarh, in Punjab, Pakistan and highlighted the possible statistical associations with prevailing management practices in this area. The information collected from the survey explores the relevant ground realities which will not only be helpful for the nomads

and small farm holders of the area but also for the decision makers for subjective planning of tick control program in the area.

MATERIALS AND METHODS

Study Area and Sampling of Animals

The study was conducted in two districts of lower Punjab i.e. Muzaffargarh and Layyah. These districts are situated in the north side of Chenab and Indus rivers. Three stage cluster random sampling was used for the selection of goats from study areas. Sample size of the union councils as primary units, farms/herds as secondary and animals as elementary units were randomly calculated using formulae given by Thrusfield et al. (2018). A total of 136 farms/herds (5644 goats) were entered into the current survey. Farms/herds were selected to at least be 10 km apart from each other and having at least 10 goats. All the animals from selected farms/herds were examined and sampling was done during July 2017 to December 2017.

Collection of Information Regarding Herd Management Factors

Before initiation of the study, a pilot survey for refinement of the questionnaire was conducted. Relevant information from the 136 enrolled goat herds (settled or free grazing herds/farms) regarding (i) herd size; (ii) herd nature (settled or nomadic farms); (iii) pattern of farming (separate or associated with large animals); (iv) housing (closed, partially closed or open); (v) animal keeping (free or tethered); (vi) floor pattern (cemented, partially cemented or uncemented) and hygienic measures (excellent, poor or acceptable) were collected on a pre-designed questionnaire (Thrusfield et al., 2018). Parameters like, (i) trend of therapy by farmers (attending or neglecting tick infestation); (ii) trend of consultancy (quacks, veterinarians or self-medication); (iii) therapeutic approach (allopathic acaricides or ethnoveterinary medicine) and (iv) choice of drugs (cypermethrin spray or pour-ons, ivermectin injectable, plant extracts, petroleum or oils) were also collected from settled farms and nomadic herds.

Collection and Identification of Ticks

All goats of 136 herds were screened for tick infestation. Ticks were carefully collected from infested goats with the help of forceps (Soulsby, 1982) and preserved in 70% ethyl alcohol. Ticks from each goat were stored in a separate plastic bottle and labeled with the area, age, sex and date of collection. Taxo-

nomic identification of collected ticks was done in the Department of Parasitology, University of Agriculture, Faisalabad (UAF), Pakistan by using keys given by Walker et al. (2007).

Statistical Analyses

The association of tick infestation with different risk factors was statistically analyzed using chi-square test. Pair-wise comparison was carried out at 95% confidence level keeping the 10-20 goats/herd, nomadic herds, separate farming, open housing system, non-tethered animal keeping, cemented floor pattern, trend of attending tick infestation, veterinarian consultancy, allopathic therapeutic approach and cypermethrin as drug of choice as reference groups in the analysis (Schork and Remington, 2010). All the analyses were done by using SAS (2010) software package.

RESULTS

Two species of ticks i.e. *Hyalomma (Euhyalomma) anatolicum* and *Rhipicephalus (R.) sanguineus* were identified from the study areas. Prevalence of *H. anatolicum* (76.72%) was significantly higher than *R. sanguineus* (23.28%). Overall prevalence of the tick infestation was 56.3% in goat population of the selected districts. Prevalence rate was higher in district Muzaffargarh (68.32%) than in district Layyah

(31.68%). The rate of tick infestation was higher during July-August and lower during November-December.

The proportion of herds having 20-40 goats/ herd was significantly higher than other groups. A significant tick infestation was found in all herd size, however, herds having 40-60 goats/herd (OR=2.61) showed highest infestation. Among 109 (80.1%) settled farms and 27 (19.8%) nomadic herds (OR=6.41), highest infestation was found in nomadic herds. Regarding farming system, a significantly higher number of goat herds was associated with the large animals. However, a non-significant association was found in goat herds reared with large ruminants or separately. In the present investigation, most of the farmers were found to adopt open housing system followed in order by partially closed and closed housing system. Association of tick infestation with closed housing goat herds was significantly higher as compared to open or partially closed. Goats kept as tethered (rope-tied and fed indoors at all times) showed significantly higher infestation than those non-tethered. Uncemented floor pattern was found significantly higher in most of the goat herds which predisposed to higher risk of tick infestation as compared to cemented or bricked. Frequency distribution of tick infestation in several categories of goat herds has been presented in Table 1.

Table 1. Determinants of herd management of goat (*Capra hircus*) influencing tick (Acari: Ixodidae) infestation in Layyah and Muzaffargarh district of Punjab, Pakistan

Parameters	groups	No. of farms	Farms visited	% of farms	Ticks +ve animals	Animals examined	% of infestation	P-value	Lower limit	Upper limit	Odds ratio
Herd Size	10-20 goat/ herd	33	136	24.3	198	504	39.3	0.0011	32.5	42.84	
	20-40 goat/ herd	65	136	47.8	1271	2200	57.8	0.0007	47.55	62.45	2.11
	40-60 goat/ herd	19	136	14.0	786	1250	62.9	0.0006	56.43	69.57	2.61
	60-80 goat/ herd	14	136	10.3	645	1130	57.1	0.0007	50.54	63.41	2.05
	>80 goat/ herd	5	136	3.7	278	560	49.6	0.0010	40.71	53.22	1.52
Nature of groups	settled farms	109	136	80.1	1790	3990	44.9	0.0033	36.13	53.53	6.41
	nomadic herds	27	136	19.9	1388	1654	83.9	-	76.04	90.96	-
Farming	Integrated with large animals	89	109	81.7	2390	4206	56.8	0.0507	50.08	62.58	1.08
	Separate	20	109	18.3	788	1438	54.8	-	46.63	60.71	-
	Open	73	109	67.0	1766	3613	48.9	0.0013	42.08	56.26	-
Housing	Closed	9	109	8.3	456	623	73.2	0.0006	66.68	82.65	2.86
	Partially closed	27	109	24.8	956	1408	67.9	0.0012	59.29	73.37	2.21
Animal keeping	Tethered	15	109	13.8	1034	1390	74.4	0.0016	66.59	82.08	2.86
	Free	94	109	86.2	2144	4254	50.4	-	41.61	58.06	-
Floor pattern	Uncemented	89	109	81.7	2435	3310	73.6	0.0006	64.74	79.92	18.94
	Cemented	8	109	7.3	98	765	12.8	0.0026	6.35	19.32	-
	Bricked	12	109	11.0	645	1569	41.1	0.0020	34.68	49.65	4.75

In nomadic herds, trend of neglecting tick infestation was higher ($P < 0.05$) as compared to that in the settled farms. However, in both systems consulting with a veterinarian for tick infestation and use of allopathic drugs was least ($P < 0.05$). Most of the farmers consulted with quacks or relied on their own to treat tick infestation (self-medication). Ethnoveterinary

practices like use of petroleum was higher than oils and/or plant extracts while in allopathic drugs, ivermectin was used more lavishly than cypermethrin. Farmers' response rates relating to their attitude towards tick infestation and possible treatment options in settled and nomadic goat farms combined with tick infestation rates per category are provided in Table 2.

Table 2. Farmers' response to tick (Acari: Ixodidae) infestation in settled farms and nomadic population of domestic goat (*Capra hircus*) in districts Layyah and Muzaffargarh, Punjab, Pakistan

A: Settled Goat Farms											
Parameters	Groups	No. of farms	Farms visited	% of farms	Ticks +ve animals	Animals examined	% of infested animals	P-value	Lower limit	Upper limit	Odds ratio
Trend of Therapy	Neglecting tick infestation	12	109	11.0	1256	1845	68.1	0.0001	60.43	73.57	6.43
	Attending tick infestation	97	109	89.0	534	2145	24.9		18.16	28.5	
Consultancy	Veterinarians	13	97	13.4	77	560	13.8	0.0029	7.45	20.26	
	Quacks	56	97	57.7	256	964	26.6	0.0011	17.29	35.42	2.27
	Self-reliance	28	97	28.9	201	621	32.4	0.0009	22.83	42.63	3
Therapeutic approaches	Ethnoveterinary medicine	26	97	26.8	239	689	34.7	0.0004	26.05	43.68	2.09
	Allopathic	71	97	73.2	295	1456	20.3		13.91	27.14	
Choice of drugs	Ivermectin	52	71	73.2	239	869	27.5	0.0008	19.74	34.92	3.6
	Cypermethrin	19	71	26.8	56	587	9.5	0.0041	2.64	15.09	
	Oils	14	26	53.8	183	578	31.7	0.0007	20.32	41.01	4.39
	Plant extracts	5	26	19.2	4	13	30.8	0.0007	21.58	40.79	4.21
	Petroleum	7	26	26.9	52	98	53.1	0.0001	41.61	65.28	10.72
B: Nomadic Goat Herds											
Trend of Therapy	Neglecting tick infestation	11	27	40.7	891	994	89.6	0.0002	83.5	93.84	2.84
	Attending tick infestation	16	27	59.3	497	660	75.3	-	69.42	79.48	-
Consultancy	Veterinarians	2	16	12.5	19	69	27.5	0.0021	20.19	35.08	-
	Quacks	8	16	50.0	291	368	79.1	0.0003	68.97	89.46	9.95
	Self-reliance	6	16	37.5	187	223	83.9	0.0001	75.38	91.54	13.69
Therapeutic approaches	Ethnoveterinary medicine	12	16	75.0	399	489	81.6	0.0002	72.3	90.11	3.3
	Allopathic	4	16	25.0	98	171	57.3	-	45.65	72.98	-
Choice of drugs	Ivermectin	3	4	75.0	79	129	61.2	0.0007	53.73	68.66	1.91
	Cypermethrin	1	4	25.0	19	42	45.2	0.0024	32.91	57.42	-
	Oils	7	12	58.3	208	278	74.8	0.0003	65.8	83.19	3.6
	Plant extracts	2	12	16.7	2	4	50.0	0.0015	42.73	59.68	1.21
	Petroleum	3	12	25.0	189	207	91.3	0.0001	85.38	97.27	12.71

DISCUSSION

Ticks have been found notorious for their sustainable distribution in various agro-geo climates of Pakistan over the last decade (Sajid, et al., 2007; 2008; 2009; 2011; 2017; Karim et al., 2017; Sajid et al., 2018; Hassan et al., 2018; Rashid et al., 2019;). The probable reasons of higher threat of ticks and tick-borne diseases in developing countries (including Pakistan) may include but are not limited to warmer seasons and higher average temperatures, which promote

the growth and propagation of ticks (Soulsby, 1982; Iqbal et al., 2013; Patel et al., 2013; Rizwan et al., 2019), the lack of appropriate husbandry practices i.e. animal housing standards and protocols used for the treatment of tick infestations (Sajid et al., 2011), maintenance of infestation from free-range grazing hosts to domesticated livestock, lack of knowledge and resources. This has led to increased threat of emerging and re-emerging tick-borne diseases in the region e.g. Crimean Congo Haemorrhagic Fever (CCHF). In Pa-

kistan, frequency and distribution of tick infestation has been reported almost in every province (Kakar & Kakarsulemankhel, 2008; Durrani & Shakoori, 2009; Perveen et al., 2010). In a recent survey conducted by Karim et al. (2017) from representative samples of all provinces of Pakistan, 19 tick species were identified from livestock. From Kaghan valley, Khan (1993) reported 12.3% prevalence of tick infestation in goats and identified seven species of ticks. Twelve species of ticks were identified from different districts (Dir, Bannu, Swat, Peshawar, Swat and Mardan) of KPK (Siddiqi & Jan, 1986). About 16 species of ticks were collected from goat and sheep population in another study conducted by Hussain and Kumar (1985) in five different agro-ecological zones of Sindh, Pakistan. Rehman et al. (2017) identified four species of ticks which were *Hyalomma anatolicum*, *R. microplus*, *H. dromedarii* and *R. turanicus*. Semi-arid and arid agro-ecological zones of Pakistan showed higher (Rehman et al., 2017) while northern zone showed lower (Irshad et al., 2010) prevalence of tick infestation than present study. Batool et al. (2019) reported lower prevalence of ticks in the northern, southern, western and central zones than that of the present study. In Uttarakhand, India (Gopalakrishnan et al., 2017), Eastern Hararghe, Ethiopia (Desalegn et al., 2015), the prevalence of tick infestation is lower than the one found in our study. In Tamil Nadu (India), *H. bispinosa* was found to be a major tick species infesting goats followed in order by *R. haemophysaloides*, *H. anatolicum* and *H.m. isaaci* (Vathsala et al., 2008).

The results of the present study are in line with the results of Rony et al. (2010), Kabir et al. (2011), Atif et al. (2012), Mustafa et al. (2014), Sultana et al. (2015), Sajid et al., (2017) who also recorded high infestation of ticks in summer. The highest prevalence of tick infestation in summer might be due the weather being hot and humid which propagates the tick infestation and survival. Similar to our study, fluctuations in the rate of tick infestation were reported in different areas of Toba Tek Singh (Iqbal et al., 2013), lower Punjab (Sajid et al., 2011), semi-arid and arid zones of Pakistan (Rehman et al., 2017). Variations in the rate of tick infestation within the same or different geographical regions can be due to differences in husbandry practices including tick control strategies and awareness of the farmers (Ghosh et al., 2007).

Iqbal et al. (2013), Sajid et al. (2013) and Rehman et al. (2017) reported that closed (traditional) housing system was associated with higher prevalence of

tick which are in-line with our study. The prevalence of tick infestation was also reported higher in other housing type like wooden, uncemented than concrete (Muhammad et al., 2008; Farooqi et al., 2017). The higher rate of tick infestation in closed housing system might be due to increased humidity in heaps and reduced exposure to sunlight as well as presence of cracks and crevices in animal sheds providing an optimal environment for tick propagation (Jouda et al., 2004; Muhammad et al., 2008). Like our study, Iqbal et al., (2013), Sajid et al. (2013) and Rehman et al. (2017) reported that uncemented floor pattern is significantly associated with high tick infestation. The possible reason for higher rate of tick infestation in uncemented floor may be the mat depth (depth of soft soil) which helps to provides more niches, maintain humidity and a better microclimatic condition required for tick survival and development (Macleod, 1935; Milne, 1948).

Similar to our results, Sajid et al. (2013) found a higher prevalence in tethered animals than in free living. The possible associated risk factors for higher prevalence in tethered animals may be high prevalence of ectoparasites in shed or microclimate (Soulsby, 1982), hormonal imbalance due to stress of animals held in confinement (Lloyd, 1983) and lack of host capacity to avoid insect attack (Radon et al., 2001). The study conducted by Ramzan et al., (2018) revealed that 28.3% illiterate farmers use only chemicals for the control of tick infestation, 22.6% farmers adopted cultural practices for the control of ticks, while 10.3% used both chemical and cultural practices for control of ticks. They also reported that only 43.3% of the farmers visited a qualified veterinarian for the examination of their animals.

Several factors responsible for tick infestation in livestock population have been observed around the world (Abunna et al., 2012; Fentahun et al., 2012; Kumsa et al., 2012; Moshaverinia et al., 2012; Shemshad et al., 2012; Beyecha et al., 2014). There are many studies available on the epidemiological determinants reported to be positively or negatively associated or not associated with tick infestation in ruminants (Vathsala et al., 2008; Fentahun et al., 2012; Kumsa et al., 2012; Shemshad et al., 2012; Iqbal et al., 2013; Patel et al., 2013; Beyecha et al., 2014). Rehman et al. (2017) reported that traditional rural housing systems, absence of acaricidal treatments and rural poultry are the major factors responsible for high tick infestation. They also reported that sex, age,

breed, species and grazing played significant role in the rate of tick infestation.

Most of local livestock farmers of Pakistan rely on ethnobotanical knowledge to cure animal diseases which is based on traditional methods, skills, practices and beliefs. According to documentation of ethnoveterinary practices in district Jhang, Pakistan 33 indigenous plants were used for the treatment of different infectious and non-infectious ailments (Badar et al., 2017). About 231 plants reviewed showed a variety of bioactive properties like repellent, toxic, antioviopositant, antifeedant and ability to immobilize tick species (Wanzala, 2017). Sindhu et al, (2010) reported 35 plant species representing 25 families used in Mansehra district, Pakistan to treat the ailing animals. In Mansehra district, oil of *Cedrus deodara* is commonly used for treatment of tick infestation.

Most of the dairy farmers of Pakistan used injectable ivermectin among allopathic acaricide formulation for the control of ticks. Sajid et al. (2011) found that *in vivo* efficacy of cypermethrin treated groups regarding both mortality of adult ticks and re-infestation rates is significantly higher as compared to ivermectin treatment. It has been reported that the use of a limited number of acaricide over the period of time might be responsible for lower efficacy (Ogden et al. 2005). In a study conducted by Dipeolu (1983), it was concluded that inefficacy of the acaricide in field con-

dition limited due to rapid build-up of the tick population on the pasture plots rather than inability of acaricide to control ticks on the animals.

Purchase of acaricides without prescription or license (due to over-the-counter availability) and their inappropriate dosage and administration in small ruminants by the farmers of quacks (personal observation) could be one of the major predisposing factors of the reduced acaricidal efficacy which might be associated with an increase in the tick prevalence over the period of time. During the previous decade, mass-scaled acaricidal campaigns in livestock population as a part of emergency response to CCHF epidemic might be one of the reinforcing factors towards the development of resistance in tick population (personal observation).

In conclusion, (a) nature of farm (b) implementation of standard farming practices for the control of goat ticks i.e. open housing system, free animal keeping, cemented floors and walls of shed; (c) consultancy with veterinarians (d) trends of therapy (e) therapeutic approach and (f) choice of drug are the significant components to minimize the tick-burden from goat population in Pakistan.

CONFLICT OF INTEREST

None declared by the authors.

REFERENCES

- Abunna F, Tura J, Regassa A (2012) Status of tick infestation in small ruminants of Bedelle District, Oromia region, Ethiopia. *Trop Anim Health Prod* 8:459.
- Afzal M, Naqvi AN (2003) Livestock resources of Pakistan: present status and future trends. Animal Sciences Division, Pakistan Agricultural Research Council, Islamabad 9: 1-14.
- Ali A, Khan MA, Zahid H, Yaseen PM, Qayash Khan M, Nawab J, Ur Rehman Z, Ateeq M, Khan S and Ibrahim M (2019) Seasonal dynamics, record of ticks infesting humans, wild and domestic animals and molecular phylogeny of *Rhipicephalus microplus* in Khyber Pakhtunkhwa Pakistan. *Front Physiol* 10:793
- Atif FA, Khan MS, Iqbal HJ, Arshad GM, Ashraf E, Ullah S (2012) Prevalence of *Anaplasma marginale*, *Babesia bigemina* and *Theileria annulata* infections among cattle in Sargodha district, Pakistan. *African J Agric Res* 7:3302-7
- Badar N, Iqbal Z, Sajid MS, Rizwan HM, Jabbar A, Babar W, Khan MN, Ahmed A (2017) Documentation of ethnoveterinary practices in district Jhang, Pakistan. *J Anim Plant Sci* 27(2): 398-406
- Batool M, Nasir S, Rafiq A, Yousaf I and Yousaf M (2019) Prevalence of tick infestation in farm animals from Punjab, Pakistan. *Pak Vet J*. xxxx, xx(x): xxx
- Beyecha K, Kumsa B, Beyene D (2014) Ectoparasites of goats in three agroecologies in central Oromia, Ethiopia. *Comp Clin Pathol* 23:21-28.
- Dipeolu OO (1983) Study on ticks of veterinary importance in Nigeria, An attempt to control tick infestation on a herd of cattle grazed on tick infested pasture through acaricide treatment alone. *Rev Elev Méd Vét Pays Trop* 36(4):379-385.
- Durrani AZ, Shakoori AR (2009) Study on ecological growth conditions of cattle *Hyalomma* ticks in Punjab, Pakistan. *Iranian J Parasitol* 4:19-25.
- Farooqi SH, Ijaz M, Saleem MH, Rashid MI, Oneeb M, Khan A, Aqib AI, Mahmood S (2017) Distribution of Ixodid tick species and associated risk factors in temporal zones of Khyber Pakhtunkhwa province, Pakistan. *Pakistan J Zool* 49(6):2011-2017.
- Fentahun T, Woldemariam F, Chanie M, Berhan M (2012) Prevalence of ectoparasites on small ruminants in and around Gondar town. *American-Eurasian J Sci Res* 7:106-111.
- Ghosh S, Bansal GC, Gupta SC, Ray D, Khan MQ, Irshad H, Shahiduz-zaman M, Seitzer U, Ahmed JS (2007) Status of tick distribution in Bangladesh, India and Pakistan. *Parasitol Res* 101(1):207-16.
- Gopalakrishnan A, Dimri U, Nandi A, Ajith Y, Joshi V, Jhambh R, Yattoo MI (2017) Prevalence study on tick infestations of goat in lower Shivalik region of Uttarakhand. *Int J Livest Res* 7(7):158-165.
- Hassan MA, Liu J, Rashid M, Iqbal N, Guan G, Yin H, Luocorresponding J (2018) Molecular survey of piroplasm species from selected areas of China and Pakistan. *Parasit Vectors* 11:457.
- Hussain SI, Kumar GA (1985) The incidence of ticks (Ixodidae: Ixodidae) infesting sheep and goats in Sind province, Pakistan. *Pak J Zool* 17:89-97.
- Iqbal A, Sajid MS, Khan MN, Khan MK (2013) Frequency distribution of hard ticks (Acari: Ixodidae) infesting bubaline population of district Toba Tek Singh, Punjab, Pakistan. *Parasitol Res* 112:535-41.
- Iqbal A, Sajid MS, Khan MN, Khan MK (2013) Frequency distribution of hard ticks (Acari: Ixodidae) infesting bubaline population of district Toba Tek Singh, Punjab, Pakistan. *Parasitol Res* 112:535-541.
- Irshad N, Qayyum M, Hussain M, Khan M (2010) Prevalence of tick infestation and theileriosis in sheep and goats. *Pak Vet J* 30:178-80.
- Jongejan F, Uilenberg G (2004) The global importance of ticks. *Parasitol* 129:S3-S14.
- Kabir MHB, Mondal MMH, Eliyas M, Mannan MA, Hashem MA, Deb-nath NC, Miazzi OF, Mohiuddin C, Kashem MA, Islam MR, Elahi MF (2011). An epidemiological survey on investigation of tick infestation in cattle at Chittagong district, Bangladesh. *African J Microbiol Res* 5:346-52.
- Kakar ME, Khan MA, Khan MS, Ashraf K, Kakar MA, Jan HS and Raz-zaq A (2017) Prevalence of tick infestation in different breeds of cattle in Balochistan. *J Anim Plant Sci*, 27(3): 797-802.
- Kakar MN, Kakarsulemankhel JK (2008) Prevalence of endo (Trematodes) and ecto-parasites in cows and buffaloes of Quetta, Pakistan. *Pak Vet J* 28:34-36.
- Karim S, Budachetri K, Mukherjee N, Williams J, Kausar A, Hassan MJ, Adamson S, Dowd SE, Apanskevich D, Arijio A, Sindhu ZU, Kakar MA, Khan RMD, Ullah S, Sajid MS, Ali A, Iqbal Z (2017) A study of ticks and tick-borne livestock pathogens in Pakistan. *PLOS Negl Trop Dis* 11(6):e0005681.
- Khan MI (1993) Taxonomical study of ticks of genus *Rhipicephalus* and their relation to the incidence of haemoparasites and comparative efficacy of different acaricides on ticks in sheep and goats in Kaghan valley. M.Sc. Thesis, College of Veterinary Sciences, Lahore, Pakistan.
- Khan MK, He L, Hussain A, Azam S, Zhang WJ, Wang LX, Zhang QL, Hu M, Zhou YQ, Zhao J (2013) Molecular epidemiology of *Theileria annulata* and identification of 18S rRNA gene and ITS regions sequences variants in apparently healthy buffaloes and cattle in Pakistan. *Infection, Gen Evol* 13:124-132
- Kumsa B, Beyecha K, Geloye M (2012) Ectoparasites of sheep in three agro-ecological zones in central Oromia, Ethiopia. *Onderstepoort J Vet Res* 79:1-7.
- Lloyd S (1983) Effect of pregnancy and lactation upon infection. *Vet Immun Immunopath* 4:153-176.
- MacLeod J (1935) *Ixodes ricinus* in relation to its physical environment. *Parasitol* 27:489-500.
- Milne A (1948) The ecology of the sheep tick, *Ixodes ricinus* microhabitat economy of the adult tick. *Parasitol* 40:14-34.
- Moshaverinia A, Dini M, Azizzadeh M (2012) Prevalence of ixodid tick infestation of sheep in the Arasbaran region of Iran. *J Parasit Dis* 36:230-233.
- Mustafa I, Shabbir RMK, Subhani M, Ahmad I, Raza A, Jamil S, Muqaddas H, Shabbir R, Ghani A, Mahmood T, Aslam M, Khan MR, Asif S, Malik IU, Raza A, Aqeel M, Qayyum M, Waqas A, Ahmed H (2014) Seasonal activity of tick infestation in goats and buffalo of Punjab Province (District Sargodha), Pakistan. *Kafkas Üniv Vet FakDerg* 20:655-62.
- Ogden NH, Swai E, Beauchamp G, Karimuribo E, Fitzpatrick JL, Bryant MJ, Kambarage D, French NP (2005) Risk factors for tick attachment to smallholder dairy cattle in Tanzania. *Prev Vet Med* 67:157-170
- Palomar AM, García-Álvarez L, Santibáñez S, Portillo A, Oteo JA (2014) Detection of tick-borne '*Candidatus* Neoehrlichia mikurensis' and *Anaplasma phagocytophilum* in Spain in 2013. *Parasit. Vectors* 7:57.
- Patel G, Shanker D, Jaiswal AK, Sudan V, Verma SK (2013) Prevalence and seasonal variation in ixodid ticks on cattle of Mathura district, Uttar Pradesh. *J Parasit Dis* 37:173-176.
- Peckle M, Pires MS, Dos TM, Santos, Roier EC, Da Silva CB, Vilela JA, Santos HA, Massard CL (2013) Molecular epidemiology of *Theileria equi* in horses and their association with possible tick vectors in the state of Rio de Janeiro, Brazil. *Parasitol Res* 112:2017-2025.
- Perveen F, Bilqees FM, Ahmad H, Bibi NS, Hussain FM (2010) Frequency of ixodid ticks infestation in livestock in two districts of NWFP, Pakistan. *Proceed Parasitol* 49:127-141.
- Radon K, Danuser B, Iversen M (2001) Respiratory symptoms in European animal farmers. *Eur Respir J* 17:747-754.
- Ramzan M, Unsar NU, Syed HMB, Ghulam M, Alamgir AK (2018) Knowledge, attitude and practices of herdsman about ticks and tick-borne diseases in district Multan. *Pak Entomol* 40(1):13-18.
- Rashid I, Saqib M, Ahmad T, Sajid MS (2019) Sero-prevalence and associated risk factors of q fever in cattle and buffaloes managed at institutional dairy farms. *Pak Vet J* xx(xx):xx-xx
- Rehman A, Nijhof AM, Sauter-Louis C, Schauer B, Staubach C, Conraths FJ (2017) Distribution of ticks infesting ruminants and risk factors associated with high tick prevalence in livestock farms in the semiarid and arid agro-ecological zones of Pakistan. *Parasites Vectors* 10:190
- Rizwan HM, Sajid MS, Abbas H, Qamar MF, Akram Q, Maqbool M

- (2019) Epidemiology and control of Congo fever in sacrificial animals of Pakistan. *Vet Sci Res* 01(02):18-24.
- Rojas A, Rojas D, Montenegro V, Gutiérrez R, Yasur-Landau D, Baneth G (2014) Vector-borne pathogens in dogs from Costa Rica: first molecular description of *Babesia vogeli* and *Hepatozoon canis* infections with a high prevalence of monocytic ehrlichiosis and the manifestations of co-infection. *Vet Parasitol* 199:121-128.
- Rony SA, Mondal MMH, Begum N, Islam MA, Affroze S (2010) Epidemiology of ectoparasitic infestations in cattle at Bhawal forest area, Gazipur. *Bang J Vet Med* 8:27-33.
- Sajid MS, Iqbal A, Khan MN, Muhammad G, Siddique RM, Iqbal Z, Khan MK, Siddique F (2013) Descriptive epidemiology of insects infesting domestic sheep (*Ovis aries*) of district Toba Tek Singh, Punjab, Pakistan. *Pak J Agri Sci* 50(1):117-122.
- Sajid MS, Kausar A, Iqbal A, Abbas H, Iqbal Z, Jones MK (2018) An insight into the ecobiology, vector significance and control of *Hyalomma* ticks (Acari: Ixodidae): A review. *Acta Trop* 187:229-239.
- Sajid MS, Iqbal Z, Shamim A, Siddique RM, Jawad-Ul-Hassan M, Rizwan HM (2017) Distribution and abundance of ticks infesting livestock population along Karakorum highway from Mansehra to Gilgit, Pakistan. *J Hellenic Vet Med Soc* 68:051-058.
- Sajid MS, Iqbal Z, Khan MN, Muhammad G, Khan MK (2011) Prevalence, associated determinants and *in vivo* chemotherapeutic control of hard ticks (Acari: Ixodidae) infesting domestic goats (*Capra hircus*) of lower Punjab, Pakistan. *Parasitol Res* 108: 601-609.
- Sajid MS, Iqbal Z, Khan MN, Muhammad G, Iqbal MU (2007) Effect of *Hyalomma* ticks (Acari: Ixodidae) on milk production of dairy buffaloes (*Bos Bubalus Bubalis*) of Punjab (Pakistan). *Italian J Anim Sci* 6:939-941.
- Schork MA, Remington RD (2010) Statistics with applications to the Biological and Health Sciences. 3rd edition Lexington KY: USA.
- Shemshad K, Rafinejad J, Kamali K, Piazak N, Sedaghat MM, Shemshad M, Biglarian MA, Nourolahi F, Beigi EV, Enayati AA (2012) Species diversity and geographic distribution of hard ticks (Acari: Ixodoidea: Ixodidae) infesting domestic ruminants, in Qazvin Province, Iran. *Parasitol Res* 110:373-380.
- Siddiqi MN, Jan AH (1986) Ixodid ticks (Ixodidae) of N.W.F.P. (Pakistan). *Pak Vet J* 6:124-126.
- Sindhu ZUD, Iqbal Z, Khan MN, Jonsson NN, Siddique M (2010) Documentation of ethno-veterinary practices used for treatment of different ailments in selected a hilly area of Pakistan. *Int J Agric Biol* 12:353-358.
- Soomro MH, Soomro SP, Bhutto MB, Akbar Z, Yaqoob M, Aarijo AG (2014) Prevalence of ticks in buffaloes in the upper Sindh Pakistan. *Buffalo Bulletin* 33:323-327.
- Soulsby EJJ (1982) Helminths, Arthropods and Protozoa of domesticated animals. 7th ed., Bailliere Tindall and Cassel Ltd., London, UK.
- Sultana N, Shamim A, Awan MS, Ali U, Hassan M, Siddique RM (2015). First pilot study on the prevalence of tick infestation in livestock of tehsil Hajira, Rawalakot, Azad Kashmir. *Adv Anim Vet Sci* 3:430-4.
- Thrusfield M, Christley R, Brown H, Diggle PJ, French N, Howe K, Kelly L, Annette O'Connor, Sargeant J, Wood H (2018). *Veterinary Epidemiology*. 4th Edition, John Wiley & Sons, Inc., 111 River Street, Hoboken, NJ 07030, USA.
- Vathsala M, Mohan P, Sacikumar, Ramesh S (2008) Survey of tick species distribution in sheep and goats in Tamil Nadu, India. *Small Rum Res* 74:238-242.
- Walker AR, Bouattour A, Camicas JL, Estrada-Pena A, Horak IJ, Latif AA, Pegram RG, Preston PM (2007) Ticks of domestic animals in Africa, Bioscience reports, Edinburgh, UK.
- Wanzala W (2017) Potential of traditional knowledge of plants in the management of arthropods in livestock industry with focus on (Acari) ticks. *Hindawi* 2017:1-33.

Determination of the ciprofloxacin-resistant *Escherichia coli* isolated from chicken meat in Turkey

S. Sahin

Department of Food Hygiene and Technology, Faculty of Veterinary Medicine, Sivas Cumhuriyet University, Sivas, Turkey

ABSTRACT. In this study, the occurrence of the ciprofloxacin-resistant (CR) *Escherichia coli* in chicken meat was determined, and their clonal relations were investigated by using pulsed-field gel electrophoresis (PFGE). Antimicrobial resistance patterns of *E. coli* isolates were determined by using disc diffusion assay, and minimum inhibitory concentration of ciprofloxacin was determined by E-test. Plasmid-mediated quinolone resistance (PMQR) and extended spectrum beta-lactamase (ESBL) resistance genes were also screened through polymerase chain reactions. Sixty chicken meat samples were collected from different supermarkets and butchers in Sivas, Turkey. CR *E. coli* strains were determined in 59 (98.3%) chicken meat samples. By analyzing PFGE fingerprint data, 34 different pulsotypes were determined. All *E. coli* strains were found to be resistant to nalidixic acid, enrofloxacin, and norfloxacin. In addition, isolates were resistant to levofloxacin (40.7%), ampicillin (94.9%), trimethoprim-sulfamethoxazole (76.3%), tetracycline (69.5%), and chloramphenicol (44.1%). However, isolates were susceptible to imipenem and colistin. In this study, 81.4% of CR *E. coli* isolates were observed to have a multidrug-resistant profile, which is defined as resistance to three or more classes of antibiotics. Through phenotypic confirmation tests, five isolates (8.3%) were determined to be ESBL-producing. The PMQR genes were not determined in any of the isolates. Two isolates (3.4%) possessed the *bla*_{CTX-M} and *bla*_{CMY-2} genes, and 40 isolates (67.8%) had the *bla*_{TEM} gene. Taken together, retail raw chicken meat is highly contaminated with CR *E. coli*. However, these isolates are not found to be carriers of the PMQR genes, indicating a low public health problem.

Keywords: Ciprofloxacin resistance; chicken meat; *E. coli*; plasmid-mediated quinolone resistance

Corresponding Author:

Seyda Sahin, Department of Food Hygiene and Technology,
Faculty of Veterinary Medicine, Sivas Cumhuriyet University, TR-58140 Sivas,
Turkey.
E-mail address: seydasahin@cumhuriyet.edu.tr

Date of initial submission: 28-08-2019
Date of revised submission: 12-06-2020
Date of acceptance: 29-07-2020

INTRODUCTION

Escherichia coli are commonly found in the gastrointestinal tract of humans and warm-blooded animals and can cause enteritis, urinary tract infection, septicemia, pneumonia, and meningitis in humans and animals (Allocati et al., 2013; Ray, 2004). The emergence of antimicrobial resistance threatens the treatment of *E. coli* infections. The higher prevalence of multidrug-resistant (MDR) *E. coli* strains have increased worldwide in the past few decades (Allocati et al., 2013; EFSA, 2019; Mavroidi et al., 2012). It is a well-known fact that the primary reason for the high prevalence of MDR *E. coli* is the unregulated use of antimicrobial agents in humans and animals (Seo and Lee, 2019).

Quinolones are broad-spectrum antibiotics widely used against gram-negative bacteria, including *E. coli* infections in human and veterinary medicines, which has eventually resulted in the rapid emergence of quinolone resistant bacteria (Borjesson et al., 2016; EFSA, 2019; WHO, 2007). The first generation of quinolone molecules were licensed for use in food animals at the beginning of the 1980s, and fluoroquinolones were licensed during the late 1980s and early 1990s (EMA, 2006). Since then, new fluoroquinolone molecules have been authorized, and a number of different veterinary medicines are now available on the market (EMA, 2006; Gouvea et al., 2015).

Two main mechanisms of quinolone resistance have been described: (i) alterations in the targets of quinolones, and (ii) decreased accumulation inside the bacteria due to decreased permeability of the membrane and/or an overexpression of efflux pump systems. Both of these mechanisms are noted to be chromosomally mediated (Ruiz, 2003). Chromosomal mutations located in the quinolone resistance-determining regions (QRDRs) of the *gyrA* and *gyrB* genes, which encode for the two DNA gyrase (topoisomerase II) subunits, and the *ParC* and *ParE* genes, which encode for two topoisomerase IV subunits (Jacoby, 2005). In addition, plasmid-mediated quinolone resistance (PMQR) genes were also noted to contribute to quinolone resistance by either altering the molecular structure of quinolone target enzymes or the enzymatic inhibition of quinolones (Martinez-Martinez et al., 1998).

PMQR genes, first reported in a pMG252 plasmid from a *Klebsiella pneumoniae* strain, were obtained from a patient's urine specimen at the University of Alabama, Birmingham in 1994 (Martinez-Martinez

et al., 1998). To date, different PMQR determinants have been identified, the *qnr* families, *aac(6')-Ib-cr* (drug modification), and *qepA* and *oqxAB* (active efflux pumps) (Rodriguez-Martinez et al., 2016), and are usually associated with mobile elements on plasmids often found to be incorporated into *sulI*-type integrons. Their sequences have been uploaded into the following web-based database: <http://www.lahey.org/qnrStudies/> (Jacoby et al., 2014; Martinez-Martinez et al., 2008). Importantly, mobile genetic elements carrying PMQR genes commonly carry other important antimicrobial resistance traits, such as extended spectrum β -lactamase (ESBL) genes (Robicsek et al., 2006; Allocati et al., 2013).

Despite the fact that the quinolones have never been used in Norway livestock production, ciprofloxacin resistance was determined by using selective method. These particular situations paved the way for investigations of PMQR genes in food from animal origins, especially in chicken meat, and were found to be significant from a public health point of view (Slettemeas et al., 2019). Although ciprofloxacin has been widely used in human and veterinary medicines in Turkey (Nazik et al., 2008; Şahintürk et al., 2016). Thus, the main aim of this study was to determine the occurrence of ciprofloxacin resistant *E. coli* strains by using selective enrichment and molecular characterization of PMQR (*qnrA*, *qnrB*, *qnrS*, *qnrC* and *aac(6')-Ib-cr*) in these isolates. The isolates were further characterized by pulsed-field gel electrophoresis (PFGE), and the presence of genes encoding different β -lactamases (*bla*_{CTX-M}, *bla*_{CMY-2}, *bla*_{TEM} and *bla*_{SHV}) was investigated.

MATERIALS AND METHODS

Sample Collection and Isolation of Ciprofloxacin Resistant *E. coli*

Sixty chicken meat samples were collected from different supermarkets and butchers from September to December 2018 in Sivas, Turkey. For the *E. coli* isolation, each chicken meat sample (25 g) was suspended in 225 mL of sterile Buffered peptone water (Oxoid CM0509) and was mixed by paddle blender (Interscience Bag Mixer, France) for 2 min. Then, the homogenate was incubated for 24 h at 37°C. At the end of the incubation, 100 μ L of the enrichment was plated on a Tryptone bile x-glucuronide (TBX) agar plate (Oxoid, CM0945), including 0.5 μ g/mL ciprofloxacin (Sigma-Aldrich, U.S.A), and incubated for 3 h at 44°C and then 24 h at 41°C. After incuba-

tion, green *E. coli* colonies (one colony per sample) isolated from each sample were subcultured on Columbia blood agar (Oxoid, CM0331). Isolates were stored in Tryptone soya broth (Oxoid CM0129) with 20% glycerol at -20°C. Species identification was performed using a MALDI-TOF (Bruker Daltonik GmbH, Leipzig, Germany). To identify bacterial species, each peak was directly matched against reference libraries and a result was considered valid (accurate identification to the species level) if the score value was ≥ 2.0 . When the scores obtained were < 2.0 , the samples were reevaluated.

Pulsed-Field Gel Electrophoresis

The genetic relatedness of the *E. coli* isolates in the current study was assessed by a PFGE procedure, and band profile analyses were performed by the Public Health Institution of Turkey (Ankara), as described previously (Durmaz et al., 2009), with XbaI restriction of DNA. The DNA band profiles were analyzed by using the BioNumerics software system (Applied Maths, Sint-Martens-Latem, Belgium). A 1% band tolerance was used for the comparison of DNA profiles. Cluster analysis was done by the unweighted pair group method using with arithmetic mean (UP-GMA). The level of the Dice similarity between patterns was defined at $\geq 85\%$.

Antimicrobial Susceptibility Testing

The antimicrobial susceptibilities of all the CR *E. coli* isolates were determined by the disc diffusion method in accordance with the CLSI guidelines (CLSI, 2015). The following discs of antibiotics (Bioanalyse, Turkey) were used: amoxicillin-clavulanic acid (AMC; 20/10 µg), ampicillin (AM; 10 µg), aztreonam (ATM; 30 µg), cefoxitin (FOX; 30 µg), cefuroxime (CXM; 30 µg), cefpodoxime (CPD; 30 µg), colistin (CT; 10 µg), imipenem (IPM; 10 µg), chloramphenicol (C; 30 µg), gentamicin (CN; 10 µg), tetracycline (TE; 30 µg), nalidixic acid (NA; 30 µg), ciprofloxacin (CIP; 5 µg), enrofloxacin (ENR; 30 µg), levofloxacin (LEV; 5 µg), norfloxacin (NOR; 30 µg), trimethoprim-sulfamethoxazole (SXT; 1.25/23.75 µg), and bacitracin (B; 30 µg). *E. coli* (ATCC 25922) was used as the standard strain in the disc diffusion assay, and the results were interpreted according to CLSI guidelines (CLSI, 2015). In addition, E-tests (Bioanalyse, Ankara, Turkey) determined the minimum inhibitory concentrations (MICs) of ciprofloxacin. Briefly, broth suspensions of *E. coli* strains equivalent to a 0.5 McFarland standard were prepared and

inoculated on Mueller-Hinton agar (Oxoid CM0337) plate. E-test strips were placed on the dry medium, which was then incubated under aerobic conditions for 24 h at 37°C. The cutoff breakpoints for ciprofloxacin were set at ≥ 4 µg/mL in accordance with the CLSI's epidemiological cutoff values (CLSI, 2015).

Determination and Characterization of PMQR and β -Lactamase Genes

All primers in this study are listed in Table 1. The genomic DNA was extracted by a standard boiling method, and the presence of the PMQR genes (*qnrA*, *qnrB*, *qnrS*, *qnrC*, *qnrD* and *aac(6')-Ib-cr*) were determined by PCR (Park et al., 2006; Robicsek et al., 2006). PCR reactions were prepared as 50 µL [5 µL 10x PCR buffer, 5 µL 25 mM MgCl₂, 250 µM from each dNTP, 1.25 U Taq DNA Polymerase (MBI, Fermentas), 50 pmol for each primer, and 25 ng genomic DNA]. The PCR protocol was conducted by using a Bio-Rad T100 gradient thermal cycler device (BioRad, California, USA). The PCR conditions were carried out in the following steps: initial denaturation at 94°C for 45 s (denaturation at 53°C for 45 s and hybridization at 72°C for 60 s) for 32 cycles. Screening for *aac(6')-Ib-cr* was carried out by PCR amplification, as previously described by Park et al. (2006). PCR conditions were carried out through the following steps: initial denaturation at 94°C for 45 s (denaturation at 55°C for 45 s and hybridization at 72°C for 45 s) for 34 cycles. PCR products were run on electrophoresis in 1.5% (w/v) agarose gel and stained with ethidium bromide (10 mg/mL) for 30 min, and then screened under an ultraviolet transilluminator (Vilber Lourmat Quantum ST4, Marne-la-Vallee Cedex 1, France), using a 100 bp DNA ladder (MBI, Fermentas) as reference. To detect CTX-M, CMY-2, TEM, and SHV type β -lactamase, the *bla*_{CTX-M}, *bla*_{CMY-2}, *bla*_{TEM}, and *bla*_{SHV} genes were also amplified by PCR assay, which was conducted as described (Hasman et al., 2005; Leinberger et al., 2010; Mulvey et al., 2003). The β -lactamase genes were confirmed by sequencing the PCR products, as described previously (Ahmed et al., 2007). PCR-positive amplicons were obtained from National Food Institute EURL-AR reference strains collection, Technical University of Denmark were used, and distilled water was used for the negative control. (<https://www.eurl-ar.eu/resources.aspx#refstrains>)

Table 1. Primer sequence of the used in PCR

Genes	Primer sequence (5'-3')	Product size (bp)	References
<i>qnrA</i>	F:GGATGCCAGTTTCGAGGA R:TGCCAGGCACAGATCTTG	492	Cavaco et al., 2008
<i>qnrB</i>	F:GGMATHGAAATTCGCCACTG R:TTTGCYGYTCGCCAGTCGAA	262	Cattoir et al., 2007
<i>qnrS</i>	F:TCGACGTGCTAACTTGCG R:GATCTAAACCGTCGAGTTCGG	466	Cavaco et al., 2008
<i>qnrC</i>	F:GGGTTGTACATTTATTGAATCG R:CACCTACCCATTTATTTTCA	307	Jacoby et al., 2009
<i>qnrD</i>	F:CGAGATCAATTTACGGGGAATA R:AACAAGCTGAAGCGCCTG	582	Cavaco et al., 2009
<i>aac(6')-Ib-cr</i>	F:TTGCGATGCTCTATGAGTGGCTA R:CTCGAATGCCTGGCGTGTTT	482	Park et al., 2006
<i>bla</i> _{CTX-M}	F:ATGTGCAGYACCAGTAARGTKATGGC R:TGGGTRAARTARGTSACCAGAAAYCAGCGG	593	Mulvey et al., 2003
<i>bla</i> _{CMY-2}	F:GCACTTAGCCACCTATACGGCAG R:GCTTTTCAAGAATGCGCCAGG	758	Hasman et al., 2005
<i>bla</i> _{TEM}	F:TGAGTATTCAACATTTCCGTGT R:TTACCAATGCTTAATCAGTGA	861	Leinberger et al., 2010
<i>bla</i> _{SHV}	F:CAAAACGCCGGGTATTC R:TTAGCGTTGCCAGTGCT	937	Leinberger et al., 2010

RESULTS

In this study, 59 (98.3%) CR *E. coli* isolates were obtained from 60 chicken meat samples. Of these 59 isolates, 34 different pulsotypes were obtained when the similarity threshold was taken as $\geq 85\%$. Among these pulsotypes, 18 isolates were determined as clonally unrelated, and the remaining 41 were found to be related, which resulted in 16 groups with two to four isolates in each group (Fig 1).

The results of the antimicrobial susceptibility tests of the CR *E. coli* strains from chicken meat samples are shown in Table 2. Fifty-nine CR *E. coli* isolates and the susceptibility to 12 antimicrobial classes of these isolates were obtained from chicken meat samples. According to the results, all *E. coli* strains (100%) were determined as resistant to B, NA, ENR, and NOR. However, 40.7% of the strains were determined resistant to LEV, and 94.9%, 76.3%, 69.5%, and 44.1% of the *E. coli* strains were determined resistant to AM, SXT, TE, and C, respectively. On the other hand, all *E. coli* strains were susceptible to IPM and CT. Additionally, susceptibility to FOX and ATM were 93.2% and 96.6% among all *E. coli* strains, respectively. MDR (≥ 3 different antimicrobial classes) was observed in 48 (81.4%) of the 59 isolates (Table 3). MDR profiles were assessed as the following: seven (14.6%) isolates were resistant to three anti-

microbial classes, 11 (22.9%) isolates were resistant to four, 15 (31.3%) isolates were resistant to five, nine (18.7%) isolates were resistant to six, five (10.4%) isolates were resistant to seven, and one (2.1%) isolate was resistant to eight antimicrobial classes. MIC values of CIP-resistant *E. coli* strains were determined as follows: ≥ 32 $\mu\text{g/mL}$ (42 isolates), ≥ 16 $\mu\text{g/mL}$ (three isolates), ≥ 12 $\mu\text{g/mL}$ (two isolates), ≥ 8 $\mu\text{g/mL}$ (seven isolates), and ≥ 6 $\mu\text{g/mL}$ (three isolates; Fig 1).

None of the PMQR genes (*qnrA*, *qnrB*, *qnrS*, *qnrC*, *qnrD*, and *aac(6')-Ib-cr*) were present among the isolates. Forty-six of the 59 CR *E. coli* isolates carried β -lactamase genes. Table 4 summarizes the results of the β -lactamase genes detected in CR *E. coli* isolates in this study. The *bla*_{TEM} gene was observed as predominant in CR *E. coli* isolates, and β -lactamase gene characterization revealed that 67.8% of the isolates had the *bla*_{TEM} gene ($n = 40$), 3.4% of the isolates had the *bla*_{CTX-M} and *bla*_{CMY-2} genes ($n = 2$), 3.4% of the isolates had the *bla*_{TEM} and *bla*_{CTX-M} genes ($n = 2$), and 3.4% of the isolates had the *bla*_{TEM} and *bla*_{CMY-2} genes ($n = 2$). None of the *E. coli* isolates contained the *bla*_{SHV} gene (Table 4). All the ampicillin-resistant isolates possessed the *bla*_{TEM} gene.

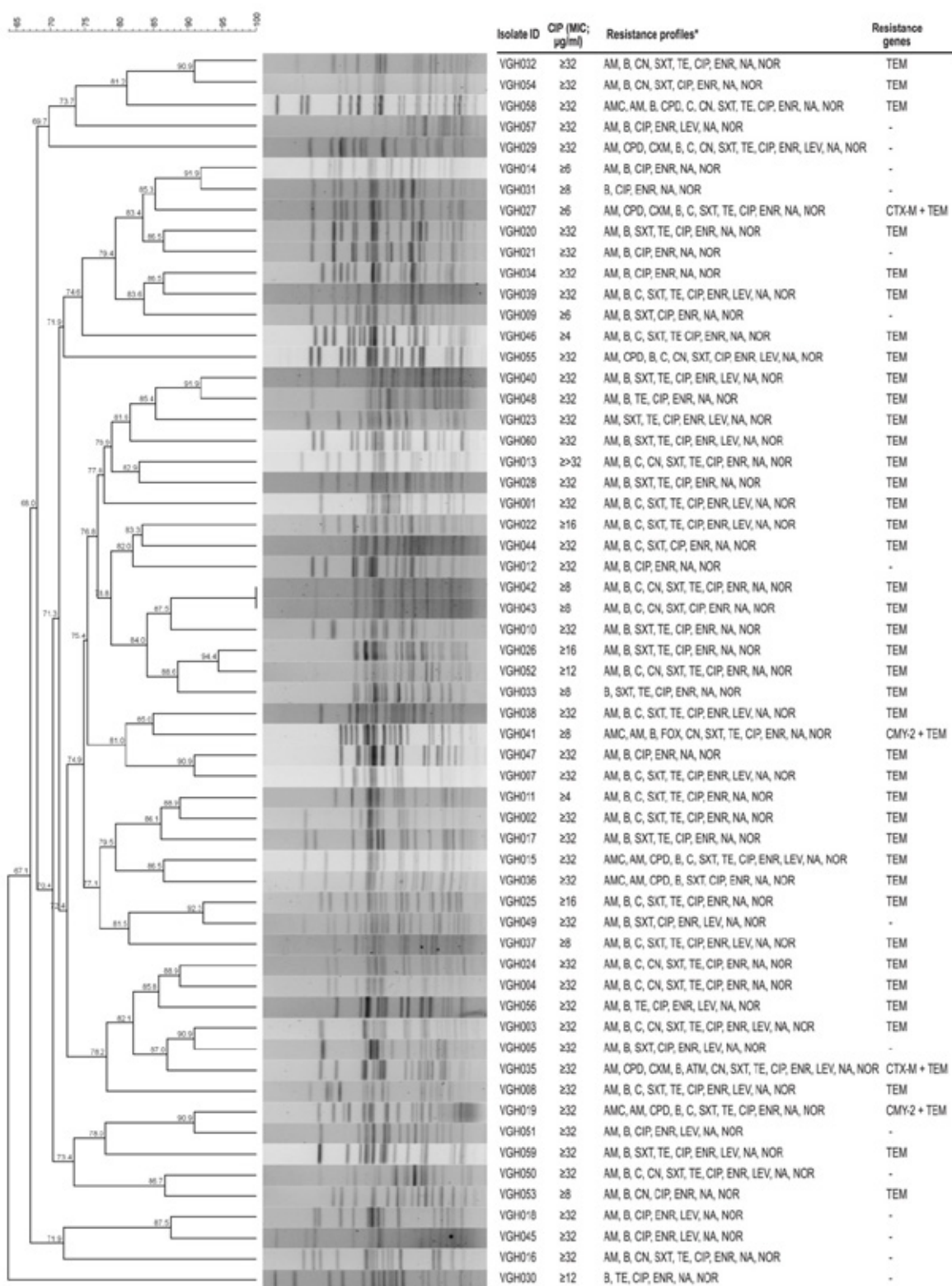
Table 2. Antimicrobial resistance of ciprofloxacin-resistant *Escherichia coli* isolated from chicken meat by disc diffusion assay (n = 59)

Antimicrobial Class	Antimicrobials	Number of isolates (%)		
		Resistant	Intermediate	Susceptible
Quinolones	Nalidixic acid	59 (100)	0	0
	Ciprofloxacin	56 (94.9)	3 (5.1)	0
	Enrofloxacin	59 (100)	0	0
	Levofloxacin	24 (40.7)	17 (28.8)	18 (30.5)
	Norfloxacin	59 (100)	0	0
Polipeptid	Bacitracin	59 (100)	0	0
Tetracyclines	Tetracycline	41 (69.5)	2 (3.4)	16 (27.1)
Folate pathway inhibitors	Trimethoprim-sulfamethoxazole	45 (76.3)	1 (1.7)	13 (22)
Aminoglycosides	Gentamicin	15 (25.4)	0	44 (74.6)
Phenicols	Chloramphenicol	26 (44.1)	4 (6.8)	29 (49.2)
β -lactam/ β -lactamase inhibitor combinations	Amoxicillin-clavulanic acid	5 (8.5)	5 (8.5)	49 (83.1)
Penicillins	Ampicillin	56 (94.9)	0	3 (5.1)
Cephems	Cefoxitin	1 (1.7)	3 (5.1)	55 (93.2)
	Cefpodoxime	9 (15.3)	0	50 (84.7)
	Cefuroxime	5 (8.5)	5 (8.5)	49 (83.1)
	Aztreonam	1 (1.7)	1 (1.7)	57 (96.6)
Monobactams	Imipenem	0	0	59 (100)
Lipopeptides	Colistin	0	0	59 (100)

Table 3. Antimicrobial resistance class pattern distribution for 48 multidrug-resistant *Escherichia coli* isolates from chicken meat

Antimicrobial resistance class patterns	No. of classes	No. of multidrug-resistant <i>E. coli</i> (%)	
		Frequency	
PCNs, PPs, FPIs	3	3	6.3
PCNs, PPs, TETs		1	2.1
PPs, FPIs, TETs		1	2.1
PCNs, PPs, TETs		1	2.1
PCNs, PPs, AMGs		1	2.1
PCNs, PPs, AMGs, FPIs	4	1	2.1
PCNs, PPs, FPIs, TETs		9	18.6
PCNs, PPs, PHs, FPIs		1	2.1
PCNs, PPs, AMGs, FPIs, TETs	5	2	4.2
PCNs, PPs, PHs, FPIs, TETs		11	22.9
PCNs, PPs, PHs, AMGs, FPIs		1	2.1
BL/BLICs, PCNs, CEPs, PPs, FPIs		1	2.1
PCNs, CEPs, PPs, PHs, FPIs, TETs	6	1	2.1
PCNs, CEPs, PPs, PHs, AMGs, FPIs		1	2.1
PCNs, PPs, PHs, AMGs, FPIs, TETs		7	14.5
PCNs, CEPs, PPs, PHs, AMGs, FPIs, TETs	7	1	2.1
PCNs, CEPs, PPs, MONs, AMGs, FPIs, TETs		1	2.1
BL/BLICs, PCNs, PPs, CEPs, AMGs, FPIs, TETs		1	2.1
BL/BLICs, PCNs, CEPs, PPs, PHs, FPIs, TETs		2	4.1
BL/BLICs, PCNs, PPs, CEPs, PHs, AMGs, FPIs, TETs	8	1	2.1
Total		48	(100)

AMGs, aminoglycosides; BL/BLICs, β -lactam/ β -lactamase inhibitor combinations; CEPs, cepheims; FPIs, folate pathway inhibitors; FPIs; PCNs, penicillins; MONs, monobactams; PHs, phenicols; TETs, tetracyclines; PPs, Polipeptids.



*AMC, amoxicillin-clavulanic acid; AM, ampicillin; ATM, aztreonam; FOX, ceftiofur; CXM, cefuroxime; CPD, cefpodoxime; C, chloramphenicol; CN, gentamicin; TE, tetracycline; NA, nalidixic acid; CIP, ciprofloxacin; ENR, enrofloxacin; LEV, levofloxacin; NOR, norfloxacin; SXT, trimethoprim-sulfamethoxazole; B, bacitracin. All *E. coli* strains were susceptible to imipenem and colistin, these two antimicrobials were not shown in the resistant profiles. - Not detected.

Figure 1. PFGE analysis of ciprofloxacin-resistant *Escherichia coli* isolates.

Table 4. Molecular characterization of *bla* and PMQR genes among ciprofloxacin-resistant *Escherichia coli* isolates (n = 59)

<i>bla</i> gene and PMQR	No. of isolates n (%)
TEM	40 (67.8)
TEM and CTX-M	2 (3.4)
TEM and CMY-2	2 (3.4)
CTX-M and CMY-2	2 (3.4)
SHV	-
<i>qnr A, B, S, C</i> and <i>aac (6'-lb-cr)</i>	-

- Not detected

DISCUSSION

The use of antimicrobials as growth promotion agents in food-producing animals has been prohibited in Turkey since 2006 (RG, 2006). Recently, Turkish Poultry Meat Producers and Breeders Association data also highlighted the decreasing trend in the use of antimicrobial drugs in poultry production in Turkey (Elmas et al., 2019). However, the occurrence of CR *E. coli* was determined as 98.3% in the current study, clearly showing a high level of contamination for chicken meat on the retail market in Turkey. The results obtained in the present study are not surprising because Ghodousi et al. (2015) reported 88.8% of CR *E. coli* isolates from chicken meat in Italy. For example, even though quinolone-based antibiotics have been not in use for poultry production, an increase in quinolone-resistant *E. coli* rates in broiler production processes were reported in Sweden (Borjesson et al., 2016). However, the results of this study were found to be much higher than the results from other countries, for example 37.4% in China (Xu et al., 2014) and 26% in the Czech Republic (Literak et al., 2013).

According to the PFGE analysis, CR *E. coli* isolates from chicken meat were clonally different. Such a difference can be attributed to the movements of humans, chickens, and vectors, and indicates that the contamination might not originate from a single source (Jakobsen et al., 2010; Sola-Gines et al., 2015). For example, in a study of *E. coli* isolated from slaughter animals in Poland, Wasyl et al. (2014) identified quinolone resistance mechanisms and noted chromosome-encoded quinolone resistance did not result from the spread of a single resistant clone, rather this was due to antimicrobial pressure leading to the selection of random *gyr* and *par* mutants.

In the present study, CR *E. coli* isolates from chicken meat samples were extremely resistant to AM (100%), SXT (76.3%), and TE (69.5%). For instance, in a previous study conducted by Ghodousi et al. (2015) in Italy, 134 *E. coli* were isolated from

109 chicken meat samples, and their resistance patterns were found for CIP (88.8%), CN (14.1%), SXT (79.1%), and TE (91.8%). In a study conducted by Soufi et al. (2011), 166 *E. coli* isolates were obtained from poultry meat (whole carcasses of chickens and turkeys) in Tunisia, and a significantly high percentage of resistance to ampicillin, nalidixic acid, sulfonamides, and tetracycline (66-95%) were observed among the isolates from poultry meat. Moreover, in another study performed by Xu et al. (2014) in China, all of the *E. coli* isolates were also resistant to AM (100%), SXT (94.3%), and TE (94.3%). High rates of resistance were observed for tetracycline (69.5%) in this study and were similar to the results reported from other countries (Soufi et al., 2011; Ghodousi et al., 2015; Xu et al. 2014). This finding is not surprising, as quinolone-resistant *E. coli* isolates were found from broilers in Sweden, which never approved these antimicrobials in the poultry industry.

In the current study, the CR *E. coli* isolates were mostly resistant to quinolone antibiotics, except for LEV. This resistance could be related to the levofloxacin molecule's C-8 methoxy group and the fluorinated quinolonic acid cores, which is different than the ciprofloxacin (Fu et al., 2013; Lu et al., 2001).

In this study, data showed that all 59 CR *E. coli* isolates had high levels of phenotypical MDR profiles (81.4%; n = 48) for the chicken meat in Turkey, which were resistant to three to eight classes of antimicrobial agents. Similar studies from the Czech Republic, Italy, and China found MDR *E. coli* in retail chicken meat at 82%, 66.9% and 59.4%, respectively (Ghodousi et al., 2015; Literak et al., 2013; Xu et al., 2014). In a study performed by Seo and Lee (2019) in Korea with 248 chicken meat samples, 152 isolates were observed to be positive for *E. coli*; 75 were identified as MDR *E. coli*. Of the MDR *E. coli* isolates, 13.3% were observed to be positive for PMQR genes, and 41.3% of the MDR *E. coli* isolates were found to be carrying class 1 integrons. The authors suggested

that PMQR genes and class 1 integrons were widely distributed in *E. coli* isolates from chicken meat and were contributed to resistance to diverse antimicrobial agents. In contrast, no PMQR genes (*qnrA*, *qnrB*, *qnrS*, *qnrC*, *qnrD*, and *aac(6')-Ib-cr*) were detected in this study. The PMQR genes were rare for Turkey (Kürekci et al., 2018; Müştak et al., 2012). However, CR *E. coli* was found with high rates in this study, and the occurrence of PMQR determinants was not always related with quinolone resistance. Yang et al. (2014) reported an increased prevalence of PMQR traits from 6.2–28.1% in 2004/2005 to 23.2–50.4% in 2010/2011, while ciprofloxacin resistance was relatively stable during the study period in China.

Several studies have shown the prevalence of PMQR genes in *E. coli* isolates from chicken meat products (Ghodousi et al., 2015; Literak et al., 2013; Yu et al., 2015). In this study, none of the PMQR genes (*qnrA*, *qnrB*, *qnrS*, *qnrC*, *qnrD*, and *aac(6')-Ib-cr*) were determined to be present in the 59 *E. coli* isolates. The prevalence of the PMQR genes (*qnrA*) in Italy was determined as 91% in nearly all of the *E. coli* isolates from the chicken meat samples (Ghodousi et al., 2015). On the other hand, PMQR genes were reported as 4% and 7.8% in the Czech Republic and China, respectively (Literak et al., 2013; Yu et al., 2015). Additionally, in other studies carried out in Turkey, a low-level presence of the PMQR gene was reported (Kürekci et al., 2018; Müştak et al., 2012). Previously in Turkey, Müştak et al. (2012) reported the presence of only the *qnrA* of the PMQR gene in five (5.3%) samples of 94 isolated chicken *E. coli* cloacal swaps. More recently, *qnrS* (n = 5) and *qnrB* (n = 8) of the PMQR genes from chicken meat were reported among the ESBL-producing *E. coli* strains obtained from chicken meat samples; however, *qnrA*, *qnrC*, *qnrD*, and *aac(6')-Ib-cr* genes were not found (Kürekci et al., 2018).

Quinolones are known to occur mainly through the accumulation of target enzyme point mutations. DNA gyrases (*gyrA* and *gyrB*) tend to be the primary target of quinolone in gram-negative bacteria, including *E. coli*, whereas in gram-positive bacteria, topoisomerase IV (*parC* and *parE*) is the primary target (Vanni et al., 2014). However, in the current study, *E. coli* isolates were not examined for chromosomal mutations. In addition, only PMQR genes were investigated in *E. coli* isolates, and PMQR genes were found in none of the isolates. In a study conducted by Xu et al. (2014), four topoisomerase point mutations showed ciproflox-

acin MIC ≥ 32 $\mu\text{g/mL}$ in all *E. coli* isolates, and the authors noted that higher ciprofloxacin MIC usually had more complex quinolone-resistant determinants, including PMQR mechanisms. In the same study (Xu et al., 2014), PMQR determinants were identified in more than 60% of the *E. coli* isolates. Xu et al. (2014) also noted the MIC value of ciprofloxacin was highly related to the accumulation of a resistance mechanism.

A meaningful correlation has been reported between ESBL (together with CTX-M types) and PMQR genes (Branger et al., 2005; Nordmann and Poirel, 2005). In a recent study of ESBL *E. coli* in milk and chicken meat samples by Kürekci et al. (2018), a significantly high rate of ESBL (86.7%) *E. coli* strains were reported to be isolated, and the authors noted that the CTX-M gene was quite prevalent (62.3%) in these isolates. In this study, 8.3% of the isolated CR *E. coli* was determined to be ESBL-positive, and two isolates (3.4%) possessed the *bla*_{CTX-M} and *bla*_{C-MY-2} genes, whereas 40 isolates (67.8%) possessed the *bla*_{TEM} gene. Similar findings were reported from other studies (Cohen Stuart et al., 2012; Xu et al., 2014; Yu et al., 2015). Moreover, all ampicillin-resistant isolates were positive for the presence of the *bla*_{TEM} gene. Literak et al. (2013) reported similar results for broiler samples in the Czech Republic.

CONCLUSION

The current study showed high rates of CR *E. coli* among retail chicken meat samples. Therefore, the prudent use of antimicrobial agents is an important issue to poultry farmers in Turkey. Although MDR was found to be high, the absence of the PMQR gene was favorable in terms of a public health concern. Hence, continuously investigating the MDR level and the feasibility of the limitations of antibiotics and the restrictions is essential.

CONFLICT OF INTEREST

None declared by the authors.

ACKNOWLEDGMENTS

I would like to thank Assoc. Prof. Dr. Cemil Kürekci (Hatay Mustafa Kemal University) for reviewing and discussing the results. I also would like to thank Dr. Özlem Ünalı (Public Health Institution of Turkey, Ankara) for helping me to analyze PFGE banding pattern on software. This research was supported by the Scientific Research Project Fund of Sivas Cumhuriyet University (Project Number: CUBAP V-083).

REFERENCES

- Ahmed AM, Motoi Y, Sato M, Maruyama A, Watanabe H, Fukumoto Y, Shimamoto T (2007) Zoo animals as reservoirs of gram-negative bacteria harboring integrons and antimicrobial resistance genes. *Appl Environ Microbiol* 73:6686-6690.
- Allocati NM, Masulli M, Alexeyev MF, Di Ilio C (2013) *Escherichia coli* in Europe: an overview. *Int J Environ Res Public Health* 10:6235-6254.
- Branger C, Zamfir O, Geoffroy S, Laurans G, Arlet G, Thien HV, Gouriou S, Picard B, Denamur E (2005) Genetic background of *Escherichia coli* and extended-spectrum beta-lactamase type. *Emerg Infect Dis* 11:54-61.
- Borjesson S, Guillard T, Landen A, Bengtsson B, Nilsson O (2016) Introduction of quinolone resistant *Escherichia coli* to Swedish broiler population by imported breeding animals. *Vet Microbiol* 194:74-78.
- Cattoir V, Poirel L, Rotimi V, Soussy CJ, Nordmann P (2007) Multiplex PCR for detection of plasmid-mediated quinolone resistance qnr genes in ESBL-producing enterobacterial isolates. *J Antimicrob Chemother* 60:394-397.
- Cavaco LM, Hasman H, Xia S, Aarestrup FM (2009) qnrD, a novel gene conferring transferable quinolone resistance in *Salmonella enterica* serovar Kentucky and Bovismorbificans strains of human origin. *Antimicrob Agents Chemother* 53:603-608.
- Cavaco LM, Frimodt-Møller N, Hasman H, Guardabassi L, Nielsen L, Aarestrup FM (2008) Prevalence of quinolone resistance mechanisms and associations to minimum inhibitory concentrations in quinolone-resistant *Escherichia coli* isolated from humans and swine in Denmark. *Microb Drug Resist* 14:163-169.
- Clinical and Laboratory Standards Institute (CLSI) (2015) Performance standards for antimicrobial susceptibility testing; twenty fifth informational supplement. CLSI document M100-S25. Clinical and Laboratory Standards Institute: Wayne, PA.
- Cohen Stuart J, Munchhof van den T, Voets G, Scharringa J, Fluit A, Hall ML (2012) Comparison of ESBL contamination in organic and conventional retail chicken meat. *Int J Food Microbiol* 154:212-214.
- Durmaz R, Otlu B, Koksall F, Hosoglu S, Ozturk R, Ersoy Y, Caliskan A (2009) The optimization of a rapid pulsed-field gel electrophoresis protocol for the typing of *Acinetobacter baumannii*, *Escherichia coli* and *Klebsiella spp.* *Jpn J Infect Dis* 62:372-377.
- Elmas E, Şen A, Karaca S, Pamukçu Ö, Ergün A, Koca S (2019) Türkiye beyaz et üretiminde veteriner tıbbi ürün kullanım trendleri. 5th International Poultry Meat Congress, 24-28 April 2019, pp: 127-131, Antalya/Turkey.
- European Medicines Agency (EMA) (2006) Reflection paper on the use of fluoroquinolones in food producing animals precautions for use in the spc regarding prudent use guidance. EMA/CVMP/416168/2006-FINAL. 8 November 2006. Available at: www.ema.europa.eu/docs/en_GB/document_library/Other/2009/10/WC500005173.pdf, [accessed 16 July 2019]
- European Food Safety Authority (EFSA) (2019) Available at: <https://efsa.onlinelibrary.wiley.com/doi/10.2903/j.efsa.2019.5598>. [accessed 14 March 2019]
- Fu Y, Zhang W, Wang H, Zhao S, Chen Y, Meng F, Zhang Y, Xu H, Chen X, Zhang F (2013) Specific patterns of *gyrA* mutations determine the resistance difference to ciprofloxacin and levofloxacin in *Klebsiella pneumoniae* and *Escherichia coli*. *BMC Infect Dis* 13:8
- Ghodousi A, Bonura C, di Noto AM, Mammina C (2015) Extended-spectrum β -Lactamase, AmpC-producing, and fluoroquinolone-resistant *Escherichia coli* in retail broiler chicken meat, Italy. *Foodborne Pathog Dis* 12:619-625.
- Gouvea R, Santos FD, de Aquino M, Pereira VL de A (2015) Fluoroquinolones in industrial poultry production, bacterial resistance and food residues: A review. *Braz J Poultry Sci* 17:1-10.
- Hasman H, Mevius D, Veldman K, Olesen I, Aarestrup FM (2005) Beta-lactamases among extended-spectrum beta-lactamase (ESBL)-resistant *Salmonella* from poultry, poultry products and human patients in The Netherlands. *J Antimicrob Chemother* 56:115-121.
- Jacoby GA, Strahilevitz J, Hooper DC (2014) *Plasmid-mediated quinolone resistance*. *Microbiol Spectr* 2:1-42.
- Jacoby GA, Gacharna N, Black TA, Millera GH, Hooper DC (2009) Temporal appearance of plasmid-mediated quinolone resistance genes. *Antimicrob Agents Chemother* 53:1665-1666.
- Jacoby GA (2005) Mechanisms of resistance to quinolones. *Clin Infect Dis* 41 (Suppl 2):120-126.
- Jakobsen L, Kurbasic A, Skjot-Rasmussen L, Ejrnaes K, Porsbo LJ, Pedersen K, Jensen LB, Emborg HD, Agersø Y, Olsen KE, Aarestrup FM, Frimodt-Møller N, Hammerum AM (2010) *Escherichia coli* isolates from broiler chicken meat, broiler chickens, pork, and pigs share phylogroups and antimicrobial resistance with community-dwelling humans and patients with urinary tract infection. *Foodborne Pathog Dis* 7:537-547.
- Kürekci C, Osek J, Aydın M, Tekeli IO, Kurpas M, Wiczorek K, Sakin F (2018) Evaluation of bulk tank raw milk and raw chicken meat samples as source of ESBL producing *Escherichia coli* in Turkey: Recent insights. *J Food Safety* e12605:1-7.
- Leinberger DM, Grimm V, Rubtsova M, Weile J, Schröppel K, Wichelhaus TA, Knabbe C, Schmid RD, Bachmann TT (2010) Integrated detection of extended-spectrum-beta-lactam resistance by DNA microarray-based genotyping of TEM, SHV, and CTX-M genes. *J Clin Microbiol* 48:460-471.
- Literak I, Reitschmied T, Bujnakova D, Dolejska M, Cizek A, Bardon J, Pokludova L, Alexa P, Halova D, Jamborova I (2013) Broilers as a source of quinolone-resistant and extraintestinal pathogenic *Escherichia coli* in the Czech Republic. *Microb Drug Resist* 19:57-63.
- Lu T, Zhao X, Li X, Drlica-Wagner A, Wang JY, Domagala J, Drlica K (2001) Enhancement of fluoroquinolone activity by C-8 halogen and methoxy moieties: action against a gyrase resistance mutant of mycobacterium smegmatis and a gyrase-topoisomerase IV double mutant of *Staphylococcus aureus*. *Antimicrob Agents Chemother* 45:2703-2709.
- Martinez-Martinez L, Eliecer Cano M, Manuel Rodriguez-Martinez J, Calvo J, Pascual A (2008) Plasmid-mediated quinolone resistance. *Expert Rev Anti Infect Ther* 6:685-711.
- Martinez-Martinez L, Pascual A, Jacoby GA (1998) Quinolone resistance from a transferable plasmid. *Lancet* 351:797-799.
- Mavroidi A, Miriagou V, Liakopoulos A, Tzelepi E, Stefanos A, Dalekos GN (2012) Ciprofloxacin-resistant *Escherichia coli* in Central Greece: mechanisms of resistance and molecular identification. *BMC Infect Dis* 12:371.
- Mulvey MR, Soule G, Boyd D, Demczuk W, Ahmed R, the Multi-provincial *Salmonella* Typhimurium Case Control Study Group (2003) Characterization of the first extended-spectrum beta-lactamase-producing *Salmonella* isolate identified in Canada. *J Clin Microbiol* 41:460-462.
- Müstak HK, İca T, Çiftci A, Diker KS (2012) Plasmid-mediated quinolone resistance in *Escherichia coli* strains isolated from animals in Turkey. *Ankara Univ Vet Fak Derg* 59:255-258.
- Nazik H, Öngen B, Kuvat N (2008) Investigation of plasmid-mediated quinolone resistance among isolates obtained in a Turkish intensive care unit. *Jpn J Infect Dis* 61:310-312.
- Nordman P, Poirel L (2005) Emergence of plasmid-mediated resistance to quinolones in *Enterobacteriaceae*. *J Antimicrob Chemother* 56:463-69.
- Park CH, Robicsek A, Jacoby GA, Sahm D, Hooper DC (2006) Prevalence in the United States of *aac(6)-Ib-cr* encoding a ciprofloxacin modifying enzyme. *Antimicrob Agents Chemother* 50:3953-3955.
- Ray B (2004) *Fundamental Food Microbiology*. 3. ed, CRC Press, Boca Raton: Florida.
- Resmi Gazete (RG) (2006) Yem Katkıları ve Premikslerin Üretimi, İthalatı, İhracatı, Satışı ve Kullanımı Hakkında Tebliğde Değişiklik Yapılmasına Dair Tebliğ. Tarım ve Köyişleri Bakanlığı'ndan. 21 Ocak 2006. Sayı: 26056 Tebliğ No: 2006/1 Resmi Gazete.
- Robicsek A, Strahilevitz J, Sahm DF, Jacoby GA, Hooper DC (2006) Qnr

- prevalence in ceftazidime-resistant *Enterobacteriaceae* isolates from the United States. *Antimicrob Agents Chemother* 50:2872-2874.
- Rodríguez-Martínez JM, Machuca J, Cano ME, Calvo J, Martínez-Martínez L, Pascual A (2016) Plasmid-mediated quinolone resistance: two decades on. *Drug Resist Updat* 29:13-29.
- Ruiz J (2003) Mechanisms of resistance to quinolones: target alterations, decreased accumulation and DNA gyrase protection. *J Antimicrob Chemother* 51:1109-1117.
- Seo KW, Lee YJ (2019) Prevalence and characterization of plasmid mediated quinolone resistance genes and class 1 integrons among multidrug-resistant *Escherichia coli* isolates from chicken meat. *J Appl Poult Res* 28:761-770.
- Slettemeas JS, Sunde M, Ulstad CR, Norstrom M, Wester AL, Urdahl AM (2019) Occurrence and characterization of quinolone resistant *Escherichia coli* from Norwegian turkey meat and complete sequence of an IncX1 plasmid encoding *qnrS1*. *PLoS ONE* 14:e0212936.
- Sola-Gines M, Gonzalez-Lopez JJ, Cameron-Veas K, Piedra-Carrasco N, Cerda-Cuellar M, Migura-Garcia L (2015) Houseflies (*Musca domestica*) as vectors for extended-spectrum β -lactamase-producing *Escherichia coli* on Spanish broiler farms. *Appl Environ Microbiol* 81:3604-3611.
- Soufi L, Sáenz Y, Vinué L, Abbassi MS, Ruiz E, Zarazaga M, Ben Hassen A, Hammami S, Torres C (2011) *Escherichia coli* of poultry food origin as reservoir of sulphonamide resistance genes and integrons. *Int J Food Microbiol* 144:497-502.
- Şahintürk P, Arslan E, Buyukcangaz E, Sonal S, Şen A, Ersoy F, Webber MA, Piddock LJV, Cengiz M (2016) High level fluoroquinolone resistance in *Escherichia coli* isolated from animals in Turkey is due to multiple mechanisms. *Turk J Vet Anim Sci* 40:214-218.
- Vanni M, Meucci V, Tognetti R, Cagnardi P, Montesissa C, Piccirillo A, Rossi AM, di Bello D, Intorre L (2014) Fluoroquinolone resistance and molecular characterization of *gyrA* and *parC* quinolone resistance-determining regions in *Escherichia coli* isolated from poultry. *Poultry Sci* 93:856-863.
- Wasyl D (2014) Prevalence and characterization of quinolone resistance mechanisms in commensal *Escherichia coli* isolated from slaughter animals in Poland, 2009-2012. *Microb Drug Resist* 20:544-549.
- World Health Organization (WHO) (2007) Available at: <https://www.who.int/whr/2007/en>. [accessed 21 March 2019]
- Xu X, Cui S, Zhang F, Luo Y, Gu Y, Yang B, Li F, Chen Q, Zhou G, Wang Y, Pang L, Lin L (2014) Prevalence and characterization of cefotaxime and ciprofloxacin co-resistant *Escherichia coli* isolates in retail chicken carcasses and ground pork, China. *Microb Drug Resist* 20:73-81.
- Yang T, Zeng Z, Rao L, Chen X, He D, Lv L, Wang J, Zeng L, Feng M, Liu JH (2014) The association between occurrence of plasmid-mediated quinolone resistance and ciprofloxacin resistance in *Escherichia coli* isolates of different origins. *Vet Microbiol* 170:89-96.
- Yu T, Jiang X, Fu K, Liu B, Xu D, Ji S, Zhou L (2015) Detection of extended-spectrum β -lactamase and plasmid-mediated quinolone resistance determinants in *Escherichia coli* isolates from retail meat in China. *J Food Sci* 80:M1039-1043.

Concurrent occurrence of *Anaplasma phagocytophilum* and *A. marginale* in bovine peripheral blood samples from southwest of Iran

S. Bahrami¹, H. Hamidinejat¹, M.R. Haji Hajikolaie², S. Kavianifar¹

¹ Department of Parasitology, Faculty of Veterinary Medicine, Shahid Chamran University of Ahvaz, Ahvaz, Iran

² Department of Clinical Sciences, Faculty of Veterinary Medicine, Shahid Chamran University of Ahvaz, Ahvaz, Iran

ABSTRACT: *Anaplasma phagocytophilum* and *A. marginale* are the most important tick-borne bacteria of veterinary and public health significance. *Anaplasma phagocytophilum* causes febrile disease in humans (human granulocytic-HGA) and animals. *Anaplasma marginale* is the aetiological agent of acute anaplasmosis, a bovine syndrome characterized by progressive hemolytic anemia associated with fever, weight loss, abortion, decreased milk production, and in some cases, death of the infected cattle. The present study was designed to investigate the prevalence of *A. phagocytophilum* and *A. marginale* in cattle from Khuzestan province, southwest of Iran. Samples were collected between March to August 2016. Farmed cattle were selected from the four geographic regions of Khuzestan province with the highest population of cattle herds: Behbahan; Dezful; Shushtar; and Ahvaz. Blood samples were collected from the jugular vein of 200 cattle. Species specification was accomplished by specific Nested PCR according to amplification of the 16S rRNA gene. To identify *A. marginale*, semi-nested PCR product was cut with restriction endonucleases Bst 1107 I. The prevalence of the *A. marginale* infection (21.5 %) was higher than that of *A. phagocytophilum* (7.5 %), which was found in a mixed infection with *A. marginale*. Overall, in the present study 7.5% of cattle were infected with both *A. phagocytophilum* and *A. marginale*. Despite the healthy appearance of infected cattle, they can transmit *Anaplasma* to ticks and are potential continuous sources for maintaining and disseminating the organisms to the human and animals' population. More epidemiological studies are needed to determine the vectors and reservoir animals for the *Anaplasma* species and to clarify the pathogenicity of *A. marginale* and *A. phagocytophilum* for humans and animals in Iran.

Keywords: *Anaplasma phagocytophilum*, *A. marginale*, Cattle, Khuzestan province, Iran

Corresponding Author:

S. Bahrami, Department of Parasitology, Faculty of Veterinary Medicine, Shahid Chamran University of Ahvaz, Ahvaz, Iran
E-mail address: s.bahrami@scu.ac.ir

Date of initial submission: 10-12-2019

Date of acceptance: 21-05-2020

INTRODUCTION

Many species of the genus *Anaplasma* induce different and distinct forms of anaplasmosis in cattle. The Office International des Epizooties (OIE) Animal Health Code categorizes anaplasmosis as a notifiable disease due to its socio-economic impact and international trade restrictions. However, the significance of anaplasmosis is frequently underestimated due to seasonal outbreaks and stability in areas of endemicity. *Anaplasma phagocytophilum* and *A. marginale* are the most important tick-borne bacteria of veterinary and public health significance (OIE 2008).

Anaplasma phagocytophilum is a medically and veterinary important emerging tick-borne pathogen. It is an alpha pleomorphic gram-negative bacterium localized in the blood cells (primarily granulocytes) or endothelial cells of blood vessels (Rikihisa 2003). *Anaplasma phagocytophilum* causes febrile disease in humans (human granulocytic- HGA) and animals. *Ixodes ricinus* is the main vector of *A. phagocytophilum* throughout Europe. Additionally, the pathogen has been detected with molecular methods in *I. persulcatus*, as well as in *Dermacentor reticulatus*, *Haemaphysalis concinna*, and *I. ventralloii* ticks (Masuzawa et al. 2008; Paulauskas et al. 2012; Santos et al. 2004; Tomanovic et al. 2013). *Anaplasma marginale* is the aetiological agent of acute anaplasmosis, a bovine syndrome characterized by progressive hemolytic anemia associated with fever, weight loss, abortion, decreased milk production, and in some cases, death of the infected cattle (Wannduragala et al. 1993). Transmission routes include ticks, particularly *Dermacentor spp.*, as well as mechanical transmission by biting flies and fomites (iatrogenically). Cattle that survive acute infection by *A. marginale* and *A. phagocytophilum* progress to become subclinical carriers of infection. The carrier animals can serve as reservoirs of infection for naïve cattle despite vaccination with live *A. centrale* bacteria and treatment in countries where domestic ruminants are vaccinated (Coetzee et al. 2006). The main methods for diagnosing anaplasmosis include serological tests and microscopic examination of Giemsa-stained blood smears (Aubry & Geale 2011), although these methods have limitations as the specific detection or as the detection of low levels of parasitemia. Thereby, a specific and sensitive molecular diagnostic method would improve detection and differentiation between species. There is very little information on *A. phagocytophilum* in Iran; therefore, the present study was designed to establish the prevalence of *A. phagocytophilum* and *A.*

marginale in cattle of Khuzestan province, Southwest of Iran.

MATERIALS AND METHODS

Study sites and collection of samples

Khuzestan province has a border of about 64,236 km², between 47° and 41' to 50° and 39' of eastern longitude from prime meridian and 29° and 58' to 33° and 4' of northern latitude from the equator (Statistical book of Khuzestan province 2006). The province has hot and wet summers, mild spring, and cold winters. Samples were collected between March to August 2016. Farmed cattle were selected from the four geographic regions of Khuzestan province with the highest population of cattle herds: Behbahan; Dezful; Shushtar; and Ahvaz. Blood samples were collected from the jugular vein of 200 cattle into sterile vacuum tubes containing EDTA and kept at -20°C until analyzed.

Polymerase chain reaction and nested-PCR for *A. phagocytophilum* identification

DNA was exploited by the application of the genomic DNA extraction Kit (Cinnagen, Iran). Species specification was accomplished by specific Nested PCR according to amplification of the 16SrRNA gene which conserved for all *Anaplasma* species. PCR protocol and primer selection were adopted according to the previously described by Noaman and Shayan (2009). Briefly, amplification of the 16S rRNA gene was performed in 25µl reaction volumes including 5µl of DNA template, 5 pmol of forward and reverse primers (P1/P2 each 1µl), 12.5µl of master mix (Ampliqon, Denmark) containing 3mM MgCl₂, 0.4mM of each dATP, dCTP, dGTP and dTTP and 0.08 U/ml Taq DNA polymerase in reaction buffer. The thermal program of PCR was as follows: 95°C for 5 min, 35 cycles of 94°C for 45s, annealing at 56°C for 45s, and 72°C for 45s, followed by a final extension step at 72°C for 5 min. Amplified products were identified using 2% of agarose gel stained by safe stain and compared with a 100bp ladder after visualization by UV transilluminator. To control the specificity of the PCR products for the 16S rRNA gene of *Anaplasma spp.*, the nested PCR technique was used, in which the additional primers (P3/P4) from the same gene were designed upstream from forward primer (P1) and downstream from reverse primer (P2). To confirm *A. phagocytophilum*, another specific PCR with primers P5/P4 was used. The primers are listed in Table 1. All the circumstances for nested PCRs including thermal

program were identical to prime PCR. One μ l of first PCR was used as the template in nested PCRs.

Semi nested PCR-RFLP for *A. marginale* identification

To identify *A. marginale*, DNA was amplified using P1/P4 primers. Prime PCR product was used as a template. 10 μ l of semi-nested PCR product was then cut with 0.1 μ l restriction endonuclease Bst 1107 I (Roche, Germany, 10U/ μ l) in 2.5 μ l 10 x corresponding buffer and 12.5 μ l H₂O for 1 h by 37°C. As control 10 μ l PCR products were treated with 2.5 μ l 10 x corresponding buffer and 12.5 μ l H₂O without adding

of the enzyme.

RESULTS

A total of 200 cattle was obtained from the four geographic regions of Khuzestan province, south-west of Iran: 61 samples were collected in Behbahan (30.5%), 40 in Dezful (20%), 45 in Shushtar (22.5%), and 54 in Ahvaz (27%) (Fig 1). The prevalence of *Anaplasma spp.* among 200 cattle was 21.5% with P1/P2 and P3/P4 but the overall prevalence of *A. phagocytophilum* was 7. 5% (15/200) with P5/P4. Fig 2. showed amplification of *Anaplasma spp.* and *A. phagocytophilum* in the mentioned methods.

Table 1. List of primers used in the present study to detect *Anaplasma spp.*, *A. phagocytophilum*, and *A. marginale*.

Primer	Nucleotide sequence	Positions	PCR product
P1	5'-agagtttgatcctggctcag-3'	1-20	781bp
P2	5'-agcactcatcggttacacgcg-3'	781-762	
P3	5'-gcaagcttaacacatgcaagtc-3'	35-56	
P4	5'-gttaagccctggtatttcac-3'	577-558	543bp
P5	5'-ctttatagcttgctataaagaa-3'	69-90	509bp
P4	5'-gttaagccctggtatttcac-3'	577-558	
P1	5'-agagtttgatcctggctcag-3'	1-20	577bp
P4	5'-gttaagccctggtatttcac-3'	577-558	

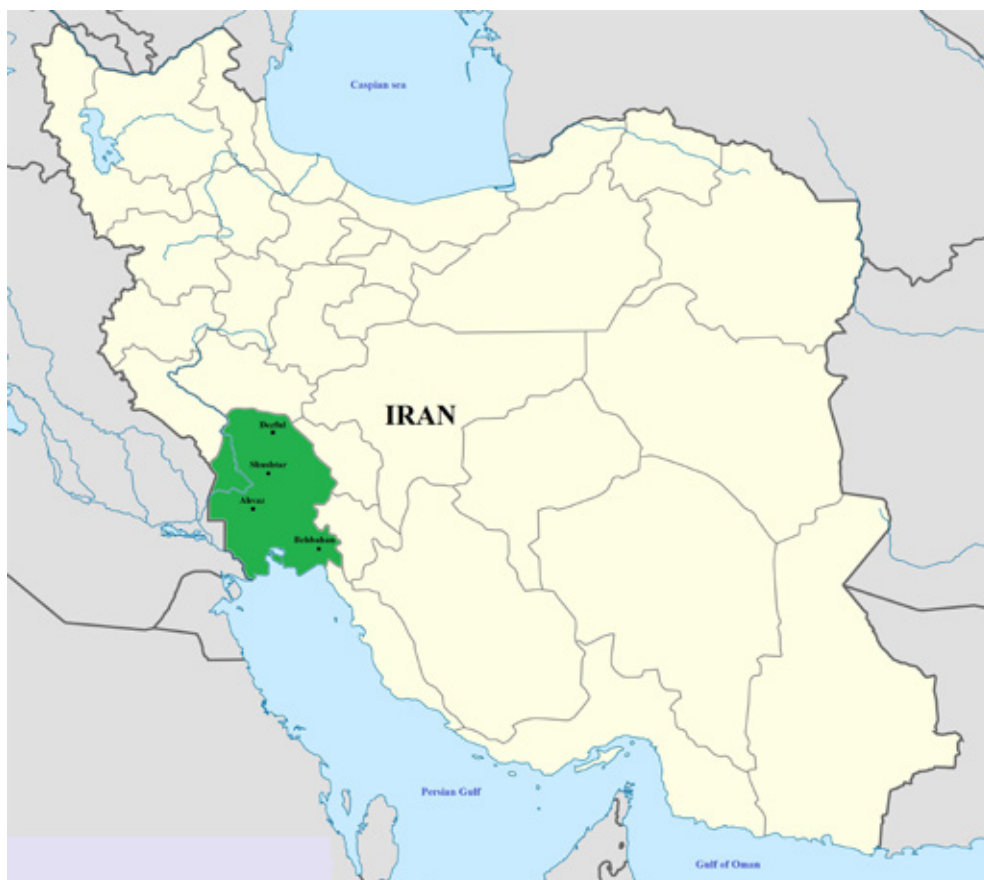

Figure 1. Map of Iran and Khuzestan province. Sampling locations were included Ahvaz, Behbahan, Dezful, and Shushtar.

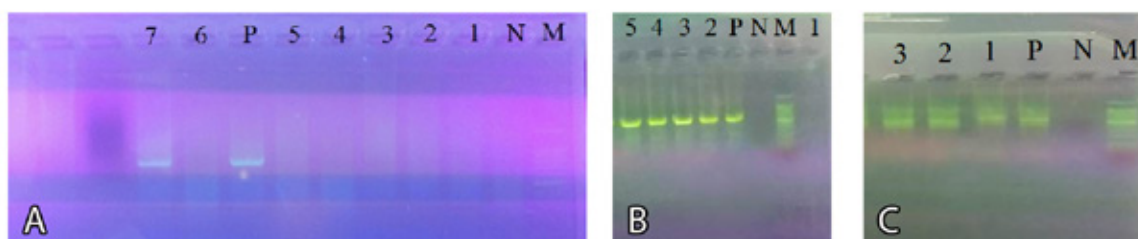


Figure 2. A: Agarose gel electrophoresis of PCR of 16SrRNA gene (P1/P2), 1-6: negative samples, 7: positive sample for *Anaplasma* spp. with 781bp of amplified products; B: PCR (P3/P4), 1: negative sample, 2-5: positive samples for *Anaplasma* spp. with 543bp of amplified products; C: Specific PCR (P5/P4), 1-3: positive samples for *A. phagocytophilum* with 509bp of amplified products. P, N, and M represent positive control, negative control, and marker (100bp), respectively.

Table 2. Prevalence of *Anaplasma* spp. based on different methods.

Method	No. examined (%)	Positive (%)	Negative (%)
PCR with P1/P2 primers to detect <i>Anaplasma</i> spp.	200 (100)	43 (21.5)	157 (78.5)
PCR with P3/P4 primers to detect <i>Anaplasma</i> spp.	200 (100)	43 (21.5)	157 (78.5)
PCR with P5/P4 primers to detect <i>A. phagocytophilum</i>	200 (100)	15 (7.5)	185 (92.5)
PCR with P1/P4 primers to detect <i>A. marginale</i>	200 (100)	43 (21.5)	157 (78.5)

Table 3. Prevalence of *A. phagocytophilum* and *A. marginale* in four geographic regions of Khuzestan province, southwest of Iran.

	Locality	No. examined (%)	Positive (%)	Negative (%)
<i>A. phagocytophilum</i>	Ahvaz	54 (27)	3 (5.5)	51 (94.5)
	Behbahan	61 (30.5)	4 (6.5)	57 (93.5)
	Dezful	40 (20)	3 (7.5)	37 (92.5)
	Shushtar	45 (22.5)	5 (11.5)	40 (88.9)
	Total	200 (100)	15 (7.5)	185 (92.5)
<i>A. marginale</i>	Ahvaz	54 (27)	14 (25.9)	40 (74.1)
	Behbahan	61 (30.5)	13 (21.3)	48 (78.7)
	Dezful	40 (20)	7 (17.5)	33 (82.5)
	Shushtar	45 (22.5)	9 (20)	36 (80)
	Total	200 (100)	43 (21.5)	157 (78.5)

Amplification of all PCR products with primers P1/P4 resulted in the PCR product of 577 bp. Then the later PCR product was purified and cut with the restriction endonuclease Bst 1107I. The restriction endonuclease Bst 1107I recognizes the sequence (GTATAC) in a corresponding PCR product of *A. marginale* and cut it in the position 68, whereas the used restriction enzyme cannot cut the corresponding PCR product of *A. ovis* (GTACGC) or *A. centrale* (GTACGC). Analysis of all 43 *Anaplasma* positive PCR products with the restriction endonuclease

Bst1107I showed that all PCR products could be cut in two expected DNA fragments with 509 bp and 68 bp in length, respectively. Forty-three cattle (21.5%) were infected with *A. marginale* and in 7.5% of cattle co-infection of *A. phagocytophilum* and *A. marginale* was occurred. Table 2. showed the prevalence of *Anaplasma*, *A. phagocytophilum* and *A. marginale* in 200 cattle.

Based on the statistical analysis there was no significant relationship between infection with *A. mar-*

ginale and *A. phagocytophilum* and the geographic regions of infected animals. Table 3. showed the number of sampled animals, locality, and molecular detection of *A. marginale* and *A. phagocytophilum*.

DISCUSSION

The tick-borne, hemoparasitic diseases are among the most devastating to cattle worldwide and include rickettsial diseases. These diseases, enzootic principally in countries with tropical and subtropical climates, place over one-half billion cattle at risk to one or more of the infectious agents. Hence, clinical manifests of *A. phagocytophilum*, if present, are not pathognomonic, therefore the diagnosis of this infection is basically based upon paraclinical aspects of the infection. For this purpose, many diagnostic approaches including microscopy to recognize morulae in leukocytes, different serologic procedures, and tracing DNA of rickettsia from blood, buffy coat, bone marrow, or spleen are well described by researchers are developed (Carade et al. 2009). Most of the molecular techniques target the major surface proteins (MSPs) (de la Fuente et al. 2007), the heat-shock gene *groEL* (Park et al. 2005), the 23S rRNA (Dahmani et al. 2015) and the 16S rRNA gene (Reinbold et al. 2010). Here, we targeted the 16S rRNA. Based on our results 21.5% of cattle were infected with *A. marginale* while 7.5% were infected with *A. phagocytophilum* which was found in a mixed infection with *A. marginale*. Despite the importance of *A. phagocytophilum*, there is limited information on the occurrence of *A. phagocytophilum* in Iran. For the first time Noaman and Shayan (2009) detected *A. phagocytophilum* in 1.33% of cattle from Iran. Yousefi et al (2017) studies showed that 1.08% (4/370) of Iranian domesticated small ruminants were positive for *A. phagocytophilum* infection. In our previous study, the molecular prevalence of *A. phagocytophilum* was noticeably high in rural dogs of Khuzestan province (Hamidinejat et al. 2019). The risk of exposure to the vector-borne pathogen is, among other factors, influenced by the abundance of the vector and the prevalence of the pathogen within the vector population (Medlock et al. 2013). Khuzestan province has wet weather with hot summer. The weather conditions of the province are perfectly suitable for ticks' growth and multiplication. *Anaplasma phagocytophilum* is usually associated with ticks of the genus *Ixodes*, including *I. scapularis*, *I. pacificus* (Parola et al. 2005) and *I. dentatus* (Goethert & Telford 2003) in the USA; *I. ricinus* and *I. trianguliceps* in Europe (Bown et al. 2008); and *I. persulcatus* in

Asia (Cao et al. 2003). However, based on our previous study *Ixodes* is not found in Khuzestan province but other ticks including, *Dermacentor reticulatus*, *D. silvarum*, *D. variabilis*, *Haemaphysalis concinna*, *H. megaspinosa*, *H. longicornis*, *Hyalomma* (Hy) *marginatum* and *Hy. detritum* are endemic (unpublished). It should be mentioned that *A. phagocytophilum* has been detected with molecular methods in *D. reticulatus*, *D. silvarum*, *D. variabilis*, *D. occidentalis*, *D. albipictus*, *H. concinna*, *H. megaspinosa*, *H. douglasi*, *H. longicornis*, *H. japonica*, *Hy marginatum*, *Hy. Detritum*, *R. turanicus* and *Boophilus kohlsi* (Cao et al. 2003; Baldrige et al. 2009; Jiang et al. 2011). Mechanical transmission by blood-sucking deer ked (*Lipoptena cervi*) from red deer (*Cervus elaphus*), roe deer (*Capreolus capreolus*), and fallow deer (*Dama dama*) have been reported using PCR (Vichová et al. 2010). It should be mentioned that in protected areas of Khuzestan province Persian fallow deer (*Dama dama mesopotamica*) can be found and they are known as one of Iran's wildlife species. Similarly, there are reports of transplacental (lambs and calves), perinatal, blood transfusions, and nosocomial associated transmissions (Horowitz et al. 1998; Dhand et al. 2007; Zhang et al. 2008; Annen et al. 2012). Variations in the prevalence of *A. phagocytophilum* in ticks may be attributed to several factors, such as the susceptibility of individual tick species, the susceptibility of certain tick populations, and the vector competence of tick species; the transmissibility of the *A. phagocytophilum* variant involved, the susceptibility of different host species, the susceptibility of individual hosts or host populations and the reservoir competence of the host. Especially the availability of different reservoir hosts and the adaptation strategy of *A. phagocytophilum* seem to be crucial factors in this variability. The availability of reservoir hosts depends on factors such as landscape structure and fragmentation (Medlock et al. 2013). Also, effects exerted by changes in climate, demography, and agriculture may influence the tick distribution and density and their hosts (Stuen et al. 2013).

Anaplasmosis caused by *A. marginale*, has the greatest worldwide prevalence. It is found on six continents and is responsible for high morbidity and mortality in cattle in temperate, subtropical, and tropical regions (Kocan et al. 2010). The obtained prevalence of *A. marginale* (21.5 %) was lower than that reported in Kansas (37.6 %) (Reinbold et al. 2010), India (73.1–36.8 %) (Sharma et al. 2015; Singh et al. 2012), Sicily (50 %) (De la Fuente et al. 2005), Brazil

(70.2 %) (Pohl et al. 2013), South African provinces (65-90 %) (Mutshembele et al. 2014), Texas (82 %) (Hairgrove et al. 2015) and Costa Rica (56.9 %) (Shebish et al. 2012). By contrast, this prevalence was higher than those recorded in Turkey (2.8 %) (Aktas et al. 2011) and the Philippines (19.8 %) (Ybanez et al. 2014). The significant prevalence of *A. marginale* warrants further investigation to evaluate the impact of this bacterium on livestock production, since it is a pathogenic species in Iran, causing severe clinical symptoms and very serious economic losses (Sergeant et al. 1945). However, at the time of blood sampling (March-August), the 43 cattle infected with *A. marginale* showed no clinical signs. These animals could be considered asymptomatic carriers.

Twenty different tick species are capable of transmitting *A. marginale* and play important roles in maintaining *A. marginale* in cattle (Kocan et al. 2004). In several geographic areas of the world *Dermacentor* species are the principal recognized vectors. Ticks can transmit the infection to susceptible cattle after acquiring the parasite from acutely infected or chronic carrier cattle (Goff et al. 1988). The agro-ecological and geo-climatic conditions of Khuzestan province highly favorable for growth and multiplication of ticks that act as natural vectors of anaplasmosis.

The pathogenesis of disease associated with *Anaplasma spp* infection is influenced by the tick vector as it attaches to host skin, feeds, and inoculates the animal with the bacteria. During feeding, hard ticks secrete bioactive salivary molecules into the skin to promote host bleeding and reduce anti-tick inflammation (Nuttall & Labuda 2004). Saliva may have a

complement, cytokine, and antibody inhibitors; histamine-binding proteins; leukocyte modulators; and anti-hemostatics. Thus, inoculation of tick-borne pathogens directly into the skin in the presence of tick saliva is likely to induce local changes in the dermis, and these changes may modulate the early pathogenesis of infection. *Anaplasma phagocytophilum* infection is immunosuppressive; thus, coinfection with *A. marginale* may modulate immunopathologic sequelae of infection, resulting in either enhancement of morbidity, increased mortality rate, or a cross-protective effect. Also, Sergeant et al. (1945) have shown that North African strains of *A. marginale* confer immune protection in experimentally infected animals.

CONCLUSIONS

In the present study 7.5% of cattle were infected with both *A. phagocytophilum* and *A. marginale*. Despite their healthy appearance, they can transmit *Anaplasma* to ticks and are a potential continuous source for maintaining and disseminating the organisms to the human and animals' population. The diagnosis of subclinical infections is important to prevent the spread of anaplasmosis. More epidemiological studies are needed to determine the vectors and reservoir animals for the *Anaplasma* species and to clarify the pathogenicity of *A. marginale* and *A. phagocytophilum* for humans and animals in Iran.

ACKNOWLEDGMENTS

This study was supported by the Shahid Chamran University of Ahvaz.

CONFLICT OF INTEREST

There is no conflict of interest.

REFERENCES

- Aktas M, Altay K, Dumanli N. (2011) Molecular detection and identification of *Anaplasma* and *Ehrlichia* species in cattle from Turkey. *Ticks Tick Borne Dis* 2: 62-65.
- Annen K, Friedman K, Eshoa C, Horowitz M, Gottschall J, Straus T (2012) Two cases of transfusion-transmitted *Anaplasma phagocytophilum*. *Am J Clin Pathol* 137: 562-565.
- Aubry P, Geale DW (2011) A review of bovine anaplasmosis. *Transbound Emerg Dis*;58 (1): 1-30.
- Baldridge GD, Scoles GA, Burkhardt NY, Schloeder B, Kurtti TJ, Munderloh UG (2009) Transovarial transmission of Francisella-like endosymbionts and *Anaplasma phagocytophilum* variants in *Dermacentor albipictus* (Acari: Ixodidae). *J Med Entomol*; 46: 625-632.
- Bown KJ, Lambin X, Telford GR, Ogden NH, Telfer S, Woldehiwet Z, Birtles RJ (2008) Relative importance of *Ixodes ricinus* and *Ixodes trianguliceps* as vectors for *Anaplasma phagocytophilum* and *Babesia microti* in field vole (*Microtus agrestis*) populations. *Appl Environ Microbiol* 74: 7118-7125.
- Cao WC, Zhao QM, Zhang PH, Yang H, Wu XM, Wen BH, Zhang XT, Habbema JD (2003) Prevalence of *Anaplasma phagocytophilum* and *Borrelia burgdorferi* in *Ixodes persulcatus* ticks from northeastern China. *Am J Trop Med Hyg* 68: 547-550.
- Carrade DD, Foley JE, Borjesson DL, Sykes JE (2009) Canine granulocytic Anaplasmosis: A review. *J Vet Intern Med* 23: 1129-1141.
- Coetzee JF, Apley MD, Kocan KM (2006) Comparison of the efficacy of enrofloxacin, imidocarb, and oxytetracycline for clearance of persistent *Anaplasma marginale* infections in cattle. *Vet Ther* 7: 347-360.
- Dahmani M, Davoust B, Benterki MS, Fenollar F, Raoult D, Mediannikov O (2015) Development of a new PCR-based assay to detect Anaplasmataceae and the first report of *Anaplasma phagocytophilum* and *Anaplasma platys* in cattle from Algeria. *Comp Immunol Microbiol Infect Dis* 39: 39-45.
- de la Fuente J, Ruybal P, Mtshali MS, Naranjo V, Shuqing L, Mangold AJ, Rodríguez SD, Jiménez R, Vicente J, Moretta R, Torina A, Almazán C, Mbatí PM, de Echaide ST, Farber M, Rosario-Cruz R, Gortazar C, Kocan KM (2007) Analysis of world strains of *Anaplasma marginale* using major surface protein 1a repeat sequences. *Vet Microbiol* 119: 382-390.
- De la Fuente J, Torina A, Caracappa S, Tumeno G, Furla R, Almazan C, Kocan KM (2005) Serologic and molecular characterization of *Anaplasma* species infection in farm animals and ticks from Sicily. *Vet Parasitol* 133: 357-362.
- Dhand A, Nadelman RB, Aguero-Rosenfeld M, Haddad FA, Stokes DP, Horowitz HW (2007) Human granulocytic anaplasmosis during pregnancy: case series and literature review. *Clin Infect Dis* 45: 589-593.
- Goethert HK, Telford SR 3rd (2003) Enzootic transmission of the agent of human granulocytic ehrlichiosis among cottontail rabbits. *Am J Trop Med Hyg* 68: 633-637.
- Goff W, Barbet A, Stiller D, Palmer G, Knowles D, Kocan K, Gorham J, McGuire T (1988) Detection of *Anaplasma marginale*-infected tick vectors by using a cloned DNA probe. *Proc Natl Acad Sci* 85: 919-923.
- Hairgrove T, Schroeder ME, Budke CM, Rodgersb S, Chungd C, Uetie MW, Bounpheng MA (2015) Molecular and serological in-herd prevalence of *Anaplasma marginale* infection in Texas cattle Preventive. *Vet Med* 119: 1-9.
- Hamidinejat H, Bahrami S, Mosalanejad B, Pahlavan S (2019) First molecular survey on *Anaplasma phagocytophilum* revealed high prevalence in rural dogs from Khuzestan province. *Iran J Parasitol* 14(2): 297-302.
- Horowitz HW, Aguero-Rosenfeld ME, Dumler JS, McKenna DF, Hsieh TC, Wu J, Schwartz I, Wormser GP (1998) Reinfection with the agent of human granulocytic ehrlichiosis. *Ann Intern Med* 129: 461-463.
- Jiang JF, Jiang BG, Yu JH, Zhang WY, Gao HW, Zhan L, Sun Y, Zhang XA, Zhang PH, Liu W, Wu XM, Xu RM, Cao WC (2011) *Anaplasma phagocytophilum* infection in ticks, China-Russia border. *Emerg Infect Dis* 17: 932-934.
- Kocan KM, de la Fuente J, Blouin EF, Coetzee JF, Ewing SA (2010) The natural history of *Anaplasma marginale*. *Vet Parasitol* 167: 95-107.
- Kocan KM, de la Fuente J, Blouin EF, Garcia-Garcia JC (2004) *Anaplasma marginale* (Rickettsiales: Anaplasmataceae): recent advances in defining host-pathogen adaptations of a tick-borne rickettsia. *Parasitol* 129: 285-300.
- Masuzawa T, Kharitononkov IG, Okamoto Y, Fukui T, Ohashi N (2008) Prevalence of *Anaplasma phagocytophilum* and its coinfection with *Borrelia afzelii* in *Ixodes ricinus* and *Ixodes persulcatus* ticks in habiting Tver Province (Russia) - asympatric region for both tick species. *J Med Microbiol* 57: 986-991.
- Medlock JM, Hansford KM, Bormane A, Derdakova M, Estrada-Peña A, George JC, Golovljova I, Jaenson TG, Jensen JK, Jensen PM, Kazimirova M, Oteo JA, Papa A, Pfister K, Plantard O, Randolph SE, Rizzoli A, Santos-Silva MM, Sprong H, Vial L, Hendrickx G, Zeller H, Van Bortel W (2013) Driving forces for changes in geographical distribution of *Ixodes ricinus* ticks in Europe. *Parasit Vectors* 6: 110-118.
- Mutshembele AM, Cabezas-Cruze A, Mtshali MS, Thekisoe OMM, Galindo RC, de la Fuente J (2014) Epidemiology and evolution of the genetic variability of *Anaplasma marginale* in South Africa. *Ticks Tick Borne Dis* 5: 624-631.
- Noaman V, Shayan P (2009) Molecular detection of *Anaplasma phagocytophilum* in carrier cattle of Iran - first documented report. *Iran J Microbiol* 1: 37-42.
- Nuttall PA, Labuda M (2004) Tick-host interactions: saliva-activated transmission. *Parasitol* 129: 177-189.
- Office International des É pizooties, Paris, France. http://www.oie.int/eng/normes/mmanual/2008/pdf/2.04.01_BOVINE_ANAPLASMO-SIS.pdf.
- Park HS, Lee JH, Jeong EJ, Park TK, Kim TY, Chae JS, Park JH, Klein TA, Jang WJ, Park KH, Lee SH (2005) Differentiation of Anaplasmataceae through partial groEL gene analysis. *Microbiol Immunol* 49: 655-662.
- Parola P, Davoust B, Raoult D (2005) Tick- and flea-borne rickettsial emerging zoonoses. *Vet Res* 36: 469-492.
- Paulauskas A, Radzijeuskaja J, Rosef O (2012) Molecular detection and characterization of *Anaplasma phagocytophilum* strains. *Comp Immunol Microbiol Infect Dis* 35: 187-195.
- Pohl AE, Cabezas-Cruz A, Flávio M, Ribeiro B, Angélica J, Silveira GA, Silaghi C, Pfister K, Passos LM (2013) Detection of genetic diversity of *Anaplasma marginale* isolates in Minas Gerais, Brazil. *Rev Bras Parasitol Vet* 22: 129-135.
- Reinbold JB, Coetzee JF, Sirigireddy KR, Ganta RR (2010) Detection of *Anaplasma marginale* and *A. phagocytophilum* in bovine peripheral blood samples by duplex real-time reverse transcriptase PCR assay. *J Clin Microbiol* 48: 2424-2432.
- Rikihisa Y (2003) Mechanisms to create a safe haven by members of the family Anaplasmataceae. *Ann N Y Acad Sci* 990: 548-555.
- Santos AS, Santos-Silva MM., Almeida VC, Bacellar F, Dumler JS (2004) Detection of *Anaplasma phagocytophilum* DNA in *Ixodes* ticks (*Acari: Ixodidae*) from Madeira Island and Setubal District, mainland Portugal. *Emerg Infect Dis* 38: 354-356.
- Sergeant E, Donatien A, Parrot L, Lestoquard F (1945) Etude sur les Piroplasmoses Bovines. *Arch Inst Pasteur Alger* 816.
- Sharma A, Singla LD, Tuli A, Kaur P, Bal MS (2015) Detection and assessment of risk factors associated with natural concurrent infection of *Trypanosoma evansi* and *Anaplasma marginale* in dairy animals by duplex PCR in eastern Punjab. *Trop Anim Health Prod* 47: 251-257.
- Shebish E, Vemulapalli R, Oseto C (2012) Prevalence and molecular detection of *Anaplasma marginale*, *Babesia bovis* and *Babesia bigemina* in cattle from Puntarenas Province, Costa Rica. *Vet Parasitol* 188: 164-167.
- Singh H, Jyoti Haque M, Singh NK, Rath SS (2012) Molecular detection of *Anaplasma marginale* infection in carrier cattle. *Ticks Tick Borne Dis* 3: 55-58.
- Stuen S, Granquist EG, Silaghi C (2013) *Anaplasma phagocytophilum*

- a widespread multi-host pathogen with highly adaptive strategies. *Front Cell Infect Microbiol* 3: 31.
- Tomanovic S, Chochlakis D, Radulovic Z, Milutinovic M, Cakić S, Mihaljica D, Tselentis Y, Psaroulaki A (2013) Analysis of pathogen co-occurrence in host-seeking adult hard ticks from Serbia. *Exp Appl Acarol* 59: 367-376.
- Vichová B, Majlathová V, Nováková M, Straka M, Pet'ko B (2010) First molecular detection of *Anaplasma phagocytophilum* in European brown bear (*Ursus arctos*). *Vector Borne Zoonotic Dis* 10: 543-545.
- Wannduragala L, Ristic M. Anaplasmosis. In: *Rickettsial and Chlamydial Diseases of Domestic Animals*. Ed. Z. Woldehiwet and M. Ristic. Pergamon Press, Oxford, UK 1993, pp. 65-87.
- Ybanez AP, Ybanez RHD, Cruz-Flores MJ, Xuenan X, Yokoyama N, Inokuma H (2014) High genetic diversity of *Anaplasma marginale* detected from Philippine cattle. *J Vet Med Sci* 76: 1009-1014.
- Yousefi A, Rahbari S, Shayan P, Sadeghi-dehkordi Z, Bahonar AF (2017) Molecular evidence of *Anaplasma phagocytophilum*: an emerging tick-borne pathogen in domesticated small ruminant of Iran; first report. *Com Clin Pathol* 26: 637-642.
- Zhang L, Liu Y, Ni D, Li Q, Liang G, Jiang X, Jing H, Run J, Luan M, Fu X, Zhang J, Yang W, Wang Y, Dumler JS, Feng Z, Ren J, Xu J (2008) Nosocomial transmission of human granulocytic anaplasmosis in China. *JAMA* 300: 2263-2270.

First occurrences of *Nerocila bivittata* on Dusky Grouper (*Ephinephelus marginatus*) and Mottled Grouper (*Mycteroperca rubra*)

S. Y. Çelik¹, J. Korun^{1*}, M. Gökoğlu²

¹Akdeniz University, Faculty of Fisheries, Aquaculture Division, Department of Fish Diseases, Antalya, Turkey, 07058

²Akdeniz University, Faculty of Fisheries, Aquaculture Division, Department of Aquaculture, Antalya, Turkey, 07058

ABSTRACT: The parasitic Isopod *Nerocila bivittata* was collected from caudal fins and body surface of dusky grouper (*Ephinephelus marginatus*) and mottled grouper (*Mycteroperca rubra*) captured by commercial trawl vessels as non-target species from Antalya Bay which is located in the eastern Mediterranean coast of Turkey. The parasites caused typically hemorrhages on caudal fins of both hosts. The parasitic isopod was identified as *Nerocila bivittata* which has not been reported from groupers in the worldwide. The study represents new hosts and geographical records.

Keywords: *Nerocila bivittata*, Isopoda, *Ephinephelus marginatus*, *Mycteroperca rubra*

Corresponding Author:

J. Korun, Akdeniz University, Faculty of Fisheries, Aquaculture Division, Department of Fish Diseases, Antalya, Turkey
E-mail address: jalekorun@akdeniz.edu.tr

Date of initial submission: 27-09-2020

Date of revised submission:

Date of acceptance: 20-02-2020

INTRODUCTION

The dusky grouper (*Epinephelus marginatus*) and mottled grouper (*Mycteroperca rubra*) which is the most important littoral fish species (Maggio et al., 2006) are greatly distributed worldwide from the eastern Atlantic Ocean to the Mediterranean Sea (Bouchereau et al., 1999). Groupers, members of the genus *Epinephelus*, are mostly tropical fish species. Distributions of them in subtropical and temperate waters are limited (Dulcic et al., 2006). *E. marginatus* is one of the seven species of groupers which were recorded in the Mediterranean Sea (Harmelin and Vivien-Harmelin, 1999). The mottled grouper, *M. rubra* prefers the shallow rocky habitats and occurs at depths less than 40 metres in the eastern Mediterranean Sea (Aranov and Goren, 2008). The members of Epinephelinae subfamily are more popular than the other fish species in the world-wide due to their commercial importance (Genç et al., 2005). Also, groupers play an important role in the ecological stability of marine ecosystems (La Mesa et al., 2006). For these reasons, many researches carried out studies on ecology (Hackradt, 2012), distribution (Mahé et al., 2012), growth (Bouchereau et al., 1999) reproduction (Andrade et al., 2003, Glamuzina et al., 1998), genetic (Maggio et al., 2006), larval evolution (Cunha et al., 2009), breeding (Marino et al., 2001) and diseases included bacterial, viral and parasitic infections (Eissa et al., 2011; Moravec and Justine, 2008; Katharios et al., 2004) of them.

Parasitic diseases are among the major problems in the aquaculture and hunting of food fish species. About 25% of parasitic agents include crustaceans such as copepod, brachiura and isopod species. The Isopoda are the second largest order and contain terrestrial and aquatic species (Kirkim et al., 2008). Marine species of this order are divided into 12 suborders which include Cymothoidae and this suborder possess Cymothoidae family presented by 43 genera and 358 species (Worms, 2018). *Nerocila bivittata* is a parasite species belong to the family Cymothoidae. It shows a wide distribution including the British waters, French coasts, Black Sea, Marmara and Aegean Seas (Fig. 1: Kayış and Er, 2012; Akmirza 2014; Kirkim et al., 2008). Although *N. bivittata* acts specifically in choice of host and has been usually reported on the members of the family Labridae, e.g. *Symphodus mediterraneus*, *S. tinca*, *S. melops* (Bariche and Trilles, 2005), there are many reports about different host species such as *Boops boops*, *Gobius geniporus*, *Mugil cephalus*, *Sciaena umbra*, *Labrus merula* for *N. bivittata* (Trilles 1994; Charfi-Cheikhrouha et al, 2000; Oğuz and Öktener 2007;

Kirkim et al, 2008; Akmirza 2014).

The main objective of the present study was to inform as new hosts dusky grouper, *Epinephelus marginatus* (Lowe, 1834) and mottled grouper, *Mycteroperca rubra* (Bloch, 1793) for *Nerocila bivittata*. This is also the first record of *N. bivittata* from the Gulf of Antalya, coastal waters of Mediterranean Sea in Turkey.

MATERIALS AND METHODS

Nerocila bivittata was found on dusky grouper (*Epinephelus marginatus*) and mottled grouper (*Mycteroperca rubra*) in the Mediterranean Sea coastal waters of Turkey. These fish species were captured by commercial trawl vessels as non-target, from Antalya Bay, which is located in the eastern Mediterranean coast of Turkey, on November 2014. The capture depth and coordinate of the specimens was 70 meters and 36° 46' 515'' N, 031° 12' 660'' E and 36° 46' 783'' N, 031° 08' 850'' E, respectively (Fig. 1). The parasites were removed from the body and fin surfaces of hosts and immediately preserved in 70% ethanol until brought to our faculty research laboratory. Subsequently, the fixed parasites were examined under a stereomicroscope. The total lengths of the isopods were measured and recorded in millimeters. Morphological characteristics of the parasites and these characters were used for the descriptions of the parasites (Risso, 1816; Brusca, 1978; Brusca, 1981).

RESULTS

A hemorrhagic lesion on caudal fin rays of *E. marginatus* where *Nerocila bivittata* was attached was observed (Fig.2). But, another external clinical finding except this lesion was not detected. The parasite was also detected on the caudal fin and body surface of *Mycteroperca rubra* (Fig. 3).

N. bivittata has dark brown body colour and there are two white strips along the dorsal part of body. The body is oval-shaped, the shell is cambered and bright. The head of the *N. bivittata* is small, rounded and flattened. There are seven large sections in the body followed by five smaller segments. The first three of its external antennas are swollen. Tail of the parasite is wide and almost square in shape. Extremities of *N. bivittata* are lanceolate and have small points at the ends. Uropod is twice the length of the endopod. Distal margin of endopod deeply intended. Totally, 3 parasites were detected on fishes and the average body length and width of them were measured as 17.2 mm and 8.3 mm, respectively. The species was identified as *Nerocila bivittata*.

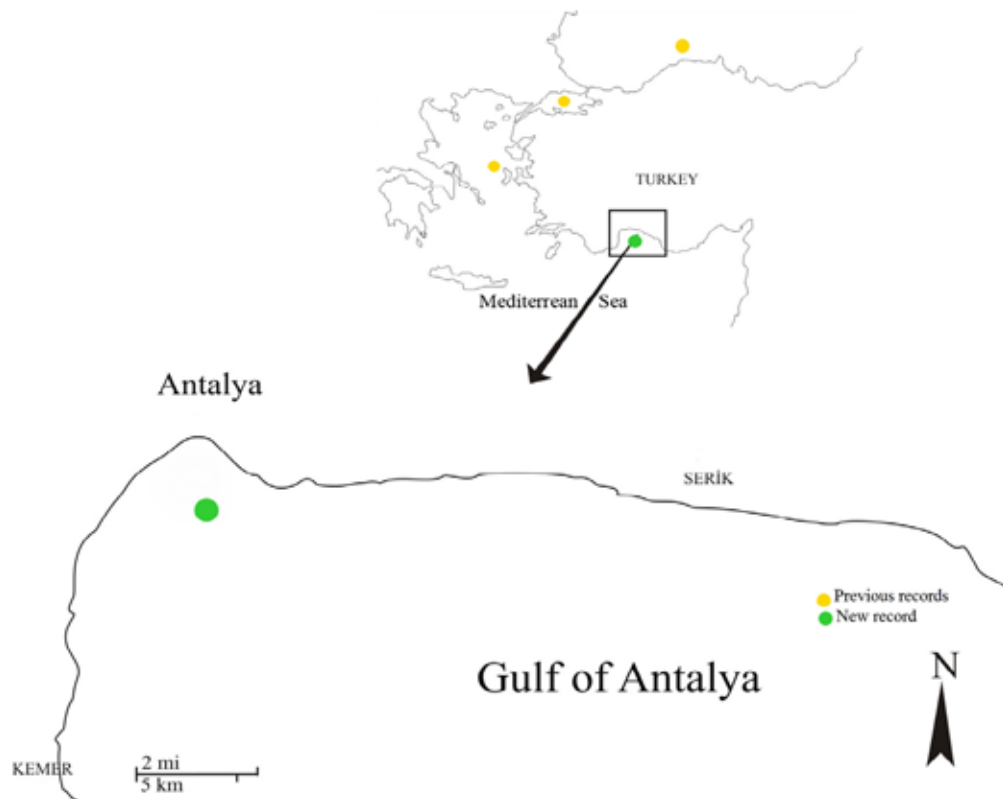


Figure 1. The map showing the previously records (yellow dots; Kayış and Er 2012; Akmirza 2014; Kirkim et al 2008) and new record (green dot) for *Nerocila bivittata* in Turkey.



Figure 2. *Nerocila bivittata* on the caudal fin of *Ephinephelus marginatus* and hemorrhagic lesion.



Figure 3. *Nerocila bivittata* on caudal fin and body surface of *Mycteroperca rubra*.

DISCUSSION

The Order Isopoda are widely distributed in all habitat types including terrestrial, marine, fresh and ground water. Some species are known as parasites and infested to the marine, freshwater and brackish water fish species (Bariche and Trilles, 2005). Parasitic isopods as crustacean ectoparasites are the most commonly reported group in marine fish species (Kabata, 1984). They are attached on the body surface, the fins, in the gill chambers, buccal cavity and nostrils or they make a pouch in the muscle of many wild tropical and cultured fish having economic value (Williams and Williams, 1994; Brusca, 1981). Isopods are haematophagous species and produce an anticoagulant substance from their latero-oesophagus glands (Bariche and Trilles, 2005). They feed on their host's blood and haemolymph and cause lesions on the body surfaces of their hosts so these parasites bring about a decrease in the economic value of the fish (Printrakoon and Purivirojkul, 2011).

N. bivittata has been described in 1816 for the first time by Risso (Risso, 1816). In 1818, the parasite was considered as a new species and described it as *Nerocila blainvillii* and Risso reported that *N. blainvillii* as the single species found in the genus. The author's specimen has been preserved in the British Museum (BMNH 1979: 400:2) but has never been fully described. Subsequently, this material as *Nerocila bivittata* was identified and recorded as conspecific with *N. blainvillii* (Trilles, 1975).

N. bivittata was generally reported from the Mediterranean countries such as Greece, Egypt, Lebanon, Libya and Algerian (Trilles 1994; Ramdane et al. 2007; Shakman et al 2009; Kolygas M 2014; Elgendy et al., 2018). This parasitic species has been isolated from many fish species such as *Siganus luridus*, *Mullus surmuletus*, *Mugil cephalus*, *Serranus scriba*, *Pagellus erythrinus*, *Meluccius merluccius*, *Belone belone*, *Uranoscopus scraber*, *Dentex macrophthalmus* from the Black, Marmara and Aegean Seas in Turkey (Oktener and Trilles, 2004; Kirkim et al., 2008; Oguz and Oktener, 2007; Alas et al. 2008; Oktener et al., 2010; Er and Kayis, 2015).

CONCLUSION

As results of the present study, the parasitic isopod *Nerocila bivittata* (Crustacea, Isopoda, Cymothoidae) on dusky grouper (*Ephinephelus marginatus*) and mottled grouper (*Mycteroperca rubra*) is the first record in the worldwide and also the first notification of *Nerocila bivittata* from the coastal waters of Mediterranean Sea, Gulf of Antalya in Turkey.

CONCLUSION

CONFLICT OF INTEREST

None declared by the authors.

REFERENCES

- Alas A, Oktener A, Iscimen A, Triller JP (2008) New host record, *Parablennius sanguinolentus* (Teleostei, Perciformes, Blenniidae) for *Nerocila bivittata* (Crustacea, Isopoda, Cymothoidae). *Parasitol Res* 102(4):645-646.
- Akmirza A (2014) Metazoan parasites of brown meagre (*Sciaena umbra* L. 1758) caught near Gökçeada, Turkey. *Turk J Vet Anim Sci* 38:299-303.
- Andrade AB, Machado LF, Hostim-Silva M, Barreiros JP (2003) Reproductive biology of the dusky grouper *Epinephelus marginatus* (Lowe, 1834). *Braz Arch Biol Technol* 46(3):373-382
- Aronov A., Goren M. 2008. Ecology of mottled grouper (*Mycteroperca rubra*) in the eastern Mediterranean. *Electronic Journal of Ichthyology* 2: 43–55
- Bariche M, Trilles JP (2005) Preliminary check-list of Cymothoids (Crustacea: Isopoda) parasitic on marine fishes from Lebanon. *Zool Middle East* 34:53-60.
- Bouchereau JL, Body P, Chauvet C (1999) Growth of the dusky grouper *Epinephelus marginatus* (Linnaeus, 1758) (Teleostei, Serranidae) in the Marine Natural Reserve of Lavezzi Islands, Corsica, France. *Sci mar* 63(1):71-77.
- Brusca R.C., 1978. Studies on the cymothoid fish symbionts of the eastern Pacific (Isopoda, Cymothoide). I. Biology of *Nerocila californica*. *Crustaceana* 34: 141–154.
- Brusca RC (1981) A monograph of the Isopoda Cymothoidae (Crustacea) of the eastern Pacific. *Zool J Linnean Soc* 73:117-119.
- Charfi-Cheikrouha F, Zghidi W, Ould Yada L, Trilles JP (2000) Les Cymothoidae (Isopodes parasites de poissons) des côtes tunisiennes: ecologie et indices parasitologiques. *Syst Parasitol* 46:146–150.
- Cunha ME, Quental H, Barradas A, Pousao-Ferreira P, Cabrita E, Engrola S (2009) Rearing larvae of dusky grouper, *Epinephelus marginatus* (Lowe, 1834), (Pisces: Serranidae) in a semi-extensive mesocosm. *Sci Mar* 73(1):201–212
- Dulcic J, Tutman P, Caleta M (2006) Northernmost occurrence of the white grouper, *Epinephelus aeneus* (Perciformes: Serranidae), in the Mediterranean area. *Acta Ichthyol Piscat* 36(1):73–75
- Eissa A, Zaki EMM, Saied S (2011) Epidemic mortalities in the dusky grouper, *Epinephelus marginatus* (Lowe, 1834) in Egyptian coastal waters. In *Proceedings of the 4th Global Fisheries and Aquaculture Research Conference, the Egyptian International Center for Agriculture, Giza, Egypt* pp 3–5
- Elgendy MY, Hassan AM, Abdel Zaher MF, Abbas HH, Soliman WS, Bayoumy EM (2018) *Nerocila bivittata* Massive Infestations in *Tilapia zillii* with Emphasis on Hematological and Histopathological Changes. *AJSR* 11(1):134–144
- Er A, Kayış S (2015) Intensity and prevalence of some crustacean fish parasites in Turkey and their molecular identification. *Turk J Zool* 39:1142–1150
- Genc E, Genc MA, Can MF, Genc E, Cengizler I (2005) A first documented record of gnathiid infestation on white grouper (*Epinephelus aeneus*) in Iskenderun Bay (north-eastern Mediterranean), Turkey. *J Appl Ichthyol* 21:448–450.
- Glamuzina B, Skaramuca B, Glavic N et al (1998) Egg and early larval development of laboratory reared dusky grouper, *Epinephelus marginatus* (Lowe, 1834) (Pisces, Serranidae). *Sci Mar* 62:373–378
- Hackradt FCF (2012) Ecology of Mediterranean reef fish early life history stages, population connectivity and implications for marine protected areas design. *Universidad de Murcia Facultad de Biología Departamento de Ecología e Hidrología, Doctoral Thesis, Murcia* pp 238
- Harmelin, J.G. and Harmelin-Vivien, M. 1999. A review on habitat, diet and growth of the dusky grouper *Epinephelus marginatus* (Lowe, 1834). *Marine Life* 9(2): 11-20
- Kayış Ş, Er A (2012) *Nerocila bivittata* (Cymothidae, Isopoda) infestation on Syngnathid Fishes in the Eastern Black Sea. *Bull Eur Ass Fish Pathol* 32(4)
- Kabata Z (1984) Diseases caused by metazoans: crustaceans. In: Kinne O, editor. *Diseases of marine animals*. Hamburg, Germany: Biologische Anstalt Helgoland pp 321-399
- Katharios P, Papadakis IE, Prapas A, Dermon CR, Ampatzis K, Divanach P (2004) Mortality control of VNN disease in grouper, *Epinephelus marginatus* after prolonged bath in dense *Chlorella minutissima* culture. *European Aquaculture Society, Biotechnologies for Quality* 20-23 October Barcelona, Spain
- Kırkım F, Kocataş A, Katagan T, Sezgin M (2008) A Report on Parasitic Isopods (Crustacea) from Marine Fishes and Decapods Collected from The Aegean Sea (Turkey). *Turk J Parasitol* 32(4):382–385
- Kolygas M (2014) Implementation of Innovative and Efficacious Treatments Against Ectoparasites of Intensive Cultured Mediterranean Fish, phd Thesis, University of Thessaly, School of Health Sciences, Faculty of Veterinary Medicine, Greece.
- La Mesa, G., Di Muccio, S. and Vacchi, M. 2006. Abundance, size distribution and habitat preferences in the grouper assemblage of the Ustica marine reserve (SW Mediterranean). *Cybium* 30(4): 365-377.
- Maggio A, Zhu J-K, Hasegawa PM, Bressan RA (2006) Osmogenetics: Aristotle to *Arabidopsis*. *Plant Cell* 18:1542–1557
- Marino G, Azzuro E, Massari A, Finoia MG, Mandich A (2001) Reproduction in the dusky grouper from the southern Mediterranean. *J Fish Biol* 58: 909–927
- Mahé K, Cochard ML, Quéro JC, Sevin K, Bailly N, Tetard A (2012) First record of *Epinephelus marginatus* (Serranidae: Epinephelinae) in the eastern English Channel Premier signalement de *Epinephelus marginatus* (Serranidae: Epinephelinae) en Manche orientale. *Ichthyological notes – Notes ichthyologiques* 36(3):485–486
- Moravec F, Justine JL (2008) Some philometrid nematodes (Philometridae), including four new species of Philometra, from marine fishes off New Caledonia. *Acta parasitol* 53(4): 369-381
- Oguz MC, Ökten A (2007) Four Parasitic Crustacean Species From Marine Fishes of Turkey. *Turkish Journal of Parasitology* 31(1):79–83
- Okten A, Trilles J.P., (2004) Report on the Cymothoids (Crustacea, Isopoda) collected from marine fishes in Turkey. *Acta Adriat* 45 (2):15–23
- Okten A, Torcu-Koc H, Erdogan Z, Paul-Trilles J., 2010. Scuba diving photography: a useful method for taxonomic and ecologic studies on fish parasites (cymothoidae). *Journal of Marine Animals and Their Ecology*, 3(2).
- Printrakoon C, Purivirojkul W (2011) Prevalence of *Nerocila depressa* (Isopoda, Cymothoidae) on *Sardinella albella* from a Thai estuary. *J Sea Res* 65:322–326
- Ramdane Z, Bensouilah MA, Trilles J.P., 2007. The Cymothoidae (Crus-

- tacea, Isopoda), parasites on marine fishes, from Algerian fauna. Belg J Zool 137(1):67–74
- Risso A (1816) Histoire Naturelle des Crustacés des Environs de Nice. *Librairie Grecque-Latine-Allemande, Paris*. Pp 175
- Shakman E, Kinzelbach R, Trilles JP, Bariche M (2009) First occurrence of native cymothoids parasites on introduced rabbitfishes in the Mediterranean Sea. Acta Parasitol 54(4):380–384
- Trillies J.P. 1975. Les Cymothoidae (Isopoda, Flabellifera) des cotes francaises. H. Les Anilocridae Schiodte et Meinert, 1881. Genres *Anilocra* Leach, 1818, et *Nerocila* Leach, 1818. Bulletin du Museum National d'Histoire Naturelle, Paris 3e serie, 290, Zoologie 200: 347-378, pI. 1
- Trilles JP (1994) Les Cymothoidae (Crustacea, Isopoda) du Monde (Prodrome pour une Faune). Stud Mar 21/22(1–2):1–288
- Williams LB, Williams EH (1994) Parasites of Puerto Rican Freshwater Sport Fishes, Sportfish Disease Project, Department of Marine Sciences, University of Puerto Rico, pp168
- WoRMS, 2018, <http://www.marinespecies.org>, [accessed 4 September 2019].

Effect of N-acetyl cysteine on the quality of blastocyst formation rate using cultured vitrified murine embryos

S. Sigüenza, I.S. Álvarez, E. Matilla*

Department of Cellular Biology, School of Life Sciences, University of Extremadura, Badajoz, Spain

ABSTRACT: Vitrification is the best method for embryo cryopreservation although it increases endogenous reactive oxygen species (ROS) production. N-acetylcysteine (NAC) a free radical scavenger may be used for reducing ROS toxic effects. The aim of the present study is to investigate potential beneficial effects of NAC on the developmental embryo competence applying different culture conditions in vitrified-warmed 2-cell embryos derived *in vivo* or *in vitro*. Thus, 2-cell embryos were vitrified or cultured fresh in presence or absence of 1 mM of NAC during: a) the entire embryo culture, b) for 24 hours with NAC at days 1.5 (G1) or 2.5 (G2) and returned to basal embryo culture (KSOM) or c) cultured in the presence of NAC for 12 hours at day 3.5 (G3). Despite NAC addition to fresh or vitrified embryos produced *in vivo* or by IVF, blastocyst rates remained unchanged. In vitrified-warmed IU or IVF-derived embryos, total cell number varied when NAC was added at day 1.5 although differences were not significant (60.1 ± 1.9 vs. 59.4 ± 1.3 for IU G1 and control respectively; and 59.3 ± 1.6 and 52.6 ± 3.0 IVF G1 and control respectively; mean cell number \pm SEM, $p > 0.05$). It seems that the embryo culture medium supplementation with 1 mM of NAC in the first day after vitrification of development improves blastocyst quality of murine embryos and does not exert any beneficial effect at other culture points.

Keywords: N-acetylcysteine, vitrification, early embryos, mouse, blastocyst quality.

Corresponding Author:

Elvira Matilla, Department of Cellular Biology, School of Life Sciences, University of Extremadura, Av. Universidad S/N, Badajoz 06006, Spain
E-mail address: ematillap@gmail.com

Date of initial submission: 24-10-2019
Date of revised submission: 13-04-2020
Date of acceptance: 05-05-2020

INTRODUCTION

Embryo cryopreservation is an assisted reproductive technology that has been extensively used in conservation programs (Somoskoi et al. 2015; Mandawala et al. 2016). Vitrification is the safest and most rapid method for embryo cryopreservation as it avoids the formation of intracellular and extracellular ice crystals (Rall W.F. 1985; Vajta 2000). This method consists in the solidification of the cell components at low temperatures reaching an amorphous-ice state by combining: a) extremely rapid cooling rates (over 1000°C/min) and b) high concentrations of permeable cryoprotectants (typically ethylene glycol or EG and dimethyl sulfoxide or DMSO) and an non-permeable cryoprotectants agents (a carbohydrate) (Rall 1987). This method expedites the freezing process reducing the exposure to the toxic effect of the cryoprotectants (Tsang W.H. and Chow L.K. 2009) although embryo survival and the subsequent development is lower than when compared to fresh embryos (Kuleshova and Lopata 2002; Azadbakht and Valojerdi 2008). It has been previously shown that cryopreservation causes alterations in the embryos by affecting the integrity of the cell membrane and cytoskeleton, inducing mitochondrial depolarization and increasing the production of reactive oxygen species (ROS) (Yan et al. 2010; Liang et al. 2012). Among these insults, oxidative stress derived from mitochondrial damage is known to trigger the apoptotic cascade leading to a decrease in the survival rate and developmental competence of embryos after thawing (Somfai et al. 2007; Tatone et al. 2010). Additionally, *in vitro* culture of mammalian embryos further enhances free radical production overwhelming the embryos' endogenous antioxidant capacity (Ali et al. 2002), being especially notable in vitrified embryos. For this reason antioxidant addition to the embryo culture medium has been tried and has shown to improve gamete quality and embryo development (Silva et al. 2015). N-acetylcysteine (NAC) is a potent free radical scavenger that can be considered as a supplement to alleviate glutathione (GSH) depletion and free radical formation during oxidative stress in mice (Silva et al. 2015). GSH is one of the major non-enzymatic antioxidants present in oocytes and embryos and is essential for their protection against oxidative stress (Marí et al. 2009). Based on a recently published work that described that addition of NAC to murine oocytes after vitrification improves the mitochondrial status of the oocytes and the quality of the blastocyst obtained by IVF (Matilla et al. 2019), in the present work the effect of NAC at

1 mM in vitrified-warmed 2 cell embryos produced *in vivo* and *in vitro*, was assessed. This embryonic stage was chosen because it is known that two-cell embryos are more sensitive to vitrification than other stages. To do this, two cells embryos are more sensitive to vitrification than other stages (Ghandy, N., Karimpur, M., Abbas, A. 2017). Also, we want check the effect of NAC addition during a long time of culture. Two-cell embryos were recovered *in vivo* or after *in vitro* fertilization (IVF), vitrified and incubated for 24 hours with 1 mM of NAC during different time points (day 1.5, day 2.5 or day 3.5) or during the entire culture to the expanded blastocyst stage. The percentage of embryos reaching the expanded blastocyst stage as well as the total cell number was assessed using a stereomicroscope.

MATERIAL AND METHODS

Reagents

Unless otherwise stated, all the reagents were purchased from Sigma-Aldrich (Barcelona, Spain).

Animals and superovulation protocol

All the experimental procedures were reviewed and approved by the Ethical Committee of the Junta de Extremadura (Spain; Ref. Exp-20190103-2). B6D2F1/OlaHsd mice were housed in the Animal housing of University of Extremadura under a 12 h light/12 h dark cycles at a controlled temperature (19-23°C) with free access to food and water. Females between 20-25 gr. of weight were intraperitoneally (IP) injected with 8 international units of equine chorionic gonadotropin (eCG, Veterin Corion, Divasa Farmavic) followed 47 h later by 8 international units of IP human chorionic gonadotropin (hCG, Foligon, MSD) to trigger ovulation.

In Vitro Fertilization

Male B6D2F1/OlaHsd mice aged 7-10 weeks and weight around 30 gr. were euthanized by cervical dislocation and ventrally dissected to remove the cauda epididymis. Once located, the epididymis and attached *vas deferens* were sectioned and transferred to a Petri dish containing 500 µl of pre-equilibrated human tubal fluid (HTF; at 37°C in a 5% CO₂/ 95% air atmosphere at 100% humidity) covered with mineral oil. Sperm were obtained by gently pressing the cauda epididymis through the *vas deferens* and were allowed to capacitate for 45 minutes at 37°C in a 5% CO₂/ 95% air atmosphere at 100% humidity. At the end of the incubation, sperm concentration was mea-

sured using a Makler chamber (Sefi-Medical instruments LTD, CA, USA). Cumulus-oocyte complexes (COCs) were recovered from oviducts following female euthanasia and placed in a Petri dish containing 500 µl of pre-equilibrated HTF covered with mineral oil; COCs were inseminated using 1.5×10^6 sperm/ml and were co-incubated for 6 hours and then transferred to equilibrated potassium-supplemented simplex optimization medium (KSOM). The day at which IVF was performed was considered as day 0. The next morning, cleaved embryos in two cell stage were retrieved and allocated as described in the experimental design section.

***In vivo* embryo recovery**

Female mice were hormonally stimulated to trigger ovulation as previously described; after hCG injection, females were paired with B6D2 males in a 1:1 ratio. After 24 hours, females were sacrificed by cervical dislocation and the embryos were collected from the oviducts; these 2-cell embryos were allocated into an experimental group (see the experimental design section).

Vitrification and warming

In vivo and *in vitro* produced two cell embryos were equilibrated in M2 medium added with 7.5% of DMSO (v/v), 7.5% ethylene glycol (v/v) and 20% (v/v) fetal bovine serum (FBS) for 3 min. Afterwards, the embryos were transferred to a vitrification solution consisting of M2 supplemented with 20% FBS added with 15% ethylene glycol (v/v), 15% DMSO (v/v) and 0.5 M sucrose for 1 minute. An average of 15 embryos were loaded in 0.25 ml French straws (IMV, L'Aigle, France) at room temperature and sealed by ultrasounds (Superultrasonic Co, Taiwan). After that, the straws were plunged into liquid nitrogen and stored for at least 7 days. Embryos were warmed at 37°C for 3-4 minutes in M2 medium added with 0.5 M sucrose and 20% FBS (v/v) and washed in M2 medium drops for further 3 minutes.

Experimental design

Fresh or vitrified-warmed *in vivo* and *in vitro* produced two cell embryos (1.5 days of development) were separately allocated to one of the following experimental groups:

Control: embryos were cultured in KSOM to the blastocyst stage; G1: embryos were cultured for 24 hours in KSOM supplemented with 1 mM NAC (day 1.5 to 2.5), after this incubation embryos were trans-

ferred to KSOM until day 4; G2: embryos were cultured in KSOM, transferred for 24 hours to KSOM supplemented with 1 mM NAC (day 2.5 to 3.5), and returned to KSOM until day 4; G3: embryos were cultured in KSOM for 12 hours supplemented with 1 mM NAC (day 3.5 to 4); C-NAC: embryos were cultured in KSOM supplemented with 1 mM NAC to the blastocyst stage. The number of embryos reaching the blastocyst stage was recorded visually by a stereomicroscope. All the embryos were moved to a new droplet of medium each day in presence or absence of NAC depending on the treatment group (Figure 1).

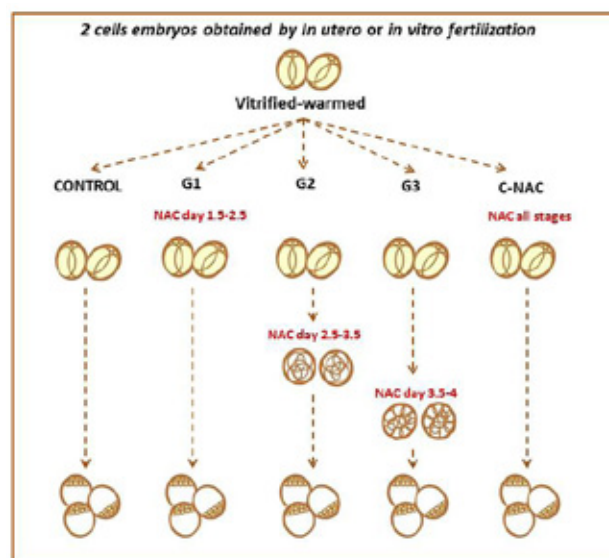


Figure 1. Two cell experimental design

Development to the blastocyst stage

To assess the development to the blastocyst stage, the embryos were followed *in vitro* for 3 days. The dish containing the embryos was placed under a stereomicroscope with a pre-heated stage (37°C). The embryos showing a completely formed inner cell mass and expanded blastocoele were assumed to have reached the blastocyst stage.

Total cell number

The number of cells in an embryo is the most critical indicator of embryo quality (ESHRE 2011). Therefore, in view of the previous data, expanded blastocysts were fixed in 4% formaldehyde in PBS added with 0.01% of polyvinyl alcohol (PVA; w/v) at 4°C for 12 hours and stained with 2.5 µg/ml of Hoechst 33342 (Eugene, OR, USA) in PBS added with PVA for 10 minutes at 37°C. Then, the blastocysts were mounted on glass slides with glycerol, covered with coverslips and sealed using nail polish. The embryos

were then visualized using a fluorescence microscope (Nikon Elipse TE2000-S) equipped with an ultraviolet lamp. Cell number was analyzed using the Fiji Image-J Software (1.45q, Wayne Rasband, NIH, USA).

Statistical analysis

Data were tested for normality using a Shapiro–Wilk test; the results are reported as mean \pm standard error of the mean (SEM). Treatment groups were compared using ANOVA on ranks due to their non-Gaussian distribution. Between groups, all pair wise comparisons were made using a Holm–Sidak post-hoc test. All statistical analyses were performed using Sigma Plot software version 12.3 for Windows (Systat Software, Chicago, IL, USA). Differences among values were considered as statistically significant when $p < 0.05$.

RESULTS

Embryo development

Differences were found between treatments in the development to the blastocyst stage but were not significant ($p > 0.05$; Table 1). Homologous treatments *in vivo* and *in vitro* were compared in a second evaluation (control, G1, G2, G3 or C-NAC) but statistically significant differences were not found ($p > 0.05$).

Total cell number determination

Significant differences were found between Control group (74.2 ± 2.3 ; mean cell number \pm SEM) compared with G2 (63.2 ± 2.7) and G3 (61.3 ± 3.2) in fresh *in utero* retrieved embryos ($p < 0.05$; Table 2). Significant differences were found comparing G1 group (74.1 ± 1.8) vs G2 (63.2 ± 2.7) and G3 (61.3 ± 3.2) in fresh *in utero* retrieved embryos ($p < 0.05$; Table 2).

Despite NAC addition in fresh IVF group significant differences were not found ($p > 0.05$; Table 2).

When *in utero*-derived embryos were vitrified and warmed significant differences were obtained in presence of 1mM of NAC (G2 and G3) compared to the control group (59.4 ± 1.3 ; mean cell number \pm SEM vs. 45.7 ± 2.2 and 46.8 ± 2.2 respectively; $p < 0.05$; Table 2

2). Also, significant differences were found in embryos supplemented with 1 mM NAC in 1.5 day group compared to days 2.5 and 3.5 (60.1 ± 1.9 mean cell number \pm SEM; vs. 45.7 ± 2.2 and 46.8 ± 2.2 respectively; $p < 0.05$; Table 2). Embryos cultured in

presence of NAC during all stages showed significant differences between NAC added in 2.5 day (55.6 ± 3.0 vs. 45.7 ± 2.2 ; $p < 0.05$; Table 2).

Conversely, when IVF derived embryos were vitrified and warmed, NAC addition at day 1.5 increased the blastomere number in G1 (59.3 ± 1.6 ; mean cell number \pm SEM) compared to day 2.5 and 3.5 of embryo development (59.3 ± 1.6 ; mean cell number \pm SEM, vs. 49.6 ± 2.6 and 46.5 ± 2.6 (G2 and G3 respectively); $p < 0.05$, Table 2 and Figure 2).

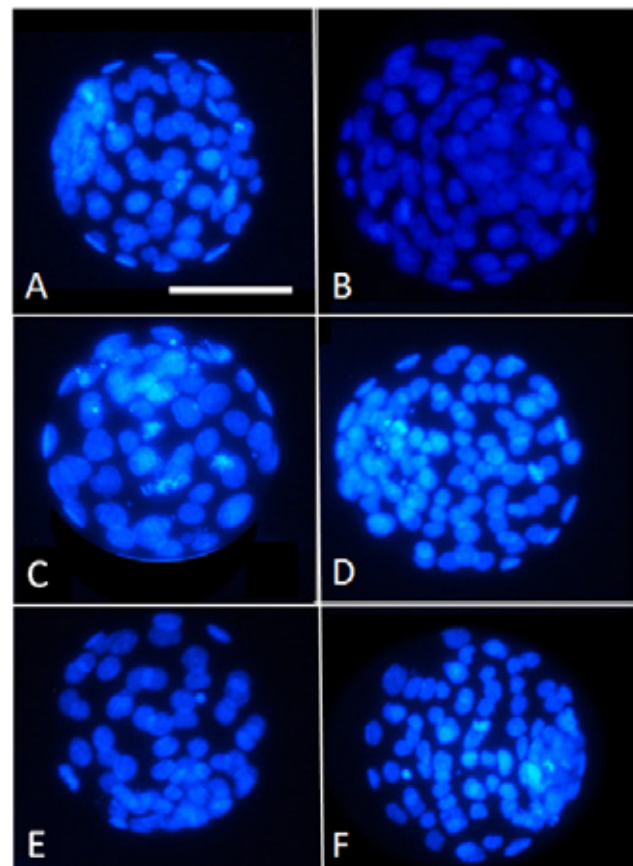


Figure 2. Blastocyst experimental design

In vivo or IVF-derived murine 2-cell embryos were obtained, vitrified and cultured to the blastocyst stage in the presence or absence of 1 mM NAC. Representative micrographs are shown of blastocysts derived from 2-cell embryos that were obtained after **A)** IVF (fresh); **B)** *In utero* harvesting (fresh); **C)** 2-cell embryos produced *in utero* followed by vitrification; **D)** produced *in utero* followed by vitrification, cultured in presence of 1 mM NAC for 24 hours (day 1.5) and allowed to develop; **E)** IVF derived 2-cell embryo subjected to vitrification and warming; **F)** IVF derived 2-cell embryo subjected to vitrification, cultured in presence of 1 mM NAC for 24 hours (day 1.5) and allowed to develop. White bar represents 100 μ m; the micrographs were taken using a 40x objective.

Table 1. Embryo development to the blastocyst stage

Embryo source	Treatment	n	Blastocyst rate
Fresh <i>In utero</i> (IU)	Control	40	92.0 ± 2.7
	NAC G1	40	92.9 ± 1.8
	NAC G2	40	93.0 ± 3.1
	NAC G3	40	89.0 ± 3.5
	C-NAC	40	93.6 ± 3.9
IU- vitrified embryos	Control	40	83.8 ± 4.1
	NAC G1	40	85.1 ± 3.2
	NAC G2	40	82.5 ± 4.2
	NAC G3	40	81.1 ± 2.6
	C-NAC	40	84.3 ± 3.3
Fresh IVF	Control	40	84.3 ± 1.6
	NAC G1	40	85.3 ± 1.0
	NAC G2	40	81.2 ± 3.5
	NAC G3	40	80.7 ± 4.3
	C-NAC	40	83.4 ± 3.3
IVF – Vitrified	Control	40	84.9 ± 3.2
	NAC G1	40	85.0 ± 1.6
	NAC G2	40	78.4 ± 4.2
	NAC G3	40	76.4 ± 4.1
	C-NAC	40	83.2 ± 4.5

Blastocyst rates of fresh and vitrified mouse embryos obtained by IVF or *in vivo* in presence or absence of NAC. The groups studied were: Control: embryos cultured in the absence of NAC; NAC G1: 1 mM NAC was added for 24 hours to the embryo culture medium at day 1.5 of embryo development; NAC G2: 1 mM NAC was added for 24 hours to the embryo culture medium at day 2.5 of embryo development; NAC G3: 1 mM NAC was added for 24 hours to the embryo culture medium at day 3.5 of embryo development; C-NAC: culture medium was supplemented with 1 mM of NAC during the entire embryo culture. Statistically significant differences were not found between treatments in the same group or between homologous treatments in the different groups studied. Values are expressed as the mean percentage ± SEM ($p > 0.05$).

Table 2. Cell number of murine blastocyst from two cells embryos.

Embryos	Treatment	n	Cell number
Fresh <i>in utero</i> (IU)	Control	20	74.2 ± 2.3 ^{a,b}
	NAC G1	20	74.1 ± 1.8 ^{c,d}
	NAC G2	20	63.2 ± 2.7 ^{a,c}
	NAC G3	20	61.3 ± 3.2 ^{b,d}
	C-NAC	20	71.2 ± 2.1
IU- vitrified embryos	Control	20	59.4 ± 1.3 ^{a,b}
	NAC G1	20	60.1 ± 1.9 ^{c,d}
	NAC G2	20	45.7 ± 2.2 ^{a,c,e}
	NAC G3	20	46.8 ± 2.2 ^{b,d}
	C-NAC	20	55.6 ± 3.0 ^e
Fresh IVF	Control	20	55.4 ± 1.2
	NAC G1	20	55.4 ± 1.5
	NAC G2	20	52.8 ± 2.3
	NAC G3	20	50.8 ± 2.7
	C-NAC	20	55.1 ± 1.8
IVF - Vitrified	Control	20	52.6 ± 3.0
	NAC G1	20	59.3 ± 1.6 ^{a,b}
	NAC G2	20	49.6 ± 2.6 ^a
	NAC G3	20	46.5 ± 2.6 ^b
	C-NAC	20	55.8 ± 1.4

Total cell number of vitrified mouse embryos obtained by IVF or *in vivo* in presence or absence of NAC. Control: embryos cultured in the absence of NAC; NAC G1: 1 mM NAC was added for 24 hours to the embryo culture medium at day 1.5 of embryo development; NAC G2: 1 mM NAC was added for 24 hours to the embryo culture medium at day 2.5 of embryo development; NAC G3: 1 mM NAC was added for 24 hours to the embryo culture medium at day 3.5 of embryo development; C-NAC: culture medium was supplemented with 1 mM of NAC during the entire embryo development. Values are expressed as the mean percentage ± SEM. Values bearing different letters in the same group differ statistically ($p < 0.05$).

DISCUSSION

Embryo vitrification is an important hallmark of the assisted reproductive technology industry. The murine model has been extensively used to test and develop vitrification protocols due to its high capacity to withstand the process. However, depending upon the developmental stage, their tolerance to vitrification notably varies (Ghandy, Nasibeh and Karimpur Malekshah 2017). For example, it has been described that vitrified 2-cell embryos exhibit a similar survival rate after warming compared to 4-cell, 8-cell, morulae and blastocysts, although their development to the blastocyst stage is significantly lower compared to vitrified-warmed embryos at the 8-cell stage (Zhang *et al.* 2009; Ghandy, N., Karimpur, M., Abbas, A. 2017; Ghandy, Nasibeh and Karimpur Malekshah 2017). This difference has been attributed to a lower cryoprotectant permeability of the zona pellucida at the earlier embryo stages and to increased ROS production after vitrification, being this stage the less suitable for cryopreservation (Pedro *et al.* 2005; Gao *et al.* 2012). Thus, in our setting, vitrified 2-cell embryos produced *in vivo* and *in vitro* were used to study the effect of NAC supplementation during the entire culture or at different time points. In our setting no statistically significant differences were observed in the developmental competence of the 2-cell embryos despite NAC addition, *in vitro* or *in vivo* embryo production and/or cryopreservation (Table 1; $p > 0.05$). However, it has to be mentioned the high development to the expanded blastocyst stage obtained after embryo vitrification in our setting (84.3 ± 1.6 and 84.9 ± 3.2 ; blastocyst rate for vitrified-warmed *in vivo* vs. IVF produced embryos respectively; Table 1). Previous works have reported up to 69.4% blastocyst rates after *in utero* retrieved 2-cell embryo vitrification using the Cryotop method (Zhang *et al.* 2009; Ghandy, N., Karimpur, M., Abbas, A. 2017; Ghandy, Nasibeh and Karimpur Malekshah 2017) or a 97.3% blastocyst rate when the embryos were produced by IVF and vitrified using the Kitasato System (Momozawa *et al.* 2017). Although the mouse strain used and the vitrification protocol (close in our setting vs. open in the mentioned reports) might influence the results obtained, our results suggest that *in vivo* and *in vitro* produced 2-cell embryos similarly withstand vitrification when a closed system is used.

As similar blastocyst rates were found among groups, we decided to compare the number of blastomeres/embryo between groups, as it has been shown to be a reliable indicator of embryonic quality (Mal-

lol *et al.* 2013; Kong *et al.* 2016). Coinciding with our findings it has been reported that the mean cell number in mouse blastocysts recovered from uterus is 74.5 ± 2.3 (Sawicki and Mystkowska 1990) and that total cell number significantly drops in IVF-derived embryos (Van der Elst J *et al.* 1998). The lower cell number of *in vitro*-derived embryos has been linked to a higher cell death compared to *in utero*-derived embryos (Jurisicova *et al.* 1998) and to an enhanced ROS production occurring during *in vitro* embryo production (Guérin *et al.* 2001).

However, despite NAC addition during the entire embryo culture, total cell number did not improve in fresh or vitrified embryos disregarding their source (*in vitro* or *in utero*; Table 2). Similar findings have been described in vitrified *in vitro*-derived porcine embryos in which addition of L-ascorbic acid to the embryo culture medium ameliorated ROS production but did not result in enhanced total cell number (Castillo-Martín *et al.* 2014).

The results by Castillo-Martín *et al.* (2014) and our own results suggest that, antioxidants added during the entire embryo culture can exert effective ROS scavenging that is not reflected by an enhanced total cell count in the resulting embryos. Interestingly, addition of 1 mM of NAC to the embryo culture at the different time points tested (day 1.5, 2.5, 3.5 or the entire embryo culture) to vitrified-warmed 2-cell embryos produced *in vitro* or *in vivo* exerted different effects. The total cell number in vitrified-warmed embryos (*in vitro* or *in vivo*) increased when NAC was added at days 1.5 compared to the control although differences were not significant (Table 2 and Figure 2). Conversely, in all groups total cell number significantly decreased at day 2.5 (G2) and 3.5 (G3) compared to control; also, we found significant differences between G1 (1.5 Day) and day 2.5 (G2) and 3.5 (G3) from fresh and vitrified *in utero* embryos and IVF vitrified and warmed embryos. Our results suggest that NAC addition exerts its maximum beneficial effect right after embryo warming (*in vitro* and *in vivo* produced embryos). It is known that physiological ROS production is required for correct embryo division and pre-implantation development (Covarrubias *et al.* 2008). Thus, our data suggest that after vitrification and warming the NAC scavenging properties might be ameliorating the increased ROS production triggered by the cryopreservation process. This effect was observed only when NAC was added during the first third of the embryo culture (*in vivo*

produced embryos), but in the second and last third of embryo development, the damages induced seem to be irreversible. This effect can be attributed to the addition of the antioxidant in the correct moment, as its addition in a non-ideal stage of development can be harmful (Guerin et al. 2001). The fact that continuous NAC addition did not result in an enhanced total cell number suggests that excessive ROS scavenging could be interfering with blastomere cytokinesis explaining why total cell number does not increase (Bedaiwy et al. 2004).

CONCLUSION

NAC addition enhances total cell number and embryo development of vitrified murine 2-cell embryos obtained *in vivo* or *in vitro* when added at day 1.5 of culture. For IVF- vitrified embryos significant differences were found depending upon the day of NAC supplementation. The vitrification process detrimentally affects *in vivo*-derived 2-cell embryos more viv-

idly than *in vitro* produced embryos, as the number of blastomeres is significantly lower after reaching the blastocyst stage. NAC supplementation during the entire culture to the blastocyst stage does not improve the quality of fresh 2-cell embryos and *in utero* vitrified-warmed embryos. NAC addition to 2.5 and 3.5 day has a toxic effect decreasing embryo quality of IU derived embryos ($p < 0.05$). More studies are necessary to clarify the optimal concentrations of NAC that improve the quality of vitrified murine embryos during early embryo development.

ACKNOWLEDGEMENTS

The authors wish to thank their accessibility to the rest of member of the Department of Biochemistry and Molecular Biology from the School of Life Sciences, University of Extremadura, Badajoz, Spain.

CONFLICT OF INTEREST

None declared by the authors.

REFERENCES

- Ali, A.A., J.F. Bilodeau and M.A. Sirard (2002). "Antioxidant requirements for bovine oocytes varies during *in vitro* maturation, fertilization and development." *Theriogenology* 59(3): 939-949.
- Azadbakht, M. and M.R. Valojerdi (2008). "Development of vitrified-warmed mouse embryos co-cultured with polarized or non-polarized uterine epithelial cells using sequential culture media." *Journal of Assisted Reproduction and Genetics* 25(6): 251-261.
- Bedaiwy, M.A., T. Falcone, M.S. Mohamed, A.A.N. Aleem, R.K. Sharma, S.E. Worley, J. Thornton and A. Agarwal (2004). "Differential growth of human embryos *in vitro*: Role of reactive oxygen species." *Fertility and Sterility* 82(3): 593-600.
- Castillo-Martin, M., S. Bonet, R. Morató and M. Yeste (2014). "Comparative effects of adding β -mercaptoethanol or α -ascorbic acid to culture or vitrification-warming media on IVF porcine embryos." *Reproduction, Fertility and Development* 26(6): 875-882.
- Covarrubias, L., D. Hernández-García, D. Schnabel, E. Salas-Vidal and S. Castro-Obregón (2008). "Function of reactive oxygen species during animal development: Passive or active?" *Developmental Biology* 320(1): 1-11.
- ESHRE (2011). *The Istanbul consensus workshop on embryo assessment: proceedings of an expert meeting*. Human Reproduction.
- Gao, C., H.-B. Han, X.-Z. Tian, D.-X. Tan, L. Wang, G.-B. Zhou, S.-E. Zhu and G.-S. Liu (2012). "Melatonin promotes embryonic development and reduces reactive oxygen species in vitrified mouse 2-cell embryos." *J Pineal Res* 52(3): 305-311.
- Ghandy, N. and A.A. Karimpur Malekshah (2017). "Which Stage of Mouse Embryos Is More Appropriate for Vitrification?" *International Journal of Fertility & Sterility* 10(4): 357-362.
- Ghandy, N., Karimpur, M., Abbas, A. (2017). "Which Stage of Mouse Embryos Is More Appropriate for Vitrification?" *International Journal of Fertility & Sterility* 10(4): 357-362.
- Guerin, P., S. El Moutassim and Y. Menezo (2001). "Oxidative stress and protection against reactive oxygen species in the pre-implantation embryo and its surroundings." *Hum Reprod Update* 7.
- Guérin, P., S. El Moutassim and Y. Ménézo (2001). "Oxidative stress and protection against reactive oxygen species in the pre-implantation embryo and its surroundings." *Hum Reprod Update* 7(2): 175-189.
- Juriscova, A., I. Rogers, A. Fasciani, R.F. Casper and S. Varmuza (1998). "Effect of maternal age and conditions of fertilization on programmed cell death during murine preimplantation embryo development." *Mol Hum Rep* 2: 139-145.
- Kong, X., S. Yang, F. Gong, C. Lu, S. Zhang, G. Lu and G. Lin (2016). "The Relationship between Cell Number, Division Behavior and Developmental Potential of Cleavage Stage Human Embryos: A Time-Lapse Study." *PLoS One* 11(4): e0153697.
- Kuleshova, L.L. and A. Lopata (2002). "Vitrification can be more favorable than slow cooling." *Fertility and Sterility* 78(3): 449-454.
- Liang, Y., F.Y. Ning, W.J. Du, C.S. Wang, S.H. Piao and T.Z. An (2012). "The type and extent of injuries in vitrified mouse oocytes." *Cryobiology* 64(2): 97-102.
- Mallol, A., J. Santaló and E. Ibáñez (2013). "Comparison of three differential mouse blastocyst staining methods." *Systems Biology in Reproductive Medicine* 59(2): 117-122.
- Mandawala, A.A., S.C. Harvey, T.K. Roy and K.E. Fowler (2016). "Cryopreservation of animal oocytes and embryos: Current progress and future prospects." *Theriogenology* 86(7): 1637-1644.
- Marí, M., A. Morales, A. Colell, C. García-Ruiz and J.C. Fernández-Checa (2009). "Mitochondrial Glutathione, a Key Survival Antioxidant." *Antioxidants & Redox Signaling* 11(11): 2685-2700.
- Matilla, E., F.E. Martín-Cano, L. González-Fernández, F.M. Sánchez-Margallo, I.S. Álvarez and B. Macías-García (2019). "N-acetylcysteine addition after vitrification improves oocyte mitochondrial polarization status and the quality of embryos derived from vitrified murine oocytes." *BMC Veterinary Research* 15(1): 31.
- Momozawa, K., A. Matsuzawa, Y. Tokunaga, S. Abe, Y. Koyanagi, M. Kurita, M. Nakano and T. Miyake (2017). "Efficient vitrification of mouse embryos using the Kitasato Vitrification System as a novel vitrification device." *Reproductive Biology and Endocrinology* 15(1): 29.
- Pedro, P.B., E. Yokoyama, S.E. Zhu, N. Yoshida, D.M. Valdez Jr, M. Tanaka, K. Edashige and M. Kasai (2005). "Permeability of Mouse Oocytes and Embryos at Various Developmental Stages to Five Cryoprotectants." *Journal of Reproduction and Development* 51(2): 235-

- 246.
- Rall W.F., F.G.M. (1985). "Ice-free cryopreservation of mouse embryos at -196 degrees C by vitrification." *Nature* 313(6003): 3.
- Rall, W.F. (1987). "Factors affecting the survival of mouse embryos cryopreserved by vitrification." *Cryobiology* 24(5): 387-402.
- Sawicki, W. and E.T. Mystkowska (1990). "In vivo staining of mouse pre-implantation embryos with hoechst 33342." *The Anatomical Record* 227(3): 359-362.
- Silva, E., A.F. Greene, K. Strauss, J.R. Herrick, W.B. Schoolcraft and R.L. Krisher (2015). "Antioxidant supplementation during in vitro culture improves mitochondrial function and development of embryos from aged female mice." *Reproduction, Fertility and Development* 27(6): 975-983.
- Somfai, T., M. Ozawa, J. Noguchi, H. Kaneko, N.W. Kuriani Karja, M. Farhudin, A. Dinnyés, T. Nagai and K. Kikuchi (2007). "Developmental competence of in vitro-fertilized porcine oocytes after in vitro maturation and solid surface vitrification: Effect of cryopreservation on oocyte antioxidative system and cell cycle stage." *Cryobiology* 55(2): 115-126.
- Somoskoi, B., N.A. Martino, R.A. Cardone, G.M. Lacalandra, M.E. Dell'Aquila and S. Cseh (2015). "Different chromatin and energy/redox responses of mouse morulae and blastocysts to slow freezing and vitrification." *Reprod Biol Endocrinol* 13: 22.
- Tatone, C., G. Di Emidio, M. Vento, R. Ciriminna and P.G. Artini (2010). "Cryopreservation and oxidative stress in reproductive cells." *Gynecological Endocrinology* 26(8): 563-567.
- Tsang W.H. and Chow L.K. (2009). "Mouse embryo cryopreservation utilizing a novel high-capacity vitrification spatula." *Biotechniques* 46(7): 3.
- Vajta, G. (2000). "Vitrification of the oocytes and embryos of domestic animals." *Animal Reproduction Science* 60-61: 357-364.
- Van der Elst J, Amerijckx Y and V.S. A. (1998). "Ultra-rapid freezing of mouse oocytes lowers the cell number in the inner cell mass of 5 day old in-vitro cultured blastocysts." *Human Reproduction* 13(6): 5.
- Yan, C.L., X.W. Fu, G.B. Zhou, X.M. Zhao, L. Suo and S.E. Zhu (2010). "Mitochondrial behaviors in the vitrified mouse oocyte and its parthenogenetic embryo: effect of Taxol pretreatment and relationship to competence." *Fertil Steril* 93(3): 959-66.
- Zhang, J., J. Cui, X. Ling, X. Li, Y. Peng, X. Guo, B.C. Heng and G.Q. Tong (2009). "Vitrification of mouse embryos at 2-cell, 4-cell and 8-cell stages by cryotop method." *Journal of Assisted Reproduction and Genetics* 26(11-12): 621-628.

Apoptotic Cell Death in Ewe Endometrium during the Oestrous Cycle

S. Benbia^{1*}, Y. Belkhiri¹, M. Yahia²

¹Department of Biology of organism, Faculty of Life and Natural Sciences, University Batna 2, Algeria.

^{1,2}Laboratory of Biotechnology of the Bioactive Molecules and the Cellular Physiopathology, Department of Biology of organism, Faculty of Life and Natural Sciences, University Batna 2, Algeria

²Department of cellular and molecular biology, Faculty of Life and Natural Sciences, University Abass Laghrour, Khenchela, Algeria.

ABSTRACT: We hypothesized that endometrial tissues from ewes undergo spatial and temporal changes. Thus, two regulatory events were investigated in this study: cell death (apoptosis) and cell proliferation. Uteri were obtained from healthy ewes at Batna abattoir (Algeria). Based on macroscopic observation of the ovaries and plasma progesterone, uteri were assigned to follicular, early and active luteal phases. Apoptosis and proliferation were assessed by detection of cleaved caspase-3 and Ki-67, respectively. Ki-67 and cleaved caspase-3 (CCP-3) were expressed in both phases of the oestrous cycle and all endometrium cells types [luminal epithelia (LE), superficial gland epithelia (SG) and deep gland epithelia (DG)]. Immunohistochemistry for cleaved caspase-3 revealed few or no apoptotic stained cells in all endometrium locations during the entire oestrous cycle. However, Ki-67 was significantly higher in the follicular phase than in the early and active luteal phase. Besides, expression of CCP-3 in LE was higher than in SG and DG at the follicular phase and early luteal phase. However, Ki-67 and CCP-3 levels in all endometrium cells types did not significantly change at active luteal phase. Therefore, it is concluded that apoptosis and proliferation were occurred in ewe endometrium in a cyclic pattern and under the influence of the endocrine profile.

Keywords: ewes; endometrium; apoptosis; proliferation; oestrous cycle.

Corresponding Author:

Souheyla Benbia, Laboratory of Biotechnology of the Bioactive Molecules and the Cellular Physiopathology, Department of Biology of organism, Faculty of Life and Natural Sciences, University Batna 2, P.O. Box 05000, Algeria
E-mail address: s.benbia@univ-batna2.dz

Date of initial submission: 13-11-2019
Date of revised submission: 08-02-2020
Date of acceptance: 07-02-2020

INTRODUCTION

It is well known that the major reason for the failure of the embryo implantation is abnormal endometrial receptivity. During this period, morphological and biochemical changes occur in mammalian endometrium. These modifications are regulated by a plethora of factors, including oestrogen, progesterone, and their receptors, transcriptional factors and many others (Lonergan and Forde, 2014; Simmons et al. Recent investigations have demonstrated the importance of apoptosis in the processes of endometrial tissue remodeling during the oestrous cycle (Arai et al., 2013; Simmons et al., 2009). The balance between cell proliferation and apoptosis regulates the periodic repair and shedding of endometrial cells and leads to the menstruation (in the woman) or prepare the mucosal layer of endometrium for the implantation of the embryo (Stewart et al., 1999; Antsiferova and Sotnikova, 2016).

Apoptosis is a form of programmed cell death in which cells condense and fragment their nuclear material, condense their cytoplasmic material and then release their contents in membrane-bound apoptotic bodies (Mcilwain et al., 2013). Cells are induced to undergo apoptosis through either extrinsic or intrinsic pathways, which are controlled by the expression of a number of regulatory apoptosis-related genes, such as bcl-2 family (Li et al., 1998; Mcilwain et al., 2013), death receptor and caspases (Li et al., 1997; Mcilwain et al., 2013). Caspases, a family of aspartic acid-specific cysteine proteases are considered a key mediator of apoptosis in various cells (Brenner and Mak, 2009). Caspase-3 is the best-identified protein among the 14 caspase family members (Brenner and Mak, 2009; Mcilwain et al., 2013).

Ki-67 is a non-histone nuclear protein observed in proliferating cells and found in all phases of the cell cycle, except of G0 phase (Gap 0), and comprises two molecules of 345- and 395-kD weight; its gene is located on human chromosome 10. This marker is expressed during G1(Gap 1), S (Synthesis), G2, and M (Mitosis) phases of cell cycle. In the first phase, Ki-67 is frequently revealed near the nucleus. During S and G2 phases, this protein is detected throughout the nucleus (Verheijen et al., 1989a). Generally, Ki-67 expression was observed during mitosis phase (Verheijen et al., 1989b).

Although cell proliferation has already been verified in the sheep endometrium (Zheng et al., 1996; Johnson et al., 1997a, 1997b), to our knowledge no

study data on apoptotic cells are available. The aim of this investigation was to examine the occurrence of endometrial apoptosis and proliferation at defined stages of the oestrous cycle of the ewe, through the assessment of active caspase-3 and Ki-67, respectively.

MATERIAL AND METHODS

Collection of endometrium and blood samples

Twenty five normal uteri without a visible conceptus were collected from ewes at commercial abattoir, Batna (Algeria). Based on the methodology described previously by Benbia et al. (2017), ten of the ewes were classified in follicular phase and fifteen were in luteal phases (six at ELP and nine at ALP). Endometrial biopsies were obtained from the uterine horns, and then fixed in formol 10% before embedding. Jugular blood samples were collected into EDTA tubes from all animals before slaughter; plasma was stored at -20°C until assay.

Immunohistochemistry and scoring

Sections of 3-4 µm were placed on Super Frost slides (Menzel-Glaser, Freiburg, Germany). Slides were deparaffinized and subjected to antigen-retrieval at 95°C for 20 minutes on a Dako PT Link Envision Flex-Target retrieval solution at low pH (pH 6.0). Thereafter, slides were cooled and incubated for 10 min in Envision Flex Washing buffer.

Sections were stained in an automatic immunohistochemical staining device (Dako Autostainer Link 48) with mouse monoclonal anti Ki-67 antibody, clone MIB-1 (M7240; Dako-Cytomation, Glostrup, Denmark) as the proliferation marker and rabbit polyclonal anti cleaved caspase 3 (Asp175) antibody (#9661; Cell Signalling Technology, Boston, USA) as the apoptotic cell marker. Normal mouse or rabbit serum was used instead of the primary antibody (for negative control). Sections were incubated with secondary antibodies (EnVision FLEX; Dako) for 20 minutes. Staining was performed with 3,3-Diaminobenzidine (DAB) as chromogen for 20 minutes. Finally, sections were counterstained with Mayer's hematoxylin, in a graded series of ethanol, cleared in xylene, and covered with a cover slip using a monted medium.

Staining was assessed at: luminal epithelium (LE), superficial gland epithelium (SG) and deep gland epithelium (DG). Immunoreactivity of both markers was calculated using Quick Score (QS). The following formula was used for the evaluation of QS as

described by Sağsöz et al. (2011) stromal cells and smooth muscle cells. Generally, in the cervix, ER α immunoreactivity was more intense in the epithelial and smooth muscle cells during the follicular phase and in the epithelial cells during the luteal phase ($p < 0.05$).

QS= Intensity score (IS) + Proportional score (PS).

The IS was defined as the intensity of brown colour of nuclei. The intensity of staining for each protein was quantified using Image-Pro Plus 6.3 image processing and analysis software according to the manufacturer's instructions (Media Cybernetics, Inc., Bethesda, MD, USA). The PS was evaluated by manually counting the number of cells showing nuclear staining in 100 epithelial cells. The Immunoreactivity was categorized as described in table 1.

Hormone assessment in blood

Plasma progesterone concentration was determined using a radioimmunoassay kit (ImmuChem™ Double Antibody Progesterone I¹²⁵ RIA Kit, MP Bio-medicals, USA). The sensitivity of this assay was 0.18 ng/ml. Plasma concentrations of oestradiol 17 β was assessed using E2 Diasorin RIA kit (Sorin Diagnostic, Antony, France). The sensitivity of the assay was 0.07 pg/ml.

Statistical analysis

Statistical analyses were performed using Graph Pad Prism 6 (ver. 5.02, GraphPad Software, Inc., CA, USA). Initially, data were tested for normality and homogeneity (Bartlett test) of variances. The factors in

the procedure were: stage of oestrous cycle (FP, ELP and ALP), and endometrium cells types (LE, SG and DG).

Effects of stage of the oestrous cycle on cell-specific expression of Ki 67 and CCP-3 were analyzed using two-way ANOVA. Comparison of means was performed by Bonferroni post hoc test. Possible correlations among cell apoptosis (CCP-3), cell proliferation (Ki-67) and plasma oestradiol 17 β concentration, in the three endometrium cell types were tested using spearman correlation. Statistical significance was considered as $P < 0.05$.

RESULTS

The plasma concentration of P4 was 3.2 ± 0.06 ng/ml in the active luteal phase and decreased ($P < 0.05$) to 1.1 ± 0.49 ng/ml in the next phase. The lowest P4 concentration was observed in the early luteal phase (0.5 ng/ml).

Localization and expression of Ki-67-positive cells throughout the oestrous cycle

As shown in Figure 1, endometrial cell proliferation and apoptosis were detected during the oestrous cycle of the ewes. Even though Ki-67 and CCP-3 were expressed in both follicular and luteal phases of the oestrous cycle, the Quick score of cells expressing Ki-67 was significantly higher than CCP-3 at the FP and ELP ($P < 0.05$) (Fig1), while CCP-3 was significantly higher in FP compared to ALP. Furthermore, Ki-67 marker was higher at the early luteal phases compared to the active luteal phase ($P < 0.05$) (Fig 1). Regarding cleaved caspase 3, no difference was observed among luteal phases ($P = 0.95$) (Fig1).

Table 1: Immunosensitivity categorization - Grading of Ki-67 and CCP-3.

IS		PS	
0	Absent staining	1	<1%
1	Weak staining	2	1–10%
2	Moderate staining	3	11–33%
3	Strong staining	4	34–66%
		5	67–100%

IS: intensity score.; PS: proportional score (%)

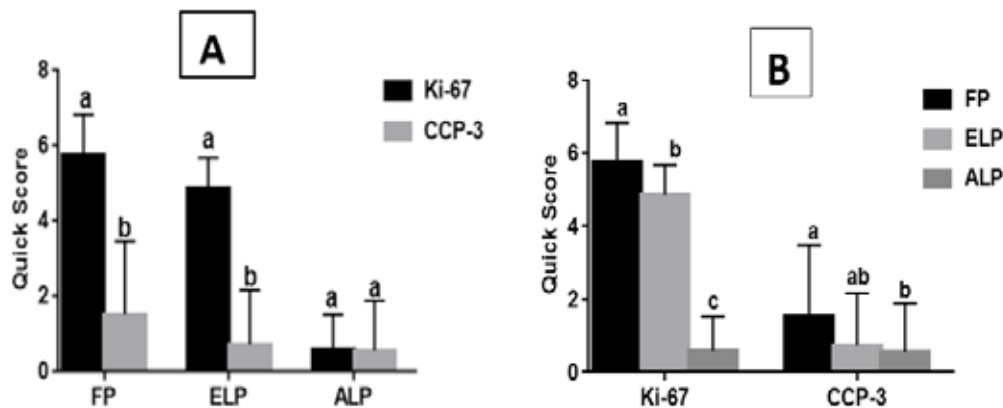


Figure 1. Comparison between total Quick score of CCP-3 (mean±SEM) and Ki-67 (mean±SEM) expression in sheep endometrium during the oestrous cycle. Values with different superscript letters differ significantly ($P < 0.05$), between Ki-67 and CCP-3 (figure 1.A) and among the FP, ELP and ALP (figure 1.B).

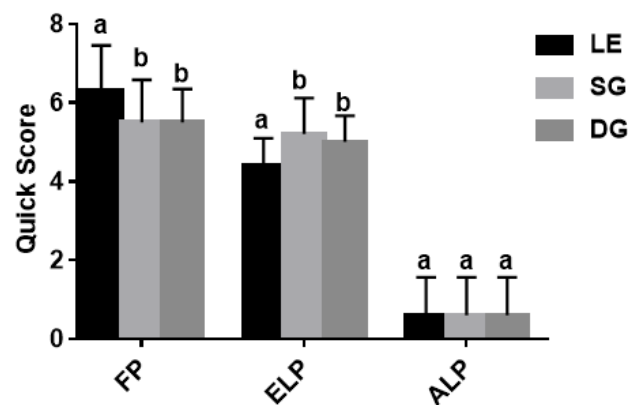


Figure 2. Quick score of Ki-67 (mean±SEM) in different sheep endometrial compartments (luminal epithelium, superficial and deeper glands) at the follicular phase and at different stages of the luteal phase. LE: luminal Epithelium; SG: Superficial Glands; DG: Deeper Glands; FP: Follicular Phase; ELP: Early Luteal Phase; ALP: Active Luteal Phase. Values with different superscript letters differ significantly, among the endometrium cell types (LE, SG, DG).

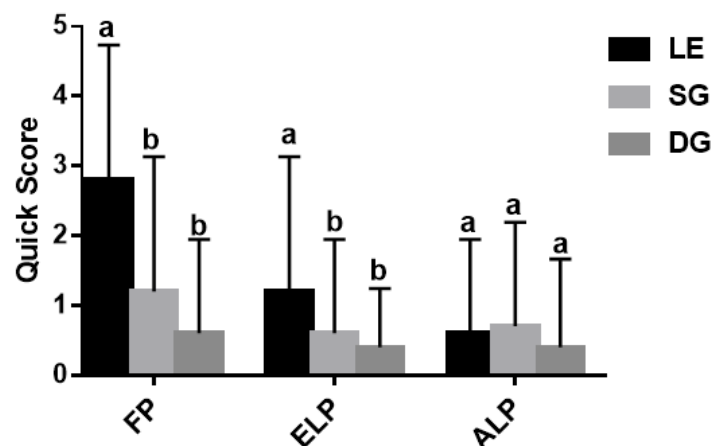


Figure 3. Quick score of CCP-3 (mean±SEM) in different sheep endometrial compartments (luminal epithelium, superficial and deeper glands) at the follicular phase and at different stages of the luteal phase. LE: luminal Epithelium; SG: Superficial Glands; DG: Deeper Glands; FP: Follicular Phase; ELP: Early Luteal Phase; ALP: Active Luteal Phase. Values with different superscript letters differ significantly, among the endometrium cell types (LE, SG, DG).

Ki-67 nuclear expression in different endometrial cells (LE, SG, DG) throughout the follicular and luteal phase are presented in Figure 2. Ki-67 stains all endometrium cells with high intensity, so intensity score was always as grade 3. The proliferative activity of luminal epithelium (LE) was significantly higher compared with endometrial glands (SG and DG) at follicular phase ($P<0.01$) (Fig 2). The immunoreactivity of cells expressing Ki-67 protein was significantly increased in the follicular phase and early luteal phase than in the active luteal phase. Besides, expression of this marker in LE, SG and DG was higher during the early luteal stage than in the active luteal phase ($P<0.05$) (Fig 2). Furthermore, Ki-67 nuclear expression in endometrial glands (SG, DG) did not significantly change during the follicular and early luteal stage transition (Fig 2).

Expression Ki-67 in uterine epithelium (LE, SG and DG) did not significantly change at active luteal phase.

Localization and expression of CCP-3-positive cells in ewe endometrium

Active CCP-3 expression was detected in both lu-

minal and glandular epithelial cells in the sheep endometrium during all phases of the oestrous cycle (Fig 3). CCP-3 was more expressed in the luminal epithelium than in the glandular epithelial cells at the follicular phase and early luteal phase ($P<0.05$); however, the active luteal phase endometrium cells types did not affect the expression of this protein (Fig 3).

Relationship between cell apoptosis (CCP-3) and cell proliferation (Ki-67)

Table 2 shows that a negative correlation was revealed between CCP-3 and Ki-67 expression; this correlation was significant during the ELP ($P=0.02$) and approached significance during FP ($P=0.05$).

Relationship between cell proliferation and plasma oestradiol 17β concentration

As shown in a Table 3, positive approached significant correlation was found between Ki-67 expression and plasma oestradiol 17β concentration in ewe endometrium in LE (ELP, $P=0.06$; ALP, $P=0.05$) and SG (ELP, $P=0.08$) during oestrous cycle phases ($P>0.05$) (this taken from the limited number of samples in this work).

Table 2. Correlation between cell apoptosis (CCP-3) and cell proliferation (Ki-67), during the oestrous cycle.

CCP-3 Quick score	Ki-67 Quick score					
	PF		ELP		ALP	
	r		r	P	r	P
	-0.62	0.05	-0.751	0.02	0.334	0.2

FP: Follicular Phase; ELP: Early Luteal Phase; ALP: Active Luteal Phase; r: correlation coefficient; P: Probabilities significant ($P<0.05$)

Table 3. Correlation between cell proliferation and plasma oestradiol 17β concentration, in the three endometrium cell types during the oestrous cycle.

Plasma oestradiol 17β concentration							
		FP		ELP		ALP	
		r	P	r	P	r	P
Ki-67 Quick score	LE	0.691	0.059	0.501	0.06	0.689	0.05
	SG	0.61	0.063	0.761	0.08	0.565	0.084
	DG	0.40	0.19	0.39	0.49	0.32	0.33

FP: Follicular Phase; ELP: Early Luteal Phase; ALP: Active Luteal Phase; LE: luminal epithelium; SG: superficial gland; DG: deeper gland; r: correlation coefficient; P: Probabilities significant ($P<0.05$).

DISCUSSION

The present study examined, for the first time, the occurrence of apoptosis (CCP-3) in the various cells types of sheep endometrium, during the stages of the oestrous cycle. In many mammals, endometrium function and homeostasis is an important physiological phenomenon that ensures a dynamic balance between cell proliferation and cell death (apoptosis) throughout the oestrous cycle (Johnson et al., 1997b, 1997a) on cow (Arai et al., 2014, 2013), goat (Zhang et al., 2018, 2019) and equine (Costa et al., 2007), but, to our best knowledge, not in sheep.

According to our results Ki-67 and cleaved caspase-3 were differentially expressed in endometrium of sheep, and this expression exhibited spatial and temporal changes. It was noteworthy that there were few or no apoptotic stained cells in all endometrium locations during the entire oestrous cycle.

In this research, we found higher levels of Ki-67 in the follicular and early luteal phase, compared with active luteal phase endometrium when low expression of this protein was observed in the various endometrium cell types. These Ki-67 patterns during luteal phase are in agreement with the results of García-Palencia et al. (2007), who demonstrated that intra-vaginal progestogen treatment had a great effect on the immunoexpression of cell proliferation marker in sheep endometrium.

In the present study, cleaved caspase-3 expression increased significantly in the follicular phase and decrease in early and active luteal phase. Additionally, we revealed that CCP-3 is differentially expressed in the various cell types of sheep endometrium. It was well-known that the main executioner involved in the cell death pathway is caspase-3 (CPP3), which is activated during the early stage of apoptosis in rat (Alan and Liman, 2016). The assessment of the active form of this protein is one of the most exploited diagnostic methods for revealing apoptosis in various cell types (Jin and El-Deiry, 2005). Likewise, it has been suggested that endometrial apoptosis was regulated by the expression of active caspase-3 during the oestrous cycle in goat and cow (Zhang et al., 2018; Arai et al., 2013) and during early pregnancy in the rat (Öner et al., 2010).

Recently, it was indicated that, several regulators of programmed cell death and cell proliferation, such

as PTEN, PTEN/PI3K/AKT, Bcl-2 family, FAS, p53 and Caspase-3 are implicated in the apoptosis and proliferation of the endometrium cells of dairy goats in vitro, (Zhang et al., 2019). For example, Zhang et al. (2018) reported that miR-26a mimic increased the Caspase-3 protein levels in endometrium epithelial cells, but it decreased the expression of this protein in endometrium stromal cells of dairy goats (Zhang et al., 2018). However, no such research has been performed in the endometrium of sheep. These in vitro studies suggested that there were enormous and complicated regulatory networks expressed differentially in cell types and functions in the endometrium of ruminants. Except the oestrogen and progesterone, a variety of factors contributed in this regulation, such as growth factors (Stevenson et al., 1994; Md. Rashedul Islam et al., 2016) and integrins (Park et al., 2017).

In this study, we found that the expression of CCP-3 and Ki-67 were highly regulated temporally and among cell types, mainly in uterine luminal epithelium. Surface epithelium is the first contact point of the embryo during the early stage of implantation (Bazer, 2013). Our result suggest that apoptosis may be indispensable for the establishment of endometrial function in sheep.

Previous investigations in several mammalian species have revealed an inverse correlation between cell apoptosis and cell proliferation in the uterus (Harada et al., 2004; Costa et al., 2007; Okano et al., 2007) which was consistent with the results of the present study in the follicular phase and early luteal phase endometrium of sheep.

In the present study, a positive correlation was suggested between oestrogen concentration and cell proliferation score (approach significant) and was significant during early luteal phase in LE and SG cells. Thus, Thus, most proliferation occurred during the follicular and early luteal phases, when follicular growth and maturation result in the highest production of E2, followed by the second E2 peak during metestrus (Robinson et al., 2001).

Endometrial epithelial cells proliferation decreased during the active luteal phase when circulating P4 levels were high.. Shiozawa et al. (2001) hypothesized that in the luteal stage, P4 can raise the levels of some negative regulators, such as p27 (Shiozawa et al., 2001) and cyclin G1 (Yuan et al., 2014) required for the proliferation inhibition as it has been observed in human endometrial epithelial cells. Recently Arm-

strong et al. (2017) revealed that apoptosis was rapidly induced after the progesterone-withdrawal in mouse and human endometrium (Armstrong et al., 2017). We hypothesized, probably, that a similar mechanism might also apply in the case of sheep.

CONCLUSION

It is concluded in the present report that both Ki-67((proliferation) and cleaved caspase-3 (apoptosis) were expressed in the endometrium of sheep, and this expression exhibited spatial and temporal variations. Tissue remodeling was mainly observed in luminal epithelium cells of endometrium.

ACKNOWLEDGEMENTS

This work was supported by Laboratory of Bioactive Molecules and Cellular Physiopathology, Faculty of Natural and Life Sciences , Batna -2 University, 05000, Batna, Algeria and Directorate-General For Scientific Research And Technological Development (DGSRTD), Algeria.

CONFLICT OF INTEREST

No potential conflict of interest was reported by the authors.

REFERENCES

- Alan E and Liman N (2016) Involution Dependent Changes in Distribution and Localization of Bax , Survivin , Caspase-3 , and Calpain-1 in the Rat Endometrium. *Microscopy Research And Technique*. 297(79):285–297.
- Antsiferova YS and Sotnikova NY (2016) Apoptosis and endometrial receptivity: Relationship with in vitro fertilization treatment outcome. *World Journal of Obstetrics and Gynecology*. 5(1):87.
- Arai M, Yoshioka S, Nishimura R and Okuda K (2014) FAS / FASL-mediated cell death in the bovine endometrium. *Animal Reproduction Science*. 151(3–4):97–104, Elsevier B.V.
- Arai M, Yoshioka S, Tasaki Y and Okuda K (2013) Remodeling of bovine endometrium throughout the estrous cycle. *Animal Reproduction Science*. 1–9, Elsevier B.V.
- Armstrong GM et al. (2017) Endometrial apoptosis and neutrophil infiltration during menstruation exhibits spatial and temporal dynamics that are recapitulated in a mouse model. *Scientific Reports*. 7:17416.
- Bazer FW (2013) Pregnancy recognition signaling mechanisms in ruminants and pigs. *Journal of animal science and biotechnology*. 4(1):.
- Benbia S, Yahia M, Letron IR and Benounne O (2017) Endometrial Cells Morphology Depending on Estrous Cycle and Histologic Layers in Cows: Morphometric Study Biotechnology's Laboratory of the Bioactive Molecules and the. *Global Veterinaria*. 18(1):68–73.
- Brenner D and Mak TW (2009) Mitochondrial cell death effectors. *Current Opinion in Cell Biology*. 21:871–877.
- Costa RPR da et al. (2007) Caspase-3 mediated apoptosis and cell proliferation in the equine endometrium during the estrous cycle. *Reproduction, Fertility and Development*. 19:925–932.
- Garcia-Palencia P et al. (2007) Sex steroid receptor expression in the oviduct and uterus of sheep with estrus synchronized with progestagen or prostaglandin analogues. *Animal Reproduction Science*. 97(1–2):25–35.
- Harada T et al. (2004) Apoptosis in human endometrium and endometriosis. *Human Reproduction Update*. 10(1):29–38.
- Jin Z and El-Deiry WS (2005) Overview of Cell Death Signaling Pathways ND ES SC. *Cancer Biology & Therapy*. 4(2):147–171.
- Johnson ML, Redmer D a and Reynolds LP (1997a) Uterine growth, cell proliferation, and c-fos proto-oncogene expression throughout the estrous cycle in ewes. *Biology of reproduction*. 56(2):393–401.
- Johnson ML, Redmer D a and Reynolds LP (1997b) Effects of ovarian steroids on uterine growth, morphology, and cell proliferation in ovariectomized, steroid-treated ewes. *Biology of reproduction*. 57(January 1997):588–596.
- Li H, Zhu H, Xu CJ and Yuan J (1998) Cleavage of BID by caspase 8 mediates the mitochondrial damage in the Fas pathway of apoptosis. *Cell*. 94(4):491–501.
- Li P et al. (1997) Cytochrome c and dATP-Dependent Formation of Apaf-1 / Caspase-9 Complex Initiates an Apoptotic Protease Cascade. 91479–489.
- Loneragan P and Forde N (2014) Maternal-embryo interaction leading up to the initiation of implantation of pregnancy in cattle. *Animal*. 8(s1):64–69.
- McIlwain DR, Berger T and Mak TW (2013) Caspase Functions in Cell Death and Disease. *Cold Spring Harb Perspect Biol*. 5:1–27.
- Md. Rashedul Islam, Yamagami K, Yoshii Y and Yamauchi N (2016) Growth factor induced proliferation, migration, and lumen formation of rat endometrial epithelial cells. *Journal of Reproduction and Development*. 62(3):271–278.
- Okano A, Ogawa H, Takahashi H and Geshi M (2007) Apoptosis in the porcine uterine endometrium during the estrous cycle, early pregnancy and Post partum. *Journal of Reproduction and Development*. 53(4):923–930.
- Öner H, Öner J and Demir R (2010) Distributions of PCNA and Cas-3 in rat uterus during early pregnancy. *Folia Histochemica Et Cytobiologica*. 48(1):71–77.
- Park HJ et al. (2017) Integrins functioning in uterine endometrial stromal and epithelial cells in estrus. *Reproduction*. 153:351–360 Introduction.
- Robinson RS, Mann GE, Lamming GE and Wathes DC (2001) Expression of oxytocin, oestrogen and progesterone receptors in uterine biopsy samples throughout the oestrous cycle and early pregnancy in cows. *Reproduction*. 122(6):965–979.
- Sağsöz H, Akbalik ME, Saruhan BG and Ketani M a (2011) Localization of estrogen receptor α and progesterone receptor B in bovine cervix

- and vagina during the follicular and luteal phases of the sexual cycle. *Biotechnic & histochemistry*. 86(4):262–71.
- Shiozawa T et al. (2001) Up-Regulation of p27Kip1 by Progestins Is Involved in the Growth Suppression of the Normal and Malignant Human Endometrial Glandular Cells. *Endocrinology*. 142(4):4182–4188.
- Simmons RM et al. (2009) Insulin-like growth factor binding protein-1 in the ruminant uterus: potential endometrial marker and regulator of conceptus elongation. *Endocrinology*. 150(9):4295–4305.
- Stevenson KR, Gilmour RS and Wathes DC (1994) Localization of insulin-like growth factor-I (IGF-I) and -II messenger ribonucleic acid and type I IGF receptors in the ovine uterus during the estrous cycle and early pregnancy. *Endocrinology*. 134(4):1655–1664.
- Stewart CJR, Critchley HOD and Farquharson MA (1999) Endometrial apoptosis in patients with dysfunctional uterine bleeding. *Histopathology*. 34:99–105.
- Verheijen R, Kuijpers HJH, Driel R Van, et al. (1989a) Ki-67 detects a nuclear matrix-associated proliferation-related antigen II. Localization in mitotic cells and association with chromosomes. *Journal of Cell Science* 92, 92531–540.
- Verheijen R, Kuijpers HJH, Schlingemann RO, et al. (1989b) Ki-67 detects a nuclear matrix-associated proliferation-related antigen I. Intracellular localization during interphase. *J Cell Sci*. 92((Pt 1)):123–30.
- Yuan D -z. et al. (2014) Progesterone-Induced Cyclin G1 Inhibits the Proliferation of Endometrial Epithelial Cell and its Possible Molecular Mechanism. *Endocrine Research*. 46:761–767.
- Zhang L et al. (2018) MiR-26a promoted endometrial epithelium cells (EECs) proliferation and induced stromal cells (ESCs) apoptosis via the PTEN-PI3K/AKT pathway in dairy goats. *Journal of Cellular Physiology*. 233(6):4688–4706.
- Zhang L et al. (2019) Endometrial Epithelial Cell Apoptosis Is Inhibited by a ciR8073-miR181a-Neurotensin Pathway during Embryo Implantation. *Molecular Therapy: Nucleic Acid*. 14(22):262–273, Elsevier Ltd.
- Zheng J, Johnson ML, Redmer DA and Reynolds LP (1996) Estrogen and progesterone receptors, cell proliferation, and c-fos expression in the ovine uterus during early pregnancy. *Endocrinology*. 137(1):340–348.

Effect of iron oxide and silver nanoparticles on boar semen CASA motility and kinetics

A. Basioura, I. Michos, A. Ntemka, I. Karagiannis, C.M. Boscos*

*Farm Animals Clinic, School of Veterinary Medicine, Faculty of Health Sciences,
Aristotle University of Thessaloniki, Greece*

ABSTRACT: The objective of the study was to investigate the potential toxic effect of iron oxide (Fe_3O_4) and silver (Ag/Fe) spherical nanoparticles (NPs) as alternative antimicrobial compounds on boar semen. The NPs' minimum inhibitory concentration was determined applying the *in vitro* antimicrobial activity evaluation test and included in the experiment. Totally, 9 ejaculates (3 boars; 3 ejaculates/boar) were extended in BTS without antibiotics at 30×10^6 spermatozoa/mL and divided in 3 aliquots corresponding to the following groups: 1) Control group (C): extended semen without treatment; 2) Iron oxide group (Fe): extended semen with Fe_3O_4 NPs of diameter 40 nm (0.192 mg/mL semen); and 3) Silver group (Ag): extended semen with Ag/Fe NPs of diameter 30 nm, consisted of Ag and a 5% of zero-valent Fe (0.128 mg/mL semen). Semen samples of all groups were incubated at 17° C for 30 min following NPs' removal through a magnetic field. All post treated samples were stored at 17° C for 48 h. Total motility (TM) and kinetics (progressive motility PM; rapid/medium/slow movement spermatozoa; static spermatozoa; VCL; VSL; VAP; LIN; STR; WOB; ALH; BCF; hyperactive spermatozoa) were evaluated by CASA system at 0, 24 and 48 h post treatment. Data were analyzed with a repeated measures mixed model. Group Fe did not differ from group C at any time point. TM and PM were lower at 24 h of storage in group Ag compared to groups C and Fe (all $P < 0.001$). By 48 h of storage spermatozoa of group Ag were totally immotile and thus excluded from analysis. The comparison within groups and between storage time points showed that the values of TM, PM, VCL, VAP, ALH and BCF decreased after 24 h of storage in group Ag (all $P < 0.05$), but not in groups C and Fe, while no significant differences were observed for the remaining parameters between successive time points within any group ($P > 0.05$). In conclusion, Ag/Fe NPs demonstrated a harmful effect on boar spermatozoa, while the used concentration of the examined Fe_3O_4 NPs did not affect boar sperm CASA motility parameters enhancing further research about their application on semen handling.

Keywords: boar; semen; CASA; motility; nanoparticles

Corresponding Author:

C.M. Boscos, Farm Animals Clinic, School of Veterinary Medicine, 11, St. Voutyra str., Thessaloniki, 54627, Greece
E-mail address: pboscos@vet.auth.gr

Date of initial submission: 14-11-2019

Date of revised submission: 17-12-2019

Date of acceptance: 23-12-2019

INTRODUCTION

Semen collection in farm animals, including boars, is a procedure that takes place under no sterile conditions. Consequently, ejaculate contamination with bacteria is inevitable and a variety of bacteria from different genera has been identified after microbiological culture of semen samples (Akhter et al., 2008; Althouse et al., 2000). Semen extenders support the longevity of spermatozoa, but at the same time provide a particularly ideal environment for bacteria proliferation (Karageorgiou et al., 2016). Currently, antibiotics are the main constituent of their composition to avoid growth of bacteria and enhance reproductive performance (Salamon and Maxwell, 2000). A variety of antibiotic compounds have been used so far, to control microbial contamination in extenders. However, during the last decades, the antibiotics have been overused to control infections of animals and human beings and as a result, the antibiotic-resistant bacterial strains have been an emergency and a serious threat for the public health and animals' diseases management worldwide (Gyles, 2011). Also, regarding animals' reproduction, more recent studies have demonstrated that some antimicrobials may have a deleterious or toxic effect on bull (Azawi and Ismaeel, 2012) and equine (Varner et al., 1998) spermatozoa. Under these circumstances, an increasing scientific interest about novel compounds with antimicrobial properties has been demonstrated (Hajipour et al., 2012).

Nanotechnology as a promising and contemporaneous scientific field introduces nanomaterials, which are objects made of different shapes and sizes in nanometer scale. Due to their tiny size and their high surface to volume ratio, they provide specific physical, chemicals and biological activities (Hajipour et al., 2012). Specifically, nanoparticles (NPs) fabricated from metals, like silver (Rai et al., 2009), or metal oxides, like iron oxide (Azam et al., 2012), have received great attention by the scientific community. It is well known from the ancient years that the silver can demonstrate strong antibacterial action and nowadays it has been used as alternative agents to conventional antibiotics (Chaloupka et al., 2010). Also, iron oxide NPs have been widely used, for instance as magnetic resonance imaging contrast agents due to their magnetic properties (Babes et al., 1999), while its antimicrobial properties are well documented in the literature (Azam et al., 2012), too.

The unique properties of NPs have made them

popular in different scientific fields, including medicine applications and biomedical research (Salata, 2004). Regarding semen technology, many published studies documented the antioxidant effect of nanoparticles on ram (Falchi et al., 2018), bull (Raana et al., 2015), rat (Afifi et al., 2015) and rooster (Safa et al., 2016) semen. Also, NPs have been used for sperm selection process in IVF protocols or for sperm purification and sorting for artificial insemination (Feugang et al., 2014). However, the last decades due to the extended use of NPs, there is an increasing concern about their possible side effects or toxicity in cellular level for humans' and animals' beings or even the environment. Recent studies have examined the effect of NPs on reproductive system and have focused mainly on spermatozoa indicating controversial results about their toxicity action on male gametes (Barkalina et al., 2014; Lafuente et al., 2016; Wiwanitkit et al., 2009).

The aim of the present study was to investigate the effect of iron oxide and silver spherical NPs on CASA motility and kinetic parameters of extended boar semen with the perspective of their possible use as alternative antimicrobial agents for semen handling.

MATERIALS AND METHODS

Reagents and media

All the reagents and chemicals used in the present study were of high analytical quality and were purchased from Sigma Aldrich, Seelze, Germany, unless otherwise stated. Semen samples were extended with Beltsville Thawing Solution (BTS: 205 mM glucose, 20.4 mM sodium citrate, 10.0 mM KCl, 15.0 mM NaHCO_3 , 3.6 mM EDTA; pH 7.4; 290-300 mosmol/kg) without antibiotics.

Synthesis and dispersions of Fe_3O_4 and Ag/Fe NPs

Iron oxide (Fe_3O_4) nanoparticles and a silver-based (Ag/Fe) nanocomposite were used in this study. Fe_3O_4 nanoparticles were synthesized by the oxidative hydrolysis of Fe^{2+} in aqueous media through the intermediate formation of green rust. Particularly, 5.56 g of $\text{FeSO}_4 \cdot 7\text{H}_2\text{O}$ were dissolved in 80 mL of 0.01 M H_2SO_4 solution and rapidly mixed with a second solution prepared by dissolving 1.84 g NaOH, 1.70 g NaNO_3 and 25 mL ethanol into 40 mL distilled water. Formed green rust precipitate was aged at 90°C for 24 h to receive spherical Fe_3O_4 nanoparticles with diameter around 40 nm. The produced solid was washed several times with distilled water until a conductivity below 1 mS/cm was obtained. On the oth-

er hand, the Ag/Fe nanocomposite was prepared by solar-powered physical vapor deposition (SPVD) in a Heliotron 2 kW glass vacuum chamber at the facilities of PROMES (France). A pellet of pressed Fe and Ag powder (5% wt. Fe) was evaporated under the focus of concentrated solar beam at a pressure of 70 torr controlled by a continuous flow of Ar. Particles were collected on a nanoporous ceramic filter located in the direction of pumping flow. The obtained Ag/Fe nanopowder maintained a composition around 5 % in zero-valent Fe with a particles' unit diameter of around 30 nm.

Taking into account the minimum inhibitory concentration (MIC) of the examined NPs after in vitro antimicrobial activity assessment, they were dissolved in distilled water and the following stock solutions were prepared: 1) solution of Fe_3O_4 NPs: 19.2 mg/ml distilled water; 2) solution of Ag/Fe NPs: 12.8 mg/ml distilled water. A fresh solution of each NP was prepared every week. Prior to their use, the NPs solutions were sonicated for 20 min to improve their dispersion stability.

Animals, semen samples collection and dilution

Semen samples were collected from 3 sexually mature (2-2.5 years old) and healthy boars (cross-bred) of a 700-capacity pig farm in Northern Greece. Totally, nine ejaculates (3 boars; 3 ejaculates/boar) were collected weekly by an experienced farm employee using the gloved hand technique and were transported in an isothermal glass vessel (37° C) to the farm laboratory. The gelatinous portion was discarded with a cotton gauze and the semen sample was estimated for volume, concentration, and motility. Sperm concentration was assessed by a photometer (SDM1, Minitube®, Germany). Sperm motility was subjectively evaluated by a phasecontrast microscope with a heated stage at 37° C. Only ejaculates with volume >200 µl, concentration >200×10⁶ spermatozoa/ml, total sperm number/ejaculate > 40×10⁹, and gross motility >70% were further processed.

Semen samples with acceptable quality were extended in BTS without antibiotics (30×10⁶ spermatozoa/ml). The extended semen samples were reexamined microscopically and those with gross motility >70% were packaged in vials of insemination and were transported (17° C) in less than 60 min in a portable semen storage unit (Minitube®, Germany) to the Unit of Biotechnology of Reproduction (UBR), Clinic of Farm Animals, Faculty of Veterinary Medicine,

Aristotle University of Thessaloniki.

Semen processing with NPs

Upon arrival in the UBR, each semen sample was divided in 3 aliquots and the following three experimental groups were prepared: 1) control group (C): extended semen without any treatment; 2) iron oxide group (Fe): extended semen with Fe_3O_4 NPs (0.192 mg Fe_3O_4 /ml semen); 3) silver group (Ag): extended semen with Ag/Fe NPs (0.128 mg Ag/Fe/ml semen).

Pretrial: Determination of coincubation time of semen with NPs

In a pretrial (data not shown), the beneficial/detrimental coincubation period of semen samples with NPs was evaluated. The C and NPs groups were incubated at 17° C (the appropriate storage temperature of extended boar semen) for 30, 45 and 60 min following the NPs' removal through a magnetic field (as it is described in the main trial) and total and progressive motility were assessed by CASA. The incubation period of 45 and 60 min were excluded because the values of the examined CASA parameters were significantly decreased in NPs groups, compared to the control group, whilst interestingly boar spermatozoa in Ag group were completely immotile after 60 min of coincubation. Consequently, the coincubation period of 30 min was selected for further research because no differences observed for the evaluated CASA parameters between the control and the NPs groups.

Main trial: Investigation of effect of NPs on boar semen quality

The three experimental groups were stored at 17° C for 30 min after Fe and Ag/Fe NPs supplementation to groups Fe and Ag, respectively, following NPs' removal through a magnetic field. For NPs' removal, tubes were placed in a plastic rack equipped with magnets, remained in vertical position for at least 5 min and the post-treated semen was transferred to a new tube, while the NPs were discarded. This procedure was repeated three times to remove completely the NPs. Finally, the control and the NPs post treated samples were stored at 17° C for 48 h. Total motility and kinetics (progressive motility; rapid/medium/slow movement spermatozoa; static spermatozoa; VCL; VSL; VAP; LIN; STR; WOB; ALH; BCF; hyperactive spermatozoa) were evaluated by CASA at 0, 24 and 48 h post treatment.

Sperm motility and kinetics evaluation by CASA

Sperm motility was evaluated by a Computer Assisted Semen Analysis (CASA) system (Sperm Class Analyser®, Microptic S.L., Automatic Diagnostic Systems, Spain) and a microscope (AXIO Scope A1, Zeiss, Germany) equipped with a heating stage and a camera (Basler scA780 54fc, Germany). The analysis performed by Sperm Class Analyser® software (SCA® v.6.3.; Microptic S.L., Automatic Diagnostic Systems, Spain) with the following configurations: 4-6 fields were recorded ($\times 100$) for each semen sample, >500 spermatozoa, 25 frames/sec, region of particle control 10-18 microns, progressive movement of $>45\%$ of the parameter STR, circumferential movement $<50\%$ LIN, depth of field 10 μm , and temperature of the microscope plate 37°C . The debris incorrectly identified as spermatozoa were manually removed before final analysis.

For each group, a 10 μl semen sample was placed on the preheated (37°C) Makler chamber (Makler® counting chamber, 10 μm deep, Sefi Medical Instruments, Israel) and the following CASA motility and kinetic parameters were evaluated: 1) total motility; %, 2) progressive motility; %, 3) rapid, medium, slow and static movement spermatozoa ($\text{static} < 10 < \text{slow} < 25 < \text{medium} < 45 < \text{rapid}$ $\mu\text{m}/\text{sec}$); %, 4) VCL-curvilinear velocity; $\mu\text{m}/\text{sec}$, 5) VSL-straight line velocity; $\mu\text{m}/\text{sec}$, 6) VAP-average path velocity; $\mu\text{m}/\text{sec}$, 7) ALH-amplitude of lateral head displacement; μm , 8) BCF-beat/cross-frequency; Hz, 9) LIN-linearity ($\text{VSL}/\text{VCL} \times 100$), 10) STR-straightness ($\text{VSL}/\text{VAP} \times 100$), 11) WOB-wobble ($\text{VAP}/\text{VCL} \times 100$) and 12) hyperactive spermatozoa ($\text{VSL} > 97$ $\mu\text{m}/\text{sec}$, $\text{ALH} > 3.5 \mu\text{m}$, $\text{LIN} < 0.32$); %.

Statistical analysis

The statistical analysis was performed using the Statistical Analysis Systems version 9.3 (SAS Institute Inc., 1996, Cary, N.C., U.S.A.). Normality of the data was tested using the Shapiro-Wilk Test (PROC UNIVARIATE). Parameters that did not follow a normal distribution were normalized by logarithmic transformation. For reasons of clarity the means and SEM of the not transformed data are presented. Statis-

tical analysis was conducted with a repeated measures mixed model (PROC MIXED). The model included group, time and their interaction as fixed effects and boar as a random effect. Semen sample within boar was defined as the subject of the repeated observations. Pairwise comparisons were performed with the PDIF command incorporating the Tukey adjustment. Statistically significant difference was defined as $P < 0.05$.

RESULTS

Casa motility and kinetics

For all the CASA evaluated parameters, there was no difference between groups at 0 h post treatment (Fig. 1; Table 1). Group Fe did not differ from group C at any time point for all the evaluated CASA parameters (Fig. 1; Table 1). Values of total and progressive motility were lower (all $P < 0.001$) at 24 h of storage in group Ag compared to groups C and Fe (Fig. 1). In all nine replicates, semen samples of group Ag were immotile after 48 h of storage (17°C) and thus excluded from analysis. Static spermatozoa decreased after 24 h of storage post treatment in group Ag and after 48 h in groups C and Fe ($P < 0.0001$). The comparison within groups and between storage time points showed that the values of total motility, progressive movement spermatozoa, VCL, ALH (Fig. 1) as well as VAP and BCF (Table 1) were decreased after 24 h of storage post treatment in group Ag (all $P < 0.05$), but not in groups C and Fe. Also, in group C, the values of LIN were lower ($P < 0.0001$) after 24 h and 48 h of storage post treatment, while no differences were observed in the other two groups (Table 1). The remaining parameters did not differ significantly ($P > 0.05$) between successive time points within any group (Table 1).

Table 1. Sperm kinetic parameters (mean \pm SEM) of semen samples evaluated by CASA at 0, 24, 48 h of storage (17° C) post co-incubation (30 min) with nanoparticles.

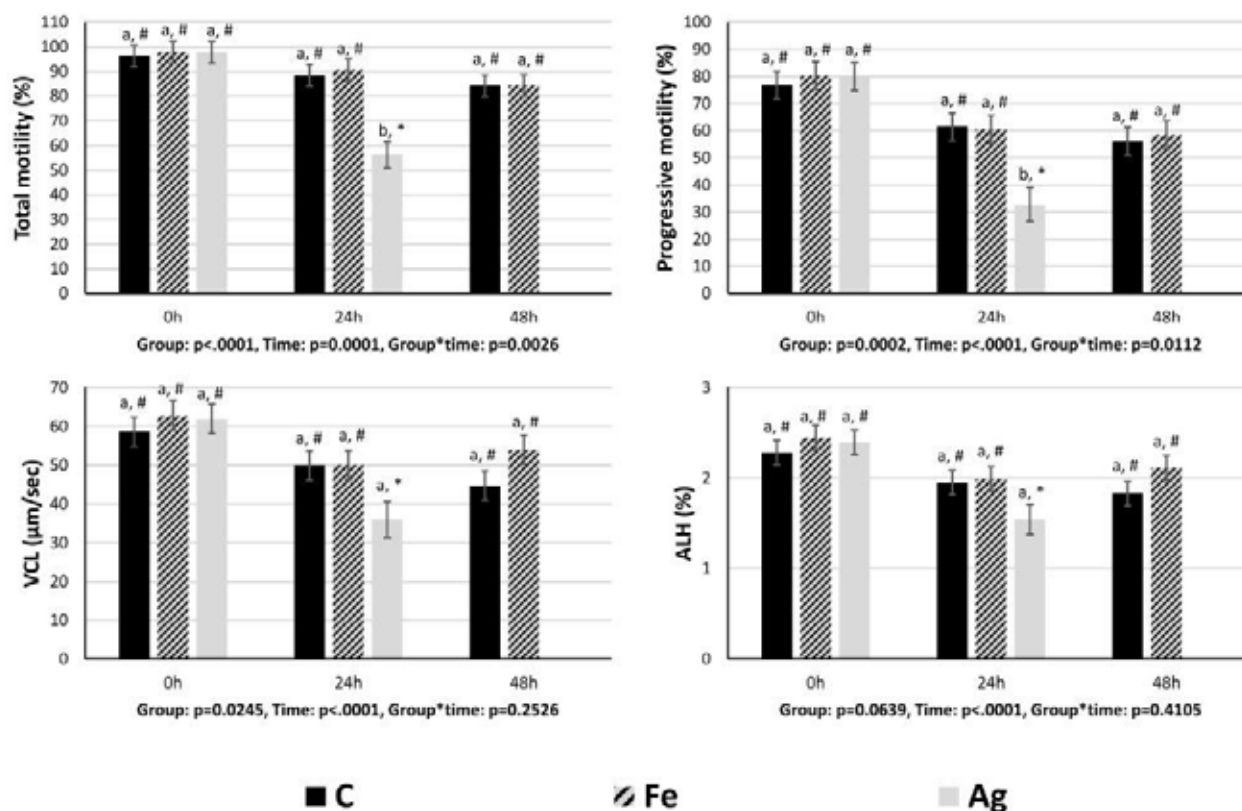
Variable	Group C			Group Fe			Group Ag			P value		
	0h	24h	48h	0h	24h	48h	0h	24h	48h	Group	Time	G*T
Rapid (%)	59.9 \pm 5.4 [#]	43.3 \pm 5.4 [#]	36.6 \pm 5.4 [#]	65.6 \pm 5.4 [#]	42.5 \pm 5.4 [#]	44.5 \pm 5.4 [#]	64.8 \pm 5.4 [#]	21.7 \pm 6.6 [*]	-	0.015	<.0001	0.2163
Medium (%)	24 \pm 2.4 [#]	23.5 \pm 2.4 [#]	24.1 \pm 2.4 [#]	22.6 \pm 2.4 [#]	24 \pm 2.4 [#]	18.3 \pm 2.4 [#]	22.9 \pm 2.4 [#]	14 \pm 2.9 [#]	-	0.0595	0.2051	0.212
Slow (%)	12.3 \pm 2.4 [#]	21.7 \pm 2.4 [#]	23.5 \pm 2.4 [#]	9.5 \pm 2.4 [#]	24.2 \pm 2.4 [*]	21.5 \pm 2.4 [*]	10.1 \pm 2.4 [#]	20.5 \pm 3 [#]	-	0.935	<.0001	0.7937
Static (%)	3.7 \pm 4.4 [#]	11.5 \pm 4.4 ^{**}	15.8 \pm 4.4 [*]	2.2 \pm 4.4 [#]	9.3 \pm 4.4 ^{**}	15.6 \pm 4.4 [*]	2.2 \pm 4.4 [#]	43.8 \pm 4.4 [*]	-	0.0228	<.0001	0.2673
VSL (μm/sec)	26.9 \pm 3 [#]	32.5 \pm 3 [#]	30.4 \pm 3 [#]	27 \pm 3 [#]	29 \pm 3 [#]	34 \pm 3 [#]	28.4 \pm 3 [#]	23.4 \pm 3.6 [#]	-	0.3819	0.2163	0.5629
VAP (μm/sec)	45 \pm 3.7 [#]	32.3 \pm 3.7 [#]	29.6 \pm 3.7 [#]	47.2 \pm 3.7 [#]	34.7 \pm 3.7 [#]	33 \pm 3.7 [#]	47.2 \pm 3.7 [#]	24.2 \pm 4.6 [*]	-	0.157	<.0001	0.7847
BCF (Hz)	5.6 \pm 0.24 [#]	5.2 \pm 0.24 [#]	5.2 \pm 0.24 [#]	5.6 \pm 0.24 [#]	5.2 \pm 0.24 [#]	5.3 \pm 0.24 [#]	5.6 \pm 0.24 [#]	4.2 \pm 0.29 [*]	-	0.0068	0.0046	0.2569
LIN (%)	45.6 \pm 3.2 [#]	55.4 \pm 3.2 [*]	58.6 \pm 3.2 [*]	42.5 \pm 3.2 [#]	52.7 \pm 3.2 [*]	54.6 \pm 3.2 [#]	44.7 \pm 3.2 [#]	52.1 \pm 3.2 [#]	-	0.5195	<.0001	0.9787
STR (%)	54.1 \pm 3.2 [#]	57.2 \pm 3.2 [#]	62.9 \pm 3.2 [#]	51 \pm 3.2 [#]	57 \pm 3.2 [#]	54.5 \pm 3.2 [#]	53.3 \pm 3.2 [#]	59.1 \pm 3.2 [#]	-	0.4228	0.0064	0.7545
WOB (%)	78.2 \pm 2.2 [#]	79.1 \pm 2.2 [#]	78.7 \pm 2.2 [#]	76.9 \pm 2.2 [#]	79.1 \pm 2.2 [#]	76.6 \pm 2.2 [#]	77.8 \pm 2.2 [#]	75 \pm 2.6 [#]	-	0.509	0.0665	0.8752
Hyper. (%)	5.1 \pm 2.7 [#]	3.5 \pm 2.7 [#]	2.5 \pm 2.7 [#]	6.5 \pm 2.7 [#]	5.1 \pm 2.7 [#]	9.5 \pm 2.7 [#]	5.1 \pm 2.7 [#]	0.2 \pm 3.3 [#]	-	0.1656	0.0476	0.6926

Group C: extended semen without any treatment, **Group Fe:** extended semen with Fe₃O₄ NPs (0.192 mg Fe₃O₄/ml semen) and **Group Ag:** extended semen with Ag/Fe NPs (0.128 mg Ag Fe/ml semen).

Rapid: rapid movement spermatozoa (%), **Medium:** medium movement spermatozoa (%), **Slow:** slow movement spermatozoa (%), **Static:** static spermatozoa (%), **VSL:** straight line velocity (μ m/sec), **VAP:** average path velocity (μ m/sec), **BCF:** beat/cross-frequency (Hz), **LIN:** linearity (VSL/VCL x 100), **STR:** straightness (VSL/VAP x 100), **WOB:** wobble (VAP/VCL x 100), **Hyper.:** hyperactive spermatozoa (%).

G*T: Group*Time.

Different symbols (#, *) denote significant differences between evaluation times within a group.

**Figure 1.** Effect of iron oxide (Fe; Fe₃O₄) and silver oxide (Ag; Ag/Fe) nanoparticles on Total and Progressive motility, VCL and ALH of boar spermatozoa at 0, 24, 48 h of storage (17° C) post co-incubation (30 min) with nanoparticles.

Group C: extended semen without treatment, Group Fe: extended semen with Fe₃O₄ NPs of diameter 40 nm (0.192 mg/mL semen), and Group Ag: extended semen with Ag/Fe NPs of diameter 30 nm, consisted of Ag and a 5% of zero-valent Fe (0.128 mg/mL semen). All the values are expressed as mean \pm SEM. Different subscripts (a, b) denote significant differences between groups for each evaluation time point. Different symbols (#, *) denote significant differences between evaluation times within a group.

Characterization of nanoparticles

The morphological characteristics of the tested nanoparticles were studied by transmission electron microscopy (Fig. 2). Iron oxide nanoparticles appear to consist of well-defined spherical units with an aver-

age size around 40 nm. The silver-based nanomaterial shows a higher degree of aggregation in the building units and a wider size distribution with an average around 30 nm.

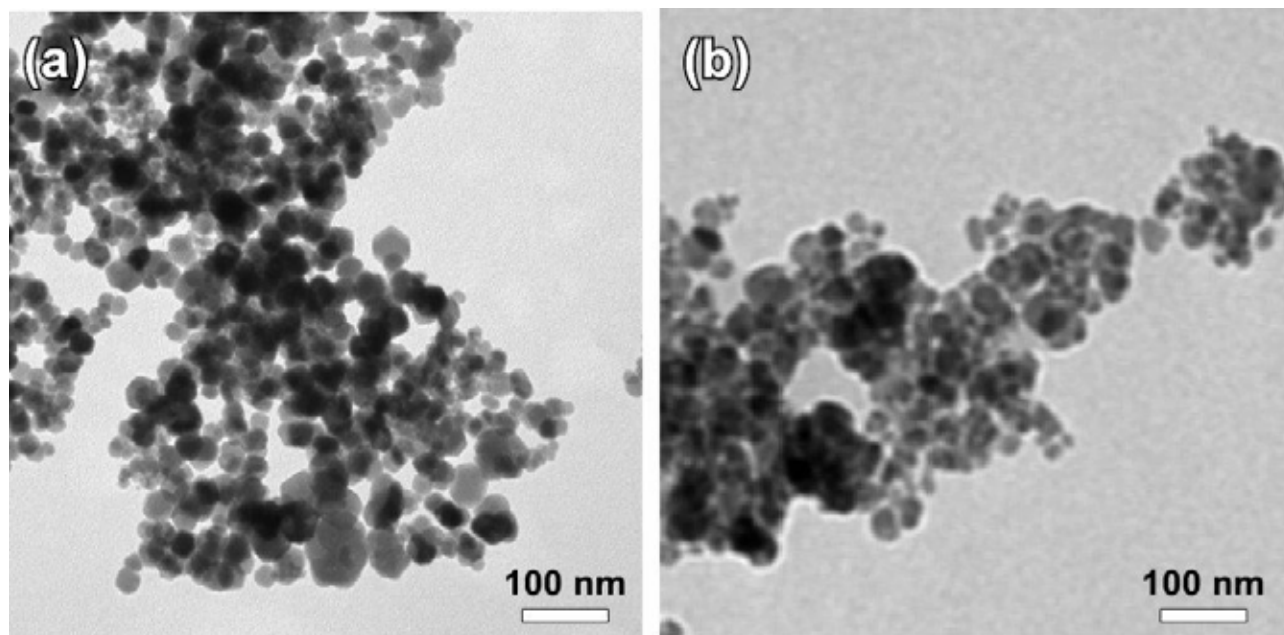


Figure 2. Transmission electron microscopy images of Fe_3O_4 (a) and Ag/Fe (b) nanoparticles.

DISCUSSION

In the present study, we investigated the possible toxic effect of the iron oxide (Fe_3O_4) and silver (Ag/Fe) spherical nanoparticles on boar sperm motility parameters as a first approach before performing further research of their potential use as alternative agents to conventional antibiotics for semen handling.

It is undoubtedly accepted that nanoparticles applications in different fields of modern life have been increasing. However, it is well known that there are potential side effects caused by NPs exposure and their extended use has raised a serious concern about their safety for human and animals' health (Johnston et al., 2010). In *in vivo* trials, it is documented that nanoparticles can penetrate the bloodtestis barrier (Lan and Yang, 2012) and under *in vitro* conditions they may cause necrosis, apoptosis and mitochondrial dysfunction (Braydich-Stolle et al., 2005). Although the toxicity of NPs on reproductive system is well documented in the literature (Ema et al., 2010), a lot of studies examined a variety of them, like iron oxide (Özgür et al., 2018), silver (Asare et al., 2012), gold (Moretti et al., 2013), zinc oxide (Barkhordari et al., 2013) under *in vitro* or *in vivo* conditions provid-

ing contradictory results and conclusions about their toxic effect on sperm (Braydich-Stolle et al., 2005) or their beneficial use for semen handling (Durfey et al., 2019; Özgür et al., 2018). Specifically, concerning the iron oxide NPs on sperm quality, according to Özgür et al., (2018), the Rainbow trout spermatozoa were exposed to magnetite (Fe_3O_4) NPs over 24 h and the values of VCL, VSL and VAP decreased, while the intraperitoneally administration of maghemite ($\gamma\text{-Fe}_2\text{O}_3$) NPs decreased the motility and kinetic parameters of mouse epididymal spermatozoa (Varzeghani et al., 2018). However, in our study the iron oxide (Fe_3O_4) NPs interacted with spermatozoa for 30 min and were carefully removed through a magnetic field. This restricted period of sperm co-incubation with NPs as well as the different kind of NPs and species may excuse the different results. Some reports also enhance the hypothesis that the time of interaction may be involved in NPs potential toxic activity. Specifically, the iron oxide (Fe_2O_3) NPs used for sperm purification of boar and bovine insemination doses did not provide any toxicity to purified spermatozoa, while the fertilizing capacity of nanopurified semen used for artificial insemination was not affected (Feugang et al., 2014; Odhiambo et al., 2014). Also, the Fe_3O_4

NPs coated with lectins and annexin V were used for boar semen selection without providing any toxic effect (Durfey et al., 2019, 2017). Although the experimental approach of the present study is different, our results are interestingly in accordance with the previous mentioned studies and demonstrated that the examined iron oxide spherical NPs interacting with spermatozoa for a short period of time had no negative effect on boar semen CASA motility parameters.

Silver NPs are very popular among others NPs and have been widespread explored for human biomedical applications, drug delivery systems, dental applications, wound healing, and catheters compartments thanks to their interesting chemical, physical and biological/antimicrobial action related to their tiny size (Burduşel et al., 2018) without providing adverse effects to healthy cells (Stensberg et al., 2011). However, their extended use warrants their potential toxicity assessment during the last decades. The available data reported that they can negatively affect the physiological function and structure of organs (Lin et al., 2017; Ribeiro et al., 2018), while there are controversial results about their toxicity on male reproductive system (Asare et al., 2012; Garcia et al., 2014; Terzuoli et al., 2012). Taking into account that human is constantly exposed to silver NPs and the social impact of human fertility capacity, the reported *in vivo* and *in vitro* studies focus mainly on human (Terzuoli et al., 2012) or on animals' experimental models examining either a time or dose effect of NPs as well as a possible interference of their size (Gromadzka-Ostrowska et al., 2012). The results of the present study demonstrated a harmful effect of the examined silver NPs on CASA motility parameters of boar semen. Although no detrimental effect on group Ag was observed at 0 h post NPs removal, the values of total motility, progressive movement spermatozoa, VCL, VAP, ALH, and BCF were lower at 24 h and interestingly, the spermatozoa of group Ag were immotile 48 h post NPs removal. In accordance with the results of our study, Terzuoli et al., (2012) observed that human sperm motility decreased after 60- and 120-min of co-incubation even at the lowest concentration of the used Ag NPs. On the contrary, Garcia et al., (2014) found that the intravenously administration of Ag NPs had no negative effect on CASA parameters of mice semen, even though the values of VSL, VCL, VAP, ALH, STR were lower 60 days post administration but these differences were not statistically significant. Also, Moretti et al., (2013) did not find any harmful effect of Ag NPs in low concentrations post co-incubation, but a dose de-

pended NPs' effect was observed on sperm motility. Surprisingly, in a preliminary study (data not shown), we found that there was a decrease in sperm motility even after 45 min of co-incubation of boar sperm with Ag NPs, while according to Tiedemann et al., (2014) when boar semen was *in vitro* supplemented with Ag NPs, no negative effect on CASA motility parameters was observed even 120 min post co-incubation. These contradictory findings could be attributed to the different synthesis, size, shape, or even the concentration of the administered NPs which could affect their properties, as well as their action on cells. It is well documented that there is a size depended and dose depended adverse effect of NPs on sperm quality and testis health (Gromadzka-Ostrowska et al., 2012; Terzuoli et al., 2012). Moreover, it has been observed that when NPs are coated with other molecules like annexin V, lectins (Durfey et al., 2017), BSA (Grade et al., 2012) their potential toxic effect could be alleviated as well as the cell culture media composition could reduce or enhance their cytotoxic action (Grade et al., 2012).

CONCLUSIONS

In conclusion, under the experimental conditions of the present study the Ag/Fe NPs exerted a harmful effect on boar spermatozoa motility and kinetic parameters evaluated by CASA, while the used concentration of Fe_3O_4 NPs did not affect boar sperm CASA parameters revealing a need for further research about their applications on semen processing. Also, it is necessary to investigate further their effect on boar spermatozoa by assessing more sperm quality and functional parameters, as well as their antimicrobial potential by microbiological cultures.

ACKNOWLEDGEMENTS

This research is co-financed by Greece and the European Union (European Social Fund - ESF) through the Operational Programme Human Resources Development, Education and Lifelong Learning 2014-2020 in the context of the project "Investigation of nanotechnological applications on farm animals' semen processing" (MIS 5004681)".

CONFLICT OF INTEREST

No conflict of interest is declared by the authors.

REFERENCES

- Afifi M, Almaghrabi OA, Kadasa NM (2015) Ameliorative Effect of Zinc Oxide Nanoparticles on Antioxidants and Sperm Characteristics in Streptozotocin-Induced Diabetic Rat Testes. *Biomed Res. Int.*:16.
- Akhter S, Ansari MS, Andrabi SMH, Ullah N, Qayyum M (2008) Effect of antibiotics in extender on bacterial and spermatozoal quality of cooled buffalo (*Bubalus bubalis*) bull semen. *Reprod. Domest. Anim.* 43:272278.
- Althouse GC, Kuster CE, Clark SG, Weisiger RM (2000) Field investigations of bacterial contaminants and their effects on extended porcine semen. *Theriogenology* 53:11671176.
- Asare N, Instanes C, Sandberg WJ, Refsnes M, Schwarze P, Kruszewski M, Brunborg G (2012) Cytotoxic and genotoxic effects of silver nanoparticles in testicular cells. *Toxicology* 291:6572.
- Azam A, Ahmed AS, Oves M, Khan MS, Habib SS, Memic A (2012) Antimicrobial activity of metal oxide nanoparticles against Gram-positive and Gram-negative bacteria: a comparative study. *Int. J. Nanomedicine* 7:60039.
- Azawi OI, Ismael MA (2012) Influence of addition of different antibiotics in semen diluent on viable bacterial count and spermatozoal viability of Awassi ram semen. *Vet. World* 5:7579.
- Babes L, Denizot B, Tanguy G, Le Jeune JJ, Jallet P (1999) Synthesis of iron oxide nanoparticles used as MRI contrast agents: A parametric study. *J. Colloid Interface Sci.* 212:474482.
- Barkalina N, Jones C, Kashir J, Coote S, Huang X, Morrison R, Townley H, Coward K, (2014) Effects of mesoporous silica nanoparticles upon the function of mammalian sperm in vitro. *Nanomedicine Nanotechnology, Biol. Med.* 10:859870.
- Barkhordari A, Hekmatimoghaddam S, Jebali A, Khalili MA, Talebi A, Noorani M (2013) Effect of zinc oxide nanoparticles on viability of human spermatozoa. *Iran. J. Reprod. Med.* 11:767771.
- Braydich-Stolle L, Hussain S, Schlager JJ, Hofmann MC (2005) In vitro cytotoxicity of nanoparticles in mammalian germline stem cells. *Toxicol. Sci.* 88:412419.
- Burdusel AC, Gherasim O, Grumescescu AM, Mogoantă L, Ficai A, Andronescu E (2018) Biomedical Applications of Silver Nanoparticles: An Up-to-date Overview. *Nanomaterials* 8.
- Chaloupka K, Malam Y, Seifalian AM (2010) Nanosilver as a new generation of nanoparticle in biomedical applications. *Trends Biotechnol.* 28:580588.
- Durfey CL, Burnett DD, Liao SF, Steadman CS, Crenshaw MA, Clemente HJ, Willard ST, Ryan PL, Feugang JM (2017) Nanotechnology-based selection of boar spermatozoa: growth development and health assessments of produced offspring. *Livest. Sci.* 205:137142.
- Durfey CL, Swistek SE, Liao SF, Crenshaw MA, Clemente HJ, Thirumalai RVKG, Steadman CS, Ryan PL, Willard ST, Feugang JM (2019) Nanotechnology-based approach for safer enrichment of semen with best spermatozoa. *J. Anim. Sci. Biotechnol.* 10:14.
- Ema M, Kobayashi N, Naya M, Hanai S, Nakanishi J (2010) Reproductive and developmental toxicity studies of manufactured nanomaterials. *Reprod. Toxicol.* 30:343352.
- Falchi L, Galleri G, Dore GM, Zedda MT, Pau S, Bogliolo L, Ariu F, Pinna A, Nieddu S, Innocenzi P, Ledda S (2018) Effect of exposure to CeO₂ nanoparticles on ram spermatozoa during storage at 4 °C for 96 hours. *Reprod. Biol. Endocrinol.* 16:19.
- Feugang J, Liao S, Crenshaw M, Clemente H, Willard S, Ryan P (2015) Lectin-functionalized magnetic iron oxide nanoparticles for reproductive improvement. *JFIV Reprod Med Genet.* 3:17-19.
- Garcia TX, Costa GMJ, França LR, Hofmann MC (2014) Sub-acute intravenous administration of silver nanoparticles in male mice alters Leydig cell function and testosterone levels. *Reprod. Toxicol.* 45:5970.
- Grade S, Eberhard J, Neumeister A, Wagener P, Winkel A, Stiesch M, Barcikowski S, (2012) Serum albumin reduces the antibacterial and cytotoxic effects of hydrogel-embedded colloidal silver nanoparticles. *RSC Adv.* 2:71907196.
- Gromadzka-Ostrowska J, Dziendzikowska K, Lankoff A, Dobrzyńska M, Instanes C, Brunborg G, Gajowik A, Radzikowska J, Wojewódzka M, Kruszewski M (2012) Silver nanoparticles effects on epididymal sperm in rats. *Toxicol. Lett.* 214:251258.
- Gyles C (2011) The growing problem of antimicrobial resistance. *Can. Vet. J. La Rev. Vet. Can.* 52:817820.
- Hajipour MJ, Fromm KM, Ashkarran AA, de Aberasturi DJ, de Larramendi IR, Rojo T, Serpooshan V, Parak WJ, Mahmoudi M (2012) Antibacterial properties of nanoparticles. *Trends in biotechnology* 30:499-511.
- Johnston HJ, Hutchison G, Christensen FM, Peters S, Hankin S, Stone V (2010) A review of the in vivo and in vitro toxicity of silver and gold particulates: Particle attributes and biological mechanisms responsible for the observed toxicity. *Crit. Rev. Toxicol.* 40:328346.
- Karageorgiou MA, Tsousis G, Boscos CM, Tzika ED, Tassis PD, Tsakmakidis IA (2016) A comparative study of boar semen extenders with different proposed preservation times and their effect on semen quality and fertility. *Acta Vet Brno.* 85:23-31.
- Lafuente D, Garcia T, Blanco J, Sánchez DJ, Sirvent JJ, Domingo JL, Gómez M (2016) Effects of oral exposure to silver nanoparticles on the sperm of rats. *Reprod. Toxicol.* 60:133139.
- Lan Z, Yang WX (2012) Nanoparticles and spermatogenesis: How do nanoparticles affect spermatogenesis and penetrate the blood-testis barrier. *Nanomedicine.* 7:579596.
- Lemire JA, Harrison JJ, Turner RJ (2013) Antimicrobial activity of metals: mechanisms, molecular targets and applications. *Nat. Rev. Microbiol.* 11:371384.
- Lin CX, Yang SY, Gu JL, Meng J, Xu HY, Cao JM (2017) The acute toxic effects of silver nanoparticles on myocardial transmembrane potential, I_{Na} and IK1 channels and heart rhythm in mice. *Nanotoxicology* 11:827837.
- Moretti E, Terzuoli G, Renieri T, Iacoponi F, Castellini C, Giordano C, Colodel G, (2013) In vitro effect of gold and silver nanoparticles on human spermatozoa. *Andrologia* 45:392396.
- Odhiambo JF, DeJarnette JM, Geary TW, Kennedy CE, Suarez SS, Sutovsky M, Sutovsky P (2014) Increased Conception Rates in Beef Cattle Inseminated with Nanopurified Bull Semen1. *Biol. Reprod.* 91.
- Özgür M, Ulu A, Balcioglu S, Özcan İ, Köytepe S, Ateş B, Özgür ME, Ulu A, Balcioglu S, Özcan İ, Köytepe S, Ateş B (2018) The Toxicity Assessment of Iron Oxide (Fe₃O₄) Nanoparticles on Physical and Biochemical Quality of Rainbow Trout Spermatozoon. *Toxics* 6:62.
- Raana J, Parisa Y, Mehdi AA, Abdollah MS, Hamid V, Mohammad C, Hasan NM, Reza BM (2015) Effect of zinc nano-complex on bull semen quality after freeze-thawing process. *J. Anim. Prod. (Journal Agric.)* 17:371380.
- Rai M, Yadav A, Gade A (2009) Silver nanoparticles as a new generation of antimicrobials. *Biotechnol. Adv.* 27:7683.
- Ribeiro APC, Anbu S, Alegria ECBA, Fernandes AR, Baptista PV, Mendes R, Matias AS, Mendes M, Guedes da Silva MFC, Pombeiro AJL (2018) Evaluation of cell toxicity and DNA and protein binding of green synthesized silver nanoparticles. *Biomed. Pharmacother.* 101:137144.
- Safa S, Moghaddam G, Jozani RJ, Daghighi Kia H, Janmohammadi H (2016) Effect of vitamin E and selenium nanoparticles on post-thaw variables and oxidative status of rooster semen. *Anim. Reprod. Sci.* 174:100106.
- Salamon S, Maxwell WM (2000) Storage of ram semen. *Anim. Reprod. Sci.* 62:77111.
- Salata O (2004) Applications of nanoparticles in biology and medicine. *J. Nanobiotechnology* 2:3.
- Stensberg MC, Wei Q, McLamore ES, Porterfield DM, Wei A, Sepúlveda MS (2011) Toxicological studies on silver nanoparticles: Challenges and opportunities in assessment, monitoring and imaging. *Nanomedicine.* 6:879898.
- Terzuoli G, Iacoponi F, Moretti E, Renieri T, Baldi G, Collodel G (2012) In vitro effect of silver engineered nanoparticles on human spermatozoa. *J. Siena Acad. Sci.* 3:27.
- Tiedemann D, Taylor U, Rehbock C, Jakobi J, Klein S, Kues WA, Barcikowski S, Rath D (2014) Reprotoxicity of gold, silver, and gold-silver alloy nanoparticles on mammalian gametes. *Analyst* 139:931942.
- Varner DD, Scanlan CM, Thompson JA, Brumbaugh GW, Blanchard TL, Carlton CM, Johnson L (1998) Bacteriology of preserved stallion semen and antibiotics in semen extenders. *Theriogenology* 50:559573.
- Varzeghani SM, Parivar K, Abdollahifard M, Karamian A (2018) Effects of Iron Oxide Nanoparticles on Mouse Sperm Parameters and Testicular Tissue, Iranian Journal of Toxicology. *Iranian Journal of Toxicology.* 12:3944.
- Wiwantitk V, Sereemasun A, Rojanathanes R (2009) Effect of gold nanoparticles on spermatozoa: the first world report. *Fertil. Steril.* 91:e7.

Biochemical composition and biometric parameters of *Mytilus galloprovincialis* from Boka Kotorska Bay in Southern Adriatic Sea

N. Grković^{*1}, V. Teodorović¹, V. Djordjević², N. Karabasil¹, S. Stajković¹, D. Vasilev¹,
I. Zuber Bogdanović³, S. Janković², B. Velebit², M. Dimitrijević¹

¹Department of Food Hygiene and Technology, Faculty of Veterinary Medicine, University of Belgrade, Serbia

²Institute of Meat Hygiene and Technology, Belgrade, Serbia

³Specilist Veterinary Laboratory, Podgorica, Montenegro

ABSTRACT: This study reports, for the first time, different physico-chemical analyses, of Mediterranean mussels (*Mytilus galloprovincialis*) from harvesting areas in the Montenegro coast of the Adriatic Sea, in order to evaluate the influence of origin on different parameters and assessed the quality of shellfish grown in this area. The Boka Kotorska Bay is situated in Montenegro, in the south-eastern part of the Adriatic Sea. The mussel samples were collected at the same time in the spring of 2019 at six locations in Boka Kotorska Bay, Montenegro: Kotor and Tivat Bays. Biometric parameters, percentage of meat, condition index, proximate composition, sensory evaluation and lipid profiles of mussels were studied. The concentrations of some micro and macro elements and heavy metals in mussels, were also analyzed. Significant differences were found between mussels from different locations. Mean biometric parameters of mussels grown in Sv. Nedjelja, were considerably higher than in mussels grown elsewhere. Protein, lipid, ash and glycogen content were varied from 7.80 to 10.26%; 1.36 to 2.18%; 1.73 to 3.34% and 12.81 to 15.38%, respectively. Gas chromatographic analysis showed that polyunsaturated fatty acids (PUFAs) were dominant lipids in mussels (37.56 to 41.08%), followed by monounsaturated (MUFAs) (30.52 to 38.31%) and saturated (SFAs) (21.89 to 29.45%) fatty acids. Fatty acid profiles were investigated and revealed high contents of n-3 PUFAs and high n-3/n-6 ratios in all mussels from Montenegro. In the mussel samples high concentrations of K, Mg, Ca, and Na, and much lower concentrations of Fe, Mn, Zn, and Cu were found. Some of toxic elements (As, Pb, Hg and Cd) were determined also. The qualitative sensory assessment showed that all mussels were acceptable. All mussels in the current study achieved scores of 3 or more out of 5 in the qualitative category. Data on biochemical composition and quality indices of the mussels cultured in the Boka Kotorska Bay demonstrated that these products could be accepted well by consumers and could compete with other currently available mussels from other locations in Adriatic Sea.

Keywords: *Mytilus galloprovincialis*, proximate composition, fatty acids, heavy metals, Adriatic Sea

Corresponding Author:

Nevena Grkovic, Department of Food Hygiene and Technology,
Faculty of Veterinary Medicine, University of Belgrade, Serbia
E-mail address: nevena.ilic@vet.bg.ac.rs

Date of initial submission: 15-11-2019
Date of revised submission: 26-04-2020
Date of acceptance: 19-05-2020

INTRODUCTION

The popularity of seafood has increased over recent decades, and this food source is becoming increasingly necessary for the growing population of people on the planet (Grienke et al., 2014). In coastal parts of Montenegro, the harvesting and cultivation of marine organisms dates back centuries. Today, Montenegro has limited mussel production, with relatively low commercial demand and value, despite intensive tourism. A specific national mariculture development plan has yet to be developed. However, because of favorable hydrographic conditions in this part of Montenegro coast, there is significant potential for development of aquaculture. Currently there are 19 small mussel farms in Montenegro, each producing 5 to 30 tonnes per year, and these are all situated in Boka Kotorska Bay. During the period of 2013–2015, the average annual production of *Mytilus galloprovincialis* was 182 tonnes respectively (Macic, 2005).

Bioactive compounds present in the flesh of seafood, and which have positive effects on human health, also contribute to the popularity of this food (Grienke et al., 2014). Bivalve molluscs are considered to be highly nutritive, as they are a rich source of proteins, carbohydrates, minerals and provide an almost unlimited variety of fatty acids (FAs), primarily highly valuable polyunsaturated fatty acids (PUFAs) (Bongiorno et al., 2015). The contents of Na, Mg, K and Ca were noticeably higher than those reported

for Spanish and Italian mussels (Fuentes et al., 2009; Bongiorno et al., 2015). As the Montenegrin coastal area, especially the Boka Kotorska Bay, receives a heavy influx of sewage and industrial effluents, as well as domestic and agricultural wastes (Jovic et al., 2011), the determination of the levels of trace metals, especially those of potentially toxic metals (Hg, Pb, Cd), in mussels is very important. The Boka Kotorska Bay is known as one of the regions in Europe with the highest amount of precipitation, and so the quantity of pollutants reaching the sea from this source cannot be neglected as an adverse factor in aquaculture (Jovic et al., 2011). Quality analysis of mussels from various sites could show the importance of differing sites for shellfish cultivation, because seawater is a complex geomorphological matrix. Several environmental factors can affect the overall quality of mussels in terms of microbiological, nutritional, technological and sensory characteristics (Vernocchi et al., 2007). In this study we compared the biochemical composition of mussels cultured at six most productive harvesting areas, three in Tivat Bay and three in Kotor-Risan Bay, with the aim of investigating if shellfish composition varied with location of the culture units. The study aims to provide new biological information for the potential development of aquaculture species in Montenegro, and to compare the quality of mussels from the Montenegrin aquatorium with mussels that is harvesting on other coast of the Adriatic Sea.

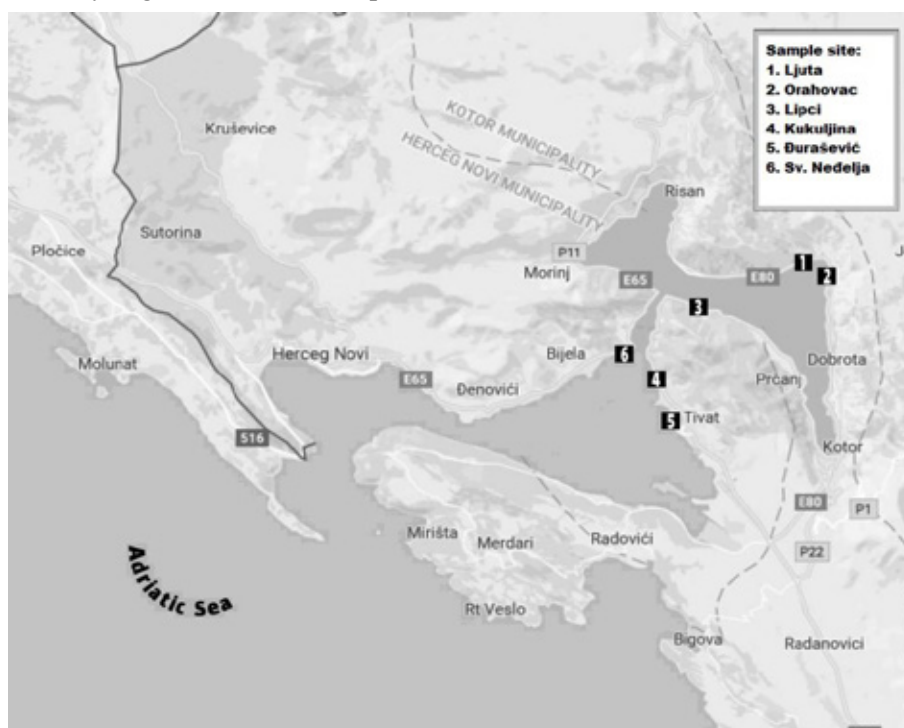


Figure 1. Sampling sites on the Boka Kotorska Bay, Montenegro (Ilic et al., 2017)

MATERIALS AND METHODS

Study site and mussel sampling

The mussels samples were collected in the same time in April 2019, from six commercial sampling sites in Bokotorska Bay: Ljuta, Orahovac, Lipci, Kukuljina, Obala Djurasevic and Sv. Nedjelja (Fig.1). The sampling sites are influenced by different hydrological characteristics of the Boka Kotorska Bay. Ljuta, Orahovac and Lipci are located in Kotor Bay, and Kukuljina, Obala Djurasevic and Sv. Nedjelja in Tivat Bay, which is under the influence of the open sea. At each sampling site, mussels were manually collected at a depth of approximately 2 m, using standard commercial protocols (Official Gazette of Montenegro, 2009). Samples were washed, placed in nylon bags with seawater and immediately transported to the laboratory. The sampling of seawater was also performed using Niskin bottles, volume of 5 l, at a depth of 0.5 m at same mussel sampling sites. Water temperatures and salinity were measured by automatic probes (Multiline 4, WTW, Germany).

Biometric parameters, meat yield, Condition index

Biometric parameters were assessed only from samples of commercial size (≥ 50 mm) (Ljuta, $n = 39$; Orahovac, $n = 34$; Lipci, $n = 40$; Kukuljina, $n = 38$; Obala Djurasevica, $n = 34$; Sv. Nedjelja, $n = 35$ mussels). Mussels were measured individually using a 0.05 mm precision calliper for the following size parameters: length (maximum measure along the anterior-posterior axis), width (maximum lateral axis), and height (maximum dorso-ventral axis). For each mussel, the total wet weight (g) was measured to the nearest 0.001 g, after which the meat was carefully dissected away from the shell.

Meat yield (MY), i.e. the percentage ratio between meat content (WT) and total wet weight of mussels (WW) is an important aspect of marketability of mussels and was calculated according to Okumus and Stirling (1998) as follows:

$$MY (\%) = (\text{meat weight (g)} / \text{whole mussel weight (g)}) \times 100$$

After the determination of individual total weight and wet meat and shell weights, we were registered meat and shell weights after oven-drying (105 °C). Condition index (CI) was calculated according to Orban et al. (2002) as follows:

$$CI (\%) = (\text{meat dry weight (g)} / \text{shell dry weight (g)}) \times 100.$$

Water activity and pH measurement

All the measurements were performed using the whole soft body of the mussels. The pH of homogenized mussel meat (around 100g of meat from one sampling site) was determined using a pH meter (Testo 205; Testo AG, Lenzkirch, Germany). The water activity (a_w) was measured with a a_w meter (aw-Wert Messer, Fa-St/1; GBX Scientific Instruments, Tal-laght, Ireland).

Chemical composition

Samples of the soft parts obtained from suitable pools of individual mussels were analysed for chemical composition. Twenty individuals from each batch/origin were dissected and minced in a food processor (IKAR M 20 universal mill, IKA 1603601; IKA, Germany) and subjected to biochemical characterization. Proximate composition was determined in triplicate. Moisture and ash were determined gravimetrically. Briefly, minced tissue pools (3g) were placed in pre-weighed porcelain trays for drying at 80°C for 24 h and then weighed to the nearest 0.001 g. Subsequently, dried mussel tissue was ashed at 450°C for 4 h in a muffle furnace.

Total protein was determined according to the Kjeldahl method (AOAC, 1997) from the nitrogen concentration of mussel. Because the Kjeldahl method does not measure the protein content directly a conversion factor (F) is needed to convert the measured nitrogen concentration to a protein concentration. A conversion factor of 6.25 (equivalent to 0.16 g nitrogen per gram of protein) is used to calculate total proteins in mussels.

Glycogen content (mg g^{-1} of wet weight) was measured by colorimetric reaction using 25 μL of prepared minced mussel meat. KOH (30%) was added to 0.5 g of homogenized mussels' tissue (ratio 2:1), then they were heated in a shaking-water bath (100 °C/ 20 min) vortexed for 30 s and subsequently chilled on ice for 5 min. Then, in each sample was added 200 μL of 95% ethanol and 1.2 mL of lukewarm water. Volumes (10 μL) of 80% aqueous phenol and 200 μL of sulphuric acid were added to the mussel meat in 96-well plates. Absorbance was measured using a multi-detection microplate reader (Synergy HT, BIO-TEK) at 490 nm. Glycogen concentration was calculated based on a mussel glycogen standard (Sigma, Saint Louis, MO) following the methodology reported by GALLARDI et al. (2014). The Total lipids (TL) were extracted from the mussel meat (2g) by accelerated solvent ex-

traction (ASE 200, Dionex, Sunnyvale, CA) with a mixture of n-hexane and isopropanol (60:40, v/v) in 33 ml extraction cell at 100°C and nitrogen pressure of 10.3 MPa (Spiric et al., 2010). The solvent was removed under a nitrogen stream at 50°C until dryness in a solvent evaporator (SE 500, Dionex, Sunnyvale, CA). The fat extract was further used for fatty acid determination. Total lipids were further converted to fatty acid methyl esters (FAMES) by using 0.25 M trimethylsulfonium hydroxide (TMSH) in methanol (EN ISO 5509:2000). FAMES were determined by capillary gas chromatography using a GC Shimadzu 2010 (Kyoto, Japan) equipped with flame ionization detector and capillary HP-88 column (100 m x 0.25 mm x 0.20 µm, J&W Scientific, USA). Separation and detection were performed under the following temperature program: initial temperature 125 °C, rate 10 °C min⁻¹ to 175 °C, hold 10 min, rate 5 °C min⁻¹ to 210 °C, hold 5 min, rate 2 °C min⁻¹ to final temperature of 230 °C, hold 12 min. Total analysis time was 50.5 min. The injector and detector temperatures were 250 °C and 280 °C, respectively; split ratio 1:50; volume 1 µL; carrier gas, N₂, 1.33 m min⁻¹; make-up gas, N₂, 30 ml min⁻¹; detector gases, H₂, 40 ml min⁻¹; synthetic air, 400 ml min⁻¹. The chromatographic peaks in the samples were identified by comparing relative retention times of FAME peaks with peaks in Supelco 37 Component FAME mix standard (Supelco, Bellefonte, USA).

Concentration of micro and macro elements were determined by inductively coupled plasma-mass spectrometry (ICP-MS) after digestion of the minced mussel meat. The instrumentation employed for pre-treatment of minced mussel meat was the microwave digestion system Start D, Milestone (Soriso, Italy). Minced mussel meat was prepared as follows: about 0.5 g homogenized minced mussel meat was weighed into a teflon digestion vessel and then 5 ml of nitric acid and 1.5 ml of hydrogen peroxide were added. The digestion vessels were closed and heated in the microwave oven using a preselected program (5 minutes from room temperature to 180°C, 10 minutes at 180°C). After cooling (20 minutes) the digests were quantitatively transferred using deionised water into 100 ml polypropylene volumetric flasks. Digests were then filtered through syringe-nylon filters into polypropylene autosampler cuvettes and used for determination of elements.

During ICP-MS, simultaneously with the samples, a working solution of internal standard was intro-

duced into the system. The internal standard included low, middle and high mass elements. Based on the recorded values (i.e. according to the percentage of intensity reduction or increase) of the internal standard, the software performed an automatic correction of the obtained concentration of elements in the minced mussel tissue digests. Calculation of the content of elements in the minced mussel tissue digests was done by the software, taking into account the equation of the calibration formula for each element, the mass of the minced tissue and the total dilution, as well as the correction based on the internal standards. In accordance with the instructions for handling the ICP-MS device, before each readout of the concentration of elements in the minced mussel tissues, and using the basic calibration solution (Tune B), the instrument parameters were automatically adjusted to meet the specified criteria, after which the instrument was ready for operation. Quality control was carried out by analyzing the certified reference material NIST 1577c. Values determined were in agreement with the certified values (data not shown).

Sensory analyses

Sensory analysis sessions were performed in a sensory analysis room compliant with ISO 8587:2006. They were conducted using six panellists who had experience with seafood. In sensory evaluations, appearance, odor, texture and elasticity of raw mussels were assessed. The sensory analysis conducted on fresh mussel samples. Eighteen individual mussels were randomly selected from each batch of different origin. Prior to the evaluation, mussels were washed with cold water and scrubbed in order to remove debris and any remaining byssal thread, and then they were stored on ice. Three raw mussels of each batch were manually shucked, immediately before testing and presented to each panellist in a white, plastic plate labelled with a 3-digit random number. Sensory evaluations were conducted using a 5-point scale (0-5), where a score of 5 was defined as excellent (Caglak et al., 2008). All the panellists were allowed into the room together and had unlimited time to complete the testing.

Statistical analysis

Statistical analysis of the results was conducted using software GraphPad Prism version 7.00 for Windows, GraphPad Software, San Diego CA, USA, www.graphpad.com. All parameters were described by descriptive statistics (mean ± standard deviation).

Data were subjected to one-way ANOVA to test significant differences for various traits. Assumptions of normality and homogeneity of variances were tested prior to ANOVA with Shapiro – Wilk and D'Agostino-Pearson test, respectively.

RESULTS

Biometric parameters, MY, CI, pH and aW values

The mussels from Lipci were statistically smaller in ($p < 0.05$) length (51.05 ± 3.10 mm), height (28.9 ± 2.06 mm) and width (19.83 ± 1.68 mm) compared with the mussels from the other sites. Conversely, mussels from Sv. Nedjelja displayed significantly higher morphometric values than others, as their average length was 56.19 ± 4.79 mm, height 32.40 ± 2.45 mm and width 22.37 ± 2.22 mm (Table 1). Meat yield ranged from $20.89 \pm 6.41\%$ in Ljuta to $26.39 \pm 7.93\%$ in Obala Djurasevic. The differences between the meat yield and condition index (CI) of mussels from Obala Djurasevic were statistically significant ($p < 0.05$) compared to mussels from the other locations. No significant differences ($p > 0.05$) were found in CI between Lipci and Sv. Nedjelja mussels in spite of the differences found in shell morphology (Table 1). There were no significant differences ($p > 0.05$) in the pH and aW values of mussels from the six sites, ranging from 7.0 to 7.2 and from 0.96 to 0.97, respectively.

Proximate composition of mussels

Significantly higher ash and protein levels in mus-

sels were detected in Orahovac and Sv. Nedjelja areas compared to the other ones. Mussel tissue protein content ranged from 7.80 in mussels from Ljuta to 10.26% in mussels from Orahovac. Mussels from Kotor Bay (Ljuta and Lipci) showed higher moisture values than mussels from Tivat Bay. Lipid contents did not show any significant differences between mussel from the different areas. Finally, glycogen levels ($15.11 \text{ mg} \cdot \text{g}^{-1}$ and $15.38 \text{ mg} \cdot \text{g}^{-1}$ in mussels from Orahovac and Sv. Nedjelja, respectively) were slightly higher, although differences were not statistically significant ($p < 0.05$) (Table 2.). The polyunsaturated fatty acids (PUFA) predominated over the monounsaturated fatty acid (MUFA) and saturated fatty acids (SFA). Significant differences in the PUFA profile were found between mussel from Sv. Nedjelja and mussels from other location. Palmitic acid (16:0), the major SFA in mussels, was clearly predominant in all samples. With regard to PUFA, a high proportion of n-3 long-chain PUFAs was found, and eicosapentaenoic (20:5 n-3) and docosahexaenoic (22:6 n-3) acids were the most important FAs in this fraction. High levels of n-3 PUFA ($18.62 \pm 2.32\%$ to $25.75 \pm 2.2\%$), low levels of n-6 PUFA ($2.86 \pm 0.17\%$ to $3.38 \pm 0.14\%$) and high n-3/n-6 ratios (5.70 ± 1.41 to 8.99 ± 1.33) characterized all sample of mussels from Bokokotoska Bay (Table 3.). Metal concentrations, of the investigated micro and macro elements and heavy metals in mussels taken at six locations, expressed in mg/kg are listed in Table 4. All mussel samples are a rich source of the macrominerals Ca, K, Na, Mg and essential elements Fe and Mn.

Table 1. Biometric characteristic, meat yields and Condition index of mussels (*Mytilus galloprovincialis*) from six different location in Boka Kotorska Bay.

	Ljuta	Orahovac	Lipci	Kukuljina	Obala Djurasevic	Sv.Nedjelja
L (mm)	53.29 ± 2.07^A	54.10 ± 3.27^B	51.05 ± 3.10^C	53.92 ± 3.91^{BD}	53.89 ± 4.32^{BE}	56.19 ± 4.79^F
H (mm)	30.10 ± 2.23^A	30.89 ± 2.32^B	28.9 ± 2.06^C	30.51 ± 3.47^{BD}	30.62 ± 3.76^{BE}	32.40 ± 2.45^F
W (mm)	21.21 ± 1.53^A	21.75 ± 1.62^B	19.83 ± 1.68^C	21.29 ± 2.65^{AF}	21.51 ± 2.42^{BDF}	22.37 ± 2.22^E
MY (%)	20.89 ± 6.41^A	21.95 ± 5.11^B	23.01 ± 6.76^C	22.80 ± 5.74^{CD}	26.39 ± 7.93^E	21.68 ± 6.46^{BF}
CI (%)	17.32 ± 15.09^A	17.24 ± 13.41^A	17.6 ± 18.09^A	16.91 ± 11.35^A	18.9 ± 14.99^B	16.5 ± 20.69^A

Values are given as Mean \pm S.D. from all samples from each sampling site. . Different letters in the same row denote statistically significant difference ($P < 0.05$) between groups

Table 2. Proximate composition of mussels from different sampling sites

	Ljuta	Orahovac	Lipci	Kukuljina	Obala Djurasevic	Sv.Nedjelja
Ash (%)	2.40 ± 0.21^A	3.34 ± 0.24^B	1.73 ± 0.32^A	2.46 ± 0.63^A	2.16 ± 0.21^A	3.30 ± 0.27^C
Moisture (%)	81.39 ± 0.52^A	77.87 ± 1.16^B	81.42 ± 1.21^A	78.9 ± 0.52^B	78.06 ± 0.82^B	78.12 ± 0.87^B
Total protein (%)	7.80 ± 0.24^A	10.26 ± 0.33^B	8.95 ± 0.48^A	8.55 ± 0.45^A	8.66 ± 0.45^A	9.70 ± 0.40^B
Total lipid (%)	2.18 ± 0.25^A	1.71 ± 0.22^A	1.36 ± 0.32^A	1.96 ± 0.61^A	2.13 ± 0.28^A	2.13 ± 0.35^A
Glycogen (mg/g)	12.81 ± 0.09^A	15.11 ± 0.06^A	14.34 ± 2.16^A	13.19 ± 0.15^A	13.2 ± 0.03^A	15.38 ± 0.49^A

Values are given as Mean \pm S.D. from triplicate ; Different letters in the same row denote statistically significant difference ($P < 0.05$) between groups.

Table 3. Fatty acid profile (% of total fatty acids) of mussels from different sampling sites

	Ljuta	Orahovac	Lipci	Kukuljina	Obala Đurasevic	Sv.Nedjelja
SFA	28.61 ± 2.12 ^A	29.45 ± 2.21 ^A	25.99±2.25 ^{AB}	21.89± 3.51 ^B	23.37±3.56 ^{AB}	28.65 ± 2.22 ^A
MUFA	31.68±1.98 ^{AC}	30.52± 1.97 ^A	34.28±2.04 ^{AC}	38.31± 2.11 ^B	35.55±1.97 ^{BC}	33.79± 2.01 ^{AC}
PUFA	39.71 ^a ± 0.82	40.03 ^a ± 0.60	39.73 ^a ± 0.83	39.80 ^a ± 0.82	41.08 ^a ± 1.15	37.56 ^b ± 1.12
n-3	25.75 ± 2.2 ^A	25.23± 2.19 ^A	21.61± 2.2 ^{AC}	18.62±2.32 ^{BC}	20.19±2.19 ^{BC}	25.54 ± 2.22 ^A
n-6	2.86 ± 0.17 ^A	3.04± 0.13 ^{AB}	3.38 ± 0.14 ^B	3.27 ± 0.13 ^B	3.18 ± 0.12 ^B	3.12± 0.13 ^{AB}
n-3/n-6	8.99 ± 1.33 ^A	8.29± 1.70 ^{AC}	6.39± 1.35 ^{BC}	5.70 ± 1.41 ^B	6.34±1.32 ^{ABC}	8.19± 1.45 ^{AC}
n-6/n-3	0.11 ± 0.03 ^A	0.12 ± 0.03 ^A	0.16 ± 0.01 ^A	0.18 ± 0.02 ^A	0.16 ± 0.02 ^A	0.12 ± 0.01 ^A
C20 :5n3 (EPA)	16.10 ± 1.73 ^A	14.09±1.70 ^{AC}	14.65± 1.82 ^{AC}	14.31±1.86 ^{AC}	16.70±2.02 ^{BC}	15.17 ± 1.93 ^A
C22 :6n3 (DHA)	16.04±1.07 ^{AB}	17.25 ± 0.98 ^A	16.09± 1.27 ^{AB}	16.60 ± 1.14 ^B	15.63±1.09 ^{AB}	17.41 ± 0.97 ^A
C18:2 n-6	2.98 ± 0.22 ^A	3.45± 0.23 ^B	3.66± 0.18 ^B	3.80± 0.06 ^B	4.1± 0.33 ^C	2.9± 0.21 ^A
C20:2 n-6	4.60 ± 0.60 ^A	5.22 ± 0.08 ^B	5.33± 0.02 ^B	5.09± 0.03 ^B	5.4± 0.21 ^B	4.1± 0.02 ^C
C14:0	11.38± 0.93 ^A	10.22±0.91 ^{AC}	10.66± 0.94 ^{AC}	9.36± 0.88 ^C	9.25 ± 0.88 ^C	8.17 ± 0.93 ^B
C16:0	17.23± 0.87 ^A	19.23 ± 0.89 ^A	15.33 ± 0.81 ^B	12.53±0.77 ^B	14.12± 0.76 ^B	20.48± 0.54 ^A
C16:1	4.33 ± 1.02 ^A	4.25 ± 1.10 ^A	4.11 ± 0.12 ^B	4.41 ± 1.03 ^{AC}	4.35 ± 1.12 ^{AC}	4.51 ± 1.02 ^{AC}
C18:1 cis-9	3.21 ± 0.80 ^{AB}	3.48 ± 0.40 ^A	3.25 ± 0.89 ^B	3.33 ± 0.84 ^B	2.92 ± 0.11 ^C	3.17 ± 0.80 ^B
C20:1	3.55 ± 0.04 ^A	3.63 ± 0.41 ^A	3.41 ± 0.03 ^B	3.41 ± 0.12 ^B	3.53 ± 0.01 ^A	3.49 ± 0.11 ^A

Values are given as Mean ± S.D. from triplicate ; Different letters in the same row denote statistically significant difference (P <0.05) between groups.

PUFA: Polyunsaturated fatty acids; MUFA: monounsaturated fatty acids; SFA: Saturated fatty acids; n-3: omega-3; n-6: omega-6; EPA: C20:5n-3; DHA: C22:6n-3;

Table 4. Metal concentrations, expressed in mg/kg, in the whole soft tissue of mussels.

	Ljuta	Orahovac	Lipci	Kukuljina	Obala Đurašević	Sv.Nedjelja
Ca	936.3	1009.1	1220.0	857.5	738.2	694.8
K	2018.3	1930.6	1749.5	2066.0	2149.8	2136.8
Mg	509.0	773.0	665.9	911.5	888.2	855.6
Na	401.03	461.73	407.15	564.90	541.72	532.03
Cu	1.3	1.1	1.3	1.6	1.4	1.5
Zn	13.1	16.8	12.6	14.2	17.0	17.5
Fe	23.2	27.3	27.6	39.0	29.9	27.9
Mn	1.5	1.4	1.9	3.4	1.6	2.2
As	2.7	2.9	2.3	2.7	3.4	3.3
Cd	0.2	0.2	0.2	0.3	0.3	0.1
Pb	0.3	0.2	0.2	0.2	0.2	0.2
Hg	0.05	0.04	0.05	0.05	0.05	0.05

Table 5. The main sensory descriptors of mussels from Boka Kotorska Bay, Montenegro

	Ljuta	Orahovac	Lipci	Kukuljina	Obala Đurašević	Sv.nedjelja
Odor	4.0 ± 0.63 ^A	5.0 ± 0.0 ^B	4.0 ± 0.0 ^A	4.0± 0.63 ^A	4.0± 0.63 ^A	3.93 ± 0.41 ^A
Appearance	4.17± 0.41 ^A	5.0 ± 0.0 ^B	3.0± 2.83 ^C	4.0± 3.83 ^{AC}	4.0± 3.33 ^{AC}	4.0± 3.81 ^{AC}
Texture	4.0± 0.00 ^A	5.0 ± 0.0 ^B	3.83± 0.41 ^A	3.33± 0.52 ^A	3.33± 0.82 ^A	4.00 ± 0.89 ^A
Elasticity	3.5 ± 0.55 ^A	5.0 ± 0.00 ^B	3.03± 0.41 ^C	4.0 ± 0.00 ^A	3.83± 0.41 ^A	4.83± 0.41 ^{BD}

Values are given as Mean ± S.D. from eighteen samples from each sampling site. Different letters in the same row denote statistically significant difference (P <0.05) between groups.

Sensory analysis

The main sensory descriptors of mussels from Boka Kotorska Bay are listed in Table 4. In our study, we confirmed significant differences (p < 0.05) in sen-

sory profiles between the mussels from Orahovac and those from the other sites. Orahovac mussels had the best ratings for odor, appearance and texture (5.0 ± 0.0).

DISCUSSION

The Boka Kotorska Bay is composed of several smaller bays and is the only part of the Southern Adriatic with jagged coastline which are influenced by specific hydrological and climatic conditions that are unique in Europe (Vukanic et al., 2016). The results of environmental monitoring indicated that the Boka Kotorska Bay seawater had a variable salinity, but similar temperature in harvesting areas that were investigated. It is important to know that this area is under the influence of freshwater inflows from numerous springs and submarine sources, which is the main factor contributing to a decline in salinity. During the sampling, the superficial waters (0–5 m) of the sampling sites showed similar temperature (15–18 °C). Since the optimum thermal range for this mussel species physiology is generally reported as 10–20 °C (Bayne, 1976), all sampling site had biological conditions for a suitable growth. Salinity was lower at Tivat Bay than at Kotor Bay (19.3 ppm vs 30.56 ppm, respectively), reflecting the lesser mixing processes in the water column reasonably attributable to its greater distance from the open sea. Several authors have highlighted the influence of extrinsic and intrinsic factors, such as water temperature and salinity, food availability and gametogenic cycle of animals on these parameters in mussels (Fernández et al. 2015; Henderikx, 2017; Cherifi et al., 2018). In areas where the eutrophication process is more pronounced microplankton population density was higher (Kotor Bay). Conversely, in Tivat Bay the microplankton populations was decreased due to the impact of the open sea (Vukanic et al., 2016). The mussel's shell is formed largely through deposition of ions, mostly calcium from the seawater and its changes in biometric characteristics is less susceptible to food availability and variety of extrinsic and intrinsic factors than mussel tissue (Alluno-Bruscia et al., 2001). In our study the mussels from Sv. Nedjelja displayed significantly higher morphometric values than others, and the mussels from Obala Đurašević had the maximum values of meat yield (26.39 ± 7.93) and condition index (18.9 ± 14.99) in spite of lower values of microplankton population in that part of Bay. The condition index and meat content in mussels are parameters of biological and technological interest, and they have a direct influence on the quality of the shellfish. The results of meat yield were comparable with previously reported data for cultivated mussels in Adriatic sea (25%) (Vernocchi et al., 2007), but they had lower values than mussels reported in the same period from dif-

ferent Spanish areas (> 30%) (Fuentes et al., 2009) and from the Gulf of Trieste (32.7%) (Bongiorno et al., 2015). The physical, chemical and microbiological stability of mussels strongly depends on the water activity of the meat. Mussels can be considered to be food products with high a_w (recorded a_w values were ≥ 0.95) and high pH (6.7–7.1) (Jay, 1996). In our study we have obtained results that are in accordance with those.

In this research, we obtained different results on biochemical composition between mussels from all sampling sites. Biochemical composition of mussels is affected by water temperature, nutrient availability, and the reproductive cycle of individuals (Fernández-Reiriz et al. 2007). Depending on the time of the year, levels of nutrients are different. In spring, mussels had a higher glycogen and protein content because they reflect the interaction between food supply, temperature, growth and reproductive cycle (Gallardi et al., 2014). In that time of the year, energy is stored for gametogenesis. Glycogen and proteins are considered the main energy substrate and they have a dominant role in bivalve metabolism for nutrient storage and to supply energy for gametogenesis (Baek et al., 2014). Our research was conducted in the spring and we also observed high levels of glycogen and protein concentrations. On the other side, changes in mussels composition are closely related to the food available. The highest chlorophyll levels have been recorded during spring, due to higher seawater temperatures (Irisarri et al., 2014).

Fatty acid composition is associated with seasonal periods and geographical origin. The results showed that of all fatty acids identified in all samples, the polyunsaturated fatty acids (PUFA) is the group with the highest percentage. This group of fatty acid, PUFAs ($37.56 \pm 1.12\%$ to $41.08 \pm 1.15\%$) were dominated followed by the monounsaturated FA (MUFA) ($30.52 \pm 1.97\%$ to $38.31 \pm 2.11\%$), while SFA levels were lower ($21.89 \pm 3.51\%$ to $29.45 \pm 2.21\%$). These results were similar to those reported by other authors (Bongiorno et al., 2015; Fernández et al., 2015). Moreover, these findings concur with studies of numerous bivalve species distributed in other regions of Europe and America. Within PUFAs, the C20:5n-3 and C22:6n-3 fatty acids showed the highest levels. The low levels of PUFA in mussels from Sv. Nedjelja probably is due to the reduced access to phytoplanktonic food. Phytoplankton represents the largest food source for bivalve molluscs and contains a high pro-

portion of polyunsaturated fatty acids of more than 20 carbons (Fernández-Reiriz et al., 1989). As discussed earlier, shellfish are rich in n-3 PUFA, with a ratio of n-3 to n-6 PUFA above 1.0 (Sriket et al., 2007). High levels of total n-3 and low levels of total n-6 PUFA were detected also in our samples and consequently high n-3/n-6 ratio values characterised the mussels cultivated in the Boka Kotorska Bay.

Mytilus galloprovincialis, like other bivalve molluscs, may also be considered a good source of nutritionally important minerals. Since these mussels are edible and marketed commercially, the presence of metals in high concentrations could limit the quantity of mussels that humans can consume, as excessive consumption of metal-contaminated mussels could be toxic to humans (Stankovic et al., 2012). In the mussel samples K, Mg, Ca, and Na concentrations were significantly higher than the remaining tested elements. Several studies have shown that K is usually found to have the highest concentration among the macro minerals in shellfish (Bilandzic et al., 2015, Manthey-Karl et al., 2015). Also, the reason for the high content of Ca and Mg in mussels is their requirement for the shell formation during the mussel growth (Bokori et al., 1995). Since mussels are seawater filter-feeders, their feeding depends on plankton. Phytoplankton are relatively rich in Ca, K and Mg content (Fujita 1971). Seafood provides a major source of Zn and Fe to humans, which are important elements in their diet, but in excess may be harmful for human health (Plum et al., 2010). Comparing data from the literature with the present results showed that concentrations of Zn were lower to those reported for Albanian coast (Cullaj et al., 2007), Croatia (Kljakovic-Gaspic et al., 2006), and Slovenia (Ščančar et al., 2007).

The amount of As, Pb, Hg and Cd in marine organisms reflects the degree of metal pollution in the aquatic environment (Stankovic et al., 2011). Contaminants in mussels have been examined from the standpoint of food safety, and in some places, including the Adriatic Sea, the levels of contaminants exceeded health standards, (Giusti and Zhang, 2002, Kljakovic-Gaspic et al., 2006). In comparison with the permissible limits set by the Montenegrin Food Regulation (2002) for total Hg (1.0 mg kg⁻¹), Cd (1.0 mg kg⁻¹), Pb (1.0 mg kg⁻¹), all concentrations of these metals from all locations were lower than the legislated limits.

The main sensory descriptors of mussels were those related to appearance, odor, texture and, to lesser extent, elasticity. The differences in the assessment of

“orange color”, “firmness” or “consistency” in fresh mussels have a biological explanation since these are the result of different natural stimuli (Costell and Durán, 2005). Our evaluation coincides with Caglak et al. (2008), who suggested that a numeric acceptability scale from 0 to 5 points is suitable to evaluate fresh mussels. The qualitative sensory assessment showed that all mussels were acceptable. All mussels in the current study achieved scores of 3 or more out of 5 in the qualitative category. From a marketing perspective, the mussels cultured in the Boka Kotorska Bay could be accepted well by consumers, and these shellfish fulfill the minimum requirements to fit and compete in the existing local market.

CONCLUSION

This is the first comprehensive report of biometric, sensory and nutritional assessment of mussels harvested in this part of Southern Adriatic Sea (Montenegro). In general, mussels from the Bay of Kotor have shown higher nutritional quality and better sensory and biometric characteristics than mussels from the Bay of Tivat. Consequently, recommendation for mussel growers from Montenegro is to concentrate their production on this area. In addition, the study determined that mussels cultured in the Boka Kotorska Bay could compete with other currently available mussels from other Adriatic Sea locations. The data obtained from the present study and further microbiological studies on the mussels from these locations can confirm the quality of these products and can be valuable for estimating the cost-effectiveness of mussel production and to support marketing of mussels to consumers.

ACKNOWLEDGEMENTS

The authors are grateful to the Diagnostic Veterinary Laboratory of Montenegro, Podgorica for assistance in sample collection. This research was funded by grants III 46009 and TR 31034 from the Ministry of Education, Science and Technological Development, Republic of Serbia.

CONFLICT OF INTEREST

None declared by the authors.

REFERENCES

- Alunno-Bruscia M, Bourget E, Fréchette M (2001) Shell allometry and length-mass-density relationship for *Mytilus edulis* in an experimental food-regulated situation. *Marine Ecology Progress Series* 219:177-88.
- AOAC (1997). Official methods of analysis (16th ed.) Arlington, USA: Association of Official Analytical Chemists International Publ (pp. 1179).
- Baek MJ, Lee YJ, Choi KS, Lee WC, Park HJ, Kwak JH, Kang CK (2014) Physiological disturbance of the Manila clam, *Ruditapes philippinarum*, by altered environmental conditions in a tidal flat on the west coast of Korea. *Marine pollution bulletin* 78(1-2):137-45.
- Bayne BL, Bayne BL, editors (1976) *Marine mussels: their ecology and physiology*. Cambridge University Press.
- Bilandžić N, Sedak M, Čalopek B, Đokić M, Kolanović BS, Varenina I, Božić Đ, Varga I, Đafić N, Mišetić D, Zrnčić S (2015) Differences in element contents of shellfish from coastal locations of Istria. *Veterinarska Stanica* 46(1):9-17.
- Bokori J, Fekete S, Kadar I, Albert M (1995). Complex study of the physiological role of cadmium. II. Effect of cadmium load on the cadmium content of eggs. *Acta Veterinaria Hungarica*;43(1):45-62.
- Bongiorno T, Iacumin L, Tubaro F, Marcuzzo E, Sensidoni A, Tulli F (2015) Seasonal changes in technological and nutritional quality of *Mytilus galloprovincialis* from suspended culture in the Gulf of Trieste (North Adriatic Sea). *Food chemistry* 173:355-62.
- Caglak E, Cakli S, Kilinc B (2008) Microbiological, chemical and sensory assessment of mussels (*Mytilus galloprovincialis*) stored under modified atmosphere packaging *European Food Research and Technology* 226(6):1293-9.
- Cherifi H, Ajjabi LC, Sadok S (2018) Nutritional value of the Tunisian mussel *Mytilus galloprovincialis* with a special emphasis on lipid quality *Food chemistry* 268:307-14.
- Costell E & Durán L (2005) Food texture: Sensory evaluation in food engineering: *Encyclopedia of life support systems*, vol. II, UNESCO – EOLSS, Paris, France pp. 391–401.
- Çullaj A, Lazo P, Duka S (2007) Heavy metals and metallothionein levels in mussel samples from the Albanian sea coast. *Mediterranean action plan med pol* 141.
- Fernández A, Grienke U, Soler-Vila A, Guihéneuf F, Stengel DB, Tasdemir D (2015) Seasonal and geographical variations in the biochemical composition of the blue mussel (*Mytilus edulis* L.) from Ireland. *Food chemistry* 177:43-52.
- Fernández-Reiriz MJ, Duarte P, Labarta U (2007) Modelos de comportamiento alimentario en el mejillón de las rías de Galicia. *Biología y cultivo del mejillón* 197-223.
- Fernández-Reiriz MJ, Perez-Camacho A, Ferreiro MJ, Blanco J, Planas M, Campos MJ, Labarta U (1989) Biomass production and variation in the biochemical profile (total protein, carbohydrates, RNA, lipids and fatty acids) of seven species of marine microalgae. *Aquaculture* 83(1-2):17-37.
- Fernández-Reiriz MJ, Perez-Camacho A, Ferreiro MJ, Blanco J, Planas M, Campos MJ, Labarta U (1989) Biomass production and variation in the biochemical profile (total protein, carbohydrates, RNA, lipids and fatty acids) of seven species of marine microalgae. *Aquaculture* 83(1-2):17-37.
- Fuentes A, Fernández-Segovia I, Escriche I, Serra JA (2009) Comparison of physico-chemical parameters and composition of mussels (*Mytilus galloprovincialis* Lmk.) from different Spanish origins. *Food Chemistry* 112(2):295-302.
- Fujita T (1971) Concentration of major chemical elements in marine plankton. *Geochemical Journal* 4(3):143-56.
- Gallardi D, Hobbs K, Mills T, Couturier C, Parrish CC, Murray HM (2014) Effects of extended ambient live holding on cultured blue mussels (*Mytilus edulis* L.) with reference to condition index, lipid profile, glycogen content and organoleptic testing. *Aquaculture* 430:149-58.
- Giusti L, Zhang H (2002) Heavy metals and arsenic in sediments, mussels and marine water from Murano (Venice, Italy). *Environmental geochemistry and Health* 24(1):47-65.
- GraphPad Prism (2017). Version 7.00 for Windows, GraphPad Software, La Jolla California, USA. Retrieved from <http://www.graphpad.com>
- Grienke U, Silke J, Tasdemir D (2014) Bioactive compounds from marine mussels and their effects on human health. *Food chemistry* 142:48-60.
- Henderikx F (2017) Labelling of food: a challenge for many. *Veterinarski glasnik* 71(1):16-23.
- Ilic N, Velebit B, Teodorovic V, Djordjevic V, Karabasil N, Vasilev D, Djuric S, Adzic B, Dimitrijevic M (2017) Influence of environmental conditions on norovirus presence in mussels harvested in Montenegro. *Food and environmental virology* 9(4):406-14.
- Irisarri J, Fernández-Reiriz MJ, De Troch M, Labarta U (2014) Fatty acids as tracers of trophic interactions between seston, mussels and biodeposits in a coastal embayment of mussel rafts in the proximity of fish cages. *Comparative Biochemistry and Physiology Part B: Biochemistry and Molecular Biology* 172:105-15.
- ISO 5509:2000 Animal and vegetable fats and oils -- Preparation of methyl esters of fatty acids. International Organization for Standardization
- ISO 8587:2006 Sensory analysis — Methodology — Ranking. International Organization for Standardization
- Jay JM (1996) *Modern Food Microbiology*, chapter 6, Seafoods (5th edn). New York: Chapman and Hall.
- Jović M, Stanković S (2014) Human exposure to trace metals and possible public health risks via consumption of mussels *Mytilus galloprovincialis* from the Adriatic coastal area. *Food and chemical toxicology* 70:241-51.
- Jović MD, Stanković A, Slavković-Bešković LJ, Tomic I, Degetto S, Stanković S (2011) Mussels as a bio-indicator of the environmental quality of the coastal water of the Boka Kotorska Bay (Montenegro). *Journal of the Serbian Chemical Society* 76(6):933-46.
- Kljaković-Gašpić Z, Odžak N, Ujević I, Zvonarić T, Horvat M, Barić A (2006) Biomonitoring of mercury in polluted coastal area using transplanted mussels. *Science of the total environment* 368(1):199-209.
- Macic V (2005) A Short Overview of the Status of Aquaculture in Montenegro. IN: Cataudella S., Massa, F.; Crossetti D.(eds) *AdriaMed Expert Consultation "Interactions between Aquaculture and Capture Fisheries"*. *AdriaMed Technical Documents*, (18).
- Manthey-Karl M, Lehmann I, Ostermeyer U, Rehbein H, Schröder U (2015) Meat composition and quality assessment of king scallops (*Pecten maximus*) and frozen Atlantic sea scallops (*Placopecten magellanicus*) on a retail level. *Foods* 4(4):524-46.
- Official Gazette of Montenegro, No 56/09, August 14, 2009. Law on Marine Fisheries and Mariculture
- Okumuş İ, Stirling HP (1998) Seasonal variations in the meat weight, condition index and biochemical composition of mussels (*Mytilus edulis* L.) in suspended culture in two Scottish sea lochs. *Aquaculture*. 159(3-4):249-61.
- Orban E, Di Lena G, Nevigato T, Casini I, Marzetti A, Caproni R (2002) Seasonal changes in meat content, condition index and chemical composition of mussels (*Mytilus galloprovincialis*) cultured in two different Italian sites. *Food Chemistry* 77(1):57-65.
- Plum LM, Rink L, Haase H (2010) The essential toxin: impact of zinc on human health. *International journal of environmental research and public health* 7(4):1342-65.
- Regulation Montenegro Food. 2002. Legislation on maximum permitted level of pesticides, heavy metals and other toxic substances, hormones, antibiotics and mycotoxins in food. *Official Gazette of SRJ* 5:67–85
- Spiric A, Trbovic D, Vranic D, Djinovic J, Petronijevic R, Matekalo-Sverak V (2010) Statistical evaluation of fatty acid profile and cholesterol content in fish (common carp) lipids obtained by different sample preparation procedures. *Analytica chimica acta* 672(1-2):66-71.
- Sriket P, Benjakul S, Visessanguan W, Kijroongrojana K (2007) Comparative studies on chemical composition and thermal properties of black tiger shrimp (*Penaeus monodon*) and white shrimp (*Penaeus vannamei*) meats. *Food chemistry* 103(4):1199-207.

- Stankovic S, Jovic M, Stankovic AR, Katsikas L (2012) Heavy metals in seafood mussels. Risks for human health. In Environmental chemistry for a sustainable world 311-373
- Ščančar J, Zuliani T, Turk T, Milačič R (2007) Organotin compounds and selected metals in the marine environment of Northern Adriatic Sea. Environmental Monitoring and Assessment. 127(1-3):271-82.
- Ventrella V, Pirini M, Pagliarini A, Trombetti F, Manuzzi MP, Borgatti AR (2008) Effect of temporal and geographical factors on fatty acid composition of *M. galloprovincialis* from the Adriatic sea. Comparative Biochemistry and Physiology Part B: Biochemistry and Molecular Biology 149(2):241-50.
- Vernocchi P, Maffei M, Lanciotti R, Suzzi G, Gardini F (2007) Characterization of mediterranean mussels (*Mytilus galloprovincialis*) harvested in Adriatic Sea (Italy). Food control 18(12):1575-83.
- Vukanić V, Vukanić D, Živić ND, Jakšić T, Čanak S (2016) Hydrographic Characteristics and Plankton Structure of the Southeastern Part of the Southern Adriatic Sea. Water Research and Management 6(4):45-53.

Effect of trans-resveratrol or ubiquinol supplementation on the sperm morphology of CD-1 mice subjected to forced swimming.

D. Vaamonde¹, A. Sánchez de Medina², B. Cortés², A. Díaz², I. Rodríguez²

¹ Morphological Sciences Department, School of Medicine and Nursing, Universidad de Córdoba, Spain.

² Animal Surgery and Medicine Department, School of Veterinary Medicine, Universidad de Córdoba, Spain.

ABSTRACT: This study was undertaken to assess the effect of a three-minute forced swimming protocol for 50 days, with and without antioxidant administration on sperm morphology in CD-1 mice. Seventy-five mice were randomly allocated to one of the following five groups: no exercise (control group; CG), swimming without antioxidant administration (EX), swimming with trans-resveratrol administration (EX-Resv), swimming with ubiquinol and excipient administration (Kaneka's ubiquinol) (EX-Ubiq), and swimming with just only the excipient for Kaneka's ubiquinol administration (EX-Excp). The EX group showed that $53.03 \pm 4.83\%$ of sperm had abnormal morphology, with significant differences with regards to CG ($46.47 \pm 10.57\%$) ($p < 0.05$). The number of sperm with abnormal morphology decreased in all groups treated with either antioxidants or with excipient; this was most noticeable in EX-Ubiq ($p < 0.05$). The percentage of midpiece and tail, as well as multiple anomalies were greater in EX than in CG ($p < 0.05$). While both antioxidants, as well as the excipient, decreased midpiece and head anomalies, only trans-resveratrol and ubiquinol had an effect on multiple anomalies. Furthermore, only trans-resveratrol had an effect upon tail anomalies. The imposed exercise caused alterations in CD-1 mice sperm morphology, and antioxidant treatment seems suitable to decrease morphological anomalies. Both trans-resveratrol and ubiquinol were effective in decreasing simple as well as multiple sperm anomalies.

Keywords: swimming exercise; sperm morphology; ubiquinol; trans-resveratrol

Corresponding Author:

Diana Vaamonde, Facultad de Medicina y Enfermería- Universidad de Córdoba.
Avenida Menéndez Pidal s/n.14004. Córdoba
E-mail address: fivresearch@yahoo.com

Date of initial submission: 30-11-2019
Date of revised submission: 21-02-2020
Date of acceptance: 06-04-2020

INTRODUCTION

There are many couples in the world with fertility problems. Male factor is usually a problem in about 40% of cases (Brugh and Lipshultz, 2004). Hormones, radiation, tobacco consumption, varicocele, infections, nutritional deficit, oxidative stress, and exercise have been linked to fertility problems (Arce et al., 1993; du Plessis et al., 2011). For several decades, the relationship between physical activity and human fertility has been studied reporting different alterations in sperm parameters such as sperm concentration, motility and morphology among others (De Souza et al., 1994; De Souza and Miller, 1997; Vaamonde et al., 2006, 2009).

In animal models, the reproductive potential has been altered as a consequence of forced swimming at different levels of intensity (Manna et al., 2003, 2004; Mingoti et al., 2003; Saki et al., 2009, 2010; Nirupama et al., 2013). A decrease in fertility rates was observed with a three-minute daily program of forced swimming for 50 days (Saki et al., 2009, 2010). It has been hypothesized that an imbalance between free radicals and body's antioxidants (oxidative stress) plays a role in these changes. Reactive oxygen species (ROS) damage cellular macromolecules, like polyunsaturated fatty acids present in the cell membrane (PUFAs); due to such damage, alterations in cell function may occur (Gozalvez et al., 2017). Sperm cells are especially vulnerable to oxidative degradation of lipids produced by ROS due to the large amount of PUFAs present in their plasma membrane (Griveau and Le Lannou, 1997). Although small amounts of ROS are necessary for sperm to acquire their fertilizing capacity (Aitken, 1997; Griveau and Le Lannou, 1997), when produced in excess such that the antioxidant capacity of the reproductive tract is exceeded, oxidative damage may occur. This may cause, among others, alterations in sperm morphology (Aziz et al., 2004; Agarwal et al., 2008; Tremellen, 2008; Jana et al., 2014). Moreover, it has been reported that abnormal spermatozoa are a source of ROS production, existing a positive correlation between ROS and sperm anomalies (Aziz et al., 2004; Sabeti et al., 2016). The sperm morphology is an important parameter related to fertility potential (Gatimel et al., 2017). In this regards, it has been reported that when the percentage of simple anomalies and, above all, multiple anomalies, increases the fertility decreases (Jouannet et al., 1988; Slama et al., 2002).

To counteract oxidative damage, the body increas-

es its own antioxidant capacity; this can also be aided by exogenous supplementation with antioxidant agents (Agarwal et al., 2004; Tremellen, 2008). Antioxidants counteract the presence of ROS and decrease lipid peroxidation, thereby maintaining the integrity of the PUFAs present in the sperm membrane and, thus, supporting sperm function.

Resveratrol is a natural antioxidant that acts by reducing lipid peroxidation, oxidation and protein nitration (Olas and Wachowicz, 2005). Additionally, resveratrol activates sirtuin-1 and protects mitochondrial function (Price et al., 2012). At the reproductive level, it has been used in animal models where it has been observed to increase the concentration of gonadotropins and testosterone in blood, resulting in increased epididymal sperm output (Juan et al., 2005). Resveratrol has also been reported to protect against testicular damage produced by various oxidizing agents (Jiang et al., 2008) and stress (Bitgul et al., 2013). In humans, the relationship of dietary resveratrol supplementation with regards to fertility has not been studied, yet some studies have reported a protective effect of resveratrol addition to human ejaculates against oxidizing agents such as butylhydroperoxide (Collodel et al., 2011) and the reduction of cryopreservation-induced sperm injury (Li et al., 2018).

In an exercise model, it has been previously used by our group, and was found to reverse the deleterious morphological effects of imposed exercise (Rodríguez et al., 2016).

Ubiquinol (the reduced form of coenzyme Q10) is a liposoluble substance with roles in bioenergetic pathways and antioxidant mechanisms (Litarru, 2007). As an antioxidant, it scavenges free radicals and prevents the initiation and propagation of lipid peroxidation in cell membranes, also helping with the regeneration of other antioxidants such as tocopherol and ascorbate (Crane, 2001). Its activity as an antioxidant has been studied in different tissues, like the testes (Ognjanovic et al., 2010; Fouad et al., 2011; Nadjarzadeh et al., 2013). As a bioenergetic molecule, it is an essential member of the mitochondrial electron transport chain and has a fundamental role in the production of ATP. Coenzyme Q10 deficits can impair mitochondrial capacity (Crane, 2001). Despite its poor solubility, it has been shown that the oral exogenous administration of ubiquinol increases levels of coenzyme-Q10 and ubiquinol in seminal plasma and sperm cells (Balercia et al., 2009; Safarinejad et al.,

2012). Ubiquinol has been reported to improve semen parameters in human patients with fertility problems (Balercia et al., 2009; Safarinejad et al., 2012). However, its effectiveness in subjects undergoing exercise has not yet been assessed.

Different compounds, including vitamin C, which is a water-soluble vitamin, have been used as an excipient to facilitate the absorption of ubiquinol. Vitamin C is present at higher concentrations in seminal fluid compared to blood plasma (Jacob et al., 1992), suggesting an important role. It is essential for the proper progression of spermatogenesis, partly due to its ability to reduce α -tocopherol and maintain this antioxidant in an active state (Aitken and Roman, 2008). Vitamin C also reduces lipid peroxidation and increases testosterone levels. As a result, sperm membrane integrity is protected, and sperm production increases, improving semen parameters (Sönmez et al., 2005; Akmal et al., 2006; Sanghishetti et al., 2014).

The objective of this study was to assess the effect of antioxidant supplementation with either trans-resveratrol or Kaneka's ubiquinol on sperm morphology of mice subjected to a forced swimming exercise protocol.

MATERIAL AND METHODS

Animals

Seventy-five adult (65-day-old) CD-1 male mice (average weight: 40 g) provided by Janvier Labs (France) were used in this study. The total sample size was calculated by using the G*power 3.1.9.4. (Faul et al., 2009). Mice were housed in the Centralized Animal Experimentation Service of the University of Cordoba. A five-day adaptation period was implemented before the study. The animals were housed in individual cages under constant conditions: $21 \pm 1^\circ\text{C}$, 55% relative humidity and a 12-h light/12-h dark cycle. Mice were given ad libitum access to food and water. Food was pellet chow with a composition of 4% animal-derived protein, 8% vegetable-derived protein, 4.10% minerals and vitamins and 83.90% cereals (barley, wheat, wheat bran, maize, soybean meal) (Panlab S.L. Augy, France).

The animals ($n = 75$) were randomly allocated to one of five groups, with 15 mice per group: non-exercise control group (CG), swimming exercise group without antioxidant supplementation (EX), swimming exercise group with administration of trans-resveratrol (EX-Resv), swimming exercise group with

administration of Kaneka's ubiquinol (EX-Ubiq), swimming exercise group with administration Kaneka's ubiquinol excipient (EX-Excp). The latter group was included in order to determine if the effect of ubiquinol was really due to ubiquinol or to the excipient used, which includes vitamin C. The animals were clinically assessed every day, following the principles of laboratory animal care and always treating them appropriately, in order to exclude any problem that could make them unsuitable for the experiment. The study was approved by the Institutional Animal Care and Use Committee of University of Cordoba (N°7623)

Training protocol

The animals of the EX, EX-Resv, EX-Ubiq and EX-Excp groups were subjected to a daily exercise session of three minutes of forced swimming for 50 days, in circular swimming pools measuring 60 cm in diameter and 80 cm deep with smooth and opaque walls and water with controlled temperature ($33^\circ\text{C} - 35^\circ\text{C}$). The order in which each animal swam was different and randomly chosen. Once the exercise session was finished, mice were dried with a paper towel and returned to their cages. The animals of the CG group were handled in the same manner as the rest, except for the swimming exercise.

Administration of antioxidants

Besides regular pellets, all mice were given a daily one-gram feed cake made from commercial feed with a caloric intake of 2900 kcal /kg (Panlab S.L.); it was assessed that mice ate the whole cake every day. Prior to the experimental phase, the cakes had been prepared and stored in the freezer until use. The ingredients for the cakes were ground up and moistened with double-distilled water. The CG and EX groups did not receive antioxidant supplementation in the cake. EX-Resv, EX-Ubiq and EX-Excp received antioxidant supplementation that was mixed with the cake as described below. In the EX-Resv group, a dose of 100 mg/kg of trans-resveratrol (Caiman Chemical Company) was added; in the EX-Ubiq group, a dose of 200 mg/kg of a compound elaborated by Kaneka was used (to improve ubiquinol absorption, this compound also included an excipient composed of 73.93% gum Arabic, 20.44% dextrin and 4.63% vitamin C); in the EX-Excp group, the proportion of the excipient corresponding to 200 mg of Kaneka's ubiquinol was used. Twenty cakes were randomly chosen from each batch to verify the anti-

oxidant quantitative content. Trans-resveratrol cakes were analyzed by an extraction method by high performance liquid chromatography (HPLC), with detection by a diode detector array (Rodriguez-Bernaldo et al., 2009). The ubiquinol cakes were analyzed by extraction of the lipid fraction of the feed (with hexane) and separation by HPLC with an electrochemical detector (Lopez-Dominguez et al., 2013). The cakes were administered together with the feed at the end of the exercise period. In the case of trans-resveratrol, these were administered in the afternoon with the beginning of the dark cycle to avoid isomerization of the product by light.

Sample collection and evaluation

The animals were sacrificed by cervical dislocation and subsequent decapitation 24 hours after the final training session. The testes were extracted and the secretion from the cauda epididymis was obtained using a sterile 22 G needle and placed into sterile tube for analysis. An eosin-nigrosin stain was performed for the assessment of sperm morphology (200 sperm assessed for each parameter) (Vital Screen™, FertiPro®). Ten microliters of the sperm sample were mixed in a sterile tube with 20µl of 1% eosin and subsequently mixed with 30µl of 5% nigrosine. Afterwards, the mix was homogenized and finally a 10µl of semen-stain mixture was used for assessment under optical microscopy (Olympus BH-2) at 100x magnification under oil immersion. Sperm morphology was classified, following the criteria of Wytobek and Bruce (1975) into normal and abnormal spermatozoa. Abnormalities were classified into four categories: head, midpiece, tail and multiple anomalies. Any spermatozoa exhibiting an abnormality in at least one segment was considered abnormal, when two or more segments were abnormal, sperm were considered as having multiple anomalies. Sperm morphology was always assessed by the same experienced observer to minimize possible inter-observer variability. The data obtained were collected in Microsoft Office Excel

spreadsheets for further statistical analysis.

Statistical analysis

The statistical analysis was carried out with the statistical program STATGRAPHICS Centurion XVI (Stat Point Technologies Inc, 2009). The Pearson Chi-Square test was used to compare differences between groups on sperm morphology. For weight gain and daily intake one-way ANOVA was used to compare if there were differences between groups. The statistical significance level was set at $p < 0.05$.

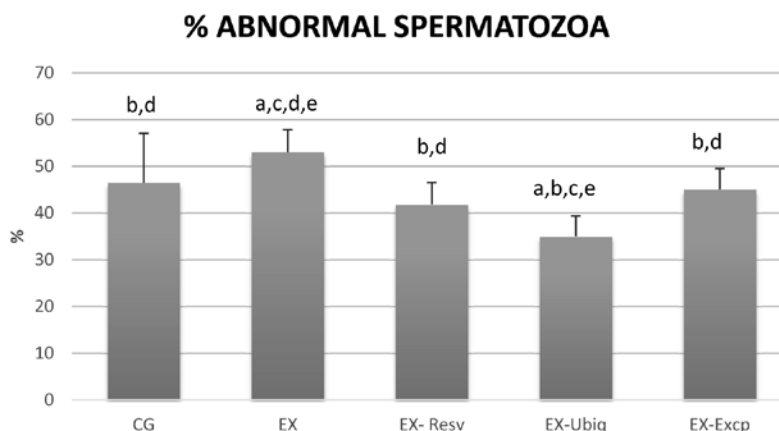
RESULTS

All animals maintained good general health throughout the study period. The body weight gain and food intake did not show any significant difference among groups (Table 1).

Exercise produced an increase in overall abnormal forms (EX: 53.03 ± 4.83 Vs CG: 46.47 ± 10.57) ($p < 0.05$) (Figure 1). Moreover, an increase in multiple anomalies was also observed as a result of the exercise intervention (EX: $178(5.93\%)$ Vs CG: $126(4.2\%)$) ($p < 0.05$) (Table 2). With regards to the different segments, midpiece and tail anomalies were statistically greater in EX group than in and CG (Table 2). The administration of either one of the antioxidants or the excipient decreased the percentage of abnormal forms in all treated groups with regards to EX (no antioxidants). Among the different antioxidants, EX-Ubiq exhibited the most noticeable changes, with statistical differences in comparison to the other compounds (Figure 1). Both antioxidants and excipient decreased midpiece anomalies; moreover, although no differences were observed in head anomalies as a result of exercise, the antioxidants were able to decrease the anomalies in this segment (Table 2). However, the only antioxidant able to decrease tail anomalies was trans-resveratrol. With regards to multiple anomalies, both trans-resveratrol and ubiquinol were able to decrease them, while the excipient was not (Table 2).

Table 1. Daily intake, initial weight and final weight in the different groups. (CG = Control group, EX = Exercise group, EX-Resv = Exercise + Resveratrol, EX-Ubiq = Exercise + Ubiquinol, EX-Excp = Exercise + Excipient). Values are mean \pm SD. There were no statistical differences between groups.

GROUP	CG(n=15)	EX(n=15)	EX-Resv(n=15)	EX-Ubiq(n=15)	EX-Excp(n=15)
Daily intake (gr)	5.8 ± 1.13	5.4 ± 1.10	5.61 ± 1.04	5.46 ± 1.07	5.34 ± 1.11
Initial weight (gr)	39.3 ± 0.05	41.22 ± 0.17	42.78 ± 0.32	41.76 ± 0.41	38.48 ± 0.47
Final weight (gr)	39.75 ± 1.01	42.57 ± 2.15	43.46 ± 1.47	42.84 ± 1.08	39.82 ± 1.38

Figure 1. Percentage of abnormal spermatozoa observed in different groups.

(CG = Control group; EX = Exercise group; EX-Resv = Exercise + Resveratrol, EX-Ubiq = Exercise + Ubiquinol, EX-Excp = Exercise + Excipient). Values are mean \pm SD for fifteen animals per group ($p < 0.05$).

Superscript letters (a,b,c,d,e) indicates significant differences ($p < 0.05$), with regard to CG (a), with regard to EX (b), with regard to EX-Resv (c), with regard to EX-Ubiq (d), with regard to EX-Excp (e).

Table 2. Number of abnormal sperm with percentages of head, midpiece, tail and multiple anomalies observed in the different groups. (CG = Control group, EX = Exercise group, EX-Resv = Exercise + Resveratrol, EX-Ubiq = Exercise + Ubiquinol, EX-Excp = Exercise + Excipient). Two hundred spermatozoa per mice were assessed, 3000 in total in each group)

GROUP	Head anomalies	Midpiece anomalies	Tail anomalies	Multiple anomalies
CG (n=15)	95(3.16%) ^{cde}	687(22.9%) ^{bd}	486(16.2%) ^{bde}	126(4.2%) ^{be}
EX (n=15)	74(2.46%) ^{cde}	756(25.2%) ^{acde}	583(19.43%) ^{ac}	178(5.93%) ^{acd}
EX-Resv (n=15)	8 (0.26%) ^{ab}	568(18.93%) ^{bd}	526(17.53%) ^b	153(5.1%) ^b
EX-Ubiq (n=15)	12(0.4%) ^{ab}	370(12.33%) ^{abce}	549(18.3%) ^a	120(4.0%) ^{be}
EX-Excp (n=15)	17(0.56%) ^{ab}	579(19.3%) ^{bd}	574(19.13%) ^a	182(6.06%) ^{ad}

Superscript letters (a,b,c,d,e) indicates significant differences ($p < 0.05$), with regard to CG (a), with regard to EX (b), with regard to EX-Resv (c), with regard to EX-Ubiq (d), with regard to EX-Excp (e).

DISCUSSION

In the current study, a three-minute daily forced swimming exercise for 50 days resulted in sperm morphological alterations. A swimming exercise with controlled temperature was employed in this study in such a way as to minimize the changes in testicular temperature. The relationship between exercise and sperm alterations has been studied in animal models reporting alterations in sperm parameters (Mingoti et al., 2003; Saki et al., 2009, 2010; Minaii et al., 2014; Moayeri et al., 2017). One of the parameters that has been reported to be altered as a result of exercise is morphology (Jana et al., 2014; Minaii et al., 2014); this parameter is of essential importance for fertility (Ombelet et al., 1995; Gatimel et al., 2017) and it may be a sensitive tool to measure reproductive potential (Menkveld et al., 2011). Some authors have used a three-minute forced swimming exercise model for 50 days, and, despite not assessing morphology, a decrease in the number and motility of sperm, as well as in in vivo fertilizing capacity, has been reported (Mingoti et al., 2003; Saki et al., 2009, 2010). However,

authors using other models of forced swimming have shown that exercise affects morphology in a manner similar to our study (Jana et al., 2014; Minaii et al., 2014). The physiopathological mechanisms by which exercise causes sperm alterations or fertility problems are not entirely clear. On one hand, exercise may cause alterations in the hypothalamic-pituitary-gonadal axis (HPG) due to physiological stress, decreasing testosterone levels and affecting spermatogenesis (Manna et al., 2003, 2004; Jana et al., 2008). Although hormonal parameters were not evaluated in this study, alterations in this axis could not be ruled out. On the other hand, since sperm membranes are rich in PUFAs, rendering these cells vulnerable to oxidative stress attack (Alvarez and Storey, 1995), exercise-induced oxidative stress may cause increased lipid peroxidation. Numerous studies have demonstrated that oxidative stress causes damage to the epithelium of the seminiferous tubules, altering spermatogenesis and, therefore, increasing the number of spermatozoa with abnormal morphology (Aziz et al., 2004; Aitken and Baker, 2006); in this regard, increased levels of ROS in the

testes have been observed as a result of exercise (Manna et al., 2003, 2004; Nirupama et al., 2013).

When considering the different types of anomalies by the segment involved, it could be observed that midpiece was the main segment affected followed by tail anomalies, results similar to those previously reported by our group (Rodriguez et al., 2016). The midpiece is a fundamental component in sperm due to its mitochondrial content; these organelles are the main source of sperm energy for motility. Thus, midpiece alterations could reflect alterations in the mitochondrial apparatus of the sperm and, thus, changes in sperm energetics. Moreover, while damage in the sperm mitochondria leads to an increase in ROS production, this increase in ROS levels in turn alter mitochondria (Sabeti et al., 2016).

The percentage of multiple anomalies was greater in EX than in CG. It must be highlighted that the presence of multiple anomalies has an important relationship with fertility; as such, it has been observed abnormal sperm correlate with altered functionality as well as with chance of conception (this latter parameter negatively), whether in vivo or in vitro (Slama et al., 2002). Previous studies conducted in exercise models, including ours, have assessed sperm morphology but not the presence of multiple anomalies (Jana et al., 2014; Minaii et al., 2014; Rodriguez et al., 2016).

In the present study, daily oral supplementation with 100 mg/kg of trans-resveratrol resulted in a decreased percentage of abnormal forms with respect to EX group. It seems to protect against damage produced by exercise in the midpiece, tail and multiple anomalies while also decreased head alterations. Whereas a dose of 200 mg/kg was previously found by our group (Rodriguez et al., 2016) to decrease the percentage of head, midpiece and tail anomalies, the dose of 100 mg/kg trans-resveratrol used in the present study, offered the same effect. To the best of our knowledge, the effect of this antioxidant in exercise models has only been assessed by our group so far. There are several mechanisms by which trans-resveratrol could decrease anomalies caused by exercise. One of these could be mediated by the estrogen-like growth-promoting characteristics of the compound, improving the HPG axis and, therefore, spermatogenesis (Juan et al., 2005). This effect has been previously demonstrated, although morphology was not assessed, in healthy mice given an oral supplementation of 20 mg/kg resveratrol; as a result, increased gonadotrophin and testosterone secretion was observed,

along with increased epididymal sperm output (Juan et al., 2005). Similar results have been reported in other animal models (Shin et al., 2008). Another proposed mechanism could be its antioxidant and ROS scavenging activity, which would protect the testis. As such, trans-resveratrol induced an improvement in sperm morphology in a model using rats with induced varicocele (Mendes et al., 2016). Finally, improved mitochondrial function could also be responsible for the observed changes since mitochondria, a fundamental organelle for sperm energetics, are the main source of intracellular ROS (Gibellini et al., 2015). A combination of these different properties is possibly the cause of the observed protection against the damage produced in the exercise condition.

Ubiquinol is another potent antioxidant. In the present study, a daily 200 mg/kg dose of Kaneka's ubiquinol was found to be the antioxidant that best protected against sperm morphological damage. Its effect was similar to that of trans-resveratrol, decreasing head anomalies and protecting against damage in the midpiece caused by exercise, even with statistical significance with regards to the other antioxidant compounds. Also, it decreases multiple anomalies caused by exercise. To the best of our knowledge, this is the first study to assess the effect of ubiquinol on testicular function in mice subjected to a forced exercise model. In human rest models, Safarinejad (2009) reported improved Sertoli cell function and spermatogenesis, but controversial results have been observed in relation to sperm morphology; some authors have showed improved sperm morphology (Safarinejad et al., 2012; Cakiroglu et al., 2014), while others have reported improved sperm motility and density, but not morphology (Safarinejad, 2009). This variation in the results could be due to the lack of homogenization in terms of dosage and administration protocols, as well as differences in commercial forms of the coenzyme Q10. In the present study, the commercial form of ubiquinol has been shown to be readily absorbed (Ikematsu et al., 2006; Ozaki et al., 2010). Ubiquinol, though it involves multiple pathways, likely worked through a similar mechanism to that of resveratrol, decreasing sperm anomalies by either increasing testosterone (Ghanbarzadeh et al., 2014), scavenging ROS, improving the electron transport chain or a combination of pathways (Crane, 2001).

The excipient alone also improved sperm morphology, but to a lesser extent than Kaneka's ubiquinol (which includes the excipient). While it decreases

head and midpiece anomalies, it was ineffective with regards to tail and multiple anomalies. This effect was possibly due to its high content of vitamin C, which is known to have antioxidant capacity (Samanta et al., 2006). As such, it has been shown to improve semen parameters, including morphology, in subfertile individuals (Akmal et al., 2006); similar results were reported in rat models where the observed increased testosterone levels could be responsible for the improvements (Sanghishetti et al., 2014; Okon and Utuk, 2016). Therefore, the combination of the excipient and ubiquinol was the most effective treatment for improving sperm morphology.

It has been shown that both Kaneka's ubiquinol and trans-resveratrol decreased both individual as well as multiple morphological anomalies in sperm. With regards ubiquinol, while it was the best compound in decreasing total number of abnormal forms, it was not effective for tail anomalies. Conversely, trans-resveratrol was able to decrease anomalies in all segments.

CONCLUSIONS

The present study confirms that the three-minute forced swimming model for 50 days results in

sperm morphological alterations being the midpiece the segment mainly affected. Additionally, antioxidant supplementation with trans-resveratrol, ubiquinol or Kaneka's ubiquinol excipient prevented such anomalies. Lower doses of trans-resveratrol were as effective as higher ones previously used. While the administration of just Kaneka's ubiquinol excipient protected against sperm damage, Kaneka's ubiquinol was the compound that best protected, even exhibiting abnormal morphology percentages lower than those of control group; it is worth mentioning that this is the first time that the effect of ubiquinol has been studied with regards to exercise and sperm morphology. Future studies should focus on investigating the underlying mechanisms by which antioxidant supplementation improves these parameters.

ACKNOWLEDGMENTS

The authors would like to thank Kaneka for providing ubiquinol and excipient, and Prof. Dr. Juan Manuel Serrano and Prof. Dr. Antonio Molina for help with statistics.

CONFLICT OF INTEREST

The authors declare no conflicts of interest.

REFERENCES

- Agarwal A, Nallella KP, Allamaneni SS, Said TM (2004) Role of antioxidants in treatment of male infertility: an overview of the literature. *Reprod Biomed Online* 8:616-627.
- Agarwal A, Makker K, Sharma R (2008) Clinical relevance of oxidative stress in male factor infertility: an update. *Am J Reprod Immunol* 59:2-11.
- Ahmadi S, Bashiri R, Ghadiri-Anari A, Nadjarzadeh A (2016) Antioxidant supplements and semen parameters: An evidence-based review. *Int J Reprod Biomed (Yazd)* 14:729-736.
- Aitken RJ (1997) Molecular mechanisms regulating human sperm function. *Mol Hum Reprod* 3:169-173.
- Aitken RJ, Baker MA (2006) Oxidative stress, sperm survival and fertility control. *Mol Cell Endocrinol* 250:66-69.
- Aitken RJ, Roman SD (2008) Antioxidant systems and oxidative stress in the testes. *Oxy Med Cell Long* 1:15-24.
- Akmal M, Qadri JQ, Noori S, Shahiya T, Afrozul H, Khelod, Y (2006) Improvement in human semen quality after oral supplementation of vitamin C. *J Med Food* 9:440-442.
- Alvarez JG, Storey BT (1995) Differential incorporation of fatty acids into and peroxidative loss of fatty acids from phospholipids of human spermatozoa. *Mol Reprod Dev* 42:334-346.
- Arce JC, De Souza MJ, Pescatello LS, Luciano AA (1993) Subclinical alterations in hormone and semen profile in athletes. *Fertil Steril* 59:398-404.
- Aziz N, Saleh RA, Sharma RK, Lewis-Jones I, Esfandiari N, Thomas AJ, et al (2004) Novel association between sperm reactive oxygen species production, sperm morphological defects, and the sperm deformity index. *Fertil Steril* 81:349-354.
- Balercia G, Buldreggini E, Vignini A, Tiano L, Paggi F, Amoroso S, et al (2009) Coenzyme Q10 treatment in infertile men with idiopathic asthenozoospermia: a placebo-controlled, double-blind randomized trial. *Fertil Steril* 91:1785-1792.
- Bitgul G, Tekmen I, Keles D, Oktay G (2013) Protective effects of resveratrol against chronic immobilization stress on testis. *ISRN Urology* 1-10.
- Brugh VM, Lipshultz LI (2004) Male factor infertility: evaluation and management. *Med Clin North Am* 88:367-385.
- Cakiroglu B, Eyyupoglu SE, Gozukucuk R, Uyanik BS (2014) Ubiquinol Effect on Sperm Parameters in Subfertile Men Who Have Asthenozoospermia with Normal Sperm Concentration. *Nephro Urol Mon* 10 e16870.
- Collodel G, Federico MG, Geminiani M, Martini S, Bonechi C, Rossi C, Figura N, Moretti E (2011) Effect of trans-resveratrol on induced oxidative stress in human sperm and in rat germinal cells. *Reprod Toxicol* 31:239-346.
- Crane FL (2001) Biochemical functions of coenzyme Q10. *J Am Coll Nutr* 20:591-598.
- De Souza MJ, Arce JC, Pescatello LS, Scherzer HS, Luciano AA (1994) Gonadal hormones and semen quality in male runners a volume threshold effect of endurance training. *Int J Sport Med* 15:383-391.
- De Souza MJ, Miller BE (1997) The effect of endurance training on reproductive function in male runners. A 'volume threshold' hypothesis. *Sport Med* 23:357-374.
- du Plessis SS, Kashou A, Vaamonde D, Agarwal A (2011) Is There a Link between Exercise and Male Factor Infertility? *Open Reprod Sci J* 3:105-113.
- Faul F, Erdfelder E, Buchner A, Lang AG (2009) Statistical power analyses using G*Power 3.1: Tests for correlation and regression analyses. *Behav Res Methods* 41: 1149-1160.
- Fouad AA, Al-Sultan AI, Yacoubi M (2011) Coenzyme Q10 counteracts testicular injury induced by sodium arsenite in rats. *Eur J Pharmacol* 655:91-98.
- Gatimel N, Moreau J, Parinaud J, Leandri R (2017) Sperm morphology: assessment, pathophysiology, clinical relevance, and state of the art in 2017. *Andrology* 5:845-862.

- Ghanbarzadeh S, Garjani A, Ziaee M, Khorrami A (2014) Effects of L-carnitine and coenzyme Q10 on impaired spermatogenesis caused by isoproterenol in male rats. *Drug Res* 64:449-453.
- Gibellini L, Bianchini E, De Biasi S, Nasi M, Cossarizza A, Pinti M (2015) Natural Compounds Modulating Mitochondrial Functions. *Evid Based Complement Alternat Med* 527209.
- Gozalvez J, Tvrda E, Agarwal A (2017) Free radical and superoxide reactivity detection in semen quality assessment: past, present, and future. *J Assist Reprod Genetics* 34:697-707.
- Griveau JF, Le Lannou D (1997) Reactive oxygen species and human spermatozoa: physiology and pathology. *Int J Andrology* 20:61-69.
- Ikematsu H, Nakamura K, Harashima S, Fujii K, Fukutomi N (2006) Safety assessment of coenzyme Q10 (Kaneka Q10) in healthy subjects: A double-blind, randomized, placebo-controlled trial. *Reg Tox Pharm* 44:212-218.
- Jacob RA, Pianalto FS, Agee RE (1992) Cellular ascorbate depletion in healthy men. *J Nutr* 122:1111-1118.
- Jana K, Samanta PK, Manna I, Ghosh P, Singh N, Khetan RP, Ray BR (2008) Protective effect of sodium selenite and zinc sulfate on intensive swimming-induced testicular gametogenic and steroidogenic disorders in mature male rats. *Appl Physiol Nutr Metab* 33:903-914.
- Jana K, Dutta A, Chakraborty P, Manna I, Firdaus SB, Bandyopadhyay D, Chattopadhyay R, Chakravarty B (2014) Alpha-lipoic acid and N-acetylcysteine protects intensive swimming exercise mediated germ-cell depletion, pro-oxidant generation, and alteration of steroidogenesis in rat testis. *Mol Reprod Dev* 81:833-850.
- Jiang Y, Peng T, Luo Y, Li MC, Lin, YH (2008) Resveratrol reestablishes spermatogenesis after testicular injury in rats caused by 2,5-hexanedione. *Chin Med J* 121:1204-1209.
- Jouannet P, Ducot B, Feneux D, Spira A (1988) Male factors and the likelihood of pregnancy in infertile couples. I. Study of sperm characteristics. *Int J Androl* 11(5):379-394.
- Juan ME, Gonzalez-Pons E, Munuera T, Ballester J, Rodriguez JE, Planas JM (2005) Trans-Resveratrol, a natural antioxidant from grapes, increases sperm output in healthy rats. *J Nutr* 135:757-760.
- Li SJ, Su WD, Qiu LJ, Wang X, Liu J (2018) Resveratrol protects human sperm against cryopreservation-induced injury. *Zhonghua Nan Ke Xue* 24:499-503.
- Litaru GP (2007) Bioenergetic and Antioxidant Properties of Coenzyme Q10: Recent Developments. *Mol Biotechnology* 37:31-37.
- López-Domínguez JA, Khaiwesh H, González-Reyes JA, López- Lluch G, Navas P, Ramsey JJ, de Cabo R, Burón MI, Villalba, JM (2013) Dietary fat modifies mitochondrial and plasma membrane apoptotic signaling in skeletal muscle of calorie-restricted mice. *Age* 35:2017-2044.
- Manna I, Jana K, Samanta PK (2003) Effect of intensive exercise-induced testicular gametogenic and steroidogenic disorders in mature male Wistar strain rats: a correlative approach to oxidative stress. *Acta Physiol Scand* 178:33-40.
- Manna I, Jana K, Samanta PK (2004) Effect of different intensities of swimming exercise on testicular oxidative stress and reproductive dysfunction in mature male albino Wistar rats. *Indian J Exp Biol* 42:816-822.
- Mendes TB, Paccola CC, de Oliveira Neves FM, Simas JN, da Costa Vaz A, Cabral RE, Vendramini V, and Miraglia SM (2016) Resveratrol improves reproductive parameters of adult rats varicocele in peripuberty. *Reproduction* 152:23-35.
- Menkveld R, Holleboom CA, Rhemrev JP (2011) Measurement and significance of sperm morphology. *Asian J Androl* 13:59-68.
- Minaii B, Moayeri A, Shokri S, Habibi Roudkenar M, Golmohammadi T, Malek F, Barbarestani M (2014) Melatonin improves the sperm quality in forced swimming test induced oxidative stress in nandrolone treated Wistar rats. *Acta Med Iran* 52:496-504.
- Mingoti GZ, Pereira RN, Monteiro CM (2003) Fertility of male adult rats submitted to forced swimming stress. *Braz J Med Biol Res* 36:677-681.
- Moayeri A, Mokhtari T, Hedayatpour A, Abbaszadeh HA, Mohammadpour S, Ramezanihah H, Shokri S (2017) Impact of melatonin supplementation in the rat spermatogenesis subjected to forced swimming exercise. *Andrologia* 18:1-9.
- Nadjarzadeh A, Shidfar F, Amirjannati N, Vafa MR, Montevalian SA, Gohari MR, Nazeri SA, Akhondi MM, Sadeghi MR (2013) Effect of Coenzyme Q10 supplementation on antioxidant enzymes activity and oxidative stress of seminal plasma: a double-blind randomised clinical trial. *Andrologia* 46:177-183.
- Nirupama M, Devaki M, Nirupama R, Yajurvedi HN (2013) Chronic intermittent stress-induced alterations in the spermatogenesis and antioxidant status of the testis are irreversible in albino rat. *J Physiol Biochem* 69:58-68.
- Ognjanovic BI, Markovic SD, Dorđević NZ, Trbojevic IS, Andras AS, Saicic ZS: Cadmium-induced lipid peroxidation and changes in antioxidant defense system in the rat testes (2010) Protective role of coenzyme Q10 and Vitamin E. *Reprod Toxicol* 29:191-197.
- Okon UA, Utuk II (2016) Ascorbic acid treatment elevates follicle stimulating hormone and testosterone plasma levels and enhances sperm quality in albino Wistar rats. *Nig Med J* 57:31-36.
- Olas B, Wachowicz B (2005) Resveratrol, a phenolic antioxidant with effects on blood platelet functions. *Platelets* 16:251-260.
- Ombelet W, Menkveld R, Kruger TF, Steeno O (1995) Sperm morphology assessment: historical review in relation to fertility. *Hum Reprod Update* 1:543-557.
- Ozaki A, Muromachi A, Sumi M, Sakai Y, Morishita K, Okamoto T (2010) Emulsification of Coenzyme Q10 using gum Arabic increase bioavailability in rats and human and improves food-processing suitability. *J Nutr Sci Vitaminol* 56:41-47.
- Price NL, Gomes AP, Ling AJ, Duarte FV, Martin-Montalvo A, North BJ, et al (2012) SIRT1 is required for AMPK activation and the beneficial effects of resveratrol on mitochondrial function. *Cell Metab* 15:675-690.
- Rodríguez-Bernaldo A, Lage-Yusty MA, López-Hernández J (2009) HPLC-analysis of polyphenolic compounds in Spanish white wines and determination of their antioxidant activity by radical scavenging assay. *Food Res Int* 42:1018-1022.
- Rodríguez I, Díaz A, Vaamonde D (2016) Assessment of the effect of prolonged forced swimming on CD-1 mice sperm morphology with and without antioxidant supplementation. *Andrologia* 48:277-281.
- Sabeti P, Pourmasumi S, Rahiminia T, Akyash F, Talebi AR (2016) Etiologies of sperm oxidative stress. *Int J Reprod Biomed* 14:231-240.
- Safarinejad MR (2009) Efficacy of coenzyme Q10 on semen parameters, sperm function and reproductive hormones in infertile men. *J Urol* 182:237-248.
- Safarinejad MR, Safarinejad S, Shafiei N, Safarinejad S (2012) Effects of reduced form of Coenzyme Q10 (Ubiquinol) on semen parameters in men with idiopathic infertility a double-blind, placebo controlled, randomized study. *J Urol* 188:526-531.
- Saki G, Rahim F, Alizadeh K (2009) Effect of forced swimming stress on count, motility and fertilization capacity of the sperm in adult rats. *J Hum Reprod Sci* 2:72-75.
- Saki G, Rahim F, Kaysi OA (2010) Effect of forced swimming stress on In-vivo fertilization capacity of rat and subsequent offspring quality. *J Hum Reprod Sci* 3:32-34.
- Samanta PK, Manna I, Jana K (2006) Effect of L- ascorbic acid supplementation on testicular oxidative stress and endocrine disorders in mature male rats exposed to intensive swimming exercise. *Reprod Med Biol* 5:145-153.
- Sanghishetti V, Ghongane BB, Nayak BB (2014) Effect of vitamin C on male fertility in rats subjected to forced swimming stress. *J Clin Diagn Res* 8: HC05-HC08.
- Slama R, Eustache F, Ducot B, Jensen TK, Jørgensen N, Horte A, Irvine S, Suominen J, Andersen AG, Auger J, Vierula M, Toppari J, Andersen AN, Keiding N, Skakkebaek NE, Spira A, Jouannet P (2002) Time to pregnancy and semen parameters: a cross-sectional study among fertile couples from four European cities. *Hum Reprod* 17:503-515.
- Sönmez M, Türk G, Yüce A (2005) The effect of ascorbic acid supplementation on sperm quality, lipid peroxidation and testosterone levels of male Wistar rats. *Theriogenology* 63:2063-2072.
- Tremellen K (2008) Oxidative stress and male infertility-a clinical perspective. *Hum Reprod Update* 14:243-258.
- Vaamonde D, Da Silva ME, Poblador MS, Lancho, JL (2006) Reproductive profile of physically active men after exhaustive endurance exercise. *Int J Sport Med* 27:680- 689.
- Vaamonde D, Da Silva- Grigoletto ME, Garcia- Manso JM, Vaamonde- Lemos R, Swanson RJ, Oehninger SC (2009) Response of semen parameters to three training modalities. *Fertil Steril* 92:1941-1946.
- Wyrobek AJ, Bruce, WR (1975) Chemical induction of sperm abnormalities in mice. *Proc Natl Acad Sci USA* 72:4425-4429.

Neosporosis and toxoplasmosis are two prevalent and important protozooses in dairy cows in small farms from Thessaly, Central Greece

M. Lefkaditis, G. Evagelopoulou, A. Sossidou, K. Spanoudis

School of Veterinary Medicine, Faculty of Health Sciences, University of Thessaly, Karditsa, Greece.

ABSTRACT: Neosporosis and toxoplasmosis are two significant protozoan parasitoses that can cause infertility and abortions in dairy cows worldwide. Those parasites, in contrary of other coccidia, are adapted to infect hosts by several routes of transmission. These include the consumption of sporulated cysts that have contaminated the environment, transplacental infection and accidental consumption of raw meat infected with bradyzoites. Infertility, abortions, neonatal mortality and other clinical symptoms in cattle in both parasitoses can cause severe financial losses, especially when these diseases acquire an endemic or epidemic manner.

The aim of this study was to report the prevalence of neosporosis and toxoplasmosis in dairy cattle as detected by ELISA technique, under the correlation with the age of infected animals. Blood samples were collected by venipuncture of the tail vein of 627 Holstein–Friesian dairy cows raised in 7 small farms (ranging from 55 the smaller to 137 the larger farm) from the region of Thessaly, central Greece. All farms have recorded a variety of infertility problems in the past. Animals were separated in three age groups; under 3 years old, between 3 and 6 years and over 6 years old. In a total of 627 cows from which the samples were taken and examined, 131 (20.89 %) of them were found positive for *N. caninum* while 51 (8.13 %) were positive for *T. gondii*. The prevalence in the three different age groups was recorded at 16.36%, 23.51% and 26.17% respectively for neosporosis and in the same age groups it was 5.20%, 9.16% and 13.08% respectively for toxoplasmosis. From the above results it becomes clear that preventative measures should be suggested to and adapted by the farmers, in order to decrease their financial losses.

Keywords: Neosporosis, toxoplasmosis, cattle, prevalence, economic impact, zoonosis

Corresponding Authors:
M. Lefkaditis, Trikalon 224, 43100, Karditsa, Greece
E-mail address: mlefkaditis@vet.uth.gr

Date of initial submission: 04-12-2019
Date of revised submission: 19-12-2019
Date of acceptance: 25-12-2019

INTRODUCTION

Neosporosis and toxoplasmosis, are two significant protozoan parasitoses that can cause infertility and abortions in dairy cows worldwide (Dubey and Shares, 2011; Dubey, 2003). These parasites, unlike other coccidia, are adapted to infect hosts by several routes of transmission.

Neospora caninum (Sarcocystidae) is an apicomplexan protozoan parasite which is the etiological agent of neosporosis (Dubey and Lindsay, 1996). In its life cycle, dogs and other related canids are the only definitive hosts that shed through their feces the unsporulated oocysts into the environment. Concurrently, many other species such as large and small ruminants, horses, rabbits, mice and others are intermediate hosts of the parasite (Dubey et al., 2007). Despite the large number of species that can be infected, to the present neosporosis has emerged as a serious disease only in cattle and dogs worldwide (Dubey et al., 2007; Dubey and Schares, 2011).

Toxoplasmosis is caused by *Toxoplasma gondii* (Sarcocystidae), a zoonotic parasite of great importance and global distribution (Robert et al., 2012). Toxoplasmosis is a protozoosis, in which the cat and other Felidae serve as final hosts, whereas nearly all warm-blooded animals and human can be infected and serve as intermediate hosts (Sukthana, 2006; Dubey, 2009). Infected cats are capable of shedding millions of oocysts with their faeces (Dabritz and Conrad, 2010). These oocysts mature in the environment, where they can survive for 12-18 months, depending on climatic conditions, thereby serving as an important source of infection for grazing animals (Sukthana, 2006; Baxton, 1998).

Infertility, abortions, neonatal mortality and other clinical symptoms in cattle in both parasitoses can cause severe financial losses, especially when these diseases acquire an endemic or epidemic character. The economic impact of these parasitoses is directly related to the costs associated with abortions and subsequent loss of the calf and indirectly with the cost of veterinary services, rebreeding, loss of milk yield and possible replacement of the cows that aborted (Ansari-Lari and Rowshan-Ghasrodashi, 2017). Moreover, toxoplasmosis is also a disease of zoonotic importance (Sukthana, 2006).

The aim of this study was to report the prevalence of neosporosis and toxoplasmosis in dairy cattle as detected by an ELISA technique, in combination with

the age of infected animals, in order to suggest preventative measures to the farmers of this area as well as other areas with similar problems.

MATERIALS AND METHODS

Blood samples were collected by tail vein venipuncture from 627 Holstein-Friesian dairy cows raised in 7 small farms (ranging from 55 the smaller to 137 the larger farm) from the region of Thessaly, central Greece. All farms have recorded infertility problems in the past.

The samples were separated in three groups according to the age of the cows. The first group included cows aged less than three years, the second between 3 to 6 years and the third those above 6 years old with 269, 251 and 107 cows respectively.

All blood samples were retrieved from the tail vein at the time of the examination procedure for gestation and collected in 5ml plastic test tubes containing EDTA. Each test tube was marked with the date, the animal's ear tag number and its age group. The collected samples were stored at 4°C and transferred to the laboratory, where they were centrifuged at 2000rpm for 15 minutes. The sera were tested for antibodies against *N. caninum* and *T. gondii* using the commercial ELISA test kits, ID Screen, according to the manufacturer's instructions.

The data from the serological results and the age of the cows tested in this research were edited and analyzed statistically using the chi-square (χ^2) test. The statistical significance level used was $P < 0.05$.

It should be pointed that in all examined farms infertility problems had been recorded and free ranged dogs and cats that did not receive appropriate veterinary care were present.

RESULTS

A total of 627 cows were examined, from which 131 (20.89 %) were found positive for *N. caninum* and 51 (8.13 %) for *T. gondii*.

The prevalence in the three different age groups was recorded at 16.36%, 23.51% and 26.17% for *N. caninum* infection (Table 1), while for *T. gondii* infection it was 5.20%, 9.16% and 13.08% respectively (Table 2).

Table 1. Prevalence of neosporosis in dairy cattle in relation to their age

Age of cattle	Number of seropositive	Number of seronegative	Prevalence of neosporosis %
<3 years n=269	44	225	16.36
3-6 years n=251	59	192	23.51
>6 years n=107	28	79	26.17
Total n=627	131	496	20.89

Table 2. Prevalence of toxoplasmosis in dairy cattle in relation to their age

Age of cattle	Number of seropositive	Number of seronegative	Prevalence of toxoplasmosis %
<3 years n=269	14	255	5.20
3-6 years n=251	23	228	9.16
>6 years n=107	14	93	13.08
Total N=627	51	576	8.13

DISCUSSION

According to data from previous studies worldwide, the prevalence of *N. caninum* in cattle has been reported to show a wide range; in South America it is reported to be between 7.6% and 76.9% (Cedepo and Benavides, 2013; Sousa et al., 2012), in Asia between 5.7% and 43% (Nazir et al., 2013; Koiwai et al., 2006), while in Africa it ranges only between 10.7% and 19.6% (Ghalimi et al., 2012; Ibrahim et al., 2012) and finally in Australia the prevalence is found to be 10.2% (Hall et al., 2005). Moreover, the prevalence of *N. caninum* in cattle in some European countries (Germany, The Netherlands, Spain, Romania and Sweden) ranges from 16% to 76 % (Imre et al., 2012; Bartels et al., 2006; Ortega-Mora, 2006).

There are studies from Balkan countries that have reported higher prevalence of neosporosis in cattle than our findings. Cvetojević et al., (2018) recorded prevalence 25% in Serbia, Mitrea et al., (2012) reported (41.7%) and Gavrea et al., (2008, 2010) recorded overall prevalence 55.95% from dairy cows from Romania. Moreover there are also similar surveys which have described prevalence of *N. caninum* antibodies at 27%, 24.4% and 22% in Germany, Italy and Denmark, respectively (Magnino et al, 1999; Jensen et al 1999; Schares et al, 1998). On the contrary,

there are several studies which reported lower prevalence than our findings in Europe. They have recorded prevalences of 12.2% in Belgium (De Meerschman et al, 2000), 4.1% in Germany (Conraths et al, 1996), 3.3% in Hungary (Hornok et al, 2006), 12.6% in Ireland (McNamee et al, 1996), 11.2% in Spain (Caetano-da-Silva et al, 2004) and 3.1% in Czech Republic (Václavěk et al, 2003).

N. caninum causes abortions in both dairy and beef cattle. The abortions can occur from the third month of gestation until parturition (Reiterova et al., 2009; Dubey et al., 2007; Wouda et al., 1999). This parasite can also cause fetal viability disorders or neurological birth defects in newborn calves (Lassen et al., 2012; Malaguti et al., 2012) and those younger than 2 months of age (Dubey, 2003). The infected young calves may present neurological signs, low birth weight (Dubey and Schares, 2011), difficulty to rise and stand, flexed or hyperextended hind and/or forelimbs, and in some cases exophthalmia or asymmetrical appearance of the eyes. However, most of the calves born congenitally-infected remain clinically free of neosporosis signs (Dubey 2003; Bielanski and Phipps-Todd 2002).

Toxoplasmosis in cattle is usually asymptomatic or causes mild symptoms while a primary infection in pregnant animals is capable of establishing a placental and fetal infection, which may result in fetal death and resorption, abortion, or stillbirth (Dubey and Jones, 2008; Dubey, 1992). Although cattle are considered as poor hosts for *T. gondii* and good hosts for *N. caninum*, *T. gondii* infections could also cause economic losses and an increased potential for transmission to other animals and humans (Dubey and Jones, 2008).

There are studies worldwide that report the prevalence of *T. gondii* in cattle in some regions of the world showing a large variation in the reported proportions of positive findings.

Compared to our results, some researchers record lower prevalence of infection in cattle, such as in Poland 3.15% (Lucyna et al., 2013), 0% in Iran (Sharif et al, 2007), 2.3% in China (Yu et al, 2007) and 6.6% in Central Ethiopia (Bekele and Kasali, 1989) while higher seroprevalence values were found in Serbia (76.3%) (Klun I, et al., 2006), France (7.8%) (Gilot-Fromont et al., 2009), Italy 11.5% (Vesco et al., 2006), eastern (23.33%) and central parts (22.73%) of Iran (Asgari et al, 2010), China (9.5%) (Deng et al., 2018), South Asia (27.9%) (Khan et al., 2017), Afri-

ca (12%) (Tonouhewa et al., 2017) and Brazil (71%) (Santos et al., 2009).

With regard to the age of infected cows with *N. caninum* in our research, which was obtained in small farms, we recorded a significant increase of the prevalence ($p < 0.05$) after the age of 3 years. A positive relation between the age of the cows and the infection with *N. caninum* has also been reported in other studies, from the northwestern America (Sanderson et al., 2000, Dyer et al., 2000), Spain (Bartels et al., 2006) and Denmark (Jensen et al., 1999). On the other hand, studies from Canada and Sweden (Waldner et al., 1998, Bartels et al., 2006) have reported a negative age effect on the prevalence of seropositive animals in dairy cattle.

With respect to the age of infected cows with *T. gondii*, our results showed over the double percentage of prevalence (13.08% compared to 5.2%) in the group of cows aged more than 6 years compared to these aged less than 3 years. These findings are similar to those of Jittapalapong et al., (2005), Teshale et al., (2007), and Tilahun et al., (2019), who reported a low prevalence in young animals and a high one in adults. This could be easily justified by the longer exposure of adults to *T. gondii* infection (Dubey, 2019). The longer animals live the more likely they are to be exposed to *T. gondii* sources (Rouatbi et al., 2019; Klun et al. 2006). A fact that we also agree on, is that in small farms the most important source of *T. gondii* for animals is the consumption of oocysts from the environment and the frequent presence of rodents.

Some researchers report that beef, especially when it is raw or undercooked, is considered to be the most important source of human infections with *T. gondii* (Baril et al., 1999; Cook et al., 2000; Jones et al., 2009; Opsteegh et al., 2011). Congenital toxoplasmosis in humans may cause abortion, neonatal death, or fetal abnormalities mainly in the neuromuscular system and eyes (Hayde and Pollak, 2000).

Cows can be infected via the environmental cyst reservoir or by accidental consumption of a rodent or other intermediate host that carries tissue cysts. Appropriate rodent control is therefore one of the measures that helps in the prevention of the infection of farm animals and cats. (Jones and Dubey, 2012). Moreover calves may acquire the infection prenatally, transplacentally (Canada et al., 2002; Costa et al., 2011), or postnatally or from other feed, water or the environment (Dubey, 2003).

In small dairy farms there are some risk factors such as the lack of proper hygienic measures, the easier access of dogs and cats in the facilities, the environment and feeding materials of cows. All these reasons lead to a higher prevalence of neosporosis and toxoplasmosis than expected. One other important risk factor is that animals in Greece are more frequently grazing pastures rather than kept in feed-lots and farmed intensively. This point has also been mentioned in reviews by Tenter et al, (2000), Klun et al. (2006), and Dubey et al, (2019). Moreover, epidemiological studies have concluded that pastures may be the most common source of these/parasitic infections (Rouatbi,et al, 2019; Gebremedhin Ortega-Mora et al., 2007).

Veterinarians' duty is the continuous consulting and training of farmers on the modes of transmission of these parasitoses as well as on the methods and measures that can be utilized to prevent exposure of uninfected animals and transmission to the entire herd, highlighting the zoonotic potential of toxoplasmosis. Moreover, veterinarians should inform the farmers about the increased cost of losses caused by neosporosis and toxoplasmosis and the additional costs that include the veterinary services and everything that is associated with establishing diagnosis, rebreeding, possible loss of milk yield and possible replacement costs of cows with fertility issues due to these parasitoses.

Under the scope of one-health, animal well-being and profit maximization, *N. caninum* and *T. gondii* infections of dairy cows in small farms should not be neglected. The most important factor in their control is to prevent the contamination of feed, water, bedding and pastures with canine and feline faeces respectively. To this direction, dogs must be prohibited to consume aborted fetuses, afterbirths and dead calves, supplies (water, feeds and bedding) and the facilities must be periodically examined for specific pathogens, in combination with rodent control and veterinary monitoring of dogs and cats that live in close proximity with the herd. These are some key-point measures that should be adopted by farmers, in combination with their own appropriate behavior of good hygiene. In case of neosporosis, in every way seropositive calves have to be excluded from breeding.

CONFLICT OF INTEREST

None declared by the authors.

REFERENCES

- Ansari-Lari M, Rowshan-Ghasrodashti A, Jesmani H, Masoudian M, Badkoobeh M (2017) Association of *Neospora caninum* with reproductive performance in dairy cows: A prospective study from Iran Volume 8, Issue 2, Spring Pages 109-114
- Asgari G, Mehrabani D, Moazeni M, Akrami Mohajeri F, Kalantari M, Motazedian MH, Hatam GR, and Davarpanah MA (2010) The Seroprevalence of Bovine Toxoplasmosis in Fars Province, Southern Iran. *Asian Journal of Animal and Veterinary Advances*, 5: 210-216.
- Baril L, Ancelle T, Goulet V, Thulliez P, Tirard-Fleury V, Carme B (1999) Risk factors for Toxoplasma infection in pregnancy: a case control study in France. *Scand J Infect Dis.*; 31: 305–309
- Bartels CJM, Arnaiz-Seco JI, Ruiz-Santa-Quitera A, Björkman C, Frössling J, Von Blumröder D, Conraths FJ, Schares G, Van Maanen C, Wouda W, and Ortega-Mora LM (2006) Supranational comparison of *Neospora caninum* seroprevalences in cattle in Germany, The Netherlands, Spain and Sweden, *Vet. Parasitol.* 137 pp. 17–27.
- Bartels CJM, Van Schaik G, Veldhuisen JP, Van den Borne BHP, Wouda W, and Dijkstra T (2006) Effect of *Neospora caninum*-serostatus on culling, reproductive performance and milk production in Dutch dairy herds with and without a history of *Neospora caninum*-associated abortion epidemics. *Preventive Veterinary Medicine*. 77, 186-198.
- Bekele T, Kasali OB (1989) Toxoplasmosis in sheep, goats and cattle in central Ethiopia. *Vet Res Commun* 13, 371–375.
- Bielanski A, Phipps-Todd B, and Robinson J (2002) Effect of *Neospora caninum* on in vitro development of preimplantation stage bovine embryos and adherence to the zona pellucida. *Veterinary Record*. 150, 316-318.
- Buxton D. 1998 Protozoan infections (*Toxoplasma gondii*, *Neospora caninum* and *Sarcocystis* spp.) in sheep and goats: recent advances,” *Veterinary Research*, vol. 29, no. 3–4, pp. 289–310,.
- Caetano-da-Silva A, Ferre I, Aduriz G, Alvarez-Garcia G, del-Pozo I, Atxaerandio R, Regidor-Cerrillo J, Ugarte-Garagalza C, and Ortega-Mora LM (2004). *Neospora caninum* infection in breeder bulls: seroprevalence and comparison of serological methods used for diagnosis. *Vet. Parasitol.* 124:19–24.
- Canada N, Meireles CS, Rocha A, da Costa JM, Erickson MW, Dubey JP 2002 Isolation of viable *Toxoplasma gondii* from naturally infected aborted bovine fetuses. *J. Parasitol.* 88, 1247–1248.
- Cedeño Q, and Benavides B (2013) Seroprevalence and risk factors associated to *Neospora caninum* in dairy cattle herds in the municipality of Pasto, Colombia. *Revista MVZ Córdoba*. 18, 3311-3316
- Conraths FJ, Bauer C, Becker W (1996) Detection of antibodies against *Neospora caninum* in cows on Hessian farms with abortion and fertility problems. *Dtsch Tierarztl Wochenschr.* Jun; 103(6):221-4
- Cook AJC, Gilbert RE, Buffolano W, Zufferey J, Petersen E, Jenum PA, Foulon W, Semprini AE, Dunn DT (2000) Sources of *Toxoplasma* infection in pregnant women: european multicentre case-control study. *Br Med J.*; 321: 142–147.
- Costa DG, Marvulo MF, Silva JS, Santana S.C, Magalhaes FJ, Filho CD, Ribeiro VO, Alves LC, Mota RA, Dubey, JP, Silva JC (2012) Seroprevalence of *Toxoplasma gondii* in domestic and wild animals from the Fernando de Noronha, Brazil. *J. Parasitol.* 98, 679–680
- Cvetojević Đ, Miličević V, Kureljušić B, Savić B (2018) Seroprevalence of *Neospora caninum* in dairy cows in Belgrade city area, Serbia. *J HELLENIC VET MED SOC* 2018, 69(2): 979-983 *IEKE* 2018, 69(2): 979-983
- Dabritz HA, and Conrad PA (2010) Cats and *Toxoplasma*: implications for public health. *Zoonoses and Public Health* 57:34–52
- De Meerschman F, Focant C, Boreux R, Leclipteux T, and Losson B (2000) Cattle neosporosis in Belgium: a case-control study in dairy and beef cattle. *Int. J. Parasitol.* 30:887–890.
- Deng H, Dam-Deisz C, Luttikholt S, Maas M, Nielen, M, Swart A, Vellemma P, van der Giessen J, Opsteegh M (2016) Risk factors related to *Toxoplasma gondii* seroprevalence in indoor-housed Dutch dairy goats. *Prev. Vet. Med.* 124, 45–51
- Dubey J, and Schares G (2011) Neosporosis in animals the last five years. *Veterinary parasitology*. 180, 90-108.
- Dubey JP (1992) Isolation of *Toxoplasma gondii* from a naturally infected beef cow. *J. Parasitol.* 78, 151–153
- Dubey JP (2003) Review of *Neospora caninum* and neosporosis in animals. *The Korean journal of parasitology*. 41, 1-16.
- Dubey JP (2019) Toxoplasmosis of Animals and Humans. Available online: <https://www.crcpress.com/Toxoplasmosis-of-Animals-and-Humans/Dubey/p/book/9781420092363>
- Dubey JP, and Lindsay DS (1996) A review of *Neospora caninum* and neosporosis. *Vet Parasitol*; 67: 1-59)
- Dubey JP, Jenkins MC, Kwok OCH, Ferreira LR, Choudhary S, Verma SK, Villena I, Butler E, and Carstensen M (2013) Congenital transmission of *Neospora caninum* in white-tailed deer (*Odocoileus virginianus*). *Veterinary Parasitology*. 196, 519-522.
- Dubey JP, Jones JL (2008) *Toxoplasma gondii* infection in humans and animals in the United States. *Int. J. Parasitol.*, 38, 1257–1278
- Dubey JP, Schares G, and Ortega-Mora LM (2007) Epidemiology and Control of neosporosis and *Neospora caninum*. *Clin Microbiology Rev. Apr*; 20(2):323-67.
- Dubey JP. (2009) History of the discovery of the life cycle of *Toxoplasma gondii*. *Int Journal Parasit.*, Jul 1;39(8):877-82.
- Dyer RM, Jenkins MC, Kwok OCH, Douglas LW, and Dubey JP (2000). Serologic survey of *Neospora caninum* infection in a closed dairy cattle herd in Maryland: risk of serologic reactivity by production groups. *Veterinary Parasitology*, 90:171–181.
- Gavrea R, Cozma V (2010) Seroprevalence of *Neospora caninum* in cows with reproductive failure in center and northwest of Romania. *Sci Parasitol*, 11, 67–70.
- Gebremedhin EZ, Agonafr A, Tessema TS, Tilahun G, Medhin G, Vitale M, Di Marco V, Cox E, Vercruysse J, Dorny P (2013) Seroepidemiological study of ovine toxoplasmosis in East and West Shewa Zones of Oromia Regional State, Central Ethiopia. *BMC Vet. Res.*, 9,
- Ghalimi F, China B, Ghalimi A, Hammitouche D, and Losson B (2012) Study of the risk factors associated with *Neospora caninum* seroprevalence in Algerian cattle populations. *Res Vet Sci*. 93, 655-661.
- Gilot-Fromont E, Aubert D, Belkilani S, Hermitte P, Gibout O, Geers R, Villena I (2009) Landscape, herd management and within-herd seroprevalence of *Toxoplasma gondii* in beef cattle herds from Champagne-Ardenne, France. *Vet Parasitol.*; 161: 36–40.
- Hall CA, Reichel MP, Ellis JT (2005) *Neospora* abortions in dairy cattle: diagnosis, mode of transmission and control. *Vet Parasitol.* 2005 Mar 31; 128(3-4):231-41.
- Hayde M, Pollak A (2000) Clinical picture: neonatal signs and symptoms, in Congenital toxoplasmosis: scientific background, clinical management and control. Ambroise-Thomas P, Petersen E, Editors. Springer-Verlag France: Paris. p. 153–164
- Holec-Gąsior L, Drapała D, Dominiak-Górski B, Kur J (2013) Epidemiological study of *Toxoplasma gondii* infection among cattle in Northern Poland. *Ann Agric Environ Med.* ;20(4):653–656
- Hornok S, Edelhofer R, and Hajtos I (2006) Seroprevalence of neosporosis in beef and dairy cattle breeds in Northeast Hungary. *Acta Vet. Hung.* 54:485–491.
- Ibrahim AM, Elfahal AM, El Hussein AR (2012) First report of *Neospora caninum* infection in cattle in Sudan Tropical Animal Health Production, 44. pp. 769-772
- Imre K, Morariu S, Ilie MS, Imre M, Ferrari N, Genchi C, Dărăbuș G (2012) Serological survey of *Neospora caninum* infection in cattle herds from Western Romania. *J Parasitol.* Jun; 98(3):683-5.
- Jensen AM, Bjorkman C, Kjeldsen AM, Wedderkopp A, Willadsen C, Uggla A, Lind P (1999) Association of *Neospora caninum* seropositivity with gestation number and pregnancy outcome in Danish dairy herds. *Prev Vet Med.*;40:151–163
- Jittapalapong S; Sangvaranond A, Pinyopanuwat N, Chimnoi W, Khachae-ram W, Koizumi S, Maruyama S (2005) Seroprevalence of *Toxoplasma gondii* infection in domestic goats in Satun Province, Thailand.

- Vet. Parasitol., 127, 17–22.
- Jones JL, Dargelas V, Roberts J, Press C, Remington JS, Montoya JG (2009) Risk factors for *Toxoplasma gondii* infection in the United States. Clin Infect Dis. 2009; 49: 878–884.
- Jones JL, and Dubey JP. (2012). Foodborne toxoplasmosis. Clin Infect Dis Sep; 55(6):845–51.
- Khan MU, Rashid I, Akbar H, Islam S, Riaz F, Nabi H, Ashraf K, Singla LD (2017) Seroprevalence of *Toxoplasma gondii* in South Asian countries. Rev. Sci. Tech. 36,981–996
- Klun I, Djurkovic-Djakovic O, Katic-Radivojevic S, Nikolic A (2006) Cross-sectional survey on *Toxoplasma gondii* infection in cattle, sheep and pigs in Serbia: seroprevalence and risk factors. Vet Parasitol.; 135: 121–131.
- Koiwai M, Hamaoka T, Haritani M, Shimizu S, Tsutsui T, Eto M, Yamane I (2005) Seroprevalence of *Neospora caninum* in dairy and beef cattle with reproductive disorders in Japan. Vet Parasitol. Jun 10; 130(1-2):15–8.
- Lassen B, Orro T, Alekseev A, Raaperi K, Jarvis T, Viltrop A (2012) *Neospora caninum* in Estonian dairy herds in relation to herd size, reproduction parameters, bovine virus diarrhoea virus, and bovine herpes virus 1. Vet Parasitol. 2012 Nov 23; 190(1-2):43–50.
- Magnino S, Vigo P G, Fabbi M, Colombo M, Bandi C, and Genchi C (1999) Isolation of a bovine *Neospora* from a newborn calf in Italy. Vet. Rec. 144:456.
- Malaguti JM, Cabral AD, Abdalla RP, Salgueiro YO, Galletti NT, Okuda LH, Cunha EM, Pituco EM, Del Fava C (2012) *Neospora caninum* as causative agent of bovine encephalitis in Brazil. Rev Bras Parasitol Vet. Jan-Mar; 21(1):48–54.
- McNamee PT, Trees AJ, Guy F, Moffett D, and Kilpatrick D (1996) Diagnosis and prevalence of neosporosis in cattle in Northern Ireland. Vet. Rec. 138:419–420.
- Mitrea IL, Enachescu V, Radulescu R, Ionita M (2012) Seroprevalence of *Neospora caninum* infection on dairy cattle in farms from southern Romania. J Parasitol 98:69–72
- Nazir MM, Maqbool A, Khan MS, Sajjid A, Lindsay DS (2013) Effects of age and breed on the prevalence of *Neospora caninum* in commercial dairy cattle from Pakistan. J Parasitol. Apr; 99(2):368–70.
- Opsteegh M, Teunis L, Zuchner A, Koets M, Langelaar J, van der GiessenLow (2011) Predictive value of seroprevalence of *Toxoplasma gondii* in cattle for detection of parasite DNA. International Journal for Parasitology. Volume 41, Issues 24.March 2011, Pages 343–354
- Ortega-Mora LM (2006) Supranational comparison of *Neospora caninum* seroprevalences in cattle in Germany, the Netherlands, Spain and Sweden. Vet. Parasitol. 137:17–27.
- Reiterová K, Špilovská S, Antolová D, and Dubinský P (2009) *Neospora caninum*, potential cause of abortions in dairy cows: The current serological follow-up in Slovakia. Veterinary Parasitology. 159, 1–6.
- Robert-Gangneux F, Dardé M (2012) Epidemiology of and diagnostic strategies for toxoplasmosis. Clinical Microbiology Reviews, 25, 264–296
- Rouatbi M; Amairia S, Amdouni Y, Boussaadoun MA, Ayadi O, Al-Hosary AAT, Rekik M, Ben Abdallah R, Aoun K, Darghouth MA (2019) *Toxoplasma gondii* infection and toxoplasmosis in North Africa: A review. Parasite 26, 6.
- Sanderson MW, Gay JM, and Baszler TV (2000) *Neospora caninum* seroprevalence and associated risk factors in beef cattle in the northwestern United States. Vet. Parasitol. 90:15–24.
- Santos TR, Costa AJ, Toniollo GH, Luvizotto MCR, Benetti AH, Santos RR, Matta DH, Lopes WZ, Oliveira JA, Oliveira GP (2009) Prevalence of anti-*Toxoplasma gondii* antibodies in dairy cattle, dogs, and humans from the Jauru micro-region, Mato Grosso state, Brazil. Vet Parasitol.; 161: 324–326.
- Schares G, Peters MR, Wurm Barwald A, and Conraths FJ (1998) The efficiency of vertical transmission of *Neospora caninum* in dairy cattle analyzed by serological techniques. Vet. Parasitol. 80:87–98.
- Sharif M, Gholami S, Ziaei H, Daryani A, and Laktarashi B (2007) Seroprevalence of *Toxoplasma gondii* in cattle, sheep and goats slaughtered for food in Mazandaran province, Iran during 2005. Vet. J. 174(2): 422–424
- Sousa Maria E, Wagner JN. Porto P, Albuquerque PF, Orestes L. Souza N, Eduardo B, Faria J, Pinheiro JW, and. Mota RA (2012) Seroprevalence and risk factors associated with infection by *Neospora caninum* of dairy cattle in the state of Alagoas, Brazil. Pesq. Vet. Bras. [online]., vol.32, n.10, pp.1009–1013.
- Sukthana Y (2006). Toxoplasmosis: beyond animals to humans. Trends in Parasitology, 22, 137–142.
- Tenter AM, Heckeroth AR, Weiss LM (2000) *Toxoplasma gondii*: From animals to humans. Int. J. Parasitol. 30, 1217–1258
- Teshale SA, Dumetre ML, Darde B, Merger D (2007) Study on Toxoplasmosis in sheep and goats in Debre Birhan and surrounding areas in Ethiopia. Bull. Anim. Health Prod. Afr., 50, 138–147.
- Tilahun B, Tolossa YH, Tilahun G, Ashenafi H, Shimelis S (2019) Seroprevalence and Risk Factors of *Toxoplasma gondii* Infection among Domestic Ruminants in East Hararghe Zone of Oromia Region, Ethiopia. Available online: <https://www.hindawi.com/journals/vmi/2018/4263470/abs/>
- Tonouhewa AB, Akpo Y, Sessou P, Adoligbe C, Yessinou E, Hounmanou YG, Assogba MN, Youssao I, Farougou S (2017) *Toxoplasma gondii* infection in meat animals from Africa: systematic review and meta-analysis of sero-epidemiological studies. Vet World 10, 194–208.
- Václavěk P, Koudela B, Modrý D, and Sedláček K. (2003) Seroprevalence of *Neospora caninum* in aborting dairy cattle in the Czech Republic. Vet. Parasitol. 115:239–245.
- Vesco G, Currò V, Liga F, Villari S (2005). Seroprevalence of *Toxoplasma gondii* in sheep and cattle slaughtered in Palermo
- Waldner CL, Janzen ED, and Ribble CS (1998) Determination of the association between *Neospora caninum* infection and reproductive performance in beef herds. J. Am. Vet. Med. Assoc. 213:685–690.
- Wouda W, Bartels CJM, and Moen AR (1999) Characteristics of *Neospora caninum* associated abortion storms in dairy herds in the Netherlands 16. (1995 to 1997). Theriogenology; 52: 233–45).
- Yu J, Xia Z, Liu Q, Liu J, Ding J, and Zhang W (2007) Seroepidemiology of *Neospora caninum* and *Toxoplasma gondii* in cattle and water buffaloes *Bubalus bubalis* in the People's Republic of China. Veterinary Parasitology, 143(1), 79–85

Effect of Purslane powder and Zinc supplementation on the performance, egg quality, antioxidant system and liver histopathology of lead-exposed laying Quails

S. Faryadi, A. Sheikhahmadi, A. Sadeghi

Department of Animal Science, Faculty of Agricultural, University of Kurdistan, Sanandaj, Iran

ABSTRACT: To determine effects of Purslane (*Portulaca oleracea*) and zinc supplementation in lead exposed quails, 180 adult female quails allocated into 9 groups. 1. Negative Control (NC, Fed with a corn-soy-based diet), 2. Corn-soy-based diet supplemented with 500 mg/kg lead acetate (Positive control), 3. Positive control supplemented with 0.5 % Purslane powder (PP), 4. Positive control supplemented with 1 % PP, 5. Positive control supplemented with 1.5 % PP, 6. Positive control supplemented with 140 mg/kg zinc, 7. Positive control supplemented with 0.5 % PP + 140 mg/kg zinc, 8. Positive control supplemented with 1 % PP + 140 mg/kg zinc, 9. Positive control supplemented with 1.5 % PP + 140 mg/kg zinc. Lead administration significantly decreased body weight, egg mass, egg production, liver weight, Haugh unit, serum concentrations of hematocrit, total protein, triglycerides and very low density lipoprotein concentration of quails ($P<0.05$). Serum alanine aminotransferase and lactate dehydrogenase activity significantly increased when compared with the NC ($P<0.05$). Superoxide dismutase and glutathione peroxidase activity in the liver and erythrocyte showed significant decrease ($P<0.05$). Lead administration resulted in a significant decrease ($P<0.05$) in total antioxidant capacity and increase in serum malondialdehyde. However, supplementation diet with 1.5% of PP reduced serum and liver malondialdehyde ($P<0.05$). Liver tissue of the birds in NC showed normal lobular architecture with central veins, radiating hepatic cords and portal triads, while this organ showed mild to severe tissue changes in lead exposed groups ($P<0.05$). It can be concluded that lead-exposure induced production of free radicals and weakened the antioxidant defenses of the quails. However, antioxidant status of quails partially improved when fed diets supplemented with 1.5 % PP and 140 ppm Zn.

Keywords: Performance, Liver histopathology, Japanese quails.

Corresponding Authors:

Ardashir Sheikhahmadi, Department of Animal Science, Faculty of Agricultural,
University of Kurdistan, Sanandaj, Iran
E-mail address: A.sheikhahmadi@uok.ac.ir

Date of initial submission: 08-12-2019
Date of revised submission: 19-01-2020
Date of acceptance: 23-03-2020

INTRODUCTION

Lead is a toxic metal that is widely used in many industrial activities. It is well known that lead contamination occurs easily via contaminated food, water and food additives which ultimately enter the human body and threaten health and wellbeing (Yuan et al., 2013). Toxicity of lead and its compounds in animals and humans can be vary from soft tissues damage, mainly liver and kidney, to reduction of hematopoiesis, reproductive and nervous systems (Gupta, 2011).

Reactive oxygen species (ROS) production has been known as a main effect of heavy metals toxicity causing cellular oxidative stress. ROS are the by-products of degradation reactions in many tissues that affect normal metabolism of cells by damaging different cellular components for instance fatty acids, proteins and DNA (Xienia, 2000). Damron et al. (1969) reported that supplementation of 1000 ppm lead in the diet lead to a reduction in the growth rate in young broiler chickens. Morgan et al. (1975) reported growth rate reduction and anemia in Japanese quails fed diets containing 500 ppm lead. Saly et al. (2004) reported that dietary lead supplementation at 1000 ppm decreased egg weight, eggshell strength and eggshell thickness in laying hens. Naturally, different protective cellular mechanisms are developed to prevent peroxidation damage including enzymatic defense system (antioxidant enzymes) and free radicals scavengers (antioxidants). Antioxidants are chemical compounds that play an important role to protect human body against damage by ROS. Free radicals formed in the body due to normal physiological process can be scavenged by antioxidants (Usha and Pushpalatha, 2017).

Trace elements are interfered in the metabolic activities through metalloenzymes which are essential for the antioxidant conservation of cells in poultry (Petrovic et al., 2011). Zinc (Zn) is one of the trace elements that play a role in the antioxidant system of the body. It is reported that Zn is an indispensable part of the SOD, which helps defend the broiler chickens against ROS production (Song et al., 2017). Cerklewska and Forbes (1976) showed that dietary Zn supplementation (200 ppm) could reduce lead concentration in the blood, liver and kidneys in rats exposed to 200 ppm of lead and alleviate lead toxicity. Rafique et al. (2010) demonstrated that the toxic effects of lead on male rats reproductive system decreased by Zn supplementation via activation antioxidant mechanisms.

During the last few decades, we have seen an increasing trend in the use of medicinal plants and extracts in poultry nutrition. Several studies showed that phenols, mostly flavonoids of some plants have

antioxidant properties. One of the well known plants with effective antioxidant properties is Purslane (*Portulaca oleracea*). Purslane as a weed grows in the tropical and subtropical regions of the world (Sedaghati et al., 2019). It is a rich source of flavonoids and other antioxidant compounds such as α -tocopherol, ascorbic acid, and β -carotene as well as glutathione (Barbosa-Filho et al., 2008). Sadeghi et al. (2016) showed that the antioxidant status of broiler chickens was improved by dietary supplementation of Purslane powder. Ghorbani et al. (2013) reported that blood superoxide dismutase (SOD) activity and serum malondialdehyde (MDA) concentration were respectively increased and decreased in broiler chickens fed diets supplemented with 2% Purslane powder.

The effect of the Purslane powder in alleviation of lead toxicity has never been investigated; however previous studies reported the effect of some plants on lead toxicity in mice. Tangpong and Satarug (2010) found that *Thunbergia laurifolia* (Linn.) extract can ameliorate oxidative stress and reduce cell death in lead-exposed mice. Also, these researchers reported co-treatment of lead with *Thunbergia laurifolia* Linn. aqueous extract at 100 or 200 mg/kg led to increased plasma total antioxidant capacity (TAC). Khalaf et al. (2012) reported that green tea improves glutathione content and SOD activity in the brain of lead exposed rats. Although different natural herbs or their extracts has been studied to decrease toxic effects of lead, however, there is no previous study investigated the effect of Purslane in lead toxicity. Furthermore, it is demonstrated that each antioxidant has specificity for a particular ROS and supplementation of a single antioxidant might be not sufficient to prevent the oxidative stress caused by lead exposure. Therefore, in the present study, we investigated the effect of dietary Purslane powder, Zn and their combination on performance, egg quality, antioxidant status and liver histology in lead-exposed laying quails.

MATERIALS AND METHODS

Sampling and plant preparation

Purslane plant was purchased from a local field in Sanandaj (Kurdistan Province, Iran). After cleaning the whole plant including seeds, leaves, stems, and roots air drying, they were finely grounded to a size of 2 mm using a typical mill. Dried purslane plant powder stored in an air-tight containers at room temperature until use (Sadeghi et al., 2016). Proximate analysis of purslane plant powder was determined using methods described by AOAC (1994) with 6 replicates. The results of proximate analysis indicated

that Purslane powder contains 931.55 ± 4.11 Dry matter (g/kg), 241.90 ± 15.39 Ash (g/kg), 195.15 ± 6.12 Crude protein (g/kg), 16.83 ± 5.84 Crude fiber (g/kg), 85.47 ± 15.62 Ether extract (g/kg).

Antioxidant capacity of Purslane powder

The total phenolic compounds (TPC) in the Purslane powder were determined using the Folin-Ciocalteu reagent according to Halicia et al. (2005). 1,1-diphenyl-2-picrylhydrazyl free radical scavenging activity (DPPH, IC₅₀) of the Purslane was determined by the method reported by Gulcin et al. (2004). The ferric reducing property (FRAP) test was measured using the assay described by Yen and Chen (1994). The results of analysis antioxidant properties indicated that Purslane powder contains 326.96 ± 15.92 TPC (mg GAE/100 g), 1.27 ± 0.09 IC₅₀ (mg/ml), 3.73 ± 0.23 FRAP (mg GAE/g).

Birds, Management and Treatments

All methods used in this study were approved by the guidelines of the Animal Ethics Committee in

University of Kurdistan. A total of 180 14-week-old laying Japanese quails were randomly distributed between 36 cages. Feed (Table 1) and water were offered *ad libitum*. Light was provided for 16 h daily throughout the experiment. The animals were divided into 9 experimental treatments included into 9 groups. 1. Negative Control (NC, Fed with a corn-soy-based diet), 2. Corn-soy-based diet supplemented with 500 mg/kg lead acetate (Positive control), 3. Positive control supplemented with 0.5 % Purslane powder (PP), 4. Positive control supplemented with 1 % PP, 5. Positive control supplemented with 1.5 % PP, 6. Positive control supplemented with 140 mg/kg zinc, 7. Positive control supplemented with 0.5 % PP + 140 mg/kg zinc, 8. Positive control supplemented with 1 % PP + 140 mg/kg zinc, 9. Positive control supplemented with 1.5 % PP + 140 mg/kg zinc. All the experimental groups, except for the negative control group, received 500 ppm lead acetate. The composition of NC, LA and diets containing 0.5, 1 and 1.5 percent are shown in Table 1.

Table 1. Experimental diets ingredients and composition

Item (% or as noted)	Diets								
	NC	PC	0.5PP	1PP	1.5PP	140Zn	0.5PPZn	1PPZn	1.5PPZn
Ingredients									
Corn	53.82	53.71	53.00	52.29	53.82	53.82	53.00	52.29	53.82
Soybean Meal (44% CP)	34.88	34.90	34.81	34.72	34.88	34.88	34.81	34.72	34.88
Limestone	5.50	5.50	5.50	5.50	5.50	5.50	5.50	5.50	5.50
Soybean Oil	3.57	3.61	3.90	4.19	3.57	3.57	3.90	4.19	3.57
Dicalcium phosphate	1.25	1.25	1.26	1.26	1.25	1.25	1.26	1.26	1.25
Common Salt	0.34	0.34	0.34	0.34	0.34	0.34	0.34	0.34	0.34
Vitamin premix ¹	0.25	0.25	0.25	0.25	0.25	0.25	0.25	0.25	0.25
Mineral premix ²	0.25	0.25	0.25	0.25	0.25	0.25	0.25	0.25	0.25
DL-Methionine	0.14	0.14	0.14	0.14	0.14	0.14	0.14	0.14	0.14
Purslane	0	0	0.50	1	1.5	53.82	0.50	1	1.5
Zinc oxide (mg/kg)	0	0	0	0	0	87.24	87.24	87.24	87.24
Lead acetate (mg/kg)	0	500	500	500	500	500	500	500	500
Calculated composition (%)									
Metabolisable energy (kcal/kg)	2900	2900	2900	2900	2900	2900	2900	2900	2900
Crude protein	20	20	20	20	20	20	20	20	20
Calcium	2.5	2.5	2.5	2.5	2.5	2.5	2.5	2.5	2.5
Available phosphorous	0.35	0.35	0.35	0.35	0.35	0.35	0.35	0.35	0.35
Sodium	0.15	0.15	0.15	0.15	0.15	0.15	0.15	0.15	0.15
Lysine	1.07	1.07	1.07	1.07	1.07	1.07	1.07	1.07	1.07
Methionine	0.45	0.45	0.45	0.45	0.45	0.45	0.45	0.45	0.45
Calculated zinc (mg/kg)	69.88	69.87	69.82	69.76	69.88	140.13	140.13	140.13	140.13
Analyzed zinc (mg/kg)	71.15	70.83	69.01	68.36	70.55	141.25	139.15	141.31	140.89
Calculated lead (mg/kg)	0	500	500	500	500	500	500	500	500
Analyzed lead (mg/kg)	2.75	498.36	491.98	505.12	506.47	492.60	495.30	511.44	500.36

NC, Negative control (Corn-soy-based diet); PC, Positive control (Corn-soy-based diet + 500 mg/kg Lead acetate); PP= purslane powder; Zn= Zinc oxide.

The vitamin premix contained (per kilogram of diet): vitamin A, 12,000 IU; vitamin D3, 2,400 IU; vitamin E, 10 IU; vitamin K3, 2.5 mg; vitamin B12, 0.015 mg; vitamin B1, 3 mg; vitamin B2, 7 mg; vitamin B6, 4 mg; folic acid, 1 mg; choline, 1,000 mg; nicotinic acid, 30 mg and pantothenic acid, 10 mg. The mineral premix contained (per kilogram of diet): manganese, 60 mg; zinc, 80 mg; iron, 60 mg; copper, 8 mg; iodine, 0.35 mg; and selenium, 0.3 mg.

Performance measurements and egg quality

During the experiment daily egg number, egg weight and feed intake was recorded for each cage. The collected data (number of eggs and egg weight) were used to calculate egg production and egg mass per replicate. Feed intake was measured on a weekly basis. Data on feed intake and egg mass were used to calculate feed conversion ratio. Body weight change calculated for the whole period of the experiment. In the last 3 days of the experiment, 12 eggs from each treatment per day (36 eggs for 3 days) were randomly selected for the evaluation of egg quality parameters. Egg shape index was calculated as, egg shape index = width of egg/length of egg $\times 100$. After weight the eggs, the albumen height of each egg was measured by a micrometer to calculate Haugh unit score [$Hu = 100 \log (H - 1.7 W^{0.37} + 7.6)$, Hu = Haugh unit, H = observed height of the albumen in mm, W = weight of egg (g)]. Furthermore, yolk weight, albumen weight, shell weight and eggshell thickness (from at least 4 places each egg with micrometer) were measured. Furthermore, egg yolk relative weight (EYRW), albumin relative weight (AlbRW) and eggshell relative weight (shellRW) were calculated.

Serum metabolites, relative organ weights and histopathology

At the end of the experiment, 2 birds from each pen were randomly selected and weighed and then blood samples were obtained from the wing vein using syringes collected from with no anticoagulant. Blood samples were centrifuged (3000 rpm, 15 min, 4 °C) and the serum was separated and stored in -20 °C for further analysis of glucose, total protein, uric acid, triglycerides, cholesterol and activity of alanine aminotransferase (ALT) and lactate dehydrogenase (LDH) using the commercial kits (Pars Azmun, Tehran, Iran). Blood for hematocrit measurement was drawn into EDTA tubes and hematocrit value was determined using microhematocrit capillary tubes by centrifuging for 5 min at 12,000 rpm (Campbell, 1995). Moreover, internal organs included liver, pancreas, heart, proventriculus, gizzard, caeca, spleen, oviduct, ovary, ileum, duodenum and jejunum were removed and weighed. Organ weights were expressed as a percentage of live body weight. For histopathological evaluation, appropriate tissue samples were collected from the livers then fixed in 10 % neutral buffered formalin, embedded in paraffin, sectioned at 5 μ m thickness, and stained with hematoxylin-eosin for light microscopic examination.

Assay of antioxidants

The activity of glutathione peroxidase (GPx), SOD and Catalase (CAT) were measured in serum, erythrocytes and liver samples. Before measuring, liver samples were homogenized in a buffer solution (1.15% potassium chloride, pH 7.4) at refrigerated temperature. Homogenized samples were centrifuged for 15 min at 5000 r.p.m for a period of 15 minutes, and the supernatant was taken and used for the related measurements. The SOD in erythrocytes and liver was measured using a kit prepared by the company Randox. The principles of GPx measurement were based on the method described by Paglia and Valentine (1967). The activity of CAT was determined at room temperature by using the method explained by Aebi (1984). TAC was determined using Randox total antioxidant status kit (Randox Laboratories Ltd, Crumlin, UK). To measure serum malondialdehyde (MDA), 0.5 ml of serum was mixed with 2.5 ml trichloro acetic acid and after incubating for 15 min (room temperature), 1.5 ml TBA was added and mixed for 30 sec then, incubated at 95 °C for 30 min. Next, each sample incubated in ice bath for 3 hours and 4.0 ml n-butanol was added and mixed vigorously for 3 min. Finally MDA-TBA adduct was centrifuged at 950 \times g for 10 min and absorbance was measured at 532 nm. 1,1,3,3-tetramethoxypropane was used to prepare MDA standard.

Statistical Analysis

The general linear model procedure of SAS software (SAS 2001) was used for analyzing the data in a completely randomized design model. The means of treatments were compared using Duncan's multiple range tests. Values of $P < 0.05$ were considered statistically significant.

RESULTS

Growth performance

Egg weight, feed intake and feed/egg ratio of the laying quails were not affected by different experimental groups ($P > 0.05$; Table 2). Although, lead exposed quails showed significant body weight, egg mass and egg production reduction when compared with the birds in NC group ($P < 0.05$, Table 2), however, PP and Zn supplementation and their combination could not mimic it.

Egg quality

No significant difference ($P > 0.05$) was observed for shell thickness, EYRW, AlbRW, shellRW and egg

shape index of quails after 5 weeks feeding experimental diets (Table 2). Feeding laying quails with diets containing lead decreased Haugh unit in compari-

son to the NC group ($P<0.05$), however dietary PP, Zn and their combination could not reduce these effect in birds exposed to lead toxicity ($P<0.05$).

Table 2. The effect of purslane and zinc on performance and egg quality of laying quails exposed to lead toxicity

Items	Experimental diets										<i>P values</i>
	NC	PC	T1	T2	T3	T4	T5	T6	T7	SEM	
BWC	29.3 ^a	-44.8 ^b	-31.7 ^b	-39.9 ^b	-25.1 ^b	-35.3 ^b	-33.9 ^b	-32.8 ^b	-27.3 ^b	4.31	0.0001
EP (%)	94.2 ^a	77.8 ^b	82.6 ^b	83.0 ^b	82.7 ^b	80.6 ^b	84.5 ^b	83.4 ^b	81.2 ^b	0.76	0.0001
EW (g)	11.5	11.4	11.2	11.3	11.4	11.4	11.3	11.2	11.5	0.04	0.57
EM(g/bird/day)	10.9 ^a	8.8 ^b	9.3 ^b	9.4 ^b	9.5 ^b	9.2 ^b	9.5 ^b	9.3 ^b	9.3 ^b	0.09	0.0001
FI (g/bird/day)	28.5	28.8	28.1	29.2	29.7	30.0	30.0	29.1	28.6	0.49	0.98
FCR	2.6	3.0	3.0	3.1	2.9	3.0	2.9	3.1	2.9	0.04	0.26
YRW (%)	34.9	32.4	34.2	35.8	31.4	34.1	33.4	32.7	34.5	0.62	0.85
ARW (%)	57.2	59.7	57.0	57.0	60.6	57.7	59.0	60.3	58.8	0.66	0.87
SRW (%)	7.8	7.8	8.6	7.1	7.9	8.1	7.5	6.8	6.6	0.18	0.18
STh (mm)	1.2	1.2	1.2	1.3	1.2	1.3	1.2	1.2	1.3	0.008	0.89
ShI	80.0	75.7	79.2	80.9	78.3	73.8	78.3	76.9	79.1	0.60	0.13
HaU	88.2 ^a	67.6 ^b	71.7 ^b	68.8 ^b	71.0 ^b	73.2 ^b	70.3 ^b	71.7 ^b	71.2 ^b	1.50	0.02

Abbreviations: BWC, Body weight change; EP, Egg production; EW, Egg weight; EM, Egg mass; FI, Feed intake; FCR, Feed conversion ratio; YRW, Yolk relative weight; ARW, Albumen relative weight; SRW, Shell reative weight; STh, Shell thickness; ShI, Shell index; HaU, Haugh unit; NC, Negative control (Corn-soy-based diet); PC, Positive control (Corn-soy-based diet + 500 mg/kg Lead acetate); T1 = PC + 0.5 % purslane powder (PP), T2 = PC + 1 % PP, T3 = PC + 1.5 % PP, T4 = PC +140 mg/kg Zinc oxide, T5 = PC + 0.5 % PP + 140 mg/kg Zinc oxide, T6 = PC + 1 % PP + 140 mg/kg Zinc oxide, T7 = PC + 1.5 % PP + 140 mg/kg Zinc oxide.

^{a-c} Means with same superscript in each row are not significantly different. SEM= standard error of the means.

Serum Metabolites

Experimental groups did not alter serum levels of glucose, uric acid and cholesterol of laying quails ($P>0.05$; Table 3). In comparison to the NC group, concentrations of hematocrit, total protein, triglycerides and very low density protein (VLDL, estimated by Friedewald et al., 1972) showed a significant decrease in all other experimental groups ($P<0.05$). Moreover, serum activity of ALT and LDH of quails fed whit all experimental groups showed significant increase

when compared with the NC group ($P<0.05$).

Relative internal organs weight

No significant change was observed in relative weights of pancreas, heart, proventriculus, gizzard, caeca, spleen, oviduct, ovary, ileum, duodenum and jejunum among the treatments (Table, 4). However, there was a significant decrease in relative weights of liver in quails fed other diets than the NC group ($P<0.05$).

Table 3. The effect of different experimental diets on serum parameters of laying quails exposed to lead

Items	Experimental diets										<i>P values</i>
	NC	PC	T1	T2	T3	T4	T5	T6	T7	SEM	
Hematocrit (%)	29.54 ^a	21.47 ^b	24.09 ^b	23.39 ^b	24.43 ^b	23.71 ^b	23.80 ^b	23.87 ^b	24.22 ^b	0.51	0.02
Glucose (mg/dl)	276.4	272.1	237.0	344.0	253.2	272.5	297.6	286.1	352.7	17.71	0.89
Chol (mg/dl)	153.2	218.5	198.6	200.6	236.6	214.7	201.3	192.7	250.3	9.51	0.50
TG (mg/dl)	488.9 ^a	366.0 ^b	392.9 ^b	375.3 ^b	394.2 ^b	377.2 ^b	380.5 ^b	383.2 ^b	372.7 ^b	8.67	0.01
TP (g/dl)	7.8 ^a	4.9 ^b	6.1 ^b	6.1 ^b	6.3 ^b	5.4 ^b	6.0 ^b	6.1 ^b	6.3 ^b	0.18	0.03
UA (mg/dl)	5.5	5.6	5.3	5.1	5.7	4.2	5.5	5.6	6.0	0.17	0.54
VLDL (md/dl)	97.7 ^a	73.2 ^b	78.5 ^b	75.0 ^b	78.8 ^b	75.4 ^b	76.1 ^b	76.6 ^b	74.5 ^b	1.73	0.01
ALT (U/L)	24.9 ^b	51.0 ^a	38.7 ^a	44.8 ^a	40.0 ^a	41.4 ^a	40.8 ^a	38.6 ^a	43.3 ^a	1.70	0.03
LDH (U/L)	200.5 ^b	395.0 ^a	322.1 ^a	330.1 ^a	307.7 ^a	314.4 ^a	314.3 ^a	329.1 ^a	314.1 ^a	12.02	0.02

Abbreviations: Chol, Cholesterol; TG, Triglycerides; TP, Total protein; UA, Uric acid; VLDL, Very low density lipoprotein; ALT, Alanine aminotransferase; LDH, Lactate dehydrogenase; NC, Negative control (Corn-soy-based diet); PC, Positive control (Corn-soy-based diet + 500 mg/kg Lead acetate); T1 = PC + 0.5 % purslane powder (PP), T2 = PC + 1 % PP, T3 = PC + 1.5 % PP, T4 = PC +140 mg/kg Zinc oxide, T5 = PC + 0.5 % PP + 140 mg/kg Zinc oxide, T6 = PC + 1 % PP + 140 mg/kg Zinc oxide, T7 = PC + 1.5 % PP + 140 mg/kg Zinc oxide.

^{a-b} means with same superscript in each row are not significantly different. SEM= Standard error of the means.

Table 4. The effect of different experimental diets on relative weight of body organs of laying quails exposed to lead (%)

Items (%)	Experimental diets									SEM	<i>P</i> -values
	NC	PC	T1	T2	T3	T4	T5	T6	T7		
Liver	2.97 ^a	1.20 ^b	1.97 ^b	2.05 ^b	2.06 ^b	2.05 ^b	1.97 ^b	2.07 ^b	1.99 ^b	0.10	0.02
Spleen	0.05	0.08	0.04	0.04	0.04	0.06	0.05	0.06	0.05	0.004	0.4
Heart	0.60	0.89	0.78	0.66	0.69	0.70	0.74	0.67	0.77	0.02	0.2
Jejunum	1.46	1.83	1.90	1.84	1.33	1.56	1.26	1.45	1.76	0.06	0.23
Duodenum	0.76	1.05	1.04	0.96	0.75	0.82	0.82	0.80	0.92	0.03	0.46
Ileum	0.2	0.19	0.22	0.28	0.20	0.23	0.22	0.23	0.23	0.007	0.08
Pancreas	0.17	0.25	0.22	0.29	0.22	0.20	0.23	0.26	0.25	0.01	0.42
Ovary	2.52	2.55	2.04	2.49	2.81	2.68	2.02	2.72	2.30	0.15	0.96
Oviduct	2.91	4.39	2.93	2.93	3.32	3.49	3.61	2.85	3.18	0.13	0.10
Gizzard	1.57	1.94	1.93	1.79	1.76	1.97	1.52	1.96	1.94	0.04	0.09
Cecum	0.54	0.68	0.63	0.63	0.69	0.59	0.52	0.59	0.51	0.03	0.91
Preventriculs	0.26	0.34	0.34	0.39	0.29	0.37	0.32	0.29	0.28	0.01	0.28

Abbreviations: NC, Negative control (Corn-soy-based diet); PC, Positive control (Corn-soy-based diet + 500 mg/kg Lead acetate); T1 = PC + 0.5 % purslane powder (PP), T2 = PC + 1 % PP, T3 = PC + 1.5 % PP, T4 = PC + 140 mg/kg Zinc oxide, T5 = PC + 0.5 % PP + 140 mg/kg Zinc oxide, T6 = PC + 1 % PP + 140 mg/kg Zinc oxide, T7 = PC + 1.5 % PP + 140 mg/kg Zinc oxide. ^{a-b} means with same superscript in each row are not significantly different. SEM= Standard error of the means.

Antioxidant enzyme activities

The effects of treatments on liver, erythrocytes and serum antioxidants status are presented in Table 5. Dietary lead decreased SOD and GPx activities in the liver and erythrocyte than the NC group ($P < 0.05$), however, had no effect on liver catalase activity ($P < 0.05$). In addition, all dietary treatments decreased ($P < 0.05$) TAC and increased serum and liver MDA

levels compared to the NC group ($P < 0.05$). The results showed that the negative effects of lead on serum activity of TAC, liver and serum MDA was ameliorated ($P < 0.05$) by 1.5 % dietary PP supplementation, but PP supplementation could not restore the activity of TAC and MDA towards close the control levels ($P < 0.05$).

Table 5. The effect of different experimental diets on liver, erythrocytes and serum antioxidants of laying quails exposed to lead (%)

Items	Experimental diets									SEM	<i>P</i> -values
	NC	PC	T1	T2	T3	T4	T5	T6	T7		
Liver											
MDA (nmol/mg of protein)	3.88 ^c	6.45 ^a	5.76 ^{ab}	6.47 ^a	4.40 ^{bc}	5.22 ^{abc}	5.43 ^{abc}	5.19 ^{abc}	4.46 ^{bc}	0.22	0.04
CAT (unit/mg of protein)	10.83	13.71	12.21	12.11	11.51	12.88	13.41	12.54	11.27	0.29	0.28
GPx (unit/mg of protein)	25.19 ^a	20.21 ^b	22.02 ^b	22.20 ^b	22.28 ^b	22.17 ^b	22.23 ^b	22.18 ^b	21.36 ^b	0.30	0.01
SOD (unit/mg of protein)	227.19 ^a	174.85 ^b	180.15 ^b	175.16 ^b	193.40 ^b	188.98 ^b	176.46 ^b	187.64 ^b	190.69 ^b	4.05	0.04
Erythrocytes											
GPx (unit/mg Hb)	71.82 ^a	42.80 ^b	50.45 ^b	51.06 ^b	55.16 ^b	47.71 ^b	44.87 ^b	45.32 ^b	54.88 ^b	2.16	0.04
SOD (unit/mg Hb)	1907.1 ^a	1485.0 ^b	1579.4 ^b	1579.6 ^b	1678.3 ^b	1622.4 ^b	1668.2 ^b	1636.0 ^b	1536.3 ^b	28.99	0.02
Serum											
MDA (nmol/ml)	1.61 ^c	3.04 ^a	2.68 ^a	2.59 ^{ab}	2.00 ^c	2.81 ^a	2.65 ^a	2.69 ^a	2.05 ^{bc}	0.09	0.0002
TAC (mmol/L)	1.31 ^a	0.77 ^c	0.88 ^{bc}	0.99 ^{bc}	1.09 ^{ab}	0.84 ^{bc}	0.96 ^{bc}	0.98 ^{bc}	0.99 ^{bc}	0.03	0.02

Abbreviations: NC, Negative control (Corn-soy-based diet); PC, Positive control (Corn-soy-based diet + 500 mg/kg Lead acetate); T1 = PC + 0.5 % purslane powder (PP), T2 = PC + 1 % PP, T3 = PC + 1.5 % PP, T4 = PC + 140 mg/kg Zinc oxide, T5 = PC + 0.5 % PP + 140 mg/kg Zinc oxide, T6 = PC + 1 % PP + 140 mg/kg Zinc oxide, T7 = PC + 1.5 % PP + 140 mg/kg Zinc oxide. CAT (Catalase), GPx (glutathione peroxidase) and SOD (Total superoxide dismutase) according to U/mg Protein, SOD (superoxide dismutase) according to mg/Hb, MDA (malondialdehyde) and TAC (Total antioxidant capacity) according to mmol/L. ^{a-c} means with same superscript in each row are not significantly different. SEM= standard error of the means.

Liver histopathology

Liver tissues from the quails in negative control group showed normal lobular architecture with central veins, radiating hepatic cords and portal triads, while this organ in the other experimental groups showed mild, moderate, and severe tissue changes (Figure 1A and 1B). The main histopathologic findings in the liver of quails, intoxicated with lead acetate alone, were hepatocyte degeneration, severe macrovesicular steatosis accompanied with marked hepatocellular ballooning, congestion and dilation of central veins and sinusoids, severe mononuclear cell infiltration in the liver parenchyma and around the portal area, proliferation of Kupffer cells, multifocal to diffuse necrosis

and moderate fibrosis, particularly in the portal areas (Figure 1C–1F).

In comparison to lead acetate group, the quails treated with different Levels of PP powder and Zn showed improvement in its histological structure. However, mild vacuolar degeneration, a few hepatocytes with pyknotic nuclei, mild mononuclear cell infiltration and moderate venous congestion were observed in the treated groups. There was no evidence of fibrosis or coagulative necrosis in these groups. In comparison between all treated groups, the most therapeutic effect was seen with the dose of 1.5 % PP (Figure. 2A and 2D).

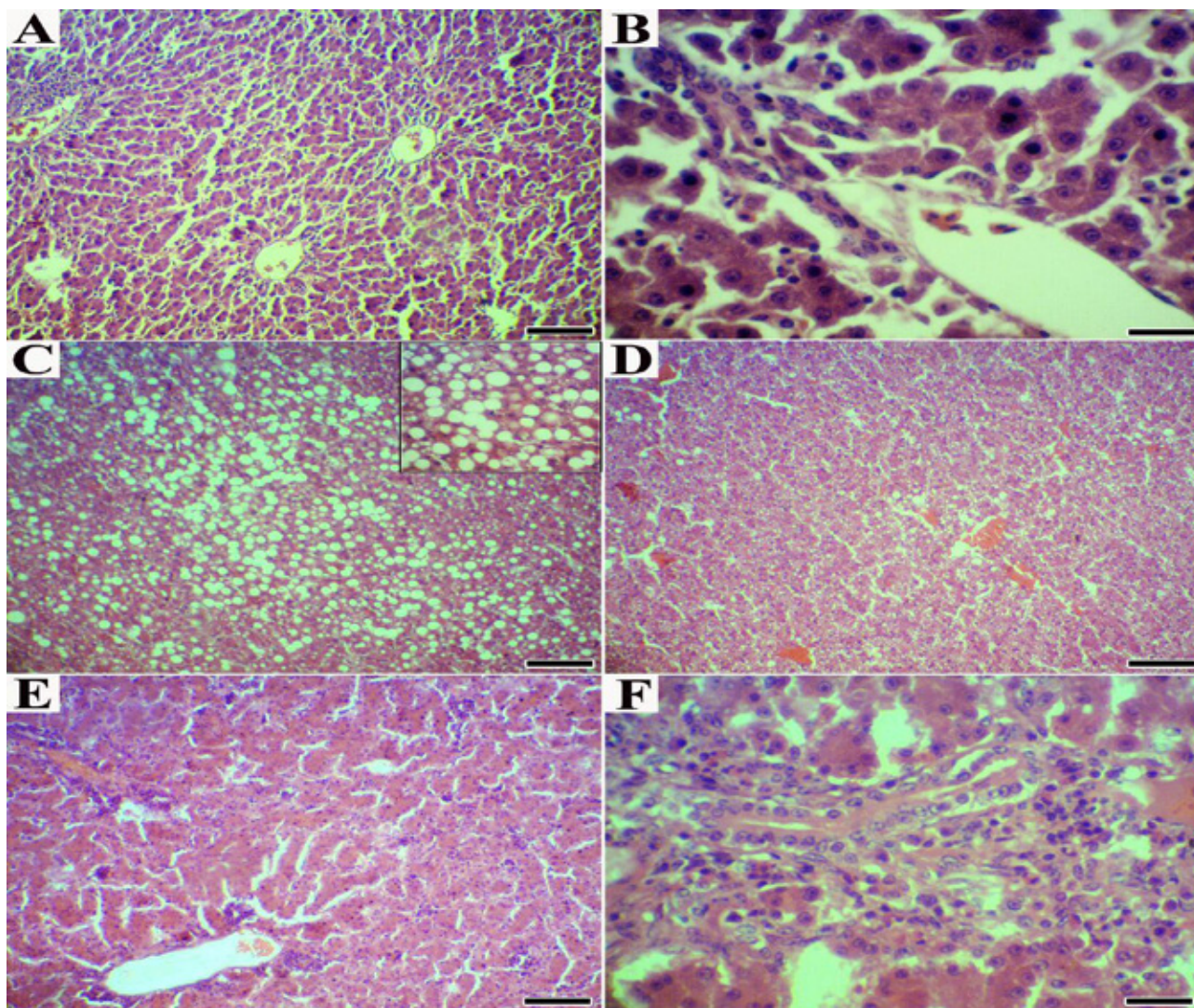


Figure 1. (A-B) Normal quails. (A) A normal lobular pattern with a centrilobular vein and radiating anastomosing plates of hepatocytes with intervening sinusoids (H&E; Bar=150 μ m); (B) Normal quails. Portal area with normal architecture (H&E; Bar=20 μ m); (C-F) Quails received lead acetate. (C) Severe macrovesicular steatosis (H&E; Bar=150 μ m); (D) Severe congestion and dilation of sinusoids (H&E; Bar=150 μ m); (E) several foci of mononuclear cell infiltration in the liver parenchyma (H&E; Bar=150 μ m); (F) Moderate infiltration of mononuclear cells and fibrous tissue around the portal area (H&E; Bar=20 μ m).

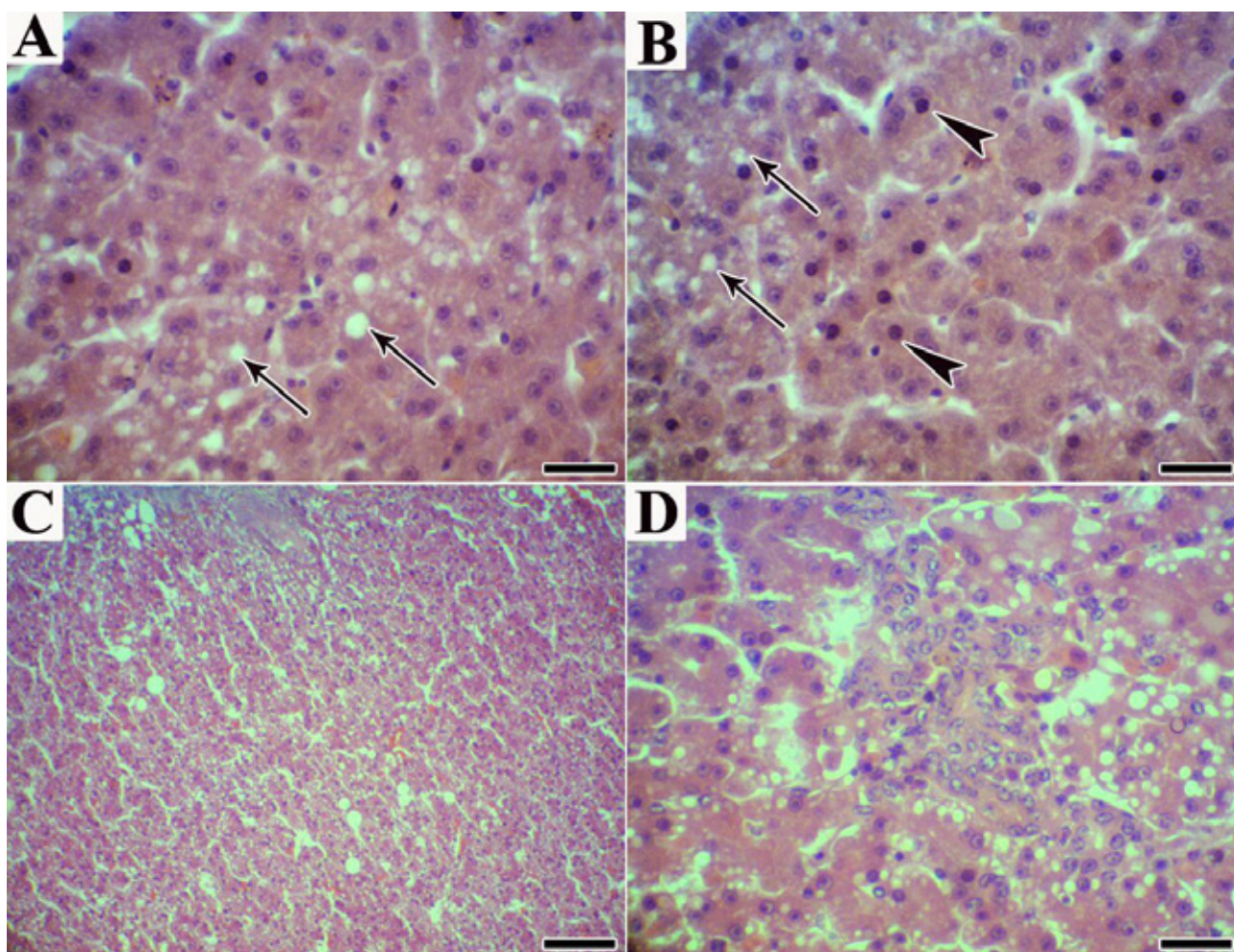


Figure 2. (A) Treated quails with zinc. Mild macrovesicular steatosis (arrows) (H&E; Bar=20 μ m) (B) Treated quails with *P. oleracea* (1.5%). Presence of a few cytoplasmic vacuoles (arrows) with pyknotic nuclei (head arrows); (C) Mild congestion with disorganization of the hepatic cords (H&E; Bar=150 μ m); (D) Treated quails with *P. oleracea* (1.5%). Mild infiltration of mononuclear cells in the in the liver parenchyma H&E; Bar=20 μ m).

DISCUSSION

This study was designed to evaluate the protective effect of PP and Zn against lead-induced toxicity in laying quails. The present study showed that consumption of 500 ppm dietary lead for 5 weeks significantly decreased body weight, egg mass and egg production. In agreement with our results, Damron and Wilson (1975) reported that feeding 3000 ppm lead acetate to quails decreased body weight and increased mortality rate. Hossain et al. (2014) reported live weight reduction in lead-exposed (100 mg/kg of diet) broiler chickens after 42 days. Goldberg (1972) demonstrated that anemia is an early sign of lead toxicity. Morgan et al. (1975) reported inhibition of growth and anemia when lead acetate administered to Japanese quails diets at levels of 500 or 1000 ppm. In mammalian species it is demonstrated that lead administration resulted in a significant reduction in feed intake, erythrocytes count, haemoglobin and the

concentration of blood iron (Saly et al., 2004). According to these reports, it is likely that body weight loss can be caused by toxic effects of lead on haemopoietic systems. This assumption is supported by lower haematocrit content in the blood of lead exposed laying quails. Oxidative stress has been known as the main mechanism of lead toxicity (Aykin-Burns et al., 2003). On the other hand, it has been demonstrated that free radical production, oxidative stress, could be strongly a possible reason for the body weight loss of quails in the present experiment (Hakim et al., 1997).

Yuan et al. (2013) reported that lead acetate reduced serum level of FSH, LH and progesterone in laying hens. Pillai et al. (2003) concluded that lead may attach to the steroid hormone receptors, for instance, estrogen and progesterone receptors; therefore, it finally prevents their secretion. Additionally, lead may interfere with calcium-dependent gonadotrophin-releasing

hormones through toxic effects on calcium homeostasis (Pillai et al., 2003). Calcium plays an important role in the regulation and secretion of gonadotropin releasing hormone and LH which lead to reduction of plasma estradiol level (Martinez De La Escalera et al., 1992). Estradiol induces the synthesis of vitellogenin in the avian liver (Gruber et al., 1976). Reduction synthesis of vitellogenesis could be a reason for the reduced yolk weight and egg weights (Faryadi and Sheikahmadi 2017). Therefore, it seems probably that decrease in plasma LH level due to the addition of lead acetate to the diet of quails could be a possible reason to reduced egg production and egg mass.

Our results showed a significant decrease in Haugh unit in the lead exposed quails compared with the NC. Haugh unit has been accepted as an index of the quality of the albumen (Eisen et al., 1962). Eggs with higher Haugh unit have better internal egg quality that could be due to lower protein damage in albumen (Begli et al., 2010). Therefore, it seems that Haugh unit reduction in the lead-exposed quails could be due to disorder in protein metabolism in the liver. It is strongly possible that toxicity effect of lead on liver cells and impairment of liver protein synthesis leading to reduced albumen protein production and especially the ovomucin which is a critical protein to creates viscosity character of egg albumen and increase Haugh unit (Omana et al., 2010).

In our present study, decrease in blood hematocrit, total protein, triglyceride, VLDL concentration and increase in the activity of ALT and LDH in the serum of the lead-exposed quails has been found when compared with the NC. These results are in accordance with Hamidipour et al. (2016), who reported higher ALT and LDH activity and decrease in triglyceride and total protein in quails exposed to lead acetate. The LDH is one of the most important liver glycolytic enzymes and can be found in the heart and other tissues. Hepatic impairment, heart failure, renal disorders, muscular dystrophy and hemolytic anemia can lead to increased levels of this enzyme in blood (Ebrahimi, 2011). In the present study, increased activity of LDH indicates damage in different tissues of the lead-exposed quails. However we measured ALT as it is well known that ALT is mainly in the cytoplasm of liver cells and any liver failures resulted in a release of this enzyme into the circulation system. Liver is one of the most important organs involved in the lead toxicity (Dzugan et al., 2012). Our findings showed that relative weight of the liver of quails decreased in

lead-exposed groups. Previous work by Mahaffey et al. (1981) showed that organ/body weight ratio negatively affected by heavy metals.

Hamidipour et al. (2016) reported lower concentration of triglycerides in lead-exposed quails is due to small intestine villi damage which causes significant impairment in the absorption of fatty acids. Liver is the main organ of lipid biosynthesis and is particularly very active in laying birds (Aydin, 2005). Therefore, liver damage may decrease the synthesis of triglycerides. In addition, liver is responsible for synthesis of most of the plasma proteins. Therefore, total protein in the plasma is an important indicator of protein synthesis in the liver (Robin et al., 1987). It is reported that feeding birds with lead for 2 months could lead to degeneration of liver protein synthesis (Yuan et al., 2013). Totally, according to the present results, increased activity of ALT and LDH and decrease in serum triglyceride, VLDL and total protein concentration can indicate liver damage in lead-exposed laying quails.

It is reported that toxic metals act as catalysts in the production of reactive oxygen species (El-Maraghy et al., 2001). Free radicals can attack to lipid molecules leading to lipid peroxidation and change in antioxidant status of the cells (Stohs et al., 2001). Antioxidant enzymes of the cells play an important role in protection the homeostasis of free oxygen radicals (Qanungo et al., 1999). Alter of antioxidant enzyme activities such as SOD, CAT, and GPx and reduction in the concentrations of some antioxidant molecules, such as GSH has been reported in lead exposed animals. Previous studies suggested that oxidative damage is one of the important mechanisms of lead toxicity (Aykin-Burns et al., 2003). In the present study, a significant decrease in SOD and GPx activities in the liver and erythrocyte and serum TAC concentration along with increased liver and serum level of MDA are indicators of increased oxidative stress in lead-exposed birds (Pan et al., 2005). These results are in accordance with Erdogan et al. (2005), who showed that lead significantly increase plasma MDA in broilers. Several studies reported that MDA levels increased when lipid peroxidation develops (Tatli Seven et al., 2009). MDA is an index of lipid peroxidation that is associated with the oxidation of polyunsaturated fatty acids. Moreover, our present study demonstrates a significant decrease in the liver and erythrocyte SOD and GPx activity in all birds exposed to lead. Many studies have reported that lead bounds with

thiol groups and therefore reduce cellular glutathione levels (Fuhr and Rabenstein 1973). Under oxidative stress oxidized glutathione is reduced to GSH via glutathione reductase which is an indirect combination of the antioxidant defense system. It has been shown that lead inhibits glutathione reductase by binding to sulfide groups at the active site of this enzyme leading to a reduction in the reduced glutathione which is a substrate for GPx (Sandhir and Gill 1995). This may explain the reduction of GPx activity in the present study. Strehlow et al. (2003) reported that estrogen up-regulates SOD expression. Previous studies reported that lead exposure resulted in a significant estrogen production (Paksy et al., 1992). Although we did not measure serum estrogen, however, it is strongly likely that reduced SOD activity in lead-exposed quails in our present study is due to lower estrogen production (Nampoothiri et al., 2007).

Antioxidants are free radical scavengers that suppress the formation of ROS. It is well known that Zn acts as an antioxidant to decrease oxidative damage of cell membrane. Zn is an important part of SOD, which protects body against free radicals by converting superoxide anions to hydrogen peroxide (Niles et al., 2008). It is suggested that increase dietary Zn can reduce toxic effects of lead in rats (Cerklewski and Forbes 1976). One of the antioxidant enzymes possess Zn involved in the active site is SOD (Nampoothiri et al., 2007). Hence in the present study we assumed that dietary Zn supplementation can increase SOD activity in lead-exposed laying quails. However, liver and erythrocyte SOD activity decreased in lead-exposed laying quails. It is strongly possible that ionic mechanism of action for lead resulted in substitution of Zn ions by lead in SOD and hence negatively affected its activity (Nampoothiri et al., 2007).

On the other hand, one natural source that could act as an antioxidant is Purslane (*Portulaca oleracea*), which has been using as an edible vegetable in many countries (Zhao et al., 2013). Purslane is a rich source of antioxidants (Simopoulos et al., 2005). In our present study, although, the negative effects of lead treatment on serum CAT activity ameliorated by dietary supplementation of PP at 1.5 %, however, it could not restore the increased activity of CAT towards the negative control levels. Moreover, TAC decreased in lead-exposed laying quails that could be due to higher production of ROS in these birds. Purslane is a rich source of glutathione that absorbed by gut and acts as a substrate for GSH-Px in animal cells and increase

the antioxidant status of birds (Simopoulos, 2001). However, we did not see any significant increase in the activity of GSH-Px after exposing laying quails to lead for 5 weeks.

Histopathological examination of liver tissue in the groups that received lead acetate showed mild, moderate, and severe tissue changes. It has been reported that adding 400 ppm lead acetate to drinking water and diet leads to liver lesions in broiler chickens (Sipos et al., 2003). These liver lesions can be caused by stimulating the intercellular signals between kuffer cells and hepatocytes, which ultimately leads to increased proteolytic activity and damage to the liver tissue (Sipos et al., 2003). The low concentration of lead in the ration of birds can lead to low grade changes through the disruption of the normal biochemical processes of the liver system. The liver is the central organ for all metabolic processes, and because of its major role in the processing of foods and xenobiotics in the body, remarkable amounts of toxic lead are absorbed and stored in the liver. Therefore, the probable reason of damage in cells caused by its ability to replace with several metal ions, especially calcium and Zn in their binding sites (Garza et al., 2006). Lead causes oxidative damage to lipids and proteins, disruption of antioxidant mechanisms, and direct oxidative damage (Garza et al., 2006) that this effects whit addition of PP to the diet due to have antioxidant effects can slightly somewhat overcome on the toxic effects of lead. Furthermore, liver pathological results supported by the serum parameters findings.

CONCLUSIONS

From this study, it can be concluded that lead-exposure induced production of free radicals and weakened the antioxidant defenses of the quails. Supplementation of PP, Zn or their combination could not prevent the negative effect of lead on the performance of quails. However, antioxidant status of quails partially improved when fed diets supplemented with 1.5 % PP and 140 ppm Zn.

ACKNOWLEDGEMENTS

We wish to thank Mohammad Hashemnia (Department of pathobiology, faculty of veterinary medicine, Razi University, Kermanshah, Iran) for assay liver histopathology.

CONFLICT OF INTEREST

The authors declare that they have no conflict of interest.

REFERENCES

- Aebi H (1984) Catalase in vitro. In Methods in enzymology. 105:121-126.
- AOAC (1995) Official Methods of Analysis, 16th edition. Association of Official Analytical Chemists (Washington, DC, USA).
- Aydin R (2005) Type of fatty acids, lipoprotein secretion from liver and fatty liver syndrome in laying hens. Int. J. Poult. Sci. 4:917-919.
- Aykin-Burns N, Laegeler A, Kellogg G, Ercal N (2003) Oxidative effects of lead in young and adult Fisher rats. Arch. Environ. Contam. Toxicol. 44:0417-0420.
- Barbosa-Filho JM, Alencar AA, Nunes XP, Tomaz AC, Sena-Filho JG, Athayde-Filho PF, Da-Cunha EVL (2008) Sources of alpha-, beta-, gamma-, delta-and epsilon-carotenes: A twentieth century review. Rev. Bras. Farmacogn. 18:135-154.
- Begli HE, Zerehdaran S, Hassani S, Abbasi MA, Ahmadi AK (2010) Heritability, genetic and phenotypic correlations of egg quality traits in Iranian native fowl. Br. Poult. Sci. 51:740-744.
- Campbell TW (1995) Avian Hematology and Cytology. 2nd ed. Iowa State University Press, Ames, IA.
- Cerklewski FL, Forbes RM (1976) Influence of dietary zinc on lead toxicity in the rat. J. Nutr. 106:689-696.
- Damron BL, Simpson CF, Harms RH (1969) The effect of feeding various levels of lead on the performance of broilers. Poult. Sci. 48:1507-1509.
- Damron BL, Wilson HR (1975) Lead toxicity of bobwhite quail. Bull. Environ. Contam. Toxicol. 14:489-496.
- Dzugas M, Zielinska S, Heclik J (2012) Evaluation of heavy metals environmental contamination based on their concentrations in tissues of wild pheasant (*phasianus colchicus L.*). J. Microbiol. Biot. Food. Sci. 2:238-245.
- Ebrahimi A (2011) The clinical interpretation of medical tests. Publishing institute teymurzadeh. 2th edition. Tehran; 628.
- Eisen EJ, Bohren BB, McKean HE (1962) The Haugh unit as a measure of egg albumen quality. Poult. Sci. 41:1461-1468.
- El-Maraghy SA, Gad MZ, Fahim AT, Hamdy MA (2001) Effect of cadmium and aluminum intake on the antioxidant status and lipid peroxidation in rat tissues. J. Biochem. Mol. Toxicol. 15:207-214.
- Erdogan Z, Erdogan S, Aksu T (2005) The effects of dietary lead exposure and ascorbic acid on performance, lipid peroxidation status and biochemical parameters of broilers. Turk. J. Vet. Anim. Sci. 29:1053-1059.
- Faryadi S, Sheikahmadi A (2017) Effect of nanosilicon dioxide on growth performance, egg quality, liver histopathology and concentration of calcium, phosphorus and silicon in egg, liver and bone in laying quails. Applied Nanoscience. 7:765-772.
- Friedewald WT, Levi RI, Fredrickson DS (1972) Estimation of the concentration of low density lipoproteins cholesterol in plasma without use of the ultracentrifuge. Clin. Chem. 18:499-502.
- Fuhr BJ, Rabenstein DL (1973) Nuclear magnetic resonance studies of the solution chemistry of metal complexes. IX. Binding of cadmium, zinc, lead, and mercury by glutathione. J. Am. Chem. Soc. 95:6944-6950.
- Garza A, Vega R, Soto E (2006) Cellular mechanisms of lead neurotoxicity. Med. Sci. Monit. 12:57-65.
- Ghorbani MR, Bojarpur M, Mayahi M, Fayazi J, Fatemi Tabatabaei R, Tabatabaei S (2013) Effect of purslane (*Portulaca oleracea L.*) on blood lipid concentration and antioxidant status of broiler chickens. Onl. J. Vet. Res. 17:54-63.
- Goldberg A (1972) Lead poisoning and haem biosynthesis. Br. J. Haematol. 23:521-524.
- Gruber M, Bos ES, Geert AB (1976) Hormonal control of vitellogenin synthesis in avian liver. Mol. Cell. Endocrinol. 5:41-50.
- Gülçin İ, Şat G, Beydemir Ş, Elmastaş M, Küfrevioğlu Öİ (2004) Comparison of antioxidant activity of clove (*Eugenia caryophyllata Thunb*) buds and lavender (*Lavandula stoechs L.*). Food. Chem. 87:393-400.
- Gupta RC (Ed.) (2011) Reproductive and developmental toxicology. Academic Press.
- Hakim ZS, Patel BK, Goyal RK (1997) Effects of chronic ramipril treatment in streptozotocin-induced diabetic rats. Indian. J. Physiol. Pharmacol. 41:353-360.
- Halicia M, Odabasoglu F, Suleymanb H, Cakirc A, Asland A, Bayir Y (2005) Effects of water extract of *Usnea longissima* on antioxidant enzyme activity and mucosal damage caused by indomethacin in rats. Phytomedicine. 12:656-662.
- Hamidipour F, Pourkhabbaz HR, Banaee M, Javanmardi S (2016) Bioaccumulation of lead in the tissues of Japanese quails and its effects on blood biochemical factors. Ira. J. Toxicol. 10.
- Hossain MA, Mostofa M, Alam MN (2014) The ameliorating effects of garlic (*Allium Sativum*) against lead (Pb) intoxication on body weight, dressing percentages, feed consumption and feed conversion ratio in lead induced broiler chickens. Bangl. J. Vet. Med. 12:1-7.
- Khalaf AA, Moselhy WA, Abdel-Hamed MI (2012) The protective effect of green tea extract on lead induced oxidative and DNA damage on rat brain. Neurotoxicology. 33:280-289.
- Mahaffey KR, Capar SG, Gladen BC, Fowler BA (1981) Concurrent exposure to lead, cadmium, and arsenic. Effects on toxicity and tissue metal concentrations in the rat. J. Lab. Clin. Med. 98:463-481.
- Martinez De La Escalera G, Choi AL, Weiner RI (1992) Beta 1-adrenergic regulation of the GT1 gonadotropin-releasing hormone (GnRH) neuronal cell lines: stimulation of GnRH release via receptors positively coupled to adenylate cyclase. Endocrinology. 131:1397-1402.
- Morgan GW, Edens FW, Thaxton P, Parkhurst CR (1975) Toxicity of dietary lead in Japanese quail. Poult. Sci. 54:1636-1642.
- Nampoothiri LP, Agarwal A, Gupta S (2007) Effect of co-exposure to lead and cadmium on antioxidant status in rat ovarian granulosa cells. Arch. Toxicol. 81:145-150.
- Niles BJ, Clegg MS, Hanna LA, Chou SS, Momma TY, Hong H, Keen CL (2008) Zinc deficiency-induced iron accumulation, a consequence of alterations in iron regulatory protein-binding activity, iron transporters, and iron storage proteins. J. Biol. Chem. 283:5168-5177.
- Omana DA, Wang J, Wu J (2010) Ovomucin—a glycoprotein with promising potential. Trends. Food. Sci. Technol. 21:455-463.
- Paglia DE, Valentine WN (1967) Studies on the quantitative and qualitative characterization of erythrocyte glutathione peroxidase. J. Lab. Clin. Med. 70:158-169.
- Paksy K, Varga B, Lazar P (1992) Cadmium interferes with steroid biosynthesis in rat granulosa and luteal cells in vitro. Biometals. 5:245-250.
- Pan JQ, Tan X, Li JC, Sun WD, Wang XL (2005) Effects of early feed restriction and cold temperature on lipid peroxidation, pulmonary vascular remodelling and ascites morbidity in broilers under normal and cold temperature. Br Poult Sci. 46:374-381.
- Petrovic V, Kushev J, Nollat L, Kovac G (2011) Effect of dietary supplementation of trace elements on blood chemistry and selected immunological indices depending on the age of broiler chickens. Acta Veterinaria Brno. 80:57-64.
- Pillai A, Priya L, Gupta S (2003) Effects of combined exposure to lead and cadmium on the hypothalamic-pituitary axis function in preovulatory rats. Food Chem. Toxicol. 41:379-384.
- Qanungo S, Sen A, Mukherjee M (1999) Antioxidant status and lipid peroxidation in human foeto-placental unit. Clinica chimica acta. 285:1-12.
- Rafique M, Pervez S, Tahir F (2010) Protective effect of zinc over lead toxicity on testes. J Coll Physicians Surg Pak. 20:377-381.
- Robin JP, Cherel Y, Girard H (1987) Uric acid and urea in relation to protein catabolism in long-term fasting geese. J Comp Physiol B. 157:491-499.
- Sadeghi G, Karimi A, Shafeie F, Vaziry A, Farhadi D (2016) The Effects of purslane (*Portulaca oleracea L.*) powder on growth performance, carcass characteristics, antioxidant status, and blood metabolites in broiler chickens. Livest Sci. 184:35-40.
- Saly J, Baranova D, Pesek L, Sevcikova Z, Koscik D, Sutiak V, Kremen J (2004) Effect of lead on health and productivity of layers. Bull. Vet. Inst. Pulawy. 48:75-80.

- Sandhir R, Gill KD (1995) Effect of lead on lipid peroxidation in liver of rats. *Biol Trace Elem Res.* 48:91-97.
- SAS Institute (2001) SAS/STAT User, Guide. Release Version 9.1. SAS Institute Inc. Cary, NC.
- Sedaghati B, Haddad R, Bandehpour M (2019) Efficient plant regeneration and Agrobacterium-mediated transformation via somatic embryogenesis in purslane (*Portulaca oleracea* L.): an important medicinal plant. *PCTOC.* 136: 231-245.
- Simopoulos AP (2001) The Mediterranean diets: what is so special about the diet of Greece? The scientific evidence. *J Nutr.* 131:3065S-3073S.
- Simopoulos AP, Tan DX, Manchester LC, Reiter RJ (2005) Purslane: a plant source of omega-3 fatty acids and melatonin. *J Pineal Res.* 39:331-332.
- Sipos P, Szentmihályi K, Feher E, Abaza M, Szilagyi M, Blazovics A (2003) Some effects of lead contamination on liver and gallbladder bile. *Acta Biol Szeged.* 47:139-142.
- Song Z, Lv J, Sheikahmadi A, Uerlings J, Everaert N (2017) Attenuating effect of zinc and vitamin E on the intestinal oxidative stress induced by silver nanoparticles in broiler chickens. *Biol Trace Elem Res.* 180:306-313.
- Stohs SJ, Bagchi D, Hassoun E, Bagchi M (2001) Oxidative mechanisms in the toxicity of chromium and cadmium ions. *J Environ Pathol Toxicol Oncol.* 20:77-88.
- Strehlow K, Rotter S, Wassmann S, Adam O, Grohé C, Laufs K, Nickenig G (2003) Modulation of antioxidant enzyme expression and function by estrogen. *Circ Res.* 93:170-177.
- Tangpong J, Satarug S (2010) Alleviation of lead poisoning in the brain with aqueous leaf extract of the *Thunbergia laurifolia* (Linn.). *Toxicol Lett.* 198:83-88.
- Tatli Seven P, Yilmaz S, Seven I (2009) The effect of propolis on selected blood indicators and antioxidant enzyme activities in broilers under heat stress. *Acta Vet. Brno.* 78:75-83.
- Usha B, Pushpalatha KC (2017) In vitro antioxidant and anti-inflammatory studies on leaf extract of *grewia heterotricha* mast and *grewia serrulata* dc. *World J Pharm Pharm Sci.* 6:750-764.
- Xienia U, Foote GC, Van S, Devreotes PN, Alexander S, Alexander H (2000) Differential developmental expression and cell type specificity of dictyostelium catalases and their response to oxidative stress and UV light. *Biochem. Biophys. Acta.* 149:295-310.
- Yen GC, Chen HY (1994) Antioxidant activity of various tea extracts in relation to their antimutagenicity. *J. Agric. Food Chem.* 43:27-32.
- Yuan C, Song HH, Jiang YJ, Azzam MMM, Zhu S, Zou XT (2013) Effects of lead contamination in feed on laying performance, lead retention of organs and eggs, protein metabolism, and hormone levels of laying hens. *J Appl Poult Res.* 22:878-884.
- Zhao XH, He X, Yang XF, Zhong XH (2013) Effect of *Portulaca oleracea* extracts on growth performance and microbial populations in ceca of broilers. *Poult Sci.* 92:1343-1347.

Molecular prevalence of *Toxoplasma gondii* in sheep from Isfahan, Iran as detected in heart samples by loop-mediated isothermal amplification (LAMP)

H. Raieszadeh¹, V. Noaman², G. Razmi³, A. Jamshidi⁴

¹Postgraduate student in the Department of Food Hygiene, Faculty of Veterinary Medicine, Ferdowsi University of Mashhad, Mashhad, Iran

²Department of Parasitic disease Research, Razi Vaccine and Serum Research Institute, Agricultural Research, Education and Extension Organization, (AREEO), Karaj, Iran.

³Department of Pathobiology, Faculty of Veterinary Medicine, Ferdowsi University of Mashhad, Mashhad, Iran

⁴Department of Food Hygiene, Faculty of Veterinary Medicine, Ferdowsi University of Mashhad, Mashhad, Iran

ABSTRACT. Toxoplasmosis is considered an important zoonosis that affects not only humans but also livestock worldwide. Small ruminants are important intermediate hosts of *T. gondii*. This study aimed to determine the molecular prevalence of *T. gondii* in the slaughtered sheep by loop-mediated isothermal amplification (LAMP) assay in Isfahan, Iran. A total of 250 sheep heart samples were collected from five different slaughterhouses in Isfahan, Iran, from October 2017 to May 2018. The LAMP assay was optimized targeting the sequence of 529 bp DNA fragments of *T. gondii* and detected *T. gondii* DNA in 96.4% (241/250) of samples. A significantly higher prevalence of *T. gondii* was recorded among female animals as compared to male animals ($p \leq 0.05$). No statistically significant difference in *T. gondii* prevalence was noted between the seasons, type of animals, and age groups ($p > 0.05$). To the best of our knowledge, the current study is the first to use the LAMP assay to determine the prevalence of *T. gondii* in sheep in Iran. The prevalence obtained in this study by the LAMP assay was higher than the prevalence reported by previous studies that used other methods. This study suggests that sheep meat may play a more prominent role as a source of infection of humans and the LAMP technique can be a recommended tool for accurate diagnosis of toxoplasmosis.

Keywords: *Toxoplasma gondii*, sheep, Loop-mediated isothermal amplification (LAMP), Iran

Corresponding Authors:

A. Jamshidi, Department of Food Hygiene, Faculty of Veterinary Medicine, Ferdowsi University of Mashhad, Mashhad, Iran
E-mail address: ajamshid@um.ac.ir

Date of initial submission: 16-12-2020
Date of revised submission: 03-04-2020
Date of acceptance: 27-04-2020

INTRODUCTION

Toxoplasma gondii is a zoonotic parasite with world-wide distribution; it is capable of developing in a wide variety of vertebrate hosts (carnivorous and herbivorous mammals and birds), but its final host is the domestic cat and some other members of the Felidae family. While the ingestion of cyst-containing meat may be a common route of infection among carnivores, herbivorous animals must acquire the infection by ingestion of oocysts. Transmission through the placenta usually occurs in the course of an acute but inapparent or undiagnosed maternal infection. In some domestic animals, chronic toxoplasmosis may lead to abortion, stillbirth or congenital defects of the newborn. Diagnosis is important for the control of toxoplasmosis (Dubey, 2009) and several tests are available to confirm the diagnosis. Sabin-Feldman dye test has proven to be reliable and accurate in a range of hosts and is the preferred test in most circumstances. The presence of antibodies against *T. gondii* in the blood is the usual sign for suspecting toxoplasmosis (Tavassoli et al., 2013). In PCR-based techniques, amplification of a specific part of the genome can generate many same copies of the target DNA sequence. Nested PCR (n-PCR) is applied not only to detect a few template copies of pathogens but also to increase the specificity of DNA products (Rostami et al., 2018). Various multi-copy targeting genes including 35-repeat B1 gene, 18S rRNA-, P30-, and 529-bp repeat fragment have been amplified for the detection of *T. gondii* in diverse samples (Rostami et al., 2018). Loop-mediated isothermal amplification (LAMP) is a rapid and efficient molecular assay, with higher specificity and sensitivity than other PCR-based methods (Sun et al., 2017). These characteristic features have stimulated many researchers to use this technique to detect different pathogens including *T. gondii* (Rostami et al., 2018). A systematic literature review/meta-analysis on the status of toxoplasmosis in Iran revealed that the prevalence of the infection is between 33-46% for humans, 26-35% for sheep, 14-42% for goats, 10-28% for cattle, and 22-46% for cats by different detection methods (Foroutan et al., 2018). A study has recently determined the prevalence of *T. gondii* in the Iranian house sparrow (*Passer domesticus*) by LAMP method (Abdoli et al., 2016). However, according to a survey of the literature, there are no data on the prevalence of *T. gondii* in small ruminants obtained with the use of LAMP assay in Iran. Therefore, the current study aimed to determine the molecular prevalence of *T. gondii* in slaughtered sheep as detected by LAMP assay in Isfahan, Iran.

MATERIALS AND METHODS

Area of study

The study was carried out on sheep in Isfahan province (longitude 49° 36'55" 31' E, latitude 30° 43'-34° 27' N), central Iran. The province is located almost in the center of Iran covering an approximate area of 107,027 km². The province has temperate and dry weather, on the whole, and the temperature varies between 10.6°C and 40.6°C on a warm day in the summer season. The mean annual temperature and rainfall have been recorded as 16.7°C, and 116.9 mm, respectively. According to statistics released by the Iranian Ministry of Jihad-e-Agricultural (animal production department) in 2017, in Isfahan province, there are about 1,398,000 sheep and 494,000 goats that produce more than 45.34 million kilograms of meat per year.

Sampling

A total of 250 sheep heart samples were randomly selected from five different slaughterhouses of Isfahan, Iran, from October 2017 to May 2018. The minimum sample size was calculated based on an estimated prevalence of 20%, an error of 5%, and a significance level of 5%, which was found to be 245 samples. However, the sample size was increased to 250 samples. Sampling was performed weekly for 25 weeks and the variables of age and sex were recorded for each animal. Each slaughterhouse was visited 25 times, and heart samples were randomly collected from two sheep for each sampling date. One gram (Approximately 1 cm³) heart sample (free of fat and connective tissue) was cut by a new sterile scalpel blade for every sample (to prevent cross-contamination) and put into sterile labeled sampling bags (75 x 125 mm). The samples were kept in a cold box immediately after collection and were transported to the research laboratory on the same day of the collection under cold conditions (2-4°C). At the laboratory, samples were frozen at liquid nitrogen and crushed in 1.5-mL plastic tubes before lysis. Proteinase K and lysis buffer (50 mL of Tris-HCl, 1 mM of EDTA, pH = 8.0; pH = 7.6, and 1% of Tween 20) were added to the 50mg homogenized heart sample and incubated at 50°C for 24 hours. DNA was isolated from heart samples using a Quick Genomic DNA Isolation Kit (MBST, Iran) according to the manufacturer's guidelines. Extracted DNA was dissolved in 100 µl of double-distilled water and stored at -20 °C until subsequent LAMP assays.

PCR assay

All primer sequences and the positions of the used primers are displayed in Table 1 and Figure 1, respectively (Lin et al., 2012; Zhang et al., 2009). In the beginning, the specificity of the outer LAMP primer pair (F3 and B3; Table 1) was tested using the PCR. The first PCR was performed in 25 µl total volume containing 1 µL extracted DNA (DNA extracted from mouse brain infected with *T. gondii* was used as the positive control), PCR buffer (one time), 0.5 U Taq Polymerase (Cinnagen, Iran) 200 µM of each dGTP, dATP, dCTP, and dTTP (Cinnagen, Iran), 1 µl of each primer (F3/ B3, 20 µM, Cinnagen), and 1.5 mM MgCl₂ in automated thermocycler (T100 Thermal

Cycler, Bio-Rad) using the following program: incubation at 95 °C for 4 min to denature double-strand DNA (Initial denaturation step), 35 cycles at 94 °C for 45 s (denaturation step), 55 °C for 45 s (annealing step) and 72 °C for 1.5 min (extension step). The PCR products were visualized under UV light after running on a 1.5% agarose gel and stained with ethidium bromide (1 µg/mL). To determine the least possible amount of template DNA in a reaction which can be detected by PCR assay, a serial dilution of DNA (positive control) was used and the minimum concentration of the genomic DNA sample (1:25) was selected and used to optimize the LAMP assay (Figure 2).

Table 1. Nucleotide sequences of LAMP primers designed in this study.

Target	Primer name	Nucleotide sequence	Amplicon	Reference or source
529-bp repetitive element	F3	5'-CCACAGAAGGGACAGAAGTC-3'	202 bp	(Zhang et al., 2009; Lin et al., 2012)
	B3	5'-TCCGGTGTCTCTTTTCCAC-3'		
	FIP	5'-TCCTCACCTCGCCTTCATCTAGGACTACAGACGCGATGC-3'		
	BIP	5'-TGTTGGGAAGCGACGAGAGTTCCAGGAAAAGCAGCCAAG-3'		
	LF	5'-TCCAAGACGGCTGGAGGAG-3'		
	LB	5'-CGGAGAGGGAGAAGATGTTTCC-3'		

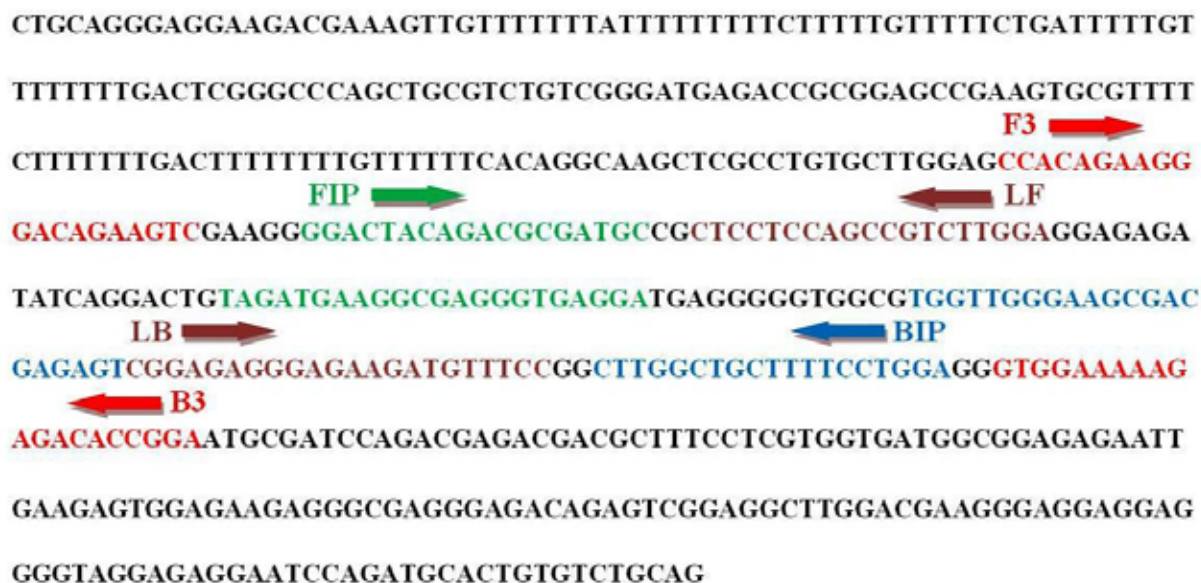

Figure 1. Position of six primers used for the LAMP assay targeting eight conserved regions within the sequence of 529 bp DNA fragment of *T. gondii* (GenBank accession number AF146527). The outer forward primer (F3), outer backward primer (B3), forward inner primer (FIP), backward inner primer (BIP), loop forward (LF) and backward (LB)

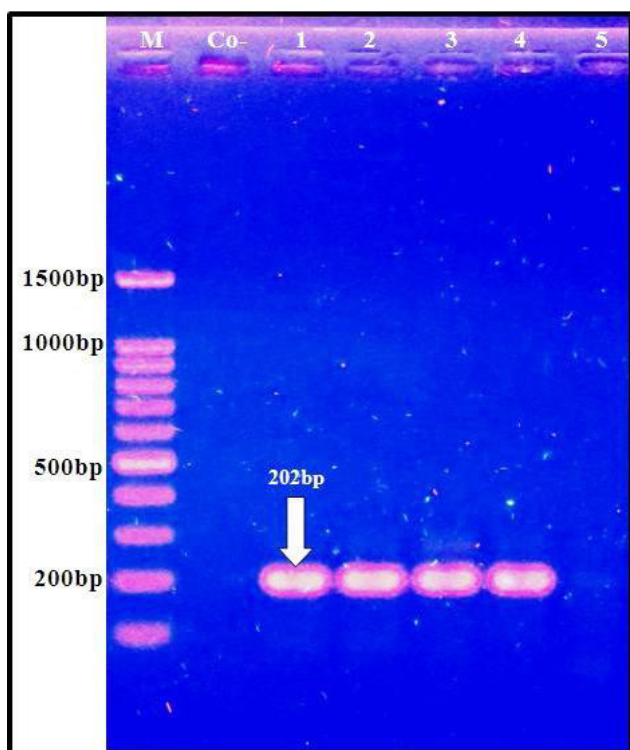


Figure 2. Electrophoresis of PCR products. A serial dilution of DNA (positive control) was amplified with primer F3/B3 resulting in PCR product of 202 bp in length (lanes 1=1:10, 2=1:15, 3=1:20, 4= 1:25 and 4= 1/30). M: 100 bp-plus molecular weight marker, Co-: Negative control (water).

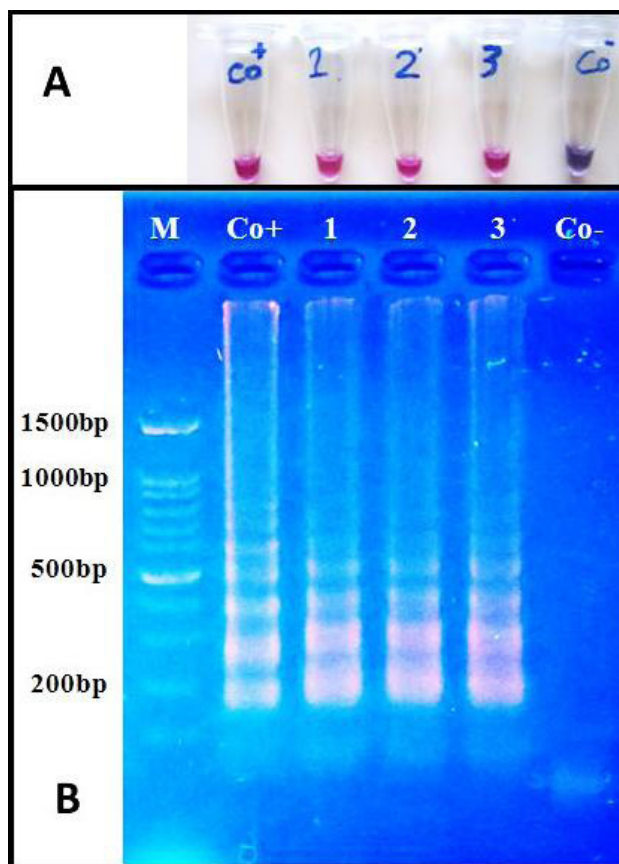


Figure 3. Results of optimized LAMP assay for the specific detection of *T. gondii* DNA targeting the RE gene. (A) Visual detection of the LAMP products based on HNB color change. (B) Agarose gel electrophoresis of LAMP products. M: 100 bp-plus molecular weight marker, Co+: Positive control, Co-: Negative control (water).

Optimization and LAMP assay

Different temperatures (60, 61, 62, 63, 64, 65, 66, 67 and 68 °C), different incubation times (60min, 90 min and 120 min) and different concentrations of MgSO₄ (8mM, 10mM, 12mM and 14mM), Bst DNA polymerase (64, 128, 192, 256, 320 U/ml) and betaine (0.8 mM, 1mM and 1.2 mM) were examined to improve the efficiency of LAMP reactions. The colorimetric assay for LAMP carried out by adding Hydroxy naphthol blue (HNB).

Statistical analysis

Chi-square (χ^2) test was used to compare the variable factors (season, sex, age and type of animal) in animals infected with *T. gondii* by using Statistical Package for Social Services (SPSS Inc, Chicago, USA) version 18.0. A p-value equal to 0.05 or less than 0.05 was considered statistically significant.

RESULTS

Optimization of LAMP reaction

During optimization, the best LAMP assay was performed in a 25 μ l reaction volume as follows: 2.5 μ l of 10 \times ThermoPol buffer (New England Biolabs, USA), 4.8 U Bst DNA polymerase (New England Biolabs, USA), 0.8 mM Betaine, 8 mM MgCl₂, 1.4 mM of each dNTP, 1.6 μ M of the primers FIP/BIP, 0.2 μ M of the primers F3/B3, 0.4 μ M of the primers LF/LB and 0.5 μ l (1:25 dilution) of DNA as the template. The best results were obtained when the reaction was performed at 66°C and the minimum time for completion of the reaction was 90 min. The reaction was finalised at 80°C for 10 min. HNB was added to the reaction solution at the final concentration of 120 μ M. The color changes occurring in the tubes were monitored by naked eye observation. A color change to reddish blue demonstrates a positive LAMP reaction while negative samples stay in violet color (Figure 3-A).

LAMP on the heart samples

The genomic DNA extracted from sheep hearts were tested by LAMP assay as explained in LAMP optimization. LAMP assay revealed that 96.4% (241/250) of samples were positive for *T. gondii* DNA. The prevalence of *T. gondii* was significantly higher in female animals as compared to male animals ($p \leq$

0.05) (Table 2). In spring season a relatively higher prevalence was shown as compared to other seasons, but the difference was not statistically significant ($p = 0.07$). Similarly, no statistically significant difference in *T. gondii* prevalence was noted between the type of animals ($p = 0.16$), and age groups ($p = 0.96$).

Table 2. Prevalence of *Toxoplasma gondii* DNA in sheep of Isfahan province according to the season, sex and age based on the LAMP method.

Category	Level	Number tested	Positive	Prevalence %	95% Confidence Interval		p-value
					Lower	Upper	
All animals	Total	250	241	96.4	94.1	98.7	-
	Winter	133	125	94.0	89.9	98.0	
Season	Fall	50	49	98.0	94.1	101.9	0.07
	Spring	67	67	100.0	100.0	100.0	
Age	<1 Year	54	52	96.3	91.3	101.3	0.96
	1-3 Years	196	189	96.4	93.8	99.0	
Sex	Female	105	104	99.0	97.2	100.9	0.05*
	Male	145	137	94.5	90.8	98.2	

* $P \leq 0.05$

DISCUSSION

Toxoplasmosis caused by *Toxoplasma gondii* is distributed worldwide. The disease is considered an important zoonosis that affects not only humans but also livestock. The prevalence of *T. gondii* is higher in small ruminants as compared to cattle, due to the higher susceptibility of small ruminants to *T. gondii* than cattle (Dubey, 2009; Sharif et al., 2015). Iran is one of the biggest sheep raising and consuming countries (more than 45 million sheep per year) in the world. Economic losses caused by abortions, stillbirths, fetal mummification and births of weak lambs from sheep with toxoplasmosis are predicted to be enormous. Furthermore, these impact on people's lives who are dependent on sheep meat production as a most important source of income (Pan et al., 2017). The prevalence of *T. gondii* in intermediate and final hosts completely differs from one country to another depending on the feeding behavior of animals and humans, environmental factors and socio-economic patterns (Hassanain et al., 2013). Oocysts, bradyzoites, and tachyzoites are the three infectious stages of *T. gondii*. Transmission of tachyzoites can occur via the placenta following primary maternal infection and rarely from ingestion of unpasteurized milk or by direct entry into the bloodstream through a blood transfusion or laboratory accident (Dubey, 2009; Sharif et al., 2015). Approximately 50% of human cases of toxoplasmosis result from the ingestion

of bradyzoites or tissue cysts in meat, meat-derived products or edible offal (such as heart, liver, and kidney) (Hassanain et al., 2013). Lamb meat is one of the major meats used for barbecue (Kebab) in Iran. Because barbecued meat is not cooked properly, there is risk of food-borne toxoplasmosis. For this reason, sheep toxoplasmosis may be the major source of the disease in humans.

In this study, samples were taken from the heart of sheep. This site of sampling was selected because following oral infection of small ruminants, *T. gondii* is mainly localized in the heart and brain tissues (Esteban-Redondo et al., 1999).

A wide range of serological methods including indirect fluorescent antibody tests, enzyme-linked immunosorbent assay, immunosorbent agglutination assay, indirect hemagglutination assay, modified agglutination test, Sabin-Feldman dye test, and Western blot have been applied in extensive epidemiological surveys (Dard et al., 2016). Although serological tests are used extensively in epidemiologic studies, because they are time-consuming, lack in diagnosing primary infections, present antigen cross-reactivity, and antibodies disappear in the long-term, these tests are not reliable when compared to molecular techniques (Sun et al., 2017).

Several diagnostic molecular methods, based on various targets and protocols, have been developed

for direct detection of *T. gondii* DNA in tissues (Khan and Noordin, 2019). The first PCR assay for the detection of *T. gondii* was founded based on the amplification of the 35-repeat B1 gene of the *T. gondii* genome (Burg et al., 1989). Subsequently, various genes including B1-genes, P30, 18S rRNA, the AF146527 element or 529-bp repeat element (RE) have been used for molecular detection of *T. gondii* in different samples (Rostami et al., 2018). Previous studies have shown that the multi-copy genes are more sensitive as compared to single-copy genes for molecular diagnosis of the parasite in samples (Fallahi et al., 2014). The 529 bp-RE genes are repeated 200- to 300-fold in the *T. gondii* genome and exist in all *T. gondii* tested (60 strains) and differentiated the *T. gondii* DNA from the DNA of humans, animals, and the other parasites (Homan et al., 2000). The results of many studies demonstrated that PCR and nested PCR based on the RE gene detected more positive samples as compared with the B1 gene (Fallahi et al., 2014; Homan et al., 2000). Results of PCR with the two multi-copy genes demonstrate that the B1 gene is 10-100 times less sensitive than the 529-bp RE gene in the detection of *T. gondii* (Homan et al., 2000).

The LAMP test is a specific, highly sensitive, and simple method compared to conventional PCR and nested-PCR. This method is not expensive and time-consuming, and it does not require complex equipment. Till now, LAMP has been used for the detection of different parasitic protozoan diseases, including cryptosporidiosis, piroplasmosis, and trypanosomosis (Sun et al., 2017). This method is a favorable molecular technique to be used for the diagnosis of toxoplasmosis, specifically in developing countries with a high prevalence rate (Khan and Noordin, 2019). In a comparative study the sensitivity of the LAMP-based on the 529 bp-RE genes was 1000- and 100-fold higher than that of the RE-nested PCR and B1-LAMP, respectively (Kong et al., 2012).

In the present study, 96.4% of samples were found to be positive for *T. gondii* infection by LAMP. To the best of our knowledge, the current study is the first to use the LAMP assay to determine the prevalence of *T. gondii* in sheep in Iran. Several serological studies have reported the prevalence of *T. gondii* in different regions of Iran, but little research has been performed on molecular detection of *T. gondii* infection in small ruminants. Recent reports in Iran revealed a molecular prevalence of *T. gondii* in sheep and goats in the range of 1.26–66% and 1.07–44.16 %, respectively

(Armand et al., 2016; Asgari et al., 2011; Habibi et al., 2012; Nematollahi et al., 2014; Tavakoli-Kareshk et al., 2017; Tavassoli et al., 2013).

Most of the epidemiological surveys on small ruminants in Iran were established upon detecting *T. gondii* antibodies serum samples. According to those surveys whose methodology allows us to estimate prevalence rates, the overall seroprevalence of toxoplasmosis in sheep and goats of Iran is estimated to be 31% and 27%, respectively (Sharif et al., 2015).

In Iran, the highest seroprevalence rate for toxoplasmosis that was ever reported was 95% in Mazandaran province, northern Iran and the lowest prevalence rate was 5.2% in the northeast of Iran at Khorasan province (Razmi et al., 2010).

Journal of Parasitology
 Volume 96, Number 4, 2010
 Pages 812-815
 ISSN 0022-3395
 DOI: 10.1017/S0022339510000416

The prevalence recorded in this study is based on a molecular method and is higher than those previously reported in small ruminants of Iran: 37.5% (sheep) and 22.7% (goat) in southwest Iran (Asgari et al., 2011), 34.32 % (sheep) in south of Iran (Armand et al., 2016), and 56.66% (sheep) and 44.16 (goat) in Eastern Iran (Tavakoli-Kareshk et al., 2017). This prevalence could reflect the LAMP is 10-1000 times more sensitive compared with conventional nested PCR (Khan and Noordin, 2019; Kong et al., 2012).

The high prevalence in sheep (96.4%) reported in the present study could reflect the widespread distribution of the parasite and high level of environmental contamination.

This finding indicates that *T. gondii* oocysts are widely distributed in small ruminants farms in Isfahan. Horizontal transmission of *T. gondii* to small ruminants by the oral uptake of environmentally resistant oocysts through contaminated fodder or water is considered the most important route of transmission (Stelzer et al., 2019). This high prevalence suggesting that *T. gondii* oocysts may be transmitted by water and annual precipitation possibly help the oocyst spread and retains access for potential hosts. Since farm animals represent a direct source of infection for humans, but also a possible reservoir for the parasite, it is important to control *T. gondii* infec-

tions in livestock (Guo et al., 2015).

Measures of hygiene and regimes of cleaning and disinfection applied at the farms may play an important role in the infection of livestock with *T. gondii* because cleaning reduces the probability of contamination of the facilities with oocysts and may also reduce exposure to infected intermediate hosts. The presence of cats often determines the risk of a farm being infected, thus cat control is a key to the control of toxoplasmosis in farms, as well as rodent control (Stelzer et al., 2019). The high prevalence of *T. gondii* in small ruminants is an important source of meat-borne toxoplasmosis in humans and is limited by avoiding the consumption of undercooked meat containing bradyzoites (Dubey et al., 2008).

However, some of the disagreement between the recorded results could be the consequence of (1) the use of inadequately small number of animals, which will lead imprecise estimate and possibly impaired objectivity of data; (2) different geographic areas with various climatic conditions; (3) management practices; (4) different diagnostic methods (Serological or Molecular) with different sensitivity and specificity. Various types of samples and selected cut-offs affect the efficiency of the serological tests; (5) sex and age of animals (Abdallah et al., 2019; Olsen et al., 2019; Sharif et al., 2015); and (6) feeding behavior of animals. In the pasture, goats tend to consume from the top of plants, trees or shrubs to obtain the desired forage and do not like to graze near the soil surface, as sheep do (Guo et al., 2015).

Concerning season, the prevalence in spring was higher than in fall and winter, but statistically, there was no difference significant ($P > 0.05$). Our finding is similar to the results of one study in Iran (Armand et al., 2016) and contrary to those who indicated a statistically significant between season and *T. gondii* prevalence (Gebremedhin et al., 2014; Yin et al., 2015). In spring, the climate is temperate and humid which extends the survival time of *T. gondii* oocysts. Also, the increased activity of cats in spring leads to the widespread distribution of oocysts. These may explain the higher seroprevalence in spring.

In several studies, it has been found that the prevalence of the *T. gondii* infection increased with age. This could be due to a shorter exposure of the younger to *T. gondii* infection than the adults (Guo et al., 2015; Sharif et al., 2015; Stelzer et al., 2019). The results of the current investigation suggest that

there was no significant difference in the prevalence between the age groups in Isfahan sheep ($P > 0.05$), which was similar to previous studies (Alvarado-Esquivel et al., 2013; Armand et al., 2016; Yin et al., 2015).

Regarding sex, the prevalence in female animals was higher than in male animals ($p \leq 0.05$). Several studies found that the prevalence in females was higher than males (Abdallah et al., 2019; Asgari et al., 2011; Kamani et al., 2010; Lopes et al., 2010). However, no statistically significant difference between the prevalence in females and males has been reported in some studies (Alvarado-Esquivel et al., 2013; Armand et al., 2016; Khezri et al., 2012; Yin et al., 2015). The higher prevalence in females was probably due to: (1) In Iran, females are reared for breeding purposes and live much longer exposed to *T. gondii* oocysts on the pastures. (2) The immune response is lower in ewes before and after parturition.

CONCLUSIONS

In conclusion, the LAMP assay targeting the RE gene was employed successfully in field samples for the detection of *T. gondii* and is purposed as a suitable method for the routine molecular diagnosis of toxoplasmosis, where providing of modern equipment is not possible. The results of the present study demonstrated a high rate of *T. gondii* DNA in the heart tissue of slaughtered sheep compared with other parts of Iran and the world. In the light of the high rate of *T. gondii* infection in sheep in this region, undercooked eatable tissues of these animals must be considered as sources of *Toxoplasma* infection for humans. Proper cooking of lamb meat and standardization of preparation and handling of meats can be recommended for preventing the transmission of *Toxoplasma* to humans. Moreover, not feeding raw or undercooked meat to cats and keeping cats outside the sheep breeding farms will reduce the risks of infection from cats to sheep.

ACKNOWLEDGEMENTS

We would like to sincerely thank the Isfahan Agricultural and Natural Resources Research and Education Center, AREEO, Isfahan, Iran for the approval and partial support of this research.

CONFLICT OF INTEREST STATEMENT

The authors declared no conflict of interest.

REFERENCES

- Abdallah M-C, Kamel M, Karima B, Samir A, Djamel K, Rachid K, Khatima A-O (2019) Cross-Sectional Survey on *Toxoplasma gondii* Infection in Cattle, Sheep, and Goats in Algeria: Seroprevalence and Risk Factors. *Vet Sci* 6:63.
- Abdoli A, Dalimi A, Soltanghorae H, Ghaffarifar F (2016) Molecular detection of *Toxoplasma gondii* in house sparrow (*Passer domesticus*) by LAMP and PCR methods in Tehran, Iran. *J Parasit Dis* 40:1317-1321.
- Alvarado-Esquivel C, Silva-Aguilar D, Villena I, Dubey JP (2013) Seroprevalence and correlates of *Toxoplasma gondii* infection in domestic sheep in Michoacán State, Mexico. *Prev Vet Med* 112:433-437.
- Armand B, Solhjoo K, Shabani-Kordshooli M, Davami MH, Sadeghi M (2016) *Toxoplasma* infection in sheep from south of Iran monitored by serological and molecular methods; risk assessment to meat consumers. *Veterinary world* 9:850.
- Asgari Q, Sarnevesht J, Kalantari M, Sadat SJA, Motazedian MH, Sarkari B (2011) Molecular survey of *Toxoplasma* infection in sheep and goat from Fars province, Southern Iran. *Trop Anim Health Prod* 43:389-392.
- Burg JL, Grover CM, Pouletty P, Boothroyd J (1989) Direct and sensitive detection of a pathogenic protozoan, *Toxoplasma gondii*, by polymerase chain reaction. *J Clin Microbiol* 27:1787-1792.
- Dard C, Fricker-Hidalgo H, Brenier-Pinchart M-P, Pelloux H (2016) Relevance of and new developments in serology for toxoplasmosis. *Trends Parasitol* 32:492-506.
- Dubey J, Sundar N, Hill D, Velmurugan G, Bandini L, Kwok O, Majumdar D, Su C (2008) High prevalence and abundant atypical genotypes of *Toxoplasma gondii* isolated from lambs destined for human consumption in the USA. *Int J Parasitol* 38:999-1006.
- Dubey J (2009) Toxoplasmosis in sheep—the last 20 years. *Vet Parasitol* 163:1-14.
- Esteban-Redondo I, Maley S, Thomson K, Nicoll S, Wright S, Buxton D, Innes E (1999) Detection of *T. gondii* in tissues of sheep and cattle following oral infection. *Vet Parasitol* 86:155-171.
- Fallahi S, Tabaei SJS, Pournia Y, Zebardast N, Kazemi B (2014) Comparison of loop-mediated isothermal amplification (LAMP) and nested-PCR assay targeting the RE and B1 gene for detection of *Toxoplasma gondii* in blood samples of children with leukaemia. *Diagn Microbiol Infect Dis* 79:347-354.
- Foroutan M, Dalvand S, Daryani A, Ahmadpour E, Majidiani H, Khademvatan S, Abbasi E (2018) Rolling up the pieces of a puzzle: a systematic review and meta-analysis of the prevalence of toxoplasmosis in Iran. *Alexandria J Med* 54:189-196.
- Gebremedhin EZ, Abdurahaman M, Hadush T, Tessema TS (2014) Seroprevalence and risk factors of *Toxoplasma gondii* infection in sheep and goats slaughtered for human consumption in Central Ethiopia. *BMC Res Notes* 7:696.
- Guo M, Dubey JP, Hill D, Buchanan RL, Gamble HR, Jones JL, Pradhan AK (2015) Prevalence and risk factors for *Toxoplasma gondii* infection in meat animals and meat products destined for human consumption. *J Food Prot* 78:457-476.
- Habibi G, Imani A, Gholami M, Hablolvarid M, Behroozikhah A, Lotfi M, Kamalzade M, Najjar E, Esmail-Nia K, Bozorgi S (2012) Detection and identification of *Toxoplasma gondii* type one infection in sheep aborted fetuses in Qazvin Province of Iran. *Iran J Parasitol* 7:64-72.
- Hassanain MA, El-Fadaly HA, Hassanain NA, Shaapan RM, Barakat AM, Abd El-Razik K (2013) Serological and molecular diagnosis of toxoplasmosis in human and animals. *World J Med Sci* 9:243-247.
- Homan W, Vercammen M, De Braekeleer J, Verschueren H (2000) Identification of a 200-to 300-fold repetitive 529 bp DNA fragment in *Toxoplasma gondii*, and its use for diagnostic and quantitative PCR. *Int J Parasitol* 30:69-75.
- Kamani J, Mani AU, Ekwu GO (2010) Seroprevalence of *Toxoplasma gondii* infection in domestic sheep and goats in Borno state, Nigeria. *Trop Anim Health Prod* 42:793-797.
- Khan AH, Noordin R (2019) Serological and molecular rapid diagnostic tests for *Toxoplasma* infection in humans and animals. *Eur J Clin Microbiol Infect Dis* 1-12.
- Khezri M, Mohammadian B, Esmailnia K, Khezri O (2012) Toxoplasmosis in sheep from Kurdistan province, Iran. *Afr J Microbiol Res* 6:3989-3992.
- Kong Q-M, Lu S-H, Tong Q-B, Lou D, Chen R, Zheng B, Kumagai T, Wen L-Y, Ohta N, Zhou X-N (2012) Loop-mediated isothermal amplification (LAMP): early detection of *Toxoplasma gondii* infection in mice. *Parasit Vectors* 5:2.
- Lin Z, Zhang Y, Zhang H, Zhou Y, Cao J, Zhou J (2012) Comparison of loop-mediated isothermal amplification (LAMP) and real-time PCR method targeting a 529-bp repeat element for diagnosis of toxoplasmosis. *Parasitol* 185:296-300.
- Lopes WZ, dos Santos TR, da Silva RdS, Rossanese WM, de Souza FA, de Faria Rodrigues JDA, de Mendonça RP, Soares VE, da Costa AJ (2010) Seroprevalence of and risk factors for *Toxoplasma gondii* in sheep raised in the Jaboticabal microregion, São Paulo State, Brazil. *Res Vet Sci* 88:104-106.
- Nematollahi A, Allah Jafari R, Shahbazi P, Khoshkardar M, Zabolli N, Nouruzi M (2014) Survey on ovine toxoplasmosis by IFAT and double-tube nested-PCR in Tabriz, Iran. *Comparative Clinical Pathology* 23:1583-1586.
- Olsen A, Berg R, Tagel M, Must K, Deksné G, Enemark HL, Alban L, Johansen MV, Nielsen HV, Sandberg M, Lundén A, Stensvold CR, Pires SM, Jokelainen P (2019) Seroprevalence of *Toxoplasma gondii* in domestic pigs, sheep, cattle, wild boars, and moose in the Nordic-Baltic region: A systematic review and meta-analysis. *Parasite Epidemiol Control* 5:e00100.
- Pan M, Lyu C, Zhao J, Shen B (2017) Sixty years (1957–2017) of research on toxoplasmosis in China—An overview. *Front Microbiol* 8:1825.
- Razmi GR, Ghezi K, Mahooti A, Naseri Z (2010) A serological study and subsequent isolation of *Toxoplasma gondii* from aborted ovine fetuses in Mashhad area, Iran. *J Parasitol* 96:812-815.
- Rostami A, Karanis P, Fallahi S (2018) Advances in serological, imaging techniques and molecular diagnosis of *Toxoplasma gondii* infection. *Infect* 46:303-315.
- Sharif M, Sarvi S, Shokri A, Teshnizi SH, Rahimi M, Mizani A, Ahmadpour E, Daryani A (2015) *Toxoplasma gondii* infection among sheep and goats in Iran: a systematic review and meta-analysis. *Parasitol Res* 114:1-16.
- Stelzer S, Basso W, Silván JB, Ortega-Mora L, Maksimov P, Gethmann J, Conraths F, Schares G (2019) *Toxoplasma gondii* infection and toxoplasmosis in farm animals: risk factors and economic impact. *Food and Waterborne Parasitol* 15:e00037.
- Sun X-m, Ji Y-s, Liu X-y, Xiang M, He G, Xie L, Suo J-x, Suo X (2017) Improvement and evaluation of loop-mediated isothermal amplification for rapid detection of *Toxoplasma gondii* infection in human blood samples. *PLoS One* 12:1-11.
- Tavakoli-Kareshk A, Mahmoudvand H, Keyhani A, Oliaee TR, Mohammadi M, Babaei Z, Hajhosseini M, Zia-Ali N (2017) Molecular detection and genetic diversity of *Toxoplasma gondii* in different tissues of sheep and goat in Eastern Iran. *Trop Biomed* 34:681-690.
- Tavassoli M, Esmailnejad B, Malekifard F, Soleimanzadeh A, Dilmaghani M (2013) Detection of *Toxoplasma gondii* DNA in Sheep and Goat Milk in Northwest of Iran by PCR-RFLP. *Jundishapur J Microbiol* 6:8201.
- Tavassoli M, Ghorbanzadehghan M, Esmailnejad B (2013) Detection of *Toxoplasma gondii* in sheep and goats blood samples by PCR-RFLP in Urmia. *Vet Res Forum* 4:43-47.
- Yin M-Y, Wang J-L, Huang S-Y, Qin S-Y, Zhou D-H, Liu G-X, Tan Q-D, Zhu X-Q (2015) Seroprevalence and risk factors of *Toxoplasma gondii* in Tibetan Sheep in Gansu province, Northwestern China. *BMC Vet Res* 11:41.
- Zhang H, Thekisoe OM, Aboge GO, Kyan H, Yamagishi J, Inoue N, Nishikawa Y, Zakimi S, Xuan X (2009) *Toxoplasma gondii*: sensitive and rapid detection of infection by loop-mediated isothermal amplification (LAMP) method. *Exp Parasitol* 122:47-50.

Seroprevalence of *Coxiella burnetii* among ewes and associated risk factors in Constantine (Northeastern Algeria)

S. Hireche¹, A. Agabou², O. Bouaziz¹

¹GSPA Research Laboratory. Institute of Veterinary Sciences. University Frères Mentouri Constantine 1. Algeria

²PADESCA Research Laboratory. Institute of Veterinary Sciences. University Frères Mentouri Constantine 1. Algeria

ABSTRACT. Q fever is a zoonotic disease caused by the rickettsia-like *Coxiella burnetii* and leads to abortions and decreased reproductive performances in domestic ruminants. A serological survey, using ELISA test, was conducted to assess the prevalence of this infection in 226 ewes belonging to 39 flocks localized in Constantine (North-eastern Algeria). A pretested questionnaire has been submitted to farmers/shepherds to collect information related to relevant risk factors.

Results revealed the presence of *C. burnetii* antibodies in 12.4% (95% CI: 8.08%–16.72%) of individual animals while 35.9% (95% CI: 21.20%–52.82%) of sampled flocks accounted at least one seropositive ewe. Significant causative associations were observed for origin of animals ($\chi^2=14.29$, $P=0.001$), vaccination against enterotoxaemia ($\chi^2=12.12$, $P=0.002$) and pox ($\chi^2=5.30$, $P=0.025$), access to the farm by foreign visitors ($\chi^2=10.87$, $P=0.004$), farmers/shepherds' visits to other farms ($\chi^2=6.31$, $P=0.021$), disinfection frequency ($\chi^2=7.98$, $P=0.046$), pest infestation within farms ($\chi^2=9.55$, $P=0.049$) and abortion history ($\chi^2=5.54$, $P=0.029$). This recorded prevalence of *Coxiella* infection would indicate a possible responsibility of this agent in causing abortion and reproductive failures in the tested flocks.

Implementing active surveillance programs and further investigations using more accurate analyses and including large samples of more animal species from several provinces are needed to elucidate the real occurrence and dynamics of this infection in the national livestock.

Keywords: Coxiellosis; prevalence; ELISA; risk factors; ewes; Constantine

Corresponding Author:

S. Hireche, Institute of Veterinary Sciences. University Frères Mentouri of Constantine 1. Route de Guelma, El Khroub. Constantine 25100. Algeria
E-mail address: hireche.sana@umc.edu.dz

Date of initial submission: 18-12-2019

Date of revised submission: 27-03-2020

Date of acceptance: 07-04-2020

INTRODUCTION

Q fever is a widespread zoonosis acknowledged and named for the first time by Edward Derrick in abattoir workers in Australia. It is caused by a small obligate intracellular bacterium *Coxiella burnetii* (de Valk, 2012). A large variety of domestic and wild animal species (mainly cattle, and small ruminants, pets and rodents) are known natural reservoirs for this pathogen (Cutler *et al.*, 2007). Transmission is possible through inhalation of contaminated aerosols generated during birthing or slaughtering of infected asymptomatic animals, which also shed the bacterium in faeces and many physiological secretions (Rodolakis, 2009; Schimmer *et al.*, 2010). In nature, arthropods such as ticks may play a role in the epidemiology of *C. Burnetii* because of their ability to harbour and transmit it trans-stadially and trans-ovarially to their descendants. Nevertheless, in livestock and humans, tick bite is an uncommon route of Coxiellosis (Sprong *et al.*, 2012; Mancini *et al.*, 2014).

In humans, the acute illness is self-limiting and evolves in general as a non-specific flu-like syndrome with inconstant pneumonia and hepatitis; whereas the chronic form (causing meningoencephalitis, myocarditis, endocarditis and other vascular infections) is life-threatening if untreated (Angelakis and Raoult, 2010). Pregnant women generally do not exhibit any clinical signs but their infection leads to obstetrical complications, spontaneous abortions and premature delivery (de Lange *et al.*, 2014).

In domestic ruminants, sheep appear to be more infected than goats and cattle (McQuiston *et al.*, 2002). Q fever is often latent and is responsible for abortion (with placentitis and endometritis) and other reproductive disorders characterized by premature births, weak or unviable progeny, infertility and mastitis (Tissot-Dupont and Raoult, 2008; Georgiev *et al.*, 2013).

Since Q fever has no specific symptoms, the diagnosis confirmation is made through laboratory analyses among which, serology remains the most commonly used because of easy serum samples collection and complicated cultivation/isolation of the bacterium. In veterinary medicine, the ELISA test allows detection of phase I and II antibodies, and due to its sensitivity, it is preferred to CFT and IFA which remains the gold standard for detection of antibodies against *C. burnetii* during acute human Coxiellosis (Horig-

an *et al.*, 2011; Stephen *et al.*, 2017).

In Algeria, there are about 26.6 million sheep, mainly located in the steppes and high plateaus, where they are reared under traditional practices and play an important role in the livelihood of many families (MADR, 2014). Nevertheless, the incidence of asymptomatic abortion in late gestation ewes is frequently reported by veterinarians causing substantial economic losses while Q fever continues to be neglected or under-diagnosed as one of the possible aetiologies of these outbreaks.

Furthermore, few studies have been undertaken on this infection because of the deficiency in diagnostic tools; even though it seems to be disseminated all over the country since it has been reported in cattle in Bejaïa (North) and Sétif (North-East), sheep in Médéa (Central North) and camels in Biskra, El-Oued, Ouargla and Ghardaïa (South) (Yahiaoui *et al.*, 2013; Agag *et al.*, 2016; Benaïssa *et al.*, 2017; Menadi *et al.*, 2019).

The present study determines the prevalence and risk factors of Q fever in ewes' population in Constantine province (North-East Algeria) and brings more insights on this infection in the local livestock, which may result in implementing more efficient preventive and control approaches.

MATERIAL AND METHODS

Study area

All the 12 municipalities of Constantine province were included in this survey. This region is located in the northeast of Algeria, at about 80 km from the Mediterranean Sea coast. It is considered as the third most populated city to which converge all the eastern high plateaus. It is about 2 297.2 km² with an altitude ranging from 300 to 1 000 m. Constantine is characterized by a semiarid climate with a typical hot and relatively dry season between June and August, and a wet season from December to April. Rain season corresponds to December, January and February with 350-500 mm of rainfall. The temperature is 25°- 40°C during summer and 0°-12°C during winter.

The ovine population counts about 179 220 heads (111 290 ewe) belonging to 1 938 flocks. Sheep breeding season usually begins in July when the daylight starts to decline. All flocks enrolled in this study grazed along the spring season till the end of August

with no feed supplementation. Along fall and winter, animals are housed and fed straw, barley, and wheat bran. Lambing period habitually lasts from December to March.

Sampling procedure

The study protocol was evaluated and approved by the ethical committee of the scientific board of the institute of veterinary sciences. University Frères Mentouri Constantine 1, Algeria.

From March 2011 to January 2012, livestock owners were contacted and informed about the purpose and the methods of the study to obtain their verbal consent. The animal welfare guidelines were rigorously followed.

The needed sample size estimation was performed in two steps (random selection of a defined number of flocks then the number of sheep to be selected was individually determined by flocks) using formulas for simple random sampling given by Thrusfield (2007).

$$N = \frac{(1.96)^2 P(1-P)}{L^2}$$

Where N is the needed sample size, $4 = (1.96)^2$ is the error alpha, P is the disease prevalence and L is the allowed error or required precision (0.06).

At the herd level, total number of flocks to be sampled was calculated by dividing the total individual sample size by the number of animals to sample from

each flock. Thus, 39 flocks of 20 to 500 heads were randomly selected. Flocks were stratified according to their size: 6 (≤ 20 heads), 8 (> 20 heads ≤ 50), 5 (> 50 heads ≤ 100), 10 (> 100 heads ≤ 300) and 10 (> 300 heads ≤ 500).

At the individual level, sample size was determined for each flock so as to detect the existence of the disease. Calculations were made using the formula commonly applied in veterinary epidemiological investigations:

$$n = \left[1 - (1 - p)^{1/d} \right] \times \left(N - \frac{d}{2} \right) + 1$$

Where n is the essential sample size, p is the probability of detection of at least one seropositive ewe, N is the herd size, and d is the number of seropositive ewes in the herd. The probability to detect at least one seropositive ewe in a herd was determined at 95% ($p=0.95$), while the number of seropositive ewes in each herd (d) was estimated assuming that within herd prevalence equals 10% (since there was no previous study in this area).

Accordingly, the minimum required sample size was calculated to be about 100 ewes. However, and in order to increase the precision of the study, a total of 226 ewes were enrolled belonging to 39 flocks localized all over Constantine. Number of ewes and flocks to be sampled per municipality was proportional to its total number of animals and flocks respectively. Herds' distribution is shown in Figure 1.

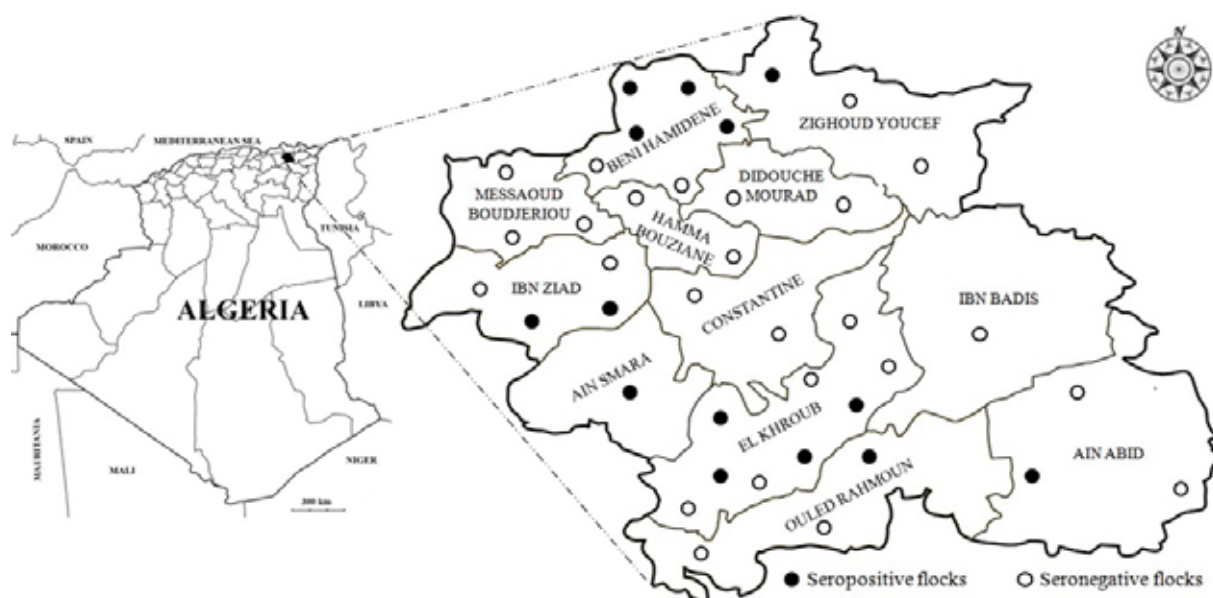

Figure 1. Distribution of seropositive and seronegative flocks among the 12 municipalities of Constantine

Blood was collected from jugular vein with disposable needle in plain Vacutainer® tubes labeled and conveyed quickly on ice to the laboratory. Sera were then separated from the clot by centrifugation and stored at -20°C until analyses. Each flock was assigned an identification number (ID n°) and its characteristics were recorded.

Serological tests

Detection of *C. burnetii* specific antibodies was carried out by using a commercial Enzyme-Linked ImmunoSorbent Assay (ELISA) according to the manufacturer's recommendations and protocols (LSIVET Ruminant Milk/Serum Q Fever ELISA COXLS LSI, Lissieu, France). The antigen is a sheep strain (phase I-II). Sensitivity of this ELISA test reaches 87% and specificity 100%. Absorbance values were measured at 450 nm (OD_{450}) using an ELx800™ absorbance microplate reader (Bio-Tek Instruments®, INC, Vermont, USA). Antibody reactivity was estimated using the sample to positive ratio (S/P) calculated as $(\text{Sample OD} - \text{Negative OD}) / (\text{Positive OD} - \text{Negative OD}) \times 100$. The S/P values were classified as negative (S/P ratio ≤ 40) or positive (S/P ratio > 40). A flock was defined as infected if it included at least one seropositive ewe.

Serological analyses were performed at the Department of Reproductive Pathology, École Nationale Vétérinaire de Nantes ONIRIS, France.

Epidemiological data collection

A questionnaire has been pre-established and pre-tested on farmers/shepherds non-included in this study to verify its accuracy and clarity. The final version included 65 questions of which 75% were close ended. Data related to farm characteristics, flock composition and characteristics, feed and water origin and quality, origin of animals (home bred or purchased), reproductive performances and problems (mainly abortion), health status of animals, treatments and vaccinations, contact with other animals or humans, biosecurity measures, disinfection and pest management were collected. Ages (in years) of sampled ewes were divided into three classes: ≤ 2 yrs, $2 < \text{yrs} \leq 3$ and $3 < \text{yrs} \leq 4$.

Data analysis

Data collected through the questionnaire and the results of serological analysis were coded, stored, and analysed using SPSS 20 software (2011). Determination of risk factors associated with *C. burnetii* seroprevalence was realized in two stages. A univariate analysis (using *chi-square test*) was performed at first to check

for significant associations between tested variables and the seroprevalence of Q fever coded as 0 (negative) or 1 (positive). In a second step, factors that show moderate statistical significance ($p \leq 0.25$) with counts ≥ 5 in each cell were introduced to a multivariable logistic regression model. The variable flock was included in the model as a fixed effect variable. The logistic model was developed using the stepwise forward approach using a likelihood ratio test at each step with 0.1 as significance level for removal or entry. In the final model, any variable with a $p < 5\%$ was considered statistically significant and was retained in the model. The fit of the model was assessed using the *Hosmer and Lemeshow goodness-of-fit test* (Abu-dalbouh *et al.* 2012).

RESULTS

In the study area, the seroprevalence of Coxiellosis was 12.4% (95% CI: 8.08% – 16.72%) in individual animals, while 35.9% (95% CI: 21.20% – 52.82%) of sampled flocks had one or more positive ewes. Most infected animals and flocks were from Beni-Hamidene and El Khroub municipalities (Table 1; Figure 1).

There was no tendency of Coxiella infection with ewes' age ($X^2 = 0.31$, $p = 0.85$) since ewes at different ages had recorded approximately the same seroprevalence ($\text{ys} \leq 2$: 13.72%; $2 < \text{ys} \leq 3$: 11.21%; $3 < \text{ys} \leq 4$: 11.76%).

As shown in Table 2, 71.42% of positive ewes had aborted, mainly those aged over 2 years. Abortion at first gestation was exclusive to seropositive females aged of ≤ 3 years old. Abortion at 2nd stage of gestation was more frequent in age class $2 < \text{ys} \leq 3$ and specific to ewes of $3 < \text{ys} \leq 4$ old. It is worth noting that in females with Coxiella antibodies, 21.42% had known repeated abortion. We could also find an association between history of abortion and seropositivity ($X^2 = 5.54$, $p = 0.02$).

The risk factors that were significantly associated to Coxiella seroprevalence are shown in Table 3. They are represented by origin of animals, vaccination against enterotoxaemia and pox, access to the farm by foreign visitors, farmers/shepherds' visits to other farms, disinfection frequency and pest infestation within the farm. It was not possible to verify with certainty a causal relationship between *C. burnetii* seropositivity and any other farming activities, other flocks' characteristics or therapeutic practices.

Conversely, the multivariate logistic regression model did not establish a significant association between the potential risk factors defined by univariate analysis and seropositivity to *C. burnetii*.

Table 1. Distribution of sampled ewes and flocks over the 12 municipalities of Constantine province

Municipality	Number of sampled ewes (%)		Number of sampled flocks (%)		Flock identification number (Number of positive ewes)
	Positive	Negative	Positive	Negative	
Ain Abid	1 (0.4%)	3 (1.3%)	1 (2.6%)	2 (5.1%)	33(1), 15(0), 37(0)
Ain Smara	4 (1.8%)	5 (2.2%)	1 (2.6%)	0 (0%)	13(4)
Beni-Hamidane	8 (3.5%)	25 (11.0%)	4 (10.3%)	2 (5.1%)	1(1), 2(4), 3(1), 26(2), 4(0), 5(0)
Constantine	0 (0%)	8 (3.5%)	0 (0%)	2 (5.1%)	12(0), 48(0)
Didouche Mourad	0 (0%)	4 (1.7%)	0 (0%)	2 (5.1%)	22(0), 24(0)
El Khroub	9 (4%)	37 (16.4%)	4 (10.3%)	5 (12.9%)	45(3), 46(2), 47(3), 54(1), 31(0), 38(0), 44(0), 52(0), 53(0)
Hamma Bouziane	0 (0%)	6 (2.7%)	0 (0%)	2 (5.1%)	11(0), 14(0)
Ibn Badis	0 (0%)	6 (2.7%)	0 (0%)	1 (2.6%)	32(0)
Ibn Ziad	3 (1.3%)	33 (14.6%)	2 (5.1%)	2 (5.1%)	41(2), 49(1), 27(0), 40(0)
Messaoud Boudjeriou	0 (0%)	11 (4.9%)	0 (0%)	3 (7.7%)	10(0), 29(0), 30(0)
Ouled Rahmoune	2 (0.9%)	37 (16.4%)	1 (2.6%)	2 (5.1%)	42(2), 43(0), 50(0)
ZighoudYoucef	1 (0.4%)	25 (11.0%)	1 (2.6%)	2 (5.1%)	9(1), 23(0), 28(0)
Total	28 (12.4%)	198 (87.6%)	14 (35.9%)	25 (64.1%)	/

Table 2. Prevalence of seropositive ewes to *C. burnetii* according to their age and abortion characteristics

Age category (years)	Number (%) Positive ewes	Abortion history	Abortion in first pregnancy	Abortion at (Stage of gestation)		Repeated abortions	Number (%) Negative ewes
				2 nd	3 rd		
ys≤2	14 (50%)	7 (25%)	5 (17.85)	2 (7.14%)	5 (17.85)	3 (10.71%)	88 (44.44%)
2<ys≤3	12 (42.85%)	11 (39.28%)	4 (14.28)	6 (21.42%)	5 (17.85)	3 (10.71%)	95 (47.97%)
3<ys≤4	2 (7.14%)	2 (7.14%)	0 (0%)	2 (7.14%)	0 (0%)	0 (0%)	15 (7.57%)
Overall	28 (100%)	20 (71.42%)	9 (32.14%)	10 (35.71%)	10 (35.71%)	6 (21.42%)	198 (100%)

Table 3. Potential risk factors associated with *C. burnetii* seropositivity in ewes at individual level

Risk factors	χ^2	p-value χ^2	Adjusted OR (95% CI)
Origin of animals	14.29	0.001	/
Vaccination against enterotoxaemia	12.12	0.002	0.32 (0.16-0.61)
Foreigners get access to the farm	10.87	0.004	2.02 (1.01-4.01)
History of abortion	5.54	0.029	0.34 (0.15-0.79)
Shepherds visit other farms	6.31	0.021	0.34 (0.15-0.79)
Vaccination against pox	5.30	0.025	0.41 (0.18-0.92)
Disinfection frequency	7.98	0.046	/
Pest presence within the farm	9.55	0.049	/

DISCUSSION

In Algerian livestock, *C. burnetii* infection is still very poorly investigated and often goes unsuspected by veterinarians during abortion outbreaks. The current survey attempts to bring more insights on the dissemination of this disease in ewes and the associated risk factors at different municipalities of Constantine province. Thus, the seroprevalence recorded at individual level (12.4%) is approximately the same as the one reported by Khaled *et al.* (2016) (12.2%) in eight Algerian provinces (including Constantine). However, it is less than the ones described by Yahiaoui *et al.* (2013) and Rahal *et al.* (2012) in Ksar El Boukhari (Médéa province) (26.08% and 19% re-

spectively). On the other hand, the surveyed herds of our study seem to be less infected (35.9%) than the ones analyzed in those previous studies (71.4%, 80% and 60% in that order).

Compared to surrounding countries, the animal level prevalence is very close to the one (11.8%) reported by Barkallah *et al.* (2018) in sheep of central-eastern Tunisia, but less than the 15.3% observed in Morocco by Benkirane *et al.* (2015). These authors have found respectively 20.21% and 54% of their flocks to be positive. In sub-Saharan neighbouring countries, the animal seroprevalence was found to be 21.5% in Mali and 2.55% in Niger (Sidibe *et al.*, 2013; Zecchini *et al.*, 2008).

In southern European countries where climate, terrain and traditional farming of sheep resemble to those in North Africa (including Algeria), the reported animal and flock seroprevalences were respectively 8.6-11.4% and 37.5% in Portugal (Anastácio *et al.* 2013; Cruz *et al.* 2018), 11.8% and 74% in Spain (Ruiz-Fons *et al.*, 2010), 18% and 73.6% in Italy (Villari *et al.*, 2018) and 8% in ewes in Greece (Filioussis *et al.*, 2017). In view of that, the seroprevalence at individual level is approximately comparable to the one recorded in our study (except for Greece and Italy); but in contrast, at flocks' level it appears to be much higher than ours.

Disparities in Q fever seroprevalence (between regions of close proximity and between adjacent countries) have already been described in Europe (Georgiev *et al.*, 2013) and within Mali (Sidibe *et al.*, 2013) for instance, and are related to differences in studies design, sampling methods and samples' size, analysing procedures and strongly to variations in risk factors associated to this infection which are still poorly understood (Vanderburg *et al.*, 2014).

Many studies had established a causative link of Coxiellosis and the geographical location (Asadi *et al.*, 2014; Keyvani Rad *et al.*, 2014). According to Barkallah *et al.* (2018), the likelihood to have a positive animal is higher in rural than in urban areas in relation to the undeveloped livestock farming practices and deficient hygiene. This is consistent with our findings and may explain in part the disparities we have recorded between the different municipalities.

In agreement with our findings, a potential association has been observed between Coxiellosis prevalence and abortions in ovine flocks in many parts of the world (Vanderburg *et al.*, 2014; Barkallah *et al.*, 2018; Ullah *et al.*, 2019), however, the fact that some of our Coxiella seronegative ewes had aborted may be led to other potential infectious or non-infectious abortifacient causes that affect sheep in our region and had not been investigated in this study. According to Palmer *et al.* (1983), abortion caused by *C. burnetii* occurs during late pregnancy and repeated abortions in the same goat and sheep are possible, which is confirmed throughout our results. Usually, sheep under a year old are less likely to experience gestation and parturition than older ones. This is why Coxiella-associated abortions in our study were more frequent in ewes of ≥ 2 years old. In this same context, and in contrast with our records, age of animals represents a predisposing factor to this infection, since ewes of

2 to 3 years old (Kennerman *et al.*, 2010) and those of ≥ 5 years old (Mahdavi-Roshan *et al.*, 2018) were described to be more infected in relation to a cumulative contact with the bacterium from their young age (Knobel *et al.*, 2013).

Even though we couldn't establish any relation of infection to mixed bred animals (sheep with cattle and/or goats), other studies concur with the fact that in mixed flocks especially with goats, the risk of getting the infection is higher because these animals are able of aborting twice following the infection, and shedding *C. burnetii* for up to 2 gestations, while ewes abort habitually once and do not shed the organism in vaginal mucus at subsequent lambing (Hatchette *et al.*, 2003; Berri *et al.*, 2007).

In consistence with our findings, the introduction of new animals of unknown health status without quarantine would consequently facilitate the introduction and the dissemination of *C. burnetii*, especially in the case of shedding females (Porten *et al.*, 2006). Ovine flocks are known to be most deeply infected than other livestock, and discard the bacterium in feces, vaginal mucus, and milk, with ewes able to eliminate *C. burnetii* for up to 2 months (Rodolakis *et al.*, 2007). The excretion of the bacterium reaches its maximum during birth or abortion (Roest *et al.*, 2012), thus birth and abortion products, mainly placentas have a very high bacterial load.

Many studies as in ours' have shown that farm managing practices (Pests, foreign visitors, hygiene and disinfection) can influence the seroprevalence of on farm Coxiellosis.

Cantas *et al.* (2011) had identified poor hygiene as one of the most important on farm risk factors associated with *C. burnetii* abortions. It is well known that *C. burnetii* (Small Cell Variants which are highly infectious) are extremely stable under adverse environmental conditions and can remain infectious for many months (Scott and Williams, 1990). As spore stage, they can survive on wool of sheep at ambient temperature for 7-10 months and large quantities of *C. burnetii* can persist in soil one year after an outbreak (Kersh *et al.*, 2013). Thus, visiting other farms by the shepherds or free access to the farm for foreign visitors (as found in our survey) may represent a potential risk factor for the introduction and the dissemination of the bacterium, especially from foot traffic (Kersh *et al.*, 2013). Cardinale *et al.* (2014), suggest that farm personnel and visitors often act as mechanical carriers.

ers/transmitters of the pathogen from infected flocks to uninfected ones. This is why the access of visitors to the farm as well the farmers/shepherds to other farms during parturition period must be avoided.

Pests presence on farm interfere positively with the dissemination of the disease on farms, since the potential role of these animals (rodents, birds, ticks) had been described as a risk factor of Coxiellosis occurrence (Gardon *et al.*, 2001; Angelakis and Raoult, 2010).

The link we have recorded between Coxiellosis prevalence and vaccinations against pox and enterotoxaemia in sheep could be explained by the lack of preventive measures during vaccination campaigns. In fact, veterinarians may participate to the dissemination of the bacterium from farm to farm, flock to flock and animal to animal via their contaminated equipment, clothes and mainly boots. Another possible route of transmission may be represented by sharing previously used and contaminated needles (Scott *et al.*, 2011) between animals during vaccination.

Many other risk factors (such as sheep breed, season, parity, ticks, raising system, flock size...) are potentially associated with seropositivity, but they were not significant in our study.

Finally, it is important to mention that some animals may remain seropositive for several years following an acute infection, while; some others may excrete the bacteria before the appearance of antibodies (Berri *et al.*, 2000). At the time of abortion, small ruminants that abort are frequently seropositive, although antibodies' titers can decrease over time (Berri *et al.*, 2001). Thus, the serological testing is of a

subtle interpretation in the case of the Q fever, and the ELISA test should be coupled with a method of direct detection of the bacterium using molecular tools (PCR) which are more sensitive (Mori *et al.*, 2013).

CONCLUSION

In conclusion, the present study reveals that *Coxiella* infection is more frequent than previously considered. Many factors (mostly related to biosecurity, hygiene and disinfection) play an important role in the occurrence and dissemination of this infection among ovine flocks of our region, which prove that preventive veterinary measures are a key point in the control of Q fever. It appears also that sheep may be potential reservoirs of *C. burnetii* for other animals and humans infection. The dissemination risk of this bacterium is amplified through animals' movements. Sheep can move from the high plateaus to the Northern provinces and sometimes till the seaside provinces. In addition to that, there is an increased animal-human contact in animal operation sectors, in pastures and watering points, in live animal markets, but also through the food chain.

Nevertheless, there still many knowledge deficiencies in determining the true incidence of this economically heavy disease which motivates the need for future studies (using more accurate analyses and including large samples of several animal species from more provinces) to understand its epidemiology among the national livestock and the broader community especially in persons with special risk factors (contact with animals).

CONFLICT OF INTEREST STATEMENT

The authors declare no conflict of interest.

REFERENCES

- Abu-dalbouh MA, Ababneh MM, Giadinis ND, Lafi SQ (2012) Ovine and caprine toxoplasmosis (*Toxoplasma gondii*) in aborted animals in Jordanian goat and sheep flocks. *Trop Anim Health Prod* 44: 49-54.
- Agag S, Kaidi R, Khelef D (2016) Seroprevalence of Q fever in cows in Bejaia area (Algeria). *Rev Elev Med Vet Pay Trop* 69: 155-159.
- Anastácio S, Tavares N, Carolino N, Sidi-Boumedine K (2013) Serological evidence of exposure to *Coxiella burnetii* in sheep and goats in central Portugal. *Vet Microbiol* 167: 500-505.
- Angelakis E, Raoult D (2010) Q fever. *Vet Microbiol* 140: 297-309.
- Asadi J, Khalili M, Kafi M, Ansari-Lari M, Hosseini SM (2014) Risk factors of Q fever in sheep and goat flocks with history of abortion. *Comparat Clin Pathol* 23: 625-630.
- Barkallah M, Gharbi Y, Hmani M, Mallek Z, Gautier M, Gdoura R, Fendri I (2018) Serological and molecular evidence of Coxiellosis and risk factors in sheep flocks in central-eastern Tunisia. *Comp Immunol Microb* 57: 15-21.
- Benaissa MH, Ansel S, Mohamed-Cherif A, Benfodil K, Khelef D, Youngs CR, Kaidi R, Ait-Oudhia K (2017). Seroprevalence and risk factors for *Coxiella burnetii*, the causative agent of Q fever in the dromedary camel (*Camelus dromedarius*) population in Algeria. *Onderstepoort J Vet* 84: e1-e7.
- Benkirane A, Essamkaoui S, El Idrissi A, Lucchese L, Natale A (2015) A sero-survey of major infectious causes of abortion in small ruminants in Morocco. *Vet Ital* 51: 25-30.
- Berri M, Laroucau K, Rodolakis A (2000) The detection of *Coxiella burnetii* from ovine genital swabs, milk and fecal samples by the use of a single touchdown polymerase chain reaction. *Vet Microbiol* 72: 285-293.
- Berri M, Rousset E, Champion JL, Russo P, Rodolakis A (2007) Goats may experience reproductive failures and shed *Coxiella burnetii* at two successive parturitions after a Q fever infection. *Res Vet Sci* 83: 47-52.
- Berri M, Souriau A, Crosby M, Crochet D, Lechopier P, Rodolakis A (2001) Relationships between the shedding of *Coxiella burnetii*, clinical signs

- and serological responses of 34 sheep. *Vet Rec* 148: 502-505.
- Cantas H, Muwonge A, Sareyyupoglu B, Yardimci H, kjerve E (2011) Q fever abortions in ruminants and associated on-farm risk factors in northern Cyprus. *BMC Vet Res* 7: 13.
- Cardinale E, Esnault O, Beral M, Naze F, Michault A (2014) Emergence of *Coxiella burnetii* in ruminants on Reunion Island? Prevalence and risk factors. *PLoS Negl Trop Dis* 8: e3055.
- Cruz R, Esteves F, Vasconcelos-Nóbrega C, Santos C, Ferreira AS, Mega C, Coelho AC, Vala H, Mesquita JR (2018) A nationwide seroepidemiologic study on Q fever antibodies in sheep of Portugal. *Vector-Borne Zoonot* 18: 601-604.
- Cutler SJ, Bouzid M, Cutler RR (2007) Q fever. *J Infect* 54: 313-318.
- de Lange MM, Schimmer B, Vellema P, Hautvast JL, Schneeberger PM, van Duinhoven YT (2014) *Coxiella burnetii* seroprevalence and risk factors in sheep farmers and farm residents in The Netherlands. *Epidemiol Infect* 142:1231-1244.
- deValk H (2012) Q fever: new insights, still many queries. *Eurosurveillance* 17: 20062.
- Filioussis G, Theodoridis A, Papadopoulos D, Gelasakis AI, Vouraki S, Bramis G, Arsenos G (2017) Serological prevalence of *Coxiella burnetii* in dairy goats and ewes diagnosed with adverse pregnancy outcomes in Greece. *Ann Agric Environ Med* 24: 702-705.
- Gardon J, Heraud JM, Laventure S, Ladam A, Capot P, Fouquet E, Favre J, Weber S, Hommel D, Hulin A, Couratte Y, Talarmin A (2001) Suburban transmission of Q fever in French Guiana: evidence of a wild reservoir. *J Infect Dis* 184: 278-284.
- Georgiev M, Afonso A, Neubauer H, Needham H, Thiery R, Rodolakis A, Roest H, Stark K, Stegeman J, Vellema P, van der Hoek W, More S (2013) Q fever in humans and farm animals in four European countries, 1982 to 2010. *Eurosurveillance* 18: 20407.
- Hatchette T, Campbell N, Hudson R, Raoult D, Marrie TJ (2003) Natural history of Q fever in goats. *Vector-Borne Zoonotic Dis* 3: 11-15.
- Horigan MW, Bell MM, Pollard TR, Sayers AR, Pritchard GC (2011) Q fever diagnosis in domestic ruminants: comparison between complement fixation and commercial enzyme-linked immunosorbent assays. *J Vet Diagn Invest* 23: 924-931.
- Kennerman E, Rousset E, Golcu E, Dufour P (2010) Seroprevalence of Q fever (Coxiellosis) in sheep from the Southern Marmara Region, Turkey. *Comp Immunol Microbiol* 33: 37-45.
- Kersh GJ, Fitzpatrick KA, Self JS, Priestley RA, Kelly AJ, Lash RR, Marsden-Haug N, Nett RJ, Bjork A, Massung RF, Anderson AD (2013) Presence and persistence of *Coxiella burnetii* in the environments of goat farms associated with a Q fever outbreak. *Appl Environ Microb* 79: 1697-1703.
- Keyvani Rad N, Azizzadeh M, Taghavi Razavizadeh AR, Mehrzad J, Rashitabaf M (2014) Seroepidemiology of coxiellosis (Q fever) in sheep and goat populations in the northeast of Iran. *Iran J Vet Res* 15 (1): 1-6.
- Khaled H, Sidi-Boumedine K, Merdja S, Dufour P, Dahmani A, Thiery R, Rousset E, Bouyoucef A, (2016) Serological and molecular evidence of Q fever among small ruminant flocks in Algeria. *Comp Immunol Microbiol* 47: 19-25.
- Knobel DL, Maina AN, Cutler SJ, Ogola E, Feikin DR, Jungthae M, Halliday JE, Richards AL, Breiman RF, Cleaveland S (2013) *Coxiella burnetii* in humans, domestic ruminants, and ticks in rural western Kenya. *Am J Trop Med Hyg* 88: 513-518.
- MADR: Ministry of Agriculture and Rural Development (2014) Agricultural statistics (Areas and productions. Series B). Algiers.
- Mahdavi-Roshan H, Saadati D, Najimi M (2018) Molecular detection of *Brucella melitensis*, *Coxiella burnetii* and *Salmonella abortusovis* in aborted fetuses of Baluchi sheep in Sistan region, south-eastern Iran. *Iran J Vet Res* 19: 128-132.
- Mancini F, Di Luca M, Toma L, Vescio F, Bianchi R, Khoury C, Marini L, Rezza G, Ciervo A (2014) Prevalence of tick-borne pathogens in an urban park in Rome, Italy. *Ann Agr Env Med* 21: 723-727.
- Menadi SE, Mura A, Santucci C, Ghalimi F, Hafsi F, Masala G (2010) Seroprevalence and risk factors of *Coxiella burnetii* infection in cattle in northeast Algeria. *Trop Anim Health Prod* 2019: 1-8.
- McQuiston JH, Childs JE (2002) Q fever in humans and animals in the United States. *Vector-Borne Zoonot* 2: 179-191.
- Mori M, Boarbi S, Michel P, Bakinahe R, Rits K, Wattiau P, Fretin D (2013) In vitro and in vivo infectious potential of *Coxiella burnetii*: a study on Belgian livestock isolates. *PLoS One* 8: e67622.
- Palmer NC, Kierstead M, Key DW, Williams JC, Peacock MG, Vellend H (1983) Placentitis and abortion in goats and sheep in Ontario caused by *Coxiella burnetii*. *Canadian Vet J* 24: 60-61.
- Porten K, Rissland J, Tigges A, Broll S, Hopp W, Lunemann M, van Treeck U, Kimmig P, Brockmann SO, Wagner-Wiening C, Hellenbrand W, Buchholz U (2006) A super-spreading ewe infects hundreds with Q fever at a farmers' market in Germany. *BMC Infect Dis* 6: 147.
- Rahal K, Khaled H, Dahmani A, Bouyoucef A (2012) True prevalence of *Coxiella burnetii* in sheep at Ksar Boukhari region (Algeria). In: Proceedings of the 13th International Symposium on Veterinary Epidemiology and Economics, Belgium-Netherlands: p 425.
- Rodolakis A (2009) Q fever in dairy animals. *Ann NY Acad Sci* 1166: 90-93.
- Rodolakis A, Berri M, Hechard C, Caudron C, Souriau A, Bodier CC, Blanchard B, Camuset P, Devillechaise P, Natorp JC, Vadet JP, Arricau-Bouvery N (2007) Comparison of *Coxiella burnetii* shedding in milk of dairy bovine, caprine and ovine herds. *J Dairy Sci* 90: 5352-5360.
- Roest HJ, van Gelderen B, Dinkla A, Frangoulidis D, van Zijderveld F, Rebel J, van Keulen L (2012) Q fever in pregnant goats: pathogenesis and excretion of *Coxiella burnetii*. *PLoS One* 7(11): e48949.
- Ruiz-Fons F, Astobiza I, Barandika JF, Hurtado A, Atxaerandio R, Juste RA, García-Pérez AL (2010) Seroepidemiological study of Q fever in domestic ruminants in semi-extensive grazing systems. *BMC Vet Res* 6: 3.
- Schimmer B, Ter Schegget R, Wegdam M, Zuchner L, de Bruin A, Schneeberger PM, Veenstra T, Vellema P, van der Hoek W (2010) The use of a geographic information system to identify a dairy goat farm as the most likely source of an urban Q-fever outbreak. *BMC Infect Dis* 10: 69.
- Scott GH, Williams JC (1990) Susceptibility of *Coxiella burnetii* to chemical disinfectants. *Ann NY Acad Sci* 590: 291-296.
- Scott PR, Penny CD, Macrae AI (2011) Q fever. In: *Cattle Medicine*. Manson Publishing, London: p 38.
- Sidibe SS, Coulibaly KW, Dakouo M, Tarnagda Z, Sery A, Niang M, Traore K, Nantoume H, Diarra S, Seyni H (2013) Fièvre Q chez les petits ruminants au Mali. Résultats d'une enquête sérologique. *Rev Elev Med Vet Pay Trop* 66: 11-18.
- Sprong H, Tijssen-Klasen E, Langelaar M, De Bruin A, Fonville M, Gassner F, Takken W, Van Wieren S, Nijhof A, Jongejan F, Maassen CB, Scholte EJ, Hovius JW, Emil-Hovius K, Spitaliska E, Van Duynhoven YT (2012) Prevalence of *Coxiella burnetii* in ticks after a large outbreak of Q fever. *Zoonoses Public Hlth* 59: 69-75.
- Stephen S, Ambroise S, Pradeep J, Gunasekaran D, Sangeetha B, Saranganpani K (2017) Unreliability of three commercial *Coxiella burnetii* Phase II IgM ELISA kits for the diagnosis of acute Q fever in human cases in Puducherry, India. *Indian J Med Res* 146: 386-391.
- Thrusfield M (2007) Simple random sampling. In: *Veterinary epidemiology*. 3rd ed. Blackwell Science, Oxford: pp 231-245.
- Tissot-Dupont H, Raoult D (2008) Q fever. *Infect Dis Clin N Am* 22: 505-514.
- Ullah Q, El-Adawy H, Jamil T, Jamil H, Qureshi ZI, Saqib M, Ullah S, Shah MK, Khan AZ, Zubair M, Khan I, Mertens-Scholz K, Henning K, Neubauer H (2019) Serological and molecular investigation of *Coxiella burnetii* in small ruminants and ticks in Punjab, Pakistan. *Int J Environ Res Public Health* 16: 4271.
- Vanderburg S, Rubach MP, Halliday JE, Cleaveland S, Reddy EA, Crump JA (2014) Epidemiology of *Coxiella burnetii* infection in Africa: a One health systematic review. *PLoS Negl Trop Dis* 8: e2787.
- Villari S, Galluzzo P, Amone M, Alfano M, Geraci F, Chiarenza G (2018) Seroprevalence of *Coxiella burnetii* infection (Q fever) in sheep farms located in Sicily (Southern Italy) and related risk factors. *Small Ruminant Res* 164: 82-86.
- Yahiaoui WI, Afri-Bouzebdia F, Bouzebdia Z, Dahmani A (2013) Sondage sérologique de la fièvre Q chez les ovins par la méthode ELISA et prévalence des avortements dans la région de Ksar El Boukhari (Algérie). *Tropicicultura* 32: 22-27.
- Zecchini M, Harouna A, Cattaneo C, Belli P, Pecile A, Moroni P, Alborali L, Idi-Adamou G, Crimella C (2008) Seroprevalence of brucellosis, chlamydiosis, Q fever and mastitis in small ruminants in the urban and periurban area of Niamey (Niger). *Large Anim Rev* 14: 234.

Effect of glauconite, sepiolite and oil supplementation on pellet quality parameters in poultry compound feed

G. Yıldız^a, Ö. Durna Aydın^{b*}

^aAnkara University, Faculty of Veterinary Medicine, Department of Animal Nutrition, and Nutritional Diseases, Ankara, Turkey

^bKafkas University, Faculty of Veterinary Medicine, Department of Animal Nutrition, and Nutritional Diseases, Kars, Turkey

ABSTRACT: The aim of this study was conducted to determine the effect of glauconite, sepiolite and oil on pellet quality parameters in poultry compound feed. There are limited studies with supplementation of different levels of sepiolite and glauconite clay minerals in diets about pellet quality during the pelleting processes. Thus, the effect of sepiolite and glauconite on pellet quality parameters was investigated in our study. The study was carried out in two different. Firstly, 1% and 2% levels sepiolite and glauconite were added to each concentrate in pellet production without adding oil. Secondly, 1% and 2% levels of sepiolite, glauconite and 1% oil were added to the concentrates during pelleting. In both experiments, the trial consisted of 1 control and 4 trial groups. Pellet concentrate feeds were produced with 7 batches (each batch was 100 kg). The disc that has hole diameter 3.5 mm and wall thickness of 70 mm was used in production. At the end of the study, dry matter level of the pellets was statistically influenced by the addition of sepiolite, glauconite and oil in poultry compound pellet feed. The lowest pellet dry matter value belongs to C and CO groups ($p < 0.05$). Pellet durability index of poultry compound pellet feed were not statistically affected by the addition of sepiolite, glauconite and oil. Pellet water activity of poultry compound pellet feed were not statistically affected by the addition of sepiolite, glauconite and oil. However, the pellet water activity of laying hens pellet concentrates (without oil addition) were statistically affected by the addition of sepiolite and glauconite ($p < 0.05$). Pellet water activity has the lowest value especially in the groups in which glauconite is added. In conclusion, these findings showed that glauconite, sepiolite and oil can be used for pellet quality in poultry compound feed (especially laying hen feed) and improve pellet storage conditions and due to the positive effect of glauconite and sepiolite on pellet water activity.

Keywords: pellet durability index, pellet water activity, sepiolite, glauconite, poultry compound feed

Corresponding Author:

Özlem Durna Aydın, Kafkas University Veterinary Faculty
Animal Nutrition and Nutritional Diseases Department TR-36100, Kars/Turkey
E-mail address: odurna36@gmail.com

Date of initial submission: 27-01-2020
Date of revised submission: 30-05-2020
Date of acceptance: 26-06-2020

INTRODUCTION

Pelleting is an important method in feed technology. Pellet is defined as combining the feeds used in animal feed and preparing a mixture representing whole feed in a pellet grain. In other words, it is defined as the animal's consumption of this particle, which represents all the food with each pellet (Ergun et al., 2019). In pellet quality (palatability, keeping together), there are features such as not being easily dispersed, not being chewed too hard, and not being burned excessively.

The materials to be pelleted are forcibly pushed through the perforated channel (which determines the diameter) and in the meantime, they are cut at a certain time interval (which determines the length). This is the application of heat rise and pressure and eliminates some antinutritional factors. In this way, the settling of some microorganisms is reduced, external moisture intake decreases, digestibility may increase (gelatinization) (Ergun et al., 2019). Pellet feed has a significant role in spreading the use of better yield from animals consuming this feed with its physical positive effects (Dozier, 2001). High-quality pellet feeds are important for broiler feeds in terms of feed selection and waste prevention (Durna et al., 2016).

Clay minerals can be used as adsorbents in feeds. Clay minerals are mainly hydrated aluminum silicate (brucite), kaolinite, hallopyrite, montmorillonite, illite, chlorite, attapulgite (sepiolite), bentonite, zeolite, and hydratesodium calcium aluminosilicate (HSKAS). It is stated that these aluminosilicates have pellet binding properties in compound feeds, prevent or delay the formation of molds and fungi in feeds with their water adsorbing capacity, reduce the toxic effect of heavy metals, bind to mycotoxins in the digestive tract and prevent their toxicological and pathological effects (Ramos, 1997). Clays supplemented to the ratio can bind, immobilize toxic substances in the gastrointestinal tract of animals and reduce their toxicity (Subramaniam and Kim, 2015). Clays are inherently non toxic to the environment (Zhou et al., 2004).

Sepiolite is a hydrated magnesium silicate clay. Sepiolite can be used as a binder and anti-caking feed additive (E-562) in all animal feeds (Angulo et al. 1995; EFSA, 2013; Wolter et al., 1990). The most important properties of sepiolite are its large specific area, high absorption capacity, low cation exchange capacity and rheological properties. The addition of sepiolite to concentrated feeds increases pellet strength and hardness and increases the physi-

cal strength of compound feed and reduces dust loss (Burçak and Yalçın, 2016). Since sepiolite binds the other ingredients in the feed, it forms pellets with high durability and hardness (EFSA, 2013). Use of 1% sepiolite in broiler diets increase body weight gain and reduce serum cholesterol and triglyceride levels (Eser et al., 2012). In addition, 1% sepiolite supplement in layer diets reduced egg yolk cholesterol and improved egg shell quality (Yalçın et al., 2016).

Glaucanite is the natural mineral with the chemical formula $(K, H_{20}) (Fe^{3+}, Al, Fe^{2+}, Mg)_2 [Si_3AlO_{10}] (OH)_2 \times nH_2O$ and it is a three-layer silicate mineral (Venig et al., 2014). Glaucanite is slightly acidic and capable of absorbing moisture 10 times more than ordinary sand. It consists of marine potash, silica, iron, magnesium, and lime, plus up to 30 other trace minerals. (İbrahim et al., 2019). Glaucanite is one of the clay minerals. Glaucanite can absorb various substances on the surface. Also, it can intercalate many inorganic and organic ions, replacing K^+ , Ca^{2+} , etc in interlayers sites (ion-exchange capacity) (Avisar et al., 2009; Wang et al., 2010). Glaucanite mineral is known to be used as dermatological and gastrointestinal agents (Venig et al., 2017). In the literature search, no studies on the use of glaucanite in poultry feeding have been found. However, the non-toxic and historically therapeutic use of the glaucanite clay mineral suggested that it could be used as a feed additive in poultry. Only in the one study, the addition of 1% and 2% doses glaucanite in broiler rations did not affect the performance parameters, biomechanical properties of bones and histomorphology of the ileum (Durna Aydın et al., 2020).

Based on this information, there are limited studies with supplementation of different levels of sepiolite and other clay minerals in diets about pellet quality during the pelleting processes. However, no study was found to investigate the effect of glaucanite mineral on pellet quality parameters in poultry compound feed in the literature study. Therefore, the purpose of this study was to the effect of glaucanite, sepiolite and oil on pellet quality parameters in poultry compound feed.

MATERIALS AND METHODS

Concentrated feeds were made by the rations research team, whose raw materials were taken from a commercial feed factory (Özhen Feed Inc., Ankara, Turkey) in this experiment. The ration of broiler and laying hens feeds in the study was prepared accord-

ing to NRC (1994). Pellet feeds are prepared in two ways with or without oil addition after then sepiolite and glauconite additions. Firstly, 1% and 2% levels of sepiolite and glauconite were added to each concentrate in pellet production without oil addition. Groups, respectively control (C), 1% sepiolite (S1), 2% sepiolite (S2), glauconite 1% (G1) and 2% glauconite (G2). Secondly, 1% and 2% levels sepiolite, glauconite and 1% level vegetable oil were added to the concentrates during pelleting. Groups respectively control (CO), sepiolite 1% + vegetable oil (SO1), sepiolite 2% + vegetable oil (SO2), glauconit 1% + vegetable oil (GO1) and glauconite 2% + vegetable oil (GO2). In both experiments, the trial consisted of 1 control and 4 trial groups. While oil addition was done by a spraying method, sepiolite and glauconite additions were added to the mixer (top-dressed). Glauconite was obtained from the Saratov University of Russia. Sepiolite was supplied from Tolsa SA (Madrid, Spain). The oil used in the study is vegetable oil.

Pellet concentrate feeds were performed in the pellet making machine of Ankara University Veterinary Faculty Farm. Pellet concentrate feeds were produced with 7 batches (each batch was 100 kg). The disc that has a hole diameter 3.5 mm and a wall thickness of 70 mm was used in production. Pellet machine has

a capacity of 100 kg / h. No water was used in pellet production processes. Production conditions for poultry compound pellet feed are shown in Table 3. After poultry compound feeds were pelleted, seven sample feeds were taken from each group from the mixer. All nutrient (dry matter, crude protein, crude fiber, ether extract, ash, and starch analysis) analyses of the collected pellet feed samples, which taken from the mixer, were performed according to AOAC (2000). The metabolizable energy level was calculated according to the formula proposed by Carpenter and Clegg (1956). Pellet durability index (PDI) was measured with a Pfast Equipment using the sieve having the hole diameter of 3 mm (Baser and Yalcin, 2017). Water activity values of feeds were measured by using water activity equipment (LabSwift-aw, Novasina, Switzerland). Quadruplicate measurements were done with each sample.

The one-way analysis of variance (ANOVA) method was used for the statistical calculations of the groups and a suitable post hoc test (Duncan's test) was used for determining the importance of the differences between the groups. The statistical analysis was done with the SPSS software package (IBM Inc, Chicago, USA, 2011).

Table 3. Production conditions for poultry compound pellet feed

Parameters	C	S1	S2	G1	G2
Production, kg	700	700	700	700	700
Mixer capacity, kg/h	100	100	100	100	100
Water added in mixer	No	No	No	No	No
Oil added in mixer	No	No	No	No	No
Sepiolite added in mixer	No	1%	2%	No	No
Glauconite added in mixer	No	No	No	1%	2%
Disc hole diameter, mm	3,5	3,5	3,5	3,5	3,5
Disc hole length, mm	70	70	70	70	70
Parameters	CO	SO1	SO2	GO1	GO2
Production, kg	700	700	700	700	700
Mixer capacity, kg/h	100	100	100	100	100
Water added in mixer	No	No	No	No	No
Oil added in mixer	1%	1%	2%	1%	2%
Sepiolite added in mixer	No	1%	2%	No	No
Glauconite added in mixer	No	No	No	1%	2%
Disc hole diameter, mm	3,5	3,5	3,5	3,5	3,5
Disc hole length, mm	70	70	70	70	70

The first trial (without vegetable oil); groups; control (C, basal ration), 1% sepiolite (S1), 2% sepiolite (S2), glauconite 1% (G1) and 2% glauconite (G2). **The second trial (with vegetable oil addition);** groups; control (CO, basal ration with added vegetable oil), sepiolite 1% + vegetable oil (SO1), sepiolite 2% + vegetable oil (SO2), glauconit 1% + vegetable oil (GO1) and glauconite 2% + vegetable oil (GO2).

RESULTS

The ration of broiler and laying hens feeds is given in Table 1. The chemical composition of the sepiolite and glauconite mineral is given in Table 2.

The effect of glauconite, sepiolite and oil on pellet dry matter in poultry compound pellet feed is given in Table 4. At the end of the study, pellet dry matter level was statistically influenced by the addition of glauconite, sepiolite and oil in poultry compound pellet feed. The lowest pellet dry matter value belongs to C and CO groups ($p < 0.05$).

The effect of glauconite, sepiolite and oil on pellet durability index in poultry compound pellet feed is given in Table 5. The end of the study, pellet dura-

bility index of in poultry compound pellet feed were not statistically affected by the addition of glauconite, sepiolite and oil ($p > 0.05$).

The effect of glauconite, sepiolite and oil usage on pellet water activity is in poultry compound pellet feed given in Table 6. The end of the study, pellet water activity of broiler and laying hens pellet concentrates (with oil addition) were not statistically affected by the addition of sepiolite and glauconite ($p > 0.05$). However, the pellet water activity of laying hens pellet feed (without oil addition) were statistically positively affected by the addition of sepiolite and glauconite. Pellet water activity has the lowest value especially in the groups in which glauconite is added ($p < 0.05$).

Table 1. The composition of the rations used in the study (%)

Ingredient	Broiler*	Laying hen**
Corn	50.05	50
DDGS	5	5
Wheat	9.7	11.4
Razmol	5	5
Soybean meal, 48%	22.8	13.6
Sunflower meal, 35%	-	5
MCP	0.54	0.26
Marble powder	1.88	9.2
Salt	0.25	0.24
DL-methionine	0.03	0.05
Vegetable oil	4.5	-
Vitamin premix	0.10	0.10
Mineral premix	0.10	0.10
Phytase	0.05	0.05
Total	100.00	100.00
Analysis Values of Pellet Feeds		
ME, kcal/kg	3108	2650
Crude protein, %	19	16
Crude ash, %	5.54	12.2
Crude fat, %	7.2	2.71
Crude fiber, %	3.13	3.86
Starch, %	41	41.2
Ca %	1.00	3.82
Total P %	0.64	0.57

*Provided per kilogram of complete diet: vitamin A, 12,000 IU; vitamin D3, 2,500 IU; vitamin E, 40 IU; vitamin K3, 5 mg; thiamin, 2.5 mg; riboflavin, 6 mg; pyridoxine, 5 mg; pantothenic acid, 15 mg; niacin, 25 mg; folic acid, 1 mg; biotin, 50 µg; vitamin B12, 20 µg. Cu, 5 mg; I, 1 mg; Co, 200 µg; Se, 150 µg; Fe, 60 mg; Zn, 60 mg; Mn, 80 mg. Folic Acid 1.000 mg/kg, Biotin 50 mg/kg, Copper 5.000 IU/kg, Iodine 1.000 IU/kg, Cobalt 200 mg/kg, Selenium 150 mg/kg, Iron 60.000 mg/kg, Zinc 60.000 mg/kg, Mangan 80.000 mg/kg.

**Composition (per 2.5 kg): 3.6 g retinol, 0.12 g cholecalciferol, 30 g DL-α tocopherol acetate, 2.5 g menadione, 2.5 g thiamin, 6 g riboflavin, 4 g pyridoxol, 20 mg cobalamin, 25 g niacin, 8 g calcium-D-panthotenate, 1 g folic acid, 50 g ascorbic acid, 50 mg Dbiotin, 150 g choline chloride, 1.5 g canthaxanthin, 0.5 g apo carotenoid acid ester, 80 g Mn, 60 g Zn, 60 g Fe, 5 g Cu, 1 g I, 0.5 g Co, 0.15 g Se.

Table 2. The chemical composition of glauconite and sepiolite used in this study (%).

Sepiolite		Glauconite	
Moisture	8.23	Moisture	10.30
SiO ₂	41.8	SiO ₂	61.82
Al ₂ O ₃	1.10	Al ₂ O ₃	21.08
MgO	21.22	Fe ₂ O ₃	3.25
CaO	13.50	CaO	2.44
Fe ₂ O ₃	0.50	MgO	2.67
Na ₂ O	0.30	CaO+ MgO	5.11
K ₂ O	0.34	K ₂ O	0.95
Mn ₂ O ₃	0.1	Na ₂ O	2.44

Table 4. The effect of glauconite, sepiolite and oil on pellet dry matter in poultry compound pellet feed

Groups	C	S1	S2	G1	G2	P
Without vegetable oil	$\bar{x} \pm S \bar{x}$	$\bar{x} \pm S \bar{x}$	$\bar{x} \pm S \bar{x}$	$\bar{x} \pm S \bar{x}$	$\bar{x} \pm S \bar{x}$	
Broiler	90.00±0.01 ^a	90.83±0.01 ^b	90.97±0.02 ^c	90.95±0.02 ^c	91.45±0.03 ^d	0.000*
Laying hen	91.80±0.02 ^a	91.68±0.03 ^a	92.55±0.04 ^d	92.04±0.06 ^b	92.18±0.03 ^c	0.000*

Groups	CO	SO1	SO2	GO1	GO2	P
With vegetable oil addition	$\bar{x} \pm S \bar{x}$	$\bar{x} \pm S \bar{x}$	$\bar{x} \pm S \bar{x}$	$\bar{x} \pm S \bar{x}$	$\bar{x} \pm S \bar{x}$	
Broiler	91.07±0.02 ^b	90.69±0.01 ^a	91.30±0.02 ^c	91.05±0.05 ^b	91.14±0.02 ^b	0.000*
Laying hen	91.96±0.03 ^a	92.18±0.02 ^b	92.47±0.00 ^d	92.12±0.02 ^b	92.38±0.02 ^c	0.000*

The first trial (without vegetable oil); groups; control (C, basal ration), 1% sepiolite (S1), 2% sepiolite (S2), glauconite 1% (G1) and 2% glauconite (G2). **The second trial (with vegetable oil addition);** groups; control (CO, basal ration with added vegetable oil), sepiolite 1% + vegetable oil (SO1), sepiolite 2% + vegetable oil (SO2), glauconite 1% + vegetable oil (GO1) and glauconite 2% + vegetable oil (GO2). Statistically not significant ($p > 0.05$). All values are given as mean \pm standard error of mean (SEM), ($n=7$). a,b,c,d; The differences between the mean values with a different letter in the same row were statistically significant ($p < 0.05$)* ($P < 0.001$)*

Table 5. The effect of glauconite, sepiolite and oil on pellet durability index in poultry compound pellet feed

Groups	C	S1	S2	G1	G2	P
Without vegetable oil	$\bar{x} \pm S \bar{x}$	$\bar{x} \pm S \bar{x}$	$\bar{x} \pm S \bar{x}$	$\bar{x} \pm S \bar{x}$	$\bar{x} \pm S \bar{x}$	
Broiler	99.88±0.00	99.17±0.30	99.67±0.05	99.78±0.02	99.78±0.10	0.176
Laying hen	99.54±0.13	99.61±0.10	99.69±0.03	99.59±0.07	99.65±0.03	0.766

Groups	CO	SO1	SO2	GO1	GO2	P
With vegetable oil addition	$\bar{x} \pm S \bar{x}$	$\bar{x} \pm S \bar{x}$	$\bar{x} \pm S \bar{x}$	$\bar{x} \pm S \bar{x}$	$\bar{x} \pm S \bar{x}$	
Broiler	99.83±0.05	99.72±0.11	99.56±0.05	99.63±0.04	99.79±0.01	0.120
Laying hen	99.70±0.04	99.63±0.00	99.66±0.04	99.53±0.15	99.67±0.00	0.530

The first trial (without vegetable oil); groups; control (C, basal ration), 1% sepiolite (S1), 2% sepiolite (S2), glauconite 1% (G1) and 2% glauconite (G2). **The second trial (with vegetable oil addition);** groups; control (CO, basal ration with added vegetable oil), sepiolite 1% + vegetable oil (SO1), sepiolite 2% + vegetable oil (SO2), glauconite 1% + vegetable oil (GO1) and glauconite 2% + vegetable oil (GO2). Statistically not significant ($p > 0.05$). All values are given as mean \pm standard error of mean (SEM), ($n=7$). a,b,c,d; The differences between the mean values with a different letter in the same row were statistically significant ($p < 0.05$)* ($P < 0.001$)*

Table 6. The effect of glauconite, sepiolite and oil on pellet water activity in poultry compound pellet feed

Groups	C	S1	S2	G1	G2	P
Without vegetable oil	$\bar{x} \pm S \bar{x}$	$\bar{x} \pm S \bar{x}$	$\bar{x} \pm S \bar{x}$	$\bar{x} \pm S \bar{x}$	$\bar{x} \pm S \bar{x}$	
Broiler	0.54±0.01	0.56±0.02	0.54±0.03	0.54±0.01	0.53±0.01	0.815
Laying hen	0.045±0.02 ^b	0.44±0.01 ^b	0.42±0.01 ^{ab}	0.40±0.00 ^a	0.40±0.01 ^a	0.047*
Groups	CO	SO1	SO2	GO1	GO2	P
With vegetable oil addition	$\bar{x} \pm S \bar{x}$	$\bar{x} \pm S \bar{x}$	$\bar{x} \pm S \bar{x}$	$\bar{x} \pm S \bar{x}$	$\bar{x} \pm S \bar{x}$	
Broiler	0.54±0.01	0.53±0.01	0.51±0.01	0.51±0.01	0.52±0.02	0.261
Laying hen	0.41±0.00	0.41±0.01	0.41±0.01	0.41±0.02	0.39±0.01	0.346

The first trial (without vegetable oil); groups; control (C, basal ration), 1% sepiolite (S1), 2% sepiolite (S2), glauconite 1% (G1) and 2% glauconite (G2). **The second trial (with vegetable oil addition);** groups; control (CO, basal ration with added vegetable oil), sepiolite 1% + vegetable oil (SO1), sepiolite 2% + vegetable oil (SO2), glauconite 1% + vegetable oil (GO1) and glauconite 2% + vegetable oil (GO2). Statistically not significant ($p > 0.05$). All values are given as mean \pm standard error of mean (SEM), ($n=7$). a,b,c,d; The differences between the mean values with a different letter in the same row were statistically significant ($p < 0.05$)*

DISCUSSION

Pelleting is the most common method used to improve the use of starch, reduce feed waste, eliminate pathogens and antinutritional factors. For this reason, the use of poultry pellet feed is positively affected by improving the feed conversion ratio of broiler performance (Abdollahi et al., 2013; Svihus 2014). The pelleting process is affected by many factors. Good pellet quality is an indication that pellets can be reached to feeders without breaking or crumbling by mechanical processes such as packaging and transportation (Yalçın et al., 2019a).

Concentrated feed, especially fat, starch, cellulose and protein level is very important in terms of pellet quality. The increased protein content of feed affects the pellet quality positively and the cellulose content adversely affects (Basmacıoğlu, 2004). The broiler feed used in our study contains 19% crude protein, 3.13% crude cellulose, and laying hens feed 16% protein, 3.86% crude cellulose. High protein and low cellulose in boiler feed had no significant effect on pellet quality. On the other hand, low protein and high cellulose in laying hen feed decreased pellet water activity and improved pellet quality. Briggs et al., (1999) in the case of increasing the protein content of poultry concentrate found that pellet quality improvement. The oil naturally contained in the raw materials had no significant effect on pressing and friction in the matrix channel in the pelleting process. In this regard, the oil added to the concentrate from the outside adversely affected the pellet quality (Richardson and Day, 1976). The fact that oil, which is the natural content of raw materials, causes a lower crumbling in the pellet feed compared to the oil added externally is explained by the fact that the intracellular fat in the feed cannot be fully revealed by grinding (Ergül, 1994). In our study,

the addition of oil increased the pellet dry matter level, did not affect the pellet durability index and the pellet water activity. Therefore, no adverse effect of oil addition on pellet quality was observed. This can be explained by the fact that the oil level used in our study is as low as 1% or the sepiolite and glauconite minerals are used as feed additives. The use of sepiolite in high-fat compound feeds allows high levels of oil to be added to the concentrate feed without disturbing the pellet quality (Burçak and Yalçın, 2016). Another a study, This study supports our findings. On the other hand, in a study where different types and levels of fat and pellet binders were added to broiler feed, pellet quality was positively affected (Hossein et al., 2019). Further studies using sepiolite and glauconite clays are needed to explain the difference among the results on the effect of nutrient contents of poultry compound feed on pellet quality.

Moisture content is an important factor of spoilage in feed and the maximum moisture level in feed raw materials should not exceed 13-14%. During cooling of the pellets, it should not absorb much moisture as it passes through the cooler and it is important to absorb the ambient moisture. It should not create an environment for the development of microorganisms in ships, containers, and trucks during the transportation of feeds. In this case, high absorption capacity of sepiolite is important for pelleting. In our study, pellet dry matter level was affected positively by addition of glauconite, sepiolite and oil. The use of sepiolite and glauconite in the production of pellets in broiler concentrate feeds increased the pellet dry matter level (EFSA, 2013). Since sepiolite use in broiler pellet feed links other feed ingredients in mixed feed, it improves pellet quality by reducing moisture content

(Burçak and Yalçın, 2016). In a different study, the addition of 1% sepiolite to the ration reduced the pellet moisture content (Yalçın et al., 2020). These studies are compatible with our study findings. On the other hand, Yalçın et al. (2019a) in their study did not affect the moisture content of sepiolite use in pellet feed production. The difference among the data obtained may be related to the dose and structure of sepiolite, and further studies need to reveal the effects of glauconite in this area.

A positive correlation between PDI and feed conversion ratio has been reported (Carre et al., 1956). High pellet strength reduces feed crumbling and reduces feed waste and prevents the selection of larger particles by poultry (Amerah et al., 2007). In this way, the performance of the animals is improved and the profits are increased in the poultry industry. In our study, PDI of poultry compound pellet feed were not statistically affected by the addition of glauconite, sepiolite and oil. Pappas et al. (2010) reported that palygorskite, a clay (Galan, 1996), did not significantly affect pellet durability index. In another study, it was reported that the addition of sepiolite to broiler starter concentrate feeds increased pellet durability index but did not affect broiler finishing concentrate feeds (Angulo et al. (1996). These studies are compatible with our study findings. On the other hand, Durna et al. (2016) reported that the use of 1% sepiolite in broiler starter concentrate feed increases the pellet durability index. Similarly, Yalçın et al. (2019a) reported that PDI value increased by adding 1.5 % sepiolite to dairy cattle concentrate feed. In a different study, it was reported that the addition of 15 mg / g sodium bentonite to the broiler feed increased the pellet durability index (Attar et al. 2019). Since there is no study on the effect of glauconite clay on pellet quality, it can not be included here. This difference between the obtained data can be explained by the difference in structure, chemical composition and dosage of sepiolite and glauconite clays.

Water activity is defined as the ratio of the vapor pressure of water in foods and feeds to the vapor pressure of pure water at the same temperature. The basic principle of various storage methods such as drying, freezing and concentrating to maintain the quality of food is to control the chemical activity of water. In other words, spoilage of feeds and foods is prevented by reducing water activities. Pathogenic effects of pathogenic microorganisms are prevented at a low water activity (Pala and Saygi, 1983).

The water activity level is an indicator of the volume of free water. The lower the free water present, the less the development of unwanted mould. A water activity level of 0.65 is often referred to as the limit for safe storage of foods, below which microbiological growth is unlikely to occur (Shi et al., 2001). Low water activity improves storage conditions by preventing the reproduction of pathogenic microorganisms and the presence of toxins caused by fungi. However, when sepiolite and glauconite were added to the laying hen feed (without the addition of fat), the addition of glauconite and sepiolite at 1% and 2% levels decreased the pellet water activity. The use of glauconitic pellets has improved the usage time and storage conditions. In our study, when sepiolite and glauconite were added to the laying hen feed (without adding oil), pellet water activity was reduced. Especially the use of glauconite provided lower water activity. Therefore, sepiolite and especially glauconite have improved the usage time and storage conditions of the poultry compound pellet feed. Aluminosilicates (such as sepiolite, bentonite, zeolite) can bind pellets in concentrate feeds, water adsorption capacity prevented or delayed the formation of mold and fungus (Ramos and Hernandez, 1997). In an experiment, Yalçın et al. (2019b) reported no significant difference between the water activity values of pellet concentrates of dairy cattle from the group in which control or sepiolite was added. These studies are compatible with our study findings. However, to support our study, the effect of glauconite on pellet water activity could not be discussed due to the lack of a study. Therefore, more studies are needed in this area to understand the effects of using glauconite and sepiolite alone or in combination on pellet water activity in poultry compound feed.

CONCLUSION

The addition of glauconite, sepiolite and oil addition of in poultry compound pellet feed affected pellet dry matter and pellet water activity, but did not affect pellet durability. Because of to the positive effects of glauconite and sepiolite on pellet dry matter and pellet water activity, poultry compound feed (especially laying hen feed) can be used as feed additives in pelleting. In addition, glauconite and sepiolite can improve the pellet storage conditions and usage time. This result will be very useful for feed industry. Many studies are needed to elucidate the investigated parameters related to the use of glauconite in pellet production. Our study is a good source for further studies.

ACKNOWLEDGMENTS

This study was funded by the Ankara University Coordination of Scientific Research Projects with the project number 15H0239001. We thank Saratov University (Russia) for the supply of glauconite and Tolsa SA (Madrid, Spain) for the supply of sepiolite clay.

We would like to thank Taner AYDIN for his support on grammar correction.

CONFLICT OF INTEREST

The authors declare that they have no conflict of interest.

REFERENCES

- Abdollahi MR, Ravindran V, Svihus B (2013) Pelleting of broiler diets: An overview with emphasis on pellet quality and nutritional value. *Anim. Feed Sci. Technol* 179: 1–23.
- Amerah AM, Ravindran V, Lentle RG, Thomas DG (2007) Feed particle size: Implications on the digestion and performance of poultry. *World's Poult Sci J* 63: 439–455.
- Angulo E, Brufau J, Esteve-Garcia E (1995). Effect of sepiolite on pellet durability in feeds differing in fat and fibre content. *Anim Feed Sci Tech* 53: 233–241.
- Angulo E, Brufau J, Esteve-Garcia, E (1996). Effect of a sepiolite product on pellet durability in pig diets differing particle size and in broiler starter and finisher diets. *Anim Feed Sci Tech* 63: 25–34.
- AOAC (2000). Official methods of analysis. 17th Ed. Association of Official Analytical Chemists. AOAC International. Maryland. Chapter 4. pp. 1–41.
- Attar A, Kermanshahi H, Golian A, Abbasi Pour A, Daneshmand A (2019). Conditioning time and sodium bentonite affect pellet quality, growth performance, nutrient retention and intestinal morphology of growing broiler chickens. *Br Poult Sci*. 23: 1–7.
- Avisar D, Primor O, Gozlan I, Mamane H (2009). Sorption of sulfonamides and tetracyclines to montmorillonite clay. *Water Air Soil Pollut* 209(1): 439–450.
- Basmacıoğlu H (2004). Karma Yem Üretiminde Pelet Kalitesine Etki Eden Etkenler Hayvansal Üretim 45(1): 23–30.
- Başer Ö, Yalçın, S (2017). Determination of some quality characteristics in pet foods. *Ankara Üniv Vet Fak Derg* 64: 21–24.
- Briggs JL, Maier DE, Watkins BA, Behnke KC (1999). Effects of ingredients and processing parameters on pellet quality. *Poult Sci* 78: 1464–1471.
- Burçak E, Yalçın S (2016). Sepiyolit özellikleri ve hayvan beslemede kullanılması. *Lalahan Hay Araşt Enst Derg* 56: 78–86.
- Carpenter KJ, Clegg KM (1956). The metabolizable energy of poultry feeding-stuffs in relation to their chemical composition. *J Sci Food Agric* 7: 45–51.
- Carre B, Mulley N, Gomez J, Ouryt FX, Laffitte E, Guillou D, Signoret C (2005). Soft wheat instead of hard wheat in pelleted diets results in high starch digestibility in broiler chickens. *Brit Poult Sci* 46: 66–74.
- Dozier WA (2001). Cost-effective pellet quality for meat birds. *Feed Management* 52 (2).
- Durna Aydın Ö, Yıldız G, Güntürkün OB, Bayraktaroğlu AG (2020). The use of glauconite as a feed additive in broiler nutrition and its effect on growth performance, intestinal histomorphology and biomechanical properties of bones. *Kafkas Univ Vet Fak Derg* 26 (3): 343–349.
- Durna Ö, Onbaşlar İ, Yalçın S, Escibano F (2016). Broyler yeminde sepiyolit kullanımının pelet kalitesi ve üretim parametreleri üzerine etkisi. In: 1st International Animal Nutrition Congress. September 28th – October 1st 2016. Antalya-Turkey (Poster).
- EFSA (2013). Scientific opinion on the safety and efficacy of a preparation of bentonite and sepiolite (Toxfin Dry) as feed additive for all species. *EFSA J* 11: 3179.
- Ergül M (1994). Karma yemler ve karma yem teknolojisi, Ders Kitabı, II. Baskı, E.Ü. Basımevi, Bornova-İzmir.
- Ergün A, Tuncer ŞD, Çolpan İ, Yalçın Sakine, Yıldız G, Küçükersan MK, Küçükersan S, Şehu A, Saçaklı P (2019). Yemler, Yem Hijyeni Ve Teknolojisi. 7. Baskı. Detamat Matbacılık, S 1–448. Ankara. ISBN: 975-97808-3-8.
- Eser H, Yalçın S, Yalçın S, Şehu A (2012). Effects of sepiolite usega in broiler diets on performance, carcass traits and some blood parameters. *Kafkas Univ Vet Fak Derg* 18 (2): 313–318.
- Galan E (1996). Properties and applications of palygorskite-sepiolite clays. *Clay Miner* 31: 443–454.
- Hossein M, Abadi MG, Moravej H, Shivazad M, Karimi Torshizi MA, Kim WK (2019) Effect of different types and levels of fat addition and pellet binders on physical pellet quality of broiler feeds. *Poult Sci* 98: 4745–4754.
- Ibrahim SS, El Kammar AM, Guda AM, Boulos TR, Saleh A (2019). Characterization and mineral beneficiation of Egyptian glauconite for possible industrial use. *Part Sci Technol* 37(2): 141–150..
- NRC (1994). Nutrient Requirements of Poultry. 9th rev. edn. National Academy Press, Washington, DC. 34–45.
- Pala M, Saygı YB (1983). Su aktivitesi ve gıda işletmedeki önemi. *Gıda* 8(1): 33–39.
- Pappas AC, Zoidis E, Theophilou N, Zervas G, Fegeros K (2010). Effects of palygorskite on broiler performance, feed technological characteristics and litter quality. *Appl Clay Sci* 49 (3): 276–280.
- Ramos AJ, Hernandez E (1997). Prevention of aflatoxicosis in farm animals by means of hydrated sodium calcium aluminosilicate addition to feedstuffs. *Anim Feed Sci Tech* 65(4):197–206.
- Richardson W, Day EJ (1976). Effect of varying levels of added fat in broiler diets on pellet quality. *Feedstuffs* 48 (20): 24.
- Shi Y, Parker DB, Cole NA, Auvermann BW, Mehlhorn JE (2001). Surface amendments to minimize ammonia emissions from beef cattle feedlots. *Amer Soc Agric Eng*, 44: 677–682.
- SPSS (2011). Statistical Packages for the Social Sciences, 20th edn., IBM Inc, Chicago, USA.
- Subramaniam MD, Kim IH (2015). Clays as dietary supplements for swine: A review. *J Anim Sci Biotechnol* 6(1): 38.
- Svihus B (2014). Starch digestion capacity of poultry. *Poult Sci* 93: 2394–2399
- Venig SB, Serjantov VG, Chernova RK, Doronin SY, Selifonova EI, Zaharevich AM, Soldatenko EM (2014). Glauconite of Saratov region, properties, composites based on it, the application. *Butlerov Communications, Russia*. 39(8), Registration Code of Publication: 14–39–8–17.
- Venig SB, Chernova RK, Doronin SY, Soldatenko EM, Selifonova EI, Sergantov VG, Zharevich AM, Shapoval OG (2017). Synthesis, properties and antibacterial activity of the composites based on glauconite. *BioNanoSci* 7 (4):659–665.
- Wang J, Hu J, Zhang S (2010). Studies on the sorption of tetracycline onto clays and marine sediment from seawater. *J Colloid Interface Sci* 349(2): 578–582.
- Wolter R, Dunoyer C, Henry N, Seegmuller N (1990). Les argiles en alimentation animale: inte're t general. *Rec Med Vet* 166: 21– 27.
- Yalçın S, Eser H, Onbaşlar İ, Yalçın S, Karakaş Oğuz F (2016). Effects of dietary sepiolite on performance, egg quality and some blood parameters in laying hens. *Ankara Univ Vet Fak Derg* 63(1): 25–29.
- Yalçın S, Burçak E, Onbaşlar İ, Ramay MS, Gebeş ES, Pirpanahi M (2019a). Improvement in pellet production parameters and pellet quality characteristics with sepiolite supplementation in dairy cattle concentrate. *Kafkas Univ Vet Fak Derg* 25(1): 119–123.
- Yalçın S, Burçak E, Onbaşlar İ, Ramay MS, Pirpanahi M (2019b): Effects of sepiolite supplementation to dairy concentrate on pellet quality characteristics. *JOAAT* 6: 119–123.
- Yalçın S, Karakan T, Ramay MS, Sarıcan İ (2020). Effects of supplementation of sepiolite and humate to beef cattle concentrate on pellet quality characteristics. *Ankara Univ Vet Fak Derg* 67(1): 81–86.
- Zhou Y, Xia M, Ye Y, Hu C (2004). Antimicrobial ability of Cu²⁺-montmorillonite. *Appl Clay Sci* 27(3–4): 215–218.

Squamous Cell Carcinoma (SCC) in Brown meagre (*Sciaena umbra* Linnaeus, 1758), a new candidate species for aquaculture in Mediterranean

M.N. Kolygas¹, E. Lampou¹, D. Doukas², D. Tontis², I. S. Pappas³, E. Gourzioti¹,
V. Bakopoulos⁴, E. Kakava¹, F. Athanassopoulou¹

¹ Laboratory of Pathology of Aquatic Animals, Ichthyology & Aquaculture, Faculty of Veterinary Medicine, University of Thessaly, Greece

² Laboratory of Pathology, Faculty of Veterinary Medicine, University of Thessaly, Greece

³ Laboratory of Veterinary Pharmacology and Toxicology, University of Thessaly, Greece

⁴ Department of Marine Sciences, School of Environment, University of The Aegean, Lesvos, Greece

ABSTRACT: A case of epithelial tissue tumors on the body of two adult Brown meagres (*Sciaena umbra* Linnaeus, 1758) is reported. Brown Meagre population of 20.000 was imported to sea cages on September of 2003 at 3g, to check the potential use of this species as a new candidate in Mediterranean aquaculture. The population had been kept for 8 years to serve as a genetic pool for further zootechnical investigation. The main pathology observed after 8 years in the sea cages were mainly ocular lesions (cataract) possibly due to natural aging and/or long culture period under high natural light intensity (UV radiation) and/or net injuries at a percentage of 1,32% of total cultured population. Apart from that, on two fish, reddish- white tumorous growths were evident on skin, macroscopically. Histologically, the tumorous growths were diagnosed as Squamous cell carcinoma. Numerous rounded pearls and nests of epidermal proliferated cells were evident, some of which had a non-cellular center. There were also foci of necrosis and irregular deposits of keratin within the tumor tissue. Special stains (Ayoub-Shklar, Haematoxylin-Eosin & Schiff's Periodic Acid) were applied to the tissue for comparison. To our knowledge this is the first presented report of SCC in this species.

Keywords: Squamous cell carcinoma, Ayoub-Shklar Stain, keratin, *Sciaena umbra*, Brown meagre

Corresponding Author:

Markos N. Kolygas, Laboratory of Pathology of Aquatic Animals, Ichthyology & Aquaculture, Faculty of Veterinary Medicine, University of Thessaly, Greece
E-mail address: kolygas@vet.uth.gr

Date of initial submission: 29-09-2019
Date of revised submission: 17-05-2020
Date of acceptance: 11-06-2020

INTRODUCTION

The epidermis in teleost fish is a non-cornified stratified squamous epithelium that varies in thickness (from 3 up to 25 cells) (Genten et al., 2009) and is capable of producing intermediate filaments (tonofilaments) of keratinous origin (Garcia et al., 2005) which represent the most abundant proteins (nearly 80% of total protein content) in stratified epithelia of vertebrates (Rao et al., 2015). Intermediate filaments (IFs) are cytoskeletal proteins generating complex networks that support the cell's shape and junctions to other cells (maculae adherents or desmosomes) (Schaffeld & Markl on Omary & Coulomb 2004). In cases of abnormal manifestations on fish epidermis, IFs and especially cytokeratins can be a major diagnostic tool on malignancies' differentiation, characterization and origin.

Teleost fish, like other vertebrates can develop benign, premalignant and/or malignant cellular deformities. The etiological agents or suspected factors of such manifestations are contributed to environmental (pollution, carcinogenic chemicals, radiation, toxins), hereditary (genetic predisposition), enzymatic, immunological, traumatic, viral & other constituents (Coffee et al. 2013, Pinkney et al. 2004, Landsberg 2002, Pinkney et al. 2001, Morrison et al. 1996, Harshbarger et al. 1993, Ahne et al. 1990, Sano et al. 1985, Harshbarger 1972), while main predisposing factors are considered to be age, sex and immunological competence.

In fish, protruding skin tumors are more common in freshwater species (Ribelin & Migaki 1975) while malignant tumors are rarer than papillomata (Poochirian et al. 2011). Squamous cell carcinoma a malignant neoplasm, has been reported in many fish species (Table 1) in a variety of loci.

MATERIALS & METHODS

Case history

A cultured population of brown meagres reared in sea cages, had been reported to present bilaterally clouded-opaque eye lenses (Fig. 1d) in a percentage of 1,32% of total cultured population, which was subsequently affecting the wholesale price. This population of 20.000 brown meagres was transferred to sea cages on September of 2003 at 3g, to check the potential use of this species as a new candidate in Mediterranean aquaculture. The population had been kept for 8 years to serve as a genetic pool for further zootechnical investigation. After 8 years, when the G2 generation was ready to substitute the G1

broodstock, the whole population of almost 20.000 brown meagres was harvested. The main pathology observed after 8 years in the sea cages were mainly ocular lesions (cataract) possibly due to natural aging and/or long culture period under high natural light intensity and/or net injuries. Apart from that, tumors were evident. During the scheduled harvesting, fish sampling took place during the packaging process in order to investigate the cause of the problem. In the course of fish sampling, two (2) brown meagres had distinctive solitary protruding lesions (one on each fish) similar in texture (Fig. 1). More specifically, the first fish (fish No1) had a protruding formation of solid texture on the proximal ventral left site of juncture between *os angulo-articulare* and *os dentale* (Fig. 1b, arrow). Circumferential skin was pale with no further obvious anomalies (ulcers or trauma). The second fish (fish No2) had a large hemispherical, ulcerative mass ($\approx 5,5 \times 3,1 \times 2,9$ cm) that was posteriorly covering the biggest area of the left pectoral fin and anteriorly was extended up to the distal end of the left operculum. The dorsal site of the mass extended near the fish's left lateral line. The lesion was strongly attached to the subjacent tissue, with no indication of fluctuated content, but with multifocal necrosis (Fig. 1c, arrows) and ulcerative processes (Fig. 1c, white asterisk).

Microbiology

Prior to parasitological examinations, tryptone soy agar (TSA) and thiosulphate citrate bile salt agar (TCBS) media, inoculated from kidney and spleen samples, while *Flexibacter Maritimus Medium* (FMM) and Marine Agar (MA) media inoculated from skin and gill samples. All petri dishes were incubated at 21°C (sea water temperature). Bacterial Identification was assessed biochemically using API 20E®, BioMérieux®.

Parasitology

Skin examination was initially conducted macroscopically. Microscopic examination of wet mount scrapings was performed only from suspicious skin loci. Parasitological examination was conducted in gills, skin, intestine and bile. Specially, bilateral gill epithelium scrapings from the first and second gill arches, was examined under light microscope for parasites. Concerning to intestine's parasitological examinations, wet mount scrapings from pars anterior, medial and posterior *canalis intestinalis* was performed. Bile was excised and handled similarly to the intestine.

Table 1. Cases of Squamous cell Carcinoma in fish

Species		Habitat	Reference
Common name	Scientific name		
Bream	<i>Abrami ssp.</i>	Freshwater	Hanjavanit & Mulcahy 2004
Yellowbullhead	<i>Ameiurus natalis</i>	Freshwater	Hanjavanit & Mulcahy 2004
Brownbullhead	<i>Ameiurus nebulosus</i>	Freshwater	Pinkney et al 2011,
Blackbullhead	<i>Ameiurus melas</i>	Freshwater	R.T.L.A. (Sterling VA) Hanjavanit & Mulcahy 2004
American eel	<i>Anguilla rostrata</i>	Catadromous	Hanjavanit & Mulcahy 2004
Oscar	<i>Astronotus ocellatus</i>	Freshwater	Rahmati-Holasoo & Hobbenaghi 2010
Barbel	<i>Barbus barbus</i>	Freshwater	Keysseltz 1908, Clunet 1910 (on Ribelin & Migaki 1975)
Gulf menhaden	<i>Brevoortia patronus</i>	Marine	Fournie et al. 1987
Goldfish	<i>Carrassius auratus</i>	Freshwater	Hanjavanit & Mulcahy 2004
Whitesucker	<i>Catostomus commersoni</i>	Freshwater	Hanjavanit & Mulcahy 2004
-	<i>Chondrostoma soetta</i>	freshwater	Mazzarelli, 1910 (on Ribelin & Migaki 1975)
Mirrorcarp	<i>Cyprinus carpio</i>	Freshwater	Manera & Biavati 1994, Wildgoose 1992
Malawichlid	<i>Cyrtocara moorii</i>	Freshwater	Hanjavanit & Mulcahy 2004
Saithe	<i>Gadus virens</i>	Marine	Williams 1929 (on Ribelin & Migaki 1975)
Gudgeon	<i>Gobio gobio</i>	Freshwater	Mawdesley-Thomas & Bucke 1967
Black Tetra	<i>Gymnocorymbus ternetzi</i>	Freshwater	Sharifpour et al. 2014
Hybrid sunfish	<i>Lepomi ssp.</i>	Freshwater	Fitzgerald et al. 1991
Ide	<i>Leuciscus idus</i>	Freshwater	Mawdesley-Thomas 1972b (on Ribelin & Migaki 1975)
Whiting	<i>Merlangius merlangus</i>	Marine	Johnstone, 1923-25, 1924, 1924-25 (on Ribelin & Migaki 1975)
Grey mullet	<i>Mugil cephalus</i>	Marine-Freshwater	Poochirian et al. 2011,
Chinooksalmon	<i>Onchorhynchus tshawytscha</i>	Anadromous	Hanjavanit & Mulcahy 2004
Medaka	<i>Oryzias latipes</i>	Amphidromous	Hanjavanit & Mulcahy 2004
European smelt	<i>Osmerus eperlanus</i>	Marine-Freshwater	Breslauer, 1915-16 (on Ribelin & Migaki 1975)
Atlantic rainbow smelt	<i>Osmerus mordax</i>	Anadromous	Hanjavanit & Mulcahy 2004, Herman 1988, Morrison & MacDonald 1995
Pudgy cuskeel	<i>Parabassogigas crassus</i> (Invalid) <i>Spectrunculus grandis</i> (valid)	Marine	Mawdesley- Thomas 1971a (on Ribelin & Migaki 1975)
Congo tetra	<i>Phenacogrammus interruptus</i>	Freshwater	Hanjavanit & Mulcahy 2004
Roach	<i>Rutilus rutilus</i>	Freshwater	Hanjavanit & Mulcahy 2004
Salmon	<i>Salmo salar</i>	Anadromous	Roberts 1972
Rudd	<i>Scardinius erythrophthalmus</i>	potamodromous	Hanjavanit et al. 1990, Hanjavanit & Mulcahy 2004
Brown meagre	<i>Sciaena umbra</i>	Marine	Kolygas et al. - (Current article)
Sea stickleback	<i>Spinachia spinachia</i>	Marine	Murray, 1908 (on Ribelin & Migaki 1975)
Alaska pollock	<i>Theragra chalcogramma</i>	Marine	Takahashi, 1929 (on Ribelin & Migaki 1975)

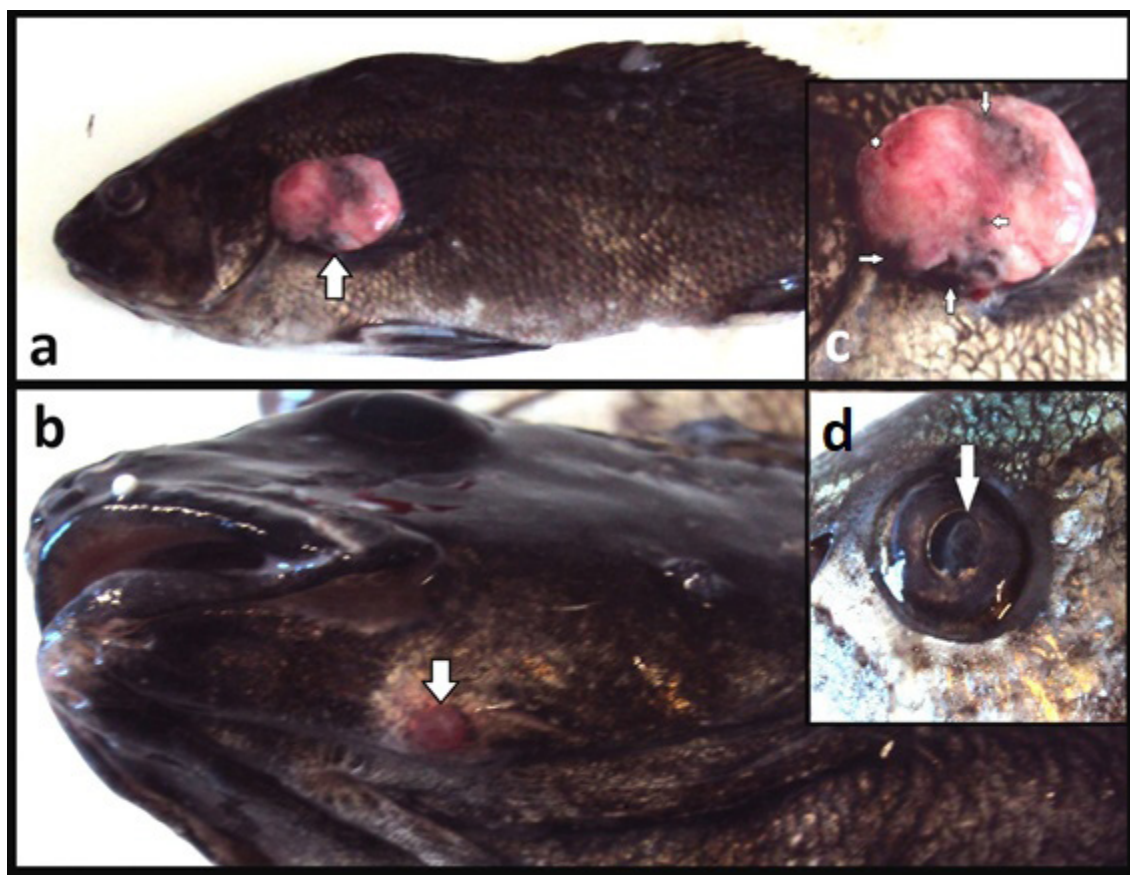


Figure 1: a) spherical, ulcerated tumor at the level of the lateral line in *Sciaena umbra*, b) small protruding formation on the left mandible, c) tumorous growth, note the necrotic loci (arrows) and the ulcerative site (white asterisk), d) cloudy-opaque eye lenses was the initial reason of examination.

Histopathology

Both lesions were excised, and tissue blocks were fixed in 10% formalin and Davidson's fixative. Tissue process was according to routine protocols. All tissue sections (5µm) were stained with Haematoxylin – Eosin (H&E), Periodic-Acid Schiff's(PAS) and Ayoub-Shklar (A-S)(Bancroft & Gamble 2008, Rao et al. 2005). In the A-S staining procedure no phosphotungstic acid(PTA) was used, the reason for this change in A-S staining protocol is explained in discussion's chapter. Sections were deparaffinized and hydrated to distilled water. Acid fuchsin5% added for 3min and slides were transferred directly to 0,5% aniline blue-1%orange G solution for 45min. Dehydration was performed on two 5min changes on 95% alcohol followed by one 3min, 100% EtOH change. After dehydration, two 3min changes on Xylene followed and eventually slides were mounted. Moreover, after necropsy, tissues from main internal organs such as liver, spleen and kidney were also selected for histopathology. Blood smears were impossible to be conducted given the fact that fish sampling took place during manufacture packaging process.

RESULTS

Microbiology

After a 72h incubation period of FMM and MA inoculated media from skin samples of both fish, colonies of distinct bacteria resembling to *Tenacibaculum maritimum* (Pazos et al., 1996) were observed and confirmed by the biochemical profile of the bacterium (Kolygas et al., 2012, Gourzioti et al., 2016). After a 48h incubation period of TSA and TCBS inoculated media from spleen and kidney, growth of *Listonella (Vibrio) anguillarum* was observed on fish No2samples.

Parasitology

Parasitological examination of the gills indicated a mild infection from monogenean parasites of the genus *Lamellodiscus* ($5,25 \pm 2,12$ parasites/gill arch). Wet skin and bile mounts showed no presence of parasites. In contrast, wet mounts of intestine from all three parts on both fish revealed scolices (mean intensity 0,43 parasites/ optical field).

HISTOPATHOLOGY

Microscopical studies from both fish lesions showed similar histopathological pattern of well differentiated squamous cell carcinomas (Fig.2). More specifically, multiple aggregates of tumor cells nests (Fig.2.c), with pleomorphic characteristics (Fig.2a) were abundant. Certain areas of well differentiated squamous epithelial cells (resembling more or less to normal fish epidermis) forming projections into the

chorium, exhibited a pattern with basosquamous cells on the nest's periphery (Fig.2a, arrow), and squamous keratinogenous cells at the center (Fig.2b, asterisk). The intermediate space between the nests, contained layers of connective tissue infiltrated by inflammatory cells (lymphocytes). Tissue from liver, spleen and kidney did not indicate any histopathological findings of neoplasm metastasis.

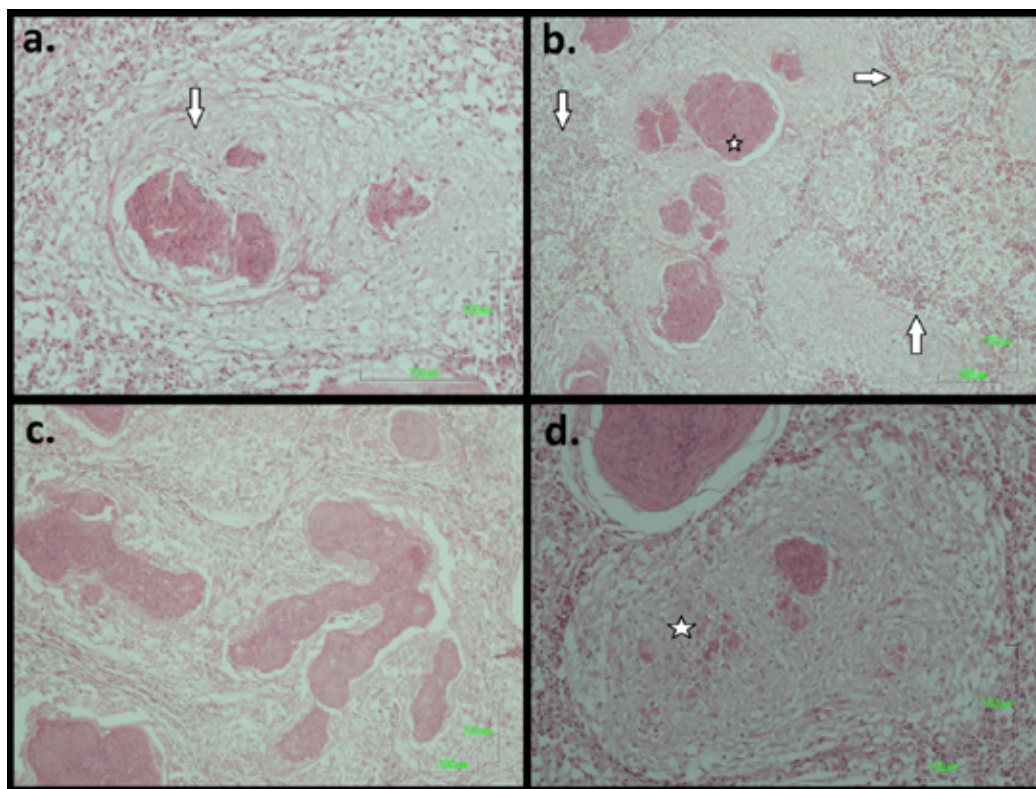


Figure 2: a) pleomorphic epithelial cells (arrow) inside a nest (H&E stain), b) wide areas of necrotic tissue (arrows) surrounding the well differentiated clusters of tumor cells (tumor cell nests). Note the squamous keratinogenous cells at the center of these nests (asterisk), (H&E stain), c) tumor's diathesis on creating digitiform tumors strands, (H&E stain), d) tumor's diathesis on creating satellite growths. The mature keratinogenous nest (center) gave early, small proximal satellite foci (asterisk) tumors (H&E stain).

Comparison between stains

Standard H&E stain on low magnifications (40x-100x) displayed a clear differentiation between the connective tissue and the tumorous growths, mainly because of the more compact distribution of epithelial cells and the hyperchromatic diathesis, of the latter. In higher magnification powers ($\geq 400x$) early development of tumorous cell nests (Fig.2d, asterisk), was difficult to diagnose. The transitional states of cell nests and keratin accumulations on the more matured ones, was problematic to distinguish. Some cells nests had higher stain accumulations than other, and that can be mistakenly attributed to respective keratin accumulation, but in fact this correlation is precarious as necrotic content within the cell nests

can give the same results (Fig.3, H&E, 100x & 400x). Staining with PAS, gave similar results to H&E on lower magnification. More specifically, discernment between the peri-tumorous connective tissue and the tumorous cells nests was fair in low magnifications (40x, 100x). Higher magnification powers ($\geq 400x$) gave the same disadvantages as H&E stain. Ayoub-Shklar stain displayed better diagnostic potentials in comparison to afore mentioned stains, as it was able not only to highlight early developmental tumorous cell nests and early satellite growths (Fig.3, A-S, 100x) but also to distinguish their transitional level with escalating stain intensities on keratin accumulation (Fig.3, A-S, 400x).

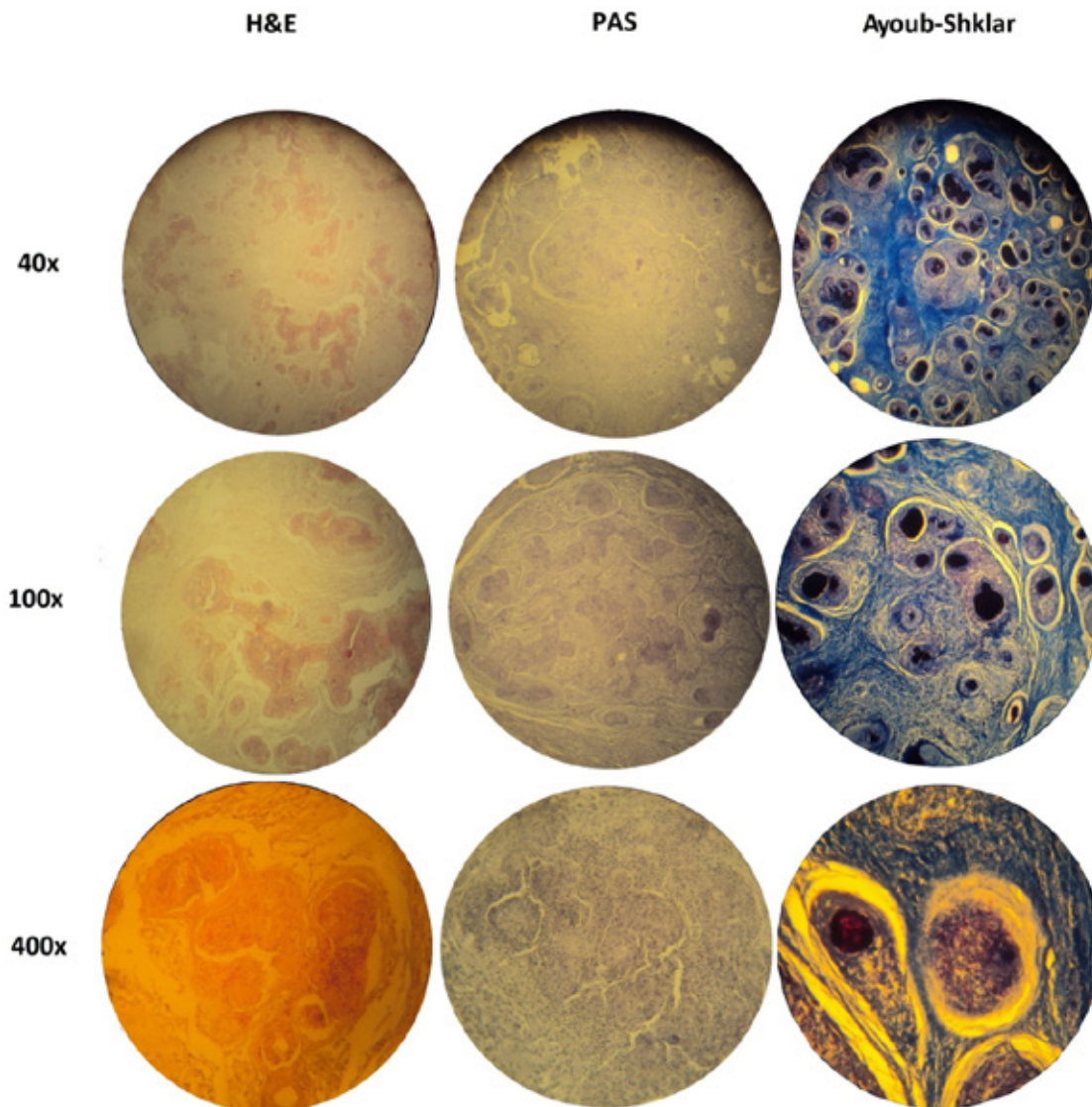


Figure 3. Pictomicrograph comparison of SCC stained with H&E, Schiff's Periodic Acid (PAS), and Ayoub-Shklar (A-S), respectively at different magnification powers.

DISCUSSION

Both cases of Brown meagres lesions, exhibit tumorous growth diagnosed as Squamous Cell Carcinomas. To our knowledge this is the first occurrence of malignancy of this type on Brown meagres. The causative agent of this malignant manifestation in these two fish is unknown, and only speculations on the possible etiology can be made. Many authors have indicated several possible agents that can give rise to such cellular abnormal proliferations (Roberts, 2001, Hanson et al, 2011). The microbiological and parasitological findings are considered of minor importance and at some level expected given the health status of both fish.

Regarding the staining methods, Ayoub-Shklar stain exhibited higher specificity than H&E and PAS in squamous cell carcinomas. Considering that the tumors were well differentiated, the risk of misinterpreted diagnosis with H&E and PAS stain was low, but in poor differentiated tumorous growths, an accurate diagnosis is highly compromised under the use of un-specific keratin stains. Keratin as a marker can provide not only concluding diagnosis in SCC but also key differential histological evidence between mesenchymal and epithelial malignancies (Ramulu et al. 2013). Immunohistochemical methods are more sensitive diagnostic tools for keratin demonstration (Karantza 2011) but are expensive and time consuming (Rao et

al. 2014). Moreover, specific stains can demonstrate histologically the degree of keratinization (Ramulu et al, 2013). Diagnostic misinterpretations between a) mature versus early SCC satellite keratin nests and b) keratin accumulations versus necrotic content within the nests, in histological sections are likely to occur when basic H&E protocols are used, in contrast to Ayoub-Sklar which is a quick, cost effective stain that can provide adequate specificity on keratin exposition in SCC cases and set definitive diagnosis on SCC in fish.

Another crucial parameter that always must be taken into consideration when cases of SCC are suspected is whether to apply or not phosphotungstic acid in Ayoub-Shklar staining protocol. In fact, the presence of PTA can dramatically change the final stain outcome of A-S on keratin demonstration of SCC cases. During a comparative staining trial on keratin demonstration it is mentioned that in some SCC cases, A-S stain failed to uniformly stain malignant manifestations of keratin pearl demonstrations (Ramulu et al 2013). Moreover, during a similar comparative staining trial of keratin demonstration, the conclusion was that H&E's staining specificity and intensity is highest when compared to special stains such as Ayoub-Shklar (Rao et al 2014), which is in contrast to the conclusions of the present study. The reason

for these dissenting results could be that the presence of PTA during A-S stain on afore mentioned studies, possibly reduces stain's overall specificity, as far as keratin demonstration is concerned. The presence of PTA possibly transitions the staining outcome closer to Masson's Trichrome stain, a stain that is used to distinguish collagen fibers versus smooth muscles and not keratinogenous cells, keratin and prekeratin. In fact, the role of PTA in histology is to bind to pre-stained specific endocellular and ectocellular molecules in order to selectively decolorize them (Everett & Miller 1974). In trichrome stains like Masson & Mallory, PTA is used to mordant anionic dyes to connective tissue fibers. In the case of A-S stain protocol, PTA might have the same effect on some keratin nests of certain maturity states, reducing the overall specificity. To either accept or reject this hypothesis, further studies on different staining protocols need to be made.

Conclusively, the above A-S stain protocol can be adopted in in-house labs as a quick and cost-effective diagnostic procedure especially on broodstock facilities where early intervention is of major importance on this high-value livestock.

CONFLICT OF INTEREST

None declared by the authors.

REFERENCES

- Ahne, W., Anders, M., Halder, M., Yoshimizu, M. (1990). Isolation of picornavirus-like particles from the European smelt, *Osmeruseperlanus* (L.). *Journal of Fish Diseases* 13:167–168.
- Bancroft, J.D. & Gamble, M. (2008) Theory and Practice of Histological Techniques. 6th Edition, Churchill Livingstone, Elsevier, China.
- Bragulla, H. H., & Homberger, D. G. (2009). Structure and functions of keratin proteins in simple, stratified, keratinized and cornified epithelia. *Journal of Anatomy*, 214(4), 516-559. doi:10.1111/j.1469-7580.2009.01066.x
- Coffee, L. L., Casey, J. W., & Bowser, P. R. (2013). Pathology of tumors in fish associated with retroviruses: A review. *Veterinary Pathology*, 50(3), 390-403. doi:10.1177/0300985813480529
- Everett, M. M., & Miller, W. A. (1974). The role of phosphotungstic and phosphomolybdic acids in connective tissue staining I. histochemical studies. *The Histochemical Journal*, 6(1), 25-34. doi:10.1007/BF01011535
- Fitzgerald, S.D., Carlton, W.W., Sandusky, G. (1991). Metastatic squamous cell carcinoma in a hybrid sunfish. *Journal of Fish Diseases*. 14:481–488.
- Fournie, J.W., Vogelbein, W.K., Overstreet, R.M. (1987). Squamous cell carcinoma in the gulf menhaden, *Brevoortia patronus* Goode. *Journal of Fish Diseases* 10:133–136. doi:10.1111/j.1365-2761.1987.tb00728.x
- García, D. M., Bauer, H., Dietz, T., Schubert, T., Markl, J., & Schaffeld, M. (2005). Identification of keratins and analysis of their expression in carp and goldfish: Comparison with the zebrafish and trout keratin catalog. *Cell and Tissue Research*, 322(2), 245-256. doi:10.1007/s00441-005-0031-1
- Genten, F., Terwinghe, E., Danguy, A. (2009) Atlas of fish Histology, Science Publishers
- Gourzioti, E., Kolygas, M.N., Athanassopoulou, F., Babili, V. (2016). Tenacibaculosis in aquaculture farmed marine fish. *Journal of Hellenic Veterinary Medical Society*, 67(1):21-31
- Quaedvlieg, P. J. F., Creyten, D. H. K. V., Epping, G. G., Peutz-Kootstra, C. J., Nieman, F. H. M., Thissen, M. R. T. M., & Krekels, G. A. (2006). Histopathological characteristics of metastasizing squamous cell carcinoma of the skin and lips. *Histopathology*, 49(3), 256-264. doi:10.1111/j.1365-2559.2006.02472.x
- Hanjavanit, C., & Mulcahy, M. F. (2004). Squamous cell carcinoma in rudd *Scardinius erythrophthalmus*: Histopathology, ultrastructure, and transmission. *Diseases of Aquatic Organisms*, 61(3), 215-226.
- Hanjavanit, C., Mulcahy, M.F., Doyle, C.T. (1990). Squamous-cell carcinoma in rudd *Scardinius erythrophthalmus*. *Dis Aquat Org* 8:155–156
- Hanson, L., Dishon, A., & Kotler, M. (2011). Herpesviruses that infect fish. *Viruses*, 3(11), 2160-2191. doi:10.3390/v3112160
- Harshbarger, J.C. (1972) Work of the Registry of Tumours in Lower Animals with emphasis on fish neoplasms. *Symposia of the Zoological Society of London* 30:285–303.
- Harshbarger, J.C., Spero, P.M., Wolcott, N.M. (1993). Neoplasms in wild fish from the marine ecosystem emphasizing environmental interaction. In: Couch J.A., Fournie J.W. (eds) *Pathobiology of marine and estuarine organisms*. CRC Press, Boca Raton, FL.
- Herman, R.L. (1988). Squamous cell carcinoma in rainbow smelt, *Osmerus mordax*. *Journal of Diseases of Aquatic Organisms* 5:71–73

- Karantza, V. (2011). Keratins in health and cancer: More than mere epithelial cell markers. *Oncogene*, 30(2), 127-138. doi:10.1038/nc.2010.456
- Kolygas, M. N., Gourzioti, E., Vatsos, I. N., & Athanassopoulou, F. (2012). Identification of tenacibaculummaritimum strains from marine farmed fish in Greece. *Veterinary Record*, 170(24), 623. doi:10.1136/vr.100778
- Landsberg, J.H. (2002). The effects of harmful algal blooms on aquatic organisms. *Reviews in Fisheries Science* 10(2):113-390.
- Manera, M., & Biavati, S. (1994). An immuno-histochemical technique used to demonstrate the transition form of a squamous cell carcinoma in a mirror carp, *Cyprinus carpio* L. *Journal of Fish Diseases*, 17(1), 93-96. doi:10.1111/j.1365-2761.1994.tb00349.x
- Matsui, T., & Amagai, M. (2015). Dissecting the formation, structure and barrier function of the stratum corneum. *International Immunology*, 27(6), 269-280. doi:10.1093/intimm/dxv013
- Mawdesley-Thomas, L. E., & Bucke, D. (1967). Squamous cell carcinoma in a gudgeon (*Gobiogobio*, L.). *Pathologia Veterinaria*, 4(5), 484-489.
- Morrison, C.M., Leggiadro, C.T., Martell, D.J. (1996). Visualisation of viruses in tumors of rainbow smelt, *Osmerus mordax*. *Diseases of aquatic organisms* 26:19-23.
- Morrison, C. M., & Macdonald, C. A. (1995). Epidermal tumors on rainbow smelt and Atlantic salmon from Nova Scotia. *Journal of Aquatic Animal Health*, 7(3), 241-250.
- Omary B. M., & Coulombe P. (2004). Intermediate filament Cytoskeleton. Academic Press. Volume 78, 1st Edition
- Pazos, F., Santos, Y., Macías, A.R., Nuñez, S., Toranzo, A.E. (1996). Evaluation of media for the successful culture of *Flexibacter maritimus*. *Journal of Fish Diseases* 19: 193-197.
- Pinkney, A. E., Harshbarger, J. C., Karouna-Renier, N. K., Jenko, K., Balk, L., Skarphéinsdóttir, H., Rutter, M. A. (2011). Tumor prevalence and biomarkers of genotoxicity in brown bullhead (*Ameiurus nebulosus*) in Chesapeake Bay tributaries. *Science of the Total Environment*, 410-411, 248-257. doi:10.1016/j.scitotenv.2011.09.035
- Pinkney, A.E., Harshbarger, J.C., May, E.B., Reichert, W.L. (2004). Tumor prevalence and biomarkers of exposure and response in brown bullhead (*Ameiurus nebulosus*) from the Anacostia River Washington, DC and Tuckahoe River, Maryland, USA. *Environmental Toxicology and Chemistry* 23(3):638-647.
- Pinkney, A.E., Harshbarger, J.C., May, E.B., Malancon, M.J. (2001). Tumor prevalence and biomarkers of exposure in brown bullheads (*Ameiurus nebulosus*) from the Tidal Potomac River Watershed. *Environmental Toxicology and Chemistry* 20:1196-1205.
- Poochirian, J. K., Maruthamuthu, N., Sahoo, P. K., & Govindarajan, T. (2011). Squamous cell carcinoma in grey mullet, *Mugil cephalus* L. (perciformes: Mugilidae). *Comparative Clinical Pathology*, 20(6), 673-675. doi:10.1007/s00580-011-1215-6
- Rahmati-Holasoo, H., Hobbenaghi, R., Tukmechi, A., & Morvaridi, A. (2010). The case report on squamous cell carcinoma in oscar (*Astronotus ocellatus*). *Comparative Clinical Pathology*, 19(4), 421-424. doi:10.1007/s00580-010-0963-z
- Ramulu, S., Kale, A. D., Hallikerimath, S., & Kotrashetti, V. (2013). Comparing modified papanicolaou stain with ayoub-shklar and haematoxylin-eosin stain for demonstration of keratin in paraffin embedded tissue sections. *Journal of Oral and Maxillofacial Pathology*, 17(1), 23-30. doi:10.4103/0973-029X.110698
- Rao, R.S., Patil, S., Majumdar, B., Oswal, R.G., (2015). Comparison of special stains for keratin with routine hematoxylin and eosin stain. *Journal of International Oral Health*. 7(3):1-5.
- Ribelín, W. E., & Migaki, G. & Registry of Comparative Pathology (1975). The Pathology of fishes: proceedings of a symposium. University of Wisconsin Press, Madison
- Roberts, R.J. (1972). Oral carcinomata in a salmon (*Salmo salar* L.). *Veterinary Record*, 91:199.
- Roberts, R.J. (2001). Neoplasia of teleosts. In: Roberts RJ (ed) Fish Pathology, 3rd edn. WB Saunders, Edinburgh, 151-168.
- Rogers, M. A., Winter, H., Langbein, L., Wollschläger, A., Praetzel-Wunder, S., Jave-Suarez, L. F., & Schweizer, J. (2007). Characterization of human KAP24.1, a cuticular hair keratin-associated protein with unusual amino-acid composition and repeat structure. *Journal of Investigative Dermatology*, 127(5), 1197-1204. doi:10.1038/sj.jid.5700702
- Sano, T., Fukuda, H., Furukawa, M. (1985). *Herpesvirus cyprini*: biologic and oncogenic properties. *Fish Pathology* 20:381-388.
- Schaffeld, M., Markl, J. (2004). Fish Keratins, research article on book Intermediate filament cytoskeleton, Academic Press, Volume 78, Pages 627-671, ISSN 0091-679X, ISBN 9780125641739
- Sharifpour, M. F., Hobbenaghi, R., Alyali, P., & Morvaridi, A. (2014). Squamous cell carcinoma in a black tetra, *Gymnocorymbus ternetzi* (Boulenger). *Journal of Fish Diseases*, 37(11), 985-987. doi:10.1111/jfd.12191
- Verzija, D., Riedl, T., Parren, P. W. H. I., & Gerritsen, A. F. (2017). A novel label-free cell-based assay technology using biolayer interferometry. *Biosensors and Bioelectronics*, 87, 388-395. doi:10.1016/j.bios.2016.08.095
- Wildgoose, W. H. (1992). Papilloma and squamous cell carcinoma in koi carp (*Cyprinus carpio*). *Veterinary Record*, 130(8), 153-1

Malignant fibrous histiocytoma in a budgerigar (*Melopsittacus undulatus*)

H. Özen¹, S. Dağ², E. Karakurt², E. Büyük³

¹ Department of Pathology, Faculty of Veterinary Medicine, Balıkesir University, Balıkesir, Turkey

² Department of Pathology, Faculty of Veterinary Medicine, Kafkas University, Kars, Turkey

³ Institute of Medical Sciences, Kafkas University, Kars, Turkey

ABSTRACT. In this report, a case of malignant fibrous histiocytoma in a budgerigar (*Melopsittacus undulatus*) is described. At necropsy, a tumorous subcutaneous mass was noted to be located under the right wing at the level of humerus in a budgerigar. On microscopic examination, the tumor was composed of pleomorphic cells having mostly round to oval large nucleus. Presence of occasional bands composed of fibroblastoid cells were noted. Occasional giant cells and mitotic figures were also observed. Based on the microscopic findings, a diagnosis of malignant fibrous histiocytoma was made. The present case in an exotic bird was found to be interesting, since malignant fibrous histiocytomas are rare tumors of domestic animals and mostly seen in dogs.

Keywords: Budgerigar, pleomorphic sarcoma, malignant fibrous histiocytoma, histopathology

Corresponding Author:

Hasan Özen, Department of Pathology, Faculty of Veterinary Medicine,
Balıkesir University, Balıkesir, Turkey
E-mail address: hasanozen@hotmail.com

Date of initial submission: 18-11-2019
Date of revised submission: 03-06-2020
Date of acceptance: 10-07-2020

INTRODUCTION

Malignant fibrous histiocytoma (MFH), in a simplified term, can be defined as an entity of undifferentiated pleomorphic sarcoma. MFH is accepted as a descriptive morphologic term and not reflects the cellular origin of the tumor (Gross et al., 2005). Debate over nomenclature of these tumors continues due to unidentified origin of the tumor cells and the various histomorphologic patterns they present. The term malignant fibrous histiocytoma was first described by O'Brien and Stout (1964) and some other names such as giant cell tumor of soft parts, dermatofibrosarcoma protuberans, malignant xanthogranuloma and reticulum cell sarcoma of soft tissues, malignant fibrous xanthoma, fibrous xanthoma were used for undifferentiated pleomorphic sarcomas (Roffe, 1987). MFH is the most common sarcoma of extremities in human, and mostly seen in soft tissues although can also be located in bones, various organs and regions of the body (Fletcher, 1992; Schneider et al., 1999). They are mostly encountered in elderly people though can also be seen in young, with a mean age of 54 years in a study population. (Gibbs et al., 2001). In the animal kingdom, dogs are the most commonly reported animals with MFH. These tumors, as in human, have been reported in older pets but can also be seen in younger ages (Pires, 1997; Do et al., 2009). Cases of MFH were reported in a number of animal species, such as mouse, rat, cat, dog, opossum, cattle, horse and birds (Schneider et al., 1999).

MFHs are highly aggressive tumors with a rapid clinic progression and poor prognosis (Gibbs et al.,

2001). Five subtypes of MFH were described in human; storiform-pleomorphic, giant cell, inflammatory, myxoid and angiomatoid, however the last one is no longer considered under MFH (Al-Agha and Igbokwe, 2008). In animals, only storiform-pleomorphic and giant cell subtypes were reported to be present, though inflammatory form is still controversial (Do et al., 2009; Hendrick, 2017; Al-Agha and Igbokwe, 2008). The most common morphologic type of MFHs has a background of pleomorphic spindle-shaped cells haphazardly organized or in storiform pattern (Kerlin and Hendrick, 1996). In MFHs, inflammatory and giant cells can be present in varying numbers. These tumors are grossly noted as firm gray-white masses and show variable metastatic potential depending on the case (Hendrick, 2017). Since MFH is a rare tumor in animals and only few previous reports are currently present in birds, one in a mallard (Roffe, 1987) and the other in a pigeon (Derakhshanfar and Oloumi, 2008), a case of MFH detected in a budgerigar was thought to worth to report.

CASE HISTORY

The study material was an adult female budgerigar (*Melopsittacus undulatus*) brought to the Department of Pathology, Faculty of Veterinary Medicine, Kafkas University in order to define the cause of death. Systemic necropsy was performed, gross and microscopic findings were described. Body condition of the bird was quite weak. A firm white to grey subcutaneous mass of 2x1x1 cm was noted under the right wing, at the level of humerus (Figure 1). No other masses were noted at any organs and no other pathological changes were seen as well. The mass was routinely fixed in formalin and paraffin embedded, and the sections cut from the paraffin blocks were stained with hematoxylin and eosin (H&E) and viewed under a light microscope.



Figure. 1. A nodular subcutaneous mass in the budgerigar

In microscopic view, pleomorphic mostly round to oval shaped cells having round to oval nucleus with dense chromatin at nuclear periphery were observed (Figure 2). The cells were mostly haphazardly located. Spindle shaped fibroblastoid cells trying to form weak bundles and few inflammatory cells were recognizable within the tumor mass, which had

patchy zones of scarce collagenous stroma. Moderate levels of anisocytosis and anisokaryosis were notable (Figure 3). Moderate number of giant cells containing 3 to 10 nuclei with mostly peripheral localization was recognizable (Figure 2). Low to high number of mitotic figures depending on the viewed area were recorded (Figure 3).

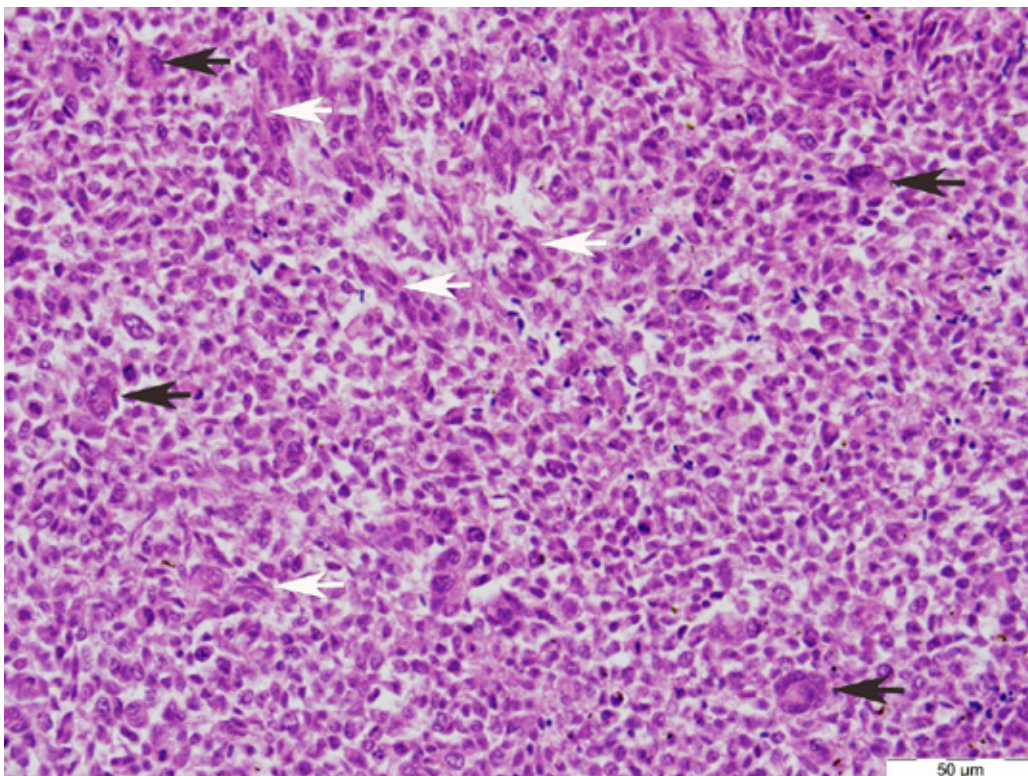


Figure. 2. Microscopic image of the tumor consisting of mostly pleomorphic cells, bands of fibroblastoid cells (white arrows) and giant cells (black arrows), H&E

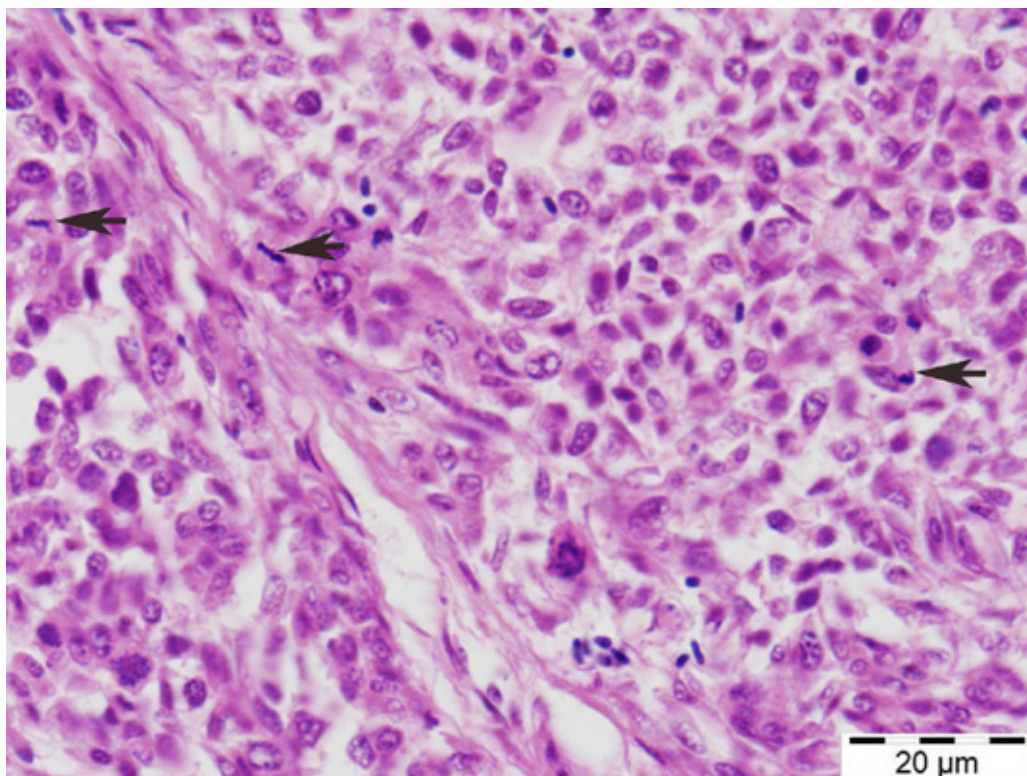


Figure 3. Pleomorphic cells showing anisocytosis and anisokaryosis. Mitotic figures are prominent (arrows), H&E

DISCUSSION

Neoplasia occurs with changing frequencies in companion birds and seems to increase with age as in mammals. A variety of tumors are encountered in these pet birds (Reavill, 2004). Among the pet birds, budgerigars are one of the most common animals that neoplastic lesions detected probably due to the widespread occupancy of this pet as well as better care conditions causing longer lifespan. Cutaneous and subcutaneous lesions happen to comprise a significant place within all tumors in exotic birds (Reavill, 2004). In an investigation, skin tumors were reported to comprise of 57% of all tumors in budgerigars (Sutherland et al., 2016). Among the skin tumors, malignant fibrous histiocytoma is a rare tumor of animals. These tumors are known to be the most common soft tissue sarcomas in humans (Zagars et al., 1996). In domestic animals, MFH is seen most commonly in dogs and occurrence of MFH in birds or poultry animals is quite rare. With this presentation, a case of MFH was described in a budgerigar with its gross and histopathology views as reference to the current knowledge of these tumors.

In domestic animals, MFHs can be viewed in three subtypes namely storiform-pleomorphic, giant cell and inflammatory (Do et al., 2009; Al-Agha and

Igbokwe, 2008; Kiran et al., 2005). However, occurrence of inflammatory subtype in domestic animals remains controversial (Hendrick, 2017). MFHs are generally described as nodular, white to gray firm masses located mostly subcutaneously. However, various organ localizations such as spleen, kidney, liver, lung, lymph nodules and bones were also described in animals (Kerlin and Hendrick, 1996). In this current case, consistent with the general gross appearance and localization, a grey-white firm nodular mass located subcutaneously in the right wing was also recorded. MFHs are known to be quite aggressive and locally invasive tumors and may metastasize to other organs, though tendency to make metastasis may show great variation from case to case (Gibbs et al., 2001). In the current case, as in similar to most MFH cases, no metastasis to other organs were noted and the tumor was a subcutaneously located unencapsulated circumscribed solitary mass.

Histomorphology of MFHs depends on the subtypes, and spindle-shaped cells mixed with histiocytes dominates the tumor mass and mostly shows storiform or whirling pattern (Hendrick, 2017). Inflammatory cells and giant cells can also be present in varying numbers and in some cases depending on the subtype may dominate the field, naming the tu-

mor as inflammatory or giant cell subtype of MFH, respectively. Occasionally, parts of tumor mass may present different views making it difficult to name it as one or the other subtype (Kerlin and Hendrick, 1996). In the current case, pleomorphic cells having mostly round to oval nucleus intermixed with spindle shaped fibroblastoid cells were noted. The tumor cells were mostly located haphazardly, however some forms of storiform pattern was also noted. Occasional inflammatory cells and giant cells containing few nuclei were observed throughout the tumorous mass. Since these cells did not dominate the field, inflammatory and giant cell subtypes for MFH was eliminated. In giant cell type of MFH, mostly osteoclastoid giant cells were described (Ko et al., 2013), and in the present case the giant cells did not show resembles to such giant cells and mostly recognized as giant cells having 3-10 vesicular nuclei that are located peripherally within the abundant eosinophilic cytoplasm. Some larger cells with a single vesicular large nucleus and scarce cytoplasm were also scattered throughout the section. General view of the tumor was greatly consistent with the storiform-pleomorphic subtype of MFH. In human and domestic animals storiform-pleomorphic subtype was also reported to be the most common among MFHs (Schneider et al., 1999; Hendrick, 2017).

Mostly high mitotic index was described in MFHs (Ko et al., 2013), however reports of MFHs with low mitotic index were also present (Kim et al., 2018). In the current case, low to high mitotic figures showing changes in number from field to field were seen in the tumor mass.

The origin of tumor cells in MFHs is mostly unknown or undetermined. Primitive mesenchymal stem cells, fibroblastoid cells and fibroblasts were suggested as the origin of the tumor and histiocytes are accepted as not to be the neoplastic component of the tumor and be only reactive cells (Schneider et al., 1999). Takeya et al. (1995) suggested that these tumors do not contain histiocytes or macrophages and hence pleomorphous sarcoma might be a better term to name them since the mesenchymal cells differentiating toward fibroblasts may promote monocytes yielding the infiltration of macrophages in these tumors. Weak storiform formation and presence of highly pleomorphic cells in the current case may be considered in this concept and the tumor might only be named as pleomorphous sarcoma, however the term is not used commonly.

Immunohistochemistry has been occasionally performed to distinguish the cell types and to determine the origin of cells. Vimentin positivity to show mesenchymal origin has been seen giving only limited information about the tumor. Markers such as CD11, CD18 and CD68 were also used for monocytic-histiocytic origin, however such attempts for differential diagnosis is yet not completely successful (Ko et al., 2013; Hendrick, 2017; Zimmerman et al., 2019). Therefore, immunohistochemistry still provides limited information about these tumors. However, vimentin only positivity without any other specific or distinct expression of cell line markers were suggested as to name the tumor MFH (Ko et al., 2013). Moreover, technical difficulties in immunohistochemical applications on bird tissues also limits the validity of the technique for differential diagnosis in these animals. In these animals, S-100 for epidermal differentiation, pan-cytokeratin for epithelial, vimentin for mesenchymal, desmin for muscle, and NSE for neuronal origin were used in some frequencies (Garner et al., 2009; Zehnder et al., 2016).

In conclusion, a case of MFH detected in a budgerigar was described with this presentation. Gross and microscopic features of the tumor greatly coincided with the storiform-pleomorphic type of MFH. However, the tumor cells showed mostly haphazard localisation instead of storiform appearance. MFHs are accepted to contain both histiocytic and fibroblastic components and the origin of tumor cells remains still controversial.

ACKNOWLEDGMENTS

This study was presented as a poster in 8th National Veterinary Pathology Congress (1-3 September 2016, Samsun-Turkey).

CONFLICT OF INTEREST

The authors declare no conflicts of interest.

REFERENCES

- Al-Agha OM, Igbokwe AA (2008) Malignant fibrous histiocytoma - Between the past and the present. *Arch Pathol Lab Med* 132: 1030-1035.
- Derakhshanfar A, Oloumi MM (2008) Malignant fibrous histiocytoma in a pigeon. *Iran J Vet Surg* 3: 91-95.
- Do SH, Hong IH, Park JK, Ji AR, Kim TH, Kwak DM, Jeong KS (2009) Two different types of malignant fibrous histiocytomas from pet dogs. *J Vet Sci* 10: 169-171.
- Fletcher CDM (1992) Pleomorphic malignant fibrous histiocytoma: Fact or fiction? *Am J Surg Pathol* 16: 213-228.
- Garner MM, Latimer KS, Mickley KA, Ritzman TK, Nordhausen RW (2009) Histologic, Immunohistochemical, and Electron Microscopic Features of a Unique Pulmonary Tumor in Cockatiels (*Nymphicus hollandicus*): Six Cases. *Vet Pathol* 46: 1100-1108.
- Gibbs JF, Huang PP, Lee RJ, McGrath B, Brooks J, McKinley B, Driscoll D, Kraybill WG (2001) Malignant fibrous histiocytoma: An institutional reviews. *Cancer invest* 19: 23-27.
- Gross TL, Ihrke PJ, Walder EJ, Affolter VK (2005) Other mesenchymal tumors. In: *Skin Diseases of the Dog and Cat: Clinical and Histopathologic Diagnosis*. 2nd ed, Blackwell Publishing, Ames, IA: pp 797-812.
- Hendrick MJ (2017) Mesenchymal tumors of the skin and soft tissues. In: Meuten D.J. (ed) *Tumors in Domestic Animals*. Iowa, John Wiley & Sons Inc, USA, pp. 142-175.
- Kerlin RL, Hendrick MJ (1996) Malignant fibrous histiocytoma and malignant histiocytosis in the dog - Convergent or divergent phenotypic differentiation? *Vet Pathol* 33: 713-716.
- Kim JH, Kim HJ, Lee SJ, Yoon HY (2018) Splenic malignant fibrous histiocytoma with concurrent hypertension and epistaxis in an Alaskan malamute dog. *BMC Vet Res* 14: 235.
- Kıran MM, Karaman M, Hatipoglu F, Koc Y (2005) Malignant fibrous histiocytoma in a dog: A case report. *Vet Med Czech* 50: 553-557.
- Ko JS, Kim, HJ, Choi YM, Kim JW, Park C, Do SH (2013) Diagnostic approach to malignant fibrous histiocytomas of soft tissue in dogs: A case report. *Vet Med-Czech* 58: 621-627.
- O'Brien JE, Stout AP (1964) Malignant fibrous xanthomas. *Cancer* 17: 1445-1458.
- Pires MA (1997) Malignant fibrous histiocytoma in a puppy. *Vet Rec* 140: 234-235.
- Reavill DR (2004) Tumors of pet birds. *Vet Clin Exot Anim* 7: 537-560.
- Roffe TJ (1987) An unusual pleomorphic sarcoma in a hybrid mallard. *J Wildl Dis* 23: 334-337.
- Schneider P, Busch U, Meister H, Qasem Q, Wunsch PH (1999) Malignant fibrous histiocytoma (MFH). A comparison of MFH in man and animals. A critical review. *Histol Histopathol* 14: 845-860.
- Sutherland M, Ploeg R, Sacks P, Macwhirter P (2016) Avian lumps and bumps: clinical and histological findings associated with avian tumours, a preliminary review. Association of Avian Veterinarians Australasian Committee Ltd. Annual Conference, Brisbane, Queensland, Australia: pp 37-45.
- Takeya M, Yamashiro S, Yoshimura T, Takahashi K (1995) Immunophenotypic and immunoelectron microscopic characterization of major constituent cells in malignant fibrous histiocytoma using human cell lines and their transplanted tumors in immunodeficient mice. *Lab Invest* 72: 679-688.
- Waters CB, Morrison WB, Denicola DB, Widmer WR, White MR (1994) Giant cell variant of malignant fibrous histiocytoma in dogs: 10 cases (1986-1993). *J Am Vet Med Assoc* 205: 1420-1424.
- Zagars GK, Mullen JR, Pollack A (1996) Malignant fibrous histiocytoma: outcome and prognostic factors following conservation surgery and radiotherapy. *Int J Radiat Oncol Biol Phys* 34: 983-994.
- Zehnder A, Graham J, Reavill DR, McLaughlin A (2016) Neoplastic Diseases in Avian Species. In: *Current Therapy in Avian Medicine and Surgery*. 1st ed, Elsevier Inc, St. Louis, MO: pp 107-141.
- Zimmerman K, Almy F, Saunders G, Crisman M, Leomanrdi L (2019) An unusual case of giant cell tumor of soft parts in an American Warmblood horse. *Open Vet J* 9: 44-48.

Feline Hypertrophic Osteopathy Associated with Congenital Megaesophagus: Two Case Reports and Literature Review

A.M. Abu-Seida*, F.A. Torad, E.A. Hassan, K.M. Ali

Department of Surgery, Anesthesiology and Radiology, Faculty of Veterinary Medicine, Cairo University. Giza, Egypt

ABSTRACT: This report describes two cases of feline hypertrophic osteopathy (HO) associated with congenital megaesophagus (ME). The diagnosis was based upon case history, physical examination, radiography and laboratory investigations. The clinical signs of both cats included; regurgitation, weakness and reluctance to walk since birth. Physical examination revealed painful and thickened long bones, swollen joints, difficult flexion of all four limbs and normal urination, defecation, appetite as well as heart and respiratory rates. The abnormal laboratory findings were thrombocytosis, leukocytosis with lymphocytosis and monocytosis. Survey and contrast thoracic radiography showed generalized esophageal dilatation. Radiography of appendicular skeleton revealed symmetrical and massive subperiosteal new bone formation of the affected long bones and pelvis. In conclusion, radiography of extremities is highly recommended for cats admitted with congenital ME and lameness to investigate the possibility of HO. Moreover, the HO should be listed during the differential diagnosis of thickened limbs in cats.

Keywords: Domestic shorthair cat, Hypertrophic osteopathy, Lameness, Megaesophagus, Periosteal proliferation.

Corresponding Author:

Ashraf M. Abu-Seida, Department of Surgery, Anesthesiology & Radiology, Faculty of Veterinary Medicine, Cairo University, PO 12211, Giza, Egypt
E-mail address: ashrafseida@cu.edu.eg, ashrafseida@yahoo.com

Date of initial submission: 05-01-2020
Date of revised submission: 25-02-2020
Date of acceptance: 07-03-2020

INTRODUCTION

Congenital megaesophagus (ME) or esophageal hypomotility is a rare disease in cats affecting mostly Siamese cats (Hoenig et al., 1990). Acquired ME can be seen in all cat breeds. It is characterized by a decreased or absent esophageal motility. The most common clinical signs include; poor body condition, weight loss, regurgitation, changes in eating habits and difficulty in swallowing. Respiratory distress, aspiration pneumonia, excessive salivation, halitosis, coughing, nasal discharge and fever are the most common complications of ME (Forbes and Leishman, 1985). Megaesophagus may be congenital, due to ill-developed signaling pathway of the esophagus, acquired due to numerous causes (Hoenig et al., 1990).

Hypertrophic osteopathy (HO) is a diffuse periosteal proliferative disease particularly affecting the appendicular long bones (Hime et al., 1972). Most of the reported cases of HO are secondary to pulmonary or abdominal neoplasms or inflammatory disease of unknown pathogenesis (Rohr 2003; Johnson and Lenz, 2011).

According to the available literature, several cases of feline HO have been reported over the years (1971-2019) as a secondary to several disorders disease such as pulmonary, digestive and renal lesions as well as kidney, adrenal gland and injection site neoplasms as shown in table (1). Moreover, four reports of idiopathic HO have been recorded (Table 1). The prognosis of HO in cats is poor as most of the recorded cases were died shortly afterwards (Richards, 1977; Gram et al., 1990)

or euthanized at the owner's request at the time of diagnosis (Carr, 1971; Roberg, 1977; de Melo et al., 2006; Guizelini et al., 2019). However, medical and surgical treatments were successful six months after their initiation in few cases of HO (Becker et al., 1999; Grierson et al., 2003; Huang et al., 2010; Mills 2010).

In addition, HO has been previously reported in canine, equine, bovine, wild animals and human secondary to thoracic neoplasms, sarcoma of the urinary bladder, bacterial endocarditis and infection by *Spirocerca lupi* or *Dirofilaria immitis* (Brodey 1971; Ndikwere and Hill, 1989; Masegi et al., 1994; Mair et al., 1996, Hassan et al., 2019).

Secondary HO is presented with lameness, long-bone pain and symptoms from the primary thoracic or abdominal lesions. The diagnosis of such cases is based upon radiography that detects the primary lesions and hypertrophic changes of long bones (Nafe et al., 1981; Gram et al., 1990; Rohr, 2003). Computed tomography (Johnson and Lenz, 2011), Magnetic Resonance Imaging (Salguero et al., 2015) and histopathology (Grierson et al., 2003; Salguero et al., 2015) have also been used in the diagnosis of HO in cats.

Nutritional and supportive treatment such as suitable fluid therapy and electrolyte correction according to the abnormalities in laboratory test results were recommended for treatment of feline HO (Huang et al., 2010).

This study aims to present two cases of feline congenital megaesophagus associated with HO.

Table 1. The primary lesions and prognosis of the recorded feline hypertrophic osteopathy

Primary lesion	No of cases	Outcome	References
Pulmonary lesion	One	Euthanized at the time of diagnosis	Carr (1971)
Pulmonary neoplasia	One	Died shortly afterwards	Richards (1977)
Pulmonary neoplasia	One	Euthanized at the time of diagnosis	Roberg (1977)
Renal papillary adenoma	One	Euthanized at the time of diagnosis	Nafe et al. (1981)
Pulmonary carcinoma	One	Died shortly afterwards	Gram et al. (1990)
Adrenocortical carcinoma	One	Recovered after 4 months of surgery	Becker et al. (1999)
Pulmonary sarcoma	One	Recovered after 6 months of surgery	Grierson et al. (2003)
Pulmonary lesion	One	Died shortly afterwards	Rohr (2003)
Megaesophagus	One	Recovered after medical therapy	Mills (2010)
Renal adenoma	One	Euthanized at the time of diagnosis	Johnson and Lenz (2011)
Injection-site sarcoma	One	Euthanized at the time of diagnosis	Salguero et al. (2015)
Cardiac interventricular septal defect	One	Euthanized at the time of diagnosis	De Sousa et al. (2019)
Idiopathic	Seven	6 cats recovered after medical therapy and one died shortly afterwards	Huang et al. (2010)
Idiopathic	One	Euthanized at the time of diagnosis	De Melo et al. (2006)
Idiopathic	One	Euthanized at the time of diagnosis	Ocarino et al. (2006)
Idiopathic	One	Euthanized at the time of diagnosis	Guizelini et al. (2019)

CASE HISTORY OF THE FIRST CAT

A 3-month-old female intact domestic shorthair kitten was admitted to the surgery clinic at Faculty of Veterinary Medicine, Cairo University, Egypt with a history of intermittent regurgitation since birth, stiffness and weakness (Fig 1). The case history revealed

that the kitten was an orphan stray animal and fed on cat milk until weaning at the age of 2 months. The appetite remained normal despite the intermittent regurgitation and defecation and urination pattern was unremarkable.

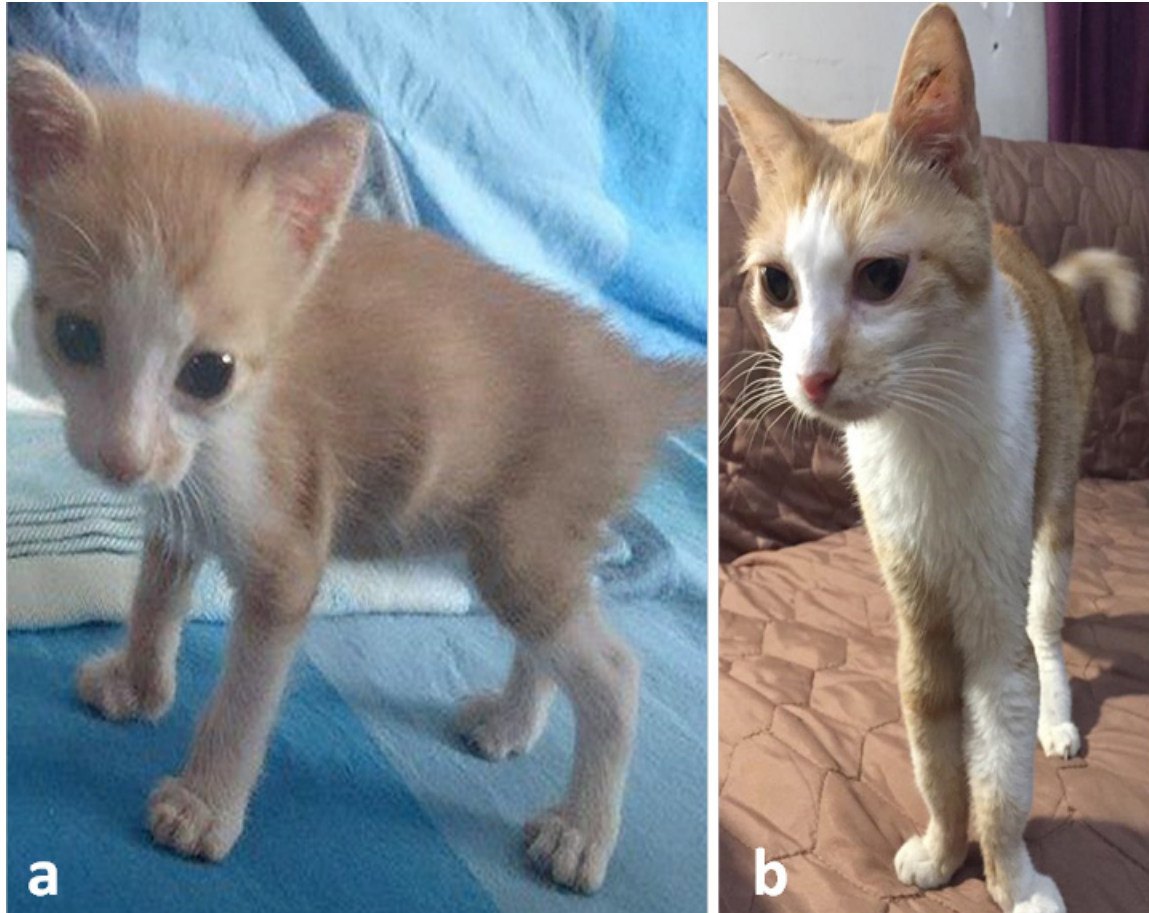

Figure 1. (a) A 3-month-old female domestic shorthair kitten with megaesophagus and hypertrophic osteopathy showing poor body condition and slight thickening of both forearms. (b) The same cat at the age of 4 years showing marked thickening of the limbs.

The kitten had also dental malocclusion, changes in eating habits, stiffness and poor condition at the age of 3 months. A thorough physical examination was unremarkable. Symptomatic and supportive therapeutic measures for presumed gastritis were initially performed in the form of intravenous injections of Dextrose 5% solution as boluses (40 mL daily) and 0.3 mg/kg of metoclopramide (Primperan®, Sanofi Aventis) as an antiemetic drug twice daily for 3 days. Three months after initial presentation, the kitten with poor body condition was readmitted for intermittent regurgitation. Plain lateral thoracic radiography and positive contrast esophagography with barium sulfate paste (E-Z-Paste® Barium sulphate esophageal cream (60% w/w), Bracco Diagnostics Inc., USA) dosed as

5–10 mL oral bolus together with the previous case history confirmed severe generalized congenital megaesophagus (Fig 2). The owner was advised to administer a liquid diet from an elevated position and hold the kitten in upright position after each meal. Over the following months, the general clinical status improved yet occasional regurgitation still occurred.

At the age of one year, the cat was re-admitted for investigation of weakness, thickening of all four limbs, reluctance to walk, stiffness in gait and occasional regurgitation. Palpation of the long bones elicited slight pain and showed hard thickening of the humerus, radius, ulna, femur, tibia and fibula. Flexion of all limbs was difficult, particularly the forelimbs.

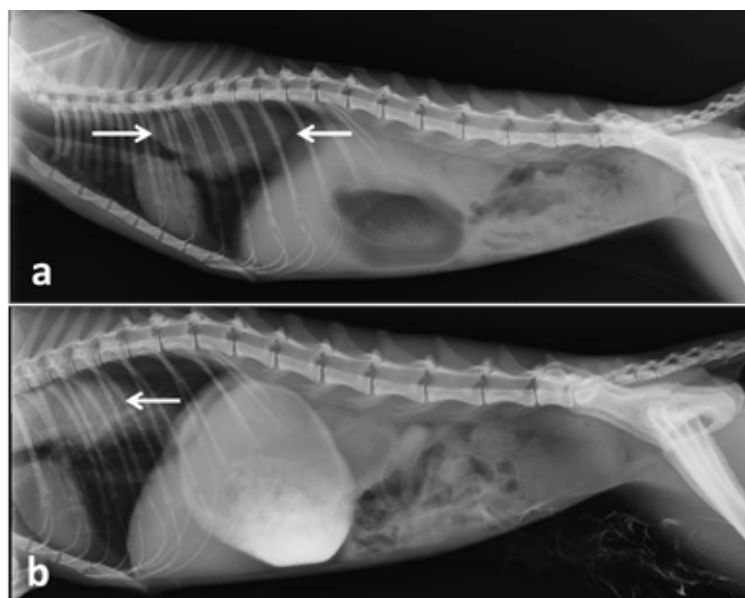


Figure 2. (a) Lateral plain and positive contrast (b) thoracic radiographs of the same cat in figure (1) showing severe esophageal dilatation (White arrows).

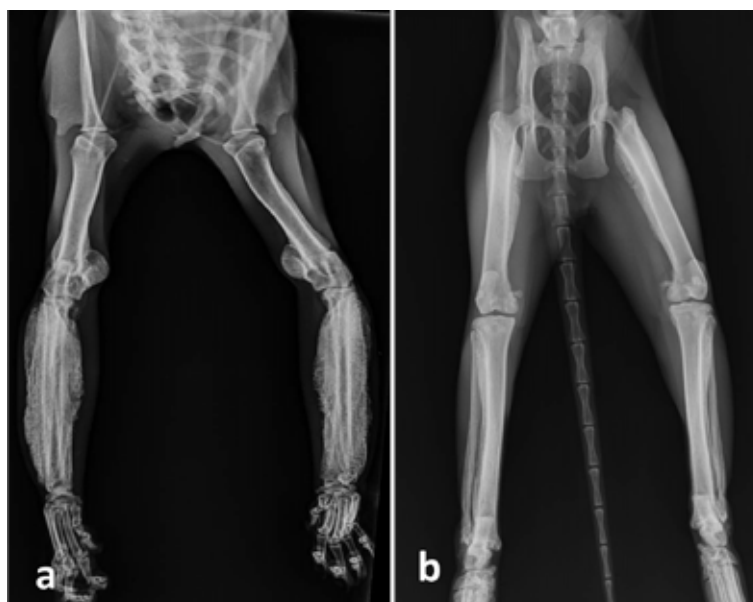


Figure 3. (a) Ventrodorsal radiographs of both forelimbs and hindlimbs (b) of the same cat in figure (1) showing marked periosteal proliferation particularly on the radius, ulna and femur bones.

Routine complete blood count (CBC) revealed thrombocytosis ($915 \times 10^3/\mu\text{L}$, reference interval [RI]: $300-800 \times 10^3/\mu\text{L}$), leukocytosis ($25.3 \times 10^3/\mu\text{L}$, RI: $5.5-19.51 \times 10^3/\mu\text{L}$) with lymphocytosis ($9.5 \times 10^3/\mu\text{L}$, RI: $1.5-7 \times 10^3/\mu\text{L}$) and monocytosis ($1.3 \times 10^3/\mu\text{L}$, RI: $0.0-0.9 \times 10^3/\mu\text{L}$). Radiographic examinations of the appendicular skeleton showed extensive subperiosteal new bone proliferation suggesting HO. Radiographic changes included intense and symmetric formation of new subperiosteal bone through all diaphyses and metaphyses of the affected bones (Fig 3). The new bone formation had uniform opacity and a 'palisading' pat-

tern in some areas. The most affected bones were radius, ulna and femur in both limbs. Interestingly, the new bone formation was more clearly seen in forelimbs than hind limbs. Oral treatment with meloxicam 0.1 mg q24h (Metacam; Boehringer Ingelheim, Germany) was given for pain control.

The animal's weight was 2 kg, 2.6 kg, 2.7 kg, 2.2 kg and 2.5 kg at the age of 6, 12, 18, 30 and 48 months, respectively. After puberty, the cat exhibited abnormal and scarce estrus cycle that lasted for 2-3 days without any obvious signs. CBC was carried out

again at the age of 2.5 and 3 years and revealed the same previous abnormal findings.

Serum biochemistry tests including albumin, creatinine, urea, alkaline phosphatase, alanine aminotransferase, aspartate aminotransferase and g-glutamyltransferase tests revealed high urea level, 49 mg/dL (reference range 10-30 mg/dL) as the only abnormality. Serum creatinine was 0.9 mg/dL (reference range <1.6 mg/dL). Urinalysis was unremarkable with inactive sediment. Until this writing (Four years after the initial presentation), in periodic follow up examinations, the cat remains in stable condition, presenting occasional regurgitation episodes.

CASE HISTORY OF THE SECOND CAT

A one-year-old female intact domestic shorthair cat was admitted with a history of intermittent regurgitation, thickened limbs, weakness and reluctance to walk. Physical examination was unremarkable. Palpation of the limbs showed hard thickening of all four

limbs with slight pain. Plain lateral thoracic radiography and positive contrast esophagography (E-Z-Paste® Barium sulphate esophageal cream (60% w/w), Bracco Diagnostics Inc., USA) dosed as 5–10 mL oral boluses revealed dilated esophagus. Radiographic examination of all limbs showed periosteal proliferation in humeri, femurs and tibiae (Fig 4). It was not known how long periosteal proliferation had been present prior to initial presentation. Feline hypertrophic osteopathy associated with congenital megaesophagus was confirmed. The owner was advised to feed the cat 5-6 times daily small amounts of liquid diets (such as; beef/chicken broth, baby cereals, blend soft cat food with broth or commercial feline liquid diets) from a high position that resulted in marked improvement in the regurgitation episodes.

The owners of both cases refused any surgical treatment (Percutaneous endoscopic gastrostomy tube placement or esophagectomy) for megaesophagus and we could not follow up the second case.

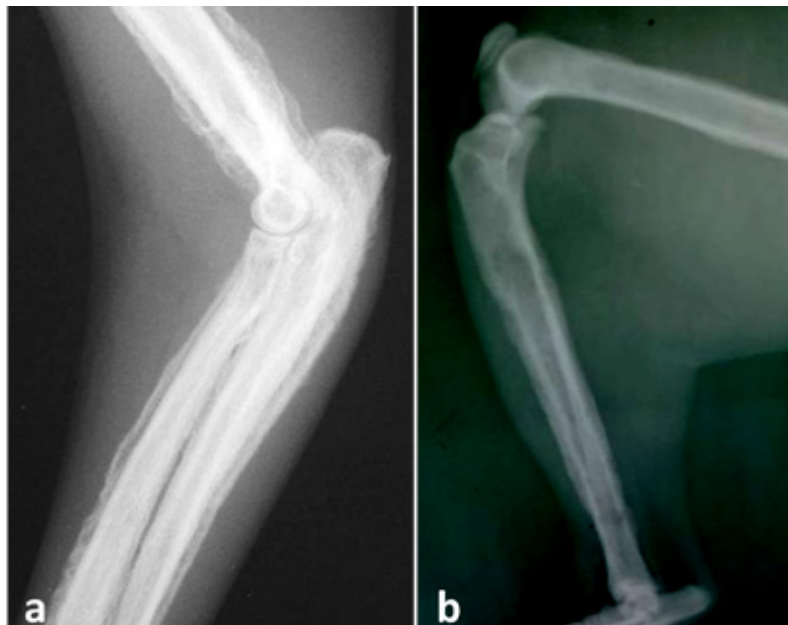


Figure 4. (a) Latero-medial radiographs of a one-year-old female domestic shorthair cat showing marked periosteal proliferation in humerus, radius and ulna in the forelimb as well as femur and tibia in hindlimb (b).

DISCUSSION

Hypertrophic osteopathy also known as Marie's disease is a rare disease of uncertain pathogenesis in cats (Langley-Hobbs, 2012). Several suggestions have been mentioned such as periosteal irritation by circulating toxins originated from the primary disease, disturbance in peripheral blood flow to the limbs, neurogenic stimuli, vagal and intercostal nerves stimulations, distal vascular production of platelet-derived

growth factor and vascular endothelial growth factor (Richards, 1977; Gram et al., 1990; Salguero et al., 2015). In our recorded cases, the pathogenesis of HO development due to ME was not determined; however, one or more of the aforementioned theories could have contributed. The increase of blood flow to the limbs is one of the most important factors responsible for development of bone lesions. According to the neuron theory, ME may stimulate the vagus nerve

and increase the peripheral blood flow with less tissue oxygen stimulating periosteal proliferation (Roberg, 1977; de Melo et al., 2006; Huang et al., 2010). In addition, we couldn't exclude the possibility of simultaneous independent occurrence of idiopathic HO and congenital ME in the recorded cases. Both idiopathic HO and HO secondary to ME were previously reported in cats as shown in table (1). We recommend further studies to identify the exact association between HO and ME in cats.

The recorded cases in this report were young adult female cats. No age, breed or sex predisposition has been reported in literature so far (Huang et al., 2010).

The weakness, poor body condition and reluctance to walk were attributed to deficient nutrition as a result of the intermittent regurgitation. Moreover, the pain, difficult flexion, enlarged joints and hard thickening of all four limbs could be attributed to the massive subperiosteal new bone proliferation. Regurgitation is the most common clinical sign noted with ME. Frequency and timing of regurgitation after feeding may vary considerably. The hematological abnormalities presented by the cats were compatible with those reported in the literature (Ocarino et al., 2006; Salgüero

et al., 2015).

Medical treatment of ME includes small, frequent meals from an upright position in order to facilitate passage of the food through the esophagus into the stomach. The decrease in the frequency of regurgitation in our recorded cases could be attributed to the improvement of esophageal function with age due to maturation of the esophageal neuromuscular system after the first year of age. Similar findings were recorded in dogs (Brodey, 1971).

Resolution of the HO after surgical removal of the primary lesion has been reported in several studies (Becker et al., 1999; Grierson et al., 2003; Mills, 2010). Although medical treatment of ME decreased regurgitation episodes in both recorded cases, it did not improve HO. This may be due to severity of both cases and the absence of complete resolution of ME in both cats.

CONFLICT OF INTEREST

The authors declare no conflict of interests regarding publishing of this article.

REFERENCES

- Becker TJ, Perry RL and Watson GL (1999) Regression of hypertrophic osteopathy in a cat after surgical excision of an adrenocortical carcinoma. *J Am Anim Hosp Assoc* 35, 499-505.
- Brodey RS (1971) Hypertrophic osteoarthropathy in the dog: a clinicopathologic survey of 60 cases. *J Am Vet Med Assoc* 159, 1242-1256.
- Carr SH (1971) Secondary hypertrophic pulmonary osteoarthropathy in a cat. *Feline Pract* 1, 25-26.
- de Melo ON, Fukushima FB, Gomes A, Bueno DF, Oliveira TS and Serakides R (2006) Idiopathic hypertrophic osteopathy in a cat. *J Feline Med Surg* 8, 345-348.
- de Sousa FAB, Bianchi MV, Taunde PA, Bandinelli MB, Fett RR, Driemeier D, Pavarini SP (2019) Hypertrophic osteopathy in a cat with cardiac interventricular septal defect. *J Vet Sci* 20, e52.
- Forbes DC and Leishman, DE (1985) Megaesophagus in a Cat. *Can Vet J* 26, 354-356.
- Gram WD, Wheaton LG, Snyder PW, Losonsky JM and Whiteley E (1990) Feline hypertrophic osteopathy associated with pulmonary carcinoma. *J Am Anim Hosp Assoc* 26, 425-428.
- Grierson JM, Burton CA and Brearley MJ (2003) Hypertrophic osteopathy secondary to pulmonary sarcoma in a cat. *Vet Comp Oncol* 1, 227-231.
- Guizelini C, Mattei DR, Pupin RC, Martins TB, and Gomes DC (2019) Hypertrophic Osteopathy in a Cat. *Acta Sci Vet* 47 (Suppl 1), 373.
- Hassan E, Torad FA, Abu-seida AM and Hassan A (2019) Mandibular hypertrophic osteodystrophy fibrosa in a German shepherd puppy. *Kafkas Univ Vet Fak Derg* 25, 883-886.
- Hime JM, Keymer IF and Appleby EC (1972) Hypertrophic pulmonary osteoarthropathy in an Orang-Utan (*Pongopygmaeus*). *Vet Rec* 91, 334-337.
- Hoenig M, Mahaffey MB, Parnell PG, Styles ME (1990) Megaesophagus in two cats. *J Am Vet Med Assoc* 196, 763-765.
- Huang CH, Jeng CR, Lin CT and Yeh LS (2010) Feline hypertrophic osteopathy: a collection of seven cases in Taiwan. *J Am Anim Hosp Assoc* 46, 346-352.
- Johnson R and Lenz S (2011) Hypertrophic Osteopathy Associated with a Renal Adenoma in a Cat. *J Vet Diagn Invest* 23, 171-175.
- Langley-Hobbs S (2012) Musculoskeletal oddities in the cat. An overview of some curious causes of lameness. *J Feline Med Surg* 14, 31-42.
- Mair TS, Dyson SJ, Fraser JA, Edwards GB, Hillyer MH and Love S (1996) Hypertrophic osteopathy (Marie's disease) in Equidae: a review of twenty-four cases. *Equine Vet J* 28, 256-262.
- Masegi T, Yani T, Sakai T, Matsumoto C, Yamazoe K, Nukaya A, Kunimune Y and Ueda K (1994) Hypertrophic pulmonary osteoarthropathy in a raccoon dog (*Nyctereutes procyonoides*) with chronic pulmonary inflammatory lesions. *J Wildl Dis* 30, 612-615.
- Mills J (2010) Hypertrophic osteopathy and megaesophagus in a cat. *Vet Comp Orthop and Traum* 23, 218-222.
- Nafe LA, Herron AJ and Burk RL (1981) Hypertrophic osteopathy in a cat associated with renal papillary adenoma. *J Am Anim Hosp Assoc* 17, 659-662.
- Ndikuwere J and Hill FWG (1989) Hypertrophic osteopathy in a dog associated with bronchopneumonia. *Zimbabwe Vet J* 20, 23-27.
- Ocarino M, Fukushima MB, Gomes AM, Bueno DF, Oliveira TS, Serakides R (2006) Idiopathic hypertrophic osteopathy in a cat. *J Feline Med Surg* 8, 345-348.
- Richards CD (1977) Hypertrophic osteopathy in a cat. *Feline Pract* 7, 41-43.
- Roberg J (1977) Hypertrophic Pulmonary Osteoarthropathy. *Feline Pract* 7, 18-22.
- Rohr S (2003) Pulmonary origin feline hypertrophic osteopathy. *Point Vet* 34, 62-64.
- Salgüero R, Demetriou J, Constantino-Casas F and Herrtage M (2015) Hypertrophic osteopathy in a cat with a concurrent injection-site sarcoma. *J Feline Med Surg Open Rep* 1: 2055116915593968.

JOURNAL OF THE HELLENIC VETERINARY MEDICAL SOCIETY

ΠΕΡΙΟΔΙΚΟ ΤΗΣ ΕΛΛΗΝΙΚΗΣ ΚΤΗΝΙΑΤΡΙΚΗΣ ΕΤΑΙΡΕΙΑΣ

Quarterly Edition
Volume 71, No 3
JULY - SEPTEMBER 2020



Τριμηνιαία Έκδοση
Τόμος 71, Νο 3
ΙΟΥΛΙΟΣ - ΣΕΠΤΕΜΒΡΙΟΣ 2020