

Journal of the Hellenic Veterinary Medical Society

Vol 73, No 2 (2022)



A Comparison of Clinical and Radiological Outcomes of Different Anatomical Regions Plate osteosynthesis in Cats with Body of Ilium Fractures

Mustafa Arıcan, N Zamirbekova, EO Uzunlu, B Ozdil, F Gümüş

doi: [10.12681/jhvms.25653](https://doi.org/10.12681/jhvms.25653)

Copyright © 2022, Mustafa Arıcan



This work is licensed under a [Creative Commons Attribution-NonCommercial 4.0](https://creativecommons.org/licenses/by-nc/4.0/).

To cite this article:

Arıcan, M., Zamirbekova, N., Uzunlu, E., Ozdil, B., & Gümüş, F. (2022). A Comparison of Clinical and Radiological Outcomes of Different Anatomical Regions Plate osteosynthesis in Cats with Body of Ilium Fractures. *Journal of the Hellenic Veterinary Medical Society*, 73(2), 3979–3988. <https://doi.org/10.12681/jhvms.25653>

A Retrospective Comparison of Clinical and Radiological Outcomes of *Plate Osteosynthesis* in Cats with Iliac Body Fractures

M. Arıcan^{1*}, N. Zamirbekova¹, E.O.Uzunlu¹, B. Ozdil¹, F. Gümüş²

¹University of Selçuk, Faculty of Veterinary Medicine, Department of Surgery, Konya, Turkey

²University of Aksaray, Faculty of Veterinary Medicine, Department of Surgery, Aksaray, Turkey

ABSTRACT: Pelvic fractures are one of the most common orthopedic problems that cause serious injuries in cats, making up 20 to 32% of all feline fractures. Fractures of the ilium constitute 18 to 46% of pelvic fractures. In this study, the post-operative clinical and radiological results of dorsal, ventral and lateral aspects of the body of the ilium in cats with iliac fractures were evaluated.

Twenty-three cats of different breeds, ages and sexes with iliac fractures and occasionally fractures of acetabular, ischial fractures and sacro-iliac joint luxation, were used as subject. History, clinical and neurological examinations of patients were undertaken, and three groups were formed for this study. Group 1 consisted of seven cases with the plate placed in the dorsal aspect of the ilium, group 2 consisted of seven cases with the plate placed on the lateral aspect of the ilium and in group 3, six cases had plates placed on the ventral aspect of the ilium. Surgery was performed under general anesthesia and either a Locking-Decompression Plate (LC-DCP) or a reconstruction plate was used for fixation. 85.7% with a full recovery rate of the cases. There was neither narrowing in the pelvic canal nor screw loosening in cases where the plate was applied dorsally and ventrally. In one case (14.3%), there was narrowing in the pelvic canal after lateral application. No difference was observed between the clinical and radiological results of placing LC-DCP or reconstruction plates on the dorsal, lateral, and ventral aspect of the bone in the post-operative period, and screw loosening did not occur.

Case selection is important in the choice, when considering lateral, dorsal, or ventral plate application in iliac fractures. If the original injury was more than five to six days before surgery, double plate application provided a better clinical prognosis. Dorsal plate application provided better surgical access when compared to ventral application. Lateral application should be used if the fracture line is close to the acetabulum.

Keywords: Cat, Iliac body fracture, Pelvic fracture

Corresponding Author:

Mustafa Arıcan, Department of Surgery, Faculty of Veterinary Medicine,
The University of Selçuk Konya, Turkey
E-mail address: marıcan@selcuk.edu.tr

Date of initial submission: 26-12-2020
Date of acceptance: 30-01-2022

INTRODUCTION

Pelvic fractures are common in cats. In the past, six weeks of cage rest was recommended to avoid surgical intervention for pelvic fractures, but after evaluating the outcomes of such management, it has been determined that a better outcomes for the cat will occur with surgical intervention (Grierson, 2019). One retrospective study found that the ilium was fractured in up to 50% of cats who suffered serious injuries and another study reported an incidence of 38% 13 out of 34 cats with pelvic injuries (Lanz, 2002). Pelvic fractures in cats and dogs are one of the most common orthopedic problems that cause serious injuries, making up between 20 to 32% of total feline fracture cases (Lanz, 2002). Iliac body fractures constitute 18 to 46% of pelvic fractures (Breshears et al. 2004). In a study of 103 cats with pelvic fractures, those occurred in the ventral of the pelvis in 90%, the ilium in 60% and sacroiliac luxation occurred in 48.5% of the cases (Bookbinder and Flanders, 1992, Lanz, 2002). Iliac body fractures are generally oblique and acetabular, ischial and pubic fractures can occur simultaneously (Lanz, 2002). Dislocation of the fragments towards the pelvic canal may result in constipation and megacolon due to narrowing of the pelvic canal and therefore assessment is part of the evaluation criteria of pelvic fractures. Total colectomy may be required together with the osteotomy of the pelvis to address pelvic canal narrowing (Matthiesen et al., 1991; Schrader, 1992; Rosin, 1993). Peripheral nerve injuries were reported in 11% of cases with iliac fractures in dogs and cats (Jacobsen & Schrader, 1987; Tomlinson, 2003) and craniomedial displacement of fracture fragments may cause *sciatic nerve* injury (De Camp, 1992).

Surgical intervention provides pain reduction and a more rapid recovery (Denny, 1978). The surgical approach to cases and the stabilization techniques in cats with pelvic fractures have been extrapolated from the experience of similar surgical procedures in dogs (Lanz, 2002). In the decision-making criteria for surgery, attention is paid to the time interval since the injury, whether the fractures affect the weight-bearing axis, the presence of neurological damage, the degree of constriction of the pelvis and the level of pain. If ischial, iliac and pubic fractures exist simultaneously, a complete physical examination should be performed because bladder and urethral rupture and peripheral nerve damage are common.

Kirschner wires, screws, interfragmentary cerclage, plate application or a combination of these techniques

have been suggested as fixation methods for iliac fractures (Vangundy et al. 1988). The application of the plate on the ventral region of the pelvis and lag screw fixation are less popular (Vangundy et al. 1988; Dyce et al. 2009).

In this study, the post-operative clinical and radiological results dorsal, ventral or lateral plate application on the ilium of cats with iliac fractures were evaluated and compared.

MATERIAL AND METHODS

Twenty-three cats of different breeds, ages, and sex with iliac or multiple pelvic fractures, including sacro-iliac luxation and acetabular or ischial fractures, were included in the study. History, clinical and neurological examinations of patients were recorded. For all cats preoperative clinical and neurological examination (including ischiatic, patellar and cranial tibial reflexes) was performed, and radiographs (SIE-MENS Model 4803388) were taken. Cats with intrathoracic or urinary damage were stabilized before surgery. Two mm locking compression plates (LCP; Travmavet, Safir Antalya) or 1.5 mm/ 2.0 mm reconstruction plates were used. The study design followed the published guidelines and was approved by the institutional Animal Care and Use Committee of the Faculty of Veterinary Medicine, University of Selçuk (2019/11).

The cats with iliac body fractures were dividing the groups according to plate location into three groups. Group 1 consisted of seven cases (Figure 4) where the plate was placed on the dorsal aspect of the iliac body. Group 2 consisted of seven cases where the plate was placed on the lateral aspect of the body of the ilium and in Group 3, six cases (Figure 2 b) had the plate placed on the ventral aspect of the ilium. When the fracture reduction was difficult due extreme dislocation of the fragments or chronicity of the fracture, double plating was performed (dorsal and lateral).

The cats were fasted for 12 hours before anesthesia. The surgical procedures were performed under general anesthesia. For sedation, 80 µg/kg IM (Domitor®, Orion Pharma, Finland), butorphanol 0.4 mg/kg SC (Butomidor® 10mg/ml, Richter-Pharma, Austria) and ketamine 5 mg/kg IM (Ketasol®, Richer-Pharma) was used for preoperative analgesia. Propofol (Propofol-Lipuro 1%, B Braun) at 1.5 to 3 mg/kg was administered intravenously for induction the patient was intubated and maintained on isoflurane (Isoflurane 100 ml, Adeka Drug Turkey).

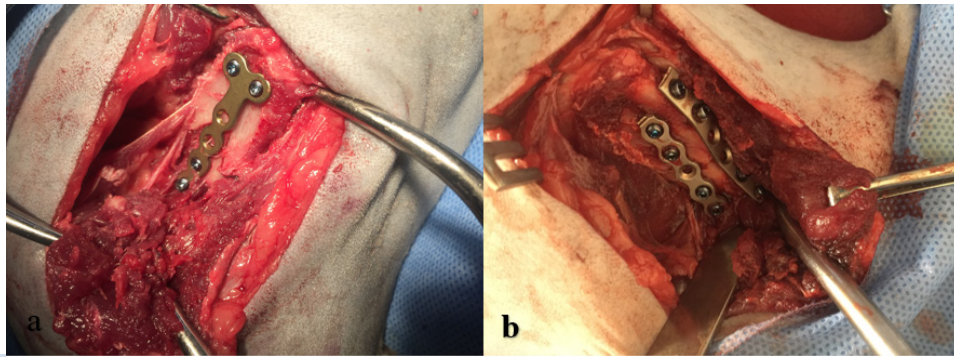


Figure 1. a) Placement of an 1.5mm six-hole T-shaped LC-DCP plate on the lateral side of the iliac body b) Insertion of a six-hole 1.5mm LC-DCP plate on the lateral side of the iliac body, and a 2.0mm six-hole LC-DCP on the dorsal side

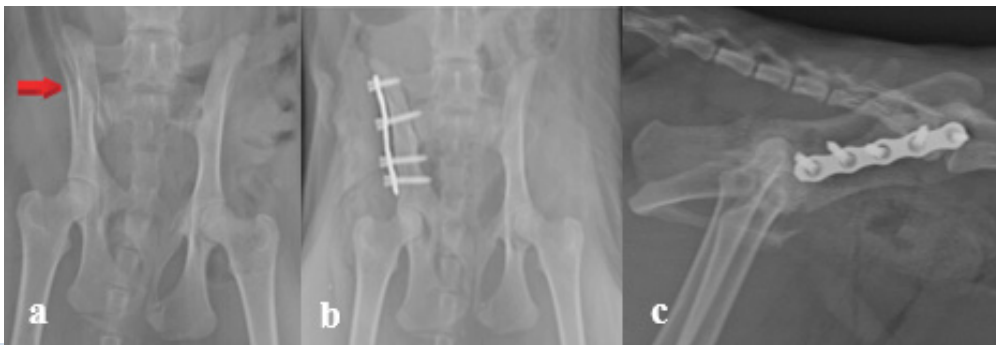


Figure 2. a) Oblique fracture of the iliac body in the pre-operative ventrodorsal radiograph b) ventrodorsal radiograph taken after plate application on the lateral aspect of the corpus ilii. c) Lateral postoperative radiograph of the same case after lateral plate application

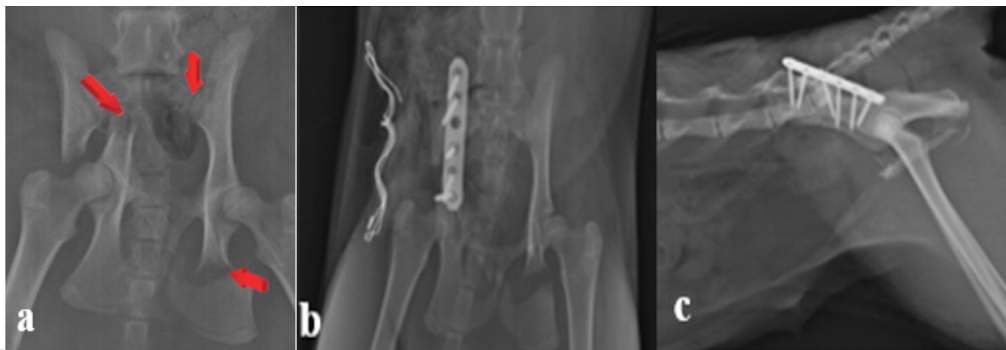

Figure 3. a) Transverse fracture of the ilium and ischium in a preoperative ventrodorsal radiograph b) The ventrodorsal radiograph image taken immediately postoperative after dorsal plate application c) The postoperative lateral radiograph of this case taken after dorsal plate application

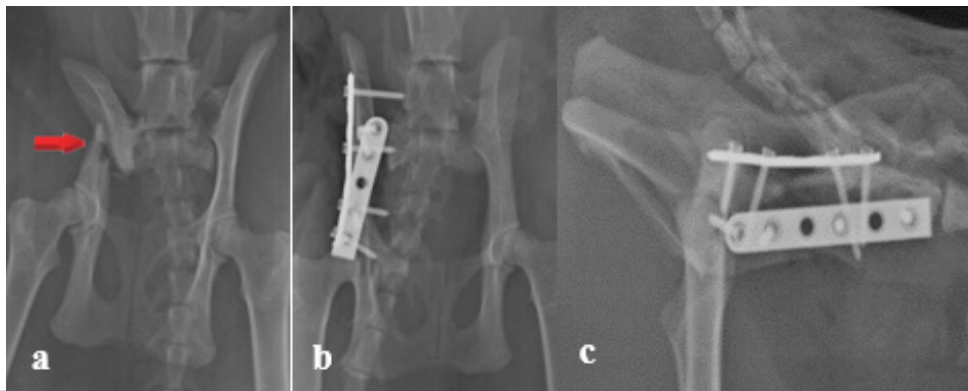


Figure 4. a) Oblique fracture of the iliac body shown in the preoperative ventrodorsal radiographic view. b) The ventrodorsal postoperative radiograph of the case c) Lateral radiographic postoperative view on after dorsal and lateral applications

Surgical Procedure

Dorsal Approach

The skin incision begun cranially over the dorsal cranial crest and cranial dorsal iliac spine and continued caudally parallel to the spine, up to the hip joint. Subcutaneous tissue and pelvic fat were incised to expose the iliac crest. The periosteal origin of the middle gluteal muscle on the lateral ridge of the iliac crest was incised, followed by a second incision through the periosteal origin of the sacrospinalis muscle on the medial ridge of the iliac crest, with the incisions merged caudally. Incision of the lumbar fascia allowed lateral reflection of the ilium and exposure of the sacroiliac joint, which was exposed dorsally. After reaching the body of the ilium, the fracture ends were repositioned and a four- to six-hole 2.0 mm thick reconstruction or LC-DCP plate with two or three 1.5 or 2.0 mm screws were placed on the dorsal surface of each fragment.

Lateral Approach

The animal was placed in lateral recumbency. The skin incision started from the center of the iliac crest and ended right caudal and distal to the trochanter major. The intermuscular septum was visualized between the superficial gluteal and the short part of the tensor fasciae latae muscle caudally. The incision was continued to separate the tensor fascia latae and middle gluteal muscle cranially and tensor fascia latae and superficial gluteal muscles caudally. The ilium was exposed by dissection between the middle and deep gluteal muscle was elevated to expose the fracture. The insertion of the gluteal muscles from the iliac wing were incised for additional exposure. This approach allowed access to the ilial wing and the body of the ilium and ended at the cranial aspect of the acetabulum. In case of caudal ilial fractures, that extend dorsal to the acetabulum, a lateral approach was combined with a dorsal surgical approach to the coxofemoral. A pre-contoured four-to six-hole reconstruction or a LC-DCP plate of different length plate was first

Table 1. Clinical, neurological and radiographic findings of cats undergoing dorsal plate osteosynthesis in ilium body fractures

Case	Radiographic Findings of the Pelvis	Neurologic Findings	Thorax findings	Operation Approach	Complications	Prognosis
1	Right iliac body and left ischium fracture.	-	-	A 1.5 mm LC-DCP plate, 3 2.0 / 12 mm locking screws, 2 2.0 / 10 mm locking screws was fixed dorsally to iliac body fracture.	Constipation	Good
2	Left sacroiliac luxation, iliac body fracture, left pubis and ischium fracture.	No urinary incontinence, paraplegia, no tail movements	HTx	Dorsal 1.5 mm reconstruction plate was fixed with 2.0 / 10 mm locking screws	Necrosis of the skin due to infection, Plate were removed.	Fair
3	Right iliac fracture, sacroiliac luxation	Urinary incontinence	PTx	Sacroiliac luxation, 2.0 / 14 mm lack screw and lateral, 1.5 mm reconstruction plate	-	Good
4	Left iliac body fracture	-	-	Dorsal of iliac body with 6 holes LC-DCP 2.0 mm plate with 6 locking screws of 2.00 / 12 mm.	-	Good
5	Left iliac body and ischium fracture	Left paralysis	-	Dorsally fixed with a 2.00 mm 6-hole LC-DCP plate and 4 locking screws of 2.00 / 12mm.	-	Good
6	Right iliac body, pubis and acetabulum fracture	-	-	Iliac body fracture was fixed dorsally with a 2.00 mm 4-hole LC-DCP plate and 4 locking screws of 2.00 / 12mm.	-	Good
7	Right iliac body fracture	-	HTx	Dorsal 2.00 mm 6-hole LC-DCP plate and 4 2.00 / 12mm locking screws,	-	Good

Table 2. Clinical, neurological and radiographic findings of cats undergoing lateral plate osteosynthesis in ilium body fractures

Case	Radiographic Findings of the Pelvis	Neurologic Findings	Thorax findings	Operation Applied	Complications	Prognosis
1	Right iliac body and left femur fracture	No tail movements, paralysis of right hind. improvement in tail movements and walking	-	Lateral 1.5 mm reconstruction plate and 5 2.0 / 12 mm locking screws	Constipation	Good
2	Right iliac body fracture	Light paraplegia. Improvement in walking after 1 month	HTx	lateral plating with a 1.5 mm reconstruction plate, 1 2.0 / 14 mm and 4 2.0 / 12 mm locking screws.	-	Good
3	left iliac body fracture, pubis and ischium	Partial improvement in walking for 7 days post op	-	Four 2.0 / 10 mm locking screws were used for a lateral 1.5 mm reconstruction plate.	-	Good
4	Right sacroiliac luxation. left iliac body fracture, pubis and ischium	Paraplegia, urinary incontinence	HTx	Reconstruction plate was used laterally with 3 locking screws of 2.0 / 12 mm. Right sacroiliac lux. was fixed with a 2.0 / 16 locking screw.	Aspiration pneumonia, severe narrowing of the pelvic canal, constipation, urinary incontinence	EX
5	Left iliac body pubis and ischium fracture.	No urinary incontinence, paraplegia, months).		A 1.5 mm T-shaped reconstruction plate was fixed laterally iliac body fracture with 4 2.0 / 10 mm locking screws.	Constipation	Good
6	Left iliac body and left ischium fracture	-		reconstruction plate from the lateral of iliac body	-	Good
7	Right iliac body fracture	-		A 6-hole LC-DCP plate was fixed to the iliac body	-	Good

attached to the caudal fragment with screws. The fracture was repositioned and the rest of the screws were placed sequentially from caudal to cranial.

Ventral Approach

The lateral approach, as described above, was used for ventral access to the ilial body. The fracture ends were brought together and stabilized with a four- to six-hole 1.5mm or 2.0 mm thickness reconstruction or a LC-DCP plate with two or three 1.5- or 2-mm screws on each fragment was placed on the ventral surface of the ilial body.

RESULTS

Radiographic evaluation revealed a left ilial body fracture in 12 (57%) cats and a right ilial body frac-

ture in nine (42.8%) cats. Eight cats had multiple fractures of the ilial body, including ilial body and femoral (4.6%), ischial (33.3%), pubic (14.3%), acetabular (4.6%), sacroiliac joint luxation (19%), femoral neck (9.5%) and tibia fractures (4.6%). During the evaluation of thoracic radiographs, hemothorax (HTx) in four cases (19%) and pneumothorax (PTx) in one case (4.6%) were detected.

Pre-operative Results

In the pre-operative neurological examination, two cats (9.5%) had no tail movement and reduced anal reflexes. Other findings of the neurological examination included loss of sensation in the hindlimbs (33.3%), urinary incontinence (23.8%) and pre-operative constipation (28.5%) (Table 1, Table 2 and Table 3).

Table 3. Clinical, neurological and radiographic findings of cats undergoing ventral plate osteosynthesis in in ilium body fractures.

Case	Radiographic Findings of the Pelvis	Neurologic Findings	Thorax findings	Operation Applied	Complications	Prognosis
1	Left iliac body fracture.	paraplegia	-	1.5 mm DCP plate and 3 2.0 / 12 mm locking screws and 2 2.0 / 10 mm locking screws were used	-	Good
2	Right corpus ilium and acetabulum fracture	paraplegia	-	1.5 mm reconstruction plate, 2 1.5 / 12 mm and 2 1.5 / 10 mm locking screws were used.	-	Good
3	Left sacroiliac lux. Transversal fracture in the right iliac body and coxofemoral luxation	-	-	Three 1.5 / 16 mm and 1 1.5 / 10 mm locking screws were applied to the 1.5 mm DCP plate	-	Good
4	Left iliac body fracture	-	-	1.5 and 2.0 reconstruction plate osteosynthesis from ventral and lateral	-	Post-op 1 haftasonra Ex
5	Right iliac bodyfracture	-	-	1.5 and 2.0 reconstruction plate osteosynthesis from ventral and lateral	-	Good
6	Bilateral sacroiliac luxation, fracture in the left iliac body	-	-	1.5 and 2.0 reconstruction plate osteosynthesis from ventral and lateral	-	Fair

Post-operative Results

A 1.5 mm reconstruction plate was used in 11 cases and a 1.5 and 2.0 mm LC-DCP plate was used in eight cases (Table 1, Table 2 and Table 3). A femoral neck fracture, was repaired with pin osteosynthesis. In cases (n=4) with sacroiliac joint luxation, a 2.0 mm locking screw was used. In cases with suspected complications, radiological examinations were performed intraoperatively to check the initial positioning of the plates and screws.

Dorsal Approach

No loosening was detected in the screws applied dorsally in post-op. According to the radiographic results obtained 4 weeks after the surgery, there was no narrowing of the pelvic canal in all seven cases (100%). During the post-operative of 15th day clinical examination, infection and muscle and skin necrosis were detected at the operation site of one patient, so the plate was removed and hemipelvectomy operation was performed. Post-operative neurological examination two weeks after surgery showed absent tail movement in one cat but these improved within four weeks. Urinary incontinence was detected in two cats, after the development of cystitis, But the cats were improved one to four weeks post-operatively.

Constipation was seen in one case. The outcome was good in the long term (post-op 8 week) follow-up of those seven patients (100%).

Lateral Approach

In 85.7% of the cases following lateral plate repair, there was no narrowing of the pelvic canal detected at follow up examination. In one case (14.7%), no improvement of the pelvic canal narrowing was detected in radiographically immediately after surgery. This finding was attributed to the presence of the ilial and acetabular fractures. Severe constipation and urinary incontinence developed and they were healed post-op. The death resulting from aspiration pneumonia because of trauma.

Cystitis developed in two cases due to urinary incontinence and this improved with medical treatment in the post-operative period. Tail reflexes were absent in the pre-operative neurological examination in two cases, but improved 1-2 months after surgery.

Three cases showed constipation that responded positively to medical treatment. No screw loosening was observed in all cases. The outcome was good in six of the seven patients (85,7%) in their long-term

follow-up (post-op 8 week).

Ventral Approach

During ventral application, more muscle damage was created using a ventral surgical approach. It was difficult to drill holes in the ventral aspect of the ilial body, especially using the equipment and plating. The ilium was retracted slightly upwards with a Hofmann retractor in order to position the plate on the ventral aspect of the bone. Due to the narrowness of the ilial body, each screw was fixed with a guide and no loosening was subsequently detected. According to the radiographic results obtained 4 weeks after surgery, there was a non-union in one of the cases (14.2%). The other 5 patients of this group recovered well and radiographically there was no narrowing of the pelvic canal. One patient died of unrelated causes and could not be included to the follow up group. Urinary incontinence was detected in two cats. A paraplegic cat, improved two weeks after the operation. Constipation was seen in two cases. The outcome was good in the long term follow-up in 5 out of 6 (83.3 %) patients.

DISCUSSION

Six weeks of cage rest combined with appropriate analgesia is an appropriate conservative management method in cases where the weight-bearing axis of the pelvis (including the pelvic floor, ilial wing and ischium fractures) is not affected, the fracture ends are minimally displaced or stable, and the fractures do not affect a vital structure or body function. The choice of analgesia is dependent on the degree of trauma and discomfort, as well as the condition of the patient. Most commonly non-steroidal anti-inflammatories (NSAIDs) are given for 10 to 14 days, with the addition of oral buprenorphine if further analgesia is needed. It is important to limit the animal's activity but still allow freedom to ensure regular urination and defecation. Cage rest can include periods of supervised activity of 10 min two to three times a day, and appropriate bedding should be used to avoid the development of decubital ulcers, especially if the animal cannot move (Miller, 2002; Grierson, 2019).

In our study, the criteria for selecting surgical therapy of pelvic fractures were based on these recommendations found in the literature. Surgery was instigated in cases where sacroiliac luxation and ilial body and acetabular fractures were along the weight-bearing axis, particularly when they resulted in narrowing of the normal pelvic canal diameter. In a study of pelvic fractures in cats, constipation or obstipation was

uncommon and no clear relationship with pelvic canal narrowing was found. As no cats in this study had pelvic narrowing, if there was extreme pain, nerve deficits and pelvic floor fractures which were widely displaced with abdominal wall avulsion, fractures of the ischial tuberosity if they are clinically disabling. Surgery was to improve the canal width if narrowing was less than -45% to -50% by Meeson and Geddes, 2017. If fracture surgical management occurs within four to five days of injury, reduction and fixation would be more effective (Grierson, 2019). However, delays of seven to 10 days following injury can make fracture reduction challenging or impossible due to early callus formation (Grierson, 2019). Ilial fractures were dislocated in all cats included in this study, so surgery was elected in all cases.

Concurrent problems such as pulmonary contusions, pneumothorax, hemothorax, rib fractures, diaphragmatic hernia and myocardial injury can be seen in cases with pelvic trauma (Miller, 2002; Grierson, 2019). In this study, hemothorax was present in four cases and pneumothorax in one case. Those animals were stabilized preoperatively and no intraoperative complications were encountered.

Twenty-three cases in the study were operated once patients were stabilized. In many cases the time of the injury was not known. We believe that difficulties in fracture reduction in some cases was due to primary callus formation. This was emphasized where neurological problems required delays of seven to 10 days for the patient to be stabilized and be adequately assessed. For this reason, cases were only operated on that were immediately stable with a good prognosis where surgery could be carried out within the first three days after the known trauma. When the fracture reduction was difficult due to extreme dislocation of the fragments or chronicity of the fracture, double plating was performed (dorsal and lateral),

Complications related to implant failure have been reported in studies using lateral DCP or reconstruction plates in the treatment of ilial body fractures in cats and dogs (Breshears et al., 2004; Hamilton et al., 2009; Schmierer et al., 2015). The most common complication of lateral plate application is screw loosening (Breshears et al., 2004; Hamilton et al., 2009). This is attributed to the narrowing of the hemipelvic canal width in the lateromedial plane (Vangundy et al., 1988; Breshears et al., 2004). In the study of Hamilton et al. (2009), the plates were applied laterally in 13 out of 21 cats and loosening of the screws was de-

tected in radiographs taken at four to six weeks. In addition, narrowing of the pelvic canal was noted in six out of 21 cats and recurrent constipation symptoms were noted in five cats. Schmierer et al. (2015) compared the incidence of screw loosening in locking and non-locking implants in cats with ilial fractures. The incidence of screw loosening in locking plates was 4%, while the incidence non-locking plates was 50%. In our study, LC-DCP or reconstruction plates applied laterally, dorsally, and ventrally to corpus ilia fractures in combination with locking screws were used and no screw loosening occurred. Our results are consistent with the results of the study performed by Schmierer et al. (2015) when using locking plates and screws. Langley-Hobbs et al. (2009) found that 2.0 mm DCP plates applied dorsally to ilium fractures in cats led to success full healing of those fractures. In this study, it was found that the plates applied dorsally required the use of more screws, there was no screw loosening and less pelvic canal narrowing compared lateral application. Those finding were also supported by Breshears et al. (2004). In our study, post-operative radiography confirmed that there was no screw loosening in all three methods of plate application.

Placing a plate on the dorsal side of the ilium in cats is more difficult than lateral application. Careful screw placement is important in especially the cranial and caudal holes to ensure that the entire plate is correctly positioned on the dorsal aspect of the ilium. This requires intramuscular dissection between the gluteal muscles to expose the ilium sufficiently. If this technique is combined with gluteal tenotomy it causes more damage to the gluteal muscle group (Langley-Hobbs et al., 2009). In this study, when surgery took place over five days after injury, two methods were used to expose the dorsal ilial region. A lateral incision was made with the plate placed on the lateral aspect of the body of the ilium, followed by exposure of the dorsal aspect by a dorsal incision.

Positioning of the patient was important in ventral application and the placement of the plate was difficult. Due to the narrow ilium, screws can accidentally be directed towards the pelvic cavity if a guide is not used. In this study, in cases with suspected complications, radiological examinations were performed intraoperatively to check the initial positioning of the plates and screws. In cases with sacro-iliac luxation, fixation was achieved by placing a long screw between the ilium and sacrum through the lateral plate (Burger et al., 2004; Pratesi et al., 2018).

Neurological damage can be seen in up to 70% of cases with ilial fractures and in 30% of cases with sacroiliac luxation (Bookbinder and Flanders, 1992). Other findings of the neurological examination included loss of sensation in the hind limbs (33.3%). The *pudendal*, *coccygeal* and *sacrococcygeal nerves* are the most affected nerves in such injuries. In a previous study, 13% of cats with pelvic fractures had ischiatic nerve damage (Meeson and Geddes 2017). In case of a neurologic deficits, inability of the cat to urinate and defecate is often observed. The presence of anal reflex, indicates that urinary dysfunction can be regained. A positive tail pain test, indicates that voluntary urination should occur again within 48 h. If it is negative, improvement was observed in only 60% of the cases (Tatton et al., 2009). A negative perianal test is a negative prognostic factor. According to the neurological findings of this study, no cats had permanent nerve damage. A slight loss of sensation was detected in the hind limbs in six cases on preoperative examination (42.8%). The gait improvement of these patients was observed within seven days to one month. One case without tail reflexes showed improvement after two months. In four cases (28.5%) with no initial urine output and constipation, improvement was noted with medical treatment in the post-operative period.

CONCLUSION

In cases of ilial fracture in cats, no difference was observed between the clinical and radiological results of placing LC-DCP or reconstruction plates on the dorsal, ventral, and lateral aspects of the ilium in the post-operative period. No difference in outcome was found between the use of LC-DCP and reconstruction plates. However, it has been observed that reconstruction plates can be shaped more easily depending on the location of the fracture line, providing convenient application. It was found that the locking plate and screws kept the fracture fragments more rigid, and that screw loosening did not occur.

Case selection is important when deciding the ideal location of the plate in os ilium fractures. Lateral application provides convenience for the surgeon while placing the plate in the dorsal and ventral regions is more difficult due to the anatomical conformation of the bone. In older fractures (i.e., in cases older than five to six days), double-plate application can provide a better prognosis. Lateral application should be used if the fracture line approaches the acetabulum. A larger group of cats is needed for further studies,

and additional complications could be expected in the long-term evaluation.

Selcuk for the financial support (Scientific Research Projects (BAP) (Project No. 19401152).

ACKNOWLEDGMENTS

The authors would like to thank University of

CONFLICT OF INTEREST

The authors declare no conflicts of interest.

REFERENCES

- Breshears LA, Fitch RB, Wallace LJ, Wells CS, Swiderski JK (2004) The radiographic evaluation of repaired canine ilial fractures. *Vet Comp OrthopTraumatol* 17:64-72.
- Bookbinder PE, Flanders JA (1992). Characteristics of pelvic fractures in the cat. A 10-year retrospective study. *Vet Comp OrthopTraumatol* 5:122-7.
- Dyce KM, Sack WO, Wensing CJC (2009). Dogs and cats. In: *Textbook of Veterinary Anatomy*. 4th ed, Saunders/Elsevier, pp 435-437.
- Grierson J (2019) Dealing with pelvic fractures in cats. In *practice Companion AnimPrac* 41:106-14.
- Hamilton MH, Evans DA, Langley-Hobbs SJ (2009) Feline ilial fractures: assessment of screw loosening and pelvic canal narrowing after lateral plating. *Vet Surg* 38:326-333.
- Jacobsen A, Schrader SC (1987) Peripheral nerve injury associated with fracture or fracture-dislocation of the pelvis in dogs and cats: 34 cases (1978-1982). *J Am Vet Med Assoc* 190:569-572.
- Langley-Hobbs SJ, Meeson RL, Hamilton MH, Radke H, Lee K (2009) Feline ilial fractures: a prospective study of dorsal plating and comparison with lateral plating. *Vet Surg* 38:334-342.
- Lanz OI (2002) Lumbo sacral and pelvic injuries. *Vet Clin North Am Small AnimPract* 32:949-962.
- Matthiesen DT, Scavelli TD, Whitney WO (1991) Subtotal colectomy for the treatment of obstipation secondary to pelvic fracture malunion in cats. *Vet Surg* 20:113-117.
- Meeson RL, Geddes AT (2017) Management and long term outcome of pelvic fractures: a retrospective study of 43 cats. *J Feline Med Surg* 19:36-41.
- Miller A (2002) Decision making in the management of pelvic fractures in small animals. In *practice Companion AnimPract* 24:54-61.
- Rosin E (1993) Megacolon in cats. The role of colectomy. *Vet Clin North Am Small AnimPract* 23:587-94.
- Schmierer PA, Kircher PR, Hartnack S, Knell SC (2015) Screw loosening and pelvic canal narrowing after lateral plating of feline ilial fractures with locking and nonlocking plates. *Vet Surg* 44:900-904.
- Tatton B, Jeffery N, Holmes M (2009) Predicting recovery of urination control in cats after sacro caudal injury: a prospective study. *J Small AnimPract* 50:593-596.
- Tomlinson JL (2003) Fractures of the pelvis. In: *Textbook of Small Animal Surgery*. 3rd ed, Saunders, Philadelphia, pp 1989-2001.
- Vangundy TE, Hulse DA, Nelson JK, Boothe HW (1998). Mechanical evaluation of two canine iliac fracture fixation systems. *Vet Surg* 17:321-327.