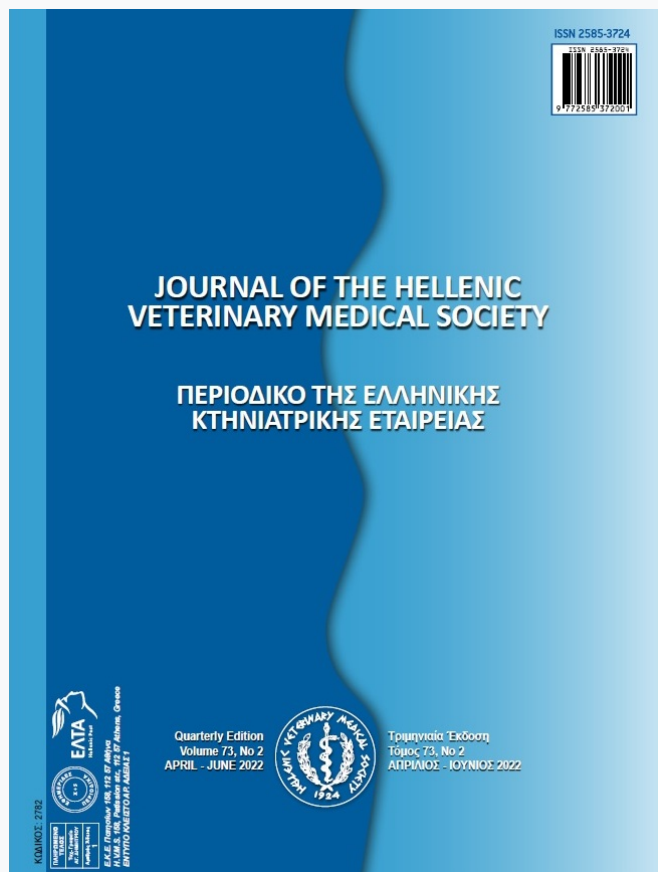

Journal of the Hellenic Veterinary Medical Society

Vol 73, No 2 (2022)



Rapid Resolution of Megaesophagus by Low-dose Levothyroxine in a Hypothyroid dog with Mitral Valve Degeneration

Dohee Lee, Taesik Yun, Yoonhoi Koo, Yeon Chae, Byeong-Teck Kang, Mhan-Pyo Yang, Hakhyun Kim

doi: [10.12681/jhvms.26553](https://doi.org/10.12681/jhvms.26553)

Copyright © 2022, Hakhyun Kim



This work is licensed under a [Creative Commons Attribution-NonCommercial 4.0](https://creativecommons.org/licenses/by-nc/4.0/).

To cite this article:

Lee, D., Yun, T., Koo, Y., Chae, Y., Kang, B.-T., Yang, M.-P., & Kim, H. (2022). Rapid Resolution of Megaesophagus by Low-dose Levothyroxine in a Hypothyroid dog with Mitral Valve Degeneration. *Journal of the Hellenic Veterinary Medical Society*, 73(2), 4265–4270. <https://doi.org/10.12681/jhvms.26553>

Rapid Resolution of Megaesophagus by Low-dose Levothyroxine in a Hypothyroid dog with Mitral Valve Degeneration

Dohee Lee^{ORCID}, Taesik Yun^{ORCID}, Yoonhoi Koo^{ORCID}, Yeon Chae^{ORCID}, Byeong-Teck Kang^{ORCID},
Mhan-Pyo Yang^{ORCID}, Hakhyun Kim*^{ORCID}

Laboratory of Veterinary Internal Medicine, College of Veterinary Medicine, Chungbuk National University, Cheongju, Chungbuk, Republic of Korea

ABSTRACT: A 14-year-old intact female Maltese dog weighting 4.84kg was presented with acute regurgitation. At presentation, the dog was diagnosed with megaesophagus and primary hypothyroidism based on the radiography and thyroid-stimulating hormone stimulation test, respectively. Treatment was initiated with oral low-dose levothyroxine (0.0025 mg/kg b.w., orally, SID) considering underlying myxomatous mitral valve disease. Ten days after the management, the clinical and radiographic signs of megaesophagus were completely resolved. The dog was managed by levothyroxine administration with a gradual increase of the dose along with the monitoring of serum thyroxine concentrations since the dog was diagnosed with hypothyroidism. At 10 months after presentation, the dog continued to do well clinically. This is first case report describing rapid resolution of generalized megaesophagus after low-dose levothyroxine administration considering underlying cardiac disease in a hypothyroid dog.

Keywords: canine; hypothyroidism; regurgitation; thyrotropin.

Corresponding Authors:

Hakhyun Kim, Laboratory of Veterinary Internal Medicine, College of Veterinary Medicine, Chungbuk National University, Cheongju, Chungbuk 28644, Republic of Korea
E-mail address: kimh@chungbuk.ac.kr

Date of initial submission: 24-03-2021
Date of acceptance: 26-04-2021

CASE HISTORY

A 14-year-old intact female Maltese dog weighing 4.84 kg was presented with a 2-day history of regurgitation. There was no history of medications or foreign body ingested. Physical examination revealed ptyalism and overdistended cervical esophagus. The dog had a diffusely poor and dry hair coat, and depressed activity but normal gait and posture on physical examination. In addition, mid systolic click sound was detected on thoracic auscultation, but other findings were unremarkable. The dog was somewhat depressed, but neurologic examinations did not show any abnormalities. Survey radiographs revealed gas-filled and overdistended esophagus and no evidence of pneumonia (Figure 1A and B). Based on a history of regurgitation and the identification of esophageal dilation on survey radiographs without chemical restraint (Manning et al, 2016), thus megaesophagus (ME) was diagnosed. For identifying comorbidities or concurrent diseases which could be a primary cause of ME, the diagnostic evaluations included blood analyses including complete blood counts, serum biochemistry and electrolytes, echocardiography, thyroid profiling, adrenocorticotrophic hormone (ACTH) stimulation test, and an acetylcholine receptor antibody titrating. Complete blood counts were within the reference intervals (RI). The abnormal blood results included hyperalbuminemia (3.7 g/dL; RI = 2.6-3.3g/dL), elevated alkaline phosphatase activity (147 IU/L; RI = 29-97 IU/L), hypercholesterolemia (482mg/dL; RI = 135-270 mg/dL), elevated creatinine kinase activity (640 IU/L; RI = 42-530 IU/L), and abnormal sodium-to-potassium ratio (26.3; RI > 30). The ACTH stimulation test showed that the cortisol was below the RI (1.1 µg/dL; RI = 2-6 µg/dL) at baseline, but the 1-h post-ACTH cortisol (17.5 µg/dL; RI = 6-18 µg/dL) concentration increased within RI after synthetic ACTH (250µg, intravenously, Synacthen®, Norvatis, Switzerland) administration. Based on these findings, hypoadrenocorticism was ruled out. The thyroid function was evaluated and the results showed that the serum total thyroxine (T_4 , <0.4 µg/dL; RI = 1.0-4.0 µg/dL) was below the detection limits, while there was an elevated level of canine thyroid-stimulating hormone (TSH, 3.39 ng/ml; RI = 0.01-0.6 ng/mL) (Table 1). Thyroglobulin, triiodothyronine and T4 autoantibodies titers were within RI. To confirm hypothyroidism, TSH stimulation test using recombinant human TSH (150 µg, intravenously, Thyrogen, Genzyme, USA) was performed and it failed to increase 6-h post-TSH T_4 concentration (<0.4 µg/dL; RI > 2.5 µg/dL)

(Boretta et al, 2009), thus, the dog was diagnosed with primary hypothyroidism (Mooney, 2011). Furthermore, the dog had echocardiographic evidences of myxomatous mitral valve disease such as mitral leaflet thickening and mitral regurgitation on the color Doppler echocardiogram (Boswood et al, 2018), thus the reduced dose of levothyroxine (L-T4) (0.0025 mg/kg b.w., orally, SID, Thyforon®, Dechra, UK) was initially prescribed considering concurrent heart disease (Phillips and Harkin, 2003; Scott-Moncrieff, 2015; Paik et al, 2016). In addition to this, the owner was advised to feed the dog canned food at frequent intervals and to hold the dog in a vertical position.

On day 10 of L-T4 treatment, follow-up thoracic radiographs were within normal limit (Figure 1C, D, E and F). Serum creatinine kinase activity (296 IU/L; RI = 42-530 IU/L) were also normalized although

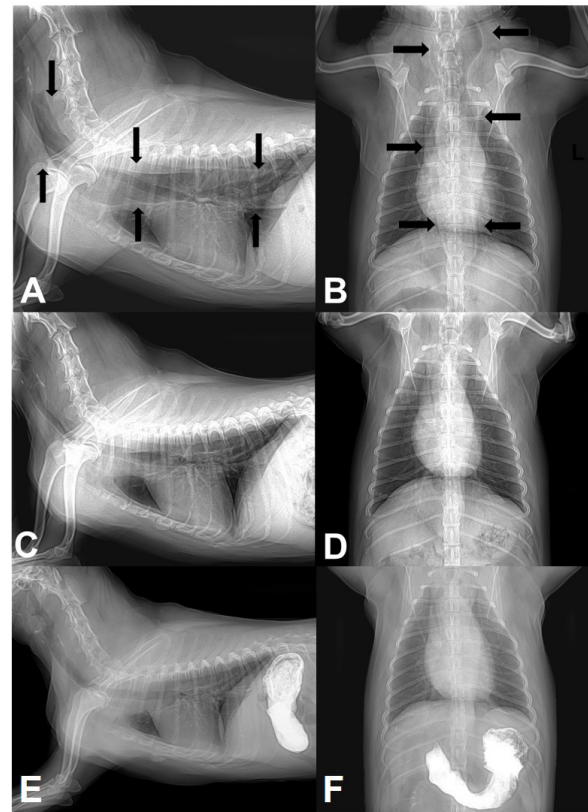


Figure 1. Thoracic radiographs obtained from a Maltese dog with hypothyroidism and megaesophagus. (A) The right lateral and (B) ventrodorsal projection of thoracic radiographs shows gas-filled and overdistended esophagus at presentation. The black arrows indicate distended esophagus. Ten days after the administration of levothyroxine, (C) the right lateral and (D) ventrodorsal projection of thoracic radiographs showed complete regression of previously overdistended esophagus. (E) The right lateral and (F) ventrodorsal projection of thoracic radiographs after oral administration of barium shows that the esophagus is outlined with a normal size and shape

Table 1. Thyroid profiling of a Maltese dog before and after levothyroxine administration

Parameter	Before levothyroxine administration	After 10 days of levothyroxine administration	Reference intervals
Basal total T4 ($\mu\text{g/dL}$)	<0.4	0.8	1.0-4.0
Post-TSH total T4 ($\mu\text{g/dL}$)	<0.4	ND	>2.5
TSH (ng/mL)	3.39	3.45	0.01-0.60
Basal total T3 (nmol/L)	0.4	ND	0.80-2.10
Thyroglobulin autoantibody (%)	2.00	ND	0.00-35.00
T4 autoantibody (%)	8.00	ND	0.00-20.00
T3 autoantibody (%)	3.00	ND	0.00-10.00

ND, not determined; T3, triiodothyronine; T4, thyroxine; TSH, thyroid-stimulating hormone.

the serum total T4 and TSH levels 4-h after L-T4 administration were considered still inadequate (Table 1), but the dog showed no regurgitation with normal feeding and good health condition with activity improvement. The result of an acetylcholine receptor antibody titration (IDEXX Laboratories Inc., USA) of serum obtained at initial presentation was within RI (0.09 nmol/L; RI < 0.6 nmol/L), thus myasthenia gravis was consequently ruled out. At 10 months after presentation, the dog continued to do well clinically and the current medication comprised 0.02 mg/kg of L-T4 SID.

DISCUSSION

Diffuse ME is functional disorder in which there is decreased or absent esophageal motility, and diffuse esophageal dilation (Manning et al, 2016). ME is often categorized as either congenital or acquired which is further classified as primary (idiopathic) and secondary in dogs. Many diseases are identified simultaneously and considered as a cause of secondary ME in dogs, including myasthenia gravis, hypoadrenocorticism, dysautonomia, tetanus, polyradiculoneuritis, leiomyoma, and possibly hypothyroidism (McBrearty et al, 2011). The resolution of ME in hypothyroid dogs has been rarely reported in dogs (Huber et al, 2001; Fracassi and Tamborini, 2011). The reason why treatment of hypothyroidism does not consistently result in ME resolution. Also, the information for the dose and duration of T4 supplementation necessary to resolution of ME associated with hypothyroidism is still lacking. This case describes firstly that generalized ME was rapidly resolved after L-T4 administration in a hypothyroid dog although the L-T4 dose was reduced considering concurrent myxomatous mitral valve disease.

In this case, a dog was diagnosed as suffering from an acquired secondary ME associated with primary

hypothyroidism, which was demonstrated by rapid ME resolution after low-dose L-T4 supplementation (0.0025 mg/kg b.w., orally, SID for 10 days) although T4 and TSH concentrations were not normalized. Hypothyroidism has historically been considered as a possible cause of acquired secondary ME (McBrearty et al, 2011), but the resolution of ME in hypothyroid dogs has been rarely reported (Huber et al, 2001; Fracassi and Tamborini, 2011), and a causal relationship has not been established (Boswood et al, 2018).

In a retrospective study, 4 dogs had ME; 1 dog was clinically improved after T4 administration, but all 4 dogs revealed persistent radiological evidence of ME 2 months after therapy (Jaggy et al, 1994). One of these dogs had completely resolved 6 months after therapy for hypothyroidism, but the dose of T4 (0.03 mg/kg PO BID) was relatively high compared to the dose in our case. In another study, there was no association between hypothyroidism and ME (Gaynor et al, 1997). However, reversible ME in 2 hypothyroid dogs with complete clinical and radiographic recovery once the thyroid is regulated by usual starting dose of L-T4 (0.02 mg/kg PO BID) have been reported (Huber et al, 2001; Fracassi et al, 2011). Therefore, the reason why treatment of hypothyroidism does not consistently result in resolution of ME and the dose and duration of T4 administration in hypothyroid dogs with ME have not been known, but some ME in hypothyroid dogs can be resolved T4 supplementation regardless of the dose of L-T4.

There are some possible reasons why ME of some hypothyroid dogs respond to T4 supplementation but others do not. The esophageal dysfunction could be the result of either a neuropathy or myopathy secondary to hypothyroidism although the exact pathogenesis is unknown (Panciera, 2001). In neuropathy, mucinous deposits around peripheral nerves which supervise the

function of esophagus in hypothyroid status, which might mechanically compress and entrap nerves by localized myxedema (Pollard, 2005). In addition, reduced mitochondrial respiratory activity of peripheral nerves can induce adenosine triphosphate deficiency and adenosine triphosphatase activity in nerve cell bodies, which reduce sodium/potassium pump activity, subsequently axonal transport of peripheral nerves supervising the motility of esophagus might be impaired (Sidenius et al, 1987). However, hypothyroid peripheral neuropathy response to treatment might be poor (Platt, 2002; Utsugi et al, 2014). The dog in this report required only 10 days to observe the improvement of clinical signs and radiologic abnormalities consistent with ME, which could be not demonstrated as hypothyroid neuropathy.

Otherwise, because the canine esophageal body is composed entirely of two oblique layers of skeletal muscle and is innervated by the somatic branches (Busch, 1980), ME could be caused by myopathy (Sindoni et al, 2016). T4 deficiency causes a reduced mitochondrial oxidative capacity, abnormal glycogenolysis and an insulin resistance of muscle cells, which leads to selective type 2 myofiber atrophy due to its dependence on glycolysis for energy. Therefore, hypothyroid myopathy is caused by alterations in muscle fibers from type 1 myofiber predominance accompanied with type 2 myofiber atrophy, deposition of glycosaminoglycans, poor contractility of actin-myosin units, low myosin adenosine triphosphatase activity and low adenosine triphosphate turnover in skeletal muscle (Sindoni et al, 2016). Similarly, nemaline rod inclusions, type 1 myofiber predominance, type 2 myofiber atrophy, and subsarcolemmal accumulations of morphologically abnormal mitochondria were identified in experimental-induced hypothyroid dogs (Rossmeis et al, 2009). In addition, defect in skeletal muscle mitochondrial function altered muscle energy metabolism such as depletion of skeletal muscle carnitine in experimental-induced hypothyroid dogs (Rossmeis et al, 2009), which are likely to affect the esophageal muscle tone and cause generalized ME as described in the present case.

Most hypothyroid dogs with myopathy rapidly respond to thyroid replacement therapy within 2-8 months (Platt, 2002; Utsugi et al, 2014). It has been considered that relatively early impairments caused by hypothyroidism are mainly metabolic abnormalities, rather than structural abnormalities in peripheral nerves (Qauttrini et al, 1993; Utsugi et al, 2014).

It is common for owners of dogs with hypothyroidism to notice rapid improvement in activity, within first 2 weeks of treatment (Rossmeis et al, 2009), which is consistent finding in the present case. Thus, the present case might be suffered from ME caused by hypothyroid myopathy. This contention might be supported by rapid resolution of ME after relatively low-dose of L-T4 supplementation along with the normalization of serum creatinine kinase activity. It resembled similar changes reported in humans with hypothyroid myopathy (Sindoni et al, 2016). However, the association between normalization of creatinine kinase activity and the resolution of ME cannot be demonstrated due to the lack of creatinine kinase activity data in the previous studies. Thus, we cannot directly compare creatinine kinase activity of our case with that of the dogs in the previous cases. In humans, serum TSH assay is justified if the high creatinine kinase activity and/or lactic dehydrogenase levels are isolated or associated to any of these other alterations: hypercholesterolemia, hyponatremia, hyperprolactinemia, and anemia, which can be consistent findings for hypothyroidism (Ladenson et al, 2000). According to the American Thyroid Association guidelines, finding an increased serum creatinine kinase and/or lactic dehydrogenase levels, that persist elevated for at least 2 weeks, is enough to justify the request of serum TSH assay in order to confirm or exclude hypothyroidism (Ladenson et al, 2000). However, there has been no data for the association between creatinine kinase level and hypothyroid myopathy in dogs. Further study using multiple nerve and esophageal muscle biopsy along with monitoring clinical signs of ME and thoracic radiography will be necessary to clarify that ME caused by hypothyroid myopathy can be resolved rapidly after T4 supplementation, but this procedure can be unusual in clinical practice.

In the present case, the dogs received more reduced dose of L-T4 (0.0025 mg/kg b.w., orally, SID) than usual starting dose considering underlying myxomatous mitral valve disease (Phillips and Harkin, 2003; Scott-Moncrieff, 2015; Paik et al, 2016) and not distinct clinical signs associated with hypothyroidism, except for poor hair coat and low activity level. To the author's knowledge, there are no published data that this low-dose of L-T4 for hypothyroid dogs with ME, but the present case well tolerated a gradually increasing dose of L-T4 starting with this low-dose for 10 days, and clinical signs associated with ME were completely resolved. It could be possible that early recovery of ME associated with metabolic functional

abnormalities in hypothyroid myopathy is expected after T4 supplementation itself if the dose of L-T4 is lower than that of usual starting dose and the serum total T4 and TSH levels 4-h after L-T4 administration are considered inadequate.

In conclusion, this case demonstrated the supplementation of L-T4 was achieved complete resolution of ME in hypothyroid dogs although the dose of L-T4 was relatively lower than usual starting dose as well as used for shortened therapeutic period that had been previously reported (Huber et al, 2001; Fracassi and Tamborini, 2011), which can indicate that L-T4 administration can rapidly resolve secondary ME related to hypothyroid myopathy in dogs. Elucidating the etiology of ME in dogs can be difficult. We contend that if ME caused by hypothyroid myopathy, it could be rapidly improved by L-T4 supplementation. Con-

versely, if ME caused by hypothyroid neuropathy or structure changes in peripheral nerve, the treatment response might be poor. This contention might describe that the reason why some ME in hypothyroid dogs respond to T4 supplementation but others do not. Further study will be necessary to clarify the effect of L-T4 supplementation on esophageal function and pathology.

ACKNOWLEDGEMENTS

The authors would like to thank the owner of the dog included in this report.

CONFLICT OF INTEREST

None declared.

REFERENCES

- Boretti FS, Sieber-Ruckstuhl NS, Wenger-Riggenbach B, Gerber B, Lutz H, Hofmann-Lehmann R, Reusch CE (2009) Comparison of 2 doses of recombinant human thyrotropin for thyroid function testing in healthy and suspected hypothyroid dogs. *J Vet Intern Med* 23:856-861.
- Boswood A, Gordon SG, Häggström J, Wess G, Stepien RL, Oyama MA, Keene BW, Bonagura J, MacDonald KA, Patteson M, Smith S, Fox PR, Sanderson K, Woolley R, Szatmári V, Menaut P, Church WM, O'Sullivan ML, Jaudon JP, Kresken JG, Rush J, Barrett KA, Rosenthal SL, Saunders AB, Ljungvall I, Deinert M, Bomassi E, Estrada AH, Fernandez Del Palacio MJ, Moise NS, Abbott JA, Fujii Y, Spier A, Luethy MW, Santilli RA, Uechi M, Tidholm A, Schummer C, Watson P (2018) Longitudinal Analysis of Quality of Life, Clinical, Radiographic, Echocardiographic, and Laboratory Variables in Dogs with Preclinical Myxomatous Mitral Valve Disease Receiving Pimobendan or Placebo: The EPIC Study. *J Vet Intern Med* 32:72-85.
- Busch C (1980) Structure of the esophagus of the dog. *Acta Anat (Basel)* 107:339-360.
- Fracassi F, Tamborini A (2011) Reversible megaesophagus associated with primary hypothyroidism in a dog. *Vet Rec* 168:329b.
- Gaynor AR, Shofer FS, Washabau RJ (1997) Risk factors for acquired megaesophagus in dogs. *J Am Vet Med Assoc* 211:1406-1412.
- Huber E, Armbrust W, Forster JL, Ribièrè T, Grosclaude P (2001) Resolution of megaesophagus after treatment of concurrent hypothyroidism in a dog. *Schweiz Arch Tierheilkd* 143:512-514.
- Jaggy A, Oliver JE, Ferguson DC, Mahaffey EA, Glaus T Jr (1994) Neurological manifestations of hypothyroidism: a retrospective study of 29 dogs. *J Vet Intern Med* 8:328-336.
- Ladenson PW, Singer PA, Ain KB, Bagchi N, Bigos ST, Levy EG, Smith SA, Daniels GH, Cohen HD (2000) American thyroid association guidelines for detection of thyroid dysfunction. *Arch Intern Med* 160:1573-5.
- Manning K, Birkenheuer AJ, Briley J, Montgomery SA, Harris J, Vanone SL, Gookin JL (2016) Intermittent At-Home Suctioning of Esophageal Content for Prevention of Recurrent Aspiration Pneumonia in 4 Dogs with Megaesophagus. *J Vet Intern Med* 30:1715-1719.
- McBrearty AR, Ramsey IK, Courcier EA, Mellor DJ, Bell R (2011) Clinical factors associated with death before discharge and overall survival time in dogs with generalized megaesophagus. *J Am Vet Med Assoc* 238:1622-1628.
- Mooney CT. Canine hypothyroidism: a review of aetiology and diagnosis (2011) *N Z Vet* 59:105-114
- Paik J, Kang JH, Chang D, Yang MP (2016) Cardiogenic Pulmonary Edema in a Dog Following Initiation of Therapy for Concurrent Hypoadrenocorticism and Hypothyroidism. *J Am Anim Hosp Assoc* 52:378-384.
- Panciera DL (2001) Conditions associated with canine hypothyroidism. *Vet Clin North Am Small Anim Pract* 31:935-950.
- Phillips DE, Harkin KR (2003) Hypothyroidism and myocardial failure in two Great Danes. *J Am Anim Hosp Assoc* 39:133-137.
- Platt SR (2002) Neuromuscular complications in endocrine and metabolic disorders. *Vet Clin North Am Small Anim Pract* 32:125-146.
- Pollard JD (2005) Neuropathy in disease of the thyroid and pituitary glands. In: *Peripheral neuropathy*. 4th ed, Elsevier Saunders, Philadelphia, USA: pp 2039-2049.
- Quattrini A, Nemni R, Marchettini P, Fazio R, Iannaccone S, Corbo M,

- Canal N (1993) Effect of hypothyroidism on rat peripheral nervous system. *Neuroreport* 4:499-502.
- Rossmeis JH, Duncan RB, Inzana KD, Panciera DL, Shelton GD (2009) Longitudinal study of the effects of chronic hypothyroidism on skeletal muscle in dogs. *Am J Vet Res* 70:879-889.
- Scott-Moncrieff JC (2015) Hypothyroidism. In: *Canine and feline endocrinology*. 4th ed, Elsevier, St.Louis, USA:pp 2015:77-135.
- Sidenius P, Nagel P, Larsen JR, Boye N, Laurberg P (1987) Axonal transport of slow component in a sciatic nerves of hypo- and hyperthyroid rats. *J Neurochem* 49:1790-1795.
- Sindoni A, Rodolico C, Pappalardo MA, Portaro S, Benvenga S (2016) Hypothyroid myopathy: A peculiar clinical presentation of thyroid failure. Review of the literature. *Rev Endocr Metab Disord* 17:499-519.
- Utsugi S, Saito M, Shelton GD (2014) Resolution of polyneuropathy in a hypothyroid dog following thyroid supplementation. *J Am Anim Hosp Assoc* 50:345-349.