

# Journal of the Hellenic Veterinary Medical Society

Vol 72, No 1 (2021)



## Canine trypanosomosis: a case report

H ABBAS, M RAFI ULLAH, HM RIZWAN, SH FAROOQI, HM AHMAD, MK ATEEQ, M AHMAD

doi: [10.12681/jhvms.26766](https://doi.org/10.12681/jhvms.26766)

Copyright © 2021, H ABBAS, M RAFI ULLAH, HM RIZWAN, SH FAROOQI, HM AHMAD, MK ATEEQ, M AHMAD



This work is licensed under a [Creative Commons Attribution-NonCommercial 4.0](https://creativecommons.org/licenses/by-nc/4.0/).

### To cite this article:

ABBAS, H., RAFI ULLAH, M., RIZWAN, H., FAROOQI, S., AHMAD, H., ATEEQ, M., & AHMAD, M. (2021). Canine trypanosomosis: a case report. *Journal of the Hellenic Veterinary Medical Society*, 72(1), 2787–2790. <https://doi.org/10.12681/jhvms.26766>

## Canine trypanosomosis: a case report

H. Abbas<sup>1\*</sup> , M. Rafi Ullah<sup>2</sup> , H.M. Rizwan<sup>1</sup> , S.H. Farooqi<sup>2</sup> , H.M. Ahmad<sup>2</sup> ,  
M.K. Ateeq<sup>3</sup> , M. Ahmad<sup>2</sup> 

<sup>1</sup>Department of Pathobiology, KBCMA, College of Veterinary & Animal Sciences, Narowal, University of Veterinary and Animal Sciences, Lahore, Pakistan

<sup>2</sup>Department of Clinical Sciences, KBCMA, College of Veterinary & Animal Sciences, Narowal, Pakistan

<sup>3</sup>Department of Basic Sciences, KBCMA, College of Veterinary & Animal Sciences, Narowal, Pakistan

**ABSTRACT:** Trypanosomosis is a haemoprotozoan infection affecting a broad range of wild and domestic animals including dogs. Infected dogs may die within 2-4 weeks in the acute and fatal form of the disease. A dog was presented with the complaint of anorexia, persistent recumbency and loss of body weight which lasted for few days. On clinical examination, the affected dog revealed rise in temperature (105°F), lachrimation, anaemia, unilateral corneal opacity, swelling of throat, enlargement of lymph nodes and severe loss of bodily condition. Wet smear, thin blood smear and hematological parameters were observed. Motile trypanosomes were found in wet smear, while trypanosomes with a characteristic flagellum, kinetoplast and undulating membrane were present outside the red blood cells in the thin smear. The dog was successfully recovered with a single dose of diminazene aceturate. This report may provide a way forward to establish effective and safe therapeutic protocols for the control of canine trypanosomosis.

**Keywords:** Dog; trypanosomes; corneal opacity; thin smear; diminazene aceturate

*Corresponding Author:*

Haider Abbas, Department of Pathobiology, KBCMA, College of Veterinary & Animal Sciences, 51600-Narowal, Sub-campus, University of Veterinary and Animal Sciences, Lahore, Pakistan  
E-mail address: haider.abbas@uvas.edu.pk

*Date of initial submission: 09-04-2020*  
*Date of revised submission: 03-05-2020*  
*Date of acceptance: 22-06-2020*

## INTRODUCTION

Trypanosomosis is a haemoprotozoan infection affecting a broad range of wild and domestic animals including dogs. Dogs are affected by two groups of trypanosomes: (i) mechanically transmitted; *Trypanosoma (T.) evansi* and (ii) biologically transmitted salivarian trypanosomes i.e. *T. brucei* and *T. congolense*. The latter trypanosomes are transmitted biologically by tsetse flies while former species are mechanically transmitted either by eating infected carcasses or by biting insects like *Tabanus* and *Stomoxys* (Green, 2006; Urquhart et al., 1996). *Trypanosoma evansi* causes surra disease mostly in camel and horses but adult dogs have also been widely affected (Rashid et al., 2008; Defontis et al., 2012; Rashid et al., 2014). In tropical and subtropical regions, trypanosomosis is prevalent and although canine trypanosomosis is not frequent but outbreaks of canine disease have been reported from South America, Brazil, Iran, Tunisian, India, Germany and Afghanistan (Ian et al., 2004; Morteza et al., 2007; Eloy and Lucheis, 2009; Rjeibi et al., 2015). In Algeria, *T. evansi* and *T. congolense* have been identified in dogs through molecular investigation (Medkour et al., 2020). Canine trypanosomosis characterized by neurologic, ocular and vascular signs in infected dogs (Bhardwaj et al., 2015). Infected dogs die within 2-4 weeks in the acute and fatal form of the disease (Soulsby, 1982). Clinical manifestations of the disease may include intermittent fever (39°C-41°C), anaemia, anorexia leading to emaciation, progressive weakness, oedema of the abdominal wall and legs, enlarged superficial lymph nodes, edema of head and throat (to be differentiated from rabies), myocarditis, paresis of the hindquarters (sometimes) and ocular signs include conjunctivitis, lachrymation, and corneal opacity (Savani et al., 2005; Sonika et al., 2007; Da Silva et al., 2009). A single dose of diminazene aceturate has been found to effective against canine infection among the available trypanosomacidal drugs including diminazene, quinapyramine and suramine (Kumar, 2017). This report presents a case of canine trypanosomosis and therapeutic response with diminazene aceturate.

## CASE HISTORY

A male greyhound dog of 3-year age was brought to outdoor clinic of KBCMA College of Veterinary and Animal Sciences Narowal, sub campus of University of Veterinary and Animal Sciences, Lahore with the complaint of anorexia, persistent recumbency and loss of body weight from last few days. The owner of

the dog reported that he also has another greyhound dog (2. 5-year-old) at home which looked normal.

On clinical examination of the dog these parameters were observed: temperature (105°F), heart rate (152 bpm), respiration (56 breaths per min), lachrymation, anaemia (markedly pale mucous membrane), unilateral corneal opacity (Figure 1), swelling of throat, enlargement of lymph nodes and severe loss of bodily condition. Next day, blood examination of the second dog, which had normal body temperature and submandibular oedema, was also performed.

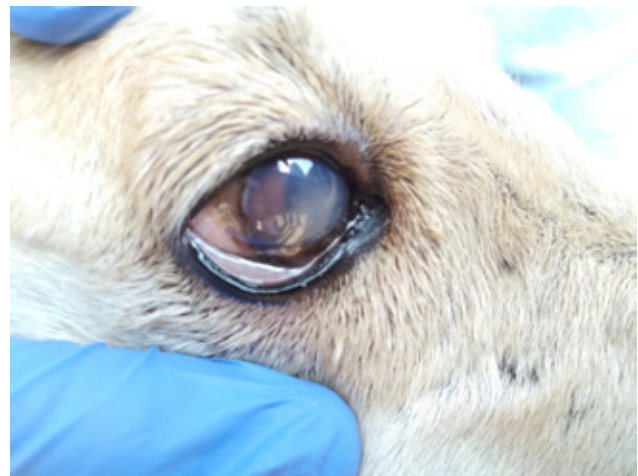


Figure 1. Corneal opacity in the dog

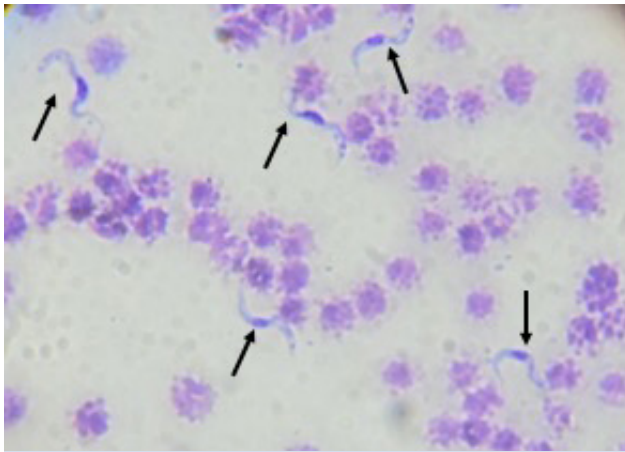
Blood sample was collected aseptically on the owner's consent. The blood was observed for parasites. For this purpose, marginal ear vein was pricked after the application of methylated spirit and drop of blood was taken on the slide. Then, thin smear was made, air dried, fixed in methanol and stained with Field's stain (A & B). The thin smear was observed under the oil immersion lens (X100). Blood from cephalic vein was taken for the observation of a direct smear (wet smear) and for examining other haematological parameters. All the blood sampling on the animals was conducted during the process of diagnosing and treatment in the veterinary practice.

## RESULTS

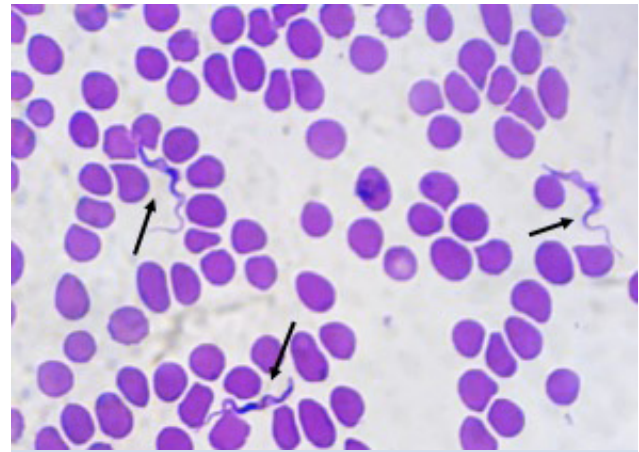
Wet smear revealed the presence of large number of motile trypanosomes. On the observation of thin smear of dog 1, trypanosomes with a characteristic flagellum, kinetoplast and undulating membrane were found outside the red blood cells (Figure 2). Results of haematological parameters have been summarized in the Table 1. The thin smear of second dog was also positive for trypanosomes (Figure 3). Babesio-

sis, theileriosis and anaplasmosis were excluded after examining a blood smear. Both the dogs were treated with diminazene aceturate (3.5 mg/kg b. w., intramus-

cularly) and other supportive therapy. With a single dose of diminazene aceturate, each dog recovered after follow up of 15 days.



**Figure 2.** *Trypanosoma* spp., dog 1, Field's-stained thin blood smear (X100)



**Figure 3.** *Trypanosoma* spp., dog 2, Field's-stained thin blood smear (X100)

**Table 1:** Haematological evaluation of dogs infected with trypanosomosis

Haematological parameter	Observed value (Dog 1)	Observed value (Dog 2)	Reference value
Platelets ( $10^9$ /L)	150	250	200–500
Erythrocytes ( $10^{12}$ /L)	4.5	5.5	5.5-8.5
Leucocytes ( $10^9$ /L)	12	10	6–17
Basophils ( $10^9$ /L)	0.02	0.01	rare
Monocytes ( $10^9$ /L)	0.88	0.86	0.15–1.35
Eosinophils ( $10^9$ /L)	0	0	0 0.1–1.25
Haemoglobin (g/dL)	8	11.5	12–18
Haematocrit (%)	30	38	37–55

## DISCUSSION

*Trypanosomosis* is of great economical and medical significance infecting a broad range of mammalian host including canines (Desquesnes et al., 2013). Despite that, reports on clinical disease in canines are limited (Aref et al., 2013; Rjeibi et al., 2015). The trypanosomes like *T. evansi*, *T. congolense*, *T. brucei*, and *T. cruzi* can infect dogs (Stephen, 1970; Abenaga et al., 2005). The clinical signs and morphological features of the trypanosomes found in the present study are in agreement with several reports (Savani et al., 2005; Sonika et al., 2007; Urquhart et al., 1996; Da Silva et al., 2009).

Since 1955, diminazene aceturate has been used as drug of choice for the treatment of trypanosomes infection in livestock. Diminazene use is limited in canine and equine species, besides being an effective trypanocidal drug (Desquesnes et al., 2013). Relapsing parasitaemia has been observed after the use of single dose of diminazene (intramuscular adminis-

tration) at 3.5 mg/kg in equines (Tuntasuvan et al., 2003) and at 5 mg/kg in dogs (Rjeibi et al., 2015). The relapsing parasitaemia may represent that drug, in case of central nervous system involvement, is not capable to cross the blood-brain barrier, its concentration in the plasma is not sufficient or drug resistance has developed (Da Silva et al., 2009). The factors like low therapeutic index, variable pharmacokinetics, excessive drug concentration in plasma, high doses, and adequate doses (given at short intervals) may contribute towards diminazene aceturate toxicosis (Flores et al., 2014; Echeverria et al., 2019). The mortality in dogs after diminazene diacetate (Rjeibiet al., 2015) and diminazene aceturate (Echeverria et al., 2019) therapy was also observed due to injury to the central nervous system. The recovery of the dog with diminazene aceturate was observed in this study which has also been observed by Gunaseelan et al. (2009) and Kumar (2017). Treatment of canine trypanosomosis with Cymelarsan® (Rhone Merieux, France) and mag-

nesium chloride has also been reported (Rashid et al., 2014).

Hematological analyses of blood of infected animals revealed anemia, hypoproteinemia and thrombocytopenia in this reported case of trypanosomiasis which is in agreement with Rjeibi et al. (2015). In a similar study, dog infected with trypanosomes represented increased erythrocyte sedimentation rate (ESR) and decreased packed cell volume (PCV) and haemoglobin (Rashid et al., 2008). Refractory hypoglycaemia occurs in dogs infected with *T. congolense* (Deschamps et al., 2016).

It is concluded, based on morphological features, that this is a case of trypanosomiasis but for species confirmation, molecular assays are required and single dose of diminazene aceturate may recover infect-

ed dogs. To our knowledge, it is first case report of trypanosomiasis in dogs in district Narowal, Pakistan which was successfully recovered with diminazene aceturate. The previous studies in Pakistan reported trypanosomes infection mostly in camels, equines, cattle, sheep, goat, bear and puma, while only two studies reported in dog so far; one in Faisalabad (2014) and other in Lahore (2008). Furthermore, one case of human African trypanosomiasis has also been reported in one of the Pakistan Army Troops in 2011, deployed to various countries of Africa as UN peace keepers. Such kind of reports may provide a way forward to establish effective and safe therapeutic protocols for canine trypanosomes.

### CONFLICT OF INTEREST

The authors declared that there is no conflict of interest.

## REFERENCES

- Abenga JN, Ezebuio CO, Kehinder D, Fajinmi AO, Samdi S (2005) Studies on anaemia in Nigerian local puppies infected with *Trypanosoma congolense*. Nigerian Institute for Trypanosomiasis Research, Kaduna, Nigeria. *Vet Archiv* 75:65-174.
- Bhardwaj RK, Singh R, Himalini, Virampal Singh (2015) Trypanosomiasis in a Bakerwali dog- a case report. *Indian J Anim Sci* 7:113-114.
- Da Silva AS, Zanette RA, Wolkmer P, Costa MM, Garcia HA, Lopes STA, Santurio JM, Teixeira MMG, Monteiro SG (2009) Diminazene aceturate in the control of *Trypanosoma evansi* infection in cats. *Vet Parasitol* 165:47-50.
- Defontis M, Richartz J, Englmann N, Bauer C, Schwierk VM, Büscher P, Moritz A (2012) Canine *Trypanosoma evansi* infection introduced into Germany. *Vet Clin Pathol* 41:396-374.
- Deschamps JY, Desquesnes M, Dorso L, Ravel S, Bossard G, Charbonneau M, Garand A, Roux FA (2016) Refractory hypoglycaemia in a dog infected with *Trypanosoma congolense*. *Parasite* 23:1.
- Desquesnes M, Dargantes A, Lai D, Lun Z, Holzmüller P, Jittapalpong S (2013) *Trypanosoma evansi* and surra: a review and perspectives on transmission, epidemiology and control, impact, and zoonotic aspects. *Biomed Res Int* 2013:321237.
- Echeverria JT, Soares RL, Crepaldi BA, Oliveira GG, Silva PMPD, Pupin RC, Martins TB, Cleveland HPK, Ramos CADN, Borges FA (2019) Clinical and therapeutic aspects of an outbreak of canine trypanosomiasis. *Rev Bras Parasitol Vet* 28:320-324.
- Eloy LJ, Luchesis SB (2009) Canine trypanosomiasis: etiology of infection and implication for public health. *J Venom Anim Toxins incl Trop Dis* 15:589-611.
- Flores MM, Pereira PR, Mazzanti A, Kommers GD, Figuera RA (2014) Aspectosepidemiológicos, clínicos e anatomopatológicos da intoxicação por acetato de diminazeno em cães. *Pesq Vet Bras* 34:667-674.
- Green CE (2006) Infectious diseases of dogs and cats. 3rd ed, Elsevier Inc: pp 676- 680.
- Gunaseelan L, Senthil KK, Selvaraj P, Kathiresan D (2009) Haematobiochemical changes in a case of canine trypanosomiasis. *Tamilnadu J Vet & Ani Sci* 4:122-123.
- Ian M, Peter HH, Michael AM (2004) The Trypanosomiasis. 1st ed, CABI Publication, Wallingford.
- Kumar S (2017) Trypanosomiasis in dog - a case report. *Explor Anim Med Res* 7:220-222.
- Medkour H, Laidoudi Y, Lafri I, Davoust B, Mekroudi A, Bitam I, Mediannikov O (2020) Canine vector-borne protozoa: Molecular and serological investigation for *Leishmania spp.*, *Trypanosoma spp.*, *Babesia spp.*, and *Hepatozoon spp.* in dogs from Northern Algeria. *Vet Parasitol Regional Studies and Reports* 19:100353.
- Morteza H, Dariush S, Sedighe, Seyed N, Ramin M (2007) *Trypanosoma evansi* in three dogs in Iran. *Comp Clin Pathol* 16:69-71.
- Rashid A, Rasheed K, Hussain A (2008) Trypanosomiasis in dog; a case report. *Iran J Arthropod Borne Dis* 2:48-51.
- Rashid I, Firyal S, Tariq A, Muhammad G, Saqib M, Zafar MS Use of cymelarsan® and manganese chloride for treatment of the canine trypanosomiasis. *Adv Anim Vet Sci* 2:104-105.
- Rjeibi MR, Hamida TB, Dalgatova Z, Mahjoub T, Rejeb A, Dridi W, Gharbi M (2015) First report of surra (*Trypanosoma evansi* infection) in a Tunisian dog. *Parasite* 22:3.
- Savani, ES, Nunes VL, Galati EA, Castilho TM, Araujo FS, Ilha IM, Carmargo MC, D'auria SR, Floeter-Winter LM (2005) Occurrence of co-infection by *Leishmania (Leishmania) chagasi* and *Trypanosoma (Trypanozoon) evansi* in a dog in the state of Mato Grosso do Sul, Brazil. *Mem Inst Oswaldo Cruz* 100:739-741.
- Sonika S, Sharma G, Juyal PD (2007) Trypanosomiasis in a German shepherd dog\_ a case report. *J Vet Parasitol* 21:81-82.
- Soulsby EJL (1982) Helminths, Arthropods and protozoa of domesticated animals. 7th ed, Bailliere Tindall, London.
- Stephen LE (1970) Clinical Manifestation of Trypanosomiasis in Livestock and other animals. HW Hulligan ed.
- Urquhart GM, Armour J, Duncan JL, Dunn AM, Jennings FW (1996) Veterinary Parasitology. 2nd ed, Blackwell Publishing (MA), UK: pp 212-218.
- Tuntasuvan D, Jarabrum W, Viseshakul N, Mohkaew K, Borisutsuwan S, Theeraphan A, Kongkanjana N (2003) Chemotherapy of surra in horses and mules with diminazene aceturate. *Vet Parasitol* 110:227-233.