ePublishing

ΕΘΝΙΚΟ ΚΕΝΤΡΟ ΤΕΚΜΗΡΙΩΣΗΣ
NATIONAL DOCUMENTATION CENTRE

Journal of the Hellenic Veterinary Medical Society

Vol 73, No 3 (2022)



Clinicopathological and biochemical evaluation of Feline Infectious Peritonitis in Turkish Van cats

M Özbek, C Özkan, A Kaya, S Yıldırım, S Kozat, Y Akgül

doi: 10.12681/jhvms.27159

Copyright © 2022, Cumali Özkan, Mustafa Özbek, Abdullah Kaya, Serkan Yıldırım, Süleyman Kozat, Yakup Akgül

This work is licensed under a Creative Commons Attribution-NonCommercial 4.0.

To cite this article:

Özbek, M., Özkan, C., Kaya, A., Yıldırım, S., Kozat, S., & Akgül, Y. (2022). Clinicopathological and biochemical evaluation of Feline Infectious Peritonitis in Turkish Van cats . *Journal of the Hellenic Veterinary Medical Society*, *73*(3), 4379–4388. https://doi.org/10.12681/jhvms.27159

https://epublishing.ekt.gr | **e-Publisher:** EKT | **Downloaded at:** 24/01/2026 09:54:50

J HELLENIC VET MED SOC 2022, 73 (3): 4379-4388
ΠΕΚΕ 2022, 73 (3): 4379-4388

Research article
Ερευνητικό άρθρο

Clinicopathological and biochemical evaluation of Feline Infectious Peritonitis in Turkish Van cats

M. Özbek[1*], C. Özkan[2], A.Kaya[2], S.Yıldırım[3], S. Kozat[2], Y. Akgül[2]

[1]*Afyon Kocatepe University, Bayat Vocational School, Department of Laborant and Veterinary Health, Afyon, Turkey*

[1] *Van Yuzuncu Yil University, Faculty of Veterinary Medicine, Department of Internal Medicine, Van, Turkey*

[2]*Ataturk University, Faculty of Veterinary Medicine, Department of Pathology, Erzurum, Turkey*

ABSTRACT: This study was performed to evaluate serum homocysteine and nitric oxide levels in cats with Feline Infectious Peritonitis and present biochemical and clinicopathological alterations related to the disease. The material of this study consisted of 30 Turkish Van Cats of different ages and genders with Feline Infectious Peritonitis that were definitely diagnosed by post-mortem examinations and immunohistochemistry. The control group consisted of 6 healthy Turkish Van Cats of different ages and genders that were brought for routine clinical examination. Cats in the study group had clinical findings such as loss of appetite, weight loss, high fever, persistent fever, jaundice, dehydration, vomiting, respiratory system symptoms, anemia, nervous findings, uveitis, and ascites. These cats were monitored and following the death, post-mortem examinations were performed and cases with a definitive diagnosis were included in the study. Among the cats consisting study group, while 25 had the dry form of the disease, 5 had wet form. According to the hematological results, there was a statistically significant reduction in platelet counts. The biochemical results showed statistically significant alterations that creatinine, aspartate aminotransferase, alkaline phosphatase, creatine kinase myocardial band, homocysteine, and nitric oxide concentrations were higher than the control group. Besides albumin concentrations were lower and the albumin/globulin ratio was 0.53. As a result; this is the first detailed study in Turkish Van Cats with Feline Infectious Peritonitis that evaluated clinical, hematological, biochemical, and pathological findings. Furthermore, serum homocysteine and nitric oxide levels were evaluated for the first time in cats with vasculitis which is the most important complication of the disease. It is concluded that the evaluation of serum homocysteine and nitric oxide concentrations in Feline Infectious Peritonitis may assist the antemortem diagnosis of e disease.

Keywords: Cats, Feline infectious peritonitis, Homocysteine, Nitric oxide, Vasculitis

Corresponding Author:
Mustafa Özbek.Van Yuzuncu Yil University, Faculty of Veterinary Medicine, Department of Internal Medicine, 65080, Van, Turkey
E-mail address: mozbek@dr.com

Date of initial submission: 30-05-2021
Date of acceptance: 01-08-2022

INTRODUCTION

Feline Infectious Peritonitis (FIP) is a fatal disease caused by Feline Coronavirus (FeCoV) (Pedersen, 2009; Kipar and Meli, 2014). FeCoV generally leads to mild diarrhea, while the mutated virus causesa mortal disease that is called Feline Infectious Peritonitis (Paltrinieri et al., 2001; German, 2012; Pedersen 2014). There is not any known definitive treatment of the disease, nevertheless, to increase the survival and life quality of the patients, several symptomatic therapies, as well as supportive treatments are necessary. However, death is inevitable due to vasculitis and pathological disorders in multiple organs (Hartmann et al., 2003; Kipar et al., 2005; Addie et al., 2009; Pedersen, 2009).

According to previous studies, alterations in serum homocysteine (Hcy) and nitric oxide (NO) concentrations were associated with vascular and cardio-vascular disorders (Stein and McBride, 1998; Hankey and Eikelboom, 1999; Chai and Abrams, 2001). Hcy increase was reported in several diseases and gained importance in the early diagnosis especially of cardiovascular disorders. Several studies are present in human medicine related to the effect of Hcy on the cardiovascular system, however, there are not numerous detailed studies in veterinary medicine related to FIP (McMichael et al., 2000; Kural et al., 2003; Stangl et al., 2000; Rezaei and Dalir-Naghadeh, 2009; Uren et al., 2009; Nursalim et al., 2013).

The purpose of this study was to evaluate serum homocysteine and nitric oxide levels in cats with Feline Infectious Peritonitis and evaluate biochemical and clinicopathological alterations related to the disease.

MATERIALS AND METHODS

The material of this study consisted of 30 Turkish Van Cats of different ages (1.15±0.82 years) and genders that were brought to the clinics of Van Yuzuncu Yil University, Faculty of Veterinary Medicine, Department of Internal Medicine. The control group consisted of 6 healthy cats of different ages (1.22±0.94 years) and genders that were brought for routine clinical examination. This study was performed withpermission of the Animal Experiments Local Ethics Committee, Rectorship of Van Yuzuncu Yil University (March 2th, 2017 - 2017/02).

Clinical examinations of the cats were performed and cats that were suspected of FIP were included in the study. Blood samples were obtained from radial veins and transferred to tubes containing EDTA and coagulant-free tubes for hematological and biochemical analyses, respectively. Hematological analyses were performed in hematology analyzer device (MS4-s Haematology Analyzer S.N. JCS211, France) and blood samples in coagulant-free tubes were centrifuged for 15 mins with 3000 RPM (Rotofix 32®-Hettich) to extract serum samples. The samples were stored at -20 °C until biochemical analyses.

Considering the clinical examinations and alterations in hematological and biochemical parameters, the cats who received routine symptomatic and supportive treatment with a pre-diagnosis of the disease were recorded and monitored. Animals that died during this period despite receiving treatment were prepared for necropsy. Necropsy was performed on the animals and following necropsy examination, macroscopic findings were recorded and tissue samples were obtained from the specific lesions for histopathological examination to perform definitive diagnosis. For histopathological examination, tissue samples obtained from brain, lung, liver, kidney, spleen, and intestines were fixed in 10% formalin solution for 48 hours. Following the fixation, the samples were embedded into paraffin blocks and tissue sections were cut in 4µm thickness. Preparations were stained with hematoxylin-eosin (HE) and examined under light microscope (Leica DM 1000, Germany). Besides, all of the sections taken to adhesive (poly-L-Lysin) glasses were passed through xylol and alcohol series, deparaffinized and dehydrated, and washed with distilled water for 5 minutes. Afterward, preparations were washed with phosphate buffer solution (PBS, pH 7.2) for 5 minutes, held in hydrogen peroxide solution (3%) and endogenous peroxidase was added. After rewashing with PBS for 5 minutes, protein blocks suitable with all primary and secondary antibodies were incubated for 5 minutes to avoid nonspecific surface staining. At the end of the incubation, extra amount of block solution over tissue sections were poured and primary FIP antibody (Catalog no: Rab11-FIP1 Antibody, Santa Cruz, USA) was dropped and incubated for one night in +4 °C. Sections were washed twice for 5 minutes and incubated with secondary antibody for 30 minutes under room temperature. After incubation, sections were rewashed with PBS and held in streptavidin-peroxidase for 30 minutes and again washed with PBS. Following the washing processes, 3-amino-9-ethyl-carbazole (AEC) was dropped on each tissue sections and incubated for 10 minutes. Then the

sections were held in Mayer's hematoxylen for 2 minutes for surface staining and washed under tap water. Eventually aquous adhesive was dripped and covered with glass and examined under light microscope (Leica DM 1000).

Hematocrit (Hct), hemoglobin concentration (Hgb), total leukocyte (WBC), erythrocyte (RBC), and platelet (PLT) counts were obtained. For biochemical analyses, total protein (TP), albumin (ALB), globulin (GLB), glucose (GLU), blood urea nitrogen (BUN), creatinine (CREA), aspartate aminotransferase (AST), alkaline phosphatase (ALP), alanine aminotransferase (ALT), lactate dehydrogenase (LDH), creatine kinase (CK), creatine kinase - myocardial band (CK-MB), total bilirubin (TBIL), direct bilirubin (DBIL), calcium (Ca), magnesium (Mg), phosphorus (P), triglyceride (TG), low-density lipoprotein (LDL), very-low-density lipoprotein (VLDL), iron (Fe), sodium (Na), potassium (K) and chloride (Cl) concentrations were measured in the auto-analyzer device (Cobas-6000 c501, Roche-Hitachi).

Serum homocysteine and nitric oxide concentrations were colorimetrically measured in ELISA device (ELISA reader®-DAS, Italy) according to each kits' procedure (Homocysteine ELISA Kit-CUSABIO, Catalog Number; CSB-E13814h; Nitrate/nitrite colorimetric assay kit, Cayman Chemical Company, catalog No: 780001/USA; respectively). Serum vitamin B_{12} and folate levels were measured in hormone device (Cobas-6000 e601, Roche-Hitachi).

As there are not any present Hcy and Nitrate/nitrite kits validated for use in feline serum samples, kits which were validated for use in humans were used in the study. This is a study limitation, and further studies may be necessary to validate the results in feline serum samples.

Statistical analyses were performed by using SPSS (for Windows ver. 22.0) statistical package software. Independent samples t-test was used to compare the arithmetic means and standard errors (SEM). Statistical $p < 0.05$ values were accepted as significant in the calculations.

RESULTS

Clinical findings

According to the clinical examinations, while 25 of the cats were suspected with dry form of the disease, 4 had wet form, and 1 had a mixed form. 18 of the suspected cats were male and 12 of them were female. Eighteen of the animals were less than 1 year old, 9 of them were 1-2 years old, and 3 of them were over 2 years old. Loss of appetite, weight loss, high fever which did not decrease despite using antibiotics, jaundice, dehydration, vomiting, respiratory system symptoms, anemia, nervous findings (2/30), uveitis (3/30), and ascites (5/30) were observed in animals as general clinical findings. Especially in animals with the dry form, pyogranulomatous lesions were detected especially in the kidney and gastrointestinal tract by palpation of the abdominal region.

Hematological findings

Hct, Hb, RBC, and thrombocyte levels of the animals in the study group were found to be lower than the control group, and there was a significant increase in WBC values ($p < 0.05$). While there was a dramatic decrease in platelet count ($p < 0.05$), the changes in other parameters were not found to be statistically significant (Table 1).

Biochemical findings

TP values were found to be close to each other in the control group and study group, but albumin levels in sick animals were statistically lower ($p < 0.01$)

Table 1. Some hematological parameter values and statistical comparisons of control and study group.

Parameters	Control group n: 6 ($\bar{x}\pm S\bar{x}$)	Study group n: 30 ($\bar{x}\pm S\bar{x}$)
Hct (%)	40.57±2.18	30.00±326
Hgb (g/dl)	13.35±1.07	10.14±1.11
WBC (m/mm^3)	10.72±0.76	19.59±4.71
RBC (M/mm^3)	8.26±0.11	6.88±0.41
PLT (m/mm^3)	336.75±65.44	147.40±49.44*

*: p<0.05, Hct: Hematocrit, Hgb: Hemoglobin, WBC: White Blood Cell Count, RBC: Red Blood Cell Count, PLT: Platelet Count

and there was a significant increase in globulin values, however, this increase was not statistically significant. In addition, BUN values were higher and creatinine values increased statistically in animals in the patient group ($p < 0.001$). However, there was a decrease in ALP levels, increases in AST, ALT, LDH, CK, CK-MB, total and direct bilirubin levels in sick animals, and the increase in total and direct bilirubin levels were statistically significant ($p < 0.001$) (Table 2).

Serum homocysteine and nitric oxide concentrations were found to be higher in cats with FIP when compared with the control group. The increase in

Table 2. Some biochemical parameters and statistical comparisons of control and study group.

Parameters	Control group n: 6 ($\bar{x}\pm S\bar{x}$)	Study group n: 30 ($\bar{x}\pm S\bar{x}$)
TP (g/dL)	7.50±0.16	7.45±0.37
ALB (g/dL)	3.50±0.15	2.53±0.09**
GLB (g/dL)	4.17±0.30	4.90±0.28
ALB/GLB	0.88±0.10	0.53±0.03*
GLU (mg/dL)	63.17±5.54	119.25±19.51*
BUN (mg/dL)	18.83±0.70	38.90±11.39
CREA (mg/dL)	1.16±0.05	1.65±0.08***
AST (U/L)	17.12±1.33	183.75±43.48**
ALP (U/L)	41.17±7.26	15.00±4.71**
ALT (U/L)	33.42±3.88	95.28±35.34
LDH (U/L)	15.86±2.28	38.39±8.39
CK (U/L)	119.50±18.07	565.00±179.10
CK-MB (U/L)	37.61±22.97	224.82±66.34*
TBIL (mg/dL)	0.03±0.00	4.42±0.99**
DBIL (mg/dL)	0.02±0.00	4.13±1.03**
Ca (mg/dL)	8.98±0.28	8.76±0.30
Mg (mg/dL)	2.06±0.05	2.77±0.21*
P (mg/dL)	5.25±0.35	6.97±0.39*
Chol (mg/dL)	110.43±9.65	131.96±18.78
TG (mg/dl)	54.16±9.94	125.11±21.80*
LDL Chol (mg/dL)	15.86±2.28	38.39±8.39*
VLDL Chol (mg/dL)	10.83±2.06	24.30±4.55*
Fe (ug/dL)	82.16±12.61	151.50±41.00
Na (mmol/L	152.00±1.03	143.10±2.77*
K (mmol/L)	4.58±0.08	3.73±0.24*
Cl (mmol/L)	110.85±0.72	100.60±3.01*

*: p<0.05, **: p<0.01,***: p<0.001, TP: Total protein, ALB: Albumin, GLB: Globulin, GLU: Glucose, BUN: Blood Urea Nitrogen, CREA: Creatinine, AST: Aspartate Aminotransferase, ALP: Alkaline Phospatase, ALT: Alanine Aminotransferase, LDH: Lactate Dehydrogenase, CK: Creatine Kinase, CK-MB: Creatine Kinase Myocardial Band, TBIL: Total Bilirubin, DBIL: Direct Bilirubin, Ca: Calcium, Mg: Magnesium, P: Phosphorus, Chol: Cholesterol, TG: Triglyceride, LDL Chol: Low Density Lipoprotein Cholesterol, VLDL Chol: Very Low Density Lipoprotein Cholesterol, Fe: Iron, Na: Sodium, K: Potassium, Cl: Chloride

Table 3. Serum homocysteine and nitric oxide concentrations and statistical comparisons of control and study group.

Parameters	Control group n: 6 ($\bar{x}\pm S\bar{x}$)	Study group n: 30 ($\bar{x}\pm S\bar{x}$)
Hcy (nmol/mL)	9.80±4.54	24.15±2.66*
NO (µmol/L)	54.54±4.20	158.70±14.32**
Vitamin B_{12} (pg/mL)	573.83±43.36	744.36±274.03
Folate (ng/mL)	17.00±0.85	17.70±0.59

*: p<0.05, **: p<0.01, Hcy: Homocysteine, NO: Nitric Oxide

these parameters were statistically significant ($p < 0.05$, $p < 0.01$, respectively) (Table 3). Besides vitamin B12 and folate levels were also found to be higher, however, these increases were not statistically significant ($p > 0.05$).

Pathological findings

According to the necropsy findings; macroscopically severe jaundice in the mucous membranes and approximately one liter of a dark, yellow, fibrinous, coagulating effusion fluid was found in the abdominal cavity in animals with wet form (Figure 1). In animals with the dry form, grayish-white granulomatous lesions close to serosa and serous atrophy in adipose tissues were detected in organs such as kidneys, liver, intestines, lung, spleen and brain (Figure 2 and Figure 3).

Figure 1. Fibrinous effusion fluid in the abdominal cavity, fibrinous (arrows) and granulomatous lesions in the intestinal serosa in a cat with the wet form of FIP.

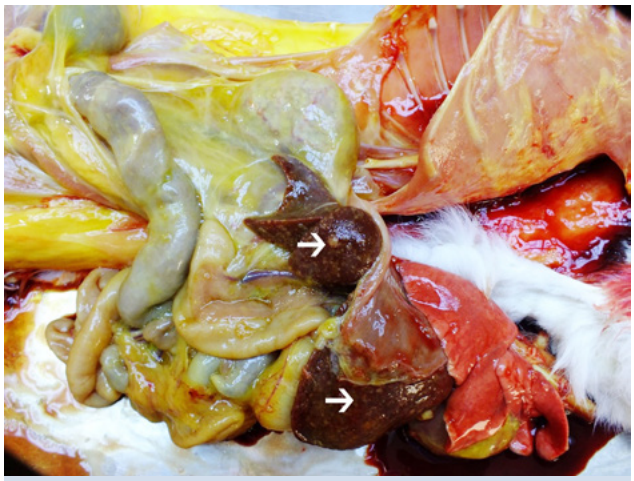

Figure 2. Multiple granulomatous lesions (arrows) in the liver and severe jaundice in the subcutaneous tissue in a cat with the dry form of FIP.

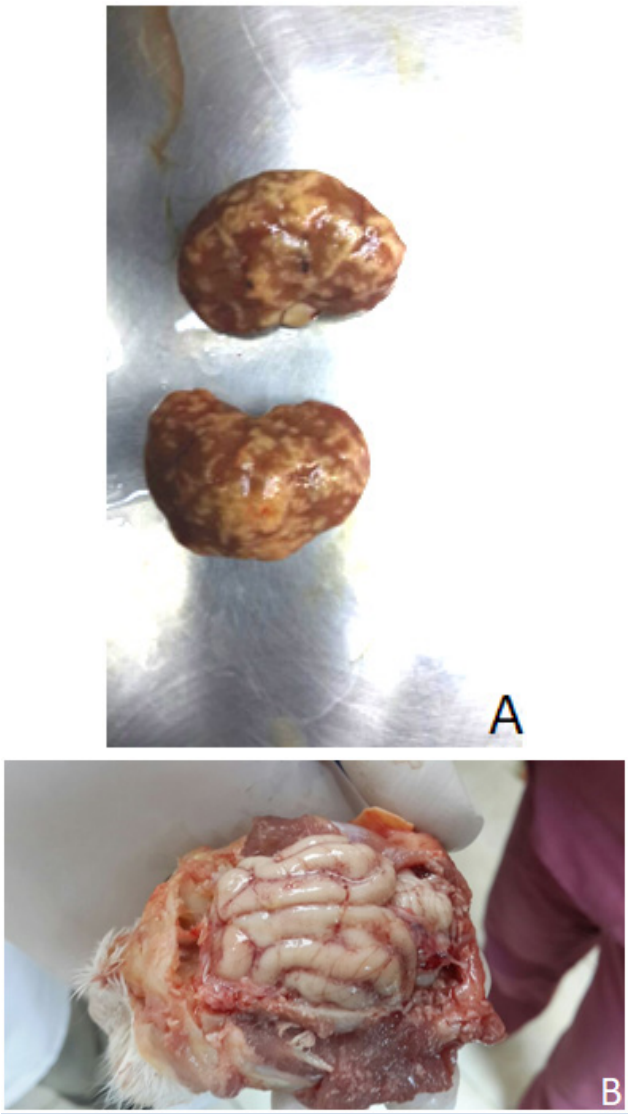

Figure 3. Pyrogranulomatous lesions in various tissues. A: Kidneys, B: Brain Tissue.

According to the histopathological examinations; advanced pyogranulomas, particularly on kidney, liver, intestine, lung, spleen, and brain tissues, mostly in the serosa, and in some cases, deeper in parenchyma tissues were detected in animals with the dry form. A necrotic mass was observed in the middle of these pyogranulomas surrounded by dense neutrophil leukocyte infiltration, macrophage, and lymphocyte infiltrations (Figure 4).

According to the immunohistochemical examinations, the agent was detected in organs with lesions in necrotic mass in the middle of granulomatous lesions and in neutrophils and macrophages which surrounded the lesions (Figure 5).

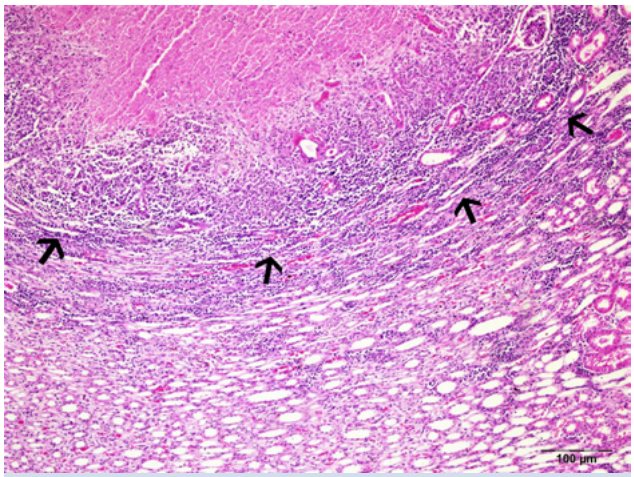

Figure 4. Pyogranuloma in the intertubular space of kidney tissue. Necrosis, neutrophil, macrophage, and lymphocyte infiltrates (arrows), H&E, Bar:100µm.

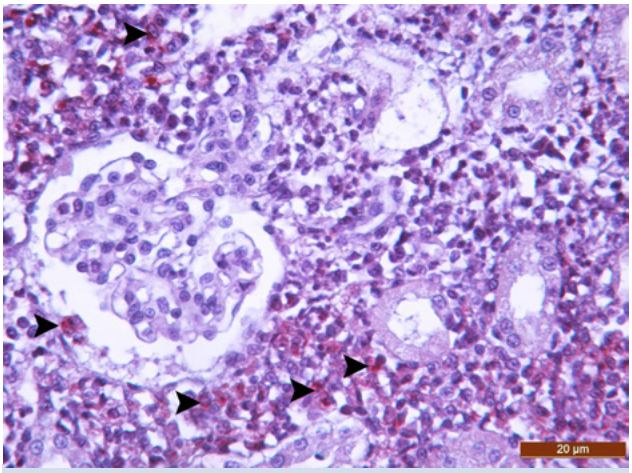

Figure 5. Neutrophils and macrophages on the granulomatous lesions in the intertubular spaces of kidney tissue (arrows), IHC-P, Bar:20µm.

DISCUSSION

FIP is a fatal disease of cats and has a complex and controversial diagnosis. The absence of pathognomonic and specific clinical, hematological and biochemical findings in both forms of the disease, and the lack of routine specific tests make the definitive diagnosis quite difficult. It has been reported that anamnesis, clinical findings, alterations in hematological and biochemical parameters, PCR tests, and serum antibody titers should be evaluated together for diagnosis (Hartmann et al., 2003; Paltrinieri et al., 2001; Norris et al., 2005; Addie et al., 2009; Pedersen, 2009; Tsai et al., 2011; Pedersen, 2014). Although serum antibody titers assist diagnosis, detected FCoV antibody titers do not mean that FIP is positive. Although many researchers have used RT-PCR or real-time RT-PCR to detect FCoVs in cats with FIP, it is still challenging to effectively distinguish FIPVs from FCoVs (Guan et al., 2020). Therefore, the most valuable diagnostic method is reported to be the histopathological findings and immunohistochemistry (Paltrinieri et al., 2001; Hartmann et al., 2003; Norris et al., 2005; Addie et al., 2009; Pedersen, 2009). Hence, in this study, patients suspected of the disease and found to be FIP positive following post-mortem examinations were included in the study.

In this study, severe jaundice in mucous membranes, fluid accumulation in the abdominal cavities, gray-white granulomatous lesions in various organs, and serous atrophy in adipose tissues were observed macroscopically. Microscopically; pyogranulomas advanced to deeper parenchymal tissue, mostly in the serosa, were found in various organs. By immunohistochemical examinations, agents were detected in organs with lesions, necrotic masses in the middle of granulomatous lesions, as well as neutrophils and macrophages. It was determined that these findings were consistent with the pathological findings reported in previous studies (Paltrinieri et al., 2001; Addie et al., 2009; Diaz and Poma, 2009; Pedersen, 2009).

In this study, clinical symptoms such as anorexia, weight loss, high fever, the persistence of fever despite using antibiotics, jaundice, dehydration, vomiting, respiratory system symptoms, anemia, nervous symptoms, uveitis, and ascites were observed in animals. On the other hand, particularly in animals with the dry form, clinical findings of the affected organs were notably distinct, and pyogranulomatous lesions in the kidney and GIS of some animals were clearly detected in the palpation of the abdominal regions. Besides clinical symptoms of the disease were not completely remarkable, and occasionally aggravated in these animals. In previous studies (Paltrinieri et al., 2001; Addie et al., 2009; Diaz and Poma, 2009; Pedersen, 2009; Tsai et al., 2011; Pedersen, 2014), non-specific alterations in some hematological parameters were reported in cats with FIP, because there may be increases or decreases in WBC levels, lymphopenia and neutrophilia may be observed and usually are associated with the stress leukogram that may also be seen in several other diseases. In addition, mild or moderate non-regenerative anemia is another common hematological condition detected in the disease. Likewise, it is reported that this condition can be seen in many other chronic disorders in cats. In this study, there was a decrease in Hct, Hb, and RBC

levels, and an increase in WBC counts in cats with FIP which were not statistically significant. However, PLT counts were low and the decrease was statistically significant ($p < 0.05$).

Parallel to the previous reports (Diaz and Poma, 2000; Paltrinieri et al., 2001; Addie et al., 2009; Pedersen, 2009; Tsai et al., 2011; Pedersen, 2014), anemia and increased WBC counts were determined in cats with FIP in this study. Besides PLT levels were significantly low and attributed to the vasculitis that occurs in the disease. Furthermore, it has been reported that the decreases in PLT levels may also be due to the migration of the activated platelets towards the affected organ and disseminated intravascular coagulopathy (DIC) which occurs in cases of infectious diseases and endotoxemia (Nyarko et al., 1998; Kuckleburg et al., 2008).

Alterations in some biochemical parameters are also observed in FIP disease. It has been reported that an increase in serum protein and globulin levels and a decrease in serum albumin levels in cats with FIP may be observed (Addie et al., 2009; Pedersen, 2009; Diaz and Poma, 2009; Pedersen, 2014). However, in some cases where the liver is severely affected, serum TP concentrations may decrease. In addition, a decrease in serum TP levels may also be seen due to the protein losses in animals with glomerular dysfunction and the transfer of protein-rich fluid to the extravascular area in animals with vasculitis (Throop et al., 2004; Addie et al., 2009; Fischer et al., 2012; Riemer et al., 2016). It is stated that the albumin/globulin ratio is one of the golden standard diagnostic parameters for FIP, and the albumin/globulin ratio less than 0.4 can be positive evidence and in healthy cats, this ratio is usually greater than 0.8. According to the previous studies, it is reported that in 50% of cats with effusion and in 70% of cats without effusion, hypergammaglobulin was detected in the blood, and protein levels in the fluid obtained from animals with effusion were found in high concentrations (Paltrinieri et al., 2001; Norris et al., 2005; Addie et al., 2009; Pedersen, 2009; Tsai et al., 2011). Furthermore, biochemical parameters can be variable due to the lesions in which they are located. There may be an increase, particularly in liver enzymes, urea and creatinine concentrations. Detection of hyperbilirubinemia and jaundice also indicates liver damage. It has been reported that the increase in bilirubin concentration in the blood assists the diagnosis in FIP (Addie et al., 2009; Pedersen, 2009; Tsai et al., 2011).

In our study, TP concentrations were similar in both control and study groups, however, albumin levels were lower in sick animals, and this decrease was statistically significant ($p < 0.01$). Globulin concentrations were higher in cats with FIP, however, this increase was not statistically significant ($p > 0.05$). However, while the albumin/globulin value was determined as 0.88 ± 0.10 in the control group animals, this value was determined as 0.53 ± 0.03 in the study group that was also statistically significant ($p < 0.05$). The decrease in ALP, increases in AST, ALT, LDH, CK, CK-MB, total and direct bilirubin concentrations in sick animals, and especially increase in total and direct bilirubin levels were found to be statistically significant. Besides, there was an increase in BUN and creatinine concentrations in animals in the study group. Alterations in biochemical parameters in our study correspond with the previously reported studies (Paltrinieri et al., 2001; Pedersen, 2009; Addie et al., 2009; Diaz and Poma, 2009; Tsai et al., 2011; Riemer et al., 2016).

Homocysteine is a sulfurous amino acid that is formed as a result of methionine metabolism and is not present in the primary structure of proteins (Stein and McBride, 1998; Rezaei and Dalir-Naghadeh, 2009; Uren et al., 2009; Nursalim et al., 2013). When homocysteine concentrations increase, it leads to several harmful effects in the body such as endothelial damage which can be like the effects of free radicals. Although the mechanism of the vascular damage caused by homocysteine is not fully elucidated, it has been reported that it may be caused by the oxidative damage and eventual platelet dysfunction in the vascular endothelium, and increase in coagulation (Stein and McBride, 1998; McMichael et al., 2000; Gauthier et al., 2003; Uren et al., 2009; Nursalim et al., 2013).

NO is synthesized from L-arginine and has several physiological functions such as endothelial inhibition, vasodilation, platelet aggregation, and adhesion, reduction of vascular smooth muscle cell proliferation, relaxation in vascular endothelium, neurotransmitting, immunomodulating. Furthermore, NO also has antioxidant and prooxidant roles. It has been reported that while the secretion of nitric oxide at basal levels is involved in physiological events, its excessive release has pathological consequences by destructing the cells (Turkoz and Ozerol, 1997; Alderton et al., 2001; Bruckdorfer, 2005).

In recent years, according to the studies in the field of human medicine (Kural et al., 2003; Nursalim et

al., 2013; Bostom and Lathrop, 1997), increase in homocysteine levels was reported in many diseases, particularly in cardiovascular diseases. It is reported that alterations in Hcy levels is reported to be important in the early diagnosis of cardiovascular diseases. While there are numerous studies in human medicine regarding the effects of Hcy on the cardiovascular system, detailed research has not been performed in the field of veterinary medicine, particularly on cats. In this study, serum Hcy and NO concentrations were found to be increased in cats with FIP and this increase was statistically significant. According to the studies in human medicine (Stein and McBride, 1998; Hankey and Eikelboom, 1999; Chai and Abrams, 2001; Nursalim et al., 2013; Gauthier et al., 2003), increase in Hcy concentrations was attributed to the damage in the vascular endothelium, and in this study, it is thought that increase in Hcy concentrations (24.15 ± 2.66 nmol/mL) in sick cats compared to healthy cats (9.80 ± 4.54 nmol/mL) is associated with damage in vascular endothelium and vasculitis that resulted by FIP. Regarding NO concentrations in human medicine (Stein and McBride, 1998; Hankey and Eikelboom, 1999; Chai and Abrams, 2001), decreases in serum NO levels were reported due to the vascular endothelium damage. Besides, in several previous studies Hcy levels were reported to increase due to kidney and liver disorders. In kidney disorders while Hcy increase was associated with the deterioration of transferase mechanism, in liver disorders it is associated with the impairment in methylation reactions (Bosy-Westphal et al., 2001; Ward, 2001; Siow, 2018).

Contrary to these reports, in this study, there was an increase in serum NO levels in cats with FIP (158.70 ± 14.32 µmol/L) than healthy cats (54.54 ± 4.20 µmol/L). This increase is thought to occur due to the increase in total leukocyte levels that are increased by the disease, as NO is released from leukocytes due to the effect of iNOS. Besides, in studies regarding NO (Turkoz and Ozerol, 1997; Alderton et al., 2001; Bruckdorfer, 2005), leukocyte counts may increase in various viral, bacterial, and parasitic diseases which also results in an increase in serum NO concentrations.

CONCLUSIONS

As a result; this is the first detailed study in Turkish Van Cats with FIP that reported the significant changes in clinical, hematological, biochemical, and pathological findings. Furthermore, serum homocysteine and NO concentrations were evaluated for the first time in cats with vasculitis which is the most important complication of FIP. It is concluded that presenting the current study is believed to enlighten future studies regarding this subject. In addition, it was concluded that the evaluation of serum homocysteine and nitric oxide concentrations in FIP may be helpful in the antemortem diagnosis of FIP.

CONFLICT OF INTEREST

The authors declare no conflict of interest.

ACKNOWLEDGEMENTS

This study was funded by Van Yuzuncu Yil University, Presidency of Scientific Research Project (Project No: TSA-2017-5941).

REFERENCES

Addie D, Belak S, Boucraut-Baralon C, Egberink H, Frymus T, Gruffydd-Jones T, Hartmann K, Hosie MJ, Lloret A, Lutz H, Marsilio F, Pennisi MG, Radford AD, Thiry E, Truyen U, Horzinek MC (2009). Feline Infectious Peritonitis. ABCD guidelines on prevention and management. JFMS 11:594-604.

Alderton WK, Cooper CE, Knowles RG (2001). Nitric Oxide Synthases: Structure, Function and Inhibition. Biochem J 357:593-615.

Bostom AG, Lathrop L (1997). Hyperhomocysteinemia in end-stage renal disease: Prevalence, etiology, and potential relationship to arteriosclerotic outcomes. Kidney Int 52:10-20.

Bosy-Westphal A, Petersen S, HinrichsenH, Czech N, Müller MJ (2001). Increased plasma homocysteine in liver cirrhosis. HepatolRes 20: 28-38.

Bruckdorfer R (2005). The basics about nitric oxide. Mol Aspects Med 26:3-31.

Chai AU, Abrams J (2001). Homocysteine: A New Cardiac Risk Factor? Clin Cardiol 24:80-84.

Diaz JV, Poma R (2009). Diagnosis and clinical signs of feline infectious peritonitis in the central nervous system. Can Vet J 50:1091-1093.

Fischer Y, Sauter-Louis C, Hartmann K (2012). Diagnostic accuracy of the Rivalta test for feline infectious peritonitis. Vet Clin Pathol 41:558-567.

Gauthier GM, Keevil JG, Mcbride PE (2003). The association of homocysteine and coronary artery disease. Clin Cardiol 26:563-568.

German A (2012). Update on feline infectious peritonitis. In Practice 34:282-291.

Guan X, Li H, Han M, Jia S, Feng B, Gao X, Wang Z, Jiang Y, Cui W, Wang L, Xu Y (2020). Epidemoiological investigation of feline infectious peritonitis in cats living in Harbin, Northeast China from 2017 to 2019 using a combination of an EvaGreen-based real-time RT-PCR and serum chemistry assays. Mol Cell Probes 49:101495.

Hankey GJ, Eikelboom JW (1999). Homocysteine and vascular disease. Lancet 354:407-413.

Hartmann K, Binder C, Hirschberger J, Cole D, Reinacher M, Schroo S, Frost J, Egberink H, Lutz H, Hermanns W (2003). Comparison of Different Tests to Diagnose Feline Infectious Peritonitis. JVIM 17:781-790.

Kipar A, May H, Menger S, Weber M, Leukert W, Reinacher M (2005). Morphologic features and development of granulomatous vasculitis in feline infectious peritonitis. Vet Pathol 42:321-330.

Kipar A, Meli ML (2014). Feline infectious peritonitis: Still an enigma? Vet Pathol 51:505-526.

Paltrinieri S, Grieco V, Comazzi S, Parodi MC (2001). Labaratory profiles in cats with different pathological and immunohistochemical findings due to feline infectious peritonitis (FIP). JFMS 3:149-159.

Kuckleburg CJ, McClenahan DJ, Czuprynski CJ (2008). Platelet activation by Histophilus somni and its LOS induces endothelial cell pro-inflammatory responses and platelet internalization. Shock 29:189-196.

Kural BV, Orem A, Cimsit G, Uydu HA, Yandi YE, Alver A (2003). Plasma homocysteine and its relationships with atherothrombotic markers in psoriatic patients. Clin Chim Acta 332:23-30.

McMichael M, Freeman LM, Selhub J, Rozanski EA, Brown DJ, Nadeau MR, Rush JE (2000). Plasma homocysteine, B vitamins, and amino acid concentrations in cats with cardiomyopathy and arterial thromboembolism. JVIM14:507-512.

Norris JM, Bosward KL, White JD, Baral RM, Catt MJ, Malik R (2005). Clinicopathological findings associated with feline infectious peritonitis in Sydney, Australia: 42 cases (1990-2002). Aust Vet J 83:666-673.

Nursalim A, Siregar P, Widyahening IS (2013). Effect of folic acid, vitamin B6 vitamin B12 supplementation on mortality and cardiovascular complication among patients with chronic kidney disease:An evidence-based case report. Acta Med Indones 45:150-156.

Nyarko KA, Coomber B, Mellors A, Gentry AP (1998). Bovine platelet adhesion is enhanced by leukotoxin and sialoglycoprotease isolated from *Pasteurella haemolytica* A1 cultures. Vet Microbiol 61:81-91.

Pedersen NC (2009) A review of feline infectious peritonitis virus infection: 1963- 2008. JFMS 11:225-258.

Pedersen NC (2014). An update on feline infectious peritonitis: diagnostics and therapeutics. Vet J 2014 201:133-141.

Rezaei SA, Dalir-Naghadeh B (2009). Association of plasma and heart homocysteine and blood malondialdehyde with cardiovascular diseases induced by acute selenium deficiency in lambs. Small Rumin Res 83:22-28.

Riemer F, Kuehner KA, Ritz S, Sauter-Louis C, Hartmann K (2016). Clinical and laboratory features of cats with feline infectious peritonitis - a retrospective study of 231 confirmed cases (2000-2010). JFMS 18:348-356.

Stangl K, Cascorbi I, Stangl V, Laule M, Dschietzig MD, Richter C, Felix SB, Roots I, Baumann G (2000). Hyperhomocysteinaemia and adverse events complicating coronary catheter interventions. Int J Cardiol 76:211-217.

Siow YL (2018). Metabolic imbalance of homocysteine and hydrogen sulfide in kidney disease. Curr Med Chem 25: 367-377.

Stein JH, McBride PE (1998). Hyperhomocysteinemia and atherosclerotic vascular disease. Arch Intern Med 158:1301-1306.

Throop JL, Kerl ME, Cohn LA (2004). Albumin in health and disease: causes and treatment of hypoalbuminemia. Compend 26:940-948.

Tsai HY, Chueh LL, Lin CN, Su BL (2011). Clinicopathological findings and disease staging of feline infectious peritonitis: 51 cases from 2003to 2009 in Taiwan. JFMS 13:74-80.

Turkoz Y, Ozerol E (1997). Nitric oxide: actions and pathological roles. J Turgut Ozal Med Cent4:453-461.

Uren N, Fidanci UR, Kirmizigül AH, Fidanci V, Pekcan M (2009). Homocysteine levels in cats with chronic renal failure. J Fac Vet Med Kafkas Uni 15: 543-546.

WardM (2001). Homocysteine, folate, and cardiovascular disease. Int J Vitam Nutr Res 71: 173-178.