ePublishing
ΕΘΝΙΚΟ ΚΕΝΤΡΟ ΤΕΚΜΗΡΙΩΣΗΣ
NATIONAL DOCUMENTATION CENTRE

Περιοδικό της Ελληνικής Κτηνιατρικής Εταιρείας

Τόμ. 72, Αρ. 2 (2021)



Pseudo-pericarditis in two cows with tropical theileriosis: clinical, haematological and biochemical findings

Ş. DEĞIRMENÇAY, A. KIRBAŞ, K.E. YANAR, M.S. EROĞLU

doi: 10.12681/jhvms.27544

Copyright © 2021, Ş. DEĞIRMENÇAY, A. KIRBAŞ, K.E. YANAR, M.S. EROĞLU

Άδεια χρήσης Creative Commons Αναφορά-Μη Εμπορική Χρήση 4.0.

Βιβλιογραφική αναφορά:

DEĞIRMENÇAY, Ş., KIRBAŞ, A., YANAR, K., & EROĞLU, M. (2021). Pseudo-pericarditis in two cows with tropical theileriosis: clinical, haematological and biochemical findings. *Περιοδικό της Ελληνικής Κτηνιατρικής Εταιρείας*, *72*(2), 2993–3000. https://doi.org/10.12681/jhvms.27544

J HELLENIC VET MED SOC 2021, 72(2): 2993-3000
ΠΕΚΕ 2021, 72(2): 2993-3000

Case report
Κλινικό περιστατικό

Pseudo-pericarditis in two cows with tropical theileriosis: clinical, haematological and biochemical findings

Ş. Değirmençay[1*], A. Kırbaş[2], K. E. Yanar[1], M. S. Eroğlu[1]

[1]*Department of Internal Medicine, Faculty of Veterinary Medicine, Atatürk University, Erzurum, Turkey*

[2]*Department of Internal Medicine, Faculty of Veterinary Medicine, Yozgat Bozok University, Yozgat, Turkey*

ABSTRACT: Pseudo-pericarditis-shaped theileriosis is a rare phenomenon that only a handful of reports have been introduced. This case report aims to describe pseudo-pericarditis due to tropical theileriosis diagnosed in a 7-year old crossbreed Simmental cow and 3-year old crossbreed Holstein cow with a loss of appetite, weakness, and weight loss. We have detected high fever, paleness in mucous membranes (anaemia), petechial haemorrhages and icterus, an obvious enlargement in the left prescapular lymph node, distension in the jugular venous and positive venous pulse in the clinical examination. The factors of *Theileria annulata* were intensively present in the microscopic investigation of the peripheral blood smears of both animals. We determined considerably low levels of hematologic parameters. Finally, biochemical analyses revealed the elevated concentration of cTn-I, activities of CK-MB, LDH, AST, GGT, and the levels of TBIL. On the contrary, levels of TP, ALB, GLU, and Ca were significantly low. In this case report, we would like to touch upon some points that were not mentioned or merely investigated in the previous studies. In this context, we will first argue the increased risk of occurrence of pseudo-pericarditis in case of severe anaemia, petechial haemorrhages in conjunctival mucosa, greatly enlarged superficial lymph nodes and considerably low numbers of haematocrit. We also think that pseudo-pericarditis is a late-stage symptom of theileriosis. Then we further elaborate on the relationship between severe anaemia, pseudo-pericarditis and myocardial damage by referring to cardiac biomarkers (cTnI, CK-MB etc.) which was never done before. Later, we will finally elucidate on the biochemical parameters (AST, LDH, ALB, TBIL etc.) which revealed hepatic damage. Finally, we argue that in case of severe anaemia along with the expansion in vena jugularis and positive venous pulse, pseudo-pericarditis should be taken into consideration for the cows with tropical theileriosis.

***Keywords*:** Cow, theileriosis, positive venous pulse, pseudo-pericarditis.

Corresponding Author:
Şükrü Değirmençay, Department of Internal Medicine, Faculty of Veterinary Medicine, Atatürk University, 25240, Erzurum, Turkey
E-mail address: s.degirmencay@atauni.edu.tr

Date of initial submission: 08-07-2020
Date of revised submission: 10-10-2020
Date of acceptance: 02-01-2021

INTRODUCTION

Tropical theileriosis or Mediterranean coast fever is a common disease of cattle which can be seen worldwide especially southern Europe, North Africa, and Central Asia. Although it generally emerges in subtropical regions in the summer, it can be seen in tropical regions throughout the year (Cicek et al., 2009). A blood parasite, *Theileria annulata* (*T. annulata*), causes this progressive lymphoproliferative disease of cattle (Fartashvand et al., 2013). High fatality rate, diminished production, reproductive problems and an increased risk of secondary infection are the consequences of theileriosis which may result in economic losses (Keleş et al., 2001; Dumanli et al., 2005; Radostits et al., 2006; Cicek et al., 2009).

Theileria annulata is transmitted through the saliva of *Ixodid* tick of genus *Hyalomma* to the host (Mirzaei, 2007). This parasite is irregular or bacilliform shaped, ovoid, and small round with an apical complex and can be encountered with in both erythrocytes and lymphocytes of their host (Levine, 1985). Schizonts, also known as Koch's blue bodies, are formed in lymphocytes which produce merozoites in cooperation with host cell division. The merozoites escaping from the lymphocytes in host cells invade the erythrocytes. At this stage, the parasites become infective for the vector (Sayin et al., 2003) and are known as piroplasms (Mehlhorn and Schein, 1985).

The most important features of tropical theileriosis are hemolytic anaemia, secondary hypoxia, and vasculitis (Fartashvand et al., 2013). Also, the high body temperature, anorexia, conjunctival petechia, nasal discharge, lacrimation, and growth in superficial lymph nodes are characteristic features of tropical theileriosis (Hooshmand-Rad, 1976; Radostits et al., 2006). The occurrence of pseudo-pericarditis is quite rare in cattle with theileriosis (Sudhakara and Sivajothi, 2017; Satheesha et al., 2017). Jugular engorgement, oedema and anorexia form in cattle with pseudo-pericarditis due to the theileriosis (Keles et al., 2003; Radostits et al., 2006). Pseudo-pericarditis occurs with the symptoms that are likened to that of pericarditis without any heart abnormalities. The formation mechanism of pseudo-pericarditis is explained as pressure on the vena cava due to the swelling of the mediastinal lymph nodes around caudal vena cava and cranial vena cava which inhibits blood backflow leading to clinical manifestations such as oedema and jugular enlargement (Keles et al., 2003; Radostits et al., 2006).

Hematologic and biochemical alterations associated with anaemia occur in tropical theileriosis. These alterations are dependent on the virulence of the parasite, the infectious dose, the breed of the animal, the state of immunity, as well as climatic regional factors. (Singh et al., 2001; Mahmmod et al., 2011). In addition, the severity of anaemia, parasitemia and hypoxia has an effect on these alterations (Singh et al., 2001). This case report aims to notify the clinical, haematological and biochemical findings of two cows with pseudo-pericarditis due to tropical theileriosis.

CASE HISTORY

This study material consists of a 7-year old crossbreed Simmental cow and 3-year old crossbreed Holstein cow, which were brought to the Animal Hospital of Atatürk University with the complaints of loss of appetite, weakness, and weight loss. For the hematologic and biochemical analysis, we took blood samples from vena jugularis of the animals into the vacuumed anticoagulant and coagulant tubes. We performed hematologic analyses using a cell counter (Abacus Junior Vet5, Hungary) and obtained biochemical findings by an autoanalyzer (Beckman Coulter, USA). To verify if any *T. annulata* piroplasms are present, we used anticoagulant blood to prepare Giemsa stained blood smears which were then examined with an optical microscope at x1000 magnification with immersion oil.

RESULTS

In the physical examination of the cases; we detected high fever (39.8 °C and 40.2°C), tachypnoea (36/min and 44/min), tachycardia (100 bpm and 116 bpm), paleness in mucous membranes (anaemia), petechial haemorrhages and icterus in the conjunctiva, an obvious enlargement in the left prescapular lymph node, distension in the jugular venous and positive venous pulse (Figure 1 and 2). The auscultation of the heart did not reveal any pericardial rub, bubbling, splashing or tinkling. We have then checked the abdominal organs with a metal detector whether any metallic foreign bodies are present, no metallic foreign body was found.

Parasitological diagnosis revealed a high amount of *T. annulata* factors in the microscopic examination of the peripheral blood smears of both animals (Figure 3). Feces samples did not indicate fascioliasis or any other parasitic diseases under the parasitological examination.

Figure 1. The paleness (A), petechial haemorrhages and icterus in conjunctival membranes (B).

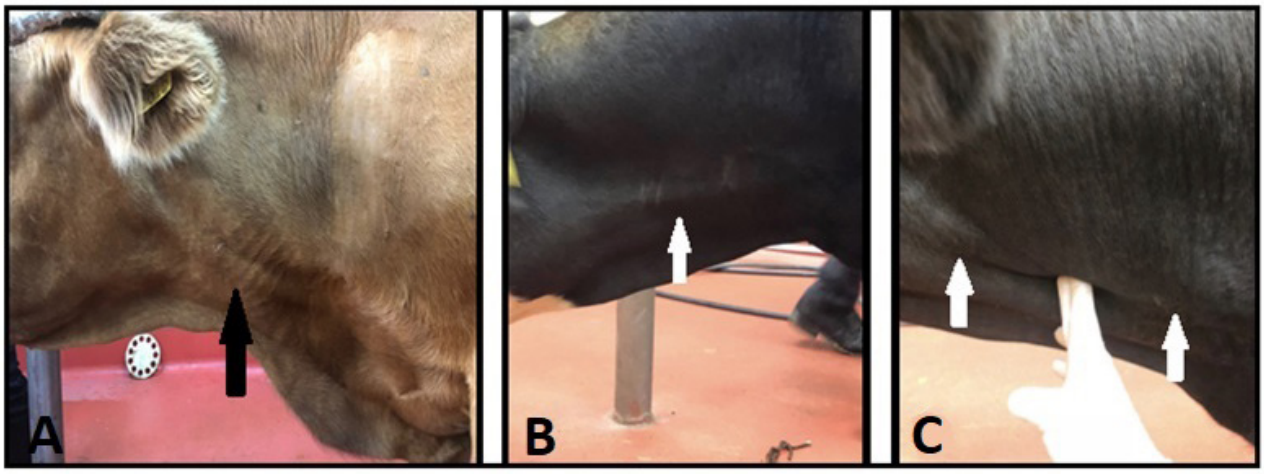

Figure 2. The fullness in the jugular vein (A and B) and positive vein pulse (C)

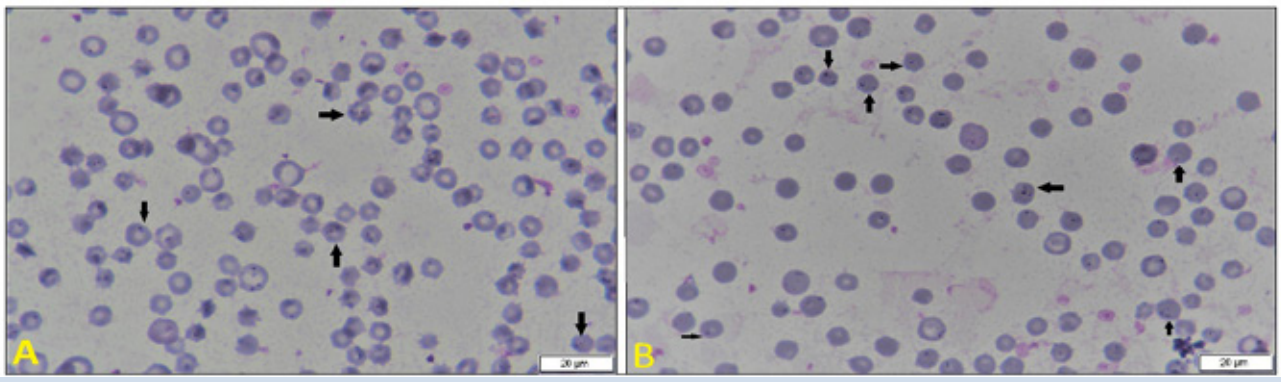

Figure 3. The ring forms of *Theileria annulata* piroplasms in red blood cells as shown with arrows in the figures (A and B)

In the hematologic examination, we observed much lower levels of lymphocyte, erythrocyte, haemoglobin, haematocrit, and platelets than the reference value (Roland, et al., 2014) (Table 1). Biochemical analyses demonstrated that levels of cardiac troponin-I (cTn-I), MB isoenzyme of creatine kinase (CK-MB), lactate dehydrogenase (LDH), aspartate aminotransferase (AST), gamma glutamyl transferase (GGT), blood urea nitrogen (BUN), and total bilirubin (TBIL) were higher than the reference value, on the contrary, the levels of total protein (TP), albumin (ALB), and glucose (GLU) were lower (Kilinc et al., 2018; Merck Veterinary Manual) (Table 2).

Table 1. Haematological findings of two cases

Parameter	Unit	Case-1	Case-2	Referance Range*
WBC	($x10^3/\mu L$)	5.65	8.00	4-12
LYM	($x10^3/\mu L$)	2.25	1.87	2.5-7.5
MON	($x10^3/\mu L$)	0.06	0.04	0-0.84
NEU	($x10^3/\mu L$)	3.30	5.95	0.6-6.7
EOS	($x10^3/\mu L$)	0.05	0.14	0.1-1
BAS	($x10^3/\mu L$)	0.00	0.00	0-0.5
RBC	($x10^6/\mu L$)	1.56	2.27	5-10
HGB	(g/dL)	2.9	3.6	8-15
HCT	(%)	9.26	11.32	24-46
PLT	($x10^3/\mu L$)	93	130	100-800

WBC: white blood cell; LYM: lymphocyte; MON: monocyte; NEU: neutrophil; EOS: eosinophil; BAS: basophil; RBC: red blood cell; HGB: haemoglobin; HCT: hematocrit; PLT: platelet
* Roland, et al. (2014)

Table 2. Biochemical findings of two cases

Parameter	Unit	Case-1	Case-2	Referance Range*
cTn-I	(ng/mL)	0.2	0.23	0.035-0.075 **
CK-MB	(U/L)	344	381	189-235 **
LDH	(U/L)	5427	7224	309-938
AST	(U/L)	364	642	60-125
GGT	(U/L)	107	22	6-17.4
BUN	(mg/dL)	26.64	38.79	10-25
TBIL	(mg/dL)	1.8	2.14	0-1.6
TP	(g/dL)	5.6	5.7	6.7-7.5
ALB	(g/dL)	1.97	2.15	2.5-3.8
GLU	(mg/dL)	30	26	40-100
Ca	(mg/dL)	5.4	7.9	8-11.4
P	(mg/dL)	6.7	6.8	5.6-8.0
Mg	(mg/dL)	1.68	1.5	1.5-2.9
Na	(mmol/L)	137	136	136-144
Cl	(mmol/L)	96	97	99-107
K	(mmol/L)	4.56	4.19	3.6-4.9

cTn-I: cardiac troponin-I; CK-MB: MB isoenzyme of creatine kinase; LDH: lactate dehydrogenase; AST: aspartate aminotransferase; GGT: gamma-glutamyl transferase; BUN: blood urea nitrogen; TBIL: total bilirubin; TP: total protein; ALB: albumin; GLU: glucose; Ca: calcium; P: phosphorus; Mg: magnesium; Na: sodium; Cl: chloride; K: potassium
* Fielder SE (2015) **Kilinc et al. (2018)

DISCUSSION

There are many studies reporting the clinical findings of theileriosis, but only a few on pseudo-pericarditis-shaped theileriosis. In this context, Parashar et al. (2016) reported the most common clinical findings in 124 cattle infected with *T. annulata* as enlarged prescapular lymph node, pale mucous membranes, decreased appetite, high fever and tear discharge. Keleş et al. (2003) and Sudhakara and Sivajothi (2017) detected high fever, enlarged prescapular lymph node, oedema on the submandibular, neck and brisket region, enlarged jugular vein and positive vein pulse in cattle with pseudo-pericarditis-shaped tropical theileriosis. Also, they did not observe pericardial friction rub, gurgling, splashing or tinkling on auscultation of the heart. They described the mechanism of the development of pseudo-pericarditis as the result of the swelling of mediastinal lymph nodes around the caudal vena cava and cranial vena cava which causes pressure on the vena cava and inhibits the backflow of the blood. In this study, we obtained similar clinical findings with those reported in tropical theileriosis along with wilt and petechial haemorrhages in the mucous membranes. Besides, we verified the findings of the previous studies on the auscultation of the heart. Obtained findings rested on the pressure on the

vena cava which is due to the enlargement of the prescapular lymph node and possible mediastinal lymph node. Thus, we inferred that pseudo-pericarditis can be formed in tropical theileriosis.

As for the haematological findings, Kachhawa et al. (2016) and Ayadi et al. (2017) reported that the levels of total leukocyte, erythrocyte, haemoglobin and haematocrit were low in cattle with tropical theileriosis. Temiz et al. (2014) found that the number of leukocytes was high, but the haemoglobin concentration, hematocrit value and PLT numbers were significantly low in cattle with theileriosis compared to the control group. As can be seen, reports on the total number of leukocytes in these studies are controversial. The mechanism behind this controversy can be explained as follows: In theileriosis, the leukocytosis occurs mostly at the early stages of the disease, while leukopenia occurs at the late stages of the disease (Sayin, 1985; Gül, 1999). Lymphocytes proliferation forms in lymphoid organs as a defensive response to the entry and multiplication of *T. annulata* which gives rise to leucocytosis (Modi et al. 2015). On the other hand, leukopenia, which is mediated by TNF- α, is related to the destruction of lymphocytes in lymphoid organs and the infiltration of these cells to various organs (Sandhu et al., 1998; Forsyth et al., 1999; Omer et al., 2002). In this study, we discovered lymphopenia in two cattle with pseudo-pericarditis due to tropical theileriosis, so it suggests that the disease is at the late stage.

Further haematological findings indicate severe anaemia as the disease progresses. In this context, Issi et al. (2010) found a significant reduction in erythrocyte, haemoglobin and hematocrit values of 10 cattle with tropical theileriosis compared to healthy animals. Similarly, Keleş et al. (2003) determined that haemoglobin (9,7 g/dL) and HCT (29%) values approached the limit values in a cow with pseudo-pericarditis due to tropical theileriosis. Sudhakara and Sivajothi (2017) reported a reduction in erythrocyte (4,2 x10^6/μL), haemoglobin (7,2 g/dL) and HCT (22%) values in a bull with pseudo pericarditis due to tropical theileriosis. Temiz et al. (2014) detected pseudo-pericarditis in a severe anaemic cow with only 12.5% HCT from 28 tropical theileriosis cattle. Our numbers are compliant with these studies, however, they are significantly lower than those reported, such as erythrocyte (1,56 x10^6/μL and 2,27 x10^6/μL), haemoglobin (2,9 g/dL and 3,6 g/dL), haematocrit (9,26% and 11,32%) and platelet (93 x10^3/μL and 130 x10^3/μL). Anaemia occurs due to removal of the piroplasm-infected erythrocytes by macrophages in the organs of the reticuloendothelial system (Beniwal et al., 2000), pro-inflammatory cytokines, particularly TNF-α (Forsyth et al., 1999), increased levels of activated complement products and oxygen radicals (Clark et al., 1986). As the disease progresses in tropical theileriosis, marked anaemia with bilirubinaemia and bilirubinuria, thrombocytopenia, greatly enlarged superficial lymph nodes, icterus and petechial haemorrhages in the conjunctiva and diarrhoea occur (Priston, 2001). In addition, we have detected severe anaemia, leukopenia, thrombocytopenia, high TBIL levels, and petechial haemorrhages in conjunctival mucosa. Consequently, it can be easily inferred that the disease being at the late stage. Furthermore, we believe that animals with theileriosis are more likely to form pseudo-pericarditis if erythrocyte, haemoglobin and especially HCT values are very low, namely, severe anaemic.

As for the biochemical findings, we also checked the cTnI concentration and CK-MB levels, since some studies on animals with theileriosis reported myocardial damage. cTnI is a potent marker used for the diagnosis of myocardial damage (Gunes et al., 2008). CK-MB, LDH, AST, and alanine aminotransferase (ALT) serve the same purpose (Basbugan et al., 2010). In this context, Kilinc et al. (2018) reported that cTnI (0.14 ng/mL ± 0.02), creatine kinase (CK) (839.13 U/L ± 84.37), CK-MB (268.86 U/L ± 27.55) and AST (83.60 U/L ± 4.06) enzyme activity were quite high in 50 cattle with theileriosis compared to the control group. Razavi et al. (2015) noted that cTnI (0.06 ng/mL ± 0.004), CK (113.27 U/L ±2.59), AST (116 U/L ± 3.28) and LDH (647.5 U/L ± 18.83) levels in 50 cattle with theileriosis were significantly high. They attributed these high numbers with significant myocardial tissue damage due to *T. annulata* which can be severed by anaemia and hypoxia. Fartashvand et al. (2013) found that mean serum cTnI level (0.028 ng/mL; range: 0.005–0.21 ng/mL), CK-MB (301 ± 103 U/L) and AST (107 ± 46 U/L) enzyme activity were quite high in 90 cattle with theileriosis compared to the control group. In addition to the contributions of Razavi et al. (2015), they stated that the severity of parasitemia would also contribute to the pathophysiology of myocardial damage. To the best of our knowledge, so far there is no study investigating the cTnI, CK-MB and LDH levels (except for AST) in cattle with pseudo-pericarditis-shaped tropical theileriosis. In this case report, for the first time in the

world, we examined and noted very high numbers of cTnI, CK-MB, LDH and AST which revealed severe myocardial damage (Table 2). We think that these high numbers, even higher than the previous studies, could be the result of severe anaemia and intense parasitemia. Furthermore, the fullness in the jugular vein could have a negative effect on the heart. Therefore, we argue that by causing heart's dysfunction, both the myocardial damage due to theileriosis and the negative effect of fullness in the jugular vein give rise to the findings of pseudo-pericarditis to become evident. However, this claim should be supported by electrocardiography and echocardiography examination methods and studies with more animals.

Interestingly, the studies on this topic did not investigate the biochemical parameters, only with an exception of Sudhakara who preferred to check only AST, TP, ALB and Glucose. Here, we examined some of the further biochemical parameters to determine the hepatic tissue damage. It has been stated that high AST and total bilirubin levels are sufficient to determine liver damage in cattle (Gul and Grunder, 1988), but haemolytic anaemia may also cause increase total bilirubin in theileriosis (Omer et al., 2003). GGT is a sensitive indicator of liver disease (Murray et al., 1990). Many researchers have reported an increase in AST-GGT enzyme activities, total bilirubin and BUN levels along with hypoproteinemia and hypoalbuminemia in cattle with theileriosis (Sandhu et al., 1998; Omer et al., 2003; Ellah, 2015; Kachhawa et al., 2016). Razavi et al. (2015) reported that there was a marked increase in AST (116 U/L ± 3.28) and LDH (647.5 U/L ± 18.83) levels in cattle with theileriosis. However, a study examining the levels of LDH, GGT and BUN in cattle with pseudo-pericarditis-shaped theileriosis has not been found. In this study, we also found high levels of AST, GGT and LDH enzyme activities, BUN and total bilirubin levels along with hypoproteinemia and hypoalbuminemia (Table 2). We stipulate that our significantly higher numbers would allude to severe hepatic damage due to anaemia, strong heart damage, hypoxia and theileriosis (Sandhu et al., 1998). Moreover, we detected low levels of glucose which may be due to the consumption of glucose by the theileria agents and liver dysfunction in the disease (Col and Uslu, 2006). Finally, blood calcium levels were lower than the reference value which can be associated with hypoalbuminemia (Ellah, 2015).

In conclusion, this study touches upon three important points. Firstly, in case of a greatly enlarged superficial lymph nodes, severe anaemia and petechial haemorrhages in conjunctival mucosa along with the low count of haematological parameters, particularly HCT, the risk of occurrence of pseudo-pericarditis due to theileriosis significantly rises. This also implies that pseudo-pericarditis is a late-stage symptom of theileriosis. Secondly, the heart damage would be more severe in cattle with pseudo-pericarditis which is evidenced through high levels of cardiac biomarkers (cTnI, CK-MB, AST and LDH). So far, this case report would be the first investigating the cardiac biomarkers on cattle with pseudo-pericarditis-shaped theileriosis. Last but not least, there is a considerable risk of hepatic damage in such animals which is elucidated with the biochemical parameters (AST, GGT, LDH, TBIL, ALB etc.). Such biochemical parameters were not preferred in the previous studies on this matter, therefore we are happy to report a case based on such parameters. However, in order to fully comprehend the effect of pseudo-pericarditis on hemogram and biochemical parameters, more comparative studies with theileriosis and pseudo-pericarditis-shaped theileriosis should be made.

CONFLICT OF INTEREST

The author(s) declared no potential conflicts of interest with respect to the research, authorship, and/or publication of this article.

ACKNOWLEDGEMENTS

This study was presented as a poster proceeding in the 1st International-5th Herd Health and Management Congress, October 14-17, 2019, Antalya/ Turkey

REFERENCES

Ayadi O, Gharbi M, Benchikh-Elfegoun MC (2017) Haematological and biochemical indicators of tropical theileriosis diseased cattle in wilaya of Setif (North East Algeria). J. Parasit. Dis. 41: 538-542.

Basbugan Y, Agaoglu Z, Yuksek N (2010) An Investigation on Serum Troponin Concentration in Healthy Ruminants. Kafkas. Univ. Vet. Fak. Derg. 16: 641-645.

Beniwal RK, Sharma RD, Nichani AK (2000) Determination of duration of immunity of calves vaccinated with the *Theileria annulata* schizont cell culture vaccine. Vet. Parasitol. 90: 25-35.

Cicek H, Cicek H, Eser M, Tandogan M (2009) Current status of ruminant theileriosis and its economical impact in Turkey. Turkiye Parazitol Derg. 33: 273-279.

Clark IA, Hunt NH, Cowden WB (1986) Oxygen-derived free radicals in the pathogenesis of parasitic disease. Adv. Parasitol. 25: 1-44.

Col R, Uslu U (2006) Haematological and coagulation profiles during severe tropical theileriosis in cattle. Turkish J. Vet. Anim. Sci. 30: 577-582.

Dumanli N, Aktas M, Cetinkaya B, Cakmak A, Koroglu E, Saki CE, Erdogmus Z, Nalbantoglu S, Ongor H, Simsek S, Karahan M, Altay K (2005) Prevalence and distribution of tropical theileriosis in eastern Turkey. Vet. Parasitol. 127: 9-15.

Ellah MRA (2015) Studying the correlations among hematological and serum biochemical constituents in cattle theileriosis. J. Parasit. Dis. 39: 134-139.

Fartashvand M, Nadalian MG, Sakha M, Safi S (2013) Elevated serum cardiac troponin I in cattle with theileriosis. J. Vet. Intern. Med. 27: 194-199.

Fielder SE (2015) Serum Biochemical Reference Ranges Special Subjects - Merck Veterinary Manual. Available online: https://www.merckvetmanual.com/special-subjects/reference-guides/serum-biochemical-reference-ranges [accessed 25 January 2020].

Forsyth LMG, Minns FC, Kirvar E, Adamson RE, Hall FR, McOrist S, Brown CGD, Preston PM (1999) Tissue damage in cattle infected with Theileria annulata accompanied by metastasis of cytokine-producing, schizont-infected mononuclear phagocyte. J. Comp. Pathol. 120: 39-57.

Gul Y, Grunder HD (1988) Estimation of Bile-Acids in Blood-Serum and Its Diagnostic-Value for Liver-Diseases in Cattle. Deut. Tıerarztl. Woch. 95: 140-146.

Gunes V, Atalan G, Citil M, Erdogan HM (2008) Use of cardiac troponin kits for the qualitative determination of myocardial cell damage due to traumatic reticuloperitonitis in cattle. Vet. Rec. 162: 514-517.

Gül Y (1999) Symptomatic nasal bleeding in a calf with theileriosis. Turkish J. Vet. Anim. Sci. 23: 209-211.

Hooshmand-Rad P (1976) The pathogenesis of anaemia in Theileria annulata infection. Res. Vet. Sci. 20: 324-329.

İssi M, Gül Y, Başbuğ O, Şahin N (2010) Clinical, haematological and some biochemical parameters with serum cobalt and vitamin B12 levels in cattle with tropical theileriosis. Kafkas. Univ. Vet. Fak. Derg. 16: 909-913.

Kachhawa JP, Kumar S, Sharma A, Singh AP, Ahuja A (2016) Studies on alterations of clinical and hemato-biochemical parameters before and after treatment in calves naturally infected with theileriosis. Vet. World. 9: 1381-1385.

Keles I, Alptekin I, Atasoy N, Cinar A, Dönmez N, Ceylan E (2003) Pseudo-pericarditis in a cow caused by theileriosis-a case report. Vet. Archiv. 73: 111-117.

Keleş İ, Değer S, Altuğ N, Karaca M, Akdemir C (2001) Tick-borne diseases in cattle: clinical and haematological findings, diagnosis, treatment, seasonal distribution, breed, sex and age factors and the transmitters of the diseases. YYU. Vet. Fak. Derg. 12: 26-32.

Kilinc OO, Ozdal N, Bicek K, Deger MS, Yuksek N, Yilmaz AB, Oguz B (2018) Relationship between cardiac injury, selected biochemical parameters, DIC, and hemogram levels in cattle with theileriosis. Med. Weter. 74: 383-386.

Levine ND (1985) Veterinary Protozoology. 1st ed, Iowa State University Press, Ames.

Mahmmod YS, Elbalkemy FA, Klaas IC, Elmekkawy MF, Monazie AM (2011) Clinical and haematological study on water buffaloes (Bubalus bubalis) and crossbred cattle naturally infected with Theileria annulata in Sharkia province, Egypt. Ticks Tick Borne Dis. 2: 168-171.

Mehlhorn H, Schein E (1985) The piroplasms: life cycle and sexual stages. Adv. Parasitol. 23: 37-103.

Mirzaei M (2007): Treatment of natural tropical theileriosis with the extract of the plant Peganum harmala. Korean. J. Parasitol. 45: 267-271.

Modi DV, Bhadesiya CM, Mandali GC (2015) Hematobiochemical changes in crossbred cattle infected with *Theileria annulata* in Banaskantha district of Gujarat. Int J Sci Res 5: 1–4.

Murray RK, Granner DK, Mayes PA, Rodwell VW (1990) Harpers Biochemistry, (Appleton and Lange, Connecticut)

Omer OH, El-Malik KH, Magzoub M, Mahmoud OM, Haroun EM, Hawas A, Omar HM (2003) Biochemical profiles in Friesian cattle naturally infected with *Theileria annulata* in Saudi Arabia. Vet. Res. Commun. 27: 15-25.

Omer OH, El-Malik KH, Mahmoud OM, Haroun EM, Hawas A, Sweeney D, Magzoub M (2002) Haematological profiles in pure bred cattle naturally infected with *Theileria annulata* in Saudi Arabia. Vet. Parasitol. 107: 161-168.

Parashar R, Sudan V, Jaiswal AK, Shanker D (2016) Variation in clinical markers in cattle naturally infected with bovine tropical theileriosis. J. Parasit. Dis. 40: 1532-1534.

Priston MP. Theilerioses. In: Service MW, Ashford RW, editors. Encyclopedia of Arthropod-transmitted Infections of Man and Domesticated Animals. New York, USA: CABI Publishing; 2001. p. 493.

Radostits OM, Gay CC, Hinchcliff KW, Constable PD (2006) Veterinary Medicine: A textbook of the diseases of cattle, horses, sheep, pigs and goats. 10th ed, WB Saunders Company, London, UK.

Razavi S, Nazifi S, Hasani S, Rakhshandehroo E (2015) Bovine tropical theileriosis: effects on the cardiovascular system on the basis of serum analysis. Comp. Clin. Pathol. 24: 29-33.

Roland L, Drillich M, Iwersen M (2014) Hematology as a diagnostic tool in bovine medicine. J. Vet. Diagn. Invest. 26: 592-598.

Sandhu GS, Grewal AS, Singh A, Kondal JK, Singh J, Brar RS (1998) Haematological and biochemical studies on experimental Theileria annulata infection in crossbred calves. Vet. Res. Commun. 22: 347-354.

Satheesha S, Dhanalakshmi S, Chandrashekhar G, Naveen M, Manasa RK, Malatesh D (2017) An Unusual case of Theileriosis in a HF cross bred cow and its Clinical management. Bull. Env. Pharma-

col. Life. Sci. 6: 140-143.

Sayin F (1985) Pathogenicities and behaviours of the Theileria spp. in the host. Turkish Society for Parasitology Press. 5: 77-96

Sayin F, Dincer S, Karaer Z, Cakmak A, Inci A, Yukari BA, Eren H, Vatansever Z, Nalbantoglu S (2003) Studies on the epidemiology of tropical theileriosis (Theileria annulata infection) in cattle in Central Anatolia, Turkey. Trop. Anim. Health. Prod. 35: 521-539.

Singh A, Singh J, Grewal AS, Brar RS (2001) Studies on some blood parameters of crossbred calves with experimental Theileria annulata infections. Vet. Res. Comm. 25: 289-300.

Sudhakara Reddy B, Sivajothi S (2017) *Theileria annulata* induced brisket oedema in a bull and its successful treatment. J. Parasit. Dis. 41: 171-174.

Temiz M, Altug N, Yuksek N (2014) Relationship between degree of anaemia and blood gases in cattle with theileriosis. Turkish J. Vet. Anim. Sci. 38: 82-87.