

Journal of the Hellenic Veterinary Medical Society

Vol 74, No 3 (2023)



A comparative study on oxidative stress indices among cattle and buffalo with foreign body syndrome

N Gomaa, NM Nassif, MA Havez, S Fawzy

doi: [10.12681/jhvms.28170](https://doi.org/10.12681/jhvms.28170)

Copyright © 2023, Naglaa Gomaa



This work is licensed under a [Creative Commons Attribution-NonCommercial 4.0](https://creativecommons.org/licenses/by-nc/4.0/).

To cite this article:

Gomaa, N., Nassif, N., Havez, M., & Fawzy, S. (2023). A comparative study on oxidative stress indices among cattle and buffalo with foreign body syndrome. *Journal of the Hellenic Veterinary Medical Society*, 74(3), 5903–5910. <https://doi.org/10.12681/jhvms.28170> (Original work published October 16, 2023)

A comparative study on oxidative stress indices among cattle and buffalo with foreign body syndrome

A.N. Gomaa^{1,2*}, N. M. Nassif¹, M. A. Hafez¹, S. Fawzy³

¹Department of Animal Medicine, Faculty of Veterinary Medicine, Kafrelsheikh University, Kafrelsheikh, Egypt

²Department of clinical studies, Faculty of Veterinary Medicine, King Faisal University, Hofuf, Alahsa, Saudi Arabia

³Directorate of Veterinary Medicine, Kafrelsheikh, Egypt

ABSTRACT: This study aimed to compare the oxidative stress indices among cattle and buffalo with foreign body syndrome (FBS) in order to clarify this syndrome's pathogenesis and explain the clinical differences between both species. The study included 60 animals. They were divided into a control group (10 healthy cows and 10 healthy buffalo-cows). The diseased animals were divided based on the clinical signs and duration of illness as well as radiographic and ultrasonographic findings into 3 groups; acute local TRP (5 buffalo-cows), chronic local traumatic reticuloperitonitis (TRP) (13 cows and 12 buffalo-cows), and traumatic pericarditis (TP) (5 cows and 5 buffalo-cows). Blood samples were obtained for hematological and biochemical analysis. In all diseased animals, the malondialdehyde (MDA) level, Glutathione peroxidase (GSH-PX) and superoxide dismutase (SOD) activities increased significantly except in buffalo with chronic local TRP, GSH-PX activity decreased significantly. The reduced glutathione (GSH) and catalase activities decreased also significantly in all diseased groups. The level of TAC was only increased significantly in acute local TRP in buffalo-cows. Statistically, there was a species difference in MDA level, in which cattle surpass buffalo in production of lipid peroxides which indicate more oxidative damage and more inflammation and systemic reactions. Whereas, buffalo with chronic local TRP showed an exhausted antioxidant defense system because of lower GSH-PX activity than in cattle that leading to more chronic changes and fibrosis. Finally, it can be concluded that there is a species difference between cattle and buffalo in lipid peroxidation and their antioxidant defence mechanism response to oxidative stress in FBS and its sequelae which could affect on the clinical signs and the progress of the disease in each species. Future researches should focus on establishment of reference oxidative stress panel for each species in order to determine appropriate oxidative stress biomarkers and antioxidant therapy.

Keywords: Buffalo; Cattle; Foreign body syndrome; Oxidative stress

Corresponding Author:

Naglaa A. Gomaa, Department of Animal Medicine, Faculty of Veterinary Medicine, Kafrelsheikh University, 33516, Egypt
E-mail address: naglaa.gomaa@vet.kfs.edu.eg, naglaagomaa505@yahoo.com

Date of initial submission: 10-10-2021

Date of acceptance: 18-10-2022

INTRODUCTION

Foreign body syndrome (FBS) is a relatively common disease in cattle and buffalo, especially in developing countries. This disease is caused by the ingestion of indigestible metallic or non-metallic blunt or sharp foreign objects (Abu-Seida and Al-Abadi, 2016). FBS is a major problem affecting dairy animals productivity. This syndrome and its sequelae, such as local and diffuse traumatic reticuloperitonitis (TRP), and reticular, splenic, hepatic, and thoracic abscesses, may lead to economic losses in milk and meat production, as well as possible deaths if traumatic pericarditis (TP) develops (Hussein et al., 2017). The importance of the disease is not only due to its higher prevalence among other digestive disorders but also due to the difficulty in early diagnosis and evaluation of its sequelae by physical examination, especially in TP, which has different pathological stages (Macedo et al., 2021). Although the risk and sequelae of TRP are considerably higher in buffalo than in cattle (Misk and Semieka, 2001), the classic symptoms of pain and systemic reactions were commonly present in cattle and less common in buffalo (Saleh et al., 2008, Abdelaal et al., 2009).

Recently, the investigations focused on the role of reactive oxygen species (ROS) and oxidative stress in the initiation and progression of numerous disorders as well as developing of chronic pathological conditions (Mittal et al., 2014; Folnožić et al., 2015). In ruminants, oxidative stress may be involved in several pathological conditions, including inflammation and tissue damage (Erel, 2005). Plasma malondialdehyde (MDA), reduced glutathione (GSH), catalase (CAT), glutathione peroxidase (GSH-PX), and superoxide dismutase (SOD) were assessed as biomarkers of oxidative stress in cattle and buffalo (Lykkesfeldt and Svendsen, 2006; Elgioushy et al., 2019). The evidence of racial and gender differences in oxidative stress and inflammatory biomarkers in humans exists, in how respond to development and progression of a disease was explained (Andrew et al., 2015). More recently, it was reported a species difference in oxidative stress markers in response to exercise and diseases in animals (Shono et al., 2020). It was reported that serum nitric oxide (NO), which was previously recognized as a more sensitive biomarker for detection of inflammatory disorders in cattle with TRP, changed insignificantly in buffalo with TRP (Elgioushy et al., 2019).

The clinicopathological alterations in cattle and

buffalo with TRP or TP have been widely investigated (Abdelaal et al., 2009; Alasker et al., 2013; Fawzy et al., 2018). Less research was performed on oxidative stress indices in cattle and buffalo with TRP or TP (Hussein et al., 2018 and Elgioushy et al., 2019). However, to date, there is still no comparative study between cattle and buffalo to explore the role of oxidative stress in the pathogenesis of TRP and TP in these animals. Therefore, the present study aimed to compare the activities of some oxidative stress indices in cattle and buffalo with FBS. The species differences in oxidative stress response to FBS could clarify this syndrome's pathogenesis and its sequelae in both species.

MATERIALS AND METHODS

Animals

This study was approved by the Institutional Animal Ethics Committee, Faculty of Veterinary Medicine, Kafrelsheikh University, (Approval No. KFS-IACUC/9/1/2017). A total of 40 female cattle and Egyptian water buffalo-cows (18 cows and 22 buffalo-cows) were included in the study, where 17 were pregnant at different stages of pregnancy, and 23 were non-pregnant or recently calved and their age ranged between 3-7 years (Table 1). They were sporadic cases from small holders from different localities along Kafrelsheikh Governorate. These animals were referred to the animal hospital of the Faculty of Veterinary Medicine, Kafrelsheikh University, Egypt; between the period of January 2017 to December 2017. The diseased animals suffered from inappetence to anorexia, fever, recurrent tympany or impaction, sharp drop in milk yield, and sometimes brisket edema. They were examined clinically according to Radostits et al. (2010) and tested for the presence of foreign bodies in the reticulum or penetrating the diaphragm toward the heart using pain test and metal detector. The disease was confirmed according to the results obtained from X-rays and ultrasonographic examinations. Clinical signs, duration of illness, hematological findings as well as radiographic and ultrasonographic findings were used as criteria for classification of diseased animals into acute local TRP (5 buffalo-cows), chronic local TRP (13 cows and 12 buffalo-cows), and TP (5 cows and 5 buffalo-cows). In addition to 20 apparently healthy cows and Egyptian water buffalo-cows (10 cows and 10 buffalo-cows), 4 pregnant at mid and late stage of pregnancy and 16 non-pregnant or recently calved with age ranged 3-5 years, were used as a control group (Table 1). The control group of

Table 1: Numbers of animals in control group and groups of diseased animals in relation to pregnancy

Groups	Control	Acute local TRP	Chronic local TRP	TP
Cattle				
Total Nr.	10	0	13	5
Pregnant	2 mid-stage		9 <div> <div>2 mid-stage</div> <div>7 late stage</div> </div>	1 late stage
Non-pregnant	8 <div> <div>6 non-pregnant</div> <div>2 recently calved</div> </div>		4 <div> <div>2 non-pregnant</div> <div>2 recently calved</div> </div>	4 <div> <div>1 non-pregnant</div> <div>3 recently calved</div> </div>
Buffalo				
Total Nr.	10	5	12	
Pregnant	2 <div> <div>1 mid-stage</div> <div>1 late stage</div> </div>	4 late stage	2 mid-stage	1 late stage
Non-pregnant	8 <div> <div>6 non-pregnant</div> <div>2 recently calved</div> </div>	1 recently calved	10 <div> <div>5 non-pregnant</div> <div>5 recently calved</div> </div>	4 <div> <div>2 non-pregnant</div> <div>2 recently calved</div> </div>

cows belonged to the Faculty of Veterinary Medicine, Kafrelsheikh University (educational farm) while, the control group of water buffalo-cows belonged to the Institute of Animal Production Research, Mehlet Moussa Experimental Station, Kafrelsheikh Governorate.

Clinical Examination

A full case history was obtained, and a thorough clinical examination was performed according to Radostits et al. (2010). Radiographic examination- were performed using the Fischer imaging system RMX-625R (manufactured by the Fisher Imaging Company, USA). The presence of foreign bodies was determined, and their position and nature recorded; the diaphragm status (intact or perforated) was also examined, and the cardiac area was visualized. Ultrasonographic examination of the reticulum and heart was performed using (Mindray Z5 ultrasound machine, China) with a 3.5-MHZ convex transducer in a standing position in the cranioventral abdomen as described by Braun and Goetz (1994). Ultrasonographic examination was performed to evaluate the contour and motility of the reticulum, fibrinous deposits between the reticular wall and abdominal wall and pericardial sac as well as the pericardial effusion.

Hematological and biochemical Examination

Blood samples were collected from each animal by puncturing the jugular vein to obtain 10 mL of blood into heparinized test tubes for early hematological examination using a veterinary automated cell counter (Medonic CA620 vet hematology analyzer, Sweden).

Another 10 mL of heparinized blood samples were used to separate plasma to evaluate the activity of reduced GSH, glutathione reductase (GR), CAT, and SOD and MDA levels. The plasma was separated by centrifugation at 3,000 rpm for 15 min, and then the samples were stored at -20 °C until analysis.

The total antioxidant capacity (TAC) levels and activities of GSH-PX, reduced GSH, CAT, SOD, and MDA levels were measured spectrophotometrically using a spectrophotometer (Turner 690, USA), according to the standard methods, using commercially available test kits (Biodiagnostic, Cairo, Egypt).

Statistical Analysis

Data were analyzed using a statistical software package (SPSS for Windows, version 16.0 Chicago, SPSS Inc.). The Shapiro-Wilk test was used to analyze the normality. All data were normally distributed and were represented as means \pm standard errors. Using factorial ANOVA (3-way ANOVA) to determine the interaction between dependant variables (oxidative stress parameters) and other three factors (species, diseases, and pregnancy). This was followed up with multicomparison post hoc tests such as Tukey HSD. An independent sample t-test was used to compare the oxidative stress parameters between different species (cattle and buffalo) in the same group. A p-value <0.05 was considered statistically significant.

RESULTS

TRP and TP were diagnosed based on radiographic evidence of a foreign body that penetrated the reticular

wall or diaphragm, respectively (Fig.1). Acute local TRP was initially diagnosed from the history, duration of illness, and physical examination and confirmed by ultrasonographic and radiographic examination (Figs 1-3). Clinical examination revealed a mild elevation in rectal temperature, mean $(39.6 \pm 0.33)^{\circ}\text{C}$. The ruminal contraction was weak or even in complete stasis. Ruminal tympany or impaction could be revealed by palpation. The heart rate was normal or slightly in-

creased but some cases, the heart sound was muffled that diagnosed to have TP. By applying the pain test, some cases showed pain reaction, which could be detected by grunting or arched back, reluctance to move, stiff gait, and grinding of the teeth. Most diseased cases had a positive result to the metal detector.

Hematological examination revealed a significant decrease in the RBC count, Hb, and PCV in all diseased

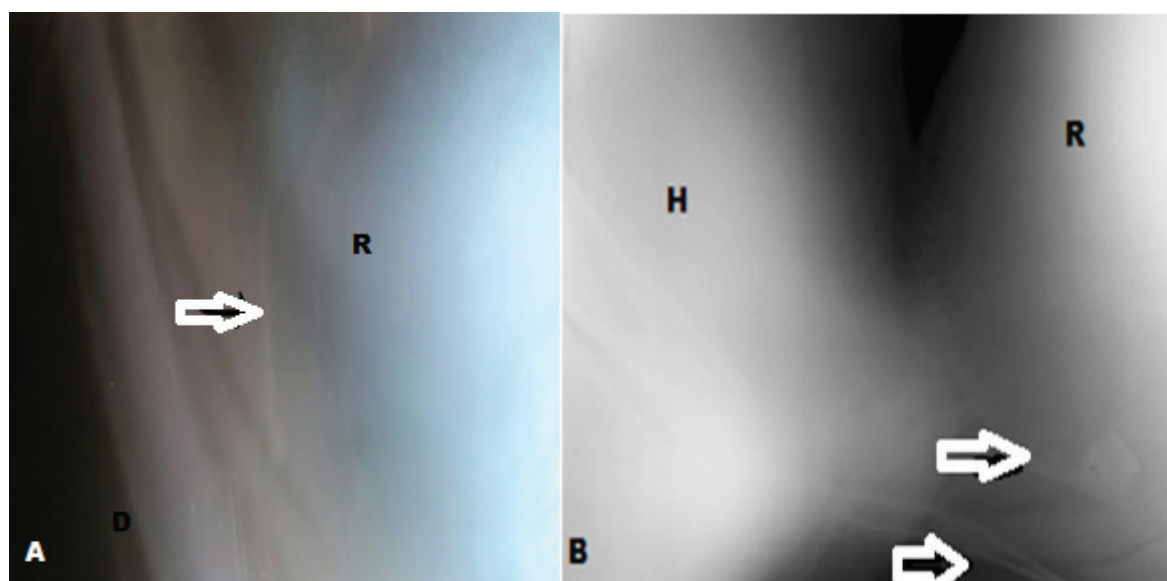


Figure 1: (A); Lateral radiographic view of the cranial abdomen of a 3-years-old buffalo with acute local TRP showing reticulum (R) with penetrating foreign body at the head of white arrow. (B); Lateral radiographic view of the caudal thoracic and cranial abdomen of a 5 years-old cow suffering from penetrating foreign body in reticulum that penetrates the diaphragm (D) causing fibrinous traumatic pericarditis. There are several nails in reticulum at the heads of white arrows. D: Diaphragm; H: Heart; R: reticulum

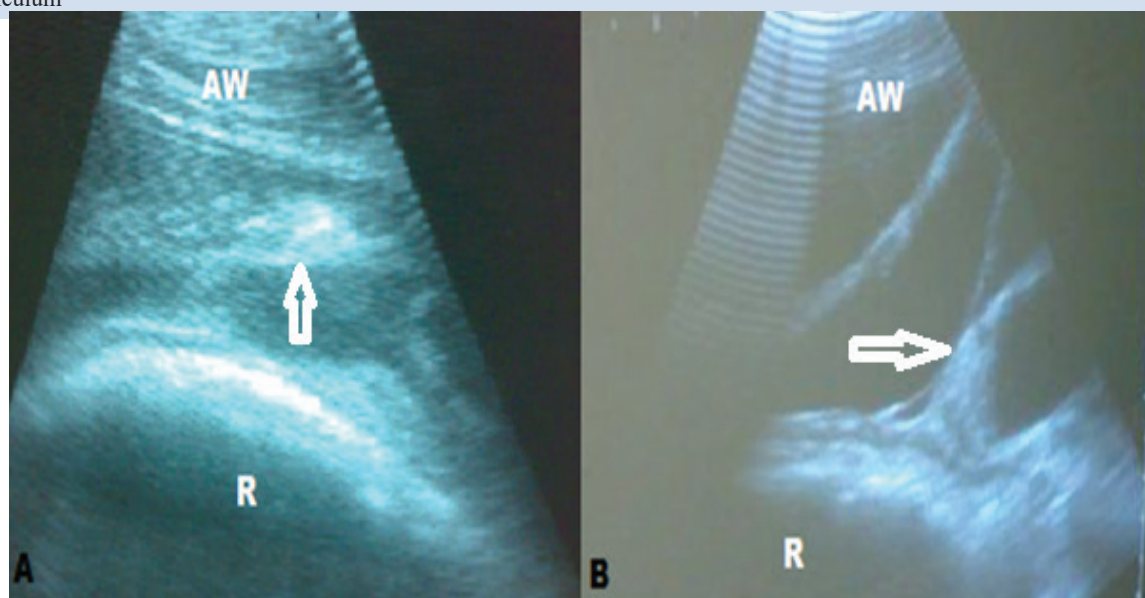


Figure 2: (A); Ultrasonographic image of acute local TRP in a 4 years-old buffalo showing thickening in reticular wall with echogenic fibrinous deposits (at the head of white arrow) between reticulum and abdominal wall. (B): Ultrasonographic image of chronic local TRP showing an echogenic fibrin interspersed with an anechoic exudate forming the fibrin network (at the head of white arrow). AW: Abdominal wall; R: reticulum.

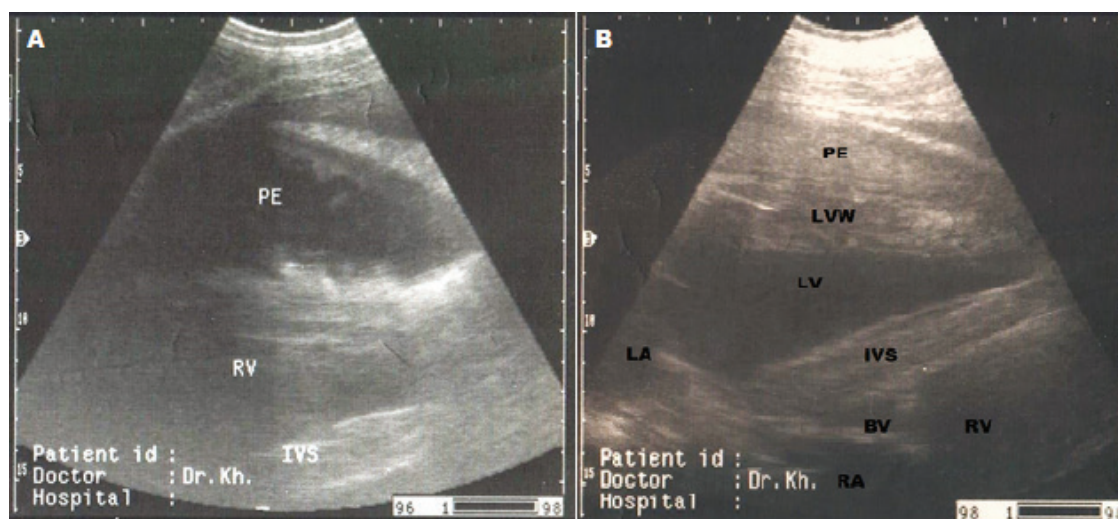


Figure 3: (A); Ultrasonographic image in buffalo with TP that revealed thick pericardium, pericardial effusion, the effusion contains fibrin shreds and anechoic exudate. PE: Pericardial effusion; RV: Right ventricle; IVS: Interventricular septum. (B); Ultrasonographic image in cow with suppurative traumatic pericarditis. It is showing thick pericardium, pericardial effusion, the effusion appears as anechoic to hypoechoic fluid content in pericardial sac (pus). PE: Pericardial effusion; LVW: Left ventricular wall; LV: Left ventricle; LA: Left atrium; BV: Bicuspid valve; RV: Right ventricle; RA: Right atrium; IVS: Interventricular septum

animals. In contrast, the total leukocytic count was significantly increased in all diseased animals. Table 2 showed the efficiency of interaction between oxidative stress parameters and other factors (species, disease, pregnancy). It was revealed that the species had a significant efficiency on oxidative stress parameters especially MDA and GSH-PX with P -value = 0.000 and 0.03, respectively. On another hand, the disease had a significant efficiency on all oxidative stress parameters except catalase (P = 0.389), while pregnancy had no significant efficiency on oxidative stress parameters. The interaction between species and disease was significant at SOD and GSH-PX. There was no significant interaction between species, diseases and pregnancy as show in table 2.

Table 3 summarize the oxidative stress markers in diseased cattle and buffalo with FBS. The MDA level increased significantly in cattle with TP and in all diseased groups of buffalo-cows. There was a significant increase in the MDA level in cattle with TP

than buffalo in the same group. The SOD activity was significantly increased in all diseased animals. It was significantly (P -value=0.049) increased in cattle than buffalo with TP. The SOD activity was also significantly (P -value=0.015) increased in buffalo with chronic local TRP than cattle in the same group. The GSH-PX activity was significantly increased in cattle with chronic local TRP and TP. The GSH-PX activity was significantly increased in cattle than buffalo in chronic local TRP (P -value=0.00001). However, the reduced GSH and CAT activities were significantly decreased in all diseased animals with no significant difference between cattle and buffalo (Table 2). The TAC level did not show any significant change in all diseased animals except in buffalo with acute local TRP, there was a significant increase (P -value=0.002). The TAC level was significantly increased (P -value=0.0024) in cattle than in buffalo with TP.

DISCUSSION

The symptoms of FBS were varied depending on

Table 2: Summary table of three-way ANOVA for the data variables

Oxidative stress parameters	Species		Diseases		Pregnancy		Species*disease		Species*disease*pregnancy	
	<i>F</i>	<i>P</i> -value	<i>F</i>	<i>P</i> -value	<i>F</i>	<i>P</i> -value	<i>F</i>	<i>P</i> -value	<i>F</i>	<i>P</i> -value
MDA (nmol/mL)	14.48	0.000	6.699	0.001	3.430	0.07	2.369	0.138	0.259	0.259
SOD (U/L)	2.893	0.096	17.879	0.000	3.425	0.071	10.473	0.071	0.305	0.305
GSH-PX (U/L)	4.929	0.031	10.828	0.000	0.480	0.492	10.513	0.000	0.954	0.954
GSH (mg/dL)	0.023	0.881	73.377	0.000	0.100	0.754	0.253	0.777	0.224	0.224
Catalase (U/mL)	0.435	0.513	1.027	0.389	0.079	0.780	1.442	0.247	0.974	0.974
TAC (mmol/L)	0.766	0.386	11.709	0.001	2.271	0.139	0.489	0.616	0.144	0.144

Table 3: Oxidative stress markers in cattle and buffalo in different groups (control, acute local TRP, chronic local TRP and TP); showing the significance difference between groups using multiple comparison post hoc tests (Tukey HSD test) and independent sample t- test for comparison between cattle and buffalo in each group

Oxidative stress markers	Species	Disease				Tukey HSD <i>p</i> -value
		Control	Acute local TRP	Chronic local TRP	TP	
MDA (nmol/mL)	Cattle	4.36±0.53 ^{ba}		5.17±0.41 ^{ba}	8.38±0.75 ^{aA}	0.012
	Buffalo	3.29±0.53 ^{bb}	4.73±0.75 ^a	4.11±0.52 ^{aA}	4.93±0.75 ^{aB}	
	t-test <i>p</i> -value	0.0123		0.082	0.049	
SOD (U/L)	Cattle	4.592.72 ^{cA}		15.63±2.07 ^{bb}	37.13±3.85 ^{aA}	0.001
	Buffalo	5.39 ±2.72 ^{ba}	18.75±3.85 ^a	23.50±2.66 ^{aA}	15.75±3.85 ^{aB}	
	t-test <i>p</i> -value	0.080		0.015	0.049	
GSH-PX (U/L)	Cattle	2.94±0.19 ^{bb}		3.94±0.15 ^{aA}	4.81±0.27 ^{aA}	0.0003
	Buffalo	3.48±0.19 ^{ba}	3.5±0.28 ^b	2.81±0.19 ^{cB}	4.21±0.28 ^{aA}	
	t-test <i>p</i> -value	0.017		0.00001	0.285	
GSH (mg/dL)	Cattle	57.56±2.36 ^{aA}		26.11±1.79 ^{ba}	32.38±3.33 ^{ba}	0.001
	Buffalo	56.13±2.35 ^{aA}	26.01±3.33 ^b	24.45±2.30 ^{ba}	34.50±3.33 ^{ba}	
	t-test <i>p</i> -value	0.374		0.274	0.381	
Catalase (U/mL)	Cattle	0.38±0.07 ^{aA}		0.41±0.06 ^{aA}	0.35±0.11 ^{aA}	0.540
	Buffalo	0.49±0.07 ^{aA}	0.31±0.11 ^b	0.31±0.07 ^{ba}	0.22±0.11 ^{cA}	
	t-test <i>p</i> -value	0.060		0.113	0.071	
TAC (mmol/L)	Cattle	3.84±0.24 ^{aB}		4.17±0.18 ^{aA}	3.94±0.34 ^{aA}	0.134
	Buffalo	3.91±0.24 ^{ba}	6.00±0.34 ^a	3.80±0.24 ^{ba}	3.66±0.34 ^{bb}	
	t-test <i>p</i> -value	0.049		0.065	0.0024	

† Data are represented as mean ±standard error (SE)

††Mean± SE with different superscript lowercase letters in the same row means there are significant differences between the disease's groups within the same species at *P* value < 0.05. While different superscript uppercase letters in the same column means there are significant differences between species at *P* value < 0.05

the site of the penetration and whether the condition is acute or chronic (El-Ashker et al., 2013; Abu-Seida and Al-Abbadi, 2016; Gogjoo et al., 2021). In the present study, there was an increase in the rectal temperature in animals with TP and acute local TRP (39.6±0.33°C). This could be attributed to bacteremia caused by perforation of sharp foreign body to the reticular wall (Fubini and Ducharme, 2016). The decreased ruminal contractions in acute and chronic cases may be caused by either a reduction in the excitatory nerve or an increase in inhibitory inputs drive to rumen (Rehage et al., 1995), or may be due to reticular adhesion in chronic cases (Ramprabhu et al., 2003). Moreover, all diseased animals suffered from sudden sharp decrease in milk production as a result of anorexia and systemic reactions (Abu-Seida and Al-Abbadi 2016). Most cases of acute local TRP in buffalo and TP in cattle and buffalo were positive to pain test while in chronic local TRP, the signs of pain and systemic reactions were observed more commonly in cows than in buffaloes and this was consistent with other previous studies (Abdelaal et al., 2009; El-Giously et al., 2019; Macedo et al. 2021). Leukocyto-

sis and anemia, which are the most common hematological alterations observed in chronic inflammatory diseases, and indicating an exudative hemorrhagic lesion (Radostits et al., 2010; Vanitha et al., 2010; Kumar and Dhar, 2013; Fawzy et al. 2017).

Oxidative stress results from an imbalance between reactive oxygen species (ROS) production and the antioxidant system leading to cell damage. Macrophages, neutrophils, and other phagocytic cells are considered as the potent cells of an immune response against microbial infection and inflammation. These cells generate large amounts of ROS that are considered the main cause of lipid peroxidation, which is an indicator of oxidative stress in cattle and buffalo with TRP and TP (Bozukluhan et al., 2013). Antioxidants protect cells against oxidative damage by preventing initiation of lipid peroxidation. This is a well-established mechanism of oxidative damage caused by ROS. In the present study, there was a significant effect of species on oxidative stress parameters especially MDA and GSH-PX (table 2). The measurement of the MDA, the intermediate product of lipid peroxidation, provides a convenient index of lipid peroxidation

(Nielsen et al., 1997). The mean MDA level was significantly increase in cattle with TP and in all groups of diseased buffalo with a significant increase in cattle than buffalo with TP. This could assign to higher lipolysis and lipid peroxides in cattle than in buffalo as the lipolysis is aggravated in dairy cows with a genetic drive which was not observed in buffalo (Nouri et al., 2011). This findings were in corroboration with previous reports (Sharma et al., 2011 and Singh et al., 2017). On the other hand, the major antioxidant enzymes that are responsible for the degradation of ROS are superoxide dismutase (SOD) which is the major intracellular antioxidant enzyme converts superoxide anion radicals to hydrogen peroxide, which is scavenged by CAT and GSH-PXs (Lunec, 1990; Kohen and Nyska, 2002). In the present study, there was a highly significant increase in the SOD level in all diseased animals, that was probably a response to higher superoxide radicals causing the inflammation reactions in acute and chronic local TRP and TP. In chronic local TRP, there was a significant increase in the SOD activity in buffalo than cattle. This could be attributable to the role of SOD in the resolution of chronic inflammation through neutrophil apoptosis that is more active in buffalo (El Kebir and Filep, 2013, Pathan et al., 2015; Brostjan and Oehler, 2020). Nevertheless the SOD activity significantly increased in cattle with TP compared with buffalo. This could be associated with a higher lipid peroxides production in cattle than in buffalo. The GSH-PX activity increased in all diseased animals except in buffalo with chronic TRP, it was significantly decreased. This means that the significant difference between cattle and buffalo was observed only in chronic TRP which confirmed by presence of significant interaction between species and disease at GSH-PX activity (table 2). The increased GSH-PX activity may be attributed to the increased requirement to this enzyme to boost the defensive mechanism of the animal against oxidation, while decreased level of the GSH-PX activity in buffalo with chronic TRP indicated an exhausted antioxidant defense system (Dröge, 2002). The increase of GSH-PX activity in cattle than buffalo with chronic TRP is consistent with increasing MDA in this group due to higher lipid peroxides in cattle than in buffalo (Nouri et al., 2011). The GSH is another significant antioxidant that presents in the cell in its reduced form, serving as an electron donor. During the reduction in the peroxide level, GSH is converted to its oxidized form, glutathione disulfide (GSSG), which can be converted again to GSH through the activity of glutathione reductase.

An increase in the GSSG/GSH ratio is indicative of oxidative stress. This means that the low GSH level can indicate oxidative stress since the enzyme is directly targeted at removing hydrogen peroxide generated during the dismutation of free radicals (Chaudhary et al., 1994; Dröge, 2002). In this study, the reduced GSH activity significantly decreased in all diseased animals, with no significant difference between cattle and buffalo. As well as, catalase activity was significantly decrease in all diseased groups of buffalo without any significant difference between cattle and buffalo. TAC is the activity of both the enzymatic and nonenzymatic antioxidant defense systems. In the present study, the TAC activity did not show any significant changes between groups except in buffalo with acute local TRP, there was a significant increase in TAC activity. Several studies have reported the decline of the antioxidant enzymes with inflammatory diseases in animals and human (Ibrahim et al., 2016; Umeki et al., 1987). By contrast, in this study, there were significant increases of SOD and TAC activities in acute local TRP and this consistent with previous study on calves with acute pneumonia (Al-Qudah, 2009). The increase of antioxidant enzyme response to the increase in free radicals would limit production of ROS at the acute phase until cellular amounts of the reduced glutathione would become insufficient for hydroperoxide reduction by GSH-PX in chronic phase leading to reduction in antioxidant enzyme activities (Gupta et al., 2009). In this study, the pregnancy had no significant effect on oxidative stress parameters (Table 2). This could be attributed to that not all animals were at transition period and they were at different stages of pregnancy and lactation. As, it is well known that oxidative stress seems to have more increase during early lactation or just after parturition in cattle and buffalo (Sharma et al., 2011 and Singh et al., 2017). The effect of the disease was significant on all oxidative stress parameters except catalase which did not show any significant change between groups as previously reported on buffalo with TRP (Elgiouhy et al., 2019).

CONCLUSIONS

It can be concluded that the type and sequelae of FBS affected mainly on oxidative stress indices in cattle and buffalo. Cattle surpass buffalo in production of lipid peroxides which indicate more oxidative damage and more inflammation and systemic reactions. Whereas, buffalo with chronic local TRP showed an exhausted antioxidant defense system because of

lower GSH-PX activity than in cattle that leading to more chronic damage and fibrosis. This could explain why the clinical signs in cattle with FBS are more pronounced than in buffalo, while its complications and chronicity are more prevalent in buffalo than in cattle. It is suggested that future researches should focus on the establishment of oxidative stress panel for each species that may allow the determining appropriate oxidative stress biomarkers in a particular disease and

the development of antioxidant therapy that may delay the progress of the disease.

ACKNOWLEDGEMENTS

The authors gratefully acknowledge King Faisal University, represented by deanship of scientific research, on the material support for this research under the project number (GRANT 3,564) during the academic year 1444AH/ 2023 AD.

REFERENCES

- Abdelaal AM, Floeck M, El Maghawry S, Baumgartner W (2009) Clinical and ultrasonographic differences between cattle and buffalo with various sequelae of traumatic reticuloperitonitis. *Vet Med-Czech* 54:399-406.
- Abu-Seida AM, Al-Abbadi OS (2016) Recent advances in the management of foreign body syndrome in cattle and buffalo: a review. *Pak Vet J* 36:385-393.
- Al-Qudah MK (2009) Oxidative stress in calves with acute or chronic bronchopneumonia. *Revue de Médecine Vétérinaire*, 160:231-236
- Andrew WG, Donald EP, Polly SM, Danuta S, Ana IC, Zoltan U, Anna C, William ES (2015) Gender and racial differences in endothelial oxidative stress and inflammation in patients with symptomatic peripheral artery disease. *Journal of Vascular Surgery* 61: 1249-1257.
- Brostjan C, Oehler R (2020) The role of neutrophil death in chronic inflammation and cancer. *Cell Death Discov* 6:26.
- Bozkuluhan K, Atakisi E, Atakisi O (2013) Nitric oxide levels, total antioxidant and oxidant capacity in cattle with foot-and-mouth-disease. *Kafkas Univ Vet Fak Derg* 19:179-181.
- Braun U, Götz M (1994) Ultrasonography of the reticulum in cows. *Am J Vet Res* 55:325-332.
- Chaudhary AK, Nokubo M, Reddy GR, Yeola AN, Morrow JD, Blair JA, Mametl (1994) Detection of endogenous malondialdehyde deoxyguanosine adducts in human liver. *Science* 265:1580-1582.
- Dröge W (2002) Free radicals in the physiological control of cell function. *Physiol Rev* 82:47-95.
- El-Ashker M, Salama M, El-Boshy M (2013) Traumatic Reticuloperitonitis in water buffalo (*Bubalus bubalis*): clinical findings and the associated inflammatory response. *J Vet Med* 2013:1-6.
- Elgiouhy M, Abdelaal A, Gouda S, Naseer E, Hashish A and Elgaml S (2019) Modulations of biochemical parameters in Egyptian buffaloes affected by diffuse peritonitis, *Italian Journal of Animal Science* 18: 963-970.
- El-Kebir D, Filep G (2013) Targeting neutrophil apoptosis for enhancing the resolution of inflammation. *Cells* 2:330-348
- Erel O (2005) A new automated colorimetric method for measuring total oxidant status. *Clin Biochem* 38:1103-1111.
- Fawzy S, Gomaa A N, Nassif NM, Hafez MA (2017) Comparative study on traumatic reticulitis and traumatic pericarditis in cattle and buffalo. *Kafrelshikh Vet Med J* 15:17-35.
- Folnožić I, Turk R, Đuričić D, Vince S, Pleadin J, Flegar-Meštrić Z, Valpotić HT, Dobranić GD, Samardžija, M (2015) Influence of body condition on serum metabolic indicators of lipid mobilization and oxidative stress in dairy cows during the transition period. *Reprod Domest Anim* 50:910-917
- Saleh MA, Rateb H.Z, Misk NA (2008) Comparison of blood serum proteins in water buffaloes with traumatic reticuloperitonitis and sequelae. *Research in Veterinary Science* 85: 208-213
- Shono S, Gin A, Minowa F, Okubo K, Mochizuki M (2020) The Oxidative Stress Markers of Horses—the Comparison with Other Animals and the Influence of Exercise and Disease. *Animals* 10:617-626.
- Fubini SL, Ducharme N (2016) Farm animal surgery-e-book. Elsevier health sciences.
- Gugjoo MB, Dar HS, Ahmad AR, Hussain TH, Dar DM, Parrah J, Dhama K (2021) Traumatic reticuloperitonitis in cattle and buffalo: recent advances in understanding of etiopathogenesis, diagnosis and treatment. *Indian Journal of animal science* 91(11):895-905.
- Gupta S, Sodhi S, Mahajan V (2009) Correlation of antioxidants with lipid peroxidation and lipid profile in patients suffering from coronary artery disease. *Expert Opin Ther Targets* 13:889-894
- Hussein A, Hana K, Yasmin O (2018) Oxidative stress indices and pathological changes in cattle with traumatic pericarditis. *J Hellenic Vet Med Soc* 68:579-586.
- Ibrahim MH, EL-seedy Y, Gomaa NA (2016): Cytokine response and oxidative stress status in dairy cows with acute clinical mastitis. *J Dairy Vet Anim Res* 3: 00064
- Kohen R, Nyska A (2002) Invited review: oxidation of biological systems: oxidative stress phenomena, antioxidants, redox reactions, and methods for their quantification. *Toxicol Pathol* 30:620-650.
- Kumar V, Dhar P (2013) Foreign body impaction in a captive Sambar (*Rusa unicorn*). *Vet World* 6:49-50.
- Lunec J (1990) Free radicals: their involvement in disease processes. *Ann Clin Biochem* 27:173-182.
- Macedo GG, de Oliveira Ferreira VL, Chiacchio BS (2021) an overview on traumatic reticulopericarditis in cattle and buffalo. *Buffalo Bulletin* 40:213-225
- Misk NA, Semieka MA, Ali SEM (2001) Varieties and sequelae of ingested foreign bodies in buffalo and cattle. *Assiut Vet Med J* 46.
- Mittal M, Siddiqui MR, Tran K, Reddy SP, Malik AB (2014) Reactive oxygen species in inflammation and tissue injury. *Antioxid Redox Signal* 20:1126-1167.
- Nielsen F, Mikkelsen BB, Nielsen JB, Andersen HR, Grandjean P (1997) Plasma malondialdehyde as biomarker for oxidative stress: reference interval and effects of life-style factors. *Clin Chem* 43:1209-1214
- Nouri M, Haji Hajikolaei M, Shahryari A, Shirazi M, Rasooli A (2011) Hepatic triacylglycerols and serum non-esterified fatty acids (NEFA) variations in indigenous water buffalo (*Bubalus bubalis*) in the province of Khuzestan, Iran. *Iran J Vet Med* 5:151-155.
- Pathan MM., Kaur M., Mohanty AK., Kapila S., Dang AK (2015): Comparative evaluation of neutrophil competence and activity of cows and buffaloes around parturition. *J Appl. Anim. Res.*, 43: 61-68.
- Umeki S., Sumi M., Niki Y., Soejima R (1987) Concentration of superoxide dismutase and superoxide anion in blood of patients with respiratory infections and compromised immune systems. *Clin. Chem.*, 33: 2230-2233.
- Radostits OM., Gay CG., Blood DC., Hinchcliff KW (2010) *Veterinary Medicine. A textbook of the Diseases of Cattle, Sheep, Pigs and Goats*. 10th ed, WB Saunders Company Ltd, New York: pp 3-31
- Ramprabhu P, Dhanapalan, Prathaban S (2003) Comparative efficacy of diagnostic tests in the diagnosis of traumatic reticuloperitonitis and allied syndromes in cattle. *Isr J Vet Med* 58:2-3.
- Rehage J, Kaske M, Stockhofe-Zurwieden N, et al (1995) Evaluation of the pathogenesis of vagus indigestion in cows with traumatic reticuloperitonitis. *J Am Vet Med Assoc* 207:1607
- Vanitha V, Nambi AP, Gowri B, Kavitha S (2010) Rumen impaction cattle with indigestible foreign bodies. *Vet Anim Sci* 6:138-140