

Journal of the Hellenic Veterinary Medical Society

Vol 73, No 4 (2022)



Border Disease In A Lamb: A Case Report

F Akkaya, FZ Evci, ZA Küpeli, Ç Kandemir, T Taşkın, N Koşum

doi: [10.12681/jhvms.28216](https://doi.org/10.12681/jhvms.28216)

Copyright © 2023, fatma akkaya, Fatma Zehra Evci, Zehra Avcı Küpeli, Çağrı Kandemir, Turğay Taşkın, Nedim Koşum



This work is licensed under a [Creative Commons Attribution-NonCommercial 4.0](https://creativecommons.org/licenses/by-nc/4.0/).

To cite this article:

Akkaya, F., Evci, F., Küpeli, Z., Kandemir, Ç, Taşkın, T., & Koşum, N. (2023). Border Disease In A Lamb: A Case Report. *Journal of the Hellenic Veterinary Medical Society*, 73(4), 5083–5088. <https://doi.org/10.12681/jhvms.28216>

Border disease in a lamb: A Case Report

F. Akkaya¹, FZ. Evci², Z. Avci Kupeli³, C. Kandemir¹, T. Taskin¹, N. Kosum¹

¹Department of Animal Science, Faculty of Agriculture, Ege University, İzmir, Turkey

²Department of Internal Medicine, Faculty of Veterinary Medicine, Bursa Uludağ University, Bursa, Turkey

³Department of Pathology, Faculty of Veterinary Medicine, Bursa Uludağ University, Bursa, Turkey

ABSTRACT: In this case, it was aimed to report the clinical, hematological and pathological analysis results of a lamb born as infected with border disease virus (BDV). Severe central nervous system findings such as standing inability, continuous teeth grinding, muscle fasciculations in the head, ear and tail, hair loss around the eyes, lips and ears, abnormal appearance of the fleece, ataxia/rhythmic tremor and incoordination were detected in the case of lamb infected with BDV. The presence of BDV antibody and the levels of Triiodothyronine (T3) and Thyroxine (T4) were investigated in the serum samples for definite diagnosis. The tissue samples obtained from the brain and cerebellum were evaluated histopathologically and diagnosis of BDV was confirmed by necroscopic findings.

Keywords: Border Disease, Lamb, Persistently Infected, Tremor, Triiodothyronine (T3)

Corresponding Author:

Fatma Akkaya, Department of Animal Science, Faculty of Agriculture, Ege University, 35040, Bornova-İzmir, Turkey
E-mail address: fatma.akkaya@ege.edu.tr

Date of initial submission: 10-12-2021
Date of acceptance: 14-01-2022

INTRODUCTION

In the recent years, increased number of Border Disease cases in sheep caused very highly important economic problems for the owners of small ruminant enterprises. The agent of this disease, which is also called as Border Disease, belongs to *Pestivirus* genus from *Flaviviridae* family (De Mia et al., 2005). This genus comprises four viruses such as Border Disease Virus (BDV), Bovine Viral Diarrhea Virus (BVDV) Genotype 1, BVDV Genotype 2 and classical swine fever virus (KDVV). The primary hosts are the bovines (bovine viral diarrhea) while sheep and goats (Border Disease) manifest disease signs (Stalder et al., 2005; Oğuzoğlu, 2008; Ural and Erol, 2017). There are many antigenic, biological and physical similarities between BVDV and BDV isolates. Border Disease may cause abortion, congenital deformation, stillbirth and alive born lambs with low viability probability depending on gestational stage at birth. Abortion is observed in the first gestational periods (45th-60th days) of the infected sheep. Viral infection persists throughout lifetime in the lambs born to infected sheep after the second gestational month (60th-80th days). Nervous system-related findings are frequently observed in such persistently infected lambs. These findings include rhythmic tremors in the head and neck regions, ataxia, severe muscle trembling, shortening in the long bones, abnormal appearance of fleece coat, remarkable trembling in the hindlegs, hair loss around the head, lips and ears, and nystagmus (Stalder et al., 2005; Oğuzoğlu, 2008). In this study, it was aimed to present the clinical, laboratory and pathological analysis reports of a lamb diagnosed with Border Disease.

CASE HISTORY

This case report presents a Tahirova crossbred male lamb born in a private small ruminant enterprise. No clinical finding was detected in the sheep before beginning of the birth season in the enterprise. After birth season started, several abnormal findings such as standing inability, high fever, rhythmic muscle tremors in the head and neck regions and impaired quality of fleece were found in an alive-born lamb of a sheep.

The lamb was taken to a separate chamber for regular evaluation of the clinical findings immediately after the birth (Figure 1). Since the clinical findings suggested Border Disease; the blood samples were properly taken from vena jugularis to serum tubes without anticoagulant (8.5 ml) and with EDTA (3 ml) for definite diagnosis before the newborn lamb re-



Figure 1. The appearance of a lamb infected with Border disease virus

ceived colostrum yet. Additionally, CSF was also obtained from the animal (Pescador et al., 2004). After death of the lamb was confirmed; brain tissue samples were also referred to the laboratory for pathological analysis. A control group was created by obtaining blood samples of 5 healthy lambs from the same age group (Table 1). The blood samples were centrifuged at 3000 rpm for 5 mins within the first 4 hours to remove serum. The serum samples were stored by freezing at -20°C until analysis.

Table 1. The clinical findings of the lamb with Border Disease and control group animals

The Parameters	BVD Positive Case	Control Group
Body Temperature	40.1°C	39.1 ± 0.3°C
Appetite	Normal	Normal
Pupillary Light Reflex	Decreased	Normal
Heartbeat Rate (P/min)	148	122 ± 5
Respiratory Rate (R/min)	62	41 ± 3
Nasal Discharge	Present	Absent
Conjunctival Examination	Conjunctivitis Positive	Normal

The obtained serum samples were sent to Balikesir System Laboratory for analysis. T3 and T4 hormone analysis were performed with electrochemilu-

minescence (ECL) method using Roche Cobas e801 device (Roche Diagnostics GmbH Sandhofer Strasse 116, 68305 Mannheim, Germany). The serum sample of the lamb with clinical symptoms was assayed for BDV antibody levels with ELISA method (Elisa Detection of Specific Antibodies to the P80 Protein of the Viruses of BVD and BD) using the Biotek ELx808 Elisa Reader (Biotek Instruments, Highland Park, Box 998, Winooski, VT05404-0998, USA).

The tissue samples taken from brain and cerebellum were sent to the Pathology Laboratory of Bursa Uludag University Veterinary Faculty. The samples were fixed in 10% buffered formaldehyde for two days and dehydrated by applying graded alcohol series and xylene. After paraffin blocking procedure, the tissues were taken to 4-micron-thick sections and stained with hematoxylin eosin (HE) and luxol fast blue (LFB).

Free T3 and T4 levels in the serum samples of the lambs included in the study were presented in Table 2. Free T3 level of the infected lamb was very low (1.99 pg/ml) whereas mean level of this parameter was 5.70

pg/ml in the control group. Mean free T4 levels of the lambs in the control group was 1.76 ng/dL whereas a very low level such as 0.89 ng/dL was found in the infected lamb. Also, BDV antibody analysis of the lamb reported as the case resulted positive.

Table 2. Free T3 and Free T4 levels in the 5 lambs of the control group and the BDV-positive lamb

Lambs	Free T3 (pg/mL)	Free T4 (ng/dL)
Healthy Lamb-1	6.10	1.76
Healthy Lamb -2	5.51	1.35
Healthy Lamb -3	7.29	2.46
Healthy Lamb -4	4.55	1.44
Healthy Lamb -5	5.07	1.79
BDV Positive Lamb	1.99	0.89

The vacuolization of the substantia alba, hyperemia of blood vessels as well as disappearance of Purkinje cell nuclei (necrosis) and complete loss of morphology in some nuclei (hypoplasia) were noticed in the cerebellum (Figure 7). Vacuolization (hypomyelination) of substantia alba was encountered in the brain (Figure 8).

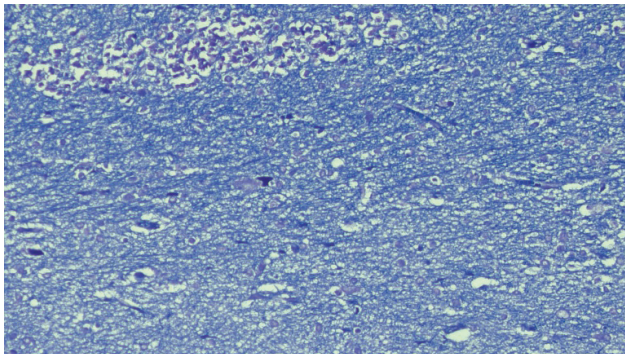


Figure 2. Cerebellum. Hypomyelination . Luxol Fast Blue x20

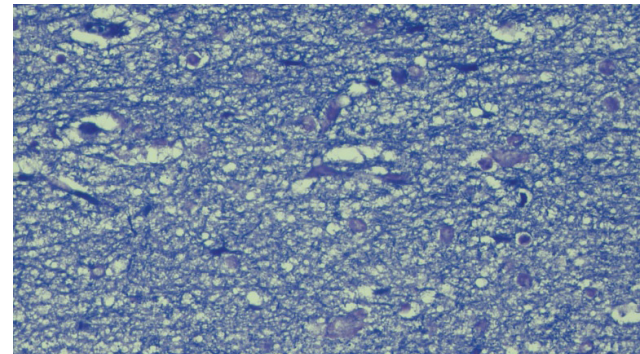


Figure 3. Cerebellum. Hypomyelination . Luxol Fast Blue x40

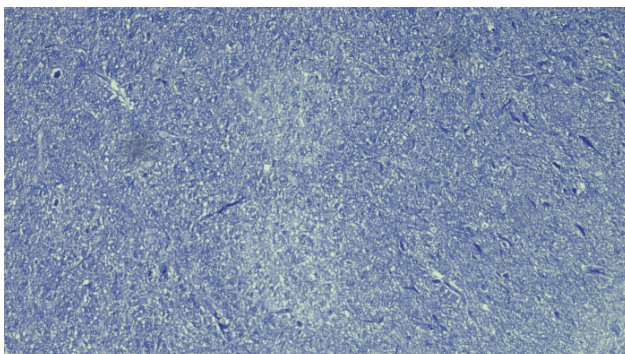


Figure 4. Brain. Hypomyelination areas in substantia alba. Luxol Fast Blue x10

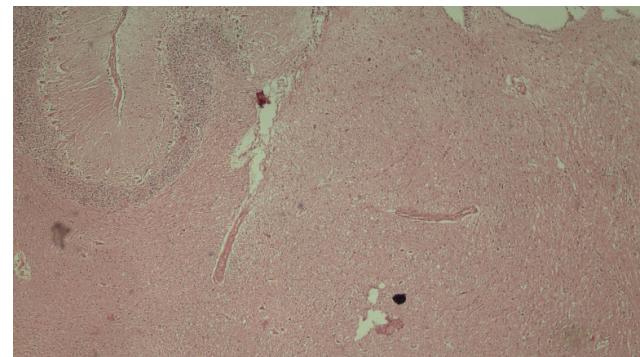


Figure 5. Cerebellum. Hypomyelination areas in substantia alba. H&E x4

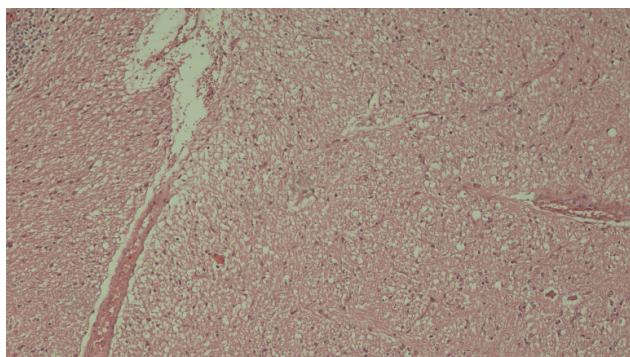


Figure 6. Cerebellum. Hypomyelination areas in substantia alba. H&E x10

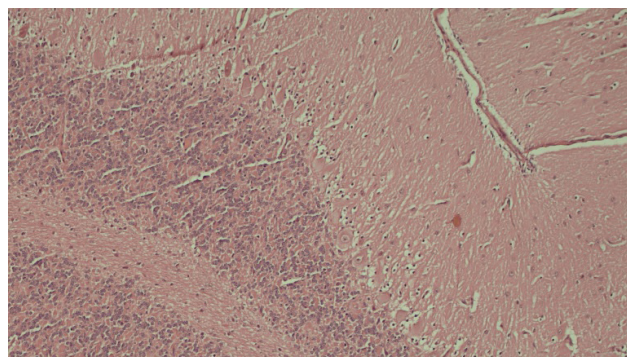


Figure 7. Cerebellum. Disappearance of Purkinje cell nuclei in substantia grisea. H&E x10

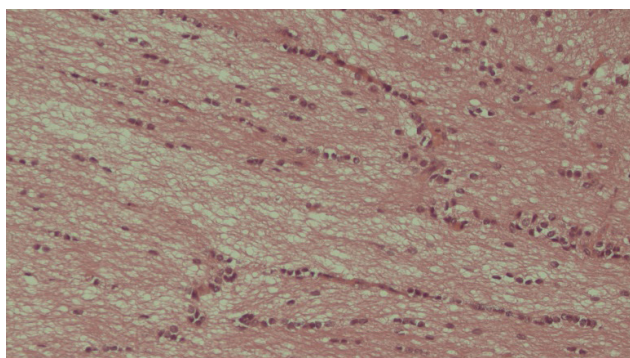


Figure 8. Brain. Hypomyelination areas in substantia alba. H&E x20

DISCUSSION

Border Disease is a viral disease that causes important economic losses in small ruminant breeding worldwide (Monies et al., 2004). Hence, early diagnosis and the soonest determination of protection methods for the disease has very great importance. The case presented in the report was detected to be infected with Border Disease Virus (BDV) by antibody screening specifically performed for the disease according to the clinical findings.

Embryonic deaths and abortions occur since virus causes acute necrotising placentitis without manifesting remarkable clinical symptoms in the sheep infected in the first gestational period (Thabti et al., 2005). On the other side, the viral agent transmitted to the newborn that don't have a complete immune system yet (until 60th-80th and 80th-100th days of gestation in the sheep and the goats, respectively) via transplacental route leads to fetal infections in the newborn ruminants of the sheep infected between the 60th-80th days of gestation. It negatively affects the release of thyroid hormones in the fetus and causes irreversible damages in the brain (Stalder et al., 2005). Inadequate

release of thyroid hormones negatively affects also release of phosphodiesterase-CNP enzyme which is responsible for myelination and that leads to negative events such as hypomyelination in the cerebellum, perivascular cell infiltration in the white matter of the brain and lymphoid depletion in the thymus (Thabti et al., 2005; Oğuzoğlu, 2008). The thyroid hormone levels of the presented case were detected to be very lower compared with the levels of FT3 and FT4 hormones assessed in the healthy lambs.

Myelin defects that occur in Border Disease have remarkable clinical implications. These clinical implications include the picture termed as “hairy shakers” generally as a because of muscle tremor in combination with abnormal hair appearance due to hair follicular pathology, incoordination, ataxia and continuous teeth grinding in the lambs born as infected with virus (Monies et al., 2004). Several findings such as loss of hair around eyes and lips, abnormal appearance of fleece like dog hair and muscle tremors were observed also in the lamb presented in our case report (Figure 1; Table 1).

The most consistent and severe microscopic

changes occur in the periventricular fields, cerebellum, brain stem, cerebral hemispheres and occasionally medulla spinalis while it is characterized with nonsuppurative and/or necrotising meningoencephalomyelitis and frequently seen accompanied with hypomyelinogenesis. The most prominent findings include periventricular leukomalacia as well as gliosis and infiltration of ependymal mononuclear cells along cerebrospinal axis. Focal or multifocal malacia may be encountered in the substantia grisea and substantia alba of the cerebral hemispheres, thalamus, hypothalamus, periventricular areas and brain stem. The parenchyma neighboring to malacic lesions demonstrates neuronal loss, neuronal eosinophilia or dystrophic mineralization accompanied with neuronal necrosis, mononuclear inflammatory reactions, focal or diffuse gliosis and neurophagia. It is characterized with the most severe necrotic and dysplastic changes due to hypoplastic cerebella, loss of Purkinje cells and focal to diffuse depletion of granulocytes (Toplu et al., 2011). In a similar way, histopathological implications such as hypomyelination in the cerebellum (Image 2-3) and loss of Purkinje cells (Figure 7) were determined.

Although, vaccination is important in prevention of such diseases, unfortunately, as far as known, no specific vaccine for sheep and goats against the viral agent of Border Disease is available in our country and worldwide. BVDV vaccine is commonly used in bovines as the primary host while it shows partial protection in sheep (Valdazo-Gonzales et al., 2006). After removal of the lamb born as persistently infected in case report and its mother sheep from the flock, whole remaining flock was applied Bovine viral diarrhoea vaccine (Hiprabovis-3®) with a half bovine dose

even it provides partial protection (Arnal et al, 2004; Monies et al., 2004; Oğuzoğlu, 2008).

CONCLUSION AND RECOMMENDATIONS

Taking the economic losses caused by this disease into consideration; it is concluded that development of a specific vaccine against the viral agent should be primarily considered. On the other side, the urgently detection of the persistently infected animal and removal from the flock is one of the commonly used protection methods. It is critically important to detect the presence of persistently infected animal in the flock for this type of diseases (Arnal et al, 2004). The organization of the regular screening tests for the reported disease by the enterprises will assure early detection of the disease in the peracute period yet and taking the precautions urgently. The awareness of the fact that there is no currently known treatment of the irreversible damages in the brain caused by the disease, the importance of the regular screening tests is emphasized more strongly. On the other side, it has been suggested that this disease causes pathological effects on the thyroid gland and leads to significant decreases in the levels of the thyroid hormones. The case presented in the report points out that more studies that are comprehensive needed to clarify the effect of Border Disease virus on the function of thyroid gland.

CONFLICT OF INTEREST

The authors of this paper certify that they have no affiliations with or involvement in any organization or entity with any financial interest, or non-financial interest in the subject matter or materials discussed in this manuscript.

REFERENCES

- Arnal M, Fernandez de Luco D, Riba L, Maley M, Gilray J, Willoughby K, Vilcek S, Nettleton P (2004): A novel pestivirus associated with deaths in Pyrenean chamois. *J Gen Virol*, (85): 3653-3657.
- De Mía GM, Greiser-Wilke I, Feliziani F, Giammarioli M, De Giuseppe A (2005): Genetic characterization of acaprine pestivirus as the first member of a putative novel pestivirus subgroup. *J Vet Med B*, (52): 206-210.
- Monies RJ, Paton DJ, Vilcek S (2004): Mucosal disease-like lesions in sheep infected with Border disease virus. *Vet Rec*, (155): 765-769.
- Oğuzoğlu TÇ (2008): Sınır Hastalığı (Border Disease), Ankara Üniv Vet Fak Derg., (55): 69-74.
- Oğuzoğlu TÇ, Tan MT, Demir AB, Bilge-Dağalp S, Karaoğlu MT, Alkan F, Burgu İ (2006): Koyun ve keçilerde yakın akraba pestivirus enfeksiyonlarının (BDV, BVDV 1 ve BVDV 2) Serolojik ve virolojik olarak araştırılması. TÜBİTAK-VHAG, 2009.
- Pescador Argenta Caroline, Corbellini Luis Gustavo, Driemeier David, Gonçalves Ricardo Kalil, Farias Cruz Cláudio Estêvão (2004): Neurological disorder associated with pestivirus infection in sheep in Rio Grande do Sul, Brazil *Ciência Rural*, 34(3): 935-938.
- Stalder HP, Meier Ph, Pfaffen G, Wageck-Canal C, Rüfenacht J, Schaller P, Bachofen C, Marti S, Vogt HR, Peterhans E (2005): Genetic heterogeneity of pestiviruses of ruminants in Switzerland. *Prev Vet Med*, (72): 37-41.
- Thabti F, Letellier C, Hammami S, Pepin M, Ribiere M, Mesplede A, Kerkhofs P, Russo P (2005): Detection of a novel border disease virus subgroup in Tunisian sheep. *Arch Virol*, 150: 215-229.
- Toplu N, Oğuzoğlu TÇ, Epikmen ET, Aydoğan A (2011): Neuropathologic Study of Border Disease Virus in Naturally Infected Fetal and Neonatal Small Ruminants and Its Association With Apoptosis. *Veterinary Pathology*, 48(3): 576-583.
- Ural ZE, Erol N (2017): Aydın ve İzmir illerindeki koyun ve keçilerde pestivirus enfeksiyonunun serolojik ve virolojik olarak araştırılması, *Harran Üniv Vet Fak Derg*, 6(1): 63-68.
- Valdazo-Gonzales B, Alvarez-Martinez M, GreiserWilke I (2006): Genetic typing and prevalence of Border Disease Virus in small ruminants flocks in Spain. *Vet Microbiol*, (117): 141-153.