

Journal of the Hellenic Veterinary Medical Society

Vol 72, No 3 (2021)



Complicated corneal ulceration in cats: diagnosis and treatment outcomes of 80 cases (2014-2018)

KM ALI, AA MOSTAFA, S SOLIMAN

doi: [10.12681/jhvms.28485](https://doi.org/10.12681/jhvms.28485)

Copyright © 2021, KM ALI, AA MOSTAFA, S SOLIMAN



This work is licensed under a [Creative Commons Attribution-NonCommercial 4.0](https://creativecommons.org/licenses/by-nc/4.0/).

To cite this article:

ALI, K., MOSTAFA, A., & SOLIMAN, S. (2021). Complicated corneal ulceration in cats: diagnosis and treatment outcomes of 80 cases (2014-2018). *Journal of the Hellenic Veterinary Medical Society*, 72(3), 3041–3050. <https://doi.org/10.12681/jhvms.28485>

Complicated corneal ulceration in cats: diagnosis and treatment outcomes of 80 cases (2014-2018)

K.M. Ali¹, A.A. Mostafa¹, S. Soliman²

¹Department of Small Animal Surgery and Ophthalmology, Faculty of Veterinary Medicine, Cairo University, Egypt

²Department of Internal Medicine and Infectious Diseases, Faculty of Veterinary Medicine, Cairo University, Egypt

ABSTRACT: The study describes the most common clinical and endoscopic findings associated with complicated corneal ulcers in cats and evaluates the short-term outcomes after surgical interventions. Eighty client-owned cats of different breeds with corneal ulcers were included. Cats were clinically evaluated to initially determine corneal abnormalities. Endoscopic examination of the corneas was performed to determine anterior and posterior segments' abnormalities. Non-healing superficial ulcer was treated by superficial keratectomy and deep stromal ulcers were treated using conjunctival flaps. Corneal sequestrum were treated by partial keratectomies and conjunctival flaps. Anterior synechiae were treated via peripheral iridectomy and separation of the adhesion between the iris and the inner cornea. Symblepharon were treated by removal of the adhered conjunctival membrane from the cornea. Unresponsive endophthalmitis was treated surgically by exenteration. Outcomes after surgical managements of selected corneal abnormalities were assessed clinically and endoscopically. Non-healing superficial ulcer, deep stromal ulcer with descemetocoele, endophthalmitis, symblepharon, corneal sequestration and anterior synechiae with secondary glaucoma and corneal scarring were the recorded complications of corneal ulcer. FHV-1 was a common etiologic factor of corneal ulceration. Persistent corneal scars of varying shape and size developed in cats with deep stromal ulcer, anterior synechiae, and corneal sequestration. Domestic shorthaired and Persian cats were the most predisposed breeds to FHV-1 infection and subsequent corneal ulceration. Management of patients with corneal ulcer would prevent serious complications. No age or sex predisposition to complicated corneal ulceration in cats was noticed.

Keywords: ophthalmology, cat, ulcer, perforation, corneal surgery

Corresponding Author:

A.A. Mostafa, Department of Veterinary Surgery, Anesthesiology & Radiology,
Faculty of Veterinary Medicine, Cairo University, Giza 12211, Egypt.
E-mail address: aymostafa@cu.edu.eg

Date of initial submission: 12-12-2019

Date of revised submission: 15-02-2021

Date of acceptance: 11-03-2021

INTRODUCTION

Corneal ulceration is one of the common eye problems affecting humans (Whitcher et al., 2001), and a wide variety of animal species (Bentley, 2005; Michau et al., 2003). It can cause varying degrees of visual impairment or even blindness. Corneal ulcers are commonly seen in veterinary practice, and although uncomplicated ulcers would likely heal without veterinary attention, a complicated ulcer requires optimal management (Maggs, 2008). Corneal transparency and clarity are associated with its unique collagen and extracellular matrix organization (Mohan et al., 2005). Decreased corneal protection or increased corneal abrasion may result into ulceration. Uncomplicated stromal injuries tend to undergo avascular healing; however, infected or destructive lesions usually stimulate and require vascularized healing (Maggs, 2008). After injury, stromal keratocytes synthesize collagen, glycosaminoglycans, and mucoprotein of the ground substance and transform to fibroblasts that produce nontransparent collagen (Hankanson and Merideth, 1987). The nontransparent collagen causes different levels of visual impairment (Wilkie and Whittaker, 1997). Furthermore, collagen fibrils produced during repair of a stromal lesion are laid down in an irregular pattern and often produce a grey “wispy” opacity within the cornea that interferes with light transmission (Vanore et al., 2007). In the Persian, Siamese, and occasionally Domestic shorthaired (DSH) cats, slow-healing epithelial defects caused by a variety of etiologic factors may result in corneal nigrum or sequestrum (Featherstone and Sansom, 2004). This may produce a brownish-black plaque or deposit that is usually located centrally or para-centrally and stimulates vascularization (Laguna et al., 2015).

Ulcerative keratitis management often requires a combination of medical and surgical therapeutic strategies (Barros et al., 2005; Vanore et al., 2007). In deep corneal ulceration, several surgical procedures have been proposed including conjunctival and (Hankanson and Merideth, 1987) corneal grafts (Wichayacoop et al., 2009), corneo-conjunctival transposition (Vanore et al., 2007), porcine small intestinal submucosa graft (Goulle, 2012), amniotic membrane transplantation (Barachetti et al., 2010), and application of tissue adhesives (Hankanson and Merideth, 1987; Barros et al., 2005).

Feline herpesvirus-1 (FHV-1) is one of the most frequently encountered causes of conjunctivitis and keratitis in cats (Stiles et al., 1997) and commonly

produces an epithelial ulcer that may be dendritic or geographic (Groth et al., 2014). In severe complicated cases, deep stromal ulceration, descemetocoele, or even globe rupture may develop (Stiles, 2014). Diagnosis of herpesvirus ocular lesions is often difficult due to the carrier state and the ubiquitous nature of the virus (Stiles and Townsend, 2007). Nevertheless, it can be either cultured, or detected with PCR, from 10% of conjunctivae and 50% of corneas of clinically normal cats (Stiles and Townsend, 2007).

The purposes of the study were the determination of the most common etiologic factors and manifestations associated with complicated corneal ulcers in cats, clinical, endoscopic and laboratory findings of complicated corneal ulceration, and evaluation of the short-term treatment outcomes.

MATERIALS AND METHODS

Animals

The present study was carried out on 80 client-owned cats examined by the Ophthalmology Service at the Department of Small Animal Surgery, Faculty of Veterinary Medicine, Cairo University, Egypt from September 2014 to December 2018. Informed consent was obtained from the owners of the 80 cats enrolled in the present clinical study and no ethical approval was acquired. Cats that had non-healing superficial or deep stromal corneal ulceration and complicated corneal ulcer were included in the study, whereas those with superficial non-complicated or corneal erosion were excluded. Patients that had epithelial erosion or herpetic keratitis were also excluded from the study reported here. Data collected from the clients included signalment, history of traumatic eye injury, duration of clinical signs, and history of previous medications.

Clinical and endoscopic examination

Clinical evaluation was initially performed by a qualified ophthalmologist (KMA) via slit lamp examination (SL 14 handheld slit lamp, Kowa, Tokyo, Japan) for detection of the current corneal abnormalities. Commercially available fluorescein strips (Bio-Glo® Fluorescein sodium Strips 1 mg; HUB pharmaceuticals, LLC., Rancho Cucamonga, CA, USA) were used to detect the type of corneal ulcer. Cats suspected to have anterior or posterior segment abnormality were examined endoscopically (Abd-Elhamid et al., 2014), using an 8.5 mm probe (Eickemeyer video endoscope unit supplied with halogen light source 150

watt, Vetlux, Tuttlingen, Germany). The endoscope unit was connected through an adapter to a computer device. Cats were sedated using xylazine hydrochloride 2% (Xylaject®;ADWIA, Cairo, Egypt) in a dose of 1mg/kg *b.w. i.m.* Topical anesthesia (Douet et al., 2013) of the cornea was achieved via instillation of Benoxate hydrochloride 0.4% (Benox®; EIPICO, Cairo, Egypt). The endoscopic probe was then gently placed on the corneal surface and series of images and video loops were captured for each examined cat. Measurement of intraocular pressure (IOP) was done using Tonopen tonometer (Tonopen XL®, Reichert Technologies, NY, USA).

Laboratory examination

Isolation and detection of FHV-1 and Mycoplasma felis

Sample collection and handling

Corneal swabs were collected by rolling dry cotton-tipped applicators along the mucosal surface of the conjunctiva or region of corneal ulceration. Separate swab samples were taken from each cat for viral and mycoplasma culture. Each sample was placed into a sterile tube containing 1 ml of sterile PBS then stored at refrigerator temperature (2-5°C).

Isolation of Mycoplasma felis

The corneal swabs were tested for the presence of *M. felis* on PPLO agar (Difco Laboratories) supplemented with thallous acetate (0.5 g/l), ampicillin (0.4

g/l), inactivated horse serum (250 ml/l), D-glucose (10 g/l) and freshly prepared yeast extract (70 ml/l). Incubation was performed at 37°C for 2-5 days in an atmosphere of 10% CO₂. *Mycoplasma* isolates were sub-cultured on ox blood agar in order to estimate hemolysis. *M. felis* was identified by colony characteristics and biochemical reactions (Razin and Freundt, 1984; Kirchhoff et al., 1985).

Detection of FHV-1 using PCR

DNA was extracted from the swabs using a QIAamp DNA mini kit (Qiagen). The swab was placed in a 1.5 ml micro centrifuge tube containing 300 µl of saline and incubated at 37°C for 10 min on a shaker. Approximately 200 µl of saline was then removed and placed in a fresh 1.5 ml tube, and DNA was extracted according to the manufacturer's protocol. The reaction was performed with master mix, primers (Table 1), PCR water and 5 µl of template DNA. Amplifications consisted of initial incubation at 95°C for 2 min, followed by 40 cycles of 95°C for 30 sec; 58°C for 30 sec, and 72°C for 30 sec; with final extension at 72°C for 5 min (Sandmeyer et al., 2010).

Treatment

The surgical procedure applied for each case based on whether the eye was potentially visual or not and on time to healing, recurrence rate, and availability of the technique at the time of presentation. Time to healing was defined as the number of days from surgery until removal of sutures and discontinuation of medication therapy. The surgical procedures for the reported complications were summarized in Table 2.

Table 1. The primers used for PCR of the samples suspected to have feline herpes virus-1

Primers	Amplicon
F 5'-CGG GAA AAT CCA GTA CGA GT-3'	200 bp
R 5'-AGG AAG AGT TCG GCG GTA TT-3'	

Table 2. The treatment protocols for the 80 cats with complicated corneal ulcer

Corneal abnormalities	Number of cats	Surgical procedure
Deep stromal ulcer with descemetocoele	22	Conjunctival flap
Nonhealing corneal ulcer	16	Superficial keratectomy
Unresponsive endophthalmitis	14	Exenteration
Symblepharon	6	Surgical removal of the adhered conjunctival tissues from the cornea
	5	Exenteration
Anterior synechia with secondary glaucoma	8	Peripheral iridectomy with removal of the adhered iris strands from the inner surface of the cornea
Chronic ulcer with granulation tissue	5	Superficial keratectomy and conjunctival flap
Corneal sequestration	4	Superficial keratectomy and third eye lid flap

Cats undergoing surgery were premedicated with atropine sulphate (0.04 mg/kg) and xylazine hydrochloride 2% (Xylaject®; ADWIA, Cairo, Egypt) in a dose of 1 mg/kg and anesthetized with ketamine hydrochloride 5% (Keiran; EIMC pharmaceuticals Co., Cairo, Egypt) in a dose of 20 mg/kg. Corneal anesthesia was established as previously described for endoscopic examination (Douet et al., 2013). The eye was prepared for aseptic surgery and draped routinely.

Cats with indolent (non-healing superficial) corneal ulcer were treated by superficial keratectomy under a binocular surgical microscope (12.5x; 66 VISION TECH CO., LTD. China) with the cat under general anesthesia. The technique utilized a microsurgical blade to excise the superficial stroma and epithelium under and around the indolent ulcer (Chavkin, 1990). Cats with deep stromal ulcer were treated by a conjunctival flap. The conjunctival flap was created in the bulbar conjunctiva using Steven's tenotomy scissors, with the base of the flap being attached to the limbus. The length of the flap was adjusted to cover the corneal defect without tension. The flap was then sutured to the borders of the corneal defect using 7-0 monofilament polypropylene (Prolene®; Ethicon, USA) in a simple interrupted. The sutures were placed deeply in the corneal stroma without penetrating the cornea completely (Gelatt and Brooks, 2011). Corneal sequestrum was managed surgically in 4 cats (5%) via partial keratectomy and conjunctival flap (Kirschner et al., 1991). A 64 Beaver blade was used to sharply remove the necrotic lesion from the cornea. The dissection was continued through the stromal thickness to a depth that allowed removal of the majority of the pigment associated with the sequestrum then a conjunctival flap was applied. Healed corneal ulcer (in 7 eyes; 8.75%) with granulation tissue were treated by use of conjunctival flap after surgical excision of the granulation tissue.

Cats diagnosed with anterior synechiae and secondary angle closure glaucoma (8 eyes; 10%) were treated surgically by peripheral iridectomy and separation of the adhesion between the iris and the inner cornea (Chavkin et al., 1990). Symblepharon were treated by removal of the adhered conjunctival membrane from the cornea in 6 out of 11 cats. In the remaining 5 cats the eye was presented by marked hypotony and phthisis bulbi, these eyes were not potential for vision and were treated by exenteration. Daily ophthalmic application of tobramycin (Tobrin®; Alcon, Cairo, Egypt) and dexamethasone (Corneregel®

ophthalmic gel; MINIPHARM, Cairo, Egypt) was performed 4-6 times a day after each surgical procedure. Medication dosages were decreased and then discontinued as healing occurred.

Cats diagnosed with corneal perforation followed by unresponsive endophthalmitis were treated by exenteration of the eye globe (Slatter, 2001).

RESULTS

Animals

Among the presented 80 cats, there were 46 (57.5 %) Domestic Shorthaired (DSH), 25 (31.25 %) Persian, 5 (6.25 %) Siamese, and 4 (5 %) Himalayan cats. Mean (\pm SD) age of the cats on initial evaluation was 21.2 ± 1.6 months (range, 3 months to 6 years). Fifty-two were females and twenty-eight were males. Seventy-four cats were sexually intact and six spayed. Thirty-seven (46.3%) cats had bilateral corneal abnormalities, 24 (30%) cats had right-sided corneal disease, and 19 (23.8%) cats had left-sided corneal disease. A history of short-term ophthalmic application of tobramycin and dexamethasone was reported in 15 cats.

Clinical findings

Clinical findings of complicated corneal ulcer of the 80 cats enrolled in this study included; deep stromal ulcers with descemetocoele (22 cats; 27.5%), indolent corneal ulcer and superficial nonhealing ulcer due to FHV-1 infection (16 cats; 20%), endophthalmitis with corneal involvement (14 cats; 17.5%), symblepharon (11 cats; 13.75%), anterior synechiae with secondary glaucoma and corneal scarring (8 cats; 10%), chronic ulcers with granulation tissue protruding on the surface of the cornea (5 cats, 6.25%), corneal sequestrum (4 cats; 5%). Corneal abnormalities associated with each cat breed are demonstrated in Table 3.

The superficial nonhealing ulcers were presented after unsuccessful treatment for several weeks and were associated with corneal vascularization and detached epithelium at the edges of the ulcer (Figure 1a), these ulcers stained with fluorescein dye that migrated beyond the edges of the ulcer (Figure 1b), while in FHV-1 infected cats they were geographically distributed with no or minimal corneal vascularization (Figure 1c). Deep stromal ulcers were associated with corneal melting, descemetocoele and variable degrees of corneal edema and vascularization (Figure 1d). In cats with chronic ulcers, corneal vascularization and

Table 3. The distribution of corneal abnormalities in the enrolled 80 cats with corneal ulcers.

Corneal abnormalities	Number (n)	Percentage (%)	Breed (n)
Deep stromal ulcer with descemetocoele	22	27.5%	Persian (11)
			Domestic shorthaired (9)
			Himalayan (2)
Nonhealing superficial ulcer	16	20 %	Domestic shorthaired (9)
			Persian (5)
			Siamese (2)
Unresponsive endophthalmitis	14	17.5%	Domestic shorthaired (11)
			Persian (2)
			Siamese (1)
Symblepharon	11	13.75%	Domestic shorthaired (6)
			Persian (5)
Anterior synechia with secondary glaucoma	8	10%	Domestic shorthaired (6)
			Himalayan (2)
Old healed ulcer with granulation tissue	5	6.25%	Domestic shorthaired (5)
Corneal sequestration	4	5%	Persian (2)
			Siamese (2)

granulation tissue were noticed over the central and paracentral quadrants of the corneal surface (Figure 2 a and b). The corneal sequestrum appeared as well-defined medium to relatively large sized blackish area (Figure 2c and d) at the central and paracentral cornea and were associated with corneal vascularization. All cats with corneal sequestration had a history of long-term use of ophthalmic corticosteroids before presentation. One of the sequestra cases was a Persian cat showing associated diffuse corneal edema and neovascularization (Figure 3a). Keratitis with corneal ulceration and granulation tissue secondary to *FHV-1* and *Mycoplasma felis* infection showed reddish to pink granulation tissue covering most of the corneal surface (Figure 3b). Unresponsive endophthalmitis secondary to perforated corneal ulcers were associated with corneal melting and large fibrin clot protruding over most of the corneal surface (Figure 4a and b).

Endoscopic findings

Endoscopic evaluation in patients presented with anterior segment abnormalities showed long iris strands arising from the pupil borders adhered to the inner cornea in 8 cats (Figure 5 a & b). One cat with perforated cornea showed immature cataract and anterior synechia (Figure 5c). Endoscopy one month after surgical removal of the iris strands adhering to the inner cornea showed normal shaped pupil with normal optic nerve head (ONH) and clear retinal blood vessels (Figure 5 d).

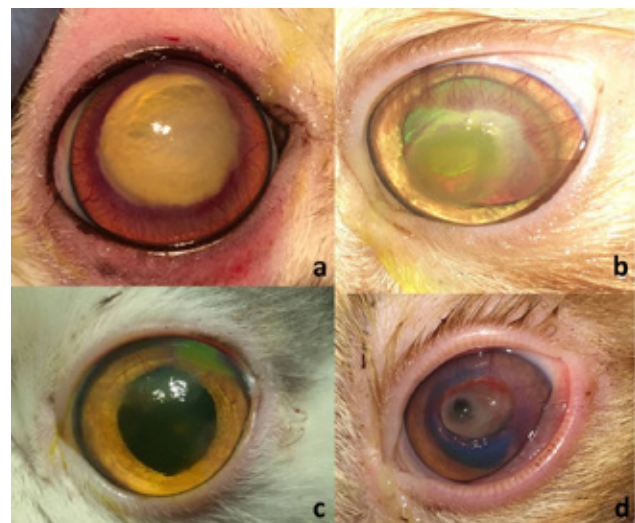


Figure 1. Photograph showing the clinical presentation of the superficial non- healing and deep stromal ulcer. (a) Superficial ulcer with corneal vascularization in a 14-month-old Himalayan cat. (b) Superficial corneal ulcer stained with fluorescein dye in a 2-year-old Persian cat with corneal vascularization; this ulcer was secondary to herpes virus infection. (c) Geographically distributed corneal ulcer in a 6-month-old Persian cat infected with herpes virus. (d) Deep stromal ulcer with descemetocoele and corneal melting in a 4-year-old DSH cat.

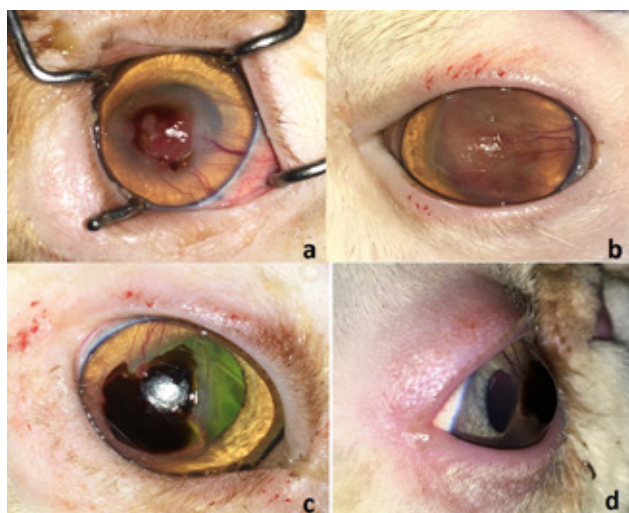


Figure 2. Representative clinical photographs complicated corneal ulcer with over granulation tissue and corneal vascularization in a 12-month-old DSH cat (a) and in a 2-year-old DSH (b). (c) A well-defined large sized corneal sequestrum secondary to FHV-1 infection in a 6-year-old Persian cat. (d) A well-defined medium sized corneal sequestrum secondary to herpes keratitis in a 6-year-old Persian cat.

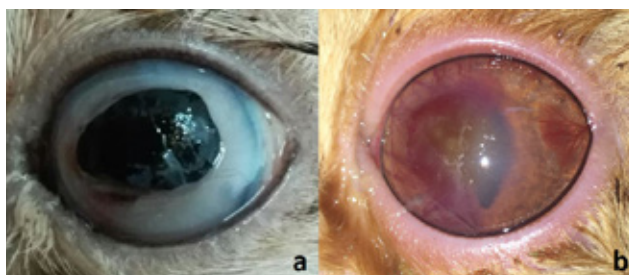


Figure 3. A relatively large sized corneal sequestrum with corneal edema and neovascularization in a 3-year-old Persian cat (a). Corneal ulceration with reddish to pink granulation tissue covering most of the corneal surface and corneal vascularization in a 6-month-old Domestic shorthaired kitten infected with FHV-1 and *Mycoplasma felis* (b).

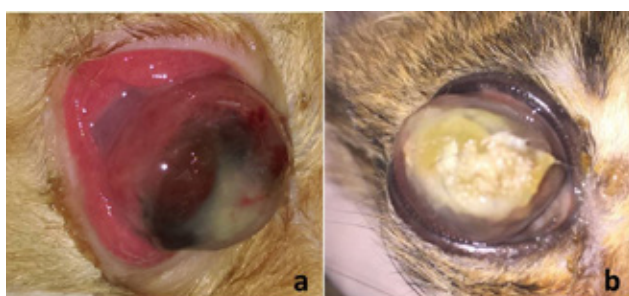


Figure 4. Clinical photograph showing perforated corneal ulcers with unresponsive endophthalmitis and large protruding fibrin clot in 3-year (a), 6-year (b), old DSH cat. FHV-1 was isolated from these 2 cats.

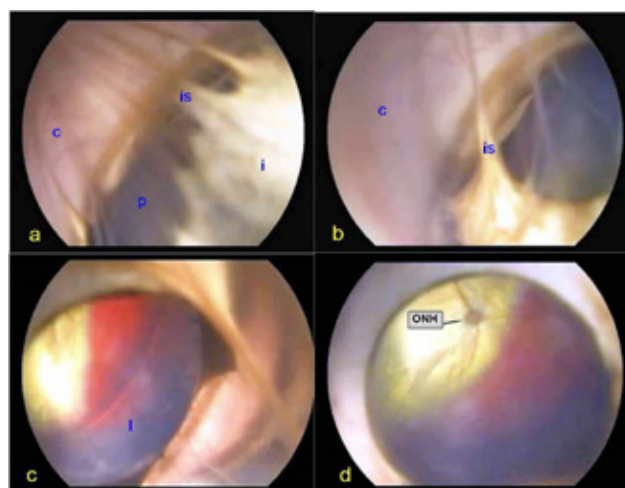


Figure 5. (a and b) Endoscopic images of cats with anterior segment abnormalities illustrating long iris strands "is" arising from the pupil "p" borders and adhering to the inner cornea "c". (c) Endoscopic image of a cat with perforated cornea showing immature cataract "l" and anterior synechia. (d) Normal shaped pupil with normal optic nerve head (ONH) and clear retinal blood vessels

Laboratory findings

FHV-1 was isolated from 57 out of 80 (71.3%) cats, and *Mycoplasma felis* was isolated from 15 out of the 57 (26.3%) cats infected with FHV-1. Cats infected with FHV-1 included 18 (31.6%) with deep stromal ulcer; 12 (21.1%) with superficial ulcer; 9 (15.8%) with symblepharon; 7 (12.2%) with anterior synechiae with secondary glaucoma and corneal scarring; 5 (8.7%) with endophthalmitis with corneal melting; 4 (7%) with corneal perforation; one (1.8%) with corneal sequestration and one (1.8%) with corneal ulceration with granulation tissue. Among the 57 FHV-1 infected cats, there were 36 (63.1%) DSH cats, 19 (33.3%) Persian cats, one (1.8%) Himalayan and one (1.8%) Siamese cat. Among the 15 cats infected with *Mycoplasma felis*, 6 (40%) showed deep stromal ulcer, 4 (26.7%) showed superficial ulcer, 3 (20%) had symblepharon and 2 (13.3%) had endophthalmitis.

Treatment outcomes

Granulation tissue and corneal sequestration were removed successfully from the surface of the cornea (Figure 6 a,b and c). The conjunctival flap was stable and well-fixed throughout the treatment period (Figure 7 a and b). Successful healing of the corneal defect after removal of the corneal sequestrum or granulation tissue was noticed 3 weeks postoperatively (Figure 8a). All reported superficial corneal ulcers were healed successfully 3 weeks postoperatively

with relative elimination of the associated symptoms. Residues of granulation tissue and variable degrees of fibrosis that disappeared completely after 3 months postoperatively were reported in 6 (42.8 %) out of 14 cats with indolent ulcer (Figure 8b and c).

Three out of 4 (75%) cats with corneal sequestration showed successful healing of the corneal defect with variable degrees of corneal fibrosis with associated varying degrees of corneal opacity and vision impairment (Figure 8d). In one Persian cat, with long lasting sequestrum and diffuse corneal edema, the necrotic material was deep and involved all layers of the cornea. Removal of the necrotic material results in corneal perforation, subsequent ocular hypotony and the condition ended up with exenteration. In 22 cats with deep stromal ulcer, lysis of the corneal stroma was minimized, and the corneas were healed successfully 4 weeks post-surgery. However, variable degrees of granulation tissue and corneal fibrosis (Figure 8e) were developed in 16 out of 22 (72.7%) cats with deep stromal ulcer. The adhered conjunctival membrane was removed successfully in 6 out of 11 cats with symblepharon and the corneal lesion was healed with granulation tissue, fibrosis and / or melanosis (Figure 8f).

Cats with anterior synechiae and secondary glaucoma showed complete recovery (Figure 5d) and the intraocular pressure was reduced from 33 to 24 mmHg one week after surgery. Recurrence of anterior synechia was identified via endoscopic examination in one Himalayan cat, one month after surgery with associated corneal scarring.

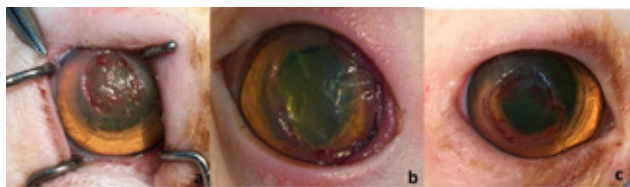

Figure 6. Intraoperative radiograph representing the successful removal of the over granulation tissue from the cat in figure 2a (a) and figure 2b (b) and the corneal sequestrum from the cat in figure 2c (c).

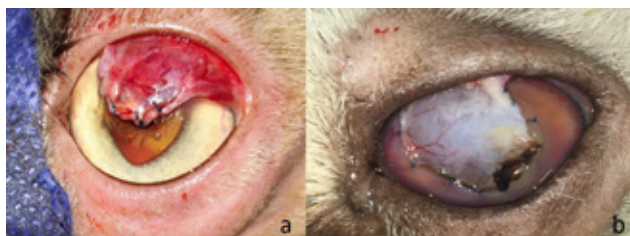


Figure 7 a and b. Photograph representing the conjunctival flaps used in this study

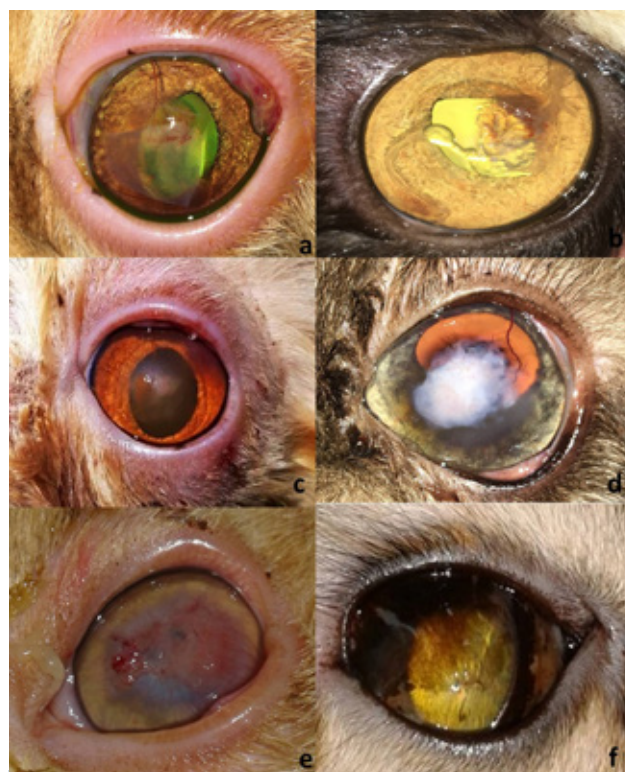

Figure 8. Post-operative radiograph showing the successful healing of the corneal defect after removal of the corneal sequestrum (a) and the healing of indolent ulcer and deep stromal ulcer with residues of granulation tissue (b) and fibrosis (c). (d) Representing severe degree of corneal fibrosis after removal of long lasting corneal sequestrum. (e) adhesion between the conjunctival tissue, granulation tissue and fibrosis was noticed in a cat with deep stromal ulcer after removal of the conjunctival flap. (f) Corneal pigmentation observed in a DSH cat one month after surgical treatment of the symblepharon

DISCUSSION

In the present study, corneal ulcer complications were evidenced in young and adult, male and female cats. The age range (3 months to 6 years) of the cats with complicated corneal ulcer differed from that reported for Boxers (2 to 10 years) (Gelatt and Samuelson, 1982). FHV-1 infection is expected to be the most common initial cause of ocular diseases in young growing cats. Infection with FHV-1 in the neonatal period, prior to eyelid opening, can lead to extensive corneal damage and globe rupture in severe cases (Nasisse et al., 1995). This is relatively in agreement with the study reported here, as there were 9 (15.8%) FHV-1 infected cats with corneal perforation and incurable endophthalmitis with extensive corneal damage. In our study, FHV-1 was isolated from approximately 71.3% of the presented cats with a higher incidence reported in Domestic shorthaired cats (63.1%) followed by Persian cats (33.3%). The high incidence documented in Domestic shorthaired

cats may be attributed to lack of vaccination in these cats. Bilateral corneal abnormalities were reported in approximately 46.3% cats. This relatively high percentage may be due to transmission of the disease to the contralateral eye (Gelatt and Samuelson, 1982), or co-infection with FHV-1.

In the study reported here, cats with deep stromal ulcer showed different degrees of visual impairment according to the size of corneal ulcer (Ali and Hassan, 2020). In previous studies, symblepharon was reported to be a serious complication associated with local herpetic infection (Martin and Stiles, 1998; Slatter, 2001). In these studies, complete blindness was evidenced in FHV-1 infected cats secondary to symblepharon, as 5 out of 11 cats with symblepharon were presented with phthisis bulbi with the eyes not potential for vision and were treated by exenteration (Slatter, 2001). Corneal sequestrum is a serious complication of long-lasting corneal ulcer or after long-term treatment with topical corticosteroids (Nasissse et al., 1995). In the present study, corneal sequestrum was superficial, affecting the anterior third of the corneal stroma, and was easily removed in all cats without complications, except in a Persian cat where the lesion extended to the Descemet's membrane and caused corneal perforation. This case ended up with hypotony and phthisis bulbi.

In the current study, superficial keratectomy and conjunctival flap were convenient treating options in cats with superficial corneal ulcer and deep stromal ulcer. This may be due to the fact that conjunctival flap provides corneal support and fibrovascular tissue to fill corneal defects (Tandon et al., 2010 and Ali and Hassan, 2020)). Additionally, it brings blood supply and blood-associated immune components along with natural anti-collagenase to the lesion (Tandon et al., 2010). In this study, the use of conjunctival flap also allowed proper visualization and monitoring of the rest of the cornea, as well as the surrounding structures of each treated eye. Persistent corneal scars developed in cats with deep stromal ulcer and anterior

synechiae caused varying degrees of visual impairment. This may be attributed to the lack of collagen fibrils produced during repair of the stromal lesion to be laid down in a regular lattice pattern. The previously described ocular endoscopic technique (Abd-Elhamid et al., 2014), was used in the present study to determine anterior chamber abnormalities in cats with corneal edema and corneal neovascularization. Moreover, this technique was useful for monitoring the outcome after surgical removal of the incarcerated iris strands that were adherent to the inner surface of the cornea. A confirmatory diagnostic method for detecting the underlying cause (FHV-1) of complicated corneal ulcers in cats was the use of PCR in this study. Future investigation on larger populations of different animal species with complicated corneal ulceration is still warranted.

In conclusion, the most common complications of corneal ulceration in cats included deep stromal ulcer with descemetocoele, endophthalmitis with corneal involvement, symblepharon, corneal sequestration and anterior synechiae with secondary glaucoma and corneal scarring. FHV-1 is thought to be the initial etiologic factor or incriminated in the pathogenesis of corneal ulceration in cats. Persistent corneal scars of varying shape and size can frequently develop in cats with deep stromal ulcer, anterior synechiae, and corneal sequestration. Domestic shorthaired and Persian cats were the most predisposed breeds to FHV-1 infection and subsequent corneal ulceration. Immediate management of patients with corneal ulcer would prevent serious complications associated with this disease.

CONFLICT OF INTEREST

The authors declare no conflict of interest and no competing financial interest related to this report.

ACKNOWLEDGMENTS

The authors would like to thank the department technicians for their assistance and the cats' owners for their cooperation.

REFERENCES

- Abd-Elhamid MA, Ali KM, and Mostafa AA (2014) Endoscopic evaluation for the anterior and posterior segment of the eye: a new and useful technique for diagnosis of glaucoma in dogs. *Life Sci. J.* 11: 233-237.
- Ali KM and Hassan MH (2020) Visual outcome evaluation of complicated perforating corneal injuries after surgical repair in 45 cats. *Turk J Vet Anim Sci* 44: 894-903
- Barachetti L, Giudice C, Mortellaro CM. (2010) Amniotic membrane transplantation for the treatment of feline corneal sequestrum: pilot study. *Vet. Ophthalmol.* 13:326-330.
- Barros PS, Safatle AM, Godoy CA, Souza MS, Barros LF, and Brooks DE (2005) Amniotic membrane transplantation for the reconstruction of the ocular surface in three cases. *Vet. Ophthalmol.* 8: 189-192.
- Bentley E (2005) Spontaneous chronic corneal epithelial defects in dogs: a review. *J. Am. Anim. Hosp. Assoc.* 41: 158-165.
- Chavkin M, Riis R, and Scherlie P (1990) Management of a persistent corneal erosion in a Boxer dog. *Cornell Vet.* 80: 347-356.
- Douet JY, Michel J, Regnier A. (2013) Degree and duration of corneal anesthesia after topical application of 0.4% oxybuprocaine hydrochloride ophthalmic solution in ophthalmically normal dogs. *Am J Vet Res.* 74:1321-1326
- Featherstone HJ, and Sansom J (2004) Feline corneal sequestra: a review of 64 cases (80 eyes) from 1993 to 2000. *Vet. Ophthalmol.* 7: 213-227.
- Gelatt K, and Samuelson D (1982). Recurrent erosions and epithelial dystrophy in the Boxer dog. *J. Am. Anim. Hosp. Assoc.* 18: 453-460.
- Gelatt KN, Brooks DE (2011) Surgery of the cornea and sclera. In: *Veterinary Ophthalmic Surgery*, 5th edn. (eds. Gelatt KN, Gelatt JP) Elsevier/Saunders, Oxford. 191- 236.
- Goulle F. Use of porcine small intestinal submucosa for corneal reconstruction in dogs and cats: 106 cases (2012). *J. Small Anim. Pract.* 53:34-43.
- Groth A, Contreras M, Kado-Fong H, et al., (2014) In vitro cytotoxicity and antiviral efficacy against feline herpesvirus type 1 of famciclovir and its metabolites. *Vet. Ophthalmol.* 17, pp. 268-274.
- Hankanson NE, and Merideth RE (1987) Conjunctival pedicle grafting in the treatment of corneal ulcers in the dog and cat. *J. Am. Anim. Hosp. Assoc.* 23: 641-648.
- Kirchhoff H (1985) Mollicutes der Hunde und Katzen. In: *Infektionen durch Mycoplasmatales*. (ed. Gylstorff I). Ferdinand Enke Verlag, Stuttgart, pp 425-447.
- Kirschner S, Brazzell R, Stern M, and Baird L (1991) The use of topical epidermal growth factor for treatment of non-healing corneal erosions in dogs. *J. Am. Anim. Hosp. Assoc.* 27: 449-452.
- Laguna F, Leiva M, Costa D, Lacerda R and Gimenez TP (2015) Corneal grafting for the treatment of feline corneal sequestrum: a retrospective study of 18 eyes (13 cats). *Vet Ophthalmol*;18:291-296.
- Maggs D (2008) Cornea and sclera. In: *Slatter's fundamentals of veterinary ophthalmology*. (eds. Maggs D, Miller P, Ofri R). 4th edn. Saunders-Elsevier, St. Louis, Missouri, pp 175-202.
- Martin C, and Stiles J (1998) Ocular infections. In: *Infectious diseases of the dog and cat*. (ed. Greene CE). 2nd edn. Philadelphia: W.B. Saunders Company, pp 659-62.
- Michau TM, Schwabenton B, Davidson MG, and Gilger BC (2003) Superficial, nonhealing corneal ulcers in horses: 23 cases (1989-2003). *Vet. Ophthalmol.* 6: 291-297.
- Mohan RR, Sharma A, Netto MV, Sinha S, and Wilson SE (2005) Gene therapy in the cornea. *Progress in Retinal and Eye Research* 24: 537-559.
- Nasise MP, English RV, Tompkins MB, Guy JS, and Sussman W (1995) Immunologic, histologic, and virologic features of herpesvirus-induced stromal keratitis in cats. *Am. J. Vet. Res.* 56: 51-55.
- Razin S, and Freundt EA (1984) Mycoplasmatales. In: *Bergey's Manual of Systematic Bacteriology*. (eds. Krieg NR, Holt JG). 1st edn. Williams and Wilkins, Baltimore, pp 740-70.
- Sandmeyer LS, Waldner CL, Bauer BS, Wen X, and Bienzle D (2010) Comparison of polymerase chain reaction tests for diagnosis of feline herpesvirus, *Chlamydomydia felis*, and *Mycoplasma* spp. infection in cats with ocular disease in Canada. *Canadian Vet. J.* 6: 629-633.
- Slatter D (2001) In: *Fundamentals of veterinary ophthalmology*. (ed. Kersey R). 3rd ed. Philadelphia: W. B. Saunders Company, pp 213-217 and 283-287.
- Stiles J (2014) Ocular manifestations of feline viral diseases, *The Veterinary Journal*, 201, 2: 166-173.

- Stiles J, and Townsend WM (2007) Feline ophthalmology. In: *Veterinary Ophthalmology*. (ed. Gelatt KN). 4th edn. Ames, IA, Blackwell Publishing, pp 1095-1164.
- Stiles J, McDermott M, Bigsby D, Willis M, Martin C, Roberts W, and Greene C (1997) Use of nested polymerase chain reaction to identify feline herpesvirus in ocular tissue from clinically normal cats and cats with corneal sequestra or conjunctivitis. *Am. J. Vet. Res.* 58: 338-342.
- Tandon A, Tovey JC, Sharma A, Gupta R, and Mohan RR (2010) Role of transforming growth factor Beta in corneal function, biology and pathology. *Curr. Mol. Med.* 10: 565-578.
- Vanore M, Chahory S, Payen G, and Clerc B (2007) Surgical repair of deep melting ulcers with porcine small intestinal submucosa (SIS) graft in dogs and cats. *Vet. Ophthalmol.* 10: 93-99.
- Whitcher JP, Srinivasan M, and Upadhyay MP (2001) Corneal blindness: a global perspective. *Bull World Health Organ* 79: 214-221.
- Wichayacoop T, Briksawan P, Tuntivanich P, and Yibchok-Anun S (2009) Anti-inflammatory effects of topical supernatant from human amniotic membrane cell culture on canine deep corneal ulcer after human amniotic membrane transplantation. *Vet. Ophthalmol.* 12: 28-35.
- Wilkie DA, and Whittaker C (1997) Surgery of the cornea. *Vet. Clin. North Am. Small Anim. Pract.* 27: 1067-1107.