

Journal of the Hellenic Veterinary Medical Society

Vol 75, No 1 (2024)



Biochemical and histological investigation of azathioprine and melatonin in rats

AA Hussein, MH Ahmed, NG Mustafa

doi: [10.12681/jhvms.31190](https://doi.org/10.12681/jhvms.31190)

Copyright © 2024, AA Hussein, MH Ahmed, NG Mustafa



This work is licensed under a [Creative Commons Attribution-NonCommercial 4.0](https://creativecommons.org/licenses/by-nc/4.0/).

To cite this article:

Hussein, A., Ahmed, M., & Mustafa, N. (2024). Biochemical and histological investigation of azathioprine and melatonin in rats. *Journal of the Hellenic Veterinary Medical Society*, 75(1), 6779–6786. <https://doi.org/10.12681/jhvms.31190>

Biochemical and histological investigation of azathioprine and melatonin in rats

A.A. Hussein¹, MarebH. Ahmed², N.G. Mustafa¹

¹Department of physiology, biochemistry and pharmacology. College of Veterinary Medicine / University of Mosul

²Alnoor University College

ABSTRACT: Azathioprine (AZA) is a purine antagonist, also known as Imuran, Azasan and Azamun, is a commonly prescribed immunosuppressive drug that is used in the management of many conditions (cancer, inflammatory bowel diseases, post-transplant immunosuppression, and various autoimmune diseases). However, their therapeutic role has been under debate because of their hepatotoxicity. Monitoring liver function in patients with hepatic impairment who are taking AZA is recommended. Melatonin (MEL) is a hormone usually produced at night by the pineal gland that acts to regulate the day and night cycle. Melatonin in supplements is usually made in a lab and is frequently used for the treatment of insomnia caused by shift work and jet lag. It is a well-known natural antioxidant, improving the hepatic detoxification system. There are numerous studies investigating the effects of MEL on liver injuries. Melatonin could control proliferation, reducing apoptosis, inflammation, and suppressing autophagic cell death in different pathophysiological conditions. The current study was undertaken to determine whether MEL could improve and ameliorate structural and biochemical changes in the liver that were induced by AZA. The 24 male adult rats were grouped as follows: The first group (G1) was given normal saline orally for 4 weeks and was listed as a control, while the second group (G2) was given AZA orally (20 mg/kg B.Wt.) for 4 weeks. MEL (10 mg/kg, B.Wt.) was given to the third group (G3) for four weeks. The fourth group (G4): given AZA (20 mg/kg B.Wt.) and MEL (10 mg/kg B.Wt.) for 4 weeks. Liver sections of the AZA-treated group showed degeneration and necrosis of hepatocytes with increased numbers of kupffer cells. Group 4 showed the normal architecture of liver tissue with increased numbers of kupffer cells. The serum biochemical profiles showed an increase in serum aspartate (AST) and alanine aminotransferase (ALT) enzymes, and a reduction in albumin and total protein in the group treated with AZA, while the liver function tests in the third and fourth groups showed a nonsignificant difference from the control group. We concluded from the results of this study that AZA induces structural and biochemical changes in the liver, and these effects could be improved by the administration of MEL in the last group.

Keywords: Azathioprine; Biochemical; Histological; Liver; Melatonin.

Corresponding Author:

Ahmed Ali Hussein, Department of physiology, biochemistry and pharmacology.
College of Veterinary Medicine / University of Mosul. Mosul / Iraq
E-mail address :ahmvet@uomosul.edu.iq

Date of initial submission: 22-08-2022
Date of acceptance: 02-11-2023

INTRODUCTION

Azathioprine (AZA) is a drug known as Imuran and there are other trade names like Azasan and Azamun. It is synthesized in 1956, and it belongs to a class of medication called immunomodulators, disease-modifying antirheumatic drugs (DMARDs), which are used in inflammatory bowel disease, autoimmune hepatitis, psoriasis, and non-infectious uveitis (Aljumah et al., 2018; Touhami et al., 2019). The Food and Drug Administration (FDA) has approved it for the management of active rheumatoid arthritis and the prevention of kidney transplant rejection (Ladrière, 2013). Azathioprine is a purine synthesis inhibitor, used by oral or intravenous (I.V.) route, absorbed through the gastrointestinal system, converted in the liver and red blood cells to its active metabolites, 6-mercaptopurine (6-MP) and thioguanine (6-TGN), which interfere with RNA, DNA and inhibit protein synthesis, and induce lymphocytic apoptosis (Wee et al., 2011). Although it is a well-known drug that is tolerated, there are numerous adverse effects related to AZA, such as gastrointestinal disturbances, arthralgia, exposure to infections, hypersensitivity, bone marrow suppression, and liver injury. (Hindorf et al., 2006)

The most common liver damage caused by AZA is an increase in the enzymes alanine (ALT) and aspartate aminotransferase (AST), which is usually temporary and returns to normal after stopping or reducing the dose and patients are generally asymptomatic in the majority of cases, however other types of hepatotoxicity can also appear, such as acute cholestatic injury during the first three months after starting the medication and chronic hepatic injury within two years (Björnsson et al., 2017). Less commonly cholestatic hepatitis and exceptionally hepatic cirrhosis have been reported by Roselli et al. (2020) in a patient with Crohn's disease using AZA therapy diagnosed with liver biopsy. There is no known specific therapy for AZA hepatotoxicity.

On the other hand Melatonin (MEL) is a lipid-soluble hormone with multiple actions released from the pineal gland into the blood and cerebrospinal fluid, it regulating the wake-sleep cycle (Auld et al., 2017). FDA has not approved MEL for any medical use, yet it is used mainly in the treatment of insomnia in Australia and in the EU countries, also it is employed to treat other sleeping disturbances in children with autism spectrum disorder (ASD) (Relia and Ekambaram, 2018). Various studies in humans and animals have shown

that the positive effects of melatonin as a medication on several disorders, including cirrhotic patients with sleep disturbance, nonalcoholic fatty liver disorder, and prevention of poison/drug-induced hepato toxicity (Abdi et al., 2021). MEL plays various roles within the human body, it demonstrates antioxidant effects in protecting cells and tissues from radical damage, in hepatic fibrosis, MEL inhibits the production of proinflammatory cytokines (TNF α , IL1 β , and IL6 b). Also, MEL has a regulatory effect on the anti-inflammatory and immunity pathways (Reiter et al., 2016). Decreasing oxidative stress and decreasing hepatocytes death (Esteban et al., 2016). The antioxidant effects of MEL are exerted by both direct and indirect mechanisms (Baydas et al., 2003). MEL stimulates the cellular antioxidant defense system by modulating the activities of antioxidative enzymes (superoxide dismutase, catalase (CAT), and glutathione peroxidase), it acts also as a free radical scavenger, and it regulates mitochondrial function in hepatocytes and the cytolysis process, thus reducing dystrophic necrotic appearances and improving the well-being of cells (Mayo et al., 2002; Ahmad et al., 2012). Moreover, it contributes to the protection of the organism from the development of cancer and neurodegenerative diseases such as Huntington's disease, Parkinson's disease, dementia, Alzheimer's disease and multiple sclerosis (Kostoglou, 2013).

So, the purpose of the present project was to detect the influence of AZA on the liver and the protective action of melatonin opposing AZA induced hepatic damage in rats.

MATERIALS AND METHODS

Drug used

1. The Azathioprine (AZA) drug used in this experiment is from Intas Pharmaceutical Ltd under trade name (Imuran, packaging- 1 \times 10 tablets, Strength 50 mg) Amneal Pharmaceuticals Pvt.Ltd. Ahmedabad 382220, INDIA
2. Melatonin tab. (5mg) used from WN Pharmaceuticals Ltd.

The approval of the study

The agreement of the study procedure by an ethics committee has been attained from the local health committee of Medical College, University of Mosul, Iraq. with certified No. UOM/COM/MREC/2020(2).

Animals and treatments

All the twenty-four rats used were male adults of

the same age group (2.5-3) months, weighing (200 ± 25) gm housed in the animal house of the Faculty of Veterinary Medicine, Mosul University. They were housed in clean wire net cages 12*20*10 cm in a quiet room, with 6 rats in each cage with temperature-controlled at 25±2°C, 12-hour light - dark cycle, and had free access to water, and food ad libitum. Animals were left for at least one week to accommodate the environment of the lab before starting the experiments.

The 24 treated rats were grouped into the following groups. The first group (G1) was orally administered normal saline and was considered the control group. While in the second group (G2) Aza was given in a dose (20 mg/kg body weight) The third group (G3): given MEL (10 mg/kg body weight). Group 4: given: AZA (20 mg/kg body weight) + MEL (10 mg/kg body weight). All treatments given orally for 4 weeks by Crush the pill and then dissolve in distilled water, given by oral gavage needles.

Laboratory tests: all groups samples of blood were taken on day 15 and 30, and after 12 hours of fasting, blood samples about 3 millimeter were collected from the retro-ocular vein of the eye and their serum was separated for biochemical analyses for liver function tests, the levels of ALT and AST activities, Total protein and albumin concentration in serum were estimated by smart biochemistry analyzer, USA using giesse diagnostics kits (Italy). The isolated serum was preserved at -20° C until the biochemical tests will be done.

After 30 day the number of animals killed is 6 rats in each group, Liver samples were dissected and fixed in 10% neutral buffered formalin for 24 hours, tissues were washed in tap water, dehydrated in increasing concentrations of ethyl alcohol, cleared in xylene, finally placed in paraffin wax at 60 C° and molded into paraffin blocks. They are then sectioned (5 micrometers) using (Rotary microtome (Hestion ERM 4000, Germany). Slides were stained with Hematoxylin and Eosin and examined un-

der light microscopy, and pictures were taken using the color USB 2.0 digital image camera (OmaxToupView 9.0-Megapixel China), which was provided with image processing software. The camera software was calibrated for all microscope lenses -Olympus-CX31 using stage micrometer (0.01mm) (ESM-11 / Japan).

Statistical analysis:

All data are expressed as the mean ± SD. Comparisons between groups were made using One -Way Analysis of Variance (ANOVA) followed by a test of least significant difference (LSD) test. The differences were accepted as statistically significant when $p < 0.05$. All analyzes were performed with the statistical package of software SPSS 20.

RESULTS

Serum Biomarkers:

The liver function markers in the serum of rats were investigated at day 15 as shown in table 1 and days 30 at the end of the experiment in table 2 illustrated that in the AZA group in 15 days the level of AST and ALT were both increased significantly ($P < 0.02$) and ($P < 0.038$) respectively in comparison with the first group, while in the MEL group there was a non significant difference according to the control, but in 15, 30 days there was a significant reduction in the AST and ALT levels in AZA and MEL group (G4) compared with the AZA treated group ($P < 0.021$) and ($P < 0.019$) respectively. Also, in 15 days there is a decrease in protein level ($P < 0.065$) and in 30 days there is a decrease significantly in total protein level ($P < 0.038$) in group 2 compared with the first group, the albumin level decreased significantly on day 15 ($P < 0.036$) compared to the control group, while in the melatonin group there was no significant difference from the control group, but in 15,30 days there was a significant increase in AZA and MEL group compared to group 2 ($P < 0.036$) and ($P < 0.027$) respectively.

Table (1): Liver function tests in day 15.

Parameters Group	AST (U/l)	ALT (U/l)	Total Protein (g/dl)	Albumin (g/dl)
Control/G1	106.25 ± 0.750	45.00 ± 0.912	6.975 ± 0.0478	4.22 ± 0.0470
AZA /G2	119.50 ± 0.645 *	47.75 ± 0.478 *	6.825 ± 0.0487	4.05 ± 0.0288 *
MEL /G3	109.75 ± 0.478 * ^a	46.50 ± 1.190	6.875 ± 0.0485	4.22±0.0487 ^a
AZA + MEL /G4	107.25 ± 0.853 ^{a,b}	45.50 ± 0.288	6.90 ± 0.0408	4.30 ± 0.0707 ^a

The values are shown as a mean ± SD for 4 rats in each group and difference of ($p < 0.05$) is significant.

Different letters mean significant differences within each column parameters.

* Differ significantly in relative to the control rats group $p < 0.05$.

a Differ significantly in relative to the azathioprine (AZA) rats group $p < 0.05$.

b Differ significantly in relative to the melatonin (MEL) rats group $p < 0.05$.

Table (2): Liver function tests in day 30.

Group	Parameters	AST (U/l)	ALT (U/l)	Total Protein (g/dl)	Albumin (g/dl)
Control/G1		106.5 ± 1.190	45.0 ± 1.5811	7.10 ± 0.0912	4.22 ± 0.085
AZA /G2		122.00 ± 1.08 *	52.75 ± 1.1086 *	6.825 ± 0.0478 *	4.07 ± 0.047
MEL /G3		114.0 ± 1.08 ^{*,a}	49.0 ± 0.9128 ^{*,a}	6.97 ± 0.0478	4.20 ± 0.057
AZA + MEL /G4		109.5 ± 0.645 ^{a,b}	40.0 ± 0.4082 ^{*,a,b}	6.88 ± 0.0212 *	4.32 ± 0.047 ^a

The values are shown as a mean ± SD for 4 rats in each group and difference of ($p \leq 0.05$) is significant.

Different letters mean significant differences within each column parameters.

* Differ significantly in relative to the control rats group $p \leq 0.05$.

a Differ significantly in relative to the azathioprine (AZA) rats group $p \leq 0.05$.

b Differ significantly in relative to the melatonin (MEL) rats group $p \leq 0.05$.

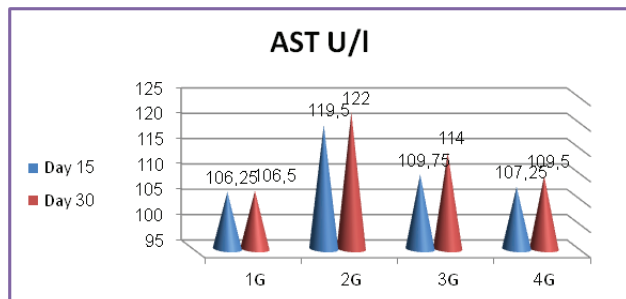


Fig.1: Serum aspartate aminotransferase (AST), G1= control, G2 = Azathioprine, G3 = Melatonin and G4 = Azathioprine + Melatonin groups .

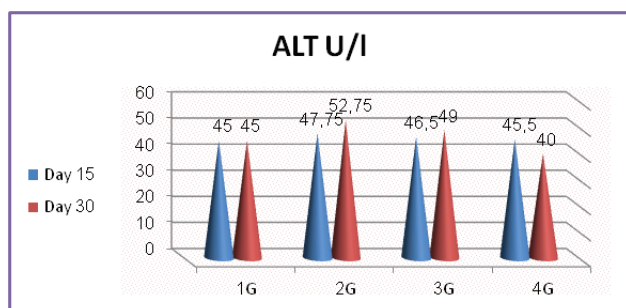


Fig.2: Serum alanine aminotransferase (ALT), G1= control, G2 = Azathioprine, G3 = Melatonin and G4 = Azathioprine + Melatonin groups.

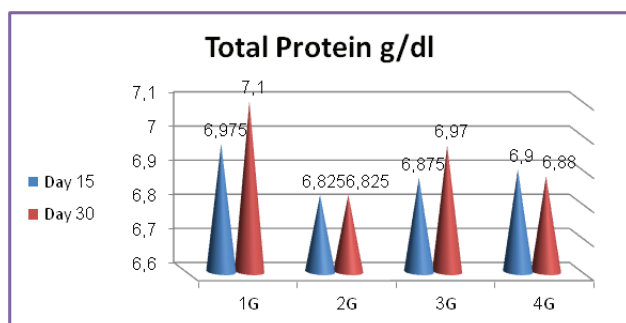


Fig.3: Serum total protein, G1= control, G2 = Azathioprine, G3 = Melatonin and G4 = Azathioprine + Melatonin groups .

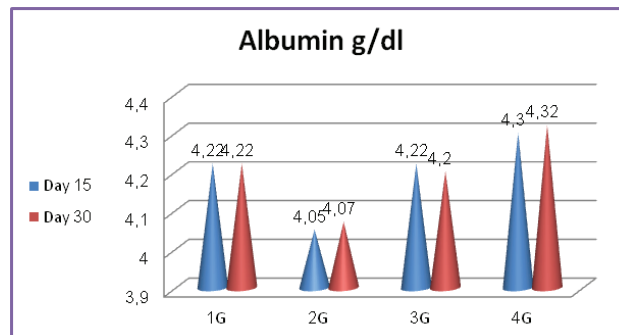


Fig.4: Serum Albumin, G1= control, G2 = Azathioprine, G3 = Melatonin and G4 = Azathioprine + Melatonin groups .

Histological changes

Group G1

All the animals in the control group remained alive and stayed active during the experiment. They had a good appetite, responded very rapidly to stimulants. The liver was congested and brown with firm consistency and a smooth surface. The liver sections from this group showing the lobular architecture of the liver were preserved, healthy hepatocytes, the sinusoids, and bile ductile looked normal (**Fig.5**).

Group G2

Liver of G2 shows hypertrophy of hepatocytes around the central vein, necrosis of some hepatocytes and increase in the kupffer cells (**Fig.6 and 7**).

Group G3

The liver appeared brownish, soft and lobulated with normal portal hepatic; the central vein is surrounded by normal hepatocytes, mild congestion of the portal vein and the sinusoids; and an increase in the number of Kupffer cells(**Fig.8 and 9**).

Group G4

Shows normal lobular architecture of liver tissue characterized by central vein, mild swelling and hydropic degeneration of hepatocytes and congestion of blood vessels (**Fig.10, and 11**).

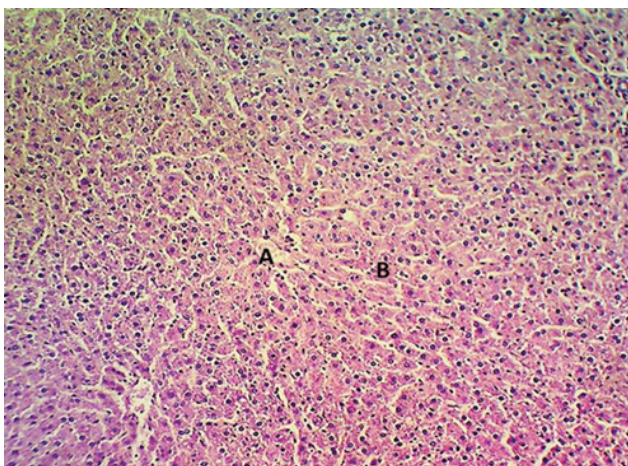


Fig.5: Liver photomicrograph of the control group showing the normal architecture of the hepatic tissue illustrated by the central vein (A), hepatocytes (B) H&E stain, 100X.

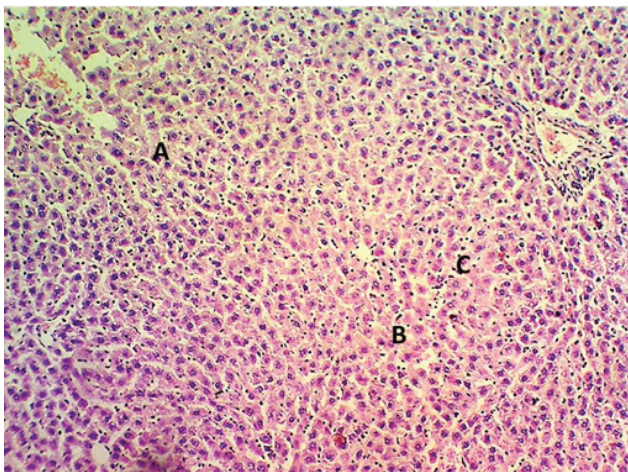


Fig.6: Liver photomicrograph of the AZA treated group 2 shows hyperatrophy of hepatocytes (A), necrosis of some hepatocytes (B) and increase in the kupffer cells (C). H&E stain, 100X.

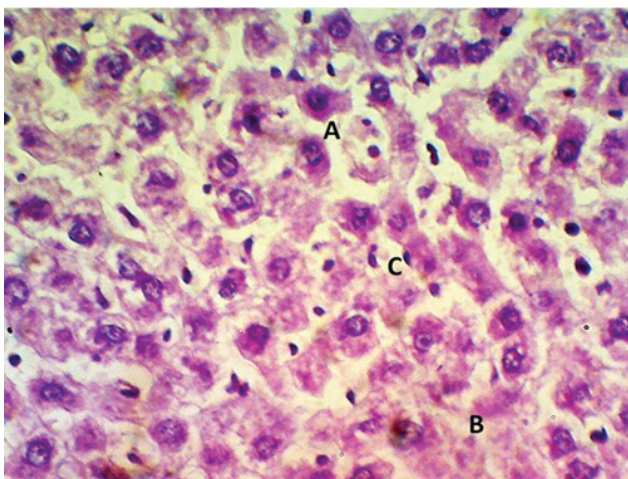


Fig.7: Photomicrograph of liver of AZA treated group 2 shows hyperatrophy of hepatocytes (A), necrosis of some hepatocytes (B) and increase in the kupffer cells (C). H&E stain, 400X

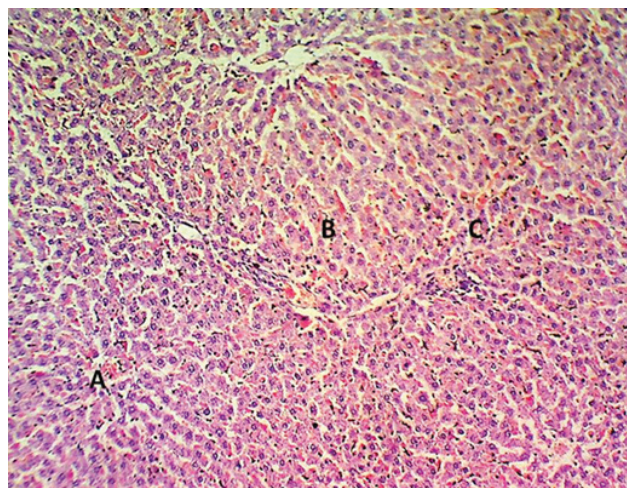


Fig.8: Liver photomicrograph of MEL group 3, illustrating the normal architecture of hepatic tissue with congestion of the central vein (A) and sinusoids (B) and an increase in the kupffer cell number (C), H&E stain, 100X.

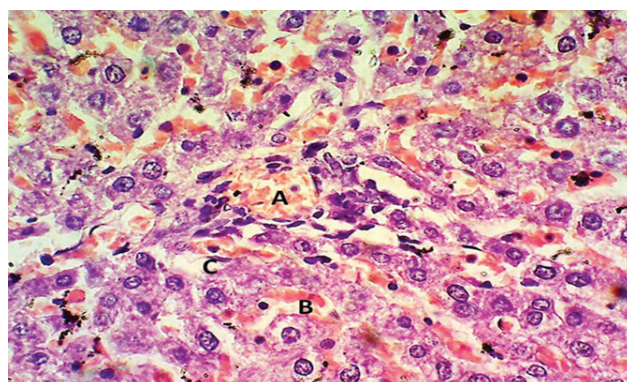


Fig.9: Liver photomicrograph of MEL group illustrating the normal architecture of hepatic tissue with congestion of the portal vein (A) and sinusoids (B) and an increase in the kupffer cell number (C), H&E stain, 100X.

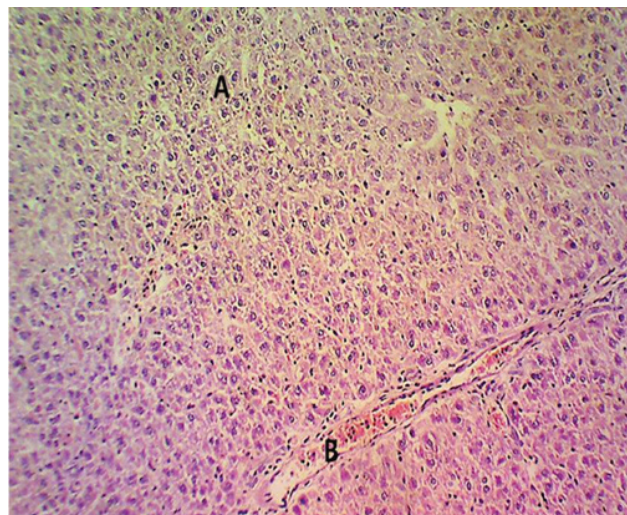


Fig.10: Liver photomicrograph of AZA drug with MEL treated group showing mild hydropic degeneration of hepatocytes (A), and congestion of blood vessels (B) H&E stain, 100X.

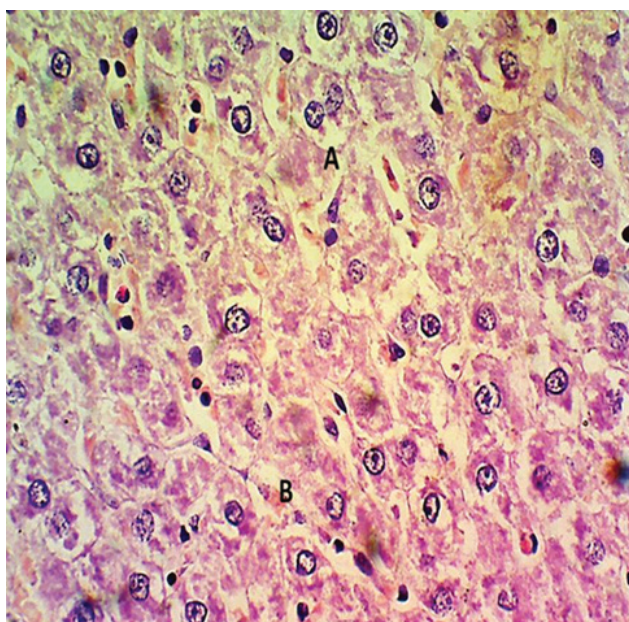


Fig.11: Liver photomicrograph of AZA drug with melatonin treated group showing mild swelling of hepatocytes (A), and congestion of sinusoids (B) H&E stain, 400X.

DISCUSSION

In the present study, we evaluated the possible protecting effect of MEL in attenuating hepatic cytotoxicity induced by AZA. Azathioprine is categorized as a chemotherapeutic, immunomodulatory drug which is used commonly in the management of autoimmune diseases, cancer, inflammatory bowel disorders, and organ transplant patients (Reggio et al., 2019).

Liver microanatomy in group 2 showed harmful effects of AZA on hepatic tissue including hypertrophy and degeneration of hepatocytes, increase in the Kupffer cells, that is corresponding to another study in albino mice (Ali, 2018). The mechanism of liver damage due to AZA is not yet fully understood, it could be due to hypersensitivity reactions, endothelial cell injury, cholestatic reactions or formation of pro-inflammatory mediators and elucidation of oxidative stress (Gisbert et al., 2007). Besides hepatic structural changes in Group 2, there was impairment in the liver function test. ALT and AST levels in serum were increased in the second week (table 1) and increased more at the end of the experiment (table 2), they can be due to liver injury (Oleshchuk et al., 2019). Ordinarily these enzymes are formed in the hepatocytes and then pass into the blood stream. and their level of elevation due to the injured hepatocytes. Similar to our observation, the levels of ALT and AST are increased with other chemotherapeutic drugs such as cisplatin, which consider water-soluble inorganic substance

has been shown to cause hepatocytes degeneration, liver damage, oxidative stress and increase inflammatory cytokines (Kaymak et al., 2022). Also, there was a drop in the serum albumin and total protein in the AZA group, indicating a decrease in the synthesis by the damaged liver.

In the AZA group the histological changes in the liver tissues and the disturbance in their function may be due to increased oxidative stress of cells and a reduction in the antioxidant agents. Therefore, it is important to give a hepatoprotective substance, preferably an antioxidant, before using an AZA drug (Esteban et al., 2016). In group 3, MEL given orally for 4 weeks revealed almost normal liver histology and the laboratory assay was more or less similar to that of control. MEL was found to have hepatoprotective effects, and the levels of liver enzymes decreased and more or less are similar to group 1.

In group 4, MEL co-treatment to the AZA returns in the level of ALT, AST, and restored protein levels as well as albumin. Also, the morphological damage in the liver was lowered and less affected than those in group 2 and the tissues appeared more or less like those of controls; this could be attributed to the antioxidant role of MEL. In group 4 albumin significantly increased is consistent with previous studies (Montasser et al., 2017). Albumin is a water-soluble protein produced in the liver and transported to the blood stream. It is an important marker in acute and chronic liver diseases (Spinella et al., 2016). Furthermore, a significant decrease in inflammation, and liver enzymes (ALT & AST) associated with a significant improvement of the albumin level in animals treated with MEL after cytotoxic drugs like cisplatin was reported (Kaymak et al., 2022). The improvement in the liver function test in group 4 indicates that MEL repairs liver damage and restores hepatocytes functions which is in accordance with other studies by Sayan et al (Sayan et al., 2020).

MEL reduced liver injury, hepatocyte death, and enzymes probably through regulation of apoptosis, proliferation, and autophagy, inhibiting cytokine production, improving oxidative stress, and reducing the activity of tumor necrosis factor α (TNF α) (Zhang et al., 2017). Another explanation by Oleshchuk et al. (2019), is that MEL decreases the concentration of inducible Nitric oxide synthases (iNOS), blocks the NO-NOS systems, and leads to the reduction of nitro oxidative stress in rats with CCL4-induced hepatitis. So, AZA should be used with caution in people with

liver problems and MEL could be a new treatment that could safely and effectively block and treat liver injuries caused by AZA.

CONCLUSION

Our study has demonstrated the effect of Azathioprine in rats and the restoration of morpho-functional state of the liver after the administration of melatonin. Subsequently, clinicians should be aware that regular monitoring of liver function tests in patients using AZA regimen, and it is essential to give a hepatoprotective agent. Melatonin may be a promising agent

that offers protection from AZA injury in the liver and prevents the disturbance in the liver function tests.

ACKNOWLEDGMENT

We would like to thank the University of Mosul for financial support and facilities that provided for the completion this article.

CONFLICT OF INTERESTS

All the authors declared they have no conflict of interest.

REFERENCES

- Abdi S, Abbasiazari M, Ataei S, Khanzadeh-Moghaddam N, Keshvari N. (2021). Benefits and Risks of Melatonin in Hepatic and Pancreatic Disorders; A Review of Clinical Evidences. *Iran J Pharm Res.* 20(3):102-109. doi: 10.22037/ijpr.2020.114477.14872.
- Ahmad R, Gupta S, Haldar C. (2012). Age dependent expression of melatonin membrane receptor (MT1, MT2) and its role in regulation of nitro sative stress in tropical rodent *Funambulus pennanti*. *Free Radic Res.* 46(2):194-203. doi: 10.3109/10715762.2011.647690.
- Ali DKH.(2018). Histopathological effect of azathioprine on liver, intestine and spleen of albino. *Pakistan Journal of Biotechnology.* 25;15(3):621-5.
- Aljumah AA, Al Jarallah B, Albenmoussa A, Al Khatlhan A, Al Zanbagi A, Al Quaiz M, Al-Judaibi B, Nabrawi K, Al Hamoudi W, Alghamdi M, Fallatah H. (2018). The Saudi association for the study of liver diseases and transplantation clinical practice guidelines for management of autoimmune hepatitis. *Saudi J Gastroenterol.* 24(7):1-20. doi: 10.4103/sjg.SJG_159_18.
- Auld F, Maschauer EL, Morrison I, Skene DJ, Riha RL.(2017). Evidence for the efficacy of melatonin in the treatment of primary adult sleep disorders. *Sleep Medicine Reviews.* 1;34:10-22. doi: 10.1016/j.smrv.2016.06.005.
- Baydas G, Kutlu S, Naziroglu M, Canpolat S, Sandal S, Ozcan M, Kelestimur H. (2003). Inhibitory effects of melatonin on neural lipid peroxidation induced by intracerebroventricularly administered homocysteine. *J Pineal Res.* 34(1): 36-39. doi: 10.1034/j.1600-079x.2003.02939.x.
- Björnsson ES, Gu J, Kleiner DE, Chalasani N, Hayashi PH and Hoofnagle JH.(2017). "Azathioprine and 6-mercaptopurine-induced liver injury," *Journal of Clinical Gastroenterology*, 51, (1):63-69, doi: 10.1097/MCG.0000000000000568.
- Esteban-Zubero E, Alatorre-Jiménez MA, López-Pingarrón L, Reyes-Gonzales MC, Almeida-Souza P, Cantín-Golet A, et al. (2016). Melatonin's role in preventing toxin-related and sepsis-mediated hepatic damage: A review. *Pharmacol Res.*105:108-20. doi: 10.1016/j.phrs.2016.01.018.
- Gisbert JP, González-Lama Y, Maté J. (2007). Thiopurine-induced liver injury in patients with inflammatory bowel disease: a systematic review. *Am J Gastroenterol.* 102(7):1518-27. doi: 10.1111/j.1572-0241.2007.01187.x.
- Hindorf U, Lindqvist M, Hildebrand H, Fagerberg U, Almer S.(2006). Adverse events leading to modification of therapy in a large cohort of patients with inflammatory bowel disease. *Aliment Pharmacol Ther.* 15;24(2):331-42. doi: 10.1111/j.1365-2036.2006.02977.x.
- Kaymak E, Ünsal M, Akın A, Öztürk E, Ceylan T, Kuloğlu N, et al.(2022). "Protective effect of melatonin on cisplatin-induced liver injury in rats". *Cukurova Medical Journal.*47:250-258 <https://dergi-park.org.tr/en/pub/cumj/issue/68810/1029473>.
- Kostoglou-Athanassiou I. (2013). Therapeutic applications of melatonin. *TherAdvEndocrinolMetab.* 4(1):13-24. doi: 10.1177/2042018813476084.
- Ladrière M. (2013). [Current indications of azathioprine in nephrology]. *Nephrol Ther.* 9(1):8-12. doi: 10.1016/j.nephro.2012.08.002.
- Mayo JC, Sainz RM, Antoli I, Herrera F, Martin V, Rodriguez C. (2002). Melatonin regulation of antioxidant enzyme gene expression. *Cell Mol Life Sci.* 59: 1706-1713. doi: 10.1007/pl00012498.
- Montasser AOS, Saleh H, Ahmed-Farid OA, Saad A, Marie MS. (2017). Protective effects of *Balanites aegyptiaca* extract, Melatonin and Ursodeoxycholic acid against hepatotoxicity induced by Methotrexate in male rats. *Asian Pac J Trop Med.* 10:557-65. doi: 10.1016/j.apjtm.2017.06.003.
- Oleshchuk O, Ivankiv Y, Falfushynska H, Mudra A, Lisnychuk N. (2019). Hepatoprotective Effect of Melatonin in Toxic Liver Injury in Rats. *Medicina (Kaunas).* 24;55(6):304. doi: 10.3390/medicina55060304.
- Reggio A, Spada F, Rosina M, Massacci G, Zuccotti A, Fuoco C, et al.(2019). The immunosuppressant drug azathioprine restrains adipogenesis of muscle Fibro/Adipogenic Progenitors from dystrophic mice by affecting AKT signaling. *Sci Rep.* 13;9(1):4360. doi: 10.1038/s41598-019-39538-y.
- Reiter RJ, Mayo JC, Tan DX, Sainz RM, Alatorre-Jimenez M, Qin L.(2016). Melatonin as an antioxidant: under promises but over delivers. *J Pineal Res.* 61:253- 78. doi: 10.1111/jpi.12360.
- Relia S, Ekambaram V.(2018). Pharmacological Approach to Sleep Disturbances in Autism Spectrum Disorders with Psychiatric Comorbidities: A Literature Review. *Med Sci (Basel).* 25;6(4):95. doi: 10.3390/medsci6040095.
- Roselli J, Innocenti T, Lynch EN, Parisio L, Macri G, Milla M, et al.(2020). Increased Risk of Liver Cirrhosis during Azathioprine Therapy for Crohn's Disease. *Case Rep Gastrointest Med.* doi: 10.1155/2020/6726384
- Sayan M, Karabulut D, Ozdamar S. (2020). Assessment of the protective and therapeutic effect of melatonin against thioacetamide-induced acute liver damage. *J BiochemMolToxicol.* 34: e22450. doi: 10.1002/jbt.22450.
- Spinella R, Sawhney R, Jalan R. (2016). Albumin in chronic liver disease:

- structure, functions and therapeutic implications. *HepatoInt*. 10:124-32. doi: 10.1007/s12072-015-9665-6.
- Touhami S, Diwo E, Sève P, Trad S, Bielefeld P, SèneD, et al. (2019). Expert opinion on the use of biological therapy in non-infectious uveitis. *Expert Opin Biol Ther*, 19(5):477-90. doi: 10.1080/14712598.2019.1595578.
- Wee JS, Marinaki A, Smith CH. (2011). Life threatening myelotoxicity secondary to azathioprine in a patient with atopic eczema and normal thiopurinomethyltransferase activity. *BMJ*. 25;342:d1417. doi: 10.1136/bmj.d1417.
- Zhang JJ, Meng X, Li Y, Zhou Y, Xu DP, Li S, Li HB. (2017). Effects of Melatonin on Liver Injuries and Diseases. *Int J Mol Sci*. 18(4):673. Published. doi:10.3390/ijms18040673.