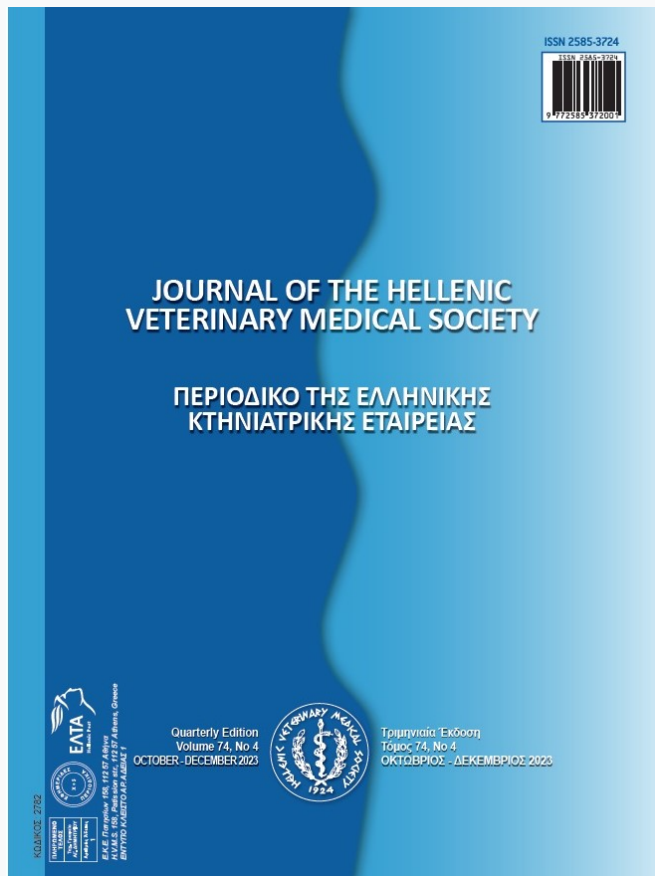

Journal of the Hellenic Veterinary Medical Society

Vol 75, No 1 (2024)



Photometric and Radiometric hoof capsule evaluation in normal and long toe underrun heel in donkey

Al El-Marakby , Al Abdelgalil, AA Metwally, MB Mostafa, AS Soliman

doi: [10.12681/jhvms.32349](https://doi.org/10.12681/jhvms.32349)

Copyright © 2024, Al El-Marakby , Al Abdelgalil, AA Metwally, MB Mostafa, AS Soliman



This work is licensed under a [Creative Commons Attribution-NonCommercial 4.0](https://creativecommons.org/licenses/by-nc/4.0/).

To cite this article:

El-Marakby , A., Abdelgalil, A., Metwally, A., Mostafa, M., & Soliman, A. (2024). Photometric and Radiometric hoof capsule evaluation in normal and long toe underrun heel in donkey. *Journal of the Hellenic Veterinary Medical Society*, 75(1). <https://doi.org/10.12681/jhvms.32349>

Photometric and Radiometric hoof capsule evaluation in normal and long toe-underrun heel in donkeys

A.I. El-Marakby¹, A.I. Abdelgalil¹ *, A.A. Metwally², MBMostafa ¹, A.S. Soliman¹

¹Department of Surgery, Anesthesiology and Radiology, Faculty of Veterinary Medicine, Cairo University, Egypt

²Department of Veterinary Surgery, Anesthesiology and Radiology, Faculty of Veterinary Medicine, Aswan University, Egypt

ABSTRACT: There is limited information documenting the normal and long toe-underrun heels in donkeys. The objectives of the study were to describe the photometric and radiometric parameters of long toe-underrun heel in comparison with normal healthy donkeys in Egypt. Lateral photographs and lateromedial and dorso-palmar radiographs of the forefeet were obtained for both normal and long toe groups. Angular and linear parameters variables were compared between long toe and normal donkeys' hooves. Morphologically, the toe and heel angles were significantly decreased in long toe-underrun heel. The difference between toe and heel angles was higher in normal healthy hooves and decreased in long toe-underrun heel. The hoof pastern axis was significantly increased while the hoof base of support showed significant decrease in long toe-underrun heel hooves. Radiographically, long toe-underrun heels showed significant decrease in the distal phalanx angle, the axis of the distal phalanx angle, the proximal palmar cortex angle and the distal phalanx solar border angle had a negative value. There were no significant variations in the distal phalanx to ground distance, distal phalanx to frog distance, dorsal coronary band height, palmar coronary band height, and heel height index. However, the determined values were consistently less than the healthy hooves. The foot length showed significant decrease and the hoof balance % was significantly increased in long toe hooves. Dorsopalmar radiographic parameters of the medial wall length, lateral wall length, lateral coronet to bottom distance, and medial coronet to bottom distance showed no significant difference between normal and long toe-underrun heel. The distal phalanx to lateral hoof wall distance had a significant decrease in long toe hooves. This study may help the veterinarians and farriers to take the correct decision for corrective trimming of long toe-underrun heel hooves in donkeys.

Keywords: Hoof; donkey; radiology; long toe; normal.

Corresponding Author:
Ahmed Ismael Abdelgalil, Department of Surgery, Anesthesiology and Radiology,
Faculty of Veterinary Medicine, Cairo University.P.O.Box: 12211 Giza.
E-mail address: ismael7591@cu.edu.eg

Date of initial submission: 12-12-2022
Date of acceptance: 21-05-2023

INTRODUCTION

Donkeys are considered one of the important working animals in agricultural and tourism activities (Mostafa et al., 2020; Salem et al., 2018; Thiemann and Poore, 2019). Foot disorders represented one of the most prevalent conditions in aged donkeys (44.8%) in a post-mortem study conducted in UK (Morrow et al., 2011). Hoof problems represented up to 65% of the musculoskeletal disorders reported in donkeys (Mendoza et al., 2018; Thiemann and Poore, 2019). The most common hoof conditions were overlong hooves, unbalanced feet, solar abscesses, white line disease, laminitis, keratomas, and third phalanx fractures (Reix et al., 2014; Thiemann and Rickards, 2013; Thiemann and Poore, 2019). Low heel conformational disorder was represented 77% of horses with hoof related lameness and 52% of thoroughbred race horses (O'Grady, 2020).

A low or underrun heel conformation is considered when the heel angles are being considerably less than the dorsal hoof wall angle (O'Grady, 2020). Low heel conformation in the horse contributes to palmar foot pain, compromised circulation in the palmar aspect of the foot, chronic heel bruising and increased strain on the DDFT (Turner, 2003). A negative solar border angle of the distal phalanx indicated the decrease in the palmar soft tissue mass and the tissue damage from stress and overloading (Castelijns, 2012; Eliashar et al., 2004). Biomechanically, the changes in the angle of insertion of the DDFT on the distal phalanx were found to increase the peak force on the navicular bone and navicular bursa (Eliashar et al., 2004).

Since the donkeys' hooves are anatomically different from horses' hooves, the horse radiographic parameters cannot be used in donkeys (Thiemann and Poore, 2019). The radiographic parameters of normal donkey feet were investigated to provide univocal radiographic parameters (Collins et al., 2011; El-Shaafaey et al., 2017; Mostafa et al., 2020; Nocera et al., 2020a and b). To the authors' knowledge, the photometric and radiometric feet parameters in long toe under-run heel have not been investigated yet. Therefore, the aim of the present study was to establish the radiometric and morphometric parameters in the normal and long toe under-run heel hooves in donkeys.

MATERIALS AND METHODS

This study was carried out on 30 front cadaveric donkeys' hooves (12 normal and 18 long toe under-run heels) collected from the veterinary teaching

hospital, faculty of veterinary medicine, Cairo University. This study was approved by the institutional animal care and use committee at Cairo University (CU/II/F/32/20).

Visual examination of the hooves was performed from all aspects (O'Grady, 2013). The feet were lightly trimmed before photographic and radiographic evaluations. Digital photography of the hooves was taken by the digital camera (KODAK, 8.2 megapixels. China), which was placed at a standardized distance (50cm) from the front feet (White et al., 2008). Lateromedial (LM) and dorso-palmar (DP) radiographic views were taken (Butler et al., 2017). Two metallic wires were placed along the dorsal hoof wall and the heel in LM views, while they were placed along the medial and lateral walls in DP views. A small metallic ball was placed just dorsal to the apex of the frog in both views. The X-ray beam was perpendicular to the X-ray cassette and parallel to the ground. The beam was focused 1 cm below the coronary band for both LM and DP views (Collins et al., 2011). Exposure factors were 50Kv and 10 mA/s for LM views and 54Kv and 10 mA/s for DP views. Photographic and radiographic images were analyzed using software (AutoCAD 2019), and all Photographic and radiographic parameters were measured 5 times by the same person to control the repeatability effects.

A total of 35 parameters were measured in both normal and long toe underrun heel feet (8 photometric and 27 linear and angular radiometric parameters). The radiometric parameters included 17 radiometric parameters obtained from the LM views and 10 parameters from DP views (Mostafa et al., 2020; Nocera et al., 2020a and b).

The measured photographic hoof capsule parameters included toe angle (TA), heel angle (HA), coronary band angle (CBA), hoof pastern axis (HPA), toe length (TL), heel length (HL), hoof base of support (HBS) and the difference between toe and heel angles (TA-HA) (Figure.1).

Latero-medial radiographic parameters included dorsal hoof wall angle (DHWA), heel angle (HA), distal phalanx angle (P3A), distal phalanx solar border angle (P3BA), coronary angle (CA), axis of distal phalanx angle (LP3A), proximal palmar cortex angle (PPCA), heel collapse index (HCI), dorsal hoof wall length (DHWL), distal phalanx to ground distance (P3G), distal phalanx to frog distance (P3F), distal phalanx to toe distance (P3T), foot length (FL),

hoof balance % (HB%), dorsal coronary band height (DCBH), palmar coronary band height (PCBH), and heel height index (HI) (Figure. 2).

Dorso-palmar (DP) radiographic parameters included medial wall angle (MWA), lateral wall angle (LWA), medial wall length (MWL), lateral wall length (LWL), lateral coronet to bottom Distance (LCBD), medial coronet to bottom Distance (MCBD), lateral distal phalanx to bottom distance (P3BL), medial distal phalanx to bottom distance (P3BM), distal phalanx to lateral hoof wall distance (P3HL), and distal phalanx to medial hoof wall distance (P3HM) (Figure. 3).

Statistical analysis

Descriptive statistics (Mean \pm SD) for normal

and long toe-under run heel hooves were estimated. Kolmogorov-Smirnov (K-S) test was used to evaluate the normal distribution of the data. The differences in the Mean \pm SD between normal and long toe under-run heel hooves were evaluated with the independent sample t-test. Statistical analysis was done by the SPSS software program. Data were considered significant when P-value <0.05 .

RESULTS

Long toe underrun heel conformation in donkeys characterized morphologically by horizontal elongation and concavity of the dorsal hoof wall, broken back HPA, increase in the frog length (Figure 4 a&b) and in severe cases, the apex of the frog was recessed

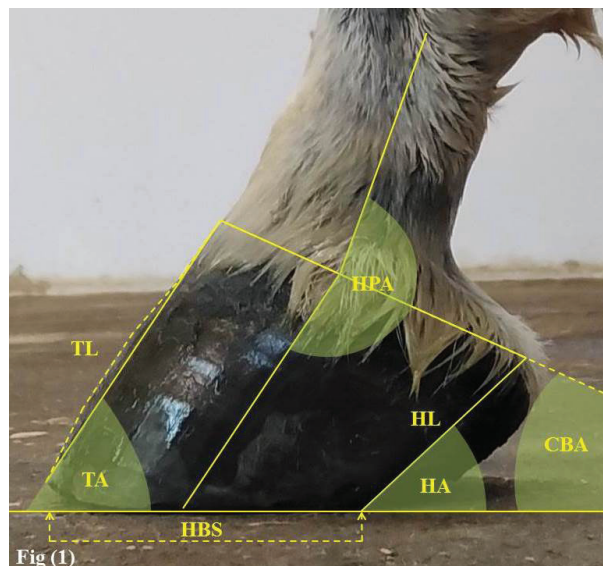


Fig 1: Lateral photographic view on normal donkey hoof: TA (Toe angle); HA (Heel angle); CBA (Coronary band angle); HPA (Hoof pastern axis); TL (Toe length); HL (Heel length); and HBS (Hoof base of support).

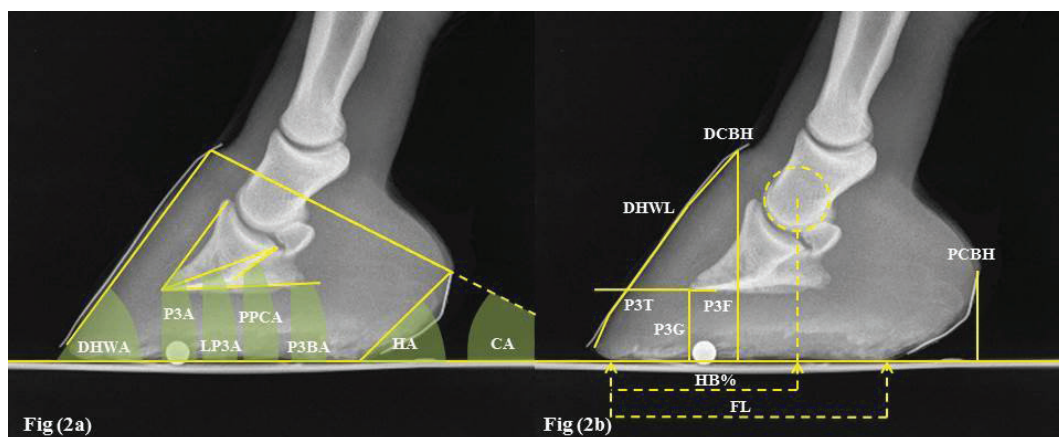


Fig 2: LM radiographic view of normal donkey hoof (a) showed angular radiometric parameters included DHWA (Dorsal hoof wall angle); P3A (Distal phalanx angle); LP3A (Axis of distal phalanx angle); PPCA (Proximal palmar cortex angle); P3BA (Distal phalanx solar border angle); HA (Heel angle); and CA (Coronary angle). (b) showed linear radiometric parameters included DHWL (Dorsal hoof wall length); DCBH (Dorsal coronary band height); PCBH (Palmar coronary band height); P3T (Distal phalanx to toe distance); P3F (Distal phalanx to frog distance); P3G (Distal phalanx to ground distance); FL (Foot length); and HB% (Hoof balance %).

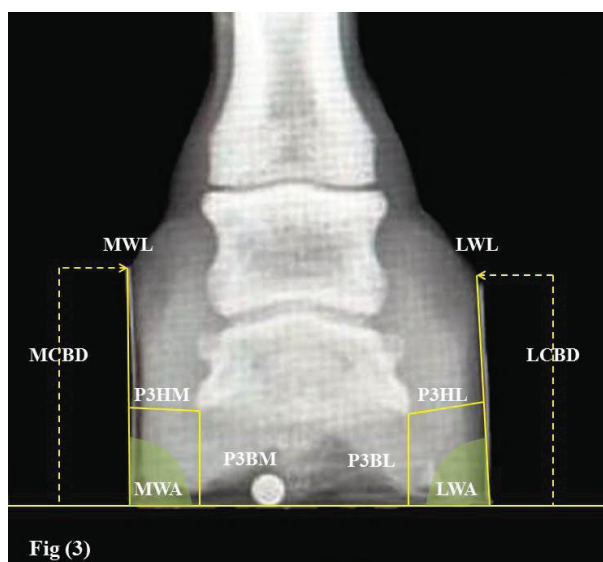


Fig (3)

Fig 3: DP radiographic view of normal donkey hoof: MWA (Medial wall angle); LWA (Lateral wall angle); MWL (Medial wall length); LWL (Lateral wall length); MCBBD (Medial coronet to bottom distance); LCBD (Lateral coronet to bottom distance); P3HM (Distal phalanx to medial hoof wall distance); P3HL (Distal phalanx to lateral hoof wall distance); P3BM (Medial distal phalanx to bottom distance); and P3BL (Lateral distal phalanx to bottom distance).

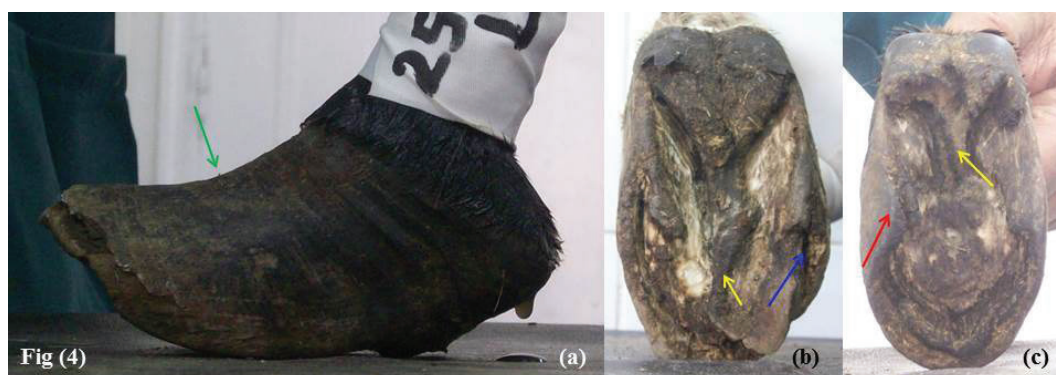

Fig (4)

Fig 4: Lateral and solar views in long toe-under run heel donkey hooves: Concavity of dorsal hoof wall (green arrow); elongation of the frog apex (Fig. 4b) which recessed in severe cases due to the damage from the abnormal weight bearing (Fig. 4c) (yellow arrow); running of the medial hoof wall under the ground surface of the hoof (red arrow); and abnormal widening of white line (blue arrow).

and destructed (Fig. 4c). The mean \pm SD of normal and long toe underrun heel hooves in donkeys were documented in table (1). TA in long toe underrun heel was significant ($P \leq 0.0001$) decreased ($41.97 \pm 9.27^\circ$) compared with a normal healthy donkey ($59.5 \pm 4.48^\circ$). Morphological HA in normal healthy donkeys was $43.33 \pm 6.5^\circ$ and it was significantly decreased ($36.42 \pm 5.44^\circ$) in underrun heel hooves. The difference between TA and HA was ($16.17 \pm 4.82^\circ$) in normal healthy donkeys and this difference was found to be decreased in long toe underrun heels ($5.56 \pm 6.3^\circ$).

HPA showed a significant ($P = 0.026$) increase in long toe underrun heel than in normal healthy donkey hoof which indicated a broken back HPA. HBS showed a significant ($P \leq 0.0001$) decrease in long toe underrun heel in donkey hoof in comparison with a normal healthy donkey. There were no significant

changes in CBA, TL, and HL parameters between normal healthy and long toe underrun heel donkeys.

The lateral radiographic angular parameters showed a significant difference ($P \leq 0.0001$) between healthy normal and long toe underrun heels hooves except CA (Table 1). The difference between DHWA and radiological HA was (5.4°) in normal healthy donkey hooves and (1.72°) in long toe underrun heel. Morphological hoof wall angle (TA) was nearly the same as the radiological one (DHWA). The values of HA were larger in radiological than in photographic measurements.

Estimated P3A was smaller than DHWA in the normal healthy donkey and the difference between them was 1.6° . The P3A in the long toe underrun heels was higher than the DHWA and the difference between

them was 7.11° . The determined P3BA showed a negative value ($-0.61 \pm 4.03^\circ$) in the long toe underrun heel compared with the normal healthy donkey ($4.8 \pm 1.64^\circ$). There was a significant ($P < 0.05$) decrease in the angles of the distal phalanx (P3A, P3BA, LP3A, and PPCA) in long toe underrun heel compared with the normal healthy donkey.

The FL showed a significant ($P = 0.009$) decrease in long toe underrun heel (57.14 ± 17.13 mm) com-

pared with normal donkey hooves (86.57 ± 9.47 mm). The HB% was significant ($P \leq 0.0001$) increased ($91.51 \pm 16.09\%$) in long toe underrun heel in comparison with the normal donkey hoof ($65.11 \pm 4.46\%$).

The distal phalanx radiographic linear measurements of P3G, P3F, DCBH, PCBH, and HI showed no significant changes between long toe underrun heel and normal healthy hooves. The determined values of these parameters in long toe underrun heel hooves

Table (1): The mean morphological and radiographic parameters of the normal hoof capsule and distal phalanx in long toe underrun heel in donky hooves:

Parameters	Normal hoof capsule	Long toe underrun heel hoof capsule	P-value
Morphological hoof capsule parameters			
Toe angle (TA)	59.5 ± 4.48	41.97 ± 9.27	≤ 0.0001
Heel angle (HA)	43.33 ± 6.5	36.42 ± 5.44	0.049
Coronary band angle (CBA)	22.83 ± 3.92	23.89 ± 5.82	0.625
Hoof pastern axis (HPA)	182.5 ± 12.24	198 ± 12.65	0.026
Difference between toe and heel angles (TA-HA)	16.17 ± 4.82	5.56 ± 6.3	0.001
Toe length (TL) (mm)	70 ± 11.4	65.22 ± 10.67	0.392
Heel length (HL) (mm)	47.13 ± 10.24	50.17 ± 7.93	0.528
Hoof base of support (HBS) (mm)	68.73 ± 9.56	39.96 ± 16.02	≤ 0.0001
LM radiographic parameters			
Dorsal hoof wall angle (DHWA)	58.6 ± 4.39	42.28 ± 8.8	≤ 0.0001
Heel angle (HA)	53.2 ± 7.98	40.56 ± 6.57	0.019
Distal phalanx angle (P3A)	57 ± 4.3	49.39 ± 4.18	0.012
Distal phalanx solar border angle (P3BA)	4.8 ± 1.64	-0.61 ± 4.03	≤ 0.0001
Coronary angle (CA)	24.2 ± 5.17	24.56 ± 5.32	0.896
Axis of distal phalanx angle (LP3A)	25.8 ± 5.12	17.78 ± 4.39	0.02
Proximal palmar cortex angle (PPCA)	45 ± 3.74	30.89 ± 5.65	≤ 0.0001
Heel collapse index (HCI)	0.9 ± 0.08	0.99 ± 0.24	0.182
Dorsal hoof wall length (DHWL) (mm)	78.33 ± 8.6	68.45 ± 10.49	0.17
Distal phalanx to ground distance (P3G) (mm)	23 ± 4.34	21.85 ± 5.6	0.71
Distal phalanx to frog distance (P3F) (mm)	10.15 ± 2.47	5.61 ± 9.49	0.161
Distal phalanx to toe distance (P3T) (mm)	29.03 ± 6.67	35.92 ± 8.43	0.205
FL (mm)	86.57 ± 9.47	57.14 ± 17.13	0.009
Hoof balance % (HB%)	65.11 ± 4.46	91.51 ± 16.09	≤ 0.0001
Dorsal coronary band height (DCBH) (mm)	68.47 ± 8.96	55.25 ± 7.56	0.112
Palmar coronary band height (PCBH) (mm)	31.7 ± 6.08	29.45 ± 5.82	0.597
Heel height index (HI)	2.21 ± 0.5	1.9 ± 0.23	0.399
DP radiographic parameters			
Mwdial wall angle (MWA)	89.4 ± 4.45	86.67 ± 7.72	0.332
Lateral wall angle (LWA)	87.8 ± 2.05	86.5 ± 5.9	0.445
Medial wall length (MWL) (mm)	60.47 ± 18.07	52.21 ± 9.83	0.514
Lateral wall Length (LWL) (mm)	57.6 ± 15.94	51.63 ± 8.03	0.586
Lateral coronet to bottom Distance (LCBD) (mm)	57.47 ± 15.71	51.04 ± 7.67	0.554
Medial coronet to bottom Distance (MCBD) (mm)	60.27 ± 17.97	51.4 ± 8.87	0.484
Lateral distal phalanx to bottom distance (P3BL) (mm)	27.73 ± 5.95	26.79 ± 6.79	0.819
Medial distal phalanx to bottom distance (P3BM) (mm)	27 ± 8.7	27.28 ± 7.1	0.962
Distal phalanx to lateral hoof wall distance (P3HL) (mm)	12.4 ± 0.36	11.22 ± 2.25	0.052
Distal phalanx to medial hoof wall distance P3HM (mm)	13.63 ± 2.8	11.14 ± 2.13	0.258

were consistently less than the healthy hooves. The determined P3T showed a marked consistently increased in long toe underrun heel.

Radiographic parameters obtained from DP view (MWL, LWL, LCB, and MCB) showed no significant difference between normal healthy and long toe underrun heel. The determined P3HL had a significant decrease in long toe underrun heel hooves in comparison with normal healthy hooves (Table 1).

DISCUSSION

The donkeys' feet are more vertical, the hoof capsule is cylindrical, the heels are narrower giving an overall U-shape to the sole compared with the conical view of the horses' hooves (Thiemann and Rickards, 2013; Thiemann and Poore, 2019). The measured photometric and radiographic parameters evaluate the anatomical relationship between the structures of the hoof capsule and characterize the morphometric appearance of the distal phalanx (Kalka et al., 2021).

The TA in normal hooves was nearly the same as previous reports (Mostafa et al., 2020; Nocera et al., 2020a; Souza et al., 2016), however, the HA was smaller than reported by previous studies (Mostafa et al., 2020; Souza et al., 2016) and similar to that in normal horses (Dyson et al., 2011). The morphological TA and HA in the long toe under-run heel in the current study were smaller than the normal values. Underrun heel conformation fails to support weight leading to more forces on the frog, DDFT, and digital cushion that becomes deteriorated resulting in atrophied frog which moved toward the rear of the foot (O'Grady, 2020).

Morphological CBA in normal donkeys' hooves in the present study was smaller than that previously reported (Mostafa et al., 2020). The CBA had a non-significant difference between the normal and long toe underrun heel groups in the present study. However, CBA was greater in lame horses with podotroclear apparatus injuries (Dyson et al., 2011).

The normal HPA in this study was higher than that reported in a previous study in normal donkeys (Mostafa et al., 2020). In the current study, the measured HPA showed a broken back in donkey hooves with long toe under-run heel. This result agreed with the reported findings in horses with underrun heels (O'Grady, 2020). Small DHWA leads to broken back HPA and increases in the forces on the palmar part of the foot resulting in more strain on the DDFT

(Eliashar et al., 2004; O'Grady, 2020).

Normal HBS in donkeys in a previous study by (Mostafa et al., 2020) was higher than determined in the present study. This could be attributed to the difference in body weight and size of the hoof. The decreased HBS in long toe in the current study could be attributed to the abnormal mechanical moment arm that leads to bending the horn tubules at toe and concavity of dorsal hoof wall (Eliashar et al., 2004; O'Grady, 2020).

The difference between TA and HA was decreased in long toe underrun heels. This finding coincided with a previous study on donkeys' hooves with long toe (El-Marakby et al., 2023). This could be due to the horizontal elongation of the dorsal hoof wall and The decrease in the palmar soft tissue mass in long toe underrun heel hoof conformation (O'Grady, 2020).

There were no significant changes in CBA, TL and HL parameters between normal healthy and long toe underrun heel donkeys. These could be attributed to differences in age, body weight, and hoof size.

Radiological evaluation of donkey hooves in the present study showed that normal DHWA was higher than normal hoof angle in Amiata donkey (Nocera et al., 2020a) while it was lower than the normal angle in European donkeys (Collins et al., 2011) and Egyptian donkeys (El-Shafaey et al., 2017). Moreover, the DHWA in the long toe-under run heel was decreased. Acute DHWA deteriorates the palmar circulation of the foot (Turner, 2003). The decrease in DHWA leads to musculoskeletal abnormalities (Kane et al., 1998), more stress at the laminar junction of the hoof (Thomason et al., 2005), alters the alignment of DIPJ (Chateau et al., 2006) and pathological abnormalities in the bony structure of the hoof (El-Marakby et al., 2022).

DHWL in normal donkeys in the present study has coincided with normal DHWL in Amiata donkey (Nocera et al., 2020a), Egyptian donkey (El-Shafaey et al., 2017), and ponies (Thieme et al., 2015a). While, DHWL in normal warm-blood horses was higher than donkey hooves in this study (Kummer et al., 2006).

Normal P3A, P3BA, and PPCA in donkeys in the present study were lower than the previous normal results of European donkeys (Collins et al., 2011), Egyptian donkeys (El-Shafaey et al., 2017), and Amiata donkeys (Nocera et al., 2020a and b). Changes in these angles alter the angle of insertion of the DDFT

on the distal phalanx and increase the load on the navicular apparatus (Eliashar et al., 2004). The decrease in these angle has been associated with the incidence of navicular bone pathology in 26.7% of donkeys' hooves (El-Marakby et al., 2022).

In the current study, long toe underrun heel donkeys showed marked decrease in P3A, P3BA, LP3A and PPCA. The decrease in these parameters indicated the reverse rotation of distal phalanx in donkey's hooves. The negative value of the P3BA indicated the negative palmar angle syndrome (NPAS) and proved the deterioration of the palmar soft tissue structures of the hoof in donkeys as previously reported in the horse (Castelijns, 2012; Eliashar et al., 2004; Floyd, 2010; O'Grady, 2009). In contrast, these parameters increased in European and Amiata donkeys with laminitis due to the rotation of distal phalanx (Collins et al., 2011; Nocera et al., 2020a and b).

The normal FL in the present study showed a lower value than FL in normal Amiata donkeys (Nocera et al., 2020a), Egyptian donkeys (El-Shafaey et al., 2017), and ponies (Thieme et al., 2015a). Meanwhile, normal HB% in this study was larger than HB% in normal ponies (Thieme et al., 2015a). Long toe underrun heel showed a decrease in FL and an increase in HB%. (Eggleston, 2012) reported that HB% is used to evaluate dorsopalmar balance in the hoof. Accordingly, the changes in the dorsal hoof wall angle, distal phalanx solar border angle, and HB% in the present study could be used as an indicator for dorsopalmar balance in long toe underrun heel. Furthermore, the broken back HPA was occurred due to the changes in long toe hooves in horses (O'Grady, 2020; Parks, 2011).

Normal P3G in this study was higher than the normal Amiata donkeys (Nocera et al., 2020a), while it was nearly the same as reported in normal Egyptian donkeys (El-Shafaey et al., 2017). The normal P3T and P3F were greater than the Amiata donkey (Nocera et al., 2020a), Egyptian donkey (El-Shafaey et al., 2017) and ponies (Thieme et al., 2015a).

In the present study, the long toe underrun heels showed increase in P3T and decrease in P3F and FL. Flat hooves with low heels tend to increase the frog length (Parks, 2003; El-Marakby et al., 2023). In addition, the decreased P3F and increased P3T could be attributed to elongation of the horny materials at the apex of the frog and dorsal hoof wall in long toe under-run heel. The increase in P3T leads to more forces

on the laminar attachment resulting in bending of the horn tubules in the dorsal hoof wall (Redden, 2003).

The MWA, LWA, MWL, and LWL in normal donkeys in the present study were higher than previously reported in Egyptian donkeys (El-Shafaey et al., 2017) and ponies (Thieme et al., 2015a). In the present study, long toe underrun heels showed decreased MWL and LWL which could be attributed to the running of the medial and lateral walls under the solar surface of the hoof in severe cases of under run heel conformation. The same has been reported in horses (O'Grady, 2020).

The distal phalanx dorsopalmar radiographic parameters in the long toe underrun heel showed a significant difference in P3HL in comparison with normal. The flaring of the lateral hoof wall could be considered the main cause for the decrease in the P3HL. However, there were no significant changes for the dorsopalmar determined linear parameters between normal healthy and long toe-under run heel hooves.

The normal hooves parameters in this study showed different values compared with normal values in previous studies on donkeys, ponies, and horses. The environment, type of pace, nutrition, the hooves management and genetic orientation have a considerable effect on the hoof conformation. Due to these variables, variations within the same species and in different species within the same genus can be identified (Souza et al., 2016). The interaction of the foot with the environmental surface has a major role in determining the foot morphology of wild horses (Hampson et al., 2013).

Melo et al. (2006) reported that the hoof size is strongly correlated with the animal's size. Domestic donkeys ranged from 80 to 480 kg in body weight and 80 to 160 cm in body height at the withers (Gürçan et al., 2022). As a result, The variation within the same species could be also attributed to the difference in the body size, height and weight. There are numerous factors can affect the hoof morphometric data, such as trimming (Kummer et al., 2006), the type of ground surface (Hampson et al., 2013), and the intensity of activity (Cruz et al., 2006). Breed has an impact on measurements as well (Thieme et al., 2015b).

CONCLUSION

This study investigated the correlation between the position of the distal phalanx and hoof capsules in normal healthy and long toe-underrun heel hooves

and that could help the veterinarians and the farriers to take the correct decision for corrective trimming of long toe-underrun heel in donkeys hooves.

MAIN LIMITATION

The feet included in this study were collected from

donkeys of variable body sizes and collected from many yards of variable nutrition and managerial care.

CONFLICT OF INTEREST

None declared.

REFERENCES

- Butler J, Colles C, Dyson S, Kold S, Poulos P (2017) The foot, the proximal and middle phalanges and the proximal interphalangeal joint. In: Clinical radiology of the horse. 4th ed., John Wiley & Sons, Ltd., Oxford, UK: pp 55-173.
- Castelijns H (2012) The basics of farriery as a prelude to therapeutic farriery. *Vet Clin North Am Equine Pract* 28: 316-320.
- Chateau H, Degueurce C, Denoix J (2006) Three-dimensional kinematics of the distal forelimb in horses trotting on a treadmill and effects of elevation of heel and toe. *Equine Vet J* 38: 164-169.
- Collins S, Dyson S, Murray R, Burden F, Trawford A (2011) Radiological anatomy of the donkey's foot: objective characterization of the normal and laminitic donkey foot. *Equine Vet J* 43: 478-486.
- Cruz C, Thomason J, Faramarzi B, Bignell W, Sears W, Dobson H, Konyer N (2006) Changes in shape of the Standardbred distal phalanx and hoof capsule in response to exercise. *Equine Comp Exerc Physiol* 3 (4): 199-208.
- Dyson S, Tranquille C, Collins S, Parkin T, Murray R (2011) An investigation of the relationships between angles and shapes of the hoof capsule and the distal phalanx. *Equine Vet J* 43: 295-301.
- Eggleson RB (2012) Value of quality foot radiographs and their impact on practical farriery. *AAEP Proceedings* 58, Anaheim, California, USA: pp 164-175.
- Eliashar E, McGuigan MP, Wilson AM (2004) Relationship of foot conformation and force applied to the navicular bone of sound horses at the trot. *Equine Vet J* 36: 431-435.
- El-Marakby AI, Abdelgalil AI, Mostafa MB, Soliman AS (2022) Biometric radiographic features between foot lesions and long toe under-run heel in donkeys. *J Hellenic Vet Med Soc* 73 (3): 4559-4566.
- El-Marakby AI, Abdelgalil AI, Mostafa MB, Soliman AS (2023) Relationships between the shape of the hoof capsule and orientation of the distal phalanx in long toe under-run heels in donkeys. *Equine vet Educ* 35: 321-326.
- El-shafaey EA, Salem MG, Mosbah E, Zaghloul AE (2017) Morphometric evaluation of relevant radiographic parameters of the fore feet of clinically normal donkeys (*Equus asinus*). *J Hellenic Vet Med Soc* 68 (3): 467-478.
- Floyd AE (2010) Use of a grading system to facilitate treatment and prognosis in horses with negative palmar angle syndrome (Heel collapse): 107 cases. *J equine vet Sci* 30 (11): 666-675.
- Gürçan EK, Genç S, Kaplan S, Özdiş F, Ünal EÖ, Bulut H, Yarkin S, Arat S, Soysal MI (2022) Determination of the morphometric characteristics of donkey (*Equus asinus*) populations reared in Turkey. *Turk J Vet Anim Sci* 46 (3): 445-456.
- Hampson BA, de Laat MA, Mills PC, Pollitt CC (2013) The feral horse foot. Part A: observational study of the effect of environment on the morphometrics of the feet of 100 Australian feral horses. *Aust Vet J* 91 (1-2): 14-22.
- Kalka K, Pollard D, Dyson SJ (2021) An investigation of the shape of the hoof capsule in hindlimbs, its relationship with the orientation of the distal phalanx and comparison with forelimb hoof capsule conformation. *Equine vet Educ* 33 (8): 422-429.
- Kane AJ, Stover SM, Gardner IA, Bock KB, Case JT, Johnson BJ, Anderson ML, Barr BC, Daft BM, Kinde H, Larochelle D, Moore J, Mysore J, Stoltz J, Woods L, Read DH, Ardans AA (1998) Hoof size, shape, and balance as possible risk factors for catastrophic musculoskeletal injury of Thoroughbred racehorses. *Am J Vet Res* 59: 1545-1552.
- Kummer M, Geyer H, Imboden I, Auer J, Lischer C (2006) The effect of hoof trimming on radiographic measurements of the front feet of normal Warmblood horses. *Vet J* 172: 58-66.
- Melo UPD, Ferreira C, Santiago RMFW et al (2006) Equilíbrio do casco equino: uma revisão. *Cienc Anim Bras* 7: 389-398.
- Mendoza FJ, Toribio RE, Perez-Ecija A (2018) Donkey internal medicine-part II: cardiovascular, respiratory, neurologic, urinary, ophthalmic, dermatology, and musculoskeletal disorders. *J Equine Vet Sci* 65: 86-97.
- Morrow LD, Smith KC, Piercy RJ, Du Toit N, Burden FA, Olmos G, Gregory NG, Verheyen KL (2011) Retrospective analysis of post-mortem findings in 1,444 aged donkeys. *J Comp Pathol* 144: 145-156.
- Mostafa MB, Abdelgalil AI, Farhat SF, Raw Z, Kubasiewicz LM (2020) Morphometric measurements of the feet of working donkeys (*Equus asinus*) in Egypt. *J Equine Sci* 31: 17-22.
- Nocera I, Aliboni B, Puccinelli C, Pietrini G, Sgorbini M, Citi S, Ricardi G (2020a) Radiographic parameters of the digit in a cohort population of Amiat donkeys. *Open Vet J* 10 (4): 354-362.
- Nocera I, Aliboni B, Ben David L, Gracia-Calvo LA, Sgorbini M, Citi S (2020b) Radiographic and Venographic Appearance of Healthy and Laminitic Feet in Amiat Donkeys. *Front Vet Sci* 7: 601665.
- O'Grady SE (2009) Guidelines for trimming the equine foot: a review. *AAEP Proceedings* 55, Las Vegas, Nevada, USA: 218-225.
- O'Grady SE (2013) How to evaluate the equine hoof capsule. *AAEP Proceedings* 59, Nashville, TN, USA: 54-61.
- O'Grady SE (2020). Principles of trimming and shoeing - Farriery for common hoof problems. In: Adams and Stashak's lameness in horses. 7th ed., USA: John Wiley & Sons, Inc: pp 1095-1133.
- Parks AH (2003) Foot balance, conformation and lameness. In: *Diagnosis and management of lameness in the horse*, 1st ed., W. B. Saunders, Philadelphia Saunders, pp 250-261.
- Parks AH (2011) The foot and shoeing. In: *Diagnosis and management of lameness in the horse*. 2nd ed., St. Louis: Saunders, Elsevier Inc: pp 282-309.
- Redden RF (2003) Hoof capsule distortion: Understanding the mechanisms as a basis for rational management. *Vet Clin N Am Equine Pract* 19: 443-462.
- Reix C, Burn CC, Pritchard JC, Barr ARS, Whay HR (2014) The range and prevalence of clinical signs and conformation associated with lameness in working draught donkeys in Pakistan. *Equine Vet J* 46: 771-777.
- Salem M, El-Shafaey EA, Mosbah E, Zaghloul A (2018) Ultrasonographic, computed tomographic and magnetic resonance imaging of the normal donkeys (*Equus asinus*) digit. *J Equine Vet Sci* 74: 68-83.
- Souza AF, Kunz JR, Laus R, Moreira MA, Muller TR, Fontequé JH (2016) Biometrics of hoof balance in equids. *Arq Bras Med Vet Zootec* 68: 825-831.
- Thieman A and Rickards K (2013) Donkey hoof disorders and their treatment. In *Pract* 35: 134-140.
- Thieman AK and Poore LA (2019) Hoof disorders and farriery in the donkey. *Vet Clin North Am Equine Pract* 35 (3): 643-658.
- Thieme K, Ehrle A, Lischer C (2015a) Radiographic measurements of the hooves of normal ponies. *Vet J* 206 (3): 332-337.
- Thieme K, Ehrle A, Lischer C (2015b) Morphometric measurements of the horses hoof - A review of the literature. *Pferdeheilkunde* 31: 108-118.
- Thomason JJ, McClinchey HL, Faramarzi B, Jofriet JC (2005) Mechanical behavior and quantitative morphology of the equine laminar junction. *Anat Rec ADiscov Mol Cell Evol Bio* 283 (2): 366-379.
- Turner TA (2003) Examination of the equine foot. *Vet Clin Equine* 19: 309-332.
- White JM, Mellor DJ, Duz M, Lischer CJ, Voute LC (2008) Diagnostic accuracy of digital photography and image analysis for the measurement of foot conformation in the horse. *Equine vet J* 40 (7): 623-628.