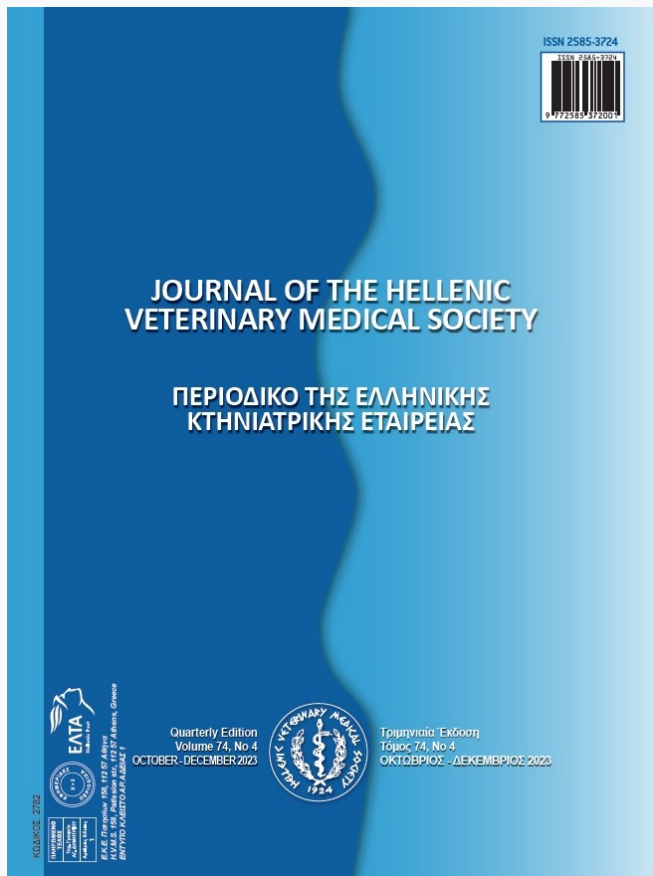


## Journal of the Hellenic Veterinary Medical Society

Vol 75, No 1 (2024)



### Canine orchietomy via scrotal approach using vessel-sealing device: prospective observational study of 200 cases

C Yiapanis, C Ober, M Psyllaki, C Attipa, M Potamopoulou, T Vasilakis, J Milram

doi: [10.12681/jhvms.32367](https://doi.org/10.12681/jhvms.32367)

Copyright © 2024, C Yiapanis, C Ober, M Psyllaki, C Attipa, M Potamopoulou, T Vasilakis, J Milram



This work is licensed under a [Creative Commons Attribution-NonCommercial 4.0](https://creativecommons.org/licenses/by-nc/4.0/).

#### To cite this article:

Yiapanis, C., Ober, C., Psyllaki, M., Attipa, C., Potamopoulou, M., Vasilakis, T., & Milram, J. (2024). Canine orchietomy via scrotal approach using vessel-sealing device: prospective observational study of 200 cases. *Journal of the Hellenic Veterinary Medical Society*, 75(1), 6831–6838. <https://doi.org/10.12681/jhvms.32367>

## Canine orchietomy via scrotal approach using vessel-sealing device: prospective observational study of 200 cases

C. Yiapanis<sup>1,7\*</sup>, C. Ober<sup>2</sup>, M. Psyllaki<sup>1</sup>, C. Attipa<sup>3,4,5</sup>, M. Potamopoulou<sup>6</sup>,  
T. Vasilakis<sup>1</sup>, J. Milgram<sup>7</sup>

<sup>1</sup>*Cyvets Veterinary Centre, Tassou Papadopoulou Avenue 138, 8025 Paphos, Cyprus*

<sup>2\*</sup>*Department of Surgery, Faculty of Veterinary Medicine, University of Agricultural Sciences and Veterinary Medicine, Calea Manastur 3-5, 400372 Cluj-Napoca, Romania*

<sup>3</sup>*Department of Tropical Disease Biology, Liverpool School of Tropical Medicine, Liverpool L3 5QA, UK*

<sup>4</sup>*Malawi Liverpool Wellcome Clinical Research Programme, Blantyre, Malawi*

<sup>5</sup>*Pathology Department, Kamuzu University of Health Sciences, Blantyre, Malawi*

<sup>6</sup>*Fitzpatrick Referrals, Halfway lane Godalming GU7 2QQ, United Kingdom*

<sup>7</sup>*Department of Small Animal Surgery, Koret School of Veterinary Medicine, The Robert H. Smith Faculty of Agriculture, Food & Environment, The Hebrew University of Jerusalem, P.O. Box 12, 76100 Rehovot, Israel*

**ABSTRACT:** Canine orchietomy procedure involves making an incision in the scrotal or prescrotal area, exteriorizing both testes via the same incision, ligating the blood vessels and spermatic cord, removing the testes, and suturing the incision. A briefer duration of anaesthesia and surgery that might decrease postoperative morbidity could be obtained using a vessel sealing device. The aim of this study was to determine the feasibility and safety of orchietomy in dogs by a scrotal approach with the use of a vessel-sealing device. Scrotal orchietomy was performed with the use of monopolar electrosurgery and a vessel sealing device. Data were collected prospectively for the following categorical variables: breed, age, body weight, lifestyle, surgical time, indications for surgery and complications. No complications were reported in 187 of 200 (93.5%). The complications documented were automutilation (AM), incisional complications (IC) and scrotal complications (SC). AM complications (11/200 [5.5%]) and SC complications (2/200 [1%]) were treated without additional surgery and resolved by day 10 after the surgery. Procedure duration (2.1 minutes $\pm$  0.4 minutes) was briefer than traditional castration duration reported in literature (3.5  $\pm$  0.4 minutes). This study provides evidence that canine orchietomy by scrotal approach with the use of a vessel-sealing device was feasible and safe. Furthermore, it was associated with a low complication rate and had the benefit of reduced surgical time.

**Keywords:** Canine orchietomy; Canine castration; neutering; sterilisation; vessel sealing device; Ligasure; scrotal approach; monopolar electrosurgery

*Corresponding Author:*  
C. Yiapanis, CYVETS Veterinary Center, Leof. T. Papadopoullos 138, Paphos 8025, Cyprus  
E-mail address: drcy@cyvets.com

*Date of initial submission: 14-12-2022*  
*Date of acceptance: 27-07-2023*

## INTRODUCTION

Canine orchietomy is one of the most commonly performed surgical procedures in first opinion small animal practice worldwide (Pollari et al., 1996, Howe, 2006, Reichler, 2009, Adin, 2011). The most common indication for orchietomy is surgical sterilisation (neutering). Other indications are the reduction of androgen-related disorders (anxiety and aggressiveness), the tendency to roam, undesirable urination, prostatic disease, perianal adenomas, perineal hernias, the prevention of hereditary diseases, testicular abnormalities, scrotal urethrostomy, inguinal-scrotal herniorrhaphy and endocrine abnormalities (Hamilton et al., 2014).

There is a wide variety in the techniques used to perform orchietomy in dogs. The technique is influenced by geographic areas, the age and the size of the patient, finances, and the purpose of the procedure (Adin, 2011). Common approaches used in adult dogs include prescrotal incision, scrotal incision-scrotal ablation, and perineal approach when performing perineal surgery (Hedlund, 2007). The scrotal approach has been proposed in prepuberal dogs (Crane, 1998, Gothem, 2016), and for castrating adult dogs of any age (Johnston and Archibald, 1974, Bushby, 2013, Woodruff et al., 2015). This approach may offer advantages that include decreases in anaesthetic and surgical times, smaller incision length and less surgical trauma, decreased postoperative discomfort, less self-trauma and decreased likelihood of formation of scrotal hematoma (Johnston and Archibald., 1974, Bushby, 2013, Woodruff et al., 2015). Severe complications of orchietomy are rare, but may include scrotal swelling and bruising, haemorrhage, scrotal hematoma, abscess, granuloma, incisional problems (swelling, seroma formation, cellulitis, infection, automutilation, dehiscence), urinary incontinence, endocrine alopecia, behavioural changes and eunuchoid syndrome (Boothe, 2003). Most complications associated with orchietomy can be prevented by using good surgical technique, including gentle tissue handling, good hemostasis, and aseptic technique (Hedlund, 2007). Haemorrhage from poorly ligated vascular pedicles can result in scrotal haemorrhage or intra-abdominal bleeding due to the retraction of the bleeding vascular pedicle through the inguinal canal (Gothem, 2016). Traditionally hemostasis is achieved with the use of ligatures but their reported disadvantages are occasional ligature slippage, introduction of foreign matter, difficult management, size limitation and application time (Gracia-Calvo et

al., 2012). For these reasons the use of electro-surgical devices with enhanced safety characteristics have gained popularity in small animal surgery (Diamantis et al., 2008). Vessel sealing devices (VSD) achieve hemostasis by the fusion of elastin and collagen in the vessel walls and surrounding connective tissue using moderate compression at a temperature less than 100°C (212°F). The low energy used in these devices results in less collateral thermal spread and tissue damage when compared to the traditional electrocoagulation devices (Kennedy et al., 1998, Landman et al., 2003). Ligasure is a feedback-controlled bipolar vessel sealing device that is now well established in human and equine surgery and has been shown to be effective in sealing vessels up to 7 mm in diameter (Launois et al., 2009). Therefore, the aim of this study was to evaluate the feasibility and safety of Ligasure vessel-sealing device for closed orchietomy via scrotal approach. We hypothesised that the technique will be fast and the complication rates would be low. in comparison to the conventional orchietomy techniques

## MATERIALS AND METHODS

### Data collection

A prospective observational study for canine orchietomy by scrotal approach using a vessel-sealing device was performed at the CYVETS Veterinary Centre from December 2015 to December 2018. Two hundred healthy intact male dogs were recruited in this study (Supplementary table 1). Dogs less than seven years old were determined to be healthy based on medical history and physical examination performed on the day of surgery, whilst in dogs more than seven years old routine biochemistry and haematology were performed prior to anaesthesia to assess their health status. The intact male dogs enrolled in the study, following a signed consent form by the owners or guardians, were presented either from local animal welfare organisations or were client-owned dogs. All procedures were approved by the Ethics Committee of Ministry of Agriculture, Development and Environment, Veterinary Services, (protocol number 1/2021) and performed according to the Cypriot legislation [The Dogs LAW, N. 184 (I)/2002]. The study was carried out in compliance with the ARRIVE guidelines. All surgical procedures were performed by a single experienced veterinary surgeon (C. Yiapanis, ECVS resident) in order to avoid interobserver variability. Data were recorded and included breed, bodyweight, age, total surgical time, lifestyle (private/shelter) and

the encountered complications up to 10 days post-surgery.

All protocols were standardised prior to commencing the study. These included: preparation for aseptic surgery, surgical procedure, recovery protocol, post-operative instructions and client communication.

After every use, each handset was initially washed in tap water to remove debris and the jaws of the handset were soaked in 2% enzymatic cleaner solution for 5 minutes according to previous recommendations (Kuvaldina et al., 2018). The jaws were scrubbed with a sponge and a brush. The handset was sterilised by using hydrogen peroxide sterilisation - 4 two-minute pulses of vaporised hydrogen peroxide at 66.7 kPa (Kuvaldina et al., 2018). The handsets were discarded after 16 cycles according to guidelines (Kuvaldina et al., 2018).

Orchiectomy time was measured from immediately prior the skin incision to apposition of the incision site and dogs were categorised based on body weight into small (<10kg), medium (10 to 20 kg) and large breed (>20 kg). Associated complications were documented including automutilation (AM), incisional complications (IC) (haemorrhage, bruising, swelling, erythema) and scrotal complications (SC) (swelling, bruising, hematoma). The treatments/measurements employed to address the encountered complications were buster collar application (BC) and local cryotherapy with ice packs (IP), for 10 minutes on the surgical site, in all complications and additional analgesia with non-steroidal anti-inflammatory medication and antibiotics in the cases with combination of incisional and scrotal complications.

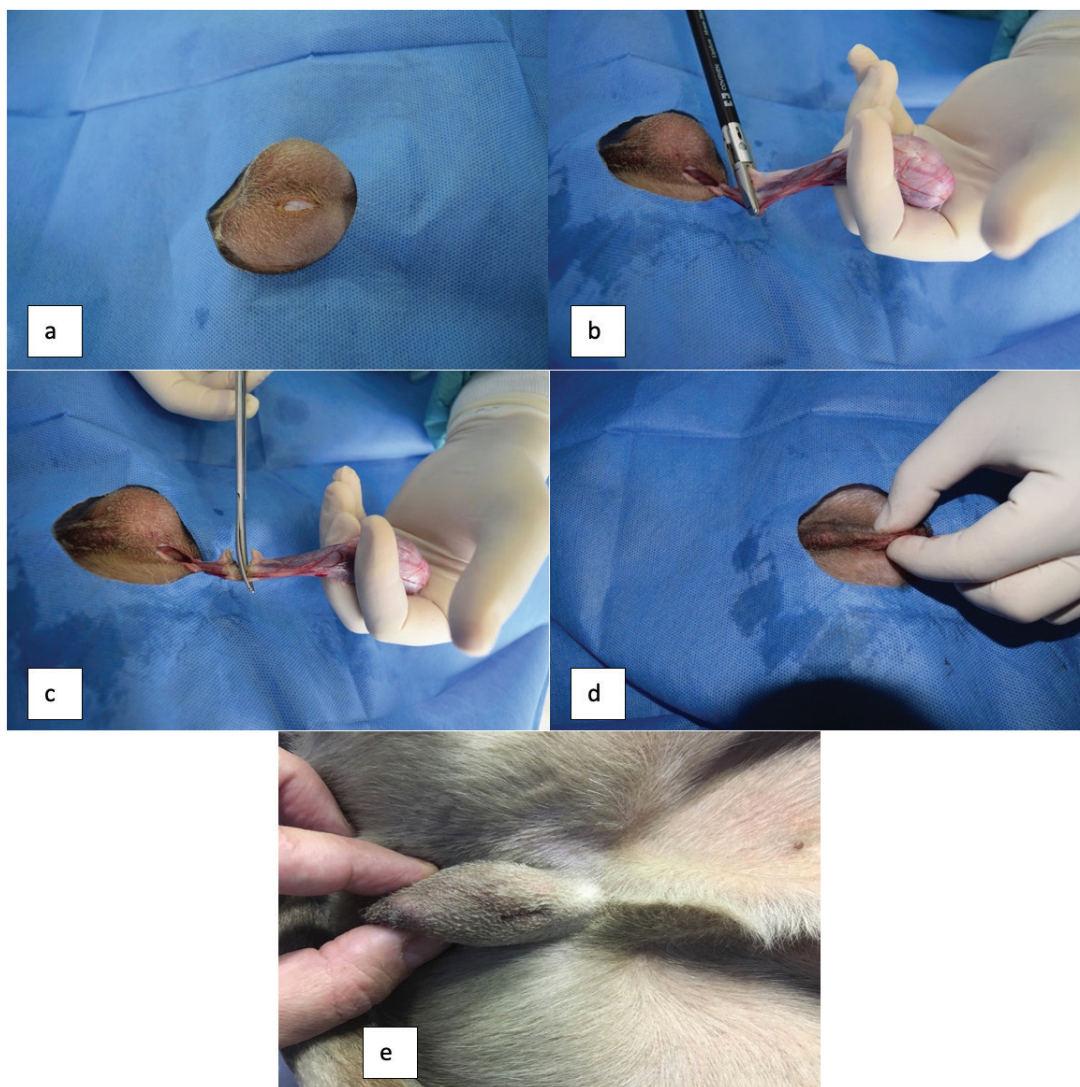
### Perioperative management

All dogs were anaesthetized by use of standard clinical protocols. Young healthy dogs were premedicated 2 to 7 minutes prior induction with 0.02 mg/kg b.w., intravenously (iv) medetomidine (Domitor, Pfizer) and 10-20 µg/kg b.w., iv buprenorphine (Bupredine, Multidose). Induction to anaesthesia was achieved with 1 to 3 mg/kg b.w. propofol slowly iv to effect (Propofol 1%, Fresenius pharma) and maintained with 2% inspired isoflurane (Isoflo 100%, Abbott Pharma) in oxygen with the use of a Bain circuit. In patients over 10 years old, medetomidine was replaced by 0.2 mg/kg b.w., iv midazolam (Dormicum, Roche). Signs of Midazolam-associated dysphoria were not encountered due to the coadministration of

buprenorphine. Anaesthesia was monitored by clinical assessment and a multi parameter anaesthesia monitor. All dogs received 0.2 mg/kg b.w., iv meloxicam (Metacam, Boehringer) before anaesthesia. Additional analgesia with buprenorphine was administered after 6 to 8 hours after surgery in patients with evidence of pain (WSAVA, 2014). A small square area around the incision site was clipped with slow-powered clippers with 0,5mm blade. Care was taken not to traumatise the sensitive scrotal skin during clipping. The skin was prepared with cotton gauze sponges soaked in surgical scrub (Dermanios Scrub CG, Anios lab) applied twice in the preparation area and once in the surgical theatre. Prior to cutting the skin, a final spraying of the surgical site was carried out with 2% Chlorhexidine Digluconate solution in distilled sterile irrigation water. The patients were positioned in dorsal recumbency and draped with a round fenestrated self-adhesive drape.

### Surgical procedures

The left testicle was grasped between the thumb and index of the surgeon and directed caudoventrally while pulling the scrotal skin taut over the testicle. The scrotal skin cranial and ventral to the median raphe at the apex of the scrotum, was incised with a monopolar electrosurgery device (Eschmann TD830), in pure cutting mode at 100-150W output (small and medium-large patients respectively), approximately one-third of the length of the long axis of the testicle (0,5-2 cm) (Figure 1A). The incision was continued through the spermatic fascia until the parietal tunic was seen. A closed approach was employed, leaving the parietal and visceral vaginal tunics intact. The testicle within the parietal layer of the vaginal process was exteriorised, and the spermatic cord was exposed by dissecting through fat and spermatic fascia with monopolar electrode and stripping all visible connective tissue from the parietal tunic using a gauze sponge. A 10-mm instrument (LigaSure Atlas Sealer/Divider—LS10) connected to a bipolar, acoustic feedback-controlled vessel sealing device (LigaSure Generator-Valleylab, Boulder, Colorado, USA) with a power setting of three bars was applied to the spermatic cord and the instrument was activated to achieve hemostasis (Figure 1B). The sealing and transection time was less than 5 seconds per cord, appreciably faster than suture ligation. After hemostasis was completed, the spermatic cord was transected with scissors and the stump was returned to the scrotum (Figure 1C,D). The second testicle was grasped and directed



**Figure 1** Surgical procedure. **A**, Scrotal incision. **B** Exteriorization of the testicle, spermatic cord exposure and LigaSure activation for hemostasis. **C** Transection of the spermatic cord with scissors distal to the sealed spermatic cord. **D** Gentle approximation of the incision edges after stump retraction. **E** Final aspect of the surgery

under the initial scrotal incision. The scrotal septum was incised with the use of monopolar electrosurgery device, and the second testicle was removed using the identical technique. After completing the procedure, the skin was opposed by gentle approximation of the incision edges with the scrotum left to heal by second intention. (Figure 1E).

### Postoperative care

All dogs were hospitalised for 6-8 hours after surgery. During this period, they were closely monitored for signs of pain, haemorrhage and swelling of the surgical site. The assessment of the amount of pain was carried out hourly and was based on the observation of the demeanour and posture of the animal in the kennel and during the interaction with the dog while

examining the wound for signs of surgery associated complications. Following discharge from the clinic, all owners were instructed to rest their dogs for 1 day. Short lead walks four to five times a day for toileting were permitted. Progressive return to exercise over one week was advised, if healing was uncomplicated. Owners were instructed not to dress or treat the wound. A buster collar was provided to the owners, but it was not applied to the animals. Owners were advised to monitor the surgical wound twice daily and apply the buster collar and contact the members of the staff if self-trauma, discomfort or swelling were evident at the surgical site.

Follow up phone calls to the owners were conducted on day 1 after discharge and on day 10. An additional phone call was conducted on day 5 in the cases

that any complication was reported. During the communication, a standard questionnaire format was employed and the owner's comments were documented.

### Statistical analysis

Data was recorded into Microsoft Office Excel 2016 and then imported into SPSS (version 22.0; SPSS Inc., Chicago IL, USA) for statistical analysis. Descriptive statistics were performed for the continuous variables of age and duration of surgery, as well as for the following categorical variables: breed, body weight (small, medium and large), lifestyle (private or shelter), indications for surgery (neutering, prostatic disease, testicular disease and other) and post-operative complications (none, AMIC, AMICSC). Independent t-test was used to evaluate for associations between continuous variables and complications. To investigate any association for complications and categorical variables a univariable analysis conducted using Chi-square test as well as the Fisher's exact test when sample size was smaller than 5. A multivariable logistic regression was performed to test for possible risk factors associated with complications. The independent variables that yielded P-values of  $< 0.2$  in a univariable analysis were then tested in a multivariable logistic regression analysis. A P-value  $\leq 0.05$  was considered statistically significant. The P-values with odds ratio (OR) and 95% confidence interval (CI) were reported.

### RESULTS

The descriptive statistics are reported at Table 1. The majority of the dogs enrolled were privately owned (79.0%, 158/200) and the most common in-

dication for this operation was neutering (92.0% 184/200). 84 dogs (42.0%) weighed less than 10kg while the remaining 116 (58%) weighed more than 10kg on the day of the surgery. The mean duration of

**Table 1** Characteristics of the study dogs underwent orchiectomy by scrotal approach using a vessel-sealing device

Characteristic	Dogs (%) (N=200)
Age in years	
Mean	3.7
Standard deviation	2.8
Breed	
Pedigree	51 (25.5)
Crossbreed	149 (74.5)
Weight	
<10kg	84 (42.0)
11-20kg	68 (34.0)
>20kg	48 (24.0)
Lifestyle	
Private	158 (79.0)
Shelter	42 (21.0)
Indication for surgery	
Neutering	184 (92.0)
Prostatic disease	7 (3.5)
Testicular disease	4 (2.0)
Other	5 (2.5)
Duration of surgery in mins	
Mean	2.1
Standard deviation	0.5
Complication	
None	187 (93.5)
AMIC	11 (5.5)
AMICSC	2 (1.0)

Abbreviations: AM: automutilation, IC: incisional complications, SC: scrotal complications

**Table 2** Summary of the dogs that developed complications at day 1 and associated treatment

Case	Breed	Age (Year)	Weight (kg)	Origin: private/shelter	Complication	Treatment
13	Pomeranian	4	5	Private	AM/IC	BC/IP
21	Chihuahua	3	3	Private	AM/IC	BC
46	Labrador	3	27	Private	AM/IC/SC	BC/IP/ANG/ATB
50	Cross breed	3	5	Private	AM/IC	BC/IP
75	Poodle	5	7	Private	AM/IC	BC/IP
114	Pointer	2	16	Private	AM/IC	BC/IP
118	Poodle	1	6	Private	AM/IC/SC	BC/ANG/ATB
136	Cross breed	1	5	Private	AM/IC	BC/IP
141	Pomeranian	1	4	Private	AM/IC	BC/IP
152	Husky	1	25	Private	AM/IC	BC/IP
163	Pincher	2	7	Private	AM/IC	BC
183	Hound	1	10	Shelter	AM/IC	BC/ANG/ATB
197	Spaniel	10	13	Private	AM/IC	BC/ANG/ATB

AM: automutilation; ANG: Analgesia; ATB: Antibiotics; BC: Buster collar; IC: incisional complications; IP: Ice Packs; SC: scrotal complications

**Table 3** Univariable analysis for associations between categorical variables and complications in dogs that underwent orchiectomy by scrotal approach using a vessel-sealing device. Significant P-values  $\leq 0.05$  are shown in bold

Variable	No. of dogs (N=200)	Complications		OR	95% CI for OR	P-value
		Yes (%)	No (%)			
Breed						
Pedigree	51	5 (9.8)	46 (90.2)	1.9	0.6 - 6.1	0.267
Crossbreed	149	8 (5.4)	141 (94.6)			
Weight						
<10kg	84	9 (10.7)	75 (89.3)	3.4	0.9 - 11.3	<b>0.040</b>
>10kg	116	4 (3.4)	112 (96.6)			
Lifestyle						
Private	158	11 (7.0)	147 (93.0)	0.6	0.1 - 3.1	0.607
Shelter	42	2 (4.8)	40 (95.2)			
Indication for surgery						
Neutering	184	12 (6.5)	172 (93.5)	0.9	0.1-7.8	0.966
Non-neutering causes	16	1 (6.3)	15 (93.8)			

Abbreviations: OR odds ratio, CI confidence interval

canine orchiectomy by scrotal approach using a vessel-sealing device was 2 minutes with a SD (standard deviation) of 0.5. Complications were noted in 13 dogs (6.5%) and all of them were reported during the first 24 hours post-operatively (Table 2). The results from univariable analysis on continuous and categorical variables are shown in Table 3. The only variable that was significantly associated with post-operative complications (including both AMIC and AMICSC) following orchiectomy by scrotal approach using a vessel-sealing device was the weight of the dog. Dogs that were less than 10 kg developed complications 3 times more often (CI: 0.9 - 11.3,  $P = 0.046$ ) compared to the dogs that weighed more than 10 kg. There was no variable that showed a trend towards significance thus the multivariable logistic regression did not yield any additional findings.

## DISCUSSION

We hypothesised that the technique will be faster than the traditional ligation and the complication rates would be low in the study population. The first hypothesis was confirmed by the fact that procedure duration was briefer (1,9 minutes  $\pm$  0.5 minutes in cases with complications and 2,1 minutes  $\pm$  0.4 minutes in cases without complications) than those reported for traditional prescrotal castration as reported by Miller et al. (2018) (3.5  $\pm$  0.4 minutes). Based on this finding, we concluded that the technique in this study provides a rapid technique for castration. Shorter duration of castration in male dogs using Ligasure were reported also by Faluvégi et al. (2018), but they used a prescrotal approach. A similar advantage in terms of timing with Ligasure was demonstrated by Bufalari et

al (2019) during Grey Squirrel gonadectomy.

The second hypothesis of the present study was that the complication rate would be low. This hypothesis was supported by the fact that the presented technique resulted in no haemorrhagic complications for any of the 200 surgeries performed, and the minor complications that were observed were scarce and self-limiting. Based on these results, we concluded that the Ligasure scrotal technique provides a rapid and safe approach for canine orchiectomy. Major haemorrhage associated with orchiectomy is uncommon in dogs (Adin, 2011) and most complications involving hemostasis result in scrotal hematomas, likely due to oozing from the vaginal tunic with open orchiectomy (Pollari et al., 1996, Adin, 2011). According to Miller's et al. (2018) experience, large dogs with large gonads will generally have a larger gonadal blood supply than small dogs with small gonads. Interestingly, dogs that were less than 10 kg developed complications 3 times more often (CI: 0.9 - 11.3,  $P = 0.046$ ) compared to the dogs that weighed more than 10 kg in our study. No hemostatic complications were seen after Ligasure application in our study. The weight of the dog was the only variable that was significantly associated with complications (including both AMIC and AMICSC) following orchiectomy by scrotal approach using a vessel-sealing device in this study. We consider the behaviour and temperament of the small dogs to be mostly responsible for incisional complications due to increased tendency for self-mutilation.

All complications were identified 24 hours

post-surgery assessment and resolved without additional surgery. We hypothesise that the inflammatory phase of healing predisposes dogs to excessive licking at day 1 postoperative, hence the increased rate of complications. All incisional complications were managed by telephone communication with the owners. None of the owners with incisional complications felt that their dog required additional analgesia. The cases that developed incisional and scrotal complications (dog 46 and 118) were admitted for examination and additional analgesia with NSAIDs was considered. Antibiotics were also indicated for these cases. None of the cases required hospitalisation and both complications were encountered in client owned animals. In case 118, the owners were unable to apply the buster collar as soon as AM was noticed due to aggression of the dog. In dog 46, both incisional and scrotal complications were also observed, the application of the collar was delayed because the dog was left unattended for several hours. Based on this, we can assume that AM is an important factor in the appearance and progression of complications. Despite the findings of this study, based on our experience, shelter animals had less complications, assuming that the distractions in the environment prevented AM or complications passed unnoticed.

In the uncomplicated cases contraction of the scrotum and elimination of the incisional gap was observed by day 3. In all cases in which the complications were observed, sufficient regression of the scrotum with no incisional gap was observed by day 10. In the cases that both incisional and scrotal complications were observed (dogs 46, 118), some skin discoloration remained in the scrotal region by day 10. Nevertheless, the majority of the animals in the study did not require a buster collar, and strict exercise restriction was limited to 24 hours post discharge. Interestingly, the limited postoperative restrictions and the avoidance of the buster collar were factors that were strongly appreciated by the owners when they were questioned regarding owners' satisfaction. Assessment at 10 days after surgery is routinely performed by several Veterinary practitioners but the value of assessment at this time point is questionable due to the fact that the majority of the complications arise the first days after the procedure (Hamilton et al., 2014). Due to the uncomplicated healing and the rapid elimination of the incisional gap, most owners felt that further assessment was not necessary.

Activation of the vessel sealing system uses elec-

tro-surgical radiofrequency energy that causes the collagen and elastin in the blood vessel walls to reorganise within the tissue thereby forming a permanent seal (Scott et al., 2017). Monopolar electrosurgery was used to incise the scrotal skin, and to control minor bleeding from septal vessels. Even though skin incisions made with monopolar electrosurgery were associated with decreased healing compared to scalpel made incisions (Scott et al., 2017), sufficient regression of the scrotum and no incisional gap was evident by day 10 in all cases. Clearly benefits in hemostasis improvements, and overall anaesthesia and surgery time reduction were demonstrated in many studies (Mckenna et al., 1996, Collard et al., 2010, Öhlund et al., 201, Wouters et al., 2011, Proença, 2015, Belch et al., 2016). Even though there are reasonable concerns regarding the high cost of using VSD in routine procedures, appropriate re-sterilization of the hand piece allows a significant reduction in the costs by increasing the number of procedures without decreasing safety characteristics (Gracia-Calvo, 2012, Gardeweg, 2019).

Several limitations of the study should be considered when interpreting the results. Primarily there was not a control group castrated with a conventional prescrotal procedure (with the same preparation and anaesthetic protocol). Furthermore, the control after surgery was considered weak as only phone calls were analysed. Thus, the low number of complications postoperative should be interpreted with caution since in case of animals were examined by a veterinarian likely more complications would have been identified. Some incisional complications could have developed beyond the 24-hour postoperative. Anyway, the owners were instructed to report any complication with the surgery. Similar to our study, in a previous report (Hamilton, 2014) most complications following canine orchietomy were discovered at the 24-hour recheck examination and no complications were found at the next recheck examination, performed 10 days after surgery. The authors of the study also advocated for re-checking of patients in the immediate postoperative period and questioned the value of follow up at 10 days after surgery. We found only one study of postoperative complications after Ligasure orchietomy in the peer-reviewed veterinary literature, thus, direct comparisons with the findings of the present study are limited (Faluvégi et al. 2018). Moreover, the authors of the study used prescrotal approach, thereby precluding any meaningful comparison with our data.



Another limitation of the study includes the use of semi-objective methods for documenting each complication and the fact that the assessment of the majority of the cases was based on owners' perception. For these reasons, more objective evaluations should be carried out in a larger randomised prospective study.

In conclusion, in this study, the Ligasure technique utilised for the orchiectomy of dogs provides a valid and promising alternative technique compared to the traditional prescrotal technique in the light of the low complications as well as the short duration of anaesthesia and surgery.

## CONCLUSIONS

The low complication rate and time advantage as-

sociated with use of the Ligasure technique for orchiectomy of dogs suggested important advantages, including shorter durations of anaesthesia and surgery than with the traditional prescrotal technique. We expect that as the Ligasure technique is more widely used, morbidity and mortality rates associated with canine orchiectomy will improve as will savings in resources, such as time and suture materials. The results of the present study provide important data for the veterinarians who perform such surgeries.

## CONFLICT OF INTEREST

None declared

## ACKNOWLEDGEMENTS

Not applicable.

## REFERENCES

- Adin CA (2011) Complications of ovariectomy and orchidectomy in companion animals. *Vet Clin North Am Small Anim Pract.*41:1023-1039.
- Belch A, Matiasovic M, Rasotto R, Demetriou J (2016) Comparison of the use of LigaSure versus a standard technique for tonsillectomy in dogs. *Vet Rec.*180:196.
- Boothe HW (2003) Testes and epididymides. In: Slatter DH, editor. *Textbook of Small Animal Surgery*, 3rd ed. W.B. Saunders: Philadelphia:1521-1531.
- Bushby PA. (2013) Surgical techniques for spay/neuter. In: Zawistowski ML, editor. *Shelter Medicine for Veterinarians and Staff*, 2nd ed. Wiley-Blackwell: 625-645.
- Collard F, Nadeau ME, Carmel EN (2010) Laparoscopic splenectomy for treatment of splenic hemangiosarcoma in a dog. *Vet Surg.* 39:870-872.
- Crane SW (1998) Orchiectomy of descended and retained testes in the dog and cat. In: Bojrab MJ, editor. *Current Techniques in Small Animal Surgery*. 4th ed. Baltimore:Williams & Wilkins: 517-523.
- Diamantis T, Gialikaris S, Kontos M, Gakiopoulou C, Felekouras E, Pappalou A., et al. (2008) Comparison of safety and efficacy of ultrasonic and bipolar thermal energy: an experimental study. *Surg Lapar End Percutan Techn.* 18:384-390.
- Faluvégi A, Bedi D, Banhidj J, Demeter A, Molnár J (2018) Neutering of dogs and cats using LigaSure device. *Magyar Állatorvosok Lapja.* 140, 217-221.
- Gardeweg S, Bockstahler B, Duprè G (2019) Effect of multiple use and sterilization on sealing performance of bipolar vessel sealing devices. *PLoS One.* 2014(8): e0221488.
- Goethem VB (2016) Orchiectomy. In: Griffon D, Hamaide A, editors. *Complications in Small Animal Surgery*. John Wiley & Sons, Inc: 528-533.
- Gracia-Calvo LA, Martín-Cuervo, M, Jiménez J, Vieitez V, Durán ME, Argüelles D, Ezquerro LJ (2012) Intra and postoperative assessment of re-sterilised Ligasure Atlas for orchidectomies in horses: clinical study. *Vet Rec.* 171(4):98.
- Hamilton K, Henderson E, Toscano M, Chanoit G (2014) Comparison of postoperative complications in healthy dogs undergoing open and closed orchidectomy. *JSAP.* 55:521-526.
- Hedlund CS (2007) Surgery of the reproductive and genital systems. In: Fossum TW, ed. *Small Animal Surgery*, 3rd ed. St.Louis: Mosby, Elsevier: 702-774.
- Howe LM (2006) Surgical methods of contraception and sterilisation. *Theriogenol.* 66:500-509.
- Johnston DE, Archibald J. (1974) Male genital system. In: Archibald J, editor. *Canine Surgery*. 2nd ed. Santa Barbara, CA: American Veterinary Publications: 703-749.
- Kennedy JS, Stranahan PL, Taylor KD, Chandler JG (1998) High-burst-strength, feedback-controlled bipolar vessel sealing. *Surg Endosc.* (12):876-878.
- Kuvaldina A, Hayes G, Summer J, Behling-Kelly E (2018) Influence of multiple reuse and reesterilization cycles on the performance of a bipolar vessel sealing device (LigaSure) intended for single use. *Veterinary Surgery*
- Landman J, Kerbl K, Rehman J, Andreoni C, Humphrey PA, Collyer W., et al (2003) Evaluation of a vessel sealing system, bipolar electrocoagulation, harmonic scalpel, titanium clips, endoscopic gastrointestinal anastomosis vascular staples and sutures for arterial and venous ligation in a porcine model. *J Urol.*169:697-700.
- Launois MT, Vandeweerd JMEF, Perrin RAR, Brogniez L, Gabriel A, Coomer R (2009) Evaluation of a vessel-sealing device to assist eye enucleation and exenteration in the horse. *Equine Vet. Educ.* 21:596-601.
- Mckenna RJ, Brenner M, Gelb AF, Mullin M, Singh N, Peters H (1996) A randomized prospective trial of stapled lung reduction versus laser bullectomy for diffuse emphysema. *J Thorac Cardiovasc Surg.* 111:317-322.
- Miller KP, Rekers WL, Lena GDT, Blanchette JM, Milovancev M. (2018) Evaluation of sutureless scrotal castration for pediatric and juvenile dogs. *JAVMA.* 253:1589-1593.
- Öhlund M, Höglund O, Olsson U, Lagerstedt AS (2011) Laparoscopic ovariectomy in dogs: a comparison of the LigaSure™ and the SonoSurg™ systems. *JSAP.* 52:290-294.
- Pollari FL, Bonnett BN, Bamsey SC, Meek AH, Allen DG (1996) Post-operative complications of elective surgeries in dogs and cats determined by examining electronic and paper medical records. *JAVMA.* 208:1882-1886.
- Proença LM. (2015) Two-Portal Access Laparoscopic Ovariectomy Using Ligasure Atlas in Exotic Companion Mammals. *Vet Clin North Am Exot Anim Pract.*18:587-596.
- Reichler IM (2009) Gonadectomy in cats and dogs: a review of risks and benefits. *Reprod Dom Anim.* 44:29-35.
- Scott JE, Swanson EA, Pearce EC, Cooley J, Wills RW (2017) Healing of canine skin incisions made with monopolar electrocoagulation versus scalpel blade. *Vet Surg.* 46:520-529.
- Woodruff K, Bushby PA, Rigdon-Brestle K, Wills R (2015) Scrotal castration versus prescrotal castration in dogs. *Vet Med.* 110:131-135.
- Wouters EGH, Buishand FO, Kik M, Kirpensteijn J (2011) Use of a bipolar vessel-sealing device in resection of canine insulinoma. *JSAP.* 52:139-145.