

Περιοδικό της Ελληνικής Κτηνιατρικής Εταιρείας

Τόμ. 75, Αρ. 2 (2024)



Ultrasonographic study on pastern soft tissue injuries in tent pegging horses

A Zohier, T Baraka , A Abdelgalil, A Aboelmaaty, SG Yehia

doi: [10.12681/jhvms.34024](https://doi.org/10.12681/jhvms.34024)

Copyright © 2024, A Zohier, T Baraka , A Abdelgalil, A Aboelmaaty, SG Yehia



Άδεια χρήσης [Creative Commons Αναφορά-Μη Εμπορική Χρήση 4.0](https://creativecommons.org/licenses/by-nc/4.0/).

Βιβλιογραφική αναφορά:

Zohier, A., Baraka , T., Abdelgalil, A., Aboelmaaty, A., & Yehia, S. (2024). Ultrasonographic study on pastern soft tissue injuries in tent pegging horses. *Περιοδικό της Ελληνικής Κτηνιατρικής Εταιρείας*, 75(2), 7309–7314. <https://doi.org/10.12681/jhvms.34024>

Ultrasonographic study on pastern soft tissue injuries in tent pegging horses

A.S.Zohier^{1*}, T.A.Baraka², A.I.Abdelgalil³, A.M.Aboelmaaty⁴, S.G. Yehia⁵

^{1*} Postgraduate master's student, Faculty of Veterinary Medicine, Cairo University

² Department of Medicine and Infectious Diseases, Faculty of Veterinary Medicine, Cairo University

³ Department of Surgery, Anesthesiology, and Radiology, Faculty of Veterinary Medicine, Cairo University, Giza, Egypt

⁴ Veterinary Research Institute, National Research Centre, Cairo, Egypt

⁵ Department of Medicine and Infectious Diseases, Faculty of Veterinary Medicine, Cairo University

ABSTRACT: Background: Pastern ultrasonography remains a useful and affordable choice, whether it is used in the field or when advanced imaging is not an option due to availability or cost considerations. Tent pegging is a high-speed sport practiced since the 4th century BC. There is a paucity of literature available about injuries associated with this type of sport. Aim of work: To study the incidence of soft tissue injuries at the pastern region in tent-pegging horses. Materials and methods: Ultrasonographic study was carried out on the palmar pastern region of 46 forelimbs (23 horses) to detect the different soft tissue injuries that occurred in association with this kind of sport. Results: Bilateral SDF chronic tendonitis was the highest percentage of the scanned affections, representing (52.2%). The most affected level in the SDFT was the right P1A (60.9%) and also showed a significant positive correlation with age. Conclusion: Long-term exposure to tent-pegging sports and poor rehabilitation programs lead to chronic tendonitis and adhesions, which subsequently lead to poor performance.

Keywords: Equine; Tendonitis; Ultrasound; Tent pegging; Pastern;

Corresponding Author:

Ahmed Sameh Zohier, Postgraduate master student, Faculty of Veterinary Medicine, Cairo University, Faculty of Veterinary Medicine, Cairo University
E-mail address: draahmedzohier@gmail.com

Date of initial submission: 20-03-2023
Date of acceptance: 01-11-2023

INTRODUCTION

Pastern ultrasonography remains a useful and affordable choice, whether it is used in the equine field to identify the structures and the type of lesions in the pastern area as a screening method or when advanced imaging is not available (Whitcomb, 2008, Coudry and Denoix, 2013). Many palmar soft tissue injuries of the limb result in non-specific subcutaneous fibrosis, which inhibits correct digital palpation of the area. So ultrasonography is particularly suitable to study such lesions (Carstens and Smith, 2014).

Tendinopathy of the deep digital flexor tendon (DDFT) is a common pastern injury in equestrian athletics. DDFT lesions represented 19%-24% of the ultrasonographic investigations at the pastern region (Acutt et al., 2022). Ultrasonography had a high sensitivity, specificity, and positive predictive value (71%) in detecting marginal DDFT tears, core lesions of the superficial digital flexor tendon (SDFT) or DDFT that are not visible with tenoscopy, and abnormal Digital Sheath (DS) findings (90% sensitivity) (Coudry and Denoix, 2013).

Straight sesamoidean ligament (SSL) injuries are uncommon. Recently, new advances in diagnostic imaging helped in better diagnosis of these injuries (Hawkins et al., 2022).

Tent pegging is an ancient sport that originated from the Indian battlefields. It is used by the cavalry to attack elephant-mounted troops (Puckey, 2015).

To the author's knowledge, there was no published literature studying the ultrasonographic changes of the forelimb pastern region and the prevalence of their injuries in tent-pegging horses. The study aimed to investigate the prevalence of palmar pastern soft tissue injuries in both forelimbs in active tent-pegging horses using ultrasound.

MATERIAL AND METHODS

Clinical examination

Lameness evaluation was visually evaluated by two expert examiners. Clinical evaluation was done by deep palpation of the flexor tendons and the distal sesamoidean ligaments for pain, heat, and swelling (Baxter and Stashak, 2020).

Animal selection

The inclusion criteria included clinically sound horses that played tent pegging for at least more than

3 years with a mean \pm SD age (14 ± 3.8) years and all horses were kept in the same equestrian club. Twenty horses had a previous history of forelimb lameness that improved after administration of phenylbutazone (Phenylject®) 3.3 mg/kg once daily for 3-5 days.

Twenty-three apparently healthy tent-pegging horses (10 stallions, 8 geldings, and 5 mares) in the period between (Jan 2021 and June 2022) were scanned for ultrasonographic changes in the pastern region extended from the distal border of proximal sesamoid bone down to the level just above the heel bulbs.

Ultrasonographic evaluation

Ultrasonographic images were obtained using a high-frequency 6.5-10 MHz linear ultrasonic transducer (Chison L7V-A, China) with a displayed depth of 3-6 cm. The palmar aspect of the pastern regions of both forelimbs was clipped, shaved, and washed. Then, ultrasound gel was applied and then the scanning began. The limb was kept in a full weight-bearing position during examination and image recording. Ultrasonographic examinations of all horses were performed by the same examiner.

The palmar aspect of the pastern region was divided into 4 transverse levels in the order (P1A, P1B, P1C, and P2A) (Baxter, 2011, Alzola et al., 2018). SDFT, DDFT, and SSL were evaluated at all levels (4 transverse scans). DS effusion was evaluated at 2 transverse levels. The data were quantitatively assessed according to the percentage of affected horses for each structure and each level.

Statistical analysis

Data are subjected to analysis using SPSS (Version 25.0, 2016). Mann-Whitney U test was used to compare between the prevalence of injuries at each level in the right limb versus the left one. Spearman's correlation coefficient (rs) was used to study the correlation of prevalence of injury between different levels and to assess the correlation between age and prevalence of injury at different levels. The statistically significant P-value was < 0.05 .

RESULTS

Seventeen horses (73.9%) were evaluated to have tendons and ligaments abnormalities at the palmar pastern of both forelimbs.

The number and percentage of horses showing af-

fection at different levels at the pastern region of the right and left forelimbs are presented in Table (1)

Twelve horses (52.2%) showed bilateral SDF tendonitis; two horses showed unilateral right SDF tendonitis; one horse showed unilateral left SDF tendonitis. There was no significant difference between right and left SDF injuries at all examined ultrasonographic levels (Table 2). The P1A level was the most affected in the right and left SDF, representing 60.9% (14 out of 23) and 52.2% (12 out of 23), respectively. Right and left SDF injuries at P1A level showed a significant positive correlation with age ($r=0.50$; $P=0.01$) ($r=0.55$; $P=0.007$), respectively (Table 3).

Two horses (8.7%) showed bilateral DDFT affections; one horse showed unilateral right DDFT ten-

donitis; three horses showed unilateral left DDFT tendonitis and seventeen horses (73.9%) showed normal DDFT. DDFT abnormalities commonly occurred bilaterally and there was no significant difference between right and left DDFT injuries at all examined levels (Table 2). The P1C level was the most affected level of the right DDFT (Figure 1) representing 13.0% (3 out of 23). The P1A and P1B levels were the most affected levels of the left DDFT representing 13.03% (3 out of 23). There was no correlation between DDFT injuries and age (Table 3).

There was no correlation between SDF tendonitis and DDFT tendonitis across all scanned levels in both right and left forelimbs (Table 4)

Seven horses (30.4%) showed bilateral SSL desmitis, three horses showed unilateral right SSL de-

Table (1) Number (N) and Percentage of affected horses at each ultrasonographic level of the pastern region

Levels	SDFT				DDFT				Adhesion between SDFT & DDFT				Distal Pouch of Digital sheath				SSL			
	Right		Left		Right		Left		Right		Left		Right		Left		Right		Left	
	N	%	N	%	N	%	N	%	N	%	N	%	N	%	N	%	N	%	N	%
P1A	14	60.87%	12	52.17%	2	8.70%	3	13.04%	14	60.87%	15	65.22%	10	43.48%	10	43.48%	7	30.43%	10	43.48%
P1B	9	39.13%	10	43.48%	2	8.70%	3	13.04%	11	47.83%	11	47.83%	10	43.48%	10	43.48%	9	39.13%	10	43.48%
P1C	3	13.04%	2	8.70%	3	13.04%	2	8.70%	6	26.09%	2	8.70%	3	13.04%			6	26.09%	2	8.70%
P2A			1	4.35%	2	8.70%	1	4.35%	3	13.04%	2	8.70%					4	17.39%	2	8.70%

N=23; SDFT: Superficial Digital Flexor Tendon; DDFT: Deep Digital Flexor Tendon; SSL: Straight Sesamoidean

Table (2) Mann-Whitney (U) test between right and left ultrasound Pastern levels

Ultrasound Metacarpus		<i>P Value</i>			
Levels		<i>SDFT</i>	<i>DDFT</i>	<i>SSL</i>	
P1A		0.556	0.639	0.365	
P1B		0.767	0.639	0.767	
P1C		0.639	0.639	0.124	
P2A		0.317	0.555	0.386	

SDFT: Superficial Digital Flexor Tendon; DDFT: Deep Digital Flexor Tendon; SSL: Straight Sesamoidean

Table (3) Spearman correlation (rs) between the Age and different ultrasound metacarpal levels in both right and left limbs:

Ultrasound metacarpus levels		SDFT		DDFT		SSL		DS	
		Correlation Coefficient (rs)	<i>P Value</i>	Correlation Coefficient (rs)	<i>P Value</i>	Correlation Coefficient (rs)	<i>P Value</i>	Correlation Coefficient (rs)	<i>P Value</i>
Right Limb	P1A	0.50	0.01	-0.11	0.63	0.238	0.274	0.100	0.648
	P1B	0.32	0.14	-0.11	0.63	0.075	0.734	0.100	0.648
	P1C	0.00	1.00	-0.18	0.42	-0.106	0.631		
	P2A	0.00	0.00	-0.11	0.63	-0.158	0.473		
Left Limb	P1A	0.55	0.007	-0.02	0.93	0.375	0.078	0.489	0.018
	P1B	0.35	0.10	0.07	0.75	0.44	0.04	0.549	0.007
	P1C	0.05	0.83	0.00	1.00	-0.106	0.630		
	P2A	-0.15	0.50	0.00	1.00	-0.106	0.630		

SDFT: Superficial Digital Flexor Tendon; DDFT: Deep Digital Flexor Tendon; SSL: Straight Sesamoidean; DS: Digital Sheath

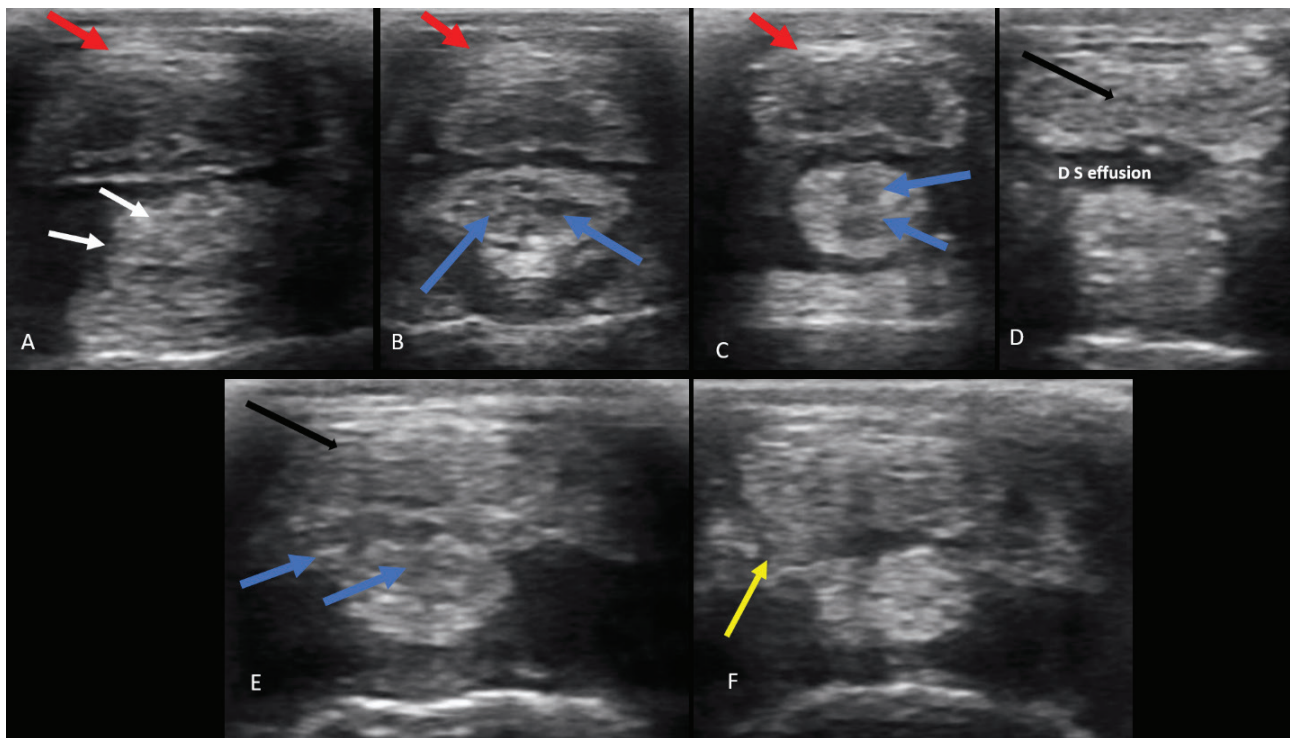


Figure 1: (A) Transverse scan of the right pastern at level P1B of a 15-year-old mare showing adhesion between SDFT and DDFT (red arrow), an irregular margin of the SSL, (SSL desmitis; white arrows). Transverse scans of the left (B) and right pastern (C) at levels P1A and P1B of a 12-year-old gelding showing increased echogenicity of the SDF with adhesion between it and the DDFT (red arrow). SSL showed hypo-echoic dots and irregular shapes (blue arrows). (D) Transverse scan of the right pastern at levels P2A of a 12-year-old gelding showing heterogeneous echogenicity of both lobes of the DDFT (black arrow), with the asymmetric appearance of the DDFT lobes. (E) A transverse scan of the right pastern at level P1C of a 16-year-old gelding showing enlarged DDFT with heterogeneous echogenicity and adhesion between it and the SSL, and SSL appeared irregular in shape with heterogeneous echogenicity (SSL desmitis). (F) Transverse scan of the left pastern at level P2A of a 16-year-old gelding showing adhesion between the SDFT branch, DDFT, and SSL with increased echogenicity of SSL and heterogeneous echogenicity of DDFT.

Table (4) Spearman correlation (r_s) between the SDFT and DDFT injuries at different ultrasound Pastern levels in both right and left limbs:

Ultrasound metacarpus levels		Correlation Coefficient (r_s)	<i>P</i> Value
Right Limb	P1A	-0.069	0.755
	P1B	0.069	0.755
	P1C	0.233	0.284
	P2A	-	-
Left Limb	P1A	-0.405	0.056
	P1B	0.181	0.408
	P1C	-0.095	0.666
	P2A	-0.045	0.837

Table (5) Spearman correlation (r_s) between the DS effusion and SDFT injuries at Pastern levels in both right and left limbs:

Ultrasound metacarpus levels		<i>Right SDFT</i>		<i>Left SDFT</i>	
		Correlation Coefficient (r_s)	<i>P</i> Value	Correlation Coefficient (r_s)	<i>P</i> Value
Right DS	P1A	.524	0.010	.489	0.018
	P1B	0.375	0.077	.469	.469
Left DS	P1A	0.523	.010	0.664	0.001
	P1B	.555	.006	0.469	0.023

DS: Digital sheath; SDFT: Superficial Digital Flexor Tendon

smitis (Figure 1), four horses showed unilateral left SSL desmitis, and nine horses (39.1%) showed normal SSL. The P1B level was the most affected level at the right SSL, representing 39.1 % (9 out of 23). The P1A and P1B levels were the most affected level at the left SSL, representing 43.5 % (10 out of 23). Left SSL injuries at the P1B level showed a significant positive correlation with age ($r=0.44$; $P=0.04$) (Table 3).

Seven horses (30.4 %) showed bilateral DS effusion, three horses showed unilateral right DS effusion, and four showed unilateral left DS effusion. nine horses (39.1 %) showed normal DS. There was a positive correlation between left DS effusion and age at P1A and P1B ($r=0.49$; $P=0.01$) ($r=0.55$; $P=0.007$), respectively. Right and left DS effusion showed a significant positive correlation with left and right SDFT injuries (Table 5).

DISCUSSION

To the authors' knowledge, this is the first study to investigate the ultrasonographic changes at the pastern region of tent-pegging horses. Ultrasonography is an immediate, valuable, and widely described diagnostic tool for the evaluation of soft tissue structures and joints (Dyson and Denoix, 1995, El-Bably and Abdelgalil, 2018, Yassin et al., 2020).

In the current study, the SDFT was the most affected tendon in both forelimbs, and this finding was in the same line with previous studies (Ely et al., 2004, Thorpe et al., 2010a, Ramzan and Palmer, 2011). Tent-pegging horses sprint at a full gallop, reaching speeds of at least 45 km/h.

There was a significant positive correlation between age and prevalence of injuries at specific anatomical sites in the right and left SDFT at the pastern region. An age-associated risk of injury to the SDFT was in the same line with previous studies (Birch et al., 1999, Perkins et al., 2005, Thorpe et al., 2013). The mechanical characteristics of the SDFT's inter-fascicular matrix alter with age and stiffen in elderly tendons, leading fascicles within the tendon to be loaded early during tendon extension. The increased pressures placed on the fascicles during use may predispose them to damage, increasing the risk of fatigue-induced tendon injury (Thorpe et al., 2013). Tendon microstructure and mechanical strength changes caused by ageing, such as a decrease in the crimp angle in the SDFT core with age (Patterson-

Kane et al., 1997), the presence of higher levels of type III collagen in aged SDFT (Birch et al., 1999), and the accumulation of partially degraded collagen in the SDFT matrix (Thorpe et al., 2010b), may explain why the prevalence of tendon damage increases with age.

During the weight-bearing phase of the stride, the distal sesamoidean ligaments act as a part of the suspensory apparatus that provides support and prevents the hyperextension of the metacarpophalangeal joint. The distal sesamoidean ligaments are the distal components of the suspensory apparatus and appear to have a similar risk of overload injury as the suspensory ligament during hyperextension (Sampson et al., 2007).

Damage to the digital sheath structures can result in varying degrees of effusion in horses. (Daniel et al., 2019). The regeneration of tendinous and ligamentous structures within synovial environments was poor, which might be attributed to the lack of an innate mechanism for intra-synovial clearance of destructed collagen fibrils, which could persist as synovial irritant foci and delay the reparative mechanism. (McIlwraith, 1992, Wright, 1995, Wright and McMahon, 1999, Minshall and Wright, 2006). This fact can explain the strong positive correlation between digital sheath effusion and SDFT injuries observed in this study. On the contrary, DDFT lesions are the most commonly linked with DS tenosynovitis (Coudry and Denoix, 2013). There was no correlation between DDFT injuries and DS effusion and this may be due to the low number of horses presented with DDFT abnormality at the pastern region ($n=17$).

In tent pegging, the peg is placed on the right side of the horse, so the rider should always bear his weight on the right side of the horse while galloping in a straight line to carry the peg with the weapon. So, the right forelimb is more prone to fatigue than the left one.

CONCLUSION

Tent pegging is a high-speed equestrian sport that leads to stress on both forelimbs. Chronic Improper management and rehabilitation after tendon injuries during training may be one of the main causes of the increased incidence of chronic tendonitis, desmitis, and chronic inflammation of the digital sheath. Age is an important factor in the pathophysiology of SDFT tendinopathy at the pastern region.

The main limitations included the small number of scanned horses, and further studies should be directed to study the risk factors and the main causes of the degenerative lesions related to tent pegging.

CONFLICT OF INTEREST STATEMENT

There was no conflict of interest.

ACKNOWLEDGMENT

The authors would like to thank the tent pegging team and their staff who participated in this study.

REFERENCES

- Acutt E.V., Contino E.K., Frisbie D.D. & Barrett M.F. (2022). Deep digital flexor tendon lesions in the pastern are associated with the presence of distal tendinopathy. *Equine Veterinary Journal*, 54, 502-512.
- Alzola R., Easter C., Riggs C., Gardner D. & Freeman S. (2018). Ultrasonographic-based predictive factors influencing successful return to racing after superficial digital flexor tendon injuries in flat racehorses: A retrospective cohort study in 469 Thoroughbred racehorses in Hong Kong. *Equine veterinary journal*, 50, 602-608.
- Baxter G.M. (2011). Chapter 4 : Imaging. In: *Manual of Equine Lameness*. First Edition ed.: John Wiley & Sons.
- Baxter G.M. & Stashak T.S. (2020). Examination for Lameness: History, Visual Exam, and Conformation. In: *Adams and Stashak's lameness in horses*. 7th edition ed.
- Birch H.L., Bailey J., Bailey A. & Goodship A. (1999). Age-related changes to the molecular and cellular components of equine flexor tendons. *Equine veterinary journal*, 31, 391-396.
- Carstens A. & Smith R.K. (2014). Ultrasonography of the foot and pastern. In: *Atlas of Equine Ultrasonography*. First Edition ed.: John Wiley & Sons, Ltd.
- Coudry V. & Denoix J.M. (2013). Ultrasonographic examination of the palmar aspect of the pastern of the horse: Digital flexor tendons and digital sheath. *Equine Veterinary Education*, 25, 196-203.
- Daniel A., Leise B., Selberg K. & Barrett M. (2019). Enhanced ultrasonographic imaging of the equine distal limb using saline injection of the digital flexor tendon sheath: a cadaver study. *The Veterinary Journal*, 247, 26-31.
- Dyson S.J. & Denoix J.-M. (1995). Tendon, tendon sheath, and ligament injuries in the pastern. *Veterinary Clinics of North America: Equine Practice*, 11, 217-233.
- El-Bably S. & Abdelgalil A. (2018). Ultrasonographic anatomy of the equine carpal region (*Equus caballus*). *International Journal of Veterinary Science*, 7, 44-49.
- Ely E., Verheyen K. & Wood J. (2004). Fractures and tendon injuries in National Hunt horses in training in the UK: a pilot study. *Equine veterinary journal*, 36, 365-367.
- Hawkins A., O'Leary L., Bolt D., Fiske-Jackson A., Berner D. & Smith R. (2022). Retrospective analysis of oblique and straight distal sesamoid ligament desmitis in 52 horses. *Equine Veterinary Journal*, 54, 312-322.
- McIlwraith C. (1992). Tearing of the medial palmar intercarpal ligament in the equine midcarpal joint. *Equine Veterinary Journal*, 24, 367-371.
- Minshall G. & Wright I. (2006). Arthroscopic diagnosis and treatment of intra-articular insertional injuries of the suspensory ligament branches in 18 horses. *Equine veterinary journal*, 38, 10-14.
- Patterson-Kane J., Firth E., Goodship A. & Parry D. (1997). Age-related differences in collagen crimp patterns in the superficial digital flexor tendon core region of untrained horses. *Australian Veterinary Journal*, 75, 39-44.
- Perkins N., Reid S. & Morris R. (2005). Risk factors for injury to the superficial digital flexor tendon and suspensory apparatus in Thoroughbred racehorses in New Zealand. *New Zealand veterinary journal*, 53, 184-192.
- Puckey M.D. (2015). *The History of Tentpegging in Great Britain* [Online]. British Tentpegging Association Available: <https://www.britishtentpegging.co.uk/history-of-tentpegging> [Accessed].
- Ramzan P.H. & Palmer L. (2011). Musculoskeletal injuries in Thoroughbred racehorses: a study of three large training yards in Newmarket, UK (2005-2007). *The Veterinary Journal*, 187, 325-329.
- Sampson S.N., Schneider R.K., Tucker R.L., Gavin P.R., Zubrod C.J. & Ho C.P. (2007). Magnetic resonance imaging features of oblique and straight distal sesamoid desmitis in 27 horses. *Veterinary Radiology & Ultrasound*, 48, 303-311.
- Thorpe C.T., Clegg P. & Birch H. (2010a). A review of tendon injury: why is the equine superficial digital flexor tendon most at risk? *Equine veterinary journal*, 42, 174-180.
- Thorpe C.T., Streeter I., Pinchbeck G.L., Goodship A.E., Clegg P.D. & Birch H.L. (2010b). Aspartic acid racemization and collagen degradation markers reveal an accumulation of damage in tendon collagen that is enhanced with aging. *Journal of Biological Chemistry*, 285, 15674-15681.
- Thorpe C.T., Udeze C.P., Birch H.L., Clegg P.D. & Screen H.R. (2013). Capacity for sliding between tendon fascicles decreases with ageing in injury prone equine tendons: a possible mechanism for age-related tendinopathy. *Eur Cell Mater*, 25.
- Whitcomb M.B. Ultrasonographic appearance and distribution of deep digital flexor injuries in the pastern region. *Proc. Am. Ass. equine Practns*, 2008. 452-454.
- Wright I. & McMahon P. (1999). Tenosynovitis associated with longitudinal tears of the digital flexor tendons in horses: a report of 20 cases. *Equine veterinary journal*, 31, 12-18.
- Wright I.M. (1995). Ligaments associated with joints. *Veterinary Clinics of North America: Equine Practice*, 11, 249-291.
- Yassin A.M., AbuBakr H.O., Abdelgalil A.I., Khattab M.S., El-Behairy A.M. & Gouda E.M. (2020). COL2A1 and caspase-3 as promising biomarkers for osteoarthritis prognosis in an *Equus asinus* model. *Biomolecules*, 10, 354.