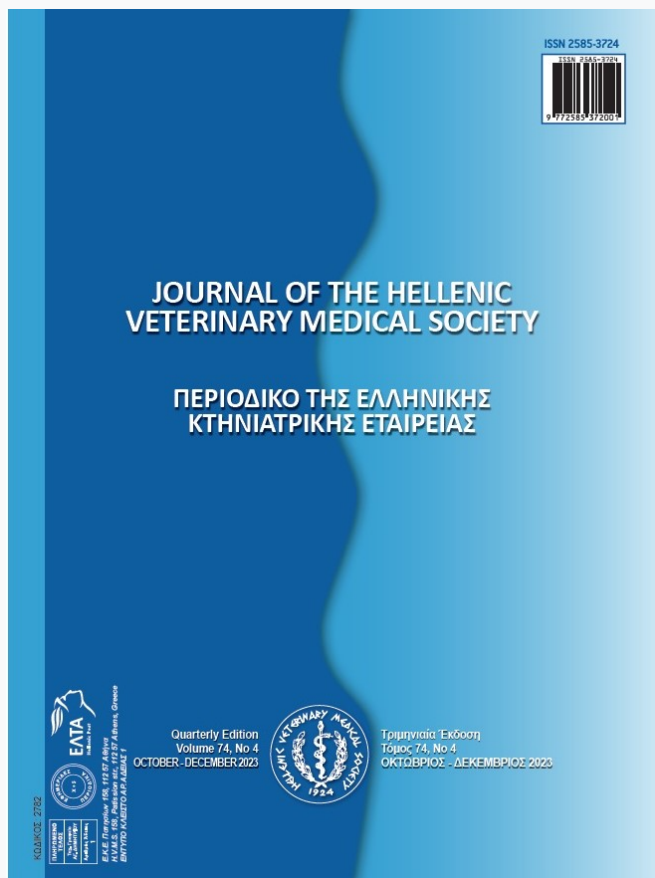


## Journal of the Hellenic Veterinary Medical Society

Vol 75, No 1 (2024)



**The effect of in ovo injection with organic selenium on the hatchability of broiler breeder hen eggs and evaluation of performance, carcass characteristics, blood constitutes, liver enzymes, immunity, cecum microbiota and breast meat fatty acid profile in their broiler chickens**

*M Yaripour, A Seidavi, M Bouyeh*

doi: [10.12681/jhvms.34215](https://doi.org/10.12681/jhvms.34215)

Copyright © 2024, M Yaripour, A Seidavi, M Bouyeh



This work is licensed under a [Creative Commons Attribution-NonCommercial 4.0](https://creativecommons.org/licenses/by-nc/4.0/).

### To cite this article:

Yaripour, M., Seidavi, A., & Bouyeh, M. (2024). The effect of in ovo injection with organic selenium on the hatchability of broiler breeder hen eggs and evaluation of performance, carcass characteristics, blood constitutes, liver enzymes, immunity, cecum microbiota and breast meat fatty acid profile in their broiler chickens. *Journal of the Hellenic Veterinary Medical Society*, 75(1), 7111–7126. <https://doi.org/10.12681/jhvms.34215>

## The effect of *in ovo* injection with organic selenium on the hatchability of broiler breeder hen eggs and evaluation of performance, carcass characteristics, blood constituents, liver enzymes, immunity, cecum microbiota and breast meat fatty acid profile in their broiler chickens

M. Yaripour<sup>1</sup>, A. Seidavi<sup>1</sup>, M. Bouyeh<sup>1</sup>

Department of Animal Science, Rasht Branch, Islamic Azad University, Rasht, Iran

**ABSTRACT:** This research aims to investigate the effect of *in ovo* injection with organic selenium on the hatchability of breeder hen eggs and evaluation of performance, carcass characteristics, blood biochemical parameters, liver enzymes, immune system response, cecum microbiota and breast fatty acid profile in production broiler chickens. Totally, 320 fertile eggs with the same average weight ( $65 \pm 1$  g) were selected from the Ross308 breeder hens (55 wks. old) for injection. Four experimental treatments include: treatment 1) negative control group (no injection); treatment 2) positive control (injection of 0.272 ml of normal saline solution); treatment 3) injection of 0.272 ml of a solution containing 5 µg/ml of organic selenium (1.36 µg for each egg) and; treatment 4) injection of 0.272 ml of a solution containing 15 µg/ml of organic selenium (4.08 micrograms for each egg). A total of 160 chickens were hatched based on a completely random design with four replications and ten birds per replication in three breeding periods including starter (1-14 days old), growth (15-28 days old) and finisher (29-42 days old) with diets based on corn-soybean meal and they were formulated on the recommended requirements. The results showed that the hatchability percentage was the highest in the group without injection (negative control). After organic selenium injection, no negative effects on production performance, carcass traits and gastrointestinal tract were observed in the whole period ( $P \geq 0.05$ ). The results of blood biochemical parameters showed that with the *in ovo* injection of organic selenium, cholesterol, atherogenic index, levels of liver enzymes, alkaline phosphatase and creatine kinase increased significantly ( $P < 0.05$ ), while the number of leukocytes decreased ( $P < 0.05$ ), which indicates the sensitivity of chickens to injected selenium, that caused a reduction in bird health parameters. The results of the intestinal microbiota showed that the groups injected with organic selenium had a noticeable decrease in *Escherichia coli* and coliform population ( $P < 0.05$ ). In conclusion, the results showed that the levels and form of organic selenium *in ovo* injected in the present study did not have a positive effect on the hatchability percentage. However, there were no negative effect on performance, carcass characteristics or gastrointestinal tract as the birds grew. In addition, blood health parameters and immune system parameters were not improved by selenium injection and some parameters were deteriorated, but there was an improvement in intestinal microbiota.

**Keywords:** Alkaline phosphatase; Coliform; Creatine kinase; *Escherichia coli*; *in ovo* injection; growth; Microbiota.

### Corresponding Author:

Alireza Seidavi; Department of Animal Science, Faculty of Agriculture, Rasht Branch, Islamic Azad University, Rasht, Iran.  
E-mail address: alirezaseidavi@iaurasht.ac.ir

Date of initial submission: 14-04-2023

Date of acceptance: 23-08-2023

## INTRODUCTION

Selenium is considered a trace mineral and an essential micronutrient, that forms part of the structure of glutathione peroxidase enzyme and plays a role in regulating energy metabolism, activation of thyroid hormones and improving the immune response and its balance. It can help protect the body against free radicals that destroy cells and acts as a natural antioxidant in the body (Arthur *et al.*, 2003; Ludwiczek *et al.*, 2004; Li and Zhao, 2009; Ahmadi *et al.*, 2018). Selenium supplements are available in two inorganic forms (sodium selenite and sodium selenate) and organic selenium (selenocysteine and selenium-rich yeast). In 2000, the US Food and Drug Administration (FDA) approved the use of selenium-rich yeast and, due to the higher absorption capacity and higher storage of the organic form than the inorganic form in the body, later Japan banned the use of the mineral form and subsequently helped to expand the consumption of organic form (Heindl *et al.*, 2010). Nowadays, with the addition of nano selenium form, promising research and reports were published, but due to the sensitivity and concerns of the form of nano material consumption, more studies are needed to ensure the accuracy and culture of using nano material forms, with more certainty be practical. A review of the scientific literature indicates the positive role of selenium supplementation on production performance and health-related parameters (blood, antioxidants, gastrointestinal tract) of broiler chickens, and it seems that supplementing the poultry diet with selenium additives it can be quite promising and effective in different forms, especially at a young age (Ahmadi *et al.*, 2019; Shabani *et al.*, 2019; Ahmadi *et al.*, 2020).

On the other hand, there are reports about overdosing with selenium (Sandholm, 1993, Balogh *et al.*, 2004). Tamrakar *et al.*, (2014) found histological alterations consisted of congestive and hemorrhagic changes of liver, lungs, kidneys, heart, spleen, brain and thymus indicating vascular effects of high doses of sodium selenite. Also, Kumar *et al.* (2018) stated that the selenium deficiency diseases have sometimes led to the overuse of selenium additives and sometimes overdosing which may result in toxic for all animals.

Moreover, as Pappas *et al.*, (2005) stated, n-3 fatty acids are beneficial for poultry health. The main problem for n-3 polyunsaturated fatty acid feeding in poultry is that they are very susceptible to peroxidation and thus increase the requirement for anti-

oxidants. Selenium is one of key components of the antioxidant system, reducing lipid peroxidation. Selenium is an essential part of a variety of selenoproteins, like glutathione peroxidase and other 6 forms of glutathione peroxidase, which are involved in cellular antioxidant protection, in synergy with vitamin E, continuing the work of vitamin E by detoxifying hydroperoxides. There are recent evidences about the need to supplement dietary (Wang *et al.*, 2011; Rajashree *et al.*, 2014; Khalil-Khalili *et al.*, 2021; Sabzian-Melei *et al.*, 2022; Araújo and Lara, 2023) and *in ovo* injection (Ibrahim *et al.*, 2020; Abdul-Majeed and Abdul-Rahman, 2022; Zhao *et al.*, 2023; Nassif *et al.*, 2023) with selenium in broiler breeder egg hens in order to improve hatcheries output and their broiler offspring productivity. Hence, we expect that optimal contents of selenium in chick embryo could improve health in offspring broiler flocks.

It is possible to increase the production of broiler chickens by improving the digestive capacity, increasing the growth rate and feed efficiency by using a series of nutrients and effective elements such as selenium with the *in ovo* injection technique. This technique can reduce mortality after hatching, improving and balancing the immune response to intestinal antigens, reducing the occurrence of developmental skeletal disorders and increasing muscle growth and meat production (Ferket, 2011). The review of scientific literature related to *in ovo* injection has attracted the attention of researchers in recent years; Hassan (2018) reports that *in ovo* feeding with selenium, without any negative effect on the embryo and was able to improve the performance of broiler chickens after the hatching process. Macalintal (2012) also states that the *in ovo* injection of selenium led to an increase in the hatchability percentage and subsequently to a decrease in the oxidation of fats. Mehmandoei *et al.*, (2017) reported that the *in ovo* injection of organic selenium led to an increase in the lifespan of newborn chicks without any negative effect on the characteristics of the incubation period. Lee *et al.*, (2014) found that the *in ovo* injection of selenium in the amniotic area of growing eggs has a great effect on strengthening the immune system and improving the antioxidant properties of the blood of productive chickens exposed to pathogens. It also has decreased necrotic enteritis and subsequently had positive and promising effects on improving the health of these chickens.

Shokraneh *et al.*, (2020) reported an increase in the antioxidant activity of newborn chicks by *in ovo* in-

jection with selenium, and at the same time reduce oxidative stress and the negative effects of incubation at high temperature. However, it has been determined that chicks are subjected to oxidative stress after hatching, and the use of compounds such as selenium can be effective in improving hatchability, increasing weight and regulating intestinal morphology (Uni and Ferket, 2003). Despite several reports on the subject, there is not strict evidence about optimal dose and form for *in ovo* injection with selenium on the hatchability of broiler breeder hen eggs and their offspring. Therefore, the main goal of this research is to investigate the effect of *in ovo* injection with organic selenium on the hatchability of broiler breeder hen eggs and further to evaluate performance, carcass characteristics, blood biochemical parameters, liver enzymes, immune system response, cecum microbiota and breast fatty acid profile in offspring broiler chickens.

## MATERIALS AND METHODS

All the activities used in this research were approved by the animal care and use committee of the Islamic Azad University of Rasht-Iran.

### Pre-hatch operation

Pre-hatch operations included incubation, *in ovo* injection and hatchery. In total, 320 fertile eggs from the Ross 308 breeder hens flock were used (55 week of age) with an average weight of  $65 \pm 1$  g, collected from the poultry farm of Navid Morgh Gilan Company (Rasht, Iran). The initial incubation was planned for the first 18 days at a temperature of  $37.6^\circ\text{C}$  and 56.0% relative humidity, with six rotations per day in a multi-stage incubator (Jamesway incubator pt100, Canada). On the 10th day of incubation, *in ovo* injections started, at the site of the amniotic fluid sac according to the protocol recommended by Williams and Hopkins (2011) and Omid *et al.*, (2020). The

contents of organic selenium injections for the experimental treatments are shown in Table 1. Eighty eggs were injected with different each treatment. In the three last days of hatchery, all the eggs were incubated according to the protocol of McQuoid (2000) in a multi-stage incubator (Jamesway incubator pt100, Canada) at a temperature of  $37.0^\circ\text{C}$  and a humidity of 58.5%.

### Post-hatch chick operation

After the incubation period of 21 days, 160 healthy chicks hatched and were raised in a completely randomized design with four treatments and four replications of ten birds for 42 days in the private farm (Guilan, Iran). The storage pens were  $1\text{ m} \times 1\text{ m} \times 1\text{ m}$  in size and were divided according to the experimental treatments. All chickens were raised in accordance with accepted animal welfare principles. The management of production chickens in terms of temperature, light, free access to drinking water and vaccination program were implemented according to the recommendations of latest the Aviagen® catalogue. Briefly, the temperature within the pens was  $31^\circ\text{C}$  in the first week and then reduced  $2^\circ\text{C}$  a week to reach a constant temperature of  $25^\circ\text{C}$ . The humidity in the pens was 55%, and the lighting program was adjusted for 23 h light and 1 h darkness. The vaccination program and other management conditions were performed according to standard instructions for Ross 308 strain.

The commercial rations were based on corn and soybean meal, in the form of pellets, during three rearing periods, including the starter (1-14 days old), grower (15-28 days old) and finisher (29-42 days old). The rations were formulated based on the recommended requirements of the breeding authority with the UFFDA software, and the components of the ration and the calculations of the amounts of nutrients are shown in Table 2. All chickens were fed *ad libitum*.

**Table 1.** Experimental treatments and concentration of solution in *ovo* injection

Treatments	Name of test ingredient in the solution	Injected amounts of solution (ml)	Amounts of organic selenium in solution ( $\mu\text{g}$ )	Experimental name groups
1	-	0	0	Negative control
2	Soluble saline	0.272	0	Positive control
3	Organic selenium <sup>1</sup>	0.272	1.36	-
4	Organic selenium <sup>2</sup>	0.272	4.08	-

<sup>1</sup> In the third treatment, the concentration of organic selenium element is  $5\text{ }\mu\text{g/ml}$  and 0.272 milliliters of injection solution was used.

<sup>2</sup> In the fourth treatment, the concentration of organic selenium element is  $15\text{ }\mu\text{g/ml}$  and 0.272 milliliters of injection solution was used.

**Table 2.** Ingredients and nutrient composition of the basal diet of the experimental treatments

Items	Starter (1-14 days)	Grower (15-28 days)	Finisher (29-42 days)
<b>Ingredients, (%)</b>			
Corn grain	49.745	46.11	50.71
Soybean Meal (SBM)	37.00	35.50	31.00
Vegetable Oil	1.50	1.50	1.50
Di-Calcium-Phosphate	1.10	0.90	0.80
CaCO <sub>3</sub>	1.25	1.20	1.20
Bentonite	0.00	1.50	1.50
NaCl	0.27	0.24	0.22
DL-Methionine (liquid)	0.21	0.16	0.15
NaHCO <sub>3</sub>	0.06	0.08	0.11
Vitamin and Mineral premix <sup>1</sup>	0.50	0.50	0.50
Diclazuril	0.03	0.03	0.00
Medermycin	0.00	0.00	0.06
DL-Methionine (powder)	0.08	0.05	0.04
Lysine	0.14	0.125	0.115
Threonine	0.06	0.05	0.04
Toxin binder	0.04	0.04	0.04
Phytase 1000	0.005	0.005	0.005
Endo-power multi enzyme	0.01	0.01	0.01
Wheat flour	8.00	12.00	12.00
<b>Calculated nutrient composition</b>			
AME <sub>n</sub> , Kcal/kg	2980	3000	3030
Crude Protein, %	21.00	20.00	18.50
Calcium, %	0.10	0.93	0.85
Available Phosphorus, %	0.48	0.47	0.45
Sodium, %	0.17	0.16	0.16

<sup>1</sup> The amount of vitamins and minerals per kg of the final diet: Vitamin A, 9000 IU; vitamin D<sub>3</sub>, 3000 IU; vitamin E, 18 IU; vitamin K<sub>3</sub>, 3 mg; vitamin B<sub>1</sub> (Thiamine), 1.8 mg; vitamin B<sub>2</sub> (Riboflavin), 6 mg; vitamin B<sub>6</sub> (Pyridoxine), 3 mg; vitamin B<sub>12</sub> (Cyanocobalamin), 0.012 mg; vitamin B<sub>3</sub> (Niacin), 30 mg; vitamin B<sub>9</sub> (Folic acid), 1 mg; vitamin H<sub>3</sub> (Biotin), 0.24mg; vitamin B<sub>5</sub> (Pantothenic acid), 10 mg; 500 mg; Choline, 100 mg; Mn, 100 mg; Zinc, 80 mg; Iron, 10 mg; Cu, 1 mg; I, 0.2 mg.

### Samples collection and preparation

On the 21st day of hatching, hatchery debris samples were broken and split to determine the embryo mortality rate and infertile or dead embryos. Visual examination of the unhatched eggs determined the number of pip eggs, exploded eggs, premature infected eggs early rot, late rot infected eggs, cracked eggs and malformation embryos (Tullett, 2009). In addition, at the end of hatchery, for hatched eggs, the total hatchability rate was calculated according to an available formula (1):

Formula (1): Total hatchability rate (%) = (number of chicks hatched/number of eggs laid in the hatchery) × 100

After reporting the hatchability percentage, the samples were collected, the weight of the chicks, and the grading of the chicks were reported. The death em-

bryo were examined and the number of feathers was determined to account for dead embryos at 11st-17th day of hatchery or at 18th-19th day of hatchery. Post-hatch period, weight gain and feed intake during rearing were measured and feed conversion ratio (FCR) was calculated. Weighing of chickens were performed on a periodical basis. This procedure has been done by calculating the difference of weight between the beginning and end of each period, in conjunction with lost birds during a time range. Then, the result was divided by the number of birds per period. Also, feed intake for each period was determined by subtracting the remaining of feed at the end of each period from the beginning of feed rationing. Furthermore, this procedure was performed for the entire period as well. Feed conversion ratio at the end of each period was calculated by knowing the body weight and feed intake in each period, as well as for the entire duration of the experiment.



At the end of the period, two chickens were selected from each replication and after four hours of fasting, they were weighed and slaughtered by cutting the jugular vein, and the weight of different carcass samples was measured. In addition, blood samples were taken from the wing vein using five milliliter syringes and centrifuged at 3000 rpm and sent to ViroMed Laboratory (Rasht, Iran). In the laboratory, the samples were measured with Pars Azmoun® commercial kits for triglycerides (TG) with colorimetric enzyme procedure and total cholesterol and very low-density lipoprotein (VLDL), low density lipoprotein (LDL) and high-density lipoprotein (HDL) were measured with enzymatic photometric method were analyzed with the protocol proposed by Tufarelli (2021) and Baghban-Kanani *et al.*, (2019). The blood glucose levels of the samples were determined by the hexokinase method based on the protocol proposed by Hosseintabar *et al.*, (2015) and Li *et al.*, (2017). Other items included alkaline phosphatase (ALP), measured according to the protocol of Sigolo *et al.*, (2019) and Safaei-Cherehh *et al.*, (2020); total protein (TP) and albumin (Alb) measured according to the method reported by Hosseintabar *et al.*, (2015); globulin (Glb) was measured according to the method reported by Belali *et al.*, (2021); creatine kinase (CK), hemoglobin (HGB) were measured according to the method used (Bahadori *et al.*, 2017) and; red blood cell count (RBC), amount of HGB in the RBC (MCH), mean RBC volume (MCV), HGB concentration in RBC (MCHC) measurements were performed according to the method of Sahr *et al.*, (2020) and Kim and Kang (2022). Liver enzymes including alanine aminotransferase (ALT) and aspartate aminotransferase (AST) were determined using the protocol used by Hosseintabar-Ghasemabad *et al.*, (2022) and Janmohammadi *et al.*, (2023).

Sampling of the bursa of Fabricius, spleen and thymus was done in order to check the immune system. In addition, in order to determine humoral immunity, chickens were immunized against sheep red blood cells (SRBC) in the amount of 0.2 cc in the wing vein on the 28th and 36th days of rearing. On the 35th and 42nd days of rearing, samples collection was done (Lerner *et al.*, 1971), and the amount of antibody of the samples was determined by the hemagglutination inhibition (HI) method (Seidavi *et al.*, 2014). On the 35th and 42nd days of rearing, two blood samples were taken from each experimental group to check the titer of Newcastle (NDV) and influenza (AIV) antibodies, and the serum titer of Newcastle and in-

fluenza were determined by the HI test based on the OIE standard (Shabani *et al.*, 2015). In the end, the samples were also used to measure heterophile (HE) according to the method of Nosrati *et al.*, (2017), monocyte (MO) according to the method of Albarrak (2021), and eosinophil (EO) according to the method of Kim and Kang (2022).

In order to evaluate the population of cecum microflora after processing the carcass, the contents of the cecum tissue sample were emptied into a sterile microtube and transferred to the laboratory. The nine-step serial dilution of cecum contents samples were done with peptone water (Merck, 1.07228.0500), and a spreading of 0.1 ml of diluted homogeneous solution (cecum contents + peptone water) by sampler on the culture media was done. Microbial assessment was done according to the method of Hosseintabar *et al.*, (2013). Bacteria culture mediums include Rogosa agar (Merck, 1.05413.0500), E.M.B agar (Merck, 1.01347.0500), MacConkey agar (Merck, 1.10426.0500), Tos propionate agar (Merck, 100043) and Nutrient agar (Merck, 100043). Merck, 105450 were used for counting populations of *Lactobacillus*, *Escherichia coli*, coliform and Bifidobacterium and the total population of lactic acid bacteria. The temperature and time of placing the cultured media in the incubator were implemented according to the recommendations of Omidi *et al.*, (2020) and the unit of colony count was CFU per gram and, for ease of analysis, the data were expressed as logarithms of 10. In order to determine the profile of fatty acids, sampling of breast meat was done. Then, based on the protocol of Zaker-Esteghamati *et al.*, (2021) and Belali *et al.*, (2021), all the stages of sample preparation and determination of the value of fatty acids were performed in ViroMed laboratory (Rasht, Iran).

### Statistical analysis

The statistical model in this research was based on a completely random design, and the accuracy of assumptions and random errors were evaluated according to the normality of the residuals with the Shapiro-Wilk method and the homogeneity test of the variance of the experimental treatments with Bartlett's test using SAS 9.1 software, and the mean comparisons it was reported using Duncan's method.

### RESULTS AND DISCUSSION

The results of the incubation period are shown in Table 3. The hatchability percentage and the chicks' weight in the negative control group ( $T_1$ ) was the

highest ( $P < 0.05$ ). Selenium-injected groups ( $T_3$  and  $T_4$ ) had a higher percentage of hatchability compared to the positive control group ( $T_2$ ) ( $P < 0.05$ ).

Visual inspection and evaluations showed that the percentage of chickens suitable for sale (1<sup>st</sup> grade chicken) were in the first treatment, 93.75%, in the second treatment, 51.25%, in the third treatment, 55%, and in the fourth treatment, 74%, respectively (Figure 1). The percentage of grade 2 chicks (cull chick) was reported in the first treatment to be 2.5%, in the second treatment, 5%, in the third treatment, 11.25% and, in the fourth treatment, 5%. The number of unhatched eggs in the first, second, third and fourth treatments were counted as 3, 33, 28 and 17, respectively. On days 11 to 17, the number of feathers in the first, second, third and fourth treatments were 1, 27, 16 and 8, respectively. On the 18th to 19th days, the number of turns for the first, second, third and fourth treatments was observed as 1, 3, 3 and 8, respectively. The evaluation of the fault-diagnosed pa-

rameters showed that there was one pip egg only for the third treatment. 3, 2 and 3 cases of late rot infected eggs were observed in the second, third and fourth treatments, respectively. Exploded eggs, early rot, cracked eggs, and malformation embryos among case experimental treatments were not observed.

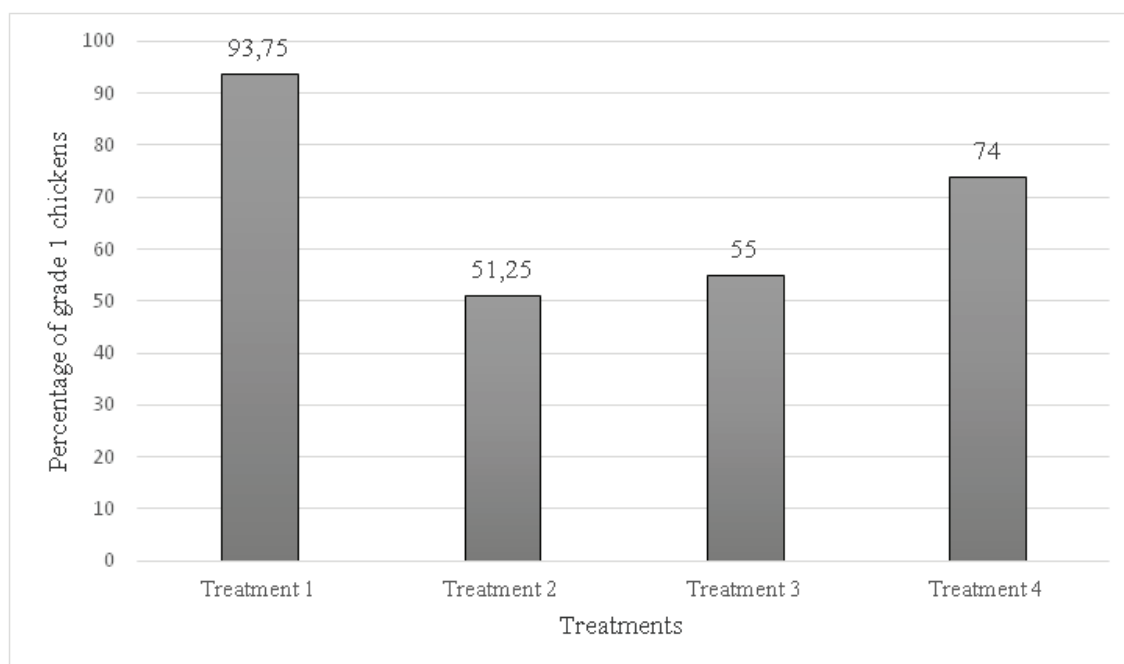
Hassan (2018), using nano selenium form, obtained the highest chick weight, and the hatchability percentage was similar to the control group without any negative effects, which was in conflict with the results of the present research. The reason for this contradiction can be attributed to the form of selenium used (nano vs organic) and the method of injection. On the other hand, El-Deep *et al.*, (2020) observed a decrease in the percentage of hatchability compared to the control group with the injection of nano selenium form (10, 20 and 30 micrograms), which is in agreement with the present research. Mohammad *et al.*, (2019) observed a decrease in the hatchability percentage and the chicks' weight, compared to the control group, by

**Table 3.** Evaluation of parametric traits related to hatching

Items	$T_1$	$T_2$	$T_3$	$T_4$	SEM	<i>P</i> -value
Hatchability (%)	96.25 <sup>a</sup>	58.75 <sup>c</sup>	66.25 <sup>bc</sup>	78.25 <sup>b</sup>	4.50	0.001
Chick weight (g)	46.63 <sup>a</sup>	44.31 <sup>b</sup>	45.50 <sup>b</sup>	44.58 <sup>b</sup>	0.40	0.001

$T_1$ : Negative control (Without injection),  $T_2$ : Positive control (Injection of 0.272 ml of normal saline solution),  $T_3$ : Positive control + 1.36 µg organic Se,  $T_4$ : Positive control + 4.8 µg organic Se.

<sup>a,b,c</sup> Means within each row with different superscripts differ significantly at  $P < 0.05$ .



**Figure 1.** First grade chickens for sale (%)

$T_1$ : Negative control (Without injection),  $T_2$ : Positive control (Injection of 0.272 ml of normal saline solution),  $T_3$ : Positive control + 1.36 µg organic Se,  $T_4$ : Positive control + 4.8 µg organic Se.

injecting nano selenium, which was in line with the results in the present study. A review of the scientific literature shows that the reason for the lack of effect and even a decrease in the characteristics of the hatchability percentage produced and the chickens weight, as well as the decrease in the percentage of grade 1 chickens and the numerical increase of the traits troubleshoot in the injection groups with different forms of selenium, can be due to the potential toxic properties of this element that occurs in the situation of excessive consumption (Latshaw *et al.*, 2004; Macalintal, 2012).

In Table 4, the performance results of the post-hatch period showed that *in ovo* injection had an effect on feed intake in the starter period ( $P < 0.05$ ). In the grower period, the positive control group (injection with saline), had the lowest feed intake ( $P < 0.05$ ). The FCR in the starter, grower, finisher and whole periods in the selenium injection groups were not significantly different from the control groups ( $P \geq 0.05$ ). Overall, no negative effects on production performance (feed intake, body weight and FCR) were observed during the whole period ( $P \geq 0.05$ ). Hassan (2018) observed an increase in daily weight and a decrease in FCR and feed intake in the groups injected with nano selenium, which was in conflict with the results of the present study. This researcher attributed this improvement in post-injection performance to improved gastrointestinal capacity. El-Deep *et al.*, (2020) also observed an increase in the FCR and weight loss after the injection

of nano selenium, which was not consistent with the results of the present study. It is possible that the form of selenium used and the levels used were the reasons for the difference between the results of this research and other researches, because in the present research, the use of organic form of selenium had no negative effect on production performance after injection and it was similar to the control group. However, the role of selenium in the regulation of enzyme and metabolic systems has been proven in several studies. In addition, due to the role of selenium in increasing the antioxidant capacity, improving the activity of intestinal microbiota and increasing the activity of digestion and absorption, respectively, which have been reported in other research, if the form and permitted levels of selenium are used in poultry nutrition, it can be expected performance improvement (Saleh and Ebeid, 2019). In fact, we would not expect a response to supplemental selenium if selenium in the diet is adequate.

Table 5 showed that the treatments injected into the *in ovo* had no negative effect on the carcass traits of broiler chickens at the end of the period ( $P \geq 0.05$ ). Table 6 shows the traits related to the intestines of broiler chickens, and the results indicated that *in ovo* injection had no negative effect on the experimental treatments ( $P \geq 0.05$ ). Mohammad *et al.*, (2019) and Hassan (2018) did not observe any negative effects on carcass traits and gastrointestinal tract with *in ovo* injection of nano selenium, which was in agreement with the present study. Sogunle *et al.*, (2018)

**Table 4.** The results of traits related to the performance of broiler chickens

Items	T <sub>1</sub>	T <sub>2</sub>	T <sub>3</sub>	T <sub>4</sub>	SEM	P-value
<b>Feed intake (g)</b>						
1-14d	524.25 <sup>ab</sup>	543.75 <sup>a</sup>	495.00 <sup>ab</sup>	480.75 <sup>b</sup>	17.29	0.02
15-28d	1655.97 <sup>a</sup>	1600.00 <sup>b</sup>	1683.00 <sup>a</sup>	1674.30 <sup>a</sup>	13.73	0.01
29-42d	2697.82	2606.50	2445.27	2808.25	303.00	0.85
1-42d	4878.10	4750.30	4623.30	4963.30	304.60	0.86
<b>Weight Gain (g)</b>						
1-14d	457.38	454.78	419.25	413.20	16.87	0.18
15-28d	1022.17	1033.25	1078.07	1081.90	17.54	0.70
29-42d	1379.67	1310.350	1219.55	1414.70	178.58	0.87
1-42d	2859.20	2798.40	2716.90	2909.80	179.00	0.88
<b>FCR (g/g)</b>						
1-14d	1.15	1.19	1.18	1.16	0.01	0.39
15-28d	1.62	1.55	1.56	1.54	0.02	0.16
29-42d	1.96	2.08	2.03	1.98	0.08	0.75
1-42d	1.71	1.69	1.70	1.71	0.008	0.85

T<sub>1</sub>: Negative control (Without injection), T<sub>2</sub>: Positive control (Injection of 0.272 ml of normal saline solution), T<sub>3</sub>: Positive control + 1.36 µg organic Se, T<sub>4</sub>: Positive control + 4.8 µg organic Se.

<sup>a,b</sup> Means within each row with different superscripts differ significantly at  $P < 0.05$ .



**Table 5.** The results of traits related to the characteristics carcasses of broiler chickens

Items	T <sub>1</sub>	T <sub>2</sub>	T <sub>3</sub>	T <sub>4</sub>	SEM	P-value
Live body weight (g)	3115.50	2809.00	2568.50	2876.00	231.84	0.45
Defeather body weight (g)	2766.50	2473.00	2338.00	2656.50	197.58	0.46
Full abdomen carcass weight (g)	2572.50	2191.50	2064.00	2347.00	184.71	0.29
Empty abdomen carcass weight (g)	2074.00	1884.00	17743.30	2015.30	152.94	0.53
Head weight (g)	60.65	58.75	53.05	57.15	5.47	0.79
Relative weight of head (%)	1.95	2.13	2.07	1.98	0.17	0.85
Breast weight (g)	844.00	763.00	725.50	869.50	70.37	0.46
Relative weight of breast (%)	27.05	27.46	28.18	30.22	1.15	0.27
Drumsticks (thighs) weight (g)	586.50	556.00	501.50	556.00	44.94	0.61
Relative weight of drumsticks (thighs) (%)	18.82	19.88	19.52	19.34	0.43	0.41
Wings weight (g)	181.00	178.50	162.00	179.50	12.74	0.69
Relative weight of wings (%)	5.81	6.49	6.33	6.22	0.27	0.36
Abdominal fat weight (g)	26.85	18.47	25.85	31.07	5.14	0.41
Relative weight of abdominal fat (%)	0.85	0.62	0.95	1.08	0.15	0.23
Pancreas weight (g)	4.72	4.73	5.00	5.70	0.39	0.30
Relative weight of pancreas (%)	0.15	0.18	0.19	0.20	0.02	0.34
Gizzard (ventriculus) weight (g)	29.55	24.70	24.75	26.77	2.58	0.52
Relative weight of gizzard (ventriculus) (%)	0.95	0.88	0.98	0.92	0.07	0.83
Heart weight (g)	15.10	13.05	14.05	13.77	1.72	0.86
Relative weight of heart (%)	0.48	0.49	0.55	0.48	0.06	0.73
Back thoracic vertebrae (notarium) weight (g)	339.00	280.50	276.50	287.00	23.29	0.25
Relative weight of back thoracic vertebrae (notarium) (%)	10.89	10.06	10.74	9.97	0.33	0.17
Neck weight (g)	102.00	96.50	101.50	107.50	10.45	0.90
Relative weight of neck (%)	3.26	3.48	3.93	3.75	0.23	0.24
Proventriculus weight (g)	9.87	11.60	8.7	17.85	2.29	0.06
Relative weight of proventriculus (%)	0.31	0.41	0.33	0.61	0.06	0.12
Crop weight (g)	9.25	5.95	6.82	7.57	1.01	0.19
Relative weight of crop (%)	0.30	0.22	0.27	0.26	0.03	0.42

T<sub>1</sub>: Negative control (Without injection), T<sub>2</sub>: Positive control (Injection of 0.272 ml of normal saline solution), T<sub>3</sub>: Positive control + 1.36 µg organic Se, T<sub>4</sub>: Positive control + 4.8 µg organic Se.

<sup>a,b,c</sup> Means within each row with different superscripts differ significantly at P<0.05.

encountered a decrease in heart weight by injecting the inorganic form of selenium, which was in conflict with the results of this study, but the other mentioned traits were did not present significant differences and agree with the present study. Uni *et al.*, (2003) believe that *in ovo* feeding of these elements can be effective in improving the growth of the gastrointestinal tract without negatively affecting the carcass characteristics. However, the form of selenium used and the amounts injected in the research are such that these traits were not negatively affected, and in order to create positive effectiveness, more studies should be done in the future.

Table 7 shows the results of blood biochemical and antioxidant parameters. TC was the lowest in T<sub>2</sub> (positive control) and the highest in T<sub>3</sub> (low selenium injection) (P<0.05). TG and VLDL increased in

the injected groups (P<0.05). LDL was significantly higher in the groups injected with selenium than in the group injected with saline (P<0.05). Atherogenic index (LDL/HDL) were the lowest for the second treatment (injection with saline) and the highest for the third treatment (injection with low selenium) (P<0.05). The content of TP, Alb and Glb was the lowest in the group injected with high selenium (T<sub>4</sub>) and the highest in the positive control group (injection with saline) (P<0.05). ALT and AST were the highest in the group injected with high selenium (T<sub>4</sub>) (P<0.05). ALP levels in all injected groups were higher than the non-injected group (P<0.05). Blood CK values also increased after injection, so this increase was noticeable with selenium injection (P<0.05).

Hassan (2018) did not observe any significant difference in some blood parameters of chickens after the

**Table 6.** The results of traits related to the gut morphometry of broiler chickens

Items	T <sub>1</sub>	T <sub>2</sub>	T <sub>3</sub>	T <sub>4</sub>	SEM	P-value
Duodenum weight (g)	12.77	12.15	11.55	11.55	1.00	0.79
Relative weight of duodenum (%)	0.41	0.43	0.45	0.40	0.02	0.47
Duodenum length (mm)	274.75	309.00	294.00	267.00	28.63	0.72
Duodenum width (mm)	6.78	8.37	8.15	8.51	0.96	0.57
Duodenum diameter (mm)	11.40	12.03	11.33	11.63	0.37	0.56
Jejunum weight (g)	28.87	25.60	24.72	27.90	3.20	0.77
Relative weight of jejunum (%)	0.92	0.91	0.97	0.96	0.08	0.95
Jejunum length (mm)	820.00	821.75	727.50	809.75	63.32	0.68
Jejunum width (mm)	9.01	8.20	8.20	8.05	0.49	0.53
Jejunum diameter (mm)	12.10	11.10	10.66	11.18	0.50	0.25
Ileum weight (g)	21.57	22.47	23.47	20.92	2.86	0.92
Relative weight of ileum (%)	0.69	0.80	0.90	0.73	0.07	0.23
Ileum length (mm)	892.80	853.30	815.25	821.50	42.60	0.57
Ileum width (mm)	7.21	7.47	7.83	8.18	1.47	0.40
Ileum diameter (mm)	10.36	11.08	9.46	10.19	10.36	0.51
Colon weight (g)	2.85	3.22	3.20	3.12	0.31	0.82
Relative weight of colon (%)	0.09	0.12	0.12	0.11	0.01	0.17
Colon length (mm)	81.25	87.50	79.75	86.00	8.62	0.90
Colon length (mm)	8.62	8.74	9.35	8.81	0.67	0.87
Colon diameter (mm)	11.07	11.78	11.51	11.00	0.34	0.35
Right cecum weight (g)	4.05	12.47	4.42	4.50	4.09	0.42
Relative weight of right cecum (%)	0.13	0.13	0.18	0.15	0.25	0.45
Right cecum length (mm)	197.75	196.25	186.25	187.50	10.26	0.80
Right cecum width (mm)	7.73	7.29	8.37	8.51	0.56	0.41
Right cecum diameter (mm)	9.37	9.55	10.68	10.30	1.02	0.78
Left cecum weight (g)	3.95	4.17	4.80	4.40	0.29	0.26
Relative weight of left cecum (%)	0.12	0.15	0.19	0.15	0.01	0.06
Left cecum length (mm)	198.75	205.00	197.75	194.50	10.62	0.91
Left cecum width (mm)	7.49	7.56	8.05	8.15	0.44	0.63
Left cecum diameter (mm)	10.47	9.35	9.76	10.73	0.61	0.39

T<sub>1</sub>: Negative control (Without injection), T<sub>2</sub>: Positive control (Injection of 0.272 ml of normal saline solution), T<sub>3</sub>: Positive control + 1.36 µg organic Se, T<sub>4</sub>: Positive control + 4.8 µg organic Se.

<sup>a,b,c</sup> Means within each row with different superscripts differ significantly at P<0.05.

injection of nano selenium form, and only the reduction of blood CK was noticeable. In the present study, the increase of CK and the decrease of blood proteins including TP, Alb and Glb after injection were in contrast with the results of Hassan's (2018) research. El-Deep *et al.*, (2020) encountered a significant increase in cholesterol and blood lipids after the injection of the nano selenium form and, on the other hand, there was a noticeable decrease in blood Glb. The results of these researchers were completely consistent with the results of the current research. It seems that selenium injection leads to an increase in blood lipids and cholesterol, and the necessity of supplementing diets with fat-reducing compounds are recommended.

In addition, El-Deep *et al.*, (2020) observed a de-

crease in liver enzymes after injection, which contradicted the results of this research. It seems that the nano form, unlike the organic form, is more effective in reducing liver enzymes. Mohammad *et al.*, (2019) did not observe any difference in blood proteins after the injection of nano selenium form, and on the other hand, TG decreased and HDL increased, which was in conflict with the results of the present study. Their nano form used is probably the reason for this difference in results. In general, the high levels of liver enzymes, ALP and CK blood in the groups injected with selenium in the present study show that the chickens were under stress and physiological damage after the injection and the need to check the injected amounts this form of selenium should be taken with more caution.

**Table 7.** The results of traits related to the biochemical parameters blood of broiler chickens

Items	T <sub>1</sub>	T <sub>2</sub>	T <sub>3</sub>	T <sub>4</sub>	SEM	P-value
Uric acid (mg/dl)	3.56	3.74	3.81	3.65	0.24	0.88
Total cholesterol (mg/dl)	116.75 <sup>ab</sup>	114.00 <sup>b</sup>	123.50 <sup>a</sup>	120.50 <sup>ab</sup>	2.30	0.04
Triglycerides (mg/dl)	50.92 <sup>c</sup>	58.32 <sup>b</sup>	79.37 <sup>a</sup>	60.65 <sup>b</sup>	1.89	0.001
VLDL (mg/dl)	10.17 <sup>c</sup>	11.65 <sup>b</sup>	15.87 <sup>a</sup>	12.12 <sup>b</sup>	0.37	0.001
HDL (mg/dl)	52.90	55.92	53.00	56.85	1.98	0.41
LDL (mg/dl)	48.90 <sup>a</sup>	44.10 <sup>b</sup>	49.95 <sup>a</sup>	46.65 <sup>ab</sup>	1.42	0.05
LDL/HDL	0.93 <sup>a</sup>	0.79 <sup>b</sup>	0.94 <sup>a</sup>	0.82 <sup>ab</sup>	0.04	0.06
Total protein (g/dl)	2.81 <sup>b</sup>	3.68 <sup>a</sup>	3.22 <sup>ab</sup>	2.76 <sup>b</sup>	0.17	0.001
Albumin (g/dl)	1.28 <sup>bc</sup>	1.61 <sup>a</sup>	1.45 <sup>ab</sup>	1.21 <sup>c</sup>	0.06	0.001
Glb (g/dl)	1.52 <sup>b</sup>	2.07 <sup>a</sup>	1.76 <sup>ab</sup>	1.55 <sup>b</sup>	0.11	0.01
S.G.O.T (AST) (U/L)	326.25 <sup>b</sup>	372.50 <sup>b</sup>	345.25 <sup>b</sup>	565.75 <sup>a</sup>	22.42	0.001
S.G.P.T (ALT) (U/L)	69.25 <sup>b</sup>	74.75 <sup>b</sup>	70.50 <sup>b</sup>	87.00 <sup>a</sup>	2.82	0.001
ALP (U/L)	9035 <sup>a</sup>	7710 <sup>b</sup>	6200 <sup>c</sup>	5745 <sup>c</sup>	303.04	0.001
CK (U/L)	16973 <sup>c</sup>	26613 <sup>b</sup>	20750 <sup>b</sup>	23950 <sup>a</sup>	1002.78	0.001
HGB (g/dL)	17.32	17.77	17.14	18.09	0.34	0.23
RBC (10*6/μL)	2536750	2579500	2489750	2623250	52204.18	0.35
MCH (pg)	68.20	68.92	68.87	68.95	0.52	0.71
MCV (fL)	143.25	144.75	145.50	145.75	0.75	0.13
MCHC (g/dL)	47.40	47.39	47.30	47.31	0.21	0.97

T<sub>1</sub>: Negative control (Without injection), T<sub>2</sub>: Positive control (Injection of 0.272 ml of normal saline solution), T<sub>3</sub>: Positive control + 1.36 μg organic Se, T<sub>4</sub>: Positive control + 4.8 μg organic Se.

VLDL: very-low-density lipoprotein, HDL: high-density lipoprotein, LDL: low-density lipoprotein, Glb: globulin, S.G.O.T: serum glutamic-oxaloacetic transaminase, AST: aspartate amino transferase, S.G.P.T: serum glutamic pyruvic transaminase, ALT: alanine amino transferase, ALP: alkaline phosphatase, CK: creatine kinase, HGB: hemoglobin, RBC: red blood cell, MCH: mean corpuscular of HGB, MCV: mean corpuscular volume, MCHC: mean corpuscular HGB concentration.

<sup>a,b,c</sup> Means within each row with different superscripts differ significantly at P<0.05.

Table 8 shows the results related to immune system traits in broiler chickens. The number of leukocytes in experimental treatments after *in ovo* injection was significantly decreased (P<0.05). In addition, IBV was the lowest in the fourth treatment (high selenium) and the highest in the group without injection (P<0.05). Hassan (2018) with the *in ovo* injection feeding of nano selenium, at seven days of age, faced a significant increase in the parameters related to the immune system, including white blood cell, lymphocytes (LY), MO, and basophils, but at 35 days of age, all the injected chickens were similar to the control group and had a normal and acceptable condition in terms of immune system. This researcher believed that in the form of nano selenium, selenium atoms are free and can bind to immune proteins and destroy free radicals and also increase the expression of cellular immune genes. The results of the current research were in conflict with the report of Hassan (2018) and the reason for the decrease in safety after selenium injection can be attributed to the difference in the form used. Sogunle *et al.*, (2018) did not observe a significant difference on humoral immunity by injecting the inorganic form of selenium, which was in agreement

with the present study.

It seems that the organic and inorganic forms of selenium have a lesser role in strengthening and stimulating immunity, and considering the potential of selenium in stimulating immunity and eliminating free radicals, the necessity of further studies in other doses is recommended. Mohammad *et al.*, (2019) also concluded that the injection of nano selenium form leads to the improvement of the immune system, which was in conflicts with the result of the present research and is probably due to the difference in the form of selenium used. If the used form of selenium can show its effects on immunity in *in ovo* feeding, improvement of the immune status can be expected, because selenium element is necessary for all parts of the body's immune system (Surai and Dvorska, 2002). On the other hand, it has been found that feeding selenium leads to an increase in the mRNA expression of cytokine genes (interleukin 2 and 6) and by balancing the antioxidant status and immunization, it can have a positive effect on the animal's health (Cai *et al.*, 2012). Khazraie *et al.*, (2015) believe that feeding organic form of selenium is effective in increasing the concentration of B

**Table 8.** The results of traits related to the immune system of broiler chickens

Items	T <sub>1</sub>	T <sub>2</sub>	T <sub>3</sub>	T <sub>4</sub>	SEM	P-value
LE (μ/L)	16400 <sup>a</sup>	111950 <sup>b</sup>	11950 <sup>b</sup>	13200 <sup>b</sup>	684.04	0.001
HE (%)	45.75	41.25	40.25	43.25	45.75	0.20
LY (%)	51.20	55.25	55.25	52.25	1.87	0.34
MO (%)	2.75	3.00	4.00	3.75	0.44	0.20
Antibody titer against Influenza within 21 days (lg2)	5.50	6.250	5.75	5.75	0.26	0.27
Antibody titer against Influenza within 28 days (lg2)	5.00	5.75	5.25	5.50	0.23	0.16
Antibody titer against first injection of Newcastle within 7 days (lg2)	3.25	3.50	4.50	4.50	0.76	0.54
Antibody titer against second injection of Newcastle within 7 days (lg2)	5.25	5.25	5.00	5.50	0.31	0.72
Antibody titer against first injection of IBV within 7 days (lg2)	815.00	576.00	651.00	429.50	105.21	0.12
Antibody titer against second injection of IBV within 7 days (lg2)	9.65	8.77	9.32	8.73	0.38	0.30
Thymus weight (g)	4.47	5.42	3.87	4.62	1.68	0.82
Relative weight of thymus (%)	0.14	0.18	0.14	0.16	0.04	0.88
Liver weight (g)	68.57	61.20	56.50	63.50	5.13	0.44
Relative weight of liver (%)	2.21	2.18	2.25	2.20	0.16	0.99
Spleen weight (g)	2.70	3.77	2.57	3.50	0.53	0.34
Relative weight of spleen (%)	0.08	0.13	0.10	0.12	0.01	0.21
Bursa of fabricius weight (g)	3.40	2.77	4.22	2.50	0.79	0.46
Relative weight of bursa of fabricius (%)	0.11	0.09	0.16	0.08	0.02	0.25

T<sub>1</sub>: Negative control (Without injection), T<sub>2</sub>: Positive control (Injection of 0.272 ml of normal saline solution), T<sub>3</sub>: Positive control + 1.36 μg organic Se, T<sub>4</sub>: Positive control + 4.8 μg organic Se.

LE: leukocytes, HE: heterophile, LY: lymphocyte, MO: monocytes

<sup>a,b</sup> Means within each row with different superscripts differ significantly at P<0.05.

and T LYs and can improve phagocytic activity by increasing the population of leukocytes.

Table 9 shows the results related to the population of cecum microflora, which indicates the state of intestinal microbiota in broilers. *Lactobacillus* population increased in the group injected with high selenium (T<sub>4</sub>) and was similar to the non-injected group (P<0.05). Bifidobacterium and lactic acid population after *in ovo* injection faced a significant decrease in T3 group (P<0.05). Coliforms and *Escherichia coli* were significantly reduced after selenium injection (P<0.05). The reports related to the feeding of selenium *in ovo* egg on the intestinal microflora are limited, but the effects of feeding on the intestinal microflora indicate the positive potential effectiveness of selenium. Bami *et al.*, (2022) reported that broilers fed with selenium increased lactic acid bacteria and decreased coliform population. Khan *et al.*, (2021) found an increase in *Lactobacillus* and a decrease in *Escherichia coli* after feeding nano selenium with chitosan in broilers. In general, the potential of sele-

nium in improving the state of intestinal microflora after feeding in different forms has been confirmed in many research studies, and the results of the present research were completely consistent with the results of the aforementioned researchers.

As Kasaikina *et al.*, (2011) stated, gastrointestinal tract microbiota, as their hosts, are sensitive to micro minerals. Some microbiota requires trace elements such as selenium for their optimal metabolic functions. Therefore, changes in selenium content of chick body can modulate the composition in gastrointestinal tract microbiota. They revealed that Se contents can affect both the composition of the existing microbiota and establishment of gut microbiota. It is due to the use of selenium by some microbiota or selenium toxicity in some other microbiota (Kasaikina *et al.*, 2011).

Table 10 shows the analysis of broiler meat fatty acids. One sample from each treatment was used to evaluate the fatty acid profile, so mean comparisons and statistical analysis were not performed. In

**Table 9.** The results of traits related to the caecum microflora of broiler chickens (CFU/g)

Items	T <sub>1</sub>	T <sub>2</sub>	T <sub>3</sub>	T <sub>4</sub>	SEM	P-value
Lactobacillus	8402.00 <sup>a</sup>	7569.75 <sup>c</sup>	6106.50 <sup>d</sup>	9666.00 <sup>a</sup>	38.80	0.001
Bifidobacterium	151371.50 <sup>a</sup>	114355.50 <sup>b</sup>	14287.50 <sup>d</sup>	63371.50 <sup>c</sup>	37.53	0.001
Lactic acid bacteria	7494.50 <sup>a</sup>	6583.00 <sup>b</sup>	4270.50 <sup>c</sup>	4358.50 <sup>c</sup>	43.66	0.001
Coliform	98344.75 <sup>b</sup>	102903.25 <sup>a</sup>	18141.75 <sup>d</sup>	85923.50 <sup>c</sup>	41.39	0.001
Escherichia coli	143192.25 <sup>a</sup>	103514.50 <sup>b</sup>	63408.75 <sup>d</sup>	97820.50 <sup>c</sup>	35.19	0.001

T<sub>1</sub>: Negative control (Without injection), T<sub>2</sub>: Positive control (Injection of 0.272 ml of normal saline solution), T<sub>3</sub>: Positive control + 1.36 µg organic Se, T<sub>4</sub>: Positive control + 4.8 µg organic Se.

<sup>a,b,c,d</sup> Means within each row with different superscripts differ significantly at P<0.05.

**Table 10.** The results of traits related to the meat fatty acids of broiler chickens

Items	T <sub>1</sub>	T <sub>2</sub>	T <sub>3</sub>	T <sub>4</sub>
Myristic acid (C14:0)	0.23	0.51	0.44	0.39
Pentadecanoic acid (C15:0)	0.17	0.11	0.03	0.09
Palmitic acid (C16:0)	18.72	21.58	21.86	20.66
Heptadecanoic acid (C17:0)	0.19	0.11	0.14	0.06
Stearic acid (C18:0)	5.86	7.35	7.66	6.78
Arachidic acid (C20:0)	0.11	0.23	0.17	0.18
Heneicosanoic acid (C21:0)	0.50	0.19	0.18	0.28
Behenic acid or Docosanoic acid (C22:0)	0.34	0.17	0.19	0.26
Total SFA	26.79	30.24	30.64	28.68
Myristoleic acid (C14:1)	0.50	0.21	0.14	0.12
Pentadecylic acid (C15:1)	6.72	1.82	2.30	2.03
Palmitoleic acid (C16:1)	1.60	2.32	2.51	2.42
Heptadecenoic acid (C17:1)	0.07	0.10	0.06	0.08
Oleic acid (C18:1, n-9)	33.44	39.19	37.76	38.03
Elaidic acid (C18:1t)	0.08	0.02	0.06	0.04
Gondoic acid or Eicosenoic acids (C20:1)	0.15	0.22	0.23	0.28
Erucic acid or Docosenoic acid (C22:1)	0.32	0.12	0.11	0.07
Total MUFA	43.10	43.42	42.36	42.50
Linoleic acid (C18:2, n-6)	18.43	23.70	23.74	25.94
Trans octadecadienoic acid (C18:2t)	0.10	0.03	0.01	0.05
Total PUFA, n-6	21.18	23.73	23.74	25.99
Dihomo-gamma linoleic acid (C20:3)	0.80	0.35	0.30	0.86
Total PUFA, n-3	0.80	0.35	0.30	0.86
Total PUFA, n-6/total PUFA, n-3	28.04	56.91	76.63	30.22
UFA	65.83	67.48	66.40	69.35
UFA/SFA	2.46	2.23	2.17	2.42

T<sub>1</sub>: Negative control (Without injection), T<sub>2</sub>: Positive control (Injection of 0.272 ml of normal saline solution), T<sub>3</sub>: Positive control + 1.36 µg organic Se, T<sub>4</sub>: Positive control + 4.8 µg organic Se.

SFA: saturated fatty acids, MUFA: monounsaturated fatty acid, PUFA: polyunsaturated fatty acids, UFA: unsaturated acid

general, it can be said that the groups injected with selenium compared to the non-injected group in the ratio of unsaturated to saturated fatty acids (UFA/SFA) and the ratio of omega-6 to omega-3 ( $\omega$ -6/ $\omega$ -3) appeared to be increased. Del Puerto *et al.*, (2017) found a decrease in the content of C:14 and C:16 in the breast muscle after feeding chickens with selenium, while the content of C18:1 increased. In addition, omega-3 levels increased in alpha linolenic acid (ALA) and eicosapentaenoic acid (EPA) forms, but

dicosapentaenoic (DPA) and dicosahexaenoic acid (DHA) forms did not increase. The ratio of omega-6 to omega-3 and the ratio of polyunsaturated to saturated fatty acids (PUFA/SFA) were unchanged. Kralik *et al.*, (2013) increased omega-3 levels and decreased monounsaturated fatty acid (MUFA) levels and decreased omega-6 to omega-3 ratio by feeding organic selenium. In general, it seems that the use of selenium can affect the quality and fatty acids of meat, which requires more research, especially in the case of *in*



*ovo* feeding.

Our results revealed that *in ovo* selenium application significantly increased the certain stress indicators including AST, ALT, VLDL, CK and TG. It clearly indicates that additional selenium with *in ovo* route might worsen antioxidant balance in the body. The lack of beneficial responses to *in ovo* selenium with regard to immunity indices and growth performance traits including meat yield are mostly attributed to the form of the used selenium. However, this contradicts the hypothesis of the current study, that selenium in the organic form is expected to outperform to that inorganic form. So, *in ovo* injection with selenium can play major role in improvement of stress indicators. As Habibian *et al.*, (2015) stated the changed redox balance led to the impaired membrane integrity in broilers under heat stress. Dietary selenium supplementation decreases malondialdehyde in broiler and quail serum. Moreover, selenium supplementation increases glutathione peroxidase activity in the broiler breast we exposed under heat stress. Some reports like Rao *et al.*, (2013) revealed selenium supplements can led to enhanced glutathione peroxidase activity. Selenium as cofactor of iodothyronine deiodinase and thioredoxin reductase enzymes have major role in free radicals' suppression and NADPH-dependent lipid peroxidation inhibition (Sun *et al.*, 1999) and also lipid peroxidation prevention via glutathione depletion inhibiting (Özgül and Nazıroğlu, 2012).

## CONCLUSIONS

In conclusion, the results of the present study showed that after the injection of organic selenium with *in ovo* technology, in all the experimental groups, the hatchability percentage and the chicks' weight were lower compared to the groups without injection. According to the evaluation of the troubleshooting traits and the state of the immune system, the results showed that after the injection of selenium in organic form, the birds were under physiological stress as indicated by a significant increase in cholesterol, atherogenic index, levels of liver enzymes, ALP and CK in the blood of birds after organic selenium injection. The birds, despite being under stress, were healthy the whole period and no negative effects were observed on the characteristics of the carcass and the gastrointestinal tract. However, the intestinal microbiota of the birds was improved significantly after the injection of organic selenium. Considering the positive effects of selenium and the parallel toxicity of this element, it is necessary to carry out more studies in different doses and forms of selenium in order to improve the health parameters of the herd and to resolve the nutritional concerns of selenium.

## CONFLICT OF INTEREST

The authors declare that they have no conflict of interest.

## REFERENCES

- Abdul-Majeed, A. F., and Abdul-Rahman, S. Y. (2022). Impact of vitamin E and selenium treatment *in ovo* and after hatching of broiler. *Iraqi Journal of Agricultural Sciences*, 53(4), 810-818.
- Ahmadi, M., Ahmadian, A., and Seidavi, A. R. (2018). Effect of different levels of nano-selenium on performance, blood parameters, immunity and carcass characteristics of broiler chickens. *Poultry Science Journal*, 6(1), 99-108.
- Ahmadi, M., Ahmadian, A., Poorhasemi, M., Makovicky, P., and Seidavi, A. (2019). Nano-Selenium affects on duodenum, jejunum, ileum and colon characteristics in chicks: An animal model. *International Journal of Nano Dimension*, 10(2), 225-229.
- Ahmadi, M., Poorhasemi, M., Seidavi, A., Hatzigiannakis, E., and Milis, C. (2020). An optimum level of nano-selenium supplementation of a broiler diet according to the performance, economical parameters, plasma constituents and immunity. *Journal of Elementology*, 25(3).
- Albarak, S. M. (2021). Supplementation with the methanolic extract of *Lyciumshawii* or *Rhanteriumepapposum* enhances immune responses of broilers. *Adv. Anim. Vet. Sci.*, 9(11), 1816-1828.
- Araújo, I. C. S., and Lara, L. J. C. (2023). Perspectives on vitamin E, canthaxanthin and selenium to chick embryo antioxidant protection. *World's Poultry Science Journal*, 79(2), 265-283.
- Arthur, J. R., McKenzie, R. C., and Beckett, G. J. (2003). Selenium in the immune system. *The Journal of nutrition*, 133(5), 1457S-1459S.
- Baghban-Kanani, P., Hosseintabar-Ghasemabad, B., Azimi-Youvalari, S., Seidavi, A., Ragni, M., Laudadio, V., and Tufarelli, V. (2019). Effects of using *Artemisia annua* leaves, probiotic blend, and organic acids on performance, egg quality, blood biochemistry, and antioxidant status of laying hens. *The Journal of Poultry Science*, 56(2), 120-127.
- Bahadori, Z., Esmailzadeh, L., Karimi-Torshizi, M. A., Seidavi, A., Olivares, J., Rojas, S., and López, S. (2017). The effect of earthworm (*Eisenia foetida*) meal with vermi-humus on growth performance, hematology, immunity, intestinal microbiota, carcass characteristics, and meat quality of broiler chickens. *Livestock Science*, 202, 74-81.
- Balogh, K., Weber, M., Erdélyi, M. And Mézes, M., (2004). Effect of inorganic and organic selenium overdose on glutathione redox system in broiler chicken. In 3. *BOKU-Symposium TIERERNÄHRUNG Fütterungsstrategien und Produktqualität*.
- Bami, M. K., Afsharmanesh, M., Espahbodi, M., and Esmailzadeh, E. (2022). Effects of dietary nano-selenium supplementation on broiler chicken performance, meat selenium content, intestinal microflora, intestinal morphology, and immune response. *Journal of Trace Elements in Medicine and Biology*, 69, 126897.
- Belali, M., Seidavi, A., and Bouyeh, M. (2021). Effects of short-term and combined use of thyme powder and aqueous extract on growth performance, carcass and organ characteristics, blood constituents, enzymes, immunity, intestinal morphology and fatty acid profile of breast meat in broilers. *Large Animal Review*, 27(4), 223-232.
- Cai, S. J., Wu, C. X., Gong, L. M., Song, T., Wu, H., and Zhang, L. Y. (2012). Effects of nano-selenium on performance, meat quality, immune function, oxidation resistance, and tissue selenium content in broilers. *Poultry Science*, 91(10), 2532-2539.
- Del Puerto, M., Cabrera, M. C., and Saadoun, A. (2017). A note on fatty acids profile of meat from broiler chickens supplemented with inorganic or organic selenium. *International Journal of Food Science*, 2017.
- El-Deep, M. H., Amber, K. A., Elgendy, S., Dawood, M. A., and Zidan, A. (2020). *In ovo* injection of nano-selenium spheres mitigates the hatchability, histopathology image and immune response of hatched chicks. *Journal of Animal Physiology and Animal Nutrition*, 104(5), 1392-1400.
- Ferket, P. R. (2011, May). *In ovo* feeding and the promise of perinatal nutrition. In *Proceedings of Alltech International Nutrition Symposium, Lexington, Kentucky, United States of America*.
- Feshangchi, M., Baghban-Kanani, P., Kashefi-Motlagh, B., Adib, F., Azimi-Youvalari, S., Hosseintabar-Ghasemabad, B., Slozhenkina, M., Gorlov, I., Zangeronimo, M.G., Swelum, A.A., Seidavi, A., Khan, R.U., Ragni, M., Laudadio, V., and Tufarelli, V. (2022). Milk Thistle (*Silybum marianum*), Marine Algae (*Spirulina platensis*) and Toxin Binder Powders in the Diets of Broiler Chickens Exposed to Aflatoxin-B1: Growth Performance, Humoral Immune Response and Cecal Microbiota. *Agriculture*, 12(6), 805.
- Habibian, M., Sadeghi, G., Ghazi, S., & Moeini, M. M. (2015). Selenium as a feed supplement for heat-stressed poultry: a review. *Biological Trace Element Research*, 165, 183-193.
- Hassan, A. M. (2018). Effect of *in ovo* injection with nano-selenium or nano-zinc on post-hatch growth performance and physiological traits of broiler chicks. *International Journal of Environment, Agriculture and Biotechnology*, 3(2), 239074.
- Heindl, J., Ledvinka, Z., Tůmová, E., and Zita, L. (2010). The importance, utilization and sources of selenium for poultry: a review. *Scientia Agriculturae Bohemica*, 41(1), 55-64.
- Hosseintabar, B., Dadashbeiki, M., Bouyeh, M., and Seidavi, A. (2013). Is the amount of L-Carnitine and methionine-lysine effect on the microbial flora of broiler cecum. *J. Pure Appl. Micro*, 8(1), 353-360.
- Hosseintabar, B., Dadashbeiki, M., Bouyeh, M., Seidavi, A., van den Hoven, R., and Gamboa, S. (2015). Effect of different levels of L-carnitine and lysine-methionine on broiler blood parameters. *Revista MVZ Córdoba*, 20(3), 4698-4708.
- Hosseintabar-Ghasemabad, B., Janmohammadi, H., Hosseinkhani, A., Amirdahri, S., Baghban-Kanani, P., Gorlov, I. F., Slozhenkina, M.I., Mosolov, A.A., Ramirez, L.S., and Seidavi, A. (2022). Effects of Using Processed Amaranth Grain with and without Enzyme on Performance, Egg Quality, Antioxidant Status and Lipid Profile of Blood and Yolk Cholesterol in Laying Hens. *Animals*, 12(22), 3123.
- Huang, Y. L., Lu, L., Luo, X. G., and Liu, B. (2007). An optimal dietary zinc level of broiler chicks fed a corn-soybean meal diet. *Poultry Science*, 86(12), 2582-2589.
- Ibrahim, N. S., Sabic, E. M., Wakwak, M. M., El-Wardany, I. E., El-Hommosany, Y. M., and El-Deen Mohammad, N. (2020). *In-ovo* and dietary supplementation of selenium nano-particles influence physiological responses, immunological status and performance of broiler chicks. *Journal of Animal and Feed Sciences*, 29(1): 46-58.
- Janmohammadi, H., Hosseintabar-Ghasemabad, B., Oliyai, M., Alijani, S., Gorlov, I. F., Slozhenkina, M. I., Mosolov, A.A., Ramirez, L.S., Seidavi, A., Laudadio, V., Tufarelli, V., and Ragni, M. (2023). Effect of Dietary Amaranth (*Amaranthus hybridus chlorostachys*) Supplemented with Enzyme Blend on Egg Quality, Serum Biochemistry and Antioxidant Status in Laying Hens. *Antioxidants*, 12(2), 456.
- Khalil-Khalili, A. A., Zhandi, M., Zaghari, M., Mehrabani-Yeganeh, H., Yousefi, A. R., and Tavakoli-Alamooti, M. (2021). The effect of dietary organic selenium on reproductive performance of broiler breeder roosters under dexamethasone induced stress. *Theriogenology*, 161, 16-25.
- Khan, I., Zaneb, H., Masood, S., Ashraf, S., Rehman, H. F., Tahir, S. K., and Shah, M. (2021). Supplementation of Selenium Nanoparticles-Loaded Chitosan Improves Production Performance, Intestinal Morphology, and Gut Microflora in Broiler Chickens. *The Journal of Poultry Science*, 59(3), 272-281.
- Khazraie, S., and Ghazanfarpoor, R. (2015). Effect of nano-selenium particles and sodium selenite on performance, glutathione peroxidase and superoxide dismutase of quail under heat stress. *Int. J. Rev. Life Sci.*, 5(1), 875-882.
- Kim, H. J., and Kang, H. K. (2022). Effects of *in ovo* Injection of Zinc or Diet Supplementation of Zinc on Performance, Serum Biochemical Profiles, and Meat Quality in Broilers. *Animals*, 12(5), 630.
- Kralik, Z., Kralik, G., Biazik, E., Straková, E., and Suchý, P. (2013). Effects of organic selenium in broiler feed on the content of selenium and fatty acid profile in lipids of thigh muscle tissue. *Acta Veterinaria Brno*, 82(3), 277-282.
- Kumar, D., Gautam AK, Sinha MK. (2018). Histopathological alterations

- of selenium toxicity induced in broiler (Birds). *Indian Journal of Animal Research*, 52(4): 599-604. DOI: 10.18805/ijar.v0iOF.7259
- Latshaw, J. D., Morishita, T. Y., Sarver, C. F., and Thilsted, J. (2004). Selenium toxicity in breeding ring-necked pheasants (*Phasianus colchicus*). *Avian diseases*, 48(4), 935-939
- Lee, S. H., Lillehoj, H. S., Jang, S. I., Jeong, M. S., Xu, S. Z., Kim, J. B., and Bravo, D. M. (2014). Effects of *in ovo* injection with selenium on immune and antioxidant responses during experimental necrotic enteritis in broiler chickens. *Poultry science*, 93(5), 1113-1121
- Lerner, K. G., Glick, B., and McDuffie, F. C. (1971). Role of the bursa of Fabricius in IgG and IgM production in the chicken: evidence for the role of a non-bursal site in the development of humoral immunity. *The Journal of Immunology*, 107(2), 493-503
- Li, M., and Zhao, C. (2009). Study on Tibetan Chicken embryonic adaptability to chronic hypoxia by revealing differential gene expression in heart tissue. *Science in China Series C: Life Sciences*, 52(3), 284-295
- Li, X.L., He, W.L., Yang, M.L., Yan, Y.M., Xue, Y.H. and Zhao, S.T., 2017. Effect of dietary supplementation of *Ligustrum lucidum* on performance, egg quality and blood biochemical parameters of Hy-Line Brown hens during the late laying period. *animal*, 11(11), pp.1899-1904.
- Ludwiczek, S., Theurl, I., Artner-Dworzak, E., Chorney, M., and Weiss, G. (2004). Duodenal HFE expression and hepcidin levels determine body iron homeostasis: modulation by genetic diversity and dietary iron availability. *Journal of Molecular Medicine*, 82(6), 373-382
- Macalintal, L. M. (2012). In ovo selenium (Se) injection of incubating chicken eggs: effects on embryo viability, tissue Se concentration, lipid peroxidation, immune response and post hatch development. Theses and Dissertations--Animal and Food Sciences. 4. [https://uknowledge.uky.edu/animalsci\\_etds/4](https://uknowledge.uky.edu/animalsci_etds/4)
- Mcquoid, D. (2000). Operation of multiple-stage and single-stage incubation systems. *World Poultry*, 18(2)
- Mehmandoei, A., Shams Shargh, M., and Hasani, S. (2017). Effect of vitamin E and organic selenium in the form of *in ovo* injection on performance, livability and meat quality of broiler chickens. *Animal science*, 30(116), 3-116
- Mohammad, N. G., El-wardany, I. E., El-homosany, Y. M., Wakwak, M. M., Sabic, E. M., and Ibrahim, N. S. (2019). In-ovo inoculation of selenium nanoparticles improves productive performance, blood biochemical profile, antioxidant status and immune response of hatched chicks. *Arab Universities Journal of Agricultural Sciences*, 27(1), 887-897
- Nassif, F., Elsebai, A., Elghalid, O., and Hassan, M. I. (2023). Impact of *in ovo* injection with selenium nanoparticles and or nicotinamide on some post-hatch traits of broiler chicks. *Egyptian Poultry Science Journal*, 43(2), 239-258.
- Nosrati, M., Javandel, F., Camacho, L. M., Khuro, A. M. E. R., Cipriano, M., Seidavi, A., and Salem, A. Z. M. (2017). The effects of antibiotic, probiotic, organic acid, vitamin C, and Echinacea purpurea extract on performance, carcass characteristics, blood chemistry, microbiota, and immunity of broiler chickens. *Journal of Applied Poultry Research*, 26(2), 295-306
- Omidi, S., Ebrahimi, M., Janmohammadi, H., Moghaddam, G., Rajabi, Z., and Hosseintabar-Ghasemabad, B. (2020). The impact of *in ovo* injection of L-arginine on hatchability, immune system and caecum microflora of broiler chickens. *Journal of Animal Physiology and Animal Nutrition*, 104(1), 178-185
- Özgül, C., & Nazıroğlu, M. (2012). TRPM2 channel protective properties of N-acetylcysteine on cytosolic glutathione depletion dependent oxidative stress and Ca<sup>2+</sup> influx in rat dorsal root ganglion. *Physiology and Behavior*, 106(2), 122-128.
- Pappas, A. C., Acamovic, T., Sparks, N. H. C., Surai, P. F., and McDevitt, R. M. (2005). Effects of supplementing broiler breeder diets with organic selenium and polyunsaturated fatty acids on egg quality during storage. *Poultry Science*, 84(6), 865-874.
- Rajashree, K., Muthukumar, T., and Karthikeyan, N. (2014). Comparative study of the effects of organic selenium on hen performance and productivity of broiler breeders. *British Poultry Science*, 55(3), 367-374.
- Rao, S. V. R., Prakash, B., Raju, M. V. L. N., Panda, A. K., Poonam, S., & Murthy, O. K. (2013). Effect of supplementing organic selenium on performance, carcass traits, oxidative parameters and immune responses in commercial broiler chickens. *Asian-Australasian journal of animal sciences*, 26(2), 247.
- Sabzian-Melei, R., Zare-Shahneh, A., Zhandi, M., Yousefi, A. R., and Rafieian-Naeini, H. R. (2022). Effects of dietary supplementation of different sources and levels of selenium on the semen quality and reproductive performance in aged broiler breeder roosters. *Poultry Science*, 101(10), 101908.
- Safaei-Chereh, A., Rasouli, B., Alaba, P. A., Seidavi, A., Hernández, S. R., and Salem, A. Z. (2020). Effect of dietary Foeniculum vulgare Mill. extract on growth performance, blood metabolites, immunity and ileal microflora in male broilers. *Agroforestry Systems*, 94(4), 1269-1278
- Sahr, W. B., Odutayo, O. J., Sogunle, O. M., Ayo-Ajasa, O. Y., Fafiolu, A. O., and Fatunmbi, F. A. (2020). Effects of *in ovo* injection of inorganic salts of Zn, Cu and Mn on hatching traits and post-hatch performance of broiler chickens in the tropics. *Nigerian Journal of Animal Science*, 22(1), 113-125
- Saleh, A. A., and Ebeid, T. A. (2019). Feeding sodium selenite and nano-selenium stimulates growth and oxidation resistance in broilers. *South African Journal of Animal Science*, 49(1), 176-183
- Sandholm, M. (1993). Acute and chronic selenium toxicity. *Norwegian Journal of Agricultural Science*. 11: 37-50.
- Seidavi, A., Asadpour, L., Dadashbeiki, M., and Payan-Carreira, R. (2014). Effects of dietary fish oil and green tea powder supplementation on broiler chickens' immunity. *Acta Scientiae Veterinariae*, 42(1), 1-13
- Shabani, R., Fakhraci, J., Yarahmadi, H. M., and Seidavi, A. (2019). Effect of different sources of selenium on performance and characteristics of immune system of broiler chickens. *Revista Brasileira de Zootecnia*, 48
- Shabani, S., Seidavi, A., Asadpour, L., and Corazzin, M. (2015). Effects of physical form of diet and intensity and duration of feed restriction on the growth performance, blood variables, microbial flora, immunity, and carcass and organ characteristics of broiler chickens. *Livestock Science*, 180, 150-157
- Shokraneh, M., Sadeghi, A. A., Mousavi, S. N., Esmailkhanian, S., and Chamani, M. (2020). Effects of *in ovo* injection of nano-selenium and nano-zinc oxide and high eggshell temperature during late incubation on antioxidant activity, thyroid and glucocorticoid hormones and some blood metabolites in broiler hatchlings. *Acta Scientiarum. Animal Sciences*, 42
- Sigolo, S., Khazaei, R., Seidavi, A., Ayasan, T., Gallo, A., and Prandini, A. (2019). Effects of supra-nutritional levels of vitamin E and vitamin C on growth performance and blood parameters of Japanese quails. *Italian Journal of Animal Science*, 18(1), 140-146
- Sogunle, O. M., Elangovan, A. V., David, C. G., Ghosh, J., and Awachat, V. B. (2018). Response of broiler chicken to *in ovo* administration of inorganic salts of zinc, selenium and copper or their combination. *Slovak Journal of Animal Science*, 51(1), 8-19
- Sun, Q. A., Wu, Y., Zappacosta, F., Jeang, K. T., Lee, B. J., Hatfield, D. L., & Gladyshev, V. N. (1999). Redox regulation of cell signaling by selenocysteine in mammalian thioredoxin reductases. *Journal of Biological Chemistry*, 274(35), 24522-24530.
- Surai, P. F., and Dvorska, J. E. (2002). Effect of selenium and vitamin E content of the diet on lipid peroxidation in breast muscle tissue of broiler hens during storage. In *Proceedings of the Australian Poultry Science Symposium* (Vol. 14, pp. 187-192).
- Tamrakar, S., Shonam, M. Mondal, R. C. Ghosh, C. S. Mishra, N. Sahu, P. Thakur, and A. Jain. (2014). Pathomorphological alterations of sub-acute selenium toxicity in broilers. *Indian Journal of Veterinary Pathology*, 38(2): 103-106. DOI : 10.5958/0973-970X.2014.01148
- Tufarelli, V., Baghban-Kanani, P., Azimi-Youvalari, S., Hosseintabar-Ghasemabad, B., Slozhenkina, M., Gorlov, I., Viktoronova, F.M., Seidavi, A., and Laudadio, V. (2021). Effect of dietary flaxseed meal supplemented with dried tomato and grape pomace on performance traits and antioxidant status of laying hens. *Animal Biotechnology*, 33(7), 1525-1532.
- Tullett, S. (2009). Ross tech: investigating hatchery practice. *Aviagen, Ross Tech (October)*, 14-15
- Uni, Z., and Ferket, P. R. (2003). *U.S. Patent No. 6,592,878*. Washington, DC: U.S. Patent and Trademark Office

- Uni, Z., Smirnov, A., and Sklan, D. (2003). Pre-and posthatch development of goblet cells in the broiler small intestine: effect of delayed access to feed. *Poultry Science*, 82(2), 320-327.]
- Wang, Y., Zhan, X., Yuan, D., Zhang, X., and Wu, R. (2011). Influence of dietary selenomethionine supplementation on performance and selenium status of broiler breeders and their subsequent progeny. *Biological Trace Element Research*, 143, 1497-1507.
- Williams, C. J., and Hopkins, B. A. (2011). Field evaluation of the accuracy of vaccine deposition by two different commercially available *in ovo* injection systems. *Poultry science*, 90(1), 223-226]
- Zaker-Esteghamati, H., Seidavi, A., and Bouyeh, M. (2021). The effects of *Cynara scolymus* and *Silybum marianum* on growth, carcass and organ characteristics, immunity, blood constituents, liver enzymes, jejunum morphology, and fatty acid profile of breast meat in broilers. *Food Science and Nutrition*, 9(12), 6692-6706.
- Zhao, M., Li, J., Shi, Q., Shan, H., Liu, L., Geng, T., Yu, L. and Gong, D., (2023). the effects of *in ovo* feeding of selenized glucose on selenium concentration and antioxidant capacity of breast muscle in neonatal broilers. *Biological Trace Element Research*, 201, 1-10.