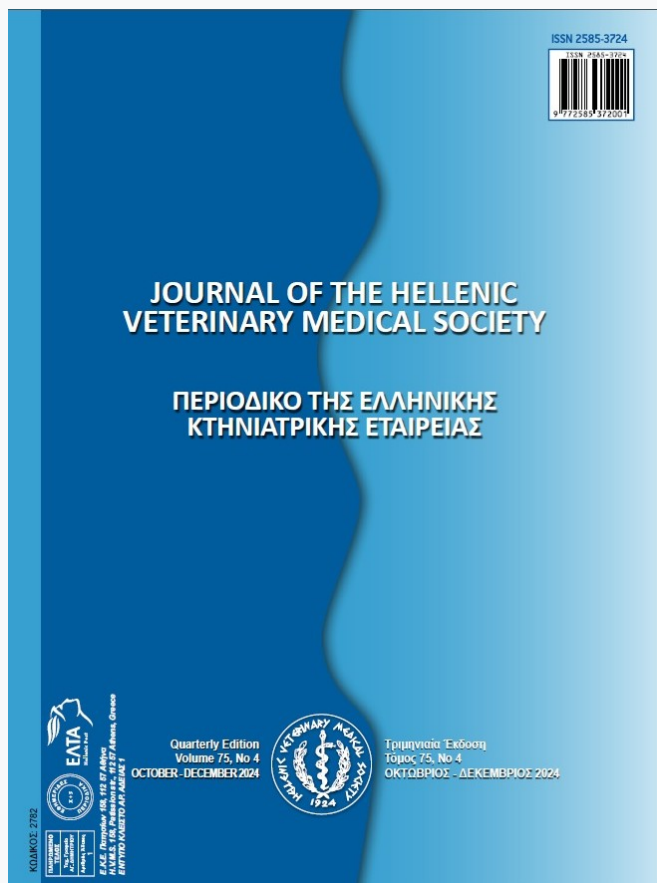


Journal of the Hellenic Veterinary Medical Society

Vol 75, No 4 (2024)



Evaluation of Eosinophilic Myositis in a Bull: Histopathological and Immunohistochemical Findings

A Milletsever, O Ozmen

doi: [10.12681/jhvms.35052](https://doi.org/10.12681/jhvms.35052)

Copyright © 2025, A Milletsever, O Ozmen



This work is licensed under a [Creative Commons Attribution-NonCommercial 4.0](https://creativecommons.org/licenses/by-nc/4.0/).

To cite this article:

Milletsever, A., & Ozmen, O. (2025). Evaluation of Eosinophilic Myositis in a Bull: Histopathological and Immunohistochemical Findings. *Journal of the Hellenic Veterinary Medical Society*, 75(4), 8467–8472. <https://doi.org/10.12681/jhvms.35052>

Evaluation of Eosinophilic Myositis in a Bull: Histopathological and Immunohistochemical Findings

A. Milletsever^{id}, O. Ozmen^{id}

Burdur Mehmet Akif Ersoy University, Faculty of Veterinary Medicine, Department of Pathology, Burdur, Turkey

ABSTRACT: In this case report, histopathological and immunohistochemical findings of eosinophilic myositis (EM) observed in the gluteal muscles of a 15-month-old Holstein bull are presented. Macroscopically, distinct gray-greenish demarcated foci with a diameter of 2-5 mm and a length of 5-10 cm with multifocal distribution were observed. Microscopic examinations revealed an inflammatory reaction with the predominance of eosinophil granulocytes accompanied by mononuclear cell infiltrations among myofibrils and increased connective tissue. Luna staining confirmed the presence of intracytoplasmic red granules in eosinophil leukocytes. Numerous remnants of *Sarcocystis* tissue cysts were found within the myofibers. Immunohistochemical examinations demonstrated increased expression of TNF- α , MMP-2, MMP-7, Cas-3, and IL-3. The findings of this study indicated the significant roles of cytokines, matrix metalloproteinases, and apoptosis in the development of eosinophilic myositis.

Keywords: bovine; eosinophilic myositis; immunohistochemistry; pathogenesis; pathology

Corresponding Author:

Adem Milletsever, Burdur Mehmet Akif Ersoy University, Faculty of Veterinary Medicine, Department of Pathology, Burdur, Turkey
E-mail address: adem.milletsever@gmail.com

Date of initial submission: 25-7-2023

Date of acceptance: 7-8-2024

INTRODUCTION

According to Selva-O'Callaghan et al. (2014), eosinophilic myositis (EM) is a subclinical, chronic disease characterized by the infiltration of eosinophil granulocytes in the heart and skeletal muscles. While it is more commonly observed in animals, it can also affect humans (Selva-O'Callaghan et al., 2014). The disease can occur in cattle and sheep of all ages. It cannot be detected in live animals and is typically observed incidentally observed after slaughter. It leads to a decline in meat quality and causes meat destruction, resulting in significant economic losses in the meat industry (Dini et al., 2023; Dubey and Rosenthal, 2023; Cooper and Valentine, 2016).

The prevalence of bovine eosinophilic myositis (BEM) varies between countries. In some cases, carcass damage associated with high BEM in the Western United States can reach up to 5% (Vangeel et al., 2012).

The cause of the disease is unknown, but some researchers have found *Sarcocystis hominis* and *Toxoplasma gondii* in the affected skeletal muscles, suggesting a link between eosinophilic inflammation and either dead or degenerating parasites (Dini et al., 2023). Similar lesions induced by Trematode and Echinococcus pathogens have also been reported (Sierra et al., 2008). Cattle experimentally infected with *Trichinella* spp. larvae can develop EM lesions, although spontaneous EM cases are unlikely (Smith et al., 1991). Eosinophil leukocyte infiltration has also been associated with traumatic muscle rupture (Fermon et al., 2022). BEM disease is associated with *Sarcocystis cruzi*-specific IgG and IgE antibody reactions, and it is believed that this pathogen forms cysts in the muscles (Rhee et al., 2008).

Macroscopically, skeletal muscles, including the heart, exhibit focal, gray to green, and occasionally brown-green muscular lesions. Foci in lesioned muscles can vary in diameter from 2-4 mm to 4-10 cm and can be clearly differentiated from intact muscles (Cooper and Valentine, 2016). Histologically, EM is primarily characterized by myofiber degeneration and extensive eosinophil leukocyte infiltration (Vangeel et al., 2012; Cooper and Valentine, 2016).

Apoptosis is a regulated program of cell death for the elimination of damaged cells. During apoptosis, the activation of caspase enzymes is observed, with caspase-3 (Cas-3) being an apoptosis marker. Additionally, Cas-3 is effective in the apoptosis of eosin-

ophils (Lee et al., 2017). Another protein that affects eosinophils is IL-3, which is one of the eosinophil hematopoietins. IL-3 ensures the activation and survival of eosinophils and regulates their activities in parasitic infections and allergies (Simon and Simon, 2007; Fermon et al., 2022). The inflammatory cytokine TNF-alpha promotes the migration and activation of eosinophils to the site of inflammation (Kankaanranta et al., 2014). MMPs play important roles in tissue remodeling by facilitating the breakdown and reformation of the extracellular matrix. They also participate in inflammatory processes (Mittal et al., 2016). MMPs also contribute to tissue inflammation and the regeneration of muscle fibers (Kumar et al., 2022). One of the MMPs, MMP-2, plays an active role in tissue remodeling. Additionally, MMP-2 promotes vascular permeability to allow the passage of leukocytes from blood vessels to injury sites, thus influencing inflammation (Fingleton, 2017).

The aim of this study is to histopathologically evaluate the case of eosinophilic myositis in a bull and evaluate the effect of TNF- α , MMP-2, MMP-7, Cas-3, and IL-3 expressions on the progression of the disease by immunohistochemistry.

CASE HISTORY

During the slaughter of a 15-month-old Holstein bull, multiple prominent lesions with a gray-green color and a well-demarcated multifocal distribution, ranging in size from 2-5 mm in diameter and 5-10 cm in length, were detected in the gluteal muscles. Samples were taken from the lesions and presented to the Department of Pathology. The muscle samples were fixed in 10% neutral buffered formalin solution for two days and then underwent a routine tissue processing procedure and embedded in paraffin. Sections of 5 μ m thickness were obtained from the paraffin blocks and stained using Hematoxylin-Eosin (HE) and Luna's method for eosinophil granulocytes (Luna, 1968).

For immunohistochemical analysis, sections were taken on poly-L-lysine slides stained according to the manufacturers' instructions with primary antibodies TNF- α [(sc-52746) Santa Cruz, Texas, USA], MMP-2 [(ab86607) Abcam, Cambridge, UK], MMP-7 [(ab302893) Abcam, Cambridge, UK], Cas-3 [(sc-56053) Santa Cruz, Texas, USA], and IL-3 [(ab167159) Abcam, Cambridge, UK] using the streptavidin-biotin peroxidase (ABP) method. All primary antibodies were used at a dilution of 1/100.

The Mouse and Rabbit Specific HRP/DAB Detection Kit-Micropolymer (ab236466) (Abcam, Cambridge, UK) IHC kit was used as the secondary kit. For microphotography the Database Manual CellSens Life Science Imaging Software System (Olympus Corporation) was utilized.

Macroscopic examination revealed gray-green, multifocal lesions in the gluteal muscle groups with well-delimited areas. These lesions ranged in length from 5 to 10 cm and in diameter from 2 to 5 mm. Although some lesions were shaped irregularly, others were parallel to the muscle fibers.

Histopathological examinations revealed inflammatory cell infiltrations, consisting predominantly of eosinophil leukocytes with a small number of lymphocytes, plasma cells, and macrophages, between and inside the myofibrils. Degeneration, atrophy, and

necrosis were observed in the myofibrils (Figure 1A). Fibrous tissue proliferation was detected. Sarcocystis tissue cyst remnants were found between the myofibrils and within the muscle cells (Figure 1B). Red-colored eosinophil leukocyte granules were observed in the tissue sections stained with Luna's method (Figure 1 C-D).

At the immunohistochemical examination, intense cytoplasmic expressions of MMP-2 (Figure 2A), MMP-7 (Figure 2B), and TNF-alpha (Figure 2C) were noted in muscle cells. MMP-2 expression in endothelial cells was noted (Figure 2A). Strong expressions of TNF-alpha antibodies were observed in eosinophil leukocytes (Figure 2C). Remarkable cytoplasmic expressions of IL-3 were detected in macrophage cells (Figure 2D). Cytoplasmic expressions of cas-3 were mainly observed in endothelial cells (Figure 2E).

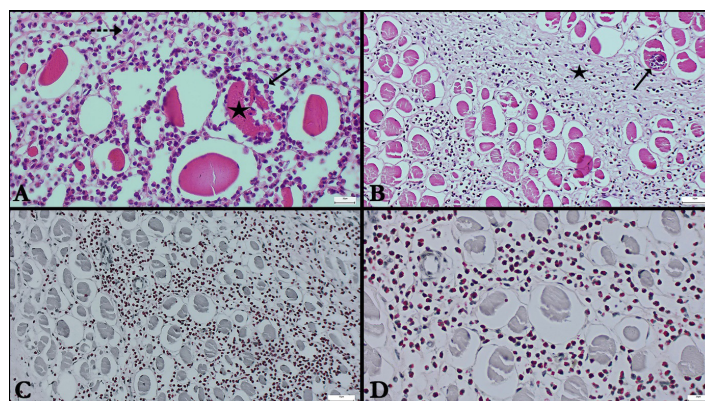


Figure 1. Microscopic view of the EM case. (A) Myofiber degeneration (star), eosinophil leukocyte infiltration (arrow) and plasma cell (dashed arrow), HE, Bar: 20 µm. (B) *Sarcocystis* tissue cyst (arrow) and fibrous tissue increase (star) in myofiber, HE, Bar: 50 µm. (C) Red-colored eosinophil leukocyte granules infiltrating between myofibers, Luna method, Bar: 50 µm. (D) Higher magnification of red-colored granules of eosinophil leukocyte cells, Luna method, Bar: 20 µm.

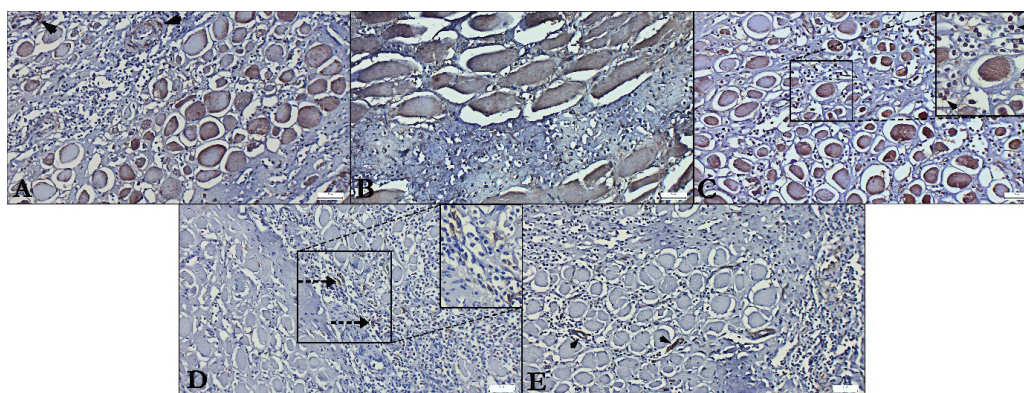


Figure 2. Immunohistochemical staining of the EM case. (A) Intense cytoplasmic expressions of MMP-2 in muscle cells and endothelial cells (arrowheads), streptavidin-biotin peroxidase method; Bars: 50 µm. (B) Intense cytoplasmic expressions of MMP-7 were noted in muscle cells, streptavidin-biotin peroxidase method; Bars: 50 µm. (C) Myofibers with markedly expressed TNF- α ; the top-right insert shows prominent expressions of TNF- α antibodies in eosinophil leukocytes (arrowheads), streptavidin-biotin peroxidase method, Bars: 50 µm. (D) IL-3 expression in macrophage cells (dashed arrow) and (E) cas-3 expressions in endothelial cells (arrowheads), streptavidin-biotin peroxidase method, Bars: 50 µm.

DISCUSSION

Eosinophilic myositis was first reported by Kuscher (Kuscher, 1940). In clinically healthy animals, the predominant inflammatory cell reaction characterized by an accumulation of eosinophil leukocytes leads to focal, localized, subclinical green muscle lesions (Cooper and Valentine, 2016). In slaughtered animals, the muscle lesions are typically identified as widespread, multifocal, gray-white lesions in the skeletal muscles. Lesions cannot be diagnosed in live animals. Smooth muscles do not develop lesions. This condition is important for meat inspection as it causes carcass losses and economic damage (Cooper and Valentine, 2016; Vangeel et al., 2012).

Lesions can occur in all muscles, including the myocardium. They differ noticeably from healthy muscles and can vary in size from 1-3 mm to 4-6 cm. Skeletal and cardiac muscles can be affected simultaneously (Vangeel et al., 2012; Do et al., 2008; Cooper and Valentine, 2016). At the gross analysis of gluteal muscle samples in this case presentation, numerous distinct areas of gray-green lesions ranging from 2 mm to 10 cm were observed and findings consistent with the literature findings.

EM is characterized by the degeneration of myofibrils and the extensive infiltration of eosinophil leukocytes. In the histopathological examinations of this case, infiltration of a small number of lymphocytes, plasma cells, and macrophages, along with intense eosinophilic leukocyte infiltration, was observed among the muscle cells. Additionally, it was noted that eosinophilic leukocytes were present around and inside the muscle cells. Red-colored granules of eosinophilic leukocytes were detected in the preparations stained with Luna's method. Although the findings in this case are consistent with previous studies, the intracellular eosinophil leukocyte infiltrations suggest a response of the muscle cells to a specific agent (Vangeel et al., 2012; Cooper and Valentine, 2016).

In eosinophilic myositis, the formation of adipose tissue and acute and chronic fibrous reactions occur in place of myofibrils. Eosinophil infiltrations lead to the disappearance of trabecular structures in the muscles (Atasever, 1998; Cooper and Valentine, 2016). Most studies demonstrate that granulomatous lesions contain degenerated myofibers with eosinophil leukocytes at their centers (Selva-O'Callaghan et al., 2014; Cooper and Valentine, 2016). In our histopathological examination, widespread infiltrations were observed in the muscle tissue along with necrotic changes in

myocytes, as well as degeneration, atrophy, necrosis, and an increase in fibrous connective tissue in the muscles.

Eosinophilic myositis is typically detected during routine necropsy examinations or postmortem evaluations after slaughter. The exact cause of EM is uncertain because *Sarcocystis*, the protozoan associated with the condition, usually elicits minimal tissue reaction in the intermediate host, although *Sarcocystis* tissue cysts are frequently observed in lesioned areas (El-Beshbishi et al., 2012; Vangeel et al., 2012; Dini et al., 2023). It is believed that this protozoan, which has a two-host life cycle, plays a role in the development of eosinophilic myositis (Vangeel et al., 2012). The involvement of *Sarcocystis* in EM is still debatable since eosinophilic myositis is significantly less common in cattle compared to the *Sarcocystis*, whose prevalence is close to 100%. Despite the presence of *Sarcocystis* tissue cyst residues between myofibrils and within muscle cells in the histopathological examinations, the presence of intracellular eosinophilic leukocyte infiltrates suggests the existence of a mechanism that triggers this event in both muscle tissue and muscle cells in the formation of EM.

Apoptosis is a type of programmed cell death that is regulated by a family of cysteine proteases called caspases. Cas-3, one of these proteases, plays an important role in apoptosis (Lee et al., 2017). Furthermore, MMP-2 depletion in mice reduced endothelial dysfunction, vascular remodeling, oxidative stress, and inflammation caused by angiotensin II, as shown by Barhoumi and colleagues' study (Barhoumi et al., 2017). In this case, immunohistochemistry analysis showed increased expression of Cas-3 in vascular endothelial cells. Cas-3 expression in vascular endothelium may be linked to MMP-2-induced endothelial dysfunction.

In both physiological and pathological conditions, matrix metalloproteinases (MMPs) alter the extracellular matrix. The primary function of MMPs is to process and break down the extracellular matrix, glycoproteins, growth factors, membrane receptors, matrix proteins, and cytokines (Kumar et al., 2022). Along with inducing apoptotic pathways and oxidative stress, it is believed that intense MMP-2 expressions in EM contribute to the pathogenesis of the disease.

Following skeletal muscle damage, the regulation of MMPs is influenced by various factors depending on the nature and severity of the damage (Chen

and Li, 2009). Increased expression of MMP-2, one of these MMPs, is associated with the regeneration, maturation, and muscle regeneration of formed myotubes (Chen and Li, 2009; Alameddine, 2012). MMPs significantly contribute to processes where degradation and reorganization of the extracellular matrix are required. The expression of MMP-2 observed in EM indicates ECM degradation and regulation. Additionally, it is believed that these expressions promote the maturation and regeneration of myotubes, thus facilitating muscle regeneration.

Occludin, a transmembrane protein of endothelial connections, is cleaved by MMP-2 (Chen et al., 2021). Furthermore, MMP-7 cleaves vascular endothelial (VE)-cadherin, the main component of endothelial junctions, leading to increased vascular permeability (Nissinen and Kähär, 2014). This explains the intense infiltration of leukocytes and mononuclear cells in EM associated with the expressions of MMP-2 and MMP-7, as in this case.

A cytokine known as tumor necrosis factor (TNF)- α is involved in inflammation, cytotoxicity, and immune regulation (van Loo and Bertrand, 2023). TNF- α is expressed by various cell types, particularly macrophages, lymphocytes, and skeletal muscle cells, and it is associated with both local and systemic inflammation. Injured muscle fibers have elevated expression levels of TNF- α (Collins and Grounds, 2001). TNF- α also causes eosinophils to become active (Kankaanranta et al., 2014). Tissue damage re-

sults from the release of pro-inflammatory cytokines, reactive oxygen species, and cationic proteins such as eosinophil cationic protein and major basic proteins by activated eosinophils (Gigon et al., 2023). It is believed that the presence of intense eosinophil leukocyte infiltrations in damaged myocytes is associated with the ability of TNF- α to prolong the lifespan of eosinophil cells and increase their numbers in the tissues, thus contributing to tissue inflammation.

Interleukin-3 (IL-3) is a hematopoietic cytokine produced by T cells, monocytes, and activated macrophages (Esnault and Kelly, 2016). The survival of eosinophils depends on IL-3, which also makes them hypodense (Gigon et al., 2023). Eosinophils stimulate T cells and induce MHC-II expression in allergy and parasitic diseases due to the action of IL-3 (McBrien and Menzies-Gow, 2017). Additionally, activated eosinophils can produce IL-3 (Fermon et al., 2022). In this case, IL-3 expression was observed in macrophages, which is consistent with the literature.

In conclusion, immunohistochemistry analyses demonstrated elevated expressions of TNF- α , MMP-2, MMP-7, Cas-3, and IL-3 in eosinophilic myositis. It has been suggested that apoptosis, matrix metalloproteinases, and inflammatory cytokines may affect the progression of cattle eosinophilic myositis.

CONFLICT OF INTERESTS

The authors declare they have no conflicts of interest.

REFERENCES

- Alameddine HS (2012) Matrix metalloproteinases in skeletal muscles: Friends or foes?. *Neurobiol Dis* 48(3):508-18.
- Atasever A (1998) Eosinophilic myositis in a Cattle. *Tr. J. of Veterinary and Animal Sciences* 22(1):93-96.
- Chen W, Zhou Z, Chen D, Li Y, Zhang Q, Su J (2021) Bone regeneration using MMP-cleavable peptides-based hydrogels. *Gels* 7(4):199.
- Chen X, Li Y (2009) Role of matrix metalloproteinases in skeletal muscle: migration, differentiation, regeneration and fibrosis. *Cell Adh Migr* 3(4):337-41.
- Collins RA, Grounds MD (2001) The role of tumor necrosis factor- α (TNF- α) in skeletal muscle regeneration: studies in TNF- α (-/-) and TNF- α (-/-)/LT- α (-/-) mice. *J Histochem Cytochem* 49(8):989-1001.
- Cooper BJ, Valentine BA (2016) Muscle and tendon. In: Jubb, Kennedy, and Palmer's Pathology of Domestic Animals. Vol. 1, 6th ed, Saunders Ltd, Philadelphia: pp 236-237.
- Dini FM, Caffara M, Jacinto JG, Benazzi C, Gentile A, Galuppi R (2023) A case of bovine eosinophilic myositis (BEM) associated with co-infection by *Sarcocystis hominis* and *Toxoplasma gondii*. *Animals (Basel)* 13(2):311.
- Do SH, Jeong da H, Chung JY, Park JK, Yang HJ, Yuan DW, Jeong KS (2008) Eosinophilic myositis in slaughtered Korean native cattle. *J Vet Sci* 9(4):425-427.
- Dubey JP, Rosenthal BM (2023) Bovine sarcocystosis: *Sarcocystis* species, diagnosis, prevalence, economic and public health considerations, and association of *Sarcocystis* species with eosinophilic myositis in cattle. *Int J Parasitol* 53(9):463-475.
- El-Beshbishi SN, Ahmed NN, Mostafa SH, El-Ganainy GA (2012) Parasitic infections and myositis. *Parasitol Res* 110:1-18.
- Esnault S, Kelly ES, (2016). Essential mechanisms of differential activation of eosinophils by IL-3 compared to GM-CSF and IL-5. *Crit Rev Immunol* 36(5):429-444.
- Fermon C, Authier FJ, Gallay L (2022) Idiopathic eosinophilic myositis: a systematic literature review. *Neuromuscul Disord* 32(2):116-124.
- Fingleton B (2017) Matrix metalloproteinases as regulators of inflammatory processes. *Biochim Biophys Acta Mol Cell Res* 1864(11):2036-2042.
- Gigon L, Fettelet T, Yousefi S, Simon D, Simon HU (2023) Eosinophils from A to Z. *Allergy* 78(7):1810-1846.
- Kankaanranta H, Ilmarinen P, Zhang X, Adcock IM, Lahti A, Barnes PJ, Giermbycz MA, Lindsay MA, Moilanen E (2014) Tumour necrosis factor- α regulates human eosinophil apoptosis via ligation of TNF-receptor 1 and balance between NF- κ B and AP-1. *PloS One*

- 9(2):e90298.
- Kumar L, Bisen M, Khan A, Kumar P, Kumar P, Patel SKS (2022) Role of matrix metalloproteinases in musculoskeletal diseases. *Biomedicine* 10(10):2477.
- Kuscher A (1940) Eosinophile Muskelentzündung beim Hund. *Wien. Tierärztl. Mschr* 27:pp 177-186.
- Lee HJ, Lee EK, Seo YE, Shin YH, Kim HS, Chun YH, Yoon JS, Kim HH, Han MY, Kim CK, Kim KE, Koh YY, Kim JT (2017) Roles of Bcl-2 and caspase-9 and -3 in CD30-induced human eosinophil apoptosis. *J Microbiol Immunol Infect* 50(2):145-152.
- Luna LG. *Manual of histologic staining methods of the armed forces institute of pathology*. 3rd Ed.. McBrien CN, Menzies-Gow A (2017) The biology of eosinophils and their role in asthma. *Front Med (Lausanne)* 4:93.
- Mittal R, Patel AP, Debs LH, Nguyen D, Patel K, Grati MH, Mittal J, Yan D, Chapagain P, Liu XZ (2016) Intricate functions of matrix metalloproteinases in physiological and pathological conditions. *J Cell Physiol* 231(12):2599-2621.
- New York: McGraw-Hill; 1968. p. 111-112.
- Nissinen L, Kähäri VM (2014) Matrix metalloproteinases in inflammation. *Biochim Biophys Acta* 1840(8):2571-2580.
- Rhee SH, Yu IJ, Kim JH, Kwon JK, Park J, You MJ, Lee JW, Park HJ, Chekarova I, Camer GA, Lim CW, Kim B (2008) Idiopathic eosinophilic myositis in Korean native cattle (*Bos taurus coreanae*). *Korean J Vet Res* (2008) 48(2):187-190.
- Selva-O'Callaghan A, Trallero-Araguás E, Grau JM (2014) Eosinophilic myositis: an updated review. *Autoimmun Rev* 13(4-5):375-8.
- Sierra MA, Gomez MA, Navarro JA, Bernabe A (2008) Bovine eosinophilic myositis caused by trematodes. *Korean J Vet Res* 48(2):187-190.
- Simon D, Simon HU (2007) Eosinophilic disorders. *J Allergy Clin Immunol* 119(6):1291-1300.
- Smith HJ, Snowdon KE, Finley GG (1991) Eosinophilic myositis in Canadian cattle. *Can J Vet Res* 55(1):94-5.
- van Loo G, Bertrand MJ (2023) Death by TNF: a road to inflammation. *Nat Rev Immunol* 23(5):289-303.
- Vangeel L, Houf K, Geldhof P, Nollet H, Vercruysse J, Ducatelle R, Chiers K (2012) Intramuscular inoculation of cattle with *Sarcocystis* antigen results in focal eosinophilic myositis. *Vet Parasitol* 183(3-4):224-30.