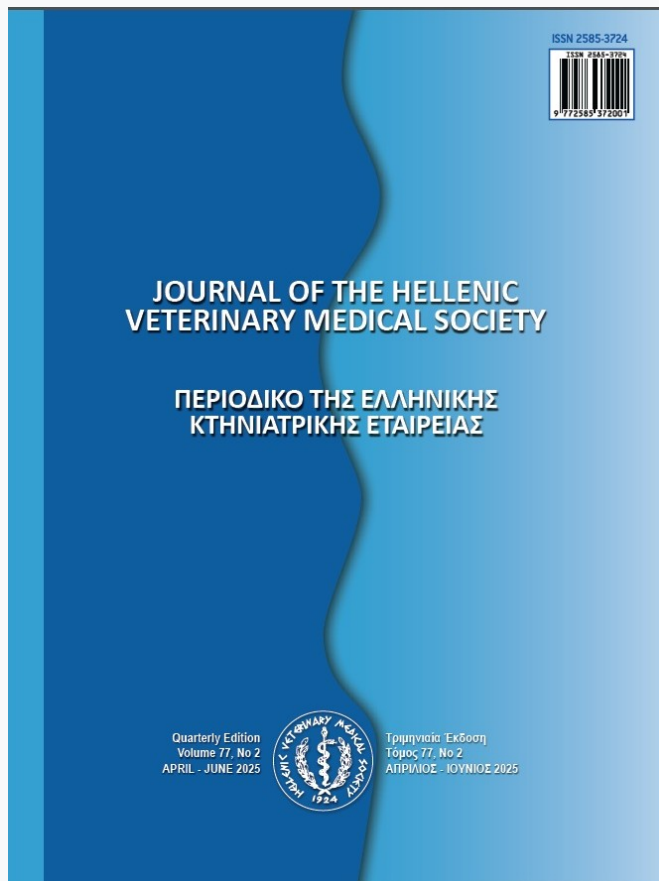


## Journal of the Hellenic Veterinary Medical Society

Vol 76, No 2 (2025)



### Ocular Ailments Doctrine (Ophthalmology) in Fish: Exophthalmia Scenario as Forzando and Eyes - Brain Connection

*N Filik*

doi: [10.12681/jhvms.36285](https://doi.org/10.12681/jhvms.36285)

Copyright © 2025, N Filik



This work is licensed under a [Creative Commons Attribution-NonCommercial 4.0](https://creativecommons.org/licenses/by-nc/4.0/).

#### To cite this article:

Filik, N. (2025). Ocular Ailments Doctrine (Ophthalmology) in Fish: Exophthalmia Scenario as Forzando and Eyes - Brain Connection. *Journal of the Hellenic Veterinary Medical Society*, 76(2), 8945–8954.  
<https://doi.org/10.12681/jhvms.36285>

## Ocular Ailments Doctrine (Ophthalmology) in Fish: Exophthalmia Scenario as Forzando and Eyes - Brain Connection

N. Filik<sup>1\*</sup>

<sup>1\*</sup>Suleyman Demirel University, 32260, Isparta, Turkey

**ABSTRACT:** Ocular ailments are leading cause of fish vision loss in worldwide. Eye is an island of soft tissue surrounded by neural crest derived tissues of craniofacial skeleton. Eye tissue is extraordinary organ in terms of its development. The visual pathway consist of retina, optic nerves, optic chiasm, optic tracts, lateral geniculate bodies, and visual cortex. The pathway is, effectively, part of central nervous system. Events such as oedema, bleeding, aneurysm (vessel ballooning) that will develop behind the eyeballs may also cause exophthalmia, that is, protrusion of the eyeballs. A decrease in strength or paralysis that will develop in the muscles that move the eye can also be counted among the factors that will cause Exophthalmia ailment is manifestations of an abnormal protrusion of ocular globe beyond confines of bony orbit. Eye disease primarily affects the cornea. Some eye diseases seen in fish are included in the literature as Eyes inflammatories, Corneal injury, Oedema of retina, Ocular trauma, Optic neuritis, Periocular cellulitis/dermatitis, Panophthalmitis, Endophthalmitis, Papillitis, Septicaemia, Keratitis, Cataract, Uveitis, Choroiditis, Scleritis, Periocular steatitis, Optic neuritis, Encephalitis, Extraocular myositis, Keratoconjunctivitis, Parasitic infestation. Whichever the case, the injury likely triggered an immune system response. This case is what causes oedema. Sick fish other ailments experience exophthalmia. For example, visceral organs failure, kidney failure, tummy cavity disease, or vital dangerous metabolic diseases can cause fluid buildup. Ailment can lead to dry or gritty eyes, redness, puffy eyes inflammation and swelling vision problems. It is a review that presents a discussion on Ophthalmology and Neuro-Ophthalmology, which deals with common diseases of the eye and nervous system and harmonious movement of eyes. It is an article presentation that explains eye diseases, emphasizing symptom of exophthalmia, a short case report, explaining doctrine of eye diseases and cerebral cortex, visual pathways from optic nerve to visual cortex where vision occurs. This review manuscript aim is to talk about doctrine of ophthalmology, to explain situations in which eye, structures around eye and visual system are affected by a series of clinical events, to present a case report of exophthalmia eye ailments, to emphasize relationship between eye and brain, to briefly explain diagnosis and treatment of such conditions together with ophthalmology, evisceration, microsurgery and to present disease setting in a polemically way.

**Keyword:** Ocular ailments doctrine; eyes ailments; eye surgery; exophthalmia ailment; eyes - brain connection; ophthalmology.

*Correspondence author:*

N. Filik,  
Suleyman Demirel University, 32260, Isparta, Turkey  
E-mail address: nurdanfilik@sdu.edu.tr

*Date of initial submission:* 19-12-2023

*Date of acceptance:* 9-12-2024

## INTRODUCTION

Ocular issues in fish are very common and can occur for several reasons (Kim et al., 2024). Although orbit is not commonly site of involvement in most ailments. Visual or ocular motility disorders are first findings in patients with orbital abnormalities. Detailed physical examinations of eyes and orbits are necessary before complex diagnoses (Arthur S. Grove, Jr., M.D., 1975; Maciag et al., 2024).

Ophthalmology is a branch of medicine that deals with the diagnosis, treatment and prevention of diseases of eye and visual system. Intervention in fish eye and nerve diseases also refers to the terminology, surgery and treatment strategies of this cities of science. So that it also includes fish eyes as a discipline (Seo et al., 2023). Ophthalmology ailments have become a serious problem in the world on fish. Among the many causes of visual impairment in fish, some have their basis in nutritional deficiencies. Nutritional deficiency is not common in fish especially wild. Malnutrition, especially a lack of essential vitamins and minerals such as vitamin A, weakens the fish's immune system. As a result, it makes you more susceptible to infections and eye-related problems. Vitamin A deficiency causes exophthalmia, clouding, severe degeneration of cornea and retina, lenticular opacity with no involvement of other orbit issues (Medori et al., 2022).

Ocular diseases are widespreadly seen in both elasmobranch and teleost fish (Caves et al., 2023). Exophthalmia ailment is dangerous, painful and difficult to combat. Exophthalmia medically known as Popeye Disease, Bulging Eyes, Exophthalmos, Proptosis is a condition where the eye of the fish is swollen and protrudes abnormally from its socket (Petco, 2023; Aitchtuoh, 2015). Fish ocular diseases have been several potential causes (Petco, 2023). Note that some fish normally have protruding eyes; this is not the same as exophthalmia ailment. Exophthalmia can seriously affect a single eye or both eyes (Aitchtuoh, 2015). Fish eyes cloudy in some cases (Kay, 2024).

In case of eye protrusion, thin skin layer around eye becomes tense. Tissue fluid leaks into the back of the eye and pushes it outward. The fish loses its vitality and appetite (Mariappan et al., 2023). Eye fungus and opportunistic bacterial infections may occur. Eye fog may occur as a result of degeneration in the cornea (Chang et al., 2024).

Exophthalmia causes are multiple agents can be

responsible for eye lenses intervention (Sanders, 2020).

It is a case where the eyeball protrudes out of the eye socket at an abnormal rate and therefore appears protruding. As it is known, the eyeballs are located in the eye socket (Wu et al., 2024) called orbita in the skull. The front part of the eye socket, covered with bone, is like an open chamber. The eyeballs are located with fat pads in this cavity. Events such as oedema, bleeding, and aneurysm that occur behind the eyeballs cause exophthalmia of eyeballs. A decrease in strength or paralysis in muscles that move eye are among causes of exophthalmia (Butt and Patel, 2020).

If you cannot be sure whether the fish has been blinded as a result of a violent impact, the fish can be warned with a camera flash while it is awake and active (swimming freely left and right). If he reacts, he sees. If he is unresponsive, there is a possibility that he is blind (even if it sees it, it may not react). If you make several different attempts like this and do not get a reaction in any of them, we can conclude that the fish is blind (Bleckmann, 2024).

These attempts should not be made repeatedly because each of these processes is ultimately a stressor. It is already under stress due to injury, and performing these visual tests after a few hours when the fish comes to its senses will give more reliable results (Huntingford et al., 2006).

This article highlights to with fish ophthalmology as a component of fish medicine for clinical decision-making and treatment. This article of aims highlited eye lesions (ocular diseases) such as forzando exophthalmia which general case reports are commonly and clinically in fish. This study seeks to highlight the wide range of primary ocular disorders and underlying systemic disease processes identified in a large cohort of fish through use of routine surveillance. Illustrates evaluation and management of eye ailments and highlights in the management of fish aliments with this article. Overall, this review presents many questions-answer regarding the role of the eye in directing development of skull, how the slightest infection of the eye affects brain, eye surgery, fish diseases that affect the eyes and fish eye anatomy.

## EYE SOCKET ANATOMY IN FISH

Eye is an important sensory organ that collects and focuses images and converts them into nerve signals (Pereira et al., 2014).

Fish eyes consist of components like human eyes, but have a different structure. An anatomical example is the presence of light-activated pigments in eyes of some fish, which darken and shade bright lights (Nilsson, 2021). Because the cornea is so round, fish can take images of the environment in almost the full hemisphere of the eye, that is, in 360°. Because water has a strong ability to refract images, fish corneas compensate by having nearly the same density as water, causing a small bending of images as they are transferred from water to the fish's eyes. The eye anatomy of fish includes the cornea, the lens for taking photographs, the iris for adjusting the light, retina containing light-sensitive cells, and the optic nerve that transmits the image to the brain (Bleckmann, 2024). The lens structure refracts a significant part of the light, unlike corneas. Their lenses are spherical. In this way, the image reaches directly to the center; However, it does mean that vision becomes increasingly blurry and refracted at the edge of vision. To focus, Pisces needs to point directly at something. This means that although their vision is almost 360°, their vision is clearest in the middle of the Picture (Moore, 2023). If the iris structure is examined, animals have an adjustable iris that controls the light coming into the pupil (Douglas, 2018). Except for a few shark species, fish do not have this feature; instead, they adjust light levels by moving their irises up and down. In eyelid replacement fish, the external eyelid is completely absent. In most fish, this means they have no eyelids at all, but some sharks have a nictitating membrane. This membrane in question is a thin and transparent film that can be pulled over the eye for protection. Some fish, although technically not eyelids, have a fatty layer over their eyes that blocks some of the light and only allows it to pass through small hole above pupil (Moore, 2023).

Absence eyelids in all teleost fish renders their ocular surface particularly vulnerable to corneal disease (Williams, 2012). Redundancy redundant tone to corneal ailments is further heightened in certain species, such as Bubble Eye fish with fluid-filled sacs beneath each eye, Celestial Eye fish known for its upward-pointing “star-gazing eyes”, and Black Moor fish characterized by its significantly enlarged eyes, all of which have evolved distinctive morphological traits (Sneddon and Wolfenden, 2019; Kim et al., 2024) Owing to their protruding nature, ocular structures and surfaces in as examples fish etc species often become traumatic injury.

## IMPORTANT CONTACT BETWEEN EYE AND BRAIN

In anatomical terms, there are five brain sections from cranial to caudal. Telencephalon (forebrain); It contains cerebrum and 2 olfactory lobes. Diencephalon; It includes the epithalamus, thalamus and hypothalamus. Mesencephalon (midbrain); Internally the torus contains 2 optic lobes connected longitudinally and medially with the torus semi-circularis and the optic tectum. Metencephalon or hindbrain (cerebellum) and myelencephalon or brainstem (medulla oblongata). The ventricular organization consists of olfactory, lateral, third, tectal, and fourth ventricles. The process of adult neurogenesis is generally observed in the fish brain, as opposed to mammalian brain. Adult neurogenesis is usually detected in the cerebellum, telencephalon and optic lobe (Abdelnaeim Hussein and Cao, 2018).

Eye is a developmentally integral part of brain. Sensory systems are interface between organisms and their environment. Visual acuity depends on morphology of structures in which image is processed in central nervous system (Iwaniuk, 2016). Retina is an extension of lateral neural tube (Kuzawa et al. 2014) and therefore forms part of the brain. Density of retinal ganglion cells and photoreceptors within the retina is the main factor in visual acuity change (Fernández-Juricic 2012). The high number of photoreceptors in retina causes a smaller distance between two adjacent receptors, which increases ability to focus on images (Haug et al. 2010). Information from photoreceptors is collected in retinal ganglion cells, and these cells carry image information through optic nerve (Collin et al. 1999).

Although proximate and ultimate factors underlying differences in visual abilities are well established, current studies linking eye anatomy, vision, and brain anatomy are correlational and do not allow for determination of causality. A recent artificial selection experiment on relative brain size in guppies offers the opportunity to experimentally test the link between brain morphology and visual acuity (Corral-López et al., 2017b ).

Because selective pressures can be powerful modulators of sensory systems, determining the sensory abilities of these fish exposed to different brain size selection regimes is vital. Thanks to this feature of the brain, the evaluation of the cognitive performance of these selection lines in numerical learning, reversal learning and maze learning tests was based



on the presentation of visual stimuli (Kotrschal et al. 2013). Using the same method, mate choices were also tested with visual representation of potential partners (Corral-López et al. 2017a). In addition to a unique opportunity to experimentally test the link between brain morphology and vision, testing visual acuity will clarify whether potential differences in the visual system contribute to apparent behavioral differences previously found along these lines of selection (Corral-López et al., 2017b). Thus, in this study, they quantitatively tested whether the directional choice of relatively large versus small brain size affects eye size and visual acuity.

Fish vary greatly in terms of vision angle and visual acuity (Caves et al. 2017). Therefore, fish are excellent model creatures to examine the relationship between eye morphology and visual acuity (Douglas and Hawryshyn 1990). In particular, behavioral measures of stereotypic innate optomotor responses to contrasting gratings have been widely used to assess visual acuity in various fish species (Haug et al. 2010; Corral-López et al. 2017b ).

In a report published by Alturfan in 2023, the identification of dopaminergic neuron populations in zebrafish (*Danio rerio*) similar to the substantia nigra in humans showed that zebrafish could be a model for the stimulation and screening of drugs for Parkinson's Disease. Zebrafish has been reported to be a vertebrate model organism used in research on neurodevelopmental and neurodegenerative diseases. In zebrafish, dopaminergic system is fully developed by 96 hours after fertilization, and tyrosine hydroxylase immunopositive neurons are considered dopaminergic neurons. The researchers in question talked about the chemical agents applied to create dopaminergic system and dopaminergic neuron damage in zebrafish. Among these agents which can easily cross the blood-brain barrier due to its lipophilic structure, is a neurotoxin used to create a model of Parkinson's disease by stimulating the loss of dopaminergic neurons in zebrafish. Paraquat and rotenone interference are associated with the development of Parkinson's disease. It has been reported that 6-hydroxydopamine, which has an affinity for dopamine transporters similar to the catecholamine structure, causes damage to dopaminergic neurons by stimulating oxidative stress and inflammation. He reported in the same report that these agents showed neurotoxic effects in zebrafish by causing damage to dopaminergic neurons (Alturfan, 2023).

Vacuolizing encephalopathy and retinal disease

syndrome causes extensive vacuolization in neural tissue (including the brain, spinal cord and retinal nerve layer). Malachia and gliosis are also observed in some case (Lambert, 2024).

A sick individual learns that his or her eyes have lost their vision because an eye disease damaged the most important eye cells in the eye retina. Then, an attempt is made to restore this patient's vision by surgically implanting some new retinal cells into the eye tissue under the supervision of doctors. However, although science has yet to offer this happy ending, researchers are working on it with the help of the humble zebrafish. When zebrafish lose retina cells, they produce new ones. This observation spurred scientists to hack and transfer zebrafish's innate regenerative capacity to learn how to treat human diseases. That's why about 80 of the National Eye Institute's 1,200 major active scientific research projects involve zebrafish (National Eye Institute, 2020).

Retina structure is layer of tissue located at back of eye that responds to light. However, many scientists think that retina tissue is part of brain. Like other neurons of the central nervous system, retinal neurons typically do not proliferate and cease to reproduce in adults. Loss of retinal neurons typically results in irreversible loss of vision. Scientists have long known that when zebrafish's retina is damaged, Müller glia neuronal support cells begin to divide to form neuronal precursor cells, and as a result of cell division, they form replacement retinal neurons (National Eye Institute, 2020).

As understood from all case reports, any medical problem in the eye seriously affects the brain, spinal cord and nerves and progresses to the point of disrupting its function. Death is inevitable as a result of deformation of the brain, which is the governing organ, and brain organ failure. For this reason, brain functions must be investigated in detail when investigating and treating eye diseases.

## EYE SURGERY (OCULAR SURGERY)

Eye diseases are physical disorders that develop due to environmental or genetic factors and can lead to various vision problems. All kinds of diseases that occur in eye, in eye membrane known as transparent layer that protects eye against external influences, in eye canals, in bones around eye, in eye lens or in nerve tissues surrounding the eye, are called eye diseases (Heesterbeek et al., 2020). When drug therapy is inadequate for treatment of eye problem cor-

rectly diagnosed through detailed eye examination, treatment methods such as surgery may be preferred (Foster et al., 2016).

In pioneering study conducted 13 years ago, Yamamoto and Jeffrey (2000) demonstrated that transplantation of fish lens into surface fish eye at 24 hours post fertilization induces eye regression in surface morph, mimicking fish eye regression (Yamamoto and Jeffery, 2000). When eye regression was induced in this manner some craniofacial bones were affected. Dependent tissue elements consist of: distance between nasal bone, antorbital bones and ossified sclera, olfactory pits, and shape of both supraorbital bone and suborbital 3. Tissue elements not altered via through presence of eye transplantation maxillary teeth, tissue elements making up suborbital bones and opercular bone (Yamamoto et al., 2003; Dufton et al., 2012).

Exophthalmia surgery treatment of ocular globe protrusion is challenging task (Wildgoose, 2000; Sladky and Clarke, 2016; Biácsi et al., 2018; Sladkovic and Divers, 2021).

Biácsi et al., 2018 was present case report that within eye-sick of fish. Ocular case of fish is infrequent and there is very few published cases of successful treatment. Conservative treatment was conducted. As postoperative treatment antibiotic was used and antibiotic dosage was reduced step by step. After surgery fish lived for another 22 months and died of unrelated reasons, recurrence was not proved after death. To researchers knowledge, this statement is first successful surgery to ocular ailment treatment.

Eye protrusion is an anterior displacement of the eyeball, with its imprisonment by the eyelids behind the equator. Eyeball reintroduction is mandatory procedure in proptoses except in cases associated with extrusion or the destruction of their internal structures. For surgical requires anesthetic elements. Doctors performs clinical examination and instructed medical treatment without significant clinical improvement, so opted for the realization of gutting the eyeball (evisceration). Eye protrusion is a disease which can be treated fish. However, in more severe or chronic cases, only surgical treatment as enucleation or evisceration should be produced (Pessoa and Norberto, 2016).

## OCULAR AILMENTS DOCTRINE (OPHTHALMOLOGY)

All orb (eyeball) parts and depend on tissues and organs (adnexa) are seriously affected. Ocular ailments are cataracts, pop-eye (exophthalmia), cyclopia, no-lens (aphakia), corneal lesions (keratopathy), eye fluke, retinopathies, choroid and iris system lesions (uveitis), choroid gland disease, lens tissues oedema, small-eye (microphthalmos), sunken-eye (endophthalmia), hyperemia of all parts, neoplasia of lens, cornea, retina, and other parts; and others (Klotz et al., 2000), sharp ache in eyes, diplopia (It is an eye problem that causes the image of a single object to appear as two images adjacent to each other horizontally, vertically and obliquely) (Burroughs et al., 2007) or double vision, caused by weakening of eye muscles blurred vision. Blindness optic nerve is compressed difficulty in acting eyes, as eye muscles are affected feeling pressure and due to this results around the eyes (Shahinpoor et al., 2024).

Globe and orbit are subject to trauma, congenital disease, inflammation, and extension of disease into orbit from adjacent cranial cavities, particularly sinuses. Orbit Diseases of result in deep cosmetic changes, and, in almost all cases, vision loss occurs. Entrapment of globe within orbit occurred by oculokinetic management of vestibular system. Orbit is completely lined with a severe, multilayered periorbitum. Currently fish medicine, improvements in implant materials will generate novel cosmetic elements for fish by severely and painful damaged globes (Hartley and Grundon, 2022).

Exophthalmia (also called exophthalmos, exophthalmos, proptosis, or exorbitism) is bulging of the eye anteriorly out of the orbit. Enophthalmos is posterior displacement of the eyeball within the orbit due to changes in the volume of the orbit (bone) relative to its contents (the eyeball and orbit fat), or loss of function of the orbitalis muscle. Orbital cellulitis is inflammation of eye tissues behind the orbital septum. It is most commonly caused by an acute widespread of infection into the eye socket. Ptosis is a drooping or falling of the upper eye. Trichiasis where eyelashes grow inwards toward the eye. The lashes rub against the cornea, the conjunctiva, and the inner surface of the eye. Entropion is a medical condition in which your eye turns outward. This leaves the inner eye surface exposed and prone to irritation. Sty, also known as a hordeolum, is a bacterial infection of an oil gland in the eye. Chalazion is a common condition in which a small lump

or cyst develops in your eye due to a blocked oil gland. Corneal abrasion is a scratch on the clear front surface of eye (cornea). Typically cause significant discomfort, red eyes, watery eyes and sensitivity to light. Corneal ulcer is an open sore of the cornea. Causes of corneal ulcers, including infection, physical and chemical trauma, corneal drying and exposure, and contact lens overwear. Herpes simplex keratitis is corneal infection with virus. It may involve the iris. Symptoms include foreign body sensation, lacrimation, photophobia, and conjunctival hyperemia. Keratoconus is a disorder of the eye which results in progressive thinning of the cornea. Arcus senilis is a depositing of phospholipid and cholesterol in the peripheral cornea (Khurana, 2019; Kumaratunga et al., 2023; Li and Bacom, 2023; Westernen, 2023).

## CASE REPORT: EXOPHTHALMIA SCENARIO

### Exophthalmia aliment

Exophthalmia refers to an abnormal protrusion of the eyeball. Ailment this condition can affect one or both eyes (unilateral or bilateral) and is typically associated with an underlying medical condition. Exophthalmia is the protrusion, or projection of the eyeball outwards. The condition arises in response to a build-up of fat, muscle or tissue behind the eye, reducing the amount of space in the eye socket. This forces the eyeball forward (Popov et al., 2023).

Exophthalmia ailment course of disease with anguish and severe lachrymator (Macpherson, 1923). Also stress is enemy of both body and eyes. For example, Central Serous Retinopathy (CSR) may develop due to triggered stress. In this problem, when stress is high, retina is negatively affected. If fluid leaks into the subretinal area and is not cleared, central vision may decrease. The disease is called 'Central' Serous Retinopathy because it generally affects the visual point (fovea) and impairs central vision. Since the source of the fluid under the retina is the choroidal tissue, another name for the disease is Central Serous Chorioretinopathy (Palakkamanil et al., 2023).

### Exophthalmia symptoms

Corneal oedema resulting from loss of corneal endothelium, epithelial shifting and mitosis to repair a superficial corneal lesion, and, pigmentation in response to chronic irritation are often observed (Jurk, 2002).

Case in point exophthalmia disease is one or both

of an fish eyes bulging from socket. Take a closer look at the eyes to be sure. See scratch or physical of injury. In addition, widespread cause is internal infection. Conjunctivitis, eye loss, protrusion of one or both eyes, blood in the eyeball, loss of appetite, cloudiness of the eyeball, stretching of eye socket, discoloration in the eyeball, eyeball rupture, clamped fins, inactivity, hiding or other behavioral changes, swollen body (Sanders, 2020; Petco, 2023). Also, firstly and easily seen macroscopically discoloured, ulcerated or disproportionate eye (Whitaker, 2001).

"Fish vision is normal, but it cannot see..." Rudrani Barik, MD, discussed a potential culprit of this sick fish compliant during neuro-ophthalmology subspecialty day: visual snow syndrome, which affects 1%-2% of fish. This differential may be considered in cases where sick fish have no structural damage or abnormal ocular tests or scans but are complaining of visual symptoms such as photophobia, floaters, myctalopia, after images and trailing images (Barik, 2023). For example this is a symptom of barotrauma more commonly seen in grouper species, but this snapper's eyes were bulging slightly after being brought up from over 200 feet. This one was safely returned with a descending device.

### Is exophthalmia serious?

Fish are injury prone creatures due to nature and environmental at greater risk. Common causes that will need to consider that if fish is suffering from unilateral infective eye disease, may be culprit is physical injury (Ray and Gragoudas, 2001; Miller et al., 2007). Fish could accidentally bump into and seriously scratch their eyes. Because fish lack eyelids, fish cannot provide last second protection for their eyes in these cases. Exophthalmia disease is a vital case that requires immediate attention. The sooner can provide treatment, better prognosis. In most cases, the disease itself is not fatal. However, additional problems that can bad affect fish. Fish may be lose sight in one or both eyes. Or lose eye socket in fish (Norden, 2023). Infected eyes can deteriorate and fall out without treatment. In exophthalmia disease, fish can still alive after losing a single eye. But this case is quality of life will be seriously affected against attack. Also can quickly cause septicemia any more. Internal septicemia occurs when infection passes into bloodstream. This in case advanced exophthalmia is a fatal infection. Fatal cases, septicemia is to blame. It may be cause organ failure throughout the body (Ruchała et al., 2014; Judith Marcin and Brazier, 2023).



## Exophthalmia treatment

The treatment to be applied in cases of exophthalmia varies depending on characteristics of case and therefore cause. Attempts are often made to reduce volume within orbit (Costan et al., 2020).

Fish do not have eyelids (Hayden, 1931). Therefore, you should be careful and avoid sudden movements. Because a fish that gets scared and runs left and right may hit its eyes and inadvertently injure it (Garcia-Abiado et al., 2006).

Exophthalmia ailment treatment is troublesome (Naffziger, 1931). Not only should you treat underlying cause, but should also address potential bacterial infections. Some treatment processes are applied to treat Exophthalmia ailment. Quarantine infected fish (Chong et al., 2023). Initially check up water conditions. Check ammonia, nitrate, pH levels and temperature. Add a little salt in media. During treatment, provide your fish with a balanced diet rich in vitamins. Deal with bacteria use antibiotic to prevent bacterial infections and corneal damage from getting worse. The eyes and the environment must be constantly monitored and monitored. Over time, eyes should deflate and return to normal (Sen and Mandal, 2018). In addition could be use pre-, pro- ve postbiotics for fish body resistance (Chong et al., 2023).

## COMPLICATIONS

If left untreated causes blindness. If cornea dries observation infection, ulcers, damage vision. Likely to develop conjunctivitis, and superior limbic keratoconjunctivitis, inflamed cornea due to tearing. Could be experience compression of the optic, ophthalmic or brain problems (Ruchała et al., 2014; Judith Marcín and Brazier, 2023). Also, globe protrusion must be account before orbital expansion and decompression procedure is planned (Verity et al., 2024).

## DISCUSSION AND CONCLUSION

Ocular lesions and periocular pathology are briefly mentioned in studies of fish (Whitaker, 2001; Gauthier and Rhodes, 2009; Woo and Buchmann, 2012). Moreover, ocular pathologies occurring secondary to trauma (Whitaker, 2001). Case reports of fish ocular neoplasia have also been published (Fournie and Overstreet, 1985; Bartlett et al., 2010; Kagan et al., 2010; Kumaratunga et al., 2023). Also, some studies which ocular pathology have documented across large cohorts of fish.

Ferguson et al. 1994 was reported that Strepto-

coccosis disease in fish. Reported that the case in point external lesions were seen in fish presented exophthalmia, while also had crucial level intra-ocular hemorrhage and periorbital hemorrhage.

Cleymaet et al. 2022 was reported that case with ocular trauma. Exophthalmia and keratitis have been reported insist on and abundant in fish diseases. The case in point, low vision to blindness secondary to corneal opacity. It is also reported to necrotizing scleritis with abscess secondary to in fish. This is case report to secondary glaucoma and endophthalmitis, presumed to be ocular manifestation of systemic sepsis. Secondary glaucoma consist of inflammation, infection, virulence, trauma, drug reaction, or neoplasia.

Kumarantuga et al. 2023 was reported that cases was studied by with Ocular Periocular Histopathology (OPHP). All cases that had undergone OPHP examinations were individually reviewed and assigned diagnosis. Diagnoses were grouped into nine generic categories for intraocular haemorrhage, buphthalmos, phthisis bulbi, corneal oedema, gas bubble disease, cataract, inflammation, and other problems.

Goldfish respond to administration of thyrotrophic hormone with exophthalmia. Retrobulbar injections of normal saline, human serum and pituitary hormones conduct transient exophthalmia, which is much more insistent when thyrotrophin is injected. Eye protrusion increases with simultaneous injections of corticotrophin. Previous treatment of fishes with long-acting corticotrophin prolonged the duration of the exophthalmia caused by retrobulbar injections of thyrotrophin; but this effect is not observed when other fluids are injected (Cañadel, and Barraquer, 1959).

Karvonen et al., in 2004 was check up parasite-induced cataract in fish using slit-lamp microscopy to determine relationship between cataract intensity and number of *Diplostomum spathaceum* parasites that were localized in lens. Cataract intensity increased significantly with parasite burden, but was also affected by pattern of exposure to parasite cercariae by reported. Slit-lamp proved valid in scoring the cataracts since it provides a 3-dimensional come in sight lens and gives an actual picture of oclation and intensity of cataracts, which allows detailed investigations of mechanisms underlying cataract in fish.

Zebrafish are well good model system for suited to study of eye diseases. Zebrafish made a major impact on understanding and treatment of eye dis-



eases are all there. Scientists have recognized this and are now studying zebrafish intensively. The stage is setup for models of clinically vital eye diseases to emerge, and with them detailed understanding of disease and thus chance of finding treatments for these disabling conditions. In addition, it is noteworthy that the zebrafish is a model for the eye and nervous system and that fish will have a serious healing effect on eye diseases.

By Iregul et al in 2012 reported that, in a fish with lesions caused by *Edwardsiella tarda*, was reported that diagnosed systemic abscesses involving muscles of the flank or caudal peduncle are common lesions. Necrotic meningitis, encephalitis, and vasculitis with fibrinoid necrosis of the blood vessels walls, as well as the formation of a plaque-like structure in the brain, are described in the study. As in this case, cases have been reported where *E. tarda* bacteria penetrate the fish's eye and move to the brain, where it settles in the nervous system, resulting in permanent damage or death.

Chronic Progressive External Ophthalmoplegia (CPEO) is the most common manifestation of mitochondrial diseases. CPEO is characterized by reduced ocular motility and bilateral symmetrical progressive ptosis. CPEO can be isolated. Also, CPEO accompanied by a clinical feature of systemic involvement of mitochondrial dysfunction as CPEO Plus Syndrome (Pashae, 2024).

Von Graefe, in 1868, originally described CPEO. And the end, in 1958, Kearns and Sayre first described their triad of CPEO, retinal degeneration, and heart block (Kearns–Sayre syndrome) (Kisilevsky et al., 2020). Microscopical findings of pathological mitochondria and ragged red fibers, as well as increased venous pyruvate and lactate were significant in anamnesis and diagnosing the pathways of disease (Ali et al., 2024).

Due to some circumstances, fish with severe eye ailments are rarely euthanized. Also, before performing to euthanasia, I highlight that several available treatment options for eye ailments in fish should be considered for corneal infectious.

This manuscript maybe contribute to literature an additional successful way of a common ailment

and injury seen in ophthalmology. The ocular problems described in research articles, reviews and case articles are very serious case, especially since exophthalmia disease causes the fish to lose its eye. Exophthalmia is not a condition, but the sign of a disorder, a symptom or a diseases. Commonly, it can signal a problem with the other ailment. In the long-term, symptoms tend to improve, but this can take years. There is possibility that the eyes may continue to bulge if treatment is not received. Depending on how sharp it is, exophthalmia can cause serious eye problems and fatal ailment. This manuscript encourages practitioners to perform complete ocular examination as part of routine physical examinations in fish by providing a review of functional anatomy of eye, clinical work-up, ocular examination, ocular diseases, and treatment.

## COMMENTS

Describes a condition where eyeball protrudes from eye socket, making it appear to bulge. One of the most important symptoms that draws attention at first glance during the anamnesis of serious and fatal microbial ailments (such as bacterial, viral, fungal) that pose a life-threatening threat in fish is Exophthalmia. Although it is considered as a symptom, it is a case that affects the brain and nervous system in cases that progress to eye blindness or even progress. In severe cases of exophthalmia, may not be able to use eyes properly. This can damage corneas (transparent tissue that covers front of eye) by causing them to dry out. If corneas become very dry, an infection or open sores may develop. Eye problems, which are tried to be explained with a case report of exophthalmia, are an event that should be carefully considered, as emphasized by many researchers. This doctrine, which even affects brain and causes death of fish in later stages, is a sensitive and serious issue. In conclusion, understanding ocular ailment has significantly advanced over the years, with the identification and their impact on different tissues and brain. Unfortunately, definitive phenotype – genotype correlations are still far out of reach for some eye ailment, and Fish doctors should familiarize themselves with these, maintain high clinical suspicion to diagnose them, and stop focusing on a solitary finding.

## REFERENCES

- Abdelnaeem Hussein M N & Cao, X (2018). Brain anatomy and Histology in Teleosts. *Benha Veterinary Medical Journal*, 35(2), 446-463.
- Aitchuoh Fischer (2015). Treating Pop-Eye. Central Florida Aquarium Society.
- Alturfan E E (2023). Zebra Balıklarında Dopaminerjik Nöron Hasarı.
- Ali, A, Esmacil, A, & Behbehani, R (2024). Mitochondrial Chronic Progressive External Ophthalmoplegia. *Brain Sciences*, 14(2), 135. <https://doi.org/10.3390/brainsci14020135>
- Arthur S Grove, Jr., M D (1975). Evaluation of Exophthalmos. *N Engl J Med*, 292, 1005-1013. <https://doi.org/10.1056/NEJM197505082921905>
- Bartlett S L, Peters R M, Lombardino I M & Bowser P R (2010). Bilateral intraocular malignant neuroectodermal tumors in a telescope goldfish (*Carassius auratus*). *Veterinary ophthalmology*, 13, 3-8. <https://doi.org/10.1111/j.1463-5224.2009.00716.x>
- Burroughs J R., Anderson R L, Patrinely J R, Weinberg D A, McCann J D & McMullan T F (2007). Preoperative assessment of the eye and periocular region. In *Seminars in plastic surgery* (Vol. 21, No. 01, pp. 005-017). Copyright© 2007 by Thieme Medical Publishers, Inc., 333 Seventh Avenue, New York, NY 10001, USA. February <https://doi.org/10.1055/s-2007-967742>
- Barik R (2023). Ophthalmology. aaoeye2023. Visual Snow Syndrome (VSS).
- Biácsi A, Varga A, Papp E & Liptovszky M (2018). Surgical removal of an ocular fibroma in an emperor red snapper (*Lutjanus sebae*, Cuvier, 1816). Case report. *Magyar Állatorvosok Lapja*, 140(8), 507-511.
- Bleckmann, H. (2024). *Stupid as a Fish?: The Surprising Intelligence Under Water*. Springer Nature.
- Butt S & Patel B C (2020). Exophthalmos. Study Guide from StatPearls Publishing, Treasure Island (FL), 10 Jul 2020, PMID: 32644749
- Cañadel J M & Barraquer J (1959). Enhancing effect of corticotrophin on thyrotrophin produced exophthalmos in fish. *Endocrinology*, 64(6), 1017-1022. <https://doi.org/10.1210/endo-64-6-1017>
- Caves E, Sutton T T & Johnsen S (2017) Visual acuity in ray-finned fishes correlates with eye size and habitat. *J Exp Biol* 220(9):1586–1596. <https://doi.org/10.1242/jeb.151183>
- Caves E M, Sutton T T, Warrant E J & Johnsen S (2023). Measures and models of visual acuity in epipelagic and mesopelagic teleosts and elasmobranchs. *Journal of Comparative Physiology A*, 209(5), 807-826. <https://doi.org/10.1007/s00359-023-01661-7>
- Chang, S., Kong, D. J., & Song, Y. M. (2024). Advanced visual components inspired by animal eyes. *Nanophotonics*, 13(6), 859-879. <https://doi.org/10.1515/nanoph-2024-0014>
- Chong C M, Shakir M Z, Lai K S, Liew H J & Loh J Y (2023). Microbes and fish diseases. In *Recent Advances in Aquaculture Microbial Technology* (pp. 65-102). Academic Press. <https://doi.org/10.1016/B978-0-323-90261-8.00009-2>
- Cleymaet A M, de Linde Henriksen M, Pederson S L, Sadar M J, Johnston M, Tovar-Lopez G, ... & Teixeira L B (2022). Pathology in Practice. *Journal of the American Veterinary Medical Association*, 259(S2), 1-4.
- Collin S P, Archer S N, Djamgoz M B A, Loew E R, Partridge J C & Vallerga S (eds) (1999) Behavioural ecology and retinal cell topography. Adaptive mechanisms in the ecology of vision. Kluwer Academic Publishers, Dordrecht
- Costan V V, Ciocan-Pendefunda C C, Ciofu M L, Boisteanu O, Timofte D V, Gheorghe L, ... & Preda C (2020). Balancing orbital volume reduction and redistribution for a tailored surgical treatment in Graves' ophthalmopathy. *Graefes's Archive for Clinical and Experimental Ophthalmology*, 258, 2313-2320. <https://doi.org/10.1007/s00417-020-04807-4>
- Corral-López A, Bloch N I, Kotrschal A, van der Bijl W, Buechel S D, Mank J E, Kolm N (2017a) Female brain size affects the assessment of male attractiveness during mate choice. *Sci Adv* 3(3):e1601990. <https://doi.org/10.1126/sciadv.1601990>
- Corral-López A, Garate-Olaizola M, Buechel S D, Kolm N & Kotrschal A (2017b). On the role of body size, brain size, and eye size in visual acuity. *Behavioral Ecology and Sociobiology*, 71, 1-10. <https://doi.org/10.1007/s00265-017-2408-z>
- Douglas R H, & Hawryshyn C W (1990) Behavioural studies of fish vision: an analysis of visual capabilities. In: Douglas RH, Djamgoz MBH (eds) *The visual system of fish*. Chapman and Hall, London, pp 373–418. [https://doi.org/10.1007/978-94-009-0411-8\\_11](https://doi.org/10.1007/978-94-009-0411-8_11)
- Douglas, R H (2018). The pupillary light responses of animals; a review of their distribution, dynamics, mechanisms and functions. *Progress in Retinal and Eye Research*, 66, 17-48. <https://doi.org/10.1016/j.preteyeres.2018.04.005>
- Dufton M, Hall B K & Franz-Odenaal T A (2012). Early lens ablation causes dramatic long-term effects on the shape of bones in the craniofacial skeleton of *Astyanax mexicanus*. *PLoS One*, 7(11), e50308. <https://doi.org/10.1371/journal.pone.0050308>
- Ferguson H W, Morales J A & Ostland V E (1994). Streptococcosis in aquarium fish. *Diseases of Aquatic Organisms*, 19(1), 1-6.
- Fernández-Juricic E (2012) Sensory basis of vigilance behavior in birds: synthesis and future prospects. *Behav Process* 89(2):143–152. <https://doi.org/10.1016/j.beproc.2011.10.006>
- Foster, C S., Kothari, S, Anesi, S D, Vitale, A T, Chu, D, Metzinger, J L, & Cerón, O (2016). The Ocular Immunology and Uveitis Foundation preferred practice patterns of uveitis management. *Survey of ophthalmology*, 61(1), 1-17. <https://doi.org/10.1016/j.survophthal.2015.07.001>
- Fournie J W & Overstreet R M (1985). Retinoblastoma in the spring cavefish, *Chologaster agassizi* Putnam. *Journal of Fish Diseases*, 8(4), 377-381. <https://doi.org/10.1111/j.1365-2761.1985.tb00959.x>
- Garcia-Abiado M A, Penn M & Dabrowski K (2006). Case study on eye abnormalities in tank-reared hybrid walleyes (*Sander vitreus* × *S. canadensis*). *Aquaculture Research*, 37(5), 443-448. <https://doi.org/10.1111/j.1365-2109.2005.01436.x>
- Gauthier D T & Rhodes M W (2009). Mycobacteriosis in fishes: a review. *The Veterinary Journal*, 180(1), 33-47. <https://doi.org/10.1016/j.tvjl.2008.05.012>
- Haug M F, Biehlmaier O, Mueller K P, Neuhauss S C (2010) Visual acuity in larval zebrafish: behavior and histology. *Front Zool* 7(1):8. <https://doi.org/10.1186/1742-9994-7-8>
- Hartley, C, & Grundon, R A (2022). Diseases and surgery of the globe and orbit. *Equine ophthalmology*, 133-186. <https://doi.org/10.1002/9781119782285.ch3>
- Hayden H W (1931). The Eyelids. *Clinical and Experimental Optometry*, 14(7), 5-8. <https://doi.org/10.1111/j.1444-0938.1931.tb00109.x>
- Heesterbeek, T J, Lorés-Motta, L, Hoyng, C B, Lechanteur, Y T, & den Hollander, A I (2020). Risk factors for progression of age-related macular degeneration. *Ophthalmic and Physiological Optics*, 40(2), 140-170. <https://doi.org/10.1111/opo.12675>
- Huntingford F A, Adams C, Braithwaite V A., Kadri S, Pottinger T G, Sandoe P, & Turnbull, J F (2006). Current issues in fish welfare. *Journal of fish biology*, 68(2), 332-372. <https://doi.org/10.1111/j.0022-1112.2006.001046.x>
- Iwaniuk A (2016). Functional correlates of brain and brain region sizes in nonmammalian vertebrates. In: Kaas JH (ed) *Evolution of nervous systems*. Academic Press, London, pp 335–348. <https://doi.org/10.1016/B978-0-12-804042-3.00024-5>
- Judith Marcin M D & Brazier Y (2023). MedicalNewsToday. Everything you need to know about exophthalmos. Medically reviewed by Judith Marcin, M.D. — By Yvette Brazier — Updated on July 12, 2023. <https://www.medicalnewstoday.com/articles/169869>
- Jurk I (2002). Ophthalmic disease of fish. *Veterinary Clinics: Exotic Animal Practice*, 5(2), 243-260. [https://doi.org/10.1016/S1094-9194\(02\)00006-3](https://doi.org/10.1016/S1094-9194(02)00006-3)
- Kagan R A, Pinkerton M E, & Kinsel M J (2010). Neuronal embryonal tumors in fish. *Veterinary pathology*, 47(3), 553-559. <https://doi.org/10.1177/0300985809359600>
- Karvonen A, Seppälä O & Valtonen E T (2004). Eye fluke-induced cataract formation in fish: quantitative analysis using an ophthalmological microscope. *Parasitology*, 129(4), 473-478. <https://doi.org/10.1017/S0031182004006006>
- Kay, J (2024). Murky waters make big eyes, but not big brains. *Journal of Experimental Biology*, 227(7). <https://doi.org/10.1242/jeb.247487>
- Khurana A K (2019). Comprehensive ophthalmology. Jaypee brothers medical publishers.
- Kim, S, Moore, B A, Parker, C, Siniard, W C, Ang, J, Teixeira, L B, ... & Soto, E (2024). Clinical and histopathological features of proliferative corneal lesions in Cyprininae fishes: Implications for treatment

- and insights into corneal tumors. *Veterinary Ophthalmology*, 27(3), 200-213. <https://doi.org/10.1111/vop.13133>
- Kisilevsky, E., Freund, P., & Margolin, E. (2020). Mitochondrial disorders and the eye. *Survey of Ophthalmology*, 65(3), 294-311. <https://doi.org/10.1016/j.survophthal.2019.11.001>
- Klotz S A, Penn C C, Negvesky G J & Butrus S I (2000). Fungal and parasitic infections of the eye. *Clinical microbiology reviews*, 13(4), 662-685. <https://doi.org/10.1128/cmr.13.4.662>
- Kotrschal A, Rogell B, Bundsen A, Svensson B, Zajitschek S, Brännström I, Immler S, Maklakov A A & Kolm N (2013) Artificial selection on relative brain size in the guppy reveals costs and benefits of evolving a larger brain. *Curr Biol* 23(2), 168–171. <https://doi.org/10.1016/j.cub.2012.11.058>
- Kumaratunga V, Adams V J, Donaldson D, Pont R T & Stidworthy M F. (2023). Ocular pathology in aquarium fish with a focus on the Syngnathidae and Apogonidae families. *Journal of Comparative Pathology*, 200, 1-11. <https://doi.org/10.1016/j.jcpa.2022.11.002>
- Kuzawa C W, Chugani H T, Grossman L I, Lipovich L, Muzik O, Hof P R, Wildman D E, Sherwood C C, Leonard W R, Lange N (2014). Metabolic costs and evolutionary implications of human brain development. *P Natl Acad Sci USA* 111(36):13010–13015. <https://doi.org/10.1073/pnas.1323099111>
- Lambert, Z. J. (2024). *Strain differentiation of prion disease in white-tailed deer and cattle* (Doctoral dissertation, Iowa State University).
- Li E, Bacorn C (Eds.) (2023). *Ophthalmology Clerkship: A Guide for Senior Medical Students*. Springer Nature.
- Maciag, E J., Martín-Noguerol, T, Ortiz-Pérez, S, Torres, C, & Luna, A (2024). Understanding Visual Disorders through Correlation of Clinical and Radiologic Findings. *Radiographics*, 44(2), e230081. <https://doi.org/10.1148/rg.230081>
- Macpherson W G (1923). *Medical Services: Diseases of the War..* (Vol. 2). HM Stationery Office.
- Mariappan, B, Kaliyamurthi, V, & Binesh, A (2023). Medicinal plants or plant derived compounds used in aquaculture. In *Recent advances in aquaculture microbial technology* (pp. 153-207). Academic Press. <https://doi.org/10.1016/B978-0-323-90261-8.00003-1>
- Medori, M C, Naureen, Z, Dhuli, K, Placidi, G, Falsini, B, & Bertelli, M (2022). Dietary supplements in retinal diseases, glaucoma, and other ocular conditions. *Journal of Preventive Medicine and Hygiene*, 63(2 Suppl 3), E189. <https://doi.org/10.15167/2421-4248/jpmh2022.63.2S3.2760>
- Meyers T R (2009). Standard necropsy procedures for finfish. NWFHS Laboratory Procedures Manual. 5th ed. Washington: US Fish and Wildlife Service. p. 64-74.
- Miller S E, Howell D N & Proia A D (2007). Viral disease. In *Garner and Klintworth's Pathobiology of Ocular Disease (Part A)* (pp. 187-364). CRC Press.
- Moore S (2023). Pets on Mom. Structure of a Fish's Eye. <https://animals.mom.com/structure-fish-eye-10517.html> Last access date: 09.11.2023
- Naffziger H C (1931). Progressive exophthalmos following thyroidectomy; its pathology and treatment. *Annals of Surgery*, 94(4), 582. <https://doi.org/10.1097/0000658-193110000-00013>
- National Eye Institute, (2020). Could a tiny fish hold the key to curing blindness? The zebrafish is a minnow; but in the lab, it's a whale of a model system September 25, 2020. <https://www.nei.nih.gov/about/news-and-events/news/could-tiny-fish-hold-key-curing-blindness>
- Nilsson, D E (2021). The diversity of eyes and vision. *Annual Review of Vision Science*, 7(1), 19-41. <https://doi.org/10.1146/annurev-vision-121820-074736>
- Norden, C. (2023). A Fish Eye View: Retinal Morphogenesis from Optic Cup to Neuronal Lamination. *Annual Review of Cell and Developmental Biology*, 39(1), 175-196. <https://doi.org/10.1146/annurev-cellbio-012023-013036>
- Palakkamanil M, Munro M, Sethi A & Adatia F (2023). Intravitreal anti-vascular endothelial growth factor for the treatment of chronic central serous retinopathy: a meta-analysis of the literature. *BMJ Open Ophthalmology*, 8(1), e001310.
- Parker-Graham C A, Stevens B N, Ang J H, Soto E, Williams D L, Kwok J & Moore B A (2022). Ophthalmology of Osteichthyes: Bony Fish. In *Wild and Exotic Animal Ophthalmology: Volume 1: Invertebrates, Fishes, Amphibians, Reptiles, and Birds* (pp. 61-104). Cham: Springer International Publishing. [https://doi.org/10.1007/978-3-030-71302-7\\_5](https://doi.org/10.1007/978-3-030-71302-7_5)
- Pashae, M P H (2024). Chronic Progressive External Ophthalmoplegia. *inSIGHT*, 4(1), 7.
- Pereira P, Raimundo J, Araújo O, Canário J, Almeida A & Pacheco M (2014). Fish eyes and brain as primary targets for mercury accumulation—A new insight on environmental risk assessment. *Science of the Total Environment*, 494, 290-298. <https://doi.org/10.1016/j.scitotenv.2014.07.008>
- Pessoa, L M B., & Norberto, G D O (2016). Ocular proptosis in eye emu (*Rhea americana*) in captivity-case report.
- Petco (2023). Dropsy, Swim Bladder Disorder, & Popeye in Aquarium Fish.
- Popov T, Fierz F C, Bockisch C J & Weber K P (2023). Using Smartphone Exophthalmometry to Measure Eyeball Protrusion. *JAMA ophthalmology*, 141(10), 974-981. doi:10.1001/jamaophthalmol.2023.4044
- Ray S & Gragoudas E (2001). Neuroretinitis. *International ophthalmology clinics*, 41(1), 83-102.
- Ruchała M, Hernik A & Zybek A (2014). Orbital radiotherapy in the management of Graves' orbitopathy — current state of knowledge Rola radioterapii oczodołów w leczeniu orbitopatii tarczycowej — aktualny stan wiedzy. *Endokrynologia Polska*, Tom/Volume 65; Numer/Number 5/2014, ISSN 0423–104X, Prace poglądowe/ Reviews, <https://doi.org/10.5603/EP.2014.0054>
- Sanders Jessie (2020). Fish Popeye. *Aquatic Veterinary Services*.
- Sargent J, Bell G, McEvoy L, Tocher D & Estevez A (1999). Recent developments in the essential fatty acid nutrition of fish. *Aquaculture*, 177(1-4), 191-199. [https://doi.org/10.1016/S0044-8486\(99\)00083-6](https://doi.org/10.1016/S0044-8486(99)00083-6)
- Sen K & Mandal R (2018). Fresh-water fish diseases in west Bengal, India. *International Journal of Fisheries and Aquatic Studies*, 6(5), 356-362.
- Seo H, Chung W G, Kwon Y W, Kim S, Hong Y M, Park W ... & Park J U (2023). Smart Contact Lenses as Wearable Ophthalmic Devices for Disease Monitoring and Health Management. *Chemical Reviews*, 123(19), 11488-11558.
- Shahinpoor, M., Soltanpour, D., & Shahinpoor, P. (2024). *Engineering Ophthalmology*. CRC Press.
- Sladakov I & Divers S J (2021). Surgery and Endoscopy. *Clinical Guide to Fish Medicine*, 213-232. <https://doi.org/10.1002/9781119259886.ch11>
- Sladky K K & Clarke E O (2016). Fish surgery: presurgical preparation and common surgical procedures. *Veterinary Clinics: Exotic Animal Practice*, 19(1), 55-76.
- Sneddon L, Wolfenden D. Ornamental fish (Actinopterygii). *Companion Animal Care and Welfare: the UFAW Companion Animal Handbook*. John Wiley & sons Ltd.; 2019: 440-478.
- Wang P C, Maekawa S & Chen S C (2022). Aquaculture Pathophysiology, Volume I. *Finfish Diseases*, Chapter 35 – Streptococcosis, Pages 439-445, <https://doi.org/10.1016/B978-0-12-812211-2.00035-4>
- Whitaker B R (2001). Ocular disorders. In *BSAVA manual of ornamental fish* (pp. 147-154). BSAVA Library. doi: 10.22233/9781910443538.18
- Wildgoose W H (2000). Fish surgery: an overview. *Fish veterinary journal*, 5, 22-36.
- Williams DL. *Ophthalmology of Exotic Pet*. John Wiley & sons Ltd.; 2012: 211-227.
- Western A C (2023). *Ophthalmic Drug Therapy Pocket Guide*, Clinical Ophthalmology. Xlibris Corporation.
- Woo P T & Buchmann K (Eds.). (2012). *Fish parasites: pathobiology and protection*. Cabi.
- Wu, K Y., Tabari, A, Mazerolle, É, & Tran, S D (2024). Towards Precision Ophthalmology: The Role of 3D Printing and Bioprinting in Oculoplastic Surgery, Retinal, Corneal, and Glaucoma Treatment. *Biomimetics*, 9(3), 145. <https://doi.org/10.3390/biomimetics9030145>
- Verity, D H., Baldeschi, L, Uddin, J M, & Paridaens, D (2024). Orbital Decompression Surgery. In *Oculoplastic, Lacrimal and Orbital Surgery: The ESOPRS Textbook: Volume 2* (pp. 495-513). Cham: Springer Nature Switzerland.
- Yamamoto, Y., & Jeffery, W. R. (2000). Central role for the lens in cave fish eye degeneration. *Science*, 289(5479), 631-633. <https://www.jstor.org/stable/3077540>
- Yamamoto Y, Espinasa L, Stock D W & Jeffery W R (2003). Development and evolution of craniofacial patterning is mediated by eye-dependent and -independent processes in the cavefish *Astyanax*. *Evol Dev* 5(5): 435–446. <https://doi.org/10.1046/j.1525-142X.2003.03050.x>
- Zebrafish UCL (2017). Cranial Nerve II: Optic Nerve, 1st Floor, Anatomy Building, University College London, Gower St, London, WC1E 6BT. Tel 020 3549 5642, Copyright © 2017 UCL. <https://zebrafishucl.org/cranial-nerves-1/optic-nerve>