

# Journal of the Hellenic Veterinary Medical Society

Vol 75, No 3 (2024)



## A stereological study: Volume estimation in the cerebellum of Norduz sheep

M Kiran, G Cakmak

doi: [10.12681/jhvms.36423](https://doi.org/10.12681/jhvms.36423)

Copyright © 2024, M Kiran, G Cakmak



This work is licensed under a [Creative Commons Attribution-NonCommercial 4.0](https://creativecommons.org/licenses/by-nc/4.0/).

### To cite this article:

Kiran, M., & Cakmak, G. (2024). A stereological study: Volume estimation in the cerebellum of Norduz sheep. *Journal of the Hellenic Veterinary Medical Society*, 75(3), 8041–8054. <https://doi.org/10.12681/jhvms.36423>

## A stereological study: Volume estimation in the cerebellum of Norduz sheep

M. Kiran<sup>1</sup>, G. Cakmak<sup>2\*</sup>

<sup>1</sup> *Department of Veterinary Anatomy, Health Sciences Institute, University of Yuzuncu Yil, Van, Türkiye*

<sup>2</sup> *Department of Anatomy, Faculty of Veterinary Medicine, University of Yuzuncu Yil, Van, Türkiye*

**ABSTRACT:** In this research, it was aimed to investigate the cerebellum volume values of Norduz sheep raised within the borders of Gurpinar district of Van province. For this purpose, 6 male and 6 female Norduz sheep heads were selected as materials. The brains were dissected and kept in 10% formaldehyde for a week. Cerebellums were separated from the brain hemispheriums. For better fixation, the cerebellums were kept in formaldehyde again for a week. Tissues obtained by sequential random sampling were included in tissue tracking. Then each tissue was embedded in paraffin. An average of 10-12 sections with a thickness of 5µm were obtained from the tissue cassettes obtained by a rotary microtome. Sections stained with hematoxylin and eosin were photographed with an x4 objective. From these photographs, total cerebellum, medulla and cortex volumes, as well as vermis volume, were calculated using the Shtereom I program using the Cavalieri Principle. The results were evaluated statistically with the Mann-Whitney U test. No statistical difference was detected in terms of male and female cerebellum volume values, Coefficient of Error (CE) and Noise calculations ( $p>0.05$ ). However, only the left hemispherium cerebelli volume having a higher value in females was statistically significant ( $p<0.05$ ).

**Keywords:** Cavalieri's Principle; cortex; medulla; nervous system; volume.

*Corresponding Author:*

Gamze Cakmak, Van Yuzuncu Yil University Faculty of Veterinary Medicine Department of Anatomy, Campus/VAN  
E-mail address: vetgamze@hotmail.com

*Date of initial submission: 05-01-2024*  
*Date of acceptance: 23-05-2024*

## INTRODUCTION

While it was observed that the sheep raised in Van region adapted to the conditions of the region, it was noted that local genetic resources, which are valuable in terms of productivity, were heading towards depletion. Although some type of breeds (Karakas, Kangal, Güney, Karaman) have been identified within the Akkaraman breed, which forms the basis of existing sheep in Türkiye, it has been revealed that the Norduz sheep is also a sub-variety of the Akkaraman breed (Bingol, 1998; Gokdal, 1998). When this sheep breed was compared with different local breeds in terms of morphological and physiological characteristics of Norduz sheep, it was seen that this breed had different characteristics from other local breeds in many aspects. Although Norduz sheep is one of the indigenous genetic resources of this country, it is seen that this breed is in danger of extinction every day if the necessary precautions will not be taken (Dayan, 2007).

Cerebellum is one of the structures of the central nervous system. Cerebellum performs motor functions such as performing movements in a targeted and coordinated manner and regulating muscle tone and balance. It originates from the metencephalon section of the cerebellum rhombencephalon (Taner et al., 2015).

Stereology is a branch of science that makes inferences by taking into account the three-dimensional properties of the tissue, based on two-dimensional images of the actual three-dimensional tissue. The largely preferred method for quantitative studies in stereology is the Cavalieri's Principle (Mayhew and Gundersen, 1996).

The objective of this study was to obtain the entire cerebellum, cortex and medulla volume values that make up the cerebellum, one by one, by using stereological methods in Norduz sheep is in danger of extinction. Our aim and expectation is that this study on the cerebellum, which is a part of the nervous system, will include the cerebellum volume values of the Norduz sheep, a local breed in the literature, in the field of veterinary medicine. It will lead to other studies to be conducted in the future and will also be considered as a reference study.

## MATERIALS AND METHODS

### Materials

This study was conducted at the Experimental Medicine Application and Research Center, in accor-

dance with the decision of the Van Yuzuncu Yil University Animal Experiments Local Ethics Committee dated 30.09.2021 and numbered 2021/09-10. In addition, the laboratory facilities of Van Yuzuncu Yil University, Faculty of Veterinary Medicine, Anatomy Department and Van Yuzuncu Yil University, Faculty of Veterinary Medicine, Department of Pathology were utilized.

In order to obtain the cerebellum used in this study, a zootechnist from the villages in the Norduz region, which is within the borders of the Gurpinar district of Van province, went to the region at different times, as soon as information was received about the slaughter of the Norduz sheep. The heads of 6 female and 6 male Norduz breed sheep, approximately 2 years old and healthy, with an average weight of 60-70 kg, were collected.

### Methods

#### Dissection of the cerebellum

Norduz sheep heads were dissected and the brains were removed in one piece. The brains, which were removed with intact integrity, were kept in 10% formaldehyde for a period of one week. Then it was carefully separated from other brain tissues such as cerebellum, medulla oblongata and brain hemispherium. In this study, it was preferred to apply the physical disector method, which is among the stereological study methods (Ertas and Cakmak, 2023). The three main parts that make up the cerebellum, hemispherium cerebelli dextra, hemispherium cerebelli sinistra and vermis cerebelli, were dissected separately. Since the tissues did not fit into the tissue tracking cassettes (Lp Italiana Spa), the hemispheriums of the cerebellum were divided into six equal parts to apply the sequential sampling method. The first, third and fifth parts were taken in accordance with the sequential random sampling rule (Ertas and Cakmak, 2023). The vermis was placed in one piece into tissue tracking cassettes. Tissue tracking was applied to all tissues.

#### Sampling method

A pilot study was conducted before starting the study to determine the number of sections to be taken from the tissues to be used in study, the number of samples, and how the sampling would be done. It was determined that the number of samples, number of sections and sampling method were appropriate by the pilot study. When the literature was examined, it was stated that in order to reach a coefficient of error

0.05 in stereological studies, it was necessary to study at least five animals (Cruz-Orive and Weibel, 1990).

### Obtaining sections

In order to reach the desired number of sections for the accuracy and reliability of the study, the hemispherium cerebelli, whose vermis was separated after sampling, were blocked with the help of paraffin. Sections of 5  $\mu\text{m}$  thickness were taken from each tissue. These sections taken from the tissues were obtained with the help of a rotary microtome (Leica RM 2135, Leica Instruments, Nussloch, Germany) (Sikandar et al., 2018). An average of 10-12 sections were taken from the cerebellum sample of each animal. Starting from the first section, a sample was taken every 50 steps. In other words, 1/50 sampling was done systematically and randomly. Sampled sections were included in the main study. Based on the inferences made from this sampling, similar procedures were carried out on the cerebellum hemispheriums and vermis of other sheep, provided that the same amount of sections were taken. Sections were stained with hematoxylin-eosin (Sikandar et al., 2013) (Figure 13, Figure 14, Figure 15, Figure 16, Figure 17, Figure 18).

### Image Analysis

Just before counting on the image, the images of the sections were photographed through a microscope x4 objective under an Olympus CX31 brand microscope (Olympus U-TV0, 5XC-3 Tokyo Japan). By counting the images obtained in this way through the Shtereom I program, all volume values of the cortex, medulla and cerebellum were calculated independently (Oguz et al., 2007). Cavalieri's Principle, which is valid for stereological methods, was used (Gundersen and Jensen, 1987; Sahin et al; 2001; Odaci et al., 2004). Since the numerical values of the points indicate volume value, the number of points was used in volume calculations (Howard and Reed, 1998; Howard and Reed, 2005). In the light of the volume values obtained as a result of the calculations, the volume values of the right-left hemispherium cerebelli and vermis cerebelli of female and male sheep were calculated and compared.

### Determining the Coefficient of Error in Volume Calculations

The fact that coefficient of error of volume values found in the studies is less than 5% shows that values of that study are close to reality and are safe (Gundersen and Jensen 1987; Gundersen et al., 1999; Mouton

2002; Garcia-Finana et al., 2003;). In this study, the coefficient of error was calculated to be lower than 5%.

### Shrinkage Rate of Cerebellum Tissue

While determining shrinkage value of values obtained as a result of the measurement of cerebellum tissue on the preparation with the help of calipers, according to average size values of tissues kept in 10% formaldehyde, this value was calculated to be 0.02382. This was the shrinkage rate of cerebellum tissue.

In statistical evaluation, Mann-Whitney U analysis was performed to compare total volume of cerebellum, average volume of medulla and cortex parts, CE and Noise values according to gender. SPSS (IBM SPSS for Windows, Ver 23) statistical program was used for statistical calculations.

## RESULTS

In general evaluation of results of the study, when all volume values of cerebellum were examined, it was seen that highest total volume value belonged to right hemispherium cerebelli of F1 (Figure 1C), while the highest volume value in male was calculated in right hemispherium cerebelli of M3 (Figure 2C). Likewise, it was determined that lowest total volume value belonged to vermis cerebelli of F5 (Figure 3C) and M2 (Figure 4C). When cerebellum was considered as a whole, it was determined that volume values of right hemispherium cerebelli of males were highest among volume values of males and females.

Considering volume values of medulla part of cerebellum, it was observed that highest medulla volume in females belonged to the left hemispherium cerebelli of F3 (Figure 5C), while highest value in males was calculated in right hemispherium cerebelli of M5 (Figure 2C). Lowest medulla volume was detected in vermis cerebelli of F5 in females (Figure 3C), while it was calculated in vermis cerebelli of M5 in males. When the mean volume of medulla was examined, it was stated that mean volume of right hemispherium cerebelli in male was higher than the others.

When volume of cortex was evaluated, it was seen that highest cortex volume was detected in left hemispherium cerebelli of F4 (Figure 5C), while it was reported that right hemispherium cerebelli of M2 had highest cortex volume in male (Figure 2C). Lowest cortex volume was calculated in vermis cerebelli of F3 in females (Figure 3C), while lowest value in

males was determined in vermis cerebelli of M5 (Figure 4C). When mean volume of cortex was evaluated, it was determined that this value was higher in left hemisphere cerebelli of females.

When total, medulla and cortex volume evaluation of Coefficient of Error (CE) values were considered, it was seen that these values were very close to each other. The fact that highest value is 0.042 and smallest value is 0.035 shows that values are close to each other and that accuracy and reliability rate of the study is high (Figure 1A, Figure 2A, Figure 3A, Figure 4A, Figure 5A, Figure 6A).

In total, medulla and cortex volume evaluation of noise (N) values, highest total N value was detected in right hemisphere cerebelli of M3 in males (Figure 2B), while highest total N value in females was detected in right hemisphere cerebelli of F1 (Figure 1B). While lowest total N value was found in vermis cerebelli of M5 in males (Figure 4B), lowest total N value was calculated in vermis cerebelli of F5 in females (Figure 3B). It was found that mean total N value was higher in right hemisphere cerebelli of males than in other parts of female and male cerebellum.

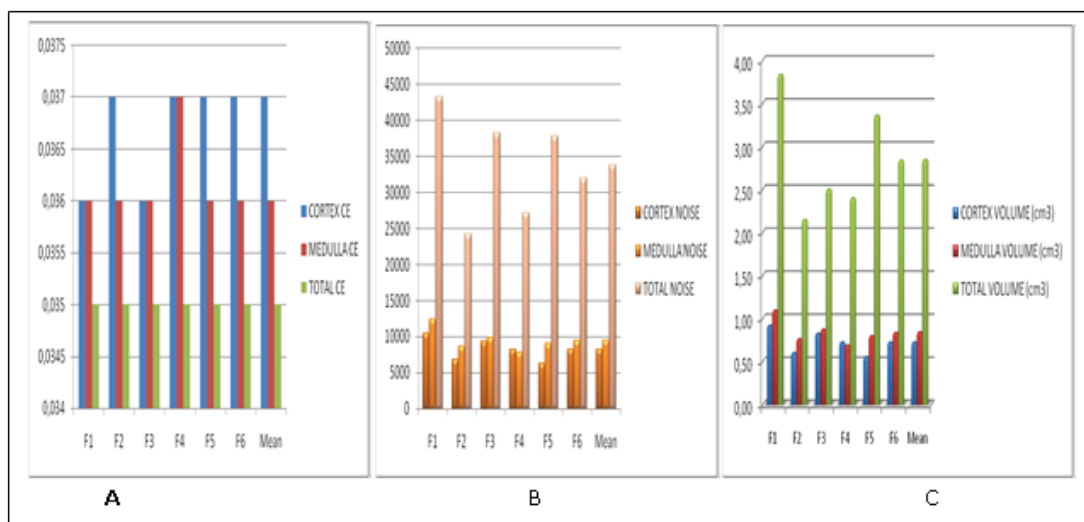
Likewise, while highest medulla N value was calculated in right hemisphere cerebelli of M5 in males (Figure 2B), highest medulla N value was detected in left hemisphere cerebelli of F5 in females. While lowest medulla N value was determined in vermis cerebelli of M5 in males (Figure 4B), lowest medulla N value was detected in vermis cerebelli of F5 in females (Figure 3B). It was found that mean medulla N value was higher in right hemisphere

cerebelli of males than in other parts of female and male cerebellum.

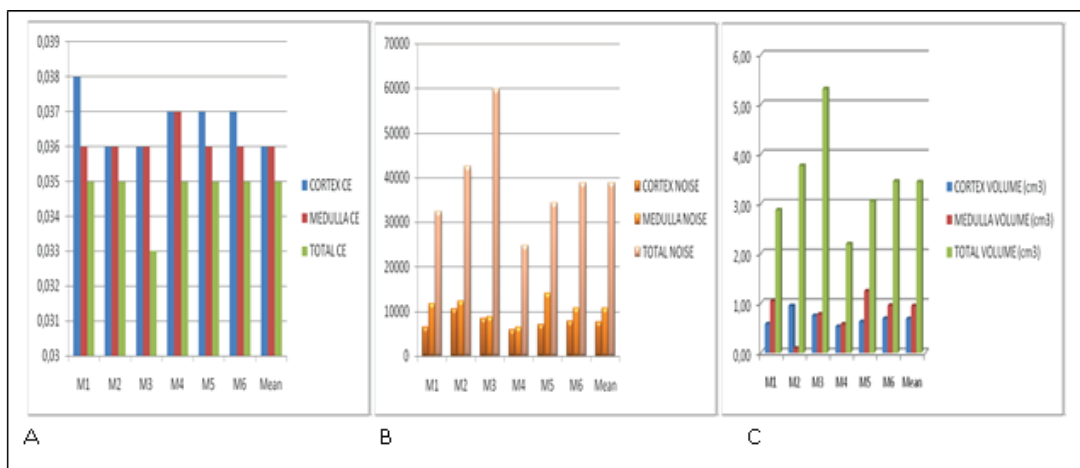
While highest cortex N value was calculated in right hemisphere cerebelli of M2 in males (Figure 2B), highest cortex N value was determined in left hemisphere cerebelli of F4 in females (Figure 5B). While lowest cortex N value was seen in vermis cerebelli of M5 in males (Figure 4B), lowest cortex N value in females was found in vermis cerebelli of F3 (Figure 3B). It was determined that mean cortex N value was higher in left hemisphere cerebelli of females compared to male and other female cerebellum parts.

Additionally, cortex/total volume, medulla/total volume and cortex/medulla volume values were calculated for right and left hemispheres and vermis in female and male Norduz sheep and were stated in Figure 7, Figure 8, Figure 9, Figure 10, Figure 11, and Figure 12.

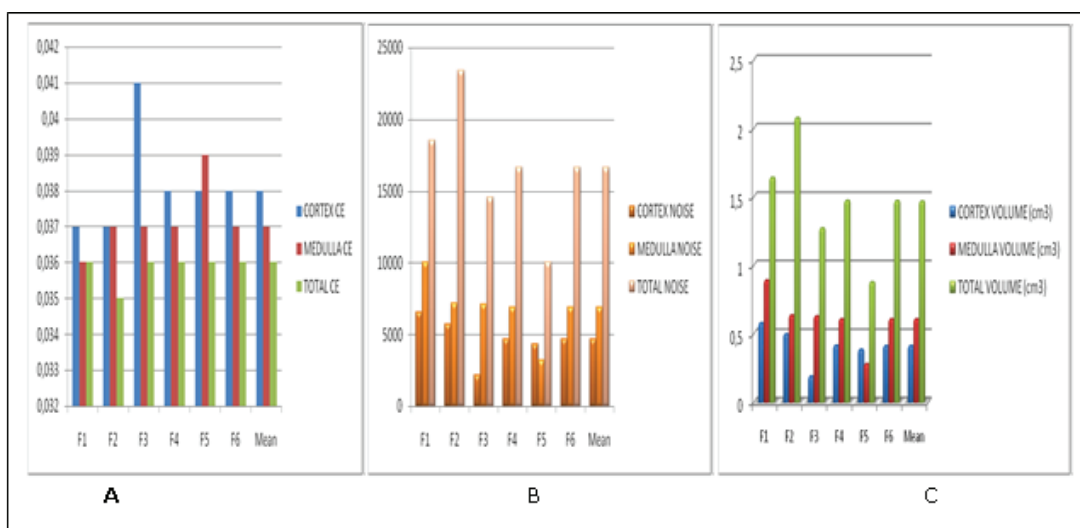
When examined in general terms, when cerebellum volumes of female and male Norduz sheep were compared, it was determined that there was no statistical difference ( $p>0.05$ ). However, only left hemisphere cerebelli volume being higher in females was found to be statistically significant ( $p<0.05$ ) (Table 1). In general, no difference could be detected in terms of CE, noise and total volume values in terms of cortex, medulla and all tissues, while the only difference between genders was detected in medulla part of hemisphere cerebelli sinister, and this difference was revealed as medulla volume was higher in female sheep.



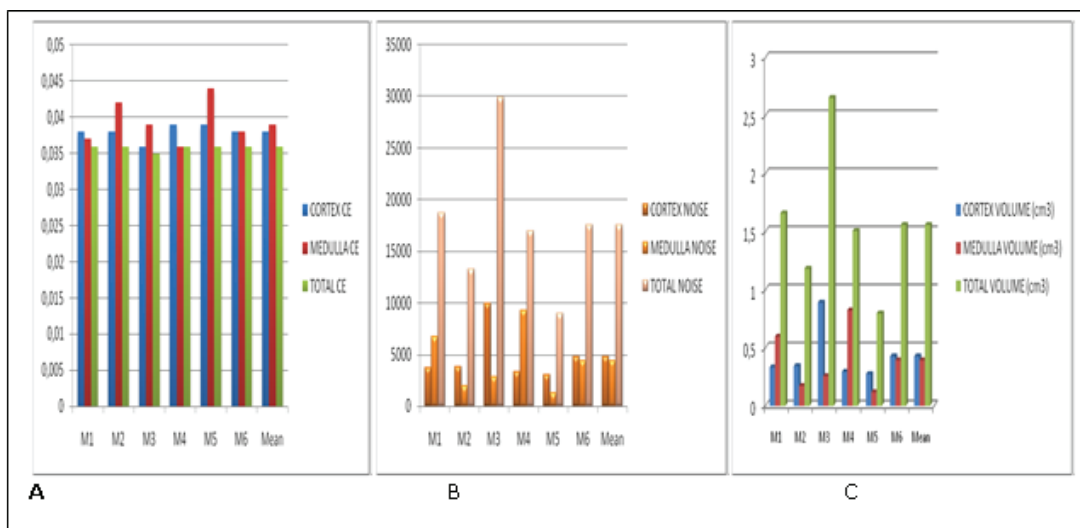
**Figure 1.** Coefficient of Error (CE), number of points (Noise) and total volume values of the total, medulla and cortex parts of the right hemisphere cerebelli in female Norduz sheep.



**Figure 2.** Coefficient of Error (CE), number of points (Noise) and total volume values of the total, medulla and cortex parts of the right hemisphere cerebelli in male Norduz sheep.



**Figure 3.** Coefficient of Error (CE), number of points (Noise) and total volume values of the total, medulla and cortex parts of the vermis cerebelli in female Norduz sheep.



**Figure 4.** Coefficient of Error (CE), number of points (Noise) and total volume values of the total, medulla and cortex parts of the vermis cerebelli in male Norduz sheep.

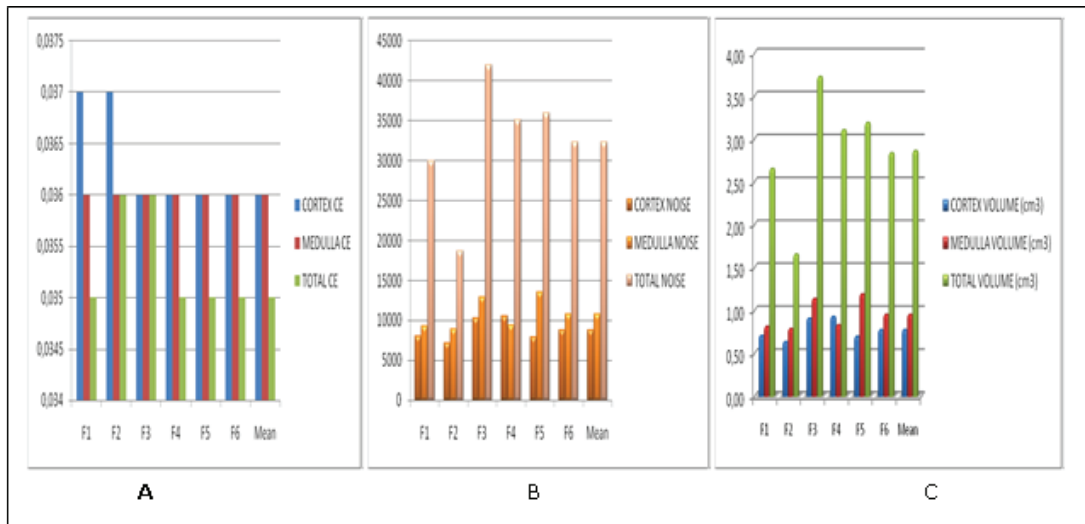


Figure 5. Coefficient of Error (CE), number of points (Noise) and total volume values of the total, medulla and cortex parts of the left hemispherium cerebelli in female Norduz sheep.

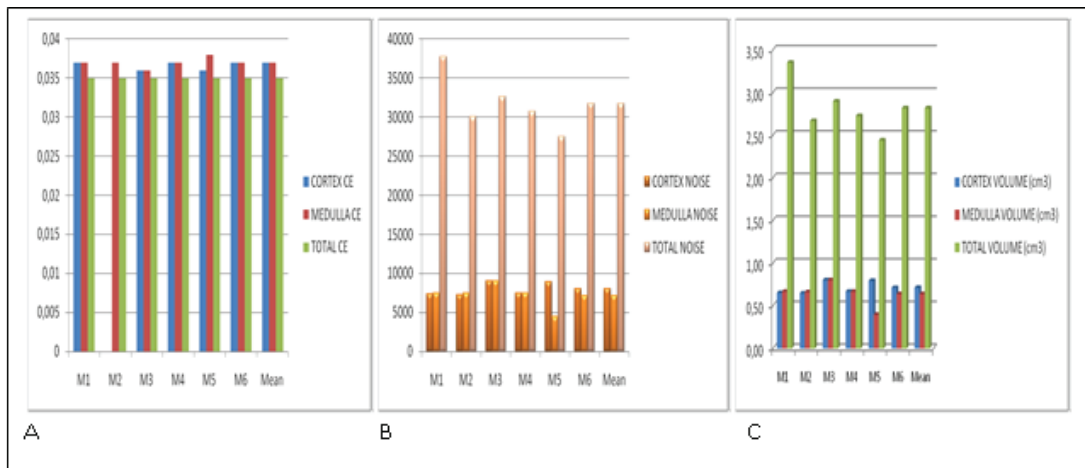


Figure 6. Coefficient of Error (CE), number of points (Noise) and total volume values of the total, medulla and cortex parts of the left hemispherium cerebelli in male Norduz sheep.

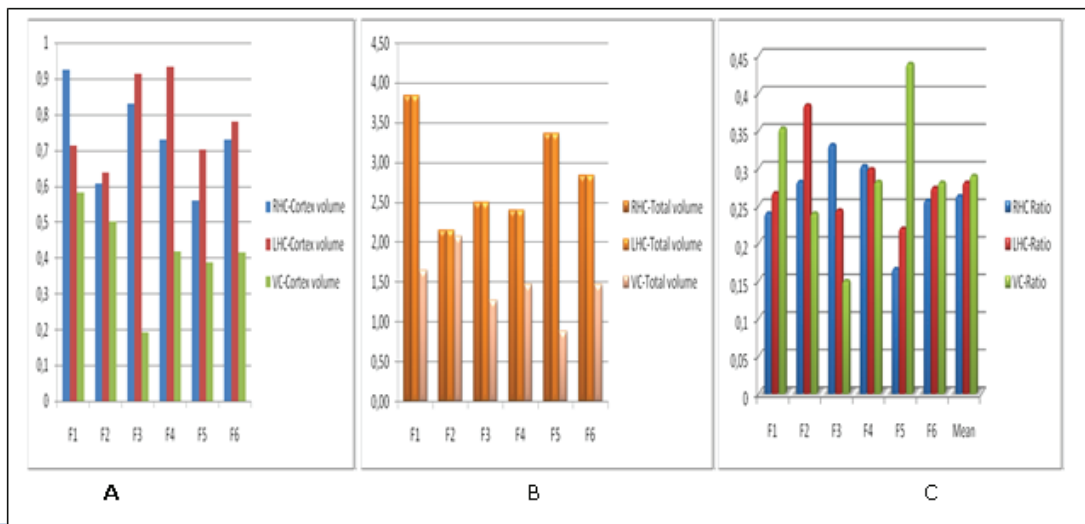
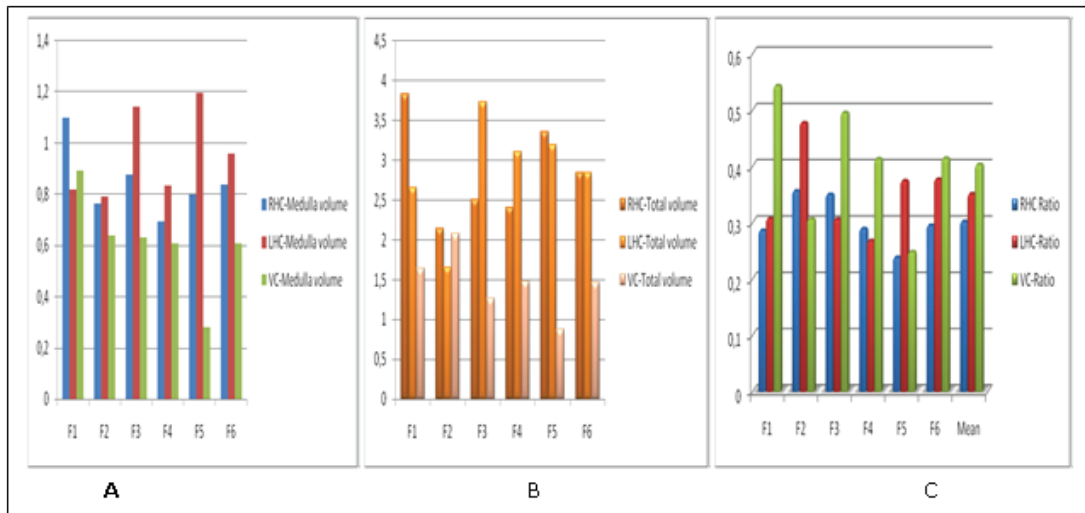
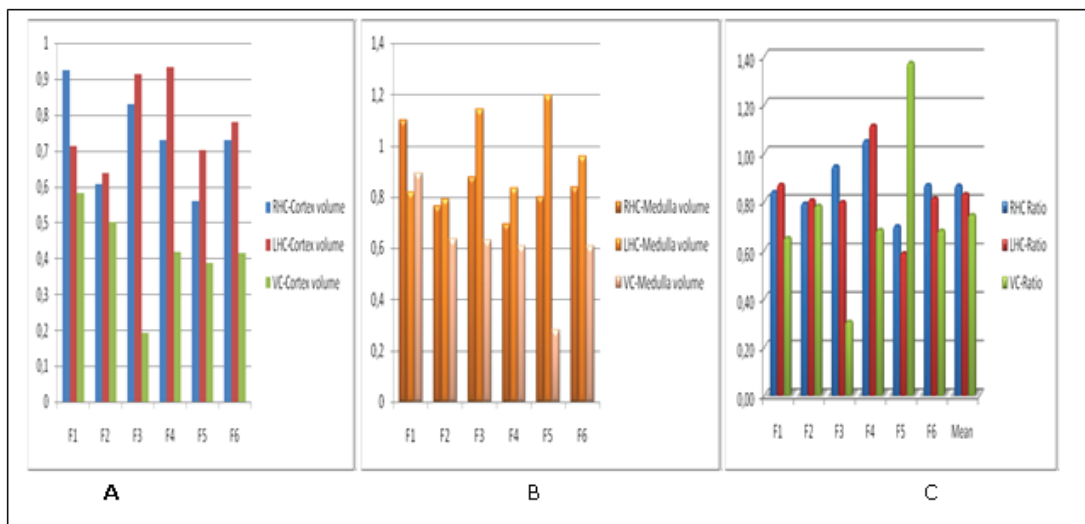


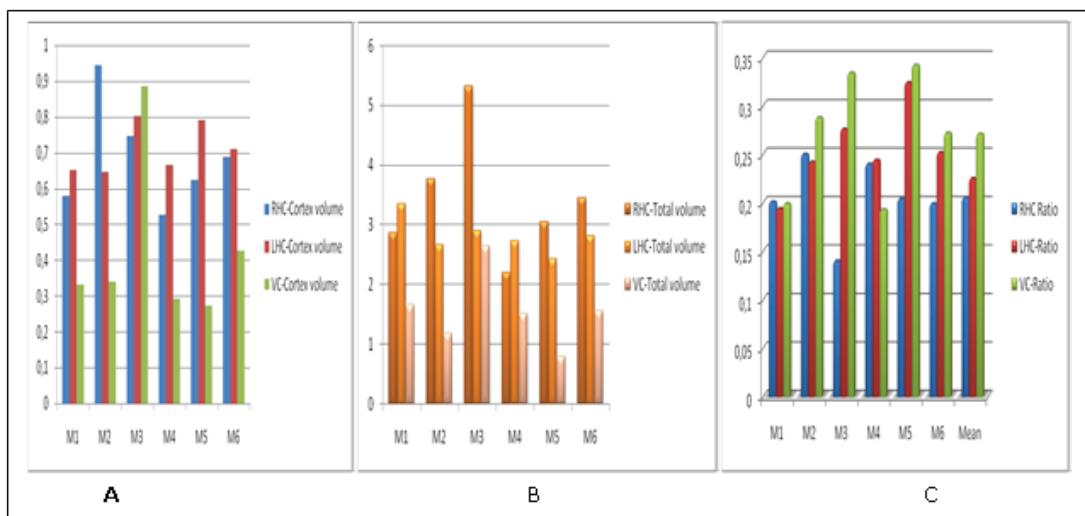
Figure 7. Cortex/total volume ratios of right hemispherium cerebelli, left hemispherium cerebelli and vermis cerebelli in female Norduz sheep.



**Figure 8.** Medulla/total volume ratios of right hemisphere cerebelli, left hemisphere cerebelli and vermis cerebelli in female Norduz sheep.

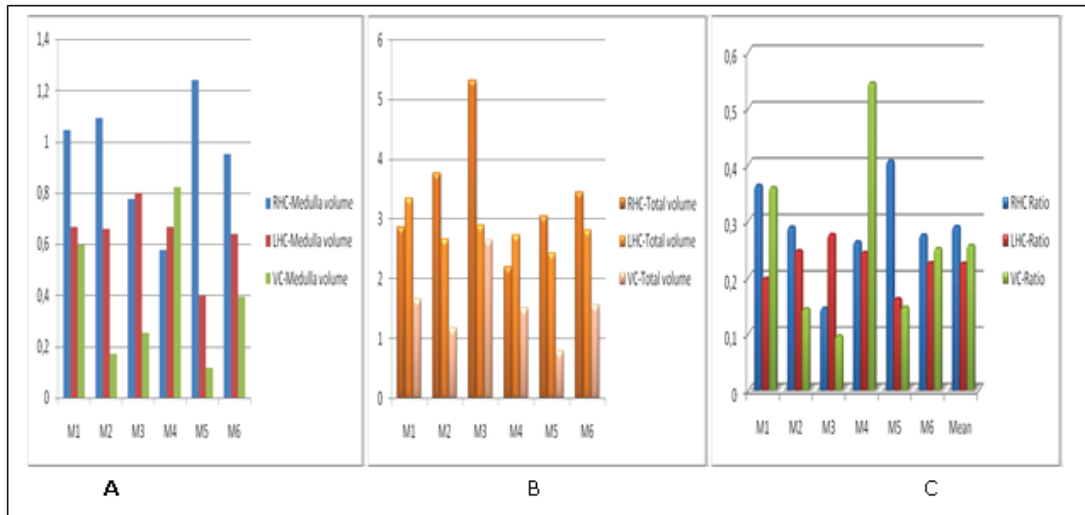


**Figure 9.** Cortex/medulla volume ratios of right hemisphere cerebelli, left hemisphere cerebelli and vermis cerebelli in female Norduz sheep.

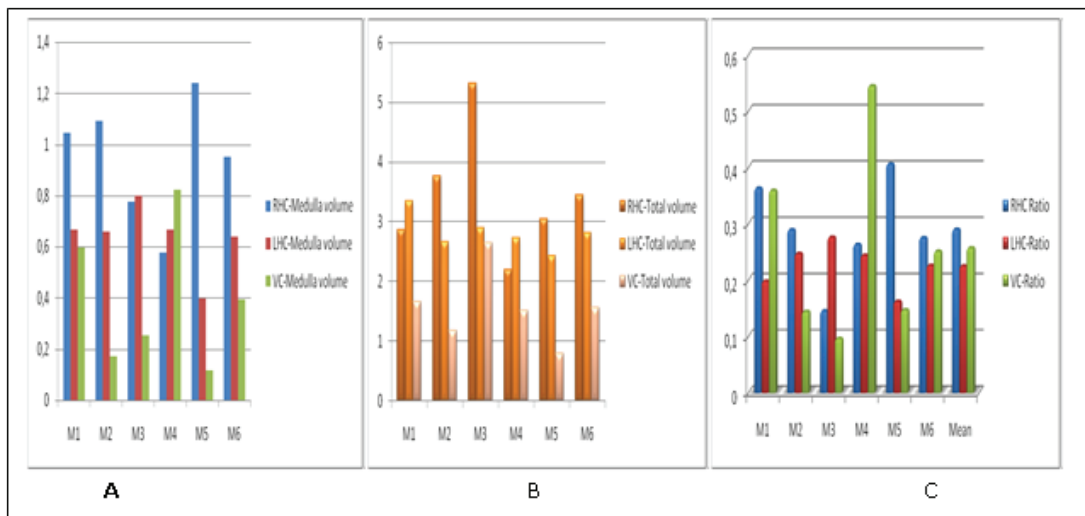


**Figure 10.** Cortex/total volume ratios of right hemisphere cerebelli, left hemisphere cerebelli and vermis cerebelli in male Norduz sheep.

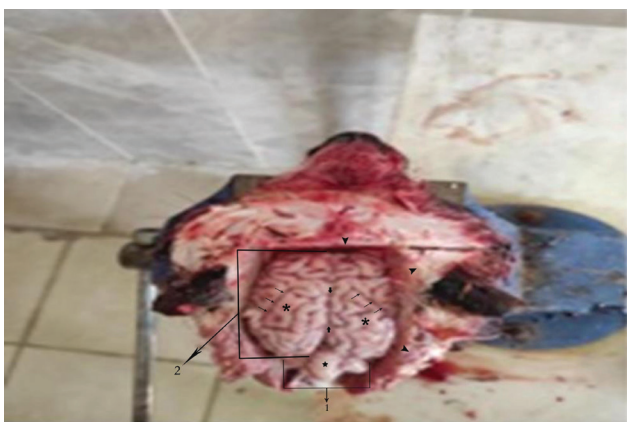



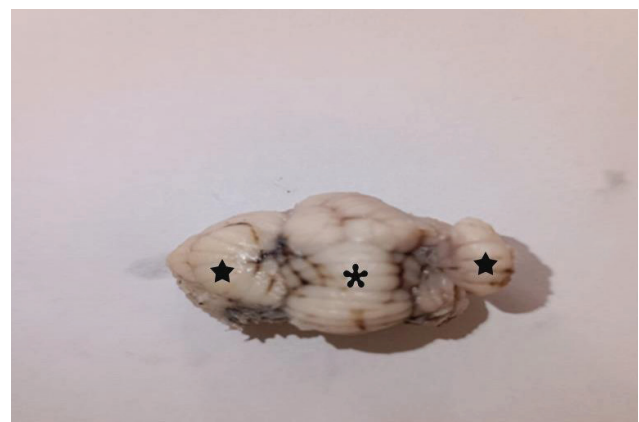**Figure 11.** Medulla/total volume ratios of right hemispherium cerebelli, left hemispherium cerebelli and vermis cerebelli in male Norduz sheep.



**Figure 12.** Cortex/medulla volume ratios of right hemispherium cerebelli, left hemispherium cerebelli and vermis cerebelli in male Norduz sheep.



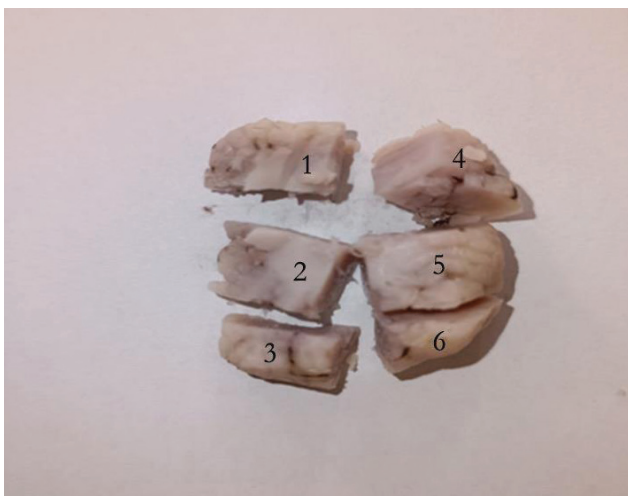
**Figure 13.** Dissection of the brain as a whole in the Norduz sheep skull.



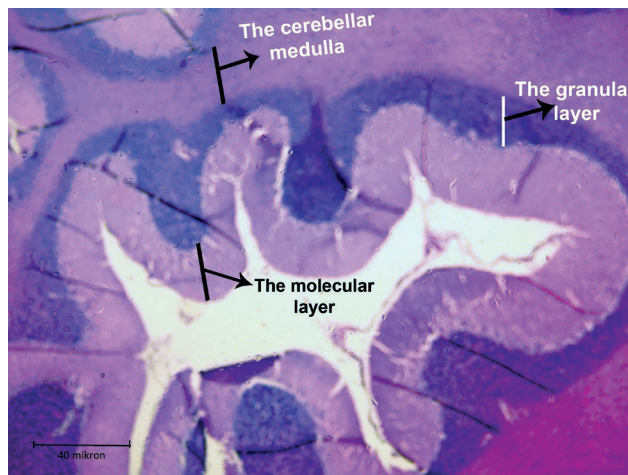
**Figure 14.** Dissected cerebellum.

fly: vermis cerebelli, star: hemispherium cerebelli

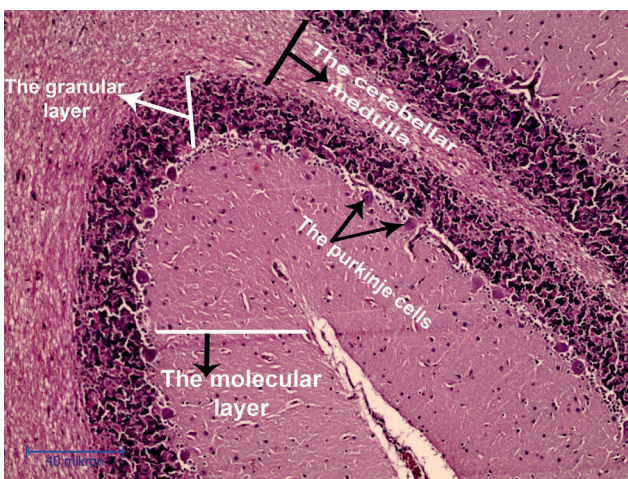
1: cerebellum, 2: hemispherium cerebri, star: vermis cerebelli, arrowhead: cavum cranii



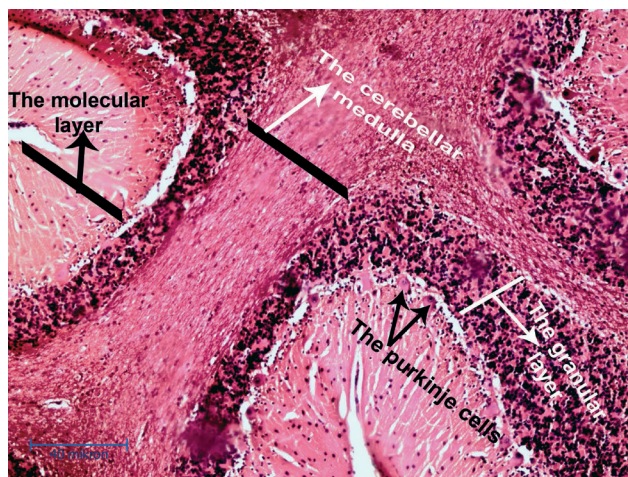
**Figure 15.** Cerebellum samples (1, 2, 3, 4, 5, 6) (Sequential random sampling in tissue)



**Figure 16.** Cerebellum in Norduz sheep (x4).



**Figure 17.** Medulla and cortex of the cerebellum in Norduz sheep (x10).



**Figure 18.** Cortex and medulla of the vermis cerebelli in Norduz sheep (x10)

**Table 1.** Statistical evaluations of cerebellum total volume, medulla volume, cortex volume, medulla/cortex volume, cortex/total volume, medulla/total volume and medulla/cortex volume in male and female Norduz sheep.

		Variable	Gender	N	Mean	Standard deviation	Minimum	Maximum	P
Vermis	Cortex	CE	Female	6	0.03817	0.001472	0.037	0.041	NS
			Male	6	0.03800	0.001095	0.036	0.039	
			Total	12	0.03808	0.001240	0.036	0.041	
	NOISE	Female	6	4695.50	1479.960	2166	6552	NS	
		Male	6	4798.67	2614.809	3072	9999		
		Total	12	4747.08	2026.405	2166	9999		
	TOTAL VOLUME	Female	6	0.41533	0.130612	0.192	0,581	NS	
		Male	6	0.42467	0.232565	0.272	0.887		
		Total	12	0.42000	0.179897	0.192	0.887		

	Variable	Gender	N	Mean	Standard deviation	Minimum	Maximum	P
Medulla	CE	Female	6	0.03717	0.000983	0.036	0.039	NS
		Male	6	0.03933	0.003077	0.036	0.044	
		Total	12	0.03825	0.002454	0.036	0.044	
	NOISE	Female	6	6890.00	2189.222	3189	10071	NS
		Male	6	4425.33	3061.084	1323	9261	
		Total	12	5657.67	2845.066	1323	10071	
	TOTAL VOLUME	Female	6	0.61067	0.194368	0.282	0.893	NS
		Male	6	0.39183	0.271472	0.117	0.821	
		Total	12	0.50125	0.252451	0.117	0.893	
Total	CE	Female	6	0.03583	0.000408	0.035	0.036	NS
		Male	6	0.03583	0.000408	0.035	0.036	
		Total	12	0.03583	0.000389	0.035	0.036	
	NOISE	Female	6	16644.50	4428.056	10017	23436	NS
		Male	6	17565.00	7008.204	8964	29889	
		Total	12	17104.75	5609.691	8964	29889	
	TOTAL VOLUME	Female	6	1.47050	0.396926	0.880	2.079	NS
		Male	6	1.55783	0.621644	0.795	2.651	
		Total	12	1.51417	0.499349	0.795	2.651	
Right hemispherium	Cortex CE	Female	6	0.03667	0.000516	0.036	0.037	NS
		Male	6	0.03683	0.000753	0.036	0.038	
		Total	12	0.03675	0.000622	0.036	0.038	
	NOISE	Female	6	8237.00	1525.589	6318	10416	NS
		Male	6	7715.17	1677.754	5934	10632	
		Total	12	7976.08	1552.954	5934	10632	
	TOTAL VOLUME	Female	6	0.73033	0.135547	0.560	0.924	NS
		Male	6	0.68400	0.148983	0.526	0.943	
		Total	12	0.70717	0.137935	0.526	0.943	
Medulla	CE	Female	6	0.03617	0.000408	0.036	0.037	NS
		Male	6	0.03617	0.000408	0.036	0.037	
		Total	12	0.03617	0.000389	0.036	0.037	
	NOISE	Female	6	9550.50	1568.793	7842	12408	NS
		Male	6	10673.00	2680.254	6510	13992	
		Total	12	10111.75	2174.321	6510	13992	
	TOTAL VOLUME	Female	6	0.84667	0.139140	0.695	1.100	NS
		Male	6	0.94650	0.237824	0.577	1.241	
		Total	12	0.89658	0.192944	0.577	1.241	
Total	CE	Female	6	0.03500	0.000000	0.035	0.035	NS
		Male	6	0.03467	0.000816	0.033	0.035	
		Total	12	0.03483	0.000577	0.033	0.035	
	NOISE	Female	6	33828.00	7322.653	24240	43344	NS
		Male	6	38804.33	11985.539	24696	59904	
		Total	12	36316.17	9819.571	24240	59904	
	TOTAL VOLUME	Female	6	2.84983	0.639622	2.150	3.837	NS
		Male	6	3.44217	1.063183	2.191	5.314	
		Total	12	3.14600	0.891880	2.150	5.314	

		Variable	Gender	N	Mean	Standard deviation	Minimum	Maximum	P	
Left hemispherium	Cortex	CE	Female	6	0.03633	0.000516	0.036	0.037	NS	
			Male	6	0.03667	0.000516	0.036	0.037		
			Total	12	0.03650	0.000522	0.036	0.037		
		NOISE	Female	6	8788.67	1338.840	7206	10512	NS	
			Male	6	8023.67	784.294	7284	9036		
			Total	12	8406.17	1119.811	7206	10512		
	TOTAL VOLUME	Female	6	0.77983	0.119354	0.639	0.932	NS		
		Male	6	0.71100	0.070017	0.646	0.801			
		Total	12	0.74542	0.099979	0.639	0.932			
	Medulla	CE	Female	Female	6	0.03600	0.000000	0.036	0.036	0,015
				Male	6	0.03700	0.000632	0.036	0.038	
				Total	12	0.03650	0.000674	0.036	0.038	
NOISE			Female	6	10794.00	1971.389	8928	13488	0.004	
			Male	6	7194.00	1490.707	4464	9036		
			Total	12	8994.00	2512.205	4464	13488		
TOTAL VOLUME		Female	6	0.95717	0.174874	0.792	1.196	0.004		
		Male	6	0.63783	0.132042	0.396	0.801			
		Total	12	0.79750	0.222792	0.396	1.196			
Total		CE	Female	Female	6	0.03533	0.000516	0.035	0.036	NS
				Male	6	0.03500	0.000000	0.035	0.035	
				Total	12	0.03517	0.000389	0.035	0.036	
	NOISE		Female	6	32348.00	7824.285	18720	42042	NS	
			Male	6	31735.17	3437.112	27480	37764		
			Total	12	32041.58	5770.556	18720	42042		
	TOTAL VOLUME	Female	6	2.86483	0.694187	1.660	3.729	NS		
		Male	6	2.81500	0.304880	2.438	3.350			
		Total	12	2.83992	0.511832	1.660	3.729			

NS: Not Significant,  $p < 0.005$

## DISCUSSION

In a study, Aydogdu (2016) aimed to calculate volume values of ventriculus lateralis, white and grey matter of brain hemispheriums in hair goats and Akkaraman sheep stereologically with help of the Cavalieri method. The obtained images were examined with the ImageJ program. By this program, the area and volume measurement values of white and grey matter and ventriculus lateralis were calculated using the Cavalieri's Principle. In the light of the data obtained, no asymmetrical situation was observed in right and left hemispheriums of the hair goat and Akkaraman sheep. When hemispherium volume values of the hair goat and Akkaraman sheep were compared, no statistically significant difference was found. A significant difference was found in right ventriculus within left and right ventriculus lateralis and in substantia alba, in favor of left substantia alba in the hair goat. The common aspect of both studies is that animals and materials used in the study belong to nervous system. But this study conducted by Aydogdu

(2016) was considered at a macro level and concluded accordingly. However, our study was planned at the micro level. In this respect, both studies do not overlap. The studies also differ in terms of the dyes used and the program chosen for volume evaluation. What both studies have in common is the use of Cavalieri method when measuring volume in nervous system organs. Additionally, in the study conducted by Aydogdu (2016), gender differences were not taken into account. As a result of statistical analysis in our study, a significant difference was detected between the volumes of the hemispherium cerebelli sinisters of male and female sheep.

In a study in which morphometric changes occurring in spinal cord during prenatal period in sheep were investigated using stereological methods, 20 healthy sheep fetuses were divided into four groups and examined. Systematic random sampling method was preferred to ensure that stereological calculations were unbiased. Cavalieri's Principle was preferred to

compare volume of grey and white matter, and their volumes with each other and to proportion them with volume of central canal, and to determine volumes of the entire spinal cord and its various regions. As a result, no significant increase in volume ratios was found (Sadeghinezhad et al., 2018). Sadeghinezhad et al. (2018) in their study is similar to this study in terms of the animal and organ they preferred, the fact that fetus was preferred makes both studies different in this sense. Sequential random sampling, which was applied in the mentioned study, was also used in this study. Sadeghinezhad et al. (2018), while examining volume values of spinal cord of sheep, volume values of white matter and grey matter parts were calculated separately. In this study, parts of cerebellum tissue, cortex, medulla and whole tissue volume were evaluated separately. Both studies are similar in this respect. In addition, Cavalieri Principle was preferred in volume calculations in both studies.

The aim of a different study conducted by Eken (2008) was to determine volume of grey and white in brain of Akkaraman crossbred sheep. For this purpose, 8 Akkaraman crossbred sheep brains were used as material. Sheep brains were kept in formaldehyde solution for one month. For calculating volumes of the brains, Archimedes' Principle was applied by placing them in a container filled with water. Then, the brains were kept in agar-agar. Serial sections with a maximum thickness of 1.6 mm were taken from the brains macroscopically with a salami machine. The white and grey matter in the sections were stained with Giemsa to better distinguish them. Pictures were taken from the obtained images with a digital imaging system. Using the Image J program, the area and volume of white and grey matter were calculated with the Cavalieri's Method. As a result, no difference in volume and area was found between right and left hemispheres and right and left white matter in Akkaraman crossbred sheep brain. In this study, Eken (2008) examined the central nervous system. Unlike Eken (2008), who did not consider gender differences, this study took into account gender differences. Additionally, in the study conducted by Eken (2008), histological sections were not preferred. However, histological sections were used in this study. In both studies, physical dissector was chosen. In addition, Eken (2008) also used the Archimedes' Principle, which is preferred in classical volume calculations, in his study. In this study, volume calculation comparison using the Archimedes' Principle was not preferred. Because it is known that the closest volume

calculation method to reality is stereological methods and the Cavalieri's Principle. At the same time, Cavalieri's Principle was used for volume calculations in both studies. The studies overlap in this signification. At the same time, in the study conducted by Eken (2008), volume values of white and grey matter regions of brain were calculated separately. In this study, it was preferred to calculate volume values of cortex and medulla regions of cerebellum separately. Both studies are similar to each other in this area. Eken (2008) used giemsa in staining. He also made volume calculation using the Image J program. However, in our study, while hematoxylin-eosin was preferred for staining, Shtereom I program was preferred for volume calculation.

In another study, it was aimed to examine stereologically medulla oblongata volume of Norduz sheep raised in Norduz region of Gurpınar district of Van province (Ertas and Cakmak, 2023). A total of 12 heads of Norduz sheep, 6 females and 6 males, were provided. Tissues obtained from medulla oblongata by sequential random sampling were submitted for tissue tracking. After tissue tracking, 10-12 sections of 5 $\mu$ m thickness were taken by sequential random sampling method. These obtained sections were stained with the hematoxylin and eosin staining method. These sections were then photographed. Total medulla oblongata volume, medulla and cortex volume values were calculated separately from the obtained images using the Shtereom I program. Cavalieri's Principle was used when applying stereological methods for volume calculations. When our study was compared to the study conducted by Ertas and Cakmak (2023), sequential random sampling with a thickness of 5  $\mu$ m was performed using the physical dissection method of the Cavalieri's Principle in both studies. At the same time, the staining methods of both works are the same. Ertas and Cakmak (2023) focused on Norduz sheep as material in his study. The studies also show parallelism in terms of material selection. Again, in both studies, nervous system organs were preferred. As in the study by Ertas and Cakmak (2023), differences between male and female individuals were taken into account in this study.

## CONCLUSIONS

As a result of the study, when the cerebellum was considered as a whole, it was determined that volume values of right hemispherium cerebelli of males were highest among volume values of males and females. When mean volume of medulla was examined, it

was stated that mean volume of right hemispherium cerebelli in males was higher than the others. When mean volume of cortex was evaluated, it was determined that this value was higher in left hemispherium cerebelli of females. When total, medulla and cortex volume evaluation of Coefficient of Error (CE) values are considered, it was seen that these values were very close to each other. The fact that highest value is 0.042 and the smallest value is 0.035 shows that values are close to each other and the accuracy and reliability of the study is high. It was found that mean total N value was higher in right hemispherium cerebelli of males than in other parts of female and male cerebellum. It was found that mean medulla N value was higher in right hemispherium cerebelli of males than in other parts of female and male cerebellum. It was determined that mean cortex N value was higher in left hemispherium cerebelli of females compared to male and other female cerebellum parts. As a result of this study when examined in general terms, when cerebellum volumes of female and male

Norduz sheep were compared, it was determined that there was no statistical difference ( $p>0.05$ ). However, only left hemispherium cerebelli volume being higher in females was statistically significant ( $p<0.05$ ).

This study we have conducted can be a reference data in anatomy, histology, neurobiology, neuroscience and many other fields, and that it can guide future studies on the nervous system on the Norduz sheep and also lead to different studies in the field of stereology.

#### **ACKNOWLEDGEMENTS**

This study was summarized from the master's thesis entitled "Stereological Investigation of Cerebellum Volume in Norduz Sheep." We want to thank Van Yuzuncu Yil University, Faculty of Veterinary Medicine, Department of Pathology.

#### **CONFLICT OF INTEREST**

The authors declare that there are no conflicts of interest.

## REFERENCES

- Aydogdu S (2016) Volumetric Estimation of the gray/white matter and lateral ventricles on the brain hemispheres in Akkaraman sheep and hair goat using Cavalieri Principle (Master's Thesis). Selcuk University Health Sciences Institute.
- Bingol M (1998). Norduz Koyunlarının Döl ve Süt Verimi ile Büyüme-Gelişme ve Dış Yapı Özellikleri (Doctorate Thesis). Van Yüzüncü Yıl Üniversitesi Fen Bilimleri Enstitüsü, Van.
- Cruz-Orive LM, Weibel ER (1990) Recent stereological methods for cell biology: a brief survey. *Am J Physiol Lung Cell Mol Physiol* 258:148-156.
- Dayan Y, Bingöl M (2008) The Structural Properties of Some Rural Farms Performed Norduz Sheep Breeding. *Yuzuncu Yil Univ J Agric Sci* 13:31-34.
- Eken E (2008) The determination of the volume of substantia alba and substantia grisea in akkaraman cross breed sheep (Master's Thesis). Selcuk University Health Sciences Institute.
- Ertas O, Cakmak G (2023) Stereological investigation of medulla oblongata volume in Norduz sheep. *Turkish J Vet Anim* 47:334-344
- Garcia-Finana M, Cruz-Orive LM, Mackay CE, Pakkenberg B, Roberts N (2003) Comparison of MR imaging against physical sectioning to estimate the volume of human cerebral compartments. *Neuroimage* 18:505-516.
- Gokdal O, Ulker H, Oto MM, Temur C, Budag Cemal (2000) Different production traits and body measurements of Karakas sheep in rural farm conditions *J Agric Sci* 10:103-111.
- Gundersen HJG, Jensen EB (1987) The efficiency of systematic sampling in stereology and its prediction. *J Microsc* 147:229-263.
- Gundersen HJG, Jensen EBV, Kieu K, Nielsen J (1999) The efficiency of systematic sampling in stereology-reconsidered. *J Microsc* 193:199-211.
- Howard CV, Reed MG (1998) Unbiased stereology. Three-dimensional measurement in microscopy. Bios, Oxford: pp 39-54.
- Howard CV, Reed MG (2005) Unbiased stereology. Three-dimensional measurement in microscopy. 2nd ed, Bios Scientific Publishers, Oxford.
- Keles A (2019). Quantitative method used in health field, stereology. *Dicle Univ. Dicle Medical Journal* 46:615-21.
- Mayhew TM, Gundersen HJG (1996) If you assume, you can make an ass out of u and me: A decade of the disector for stereological counting of particles in 3D space. *J Anat* 188:1-15.
- Mouton PR (2002) Principles and practices unbiased stereology. 1st ed, The Johns Hopkins University Press, United States of America.
- Odaci E, Yıldırım S, Bahadır A, Canan S, Sahin B, Bas O, Bilgic S, Kaplan S (2004). The possible error sources of new stereological methods and their solutions. *Turkiye Klinikleri J Med Sci* 24:78-87.
- Oguz OE, Konkur SE, Sari M (2007) Shterem I simple windows based software for stereology volume and number estimations. *Image Anal Stereol* 26:45-50.
- Sadeghinezhad J, Zadsar N, Hasanzadeh B (2018) Morphometric changes in the spinal cord during prenatal life: a stereological study in sheep. *Anat Sci Int* 93:269-276.
- Sahin B, Aslan H, Unal B, Canan S, Bilgic S, Kaplan S, Tumkaya L (2001). Brain volumes of the lamb rat and bird do not show hemispheric asymmetry: A stereological study. *Image Anal Stereol* 20:9-13.
- Sikandar A, Cheema AH, Younus M, Zaneb H (2013). Mycobacterium avium subspecies paratuberculosis multibacillary infection (Johne's disease) in a Teddy goat. *Pak Vet J* 33:260-262.
- Sikandar A, Adil M, Zaneb H, Arshad M, Ali HM, Khan MA, Rehman T, Nadem MA (2018). Concurrent cerebral and extra-cerebral caprine coenurosis: A case report. *Pak J Life Soc Sci* 16:55-58.
- Taner D, Sancak B, Akşit D, Cumhuri M, İlgi S, Kural E, Başar R, Önderoğlu S, Tuncel M, Çelik H, Sargon MF, Sürücü S, Taşcıoğlu B, Yener N, Durgun B, Atasever A, Özkul E (2007). *Fonksiyonel nöroanatomi*. 6th ed, ODTÜ Yayınevi, Ankara, pp 49-88.