

Journal of the Hellenic Veterinary Medical Society

Vol 75, No 4 (2024)



Efficacy of Dietary Mycotoxins Adsorbents to Toxic Effects of Zearalenone and Fumonisin in Weaned Piglets

N Puvača, S Roljević Nikolić², I Radojičić, V Bursić, G Avantaggiato, V Tufarelli, L Pinotti, I Brkić

doi: [10.12681/jhvms.37208](https://doi.org/10.12681/jhvms.37208)

Copyright © 2025, N Puvača, S Roljević Nikolić², I Radojičić, V Bursić, G Avantaggiato, V Tufarelli, L Pinotti, I Brkić



This work is licensed under a [Creative Commons Attribution-NonCommercial 4.0](https://creativecommons.org/licenses/by-nc/4.0/).

To cite this article:

Puvača, N., Roljević Nikolić², S., Radojičić, I., Bursić, V., Avantaggiato, G., Tufarelli, V., Pinotti, L., & Brkić, I. (2025). Efficacy of Dietary Mycotoxins Adsorbents to Toxic Effects of Zearalenone and Fumonisin in Weaned Piglets. *Journal of the Hellenic Veterinary Medical Society*, 75(4), 8395–8402. <https://doi.org/10.12681/jhvms.37208>

Efficacy of Dietary Mycotoxins Adsorbents to Toxic Effects of Zearalenone and Fumonisin in Weaned Piglets

N. Puvača^{1*}, S. Roljević Nikolić², I. Radojičić³, V. Bursić⁴, G. Avantaggiato⁵,
V. Tufarelli⁶, L. Pinotti⁷, I. Brkić¹

¹Department of Engineering Management in Biotechnology, Faculty of Economics and Engineering Management in Novi Sad, University Business Academy in Novi Sad, Cvečarska 2, 21000 Novi Sad, Serbia

²Research and Development Institute Tamiš Pančevo, Novoseljanski put 33, 26000 Pančevo, Serbia

³INBERG d.o.o., Braće Iker 74, 11275 Boljevci, Serbia

⁴Faculty of Agriculture, University of Novi Sad, Trg Dositeja Obradovića 8, 21000 Novi Sad, Serbia

⁵Institute of Sciences of Food Production (ISPA), National Research Council (CNR), Via Amendola, 70126 Bari, Italy

⁶Department of Precision and Regenerative Medicine and Jonian Area (DiMePRE-J), Section of Veterinary Science and Animal Production, University of Bari Aldo Moro, 70010 Valenzano, Italy

⁷Department of Health, Animal Science and Food Safety, University of Milan, Via Trentacoste, 20134 Milan, Italy

ABSTRACT: Mycotoxin contamination in animal feed poses a significant threat to animal health and productivity, particularly in swine production. Zearalenone (ZEN) and fumonisins (FBs) are among the most prevalent mycotoxins found in swine diets, exerting toxic effects on various organs and reproductive systems. This study investigates the efficacy of a dietary mycotoxin adsorbent in mitigating the toxic effects of ZEN and FBs on weaned piglets, focusing on vulva size, liver histology, and ovarian histology. A total of 60 weaned piglets were randomly assigned to different dietary treatments: control diet naturally contaminated diet with ZEN and FBs (T1), and experimental diets supplemented with the bentonite-based mycotoxin adsorbent named Mycostop Duplo® in two concentrations, i.e. 1.0 kg/ton (T2) and 2.5 kg/ton (T3) of complete feed. At the end of the trial, vulvas were pictured and measured, while liver and ovarian samples were collected for histological analysis. Results indicated that piglets fed the contaminated diet without the adsorbent exhibited significant increases in vulva size compared to the control group ($p < 0.05$). Histological examination of the liver revealed notable moderate liver dysplasia in the control group, indicative of liver damage. Similarly, ovarian histology showed alterations in follicular development and ovarian morphology in piglets exposed to ZEN. In contrast, piglets receiving the contaminated diet supplemented with the mycotoxin adsorbent showed significantly reduced vulva sizes compared to the contaminated group ($p < 0.05$). Histological analysis of liver and ovarian tissues from the adsorbent-supplemented group revealed mitigated histopathological changes compared to the contaminated group, suggesting protective effects against ZEN and FB toxicity. In conclusion, dietary supplementation with Mycostop Duplo® effectively mitigated the toxic effects of ZEN and FBs on weaned piglets, as evidenced by reduced vulva sizes and ameliorated histological changes in the liver and ovaries. These findings underscore the importance of mycotoxin management strategies in swine nutrition to safeguard animal health and welfare. Further research is warranted to optimize the use of mycotoxin adsorbents and evaluate their long-term effects on piglet growth and reproductive performance.

Keywords: piglets; mycotoxins; bentonite; nutrition, toxins.

Corresponding Author:

Nikola Puvača, Department of Engineering Management in Biotechnology, Faculty of Economics and Engineering Management Novi Sad, University Business Academy, 8 Cvečarska 2, 21000, Novi Sad, Serbia.
E-mail address: nikola.puvaca@fimek.edu.rs

Date of initial submission: 14-3-2024
Date of acceptance: 16-4-2024

INTRODUCTION

Weaned piglets, crucial assets in the swine industry, are highly susceptible to various mycotoxins, including zearalenone (ZEN) and fumonisin (FB) (Bulgaru et al., 2023; D'Mello et al., 1999). These toxins, primarily produced by fungi such as *Fusarium* species, pose significant threats to pig health and productivity (Mahato et al., 2021; Puvača, Ljubojević Pelić, & Tufarelli, 2023). ZEN is known for its estrogenic properties, leading to reproductive disorders and impaired growth in swine (Pack et al., 2020), while FB is associated with neurotoxicity, hepatotoxicity, and immune suppression (Chen et al., 2021). The co-occurrence of these mycotoxins in swine feed amplifies their adverse effects, necessitating effective mitigation strategies to safeguard piglet health and ensure sustainable swine production (Gao et al., 2020).

The contamination of feed ingredients with mycotoxins is a global concern in livestock production, including the swine industry (Čolović et al., 2019). Mycotoxins, secondary metabolites of fungi, can thrive in various climatic conditions and during different stages of crop production, leading to their widespread presence in swine feed ingredients such as corn, wheat, and soybeans (Perrone et al., 2020). ZEN and FB are among the most prevalent mycotoxins detected in swine feed, posing substantial economic and health challenges to pig producers worldwide.

Weaned piglets are particularly vulnerable to mycotoxin exposure due to their immature gastrointestinal and immune systems (Zheng et al., 2021). ZEN, upon ingestion, exerts estrogenic effects in piglets, disrupting reproductive functions and causing clinical symptoms such as vulvar swelling, vaginal discharge, and reduced fertility (Gajęcka et al., 2017). Moreover, ZEN can impair growth performance and compromise the overall health status of piglets (Dänicke et al., 2023). Similarly, FB exposure in weaned piglets is associated with various detrimental effects, including hepatic and renal damage, immunosuppression, and increased susceptibility to infectious diseases (Burel et al., 2013; Rao et al., 2020). The combined toxicity of ZEN and FB further exacerbates these adverse effects, highlighting the urgent need for effective mitigation strategies to counteract mycotoxin-induced challenges in piglet production.

Bentonite, a naturally occurring clay mineral rich in montmorillonite, has gained attention as a potential mycotoxin binder in animal feed due to its high adsorption capacity and safety profile (Puvača, Ljubo-

jević Pelić, & Tufarelli, 2023). The unique structure of bentonite facilitates the physical adsorption of mycotoxins in the gastrointestinal tract, preventing their absorption into the bloodstream and subsequent systemic effects (Rasheed et al., 2020). Several studies have investigated the efficacy of bentonite in mitigating the toxic effects of mycotoxins in various animal species (Adegbeye et al., 2020; Deng et al., 2023; Elliott et al., 2020; Hassan et al., 2019; Hussain et al., 2017; Ochieng et al., 2023), demonstrating promising results in terms of improved growth performance, reduced organ damage, and enhanced immune function.

The primary objective of this study is to evaluate the efficacy of dietary bentonite supplementation in concentrations of 1 and 2.5 kg/t of complete feed in alleviating the toxic effects of ZEN and FB in weaned piglets. Specifically, the aim is to assess the impact of bentonite on organ histopathology in piglets exposed to ZEN and FB contaminated feed. By elucidating the potential benefits of bentonite supplementation in mitigating mycotoxin-induced toxicity in piglets, this research seeks to provide valuable insights into the development of practical strategies for mycotoxin management in swine production.

MATERIALS AND METHODS

The animal study protocol was approved by the University Business Academy in Novi Sad Ethics Committee (EC22/08-123) (Puvača, Ljubojević Pelić, & Tufarelli, 2023).

Piglet feeding and experimental design

A total of 60 weaned piglets (28 days old) were randomly assigned to five dietary treatment groups (20 piglets in each group) for a duration of 42 days. All piglets in the experiment were provided with *ad libitum* access to feed and drinking water. Also, the unconsumed feed mixture was monitored. All diets were formulated to be isocaloric and isonitrogenous (Table 1). The dietary treatments included: control group T1 with no mycotoxin adsorbent; group T2 supplemented with Mycostop Duplo[®] adsorbent in amount of 1kg/t of feed; and group T3 supplemented with Mycostop Duplo[®] adsorbent in amount of 2.5kg/t of feed. Piglets were weighed on the 1st, 21st, and 42nd day of the experiment. The conversions feed intake and feed conversion were monitored for the respective experimental periods of piglet's weight control. The mortality of piglets was recorded daily.

Table 1. Analyzed nutrient composition of experimental diets (as-fed basis).

Nutrient levels	%
Crude protein	20.0
Crude fat	6.50
Crude fibre	3.0
Lysine	1.52
Methionine	0.47
Threonine	0.91
Tryptophan	0.23
Calcium	0.86
Total phosphorus	0.63
Sodium chloride	0.30
Digestible energy, MJ/kg	15.0

Digestible energy is calculated value. Other nutrient levels in the table are analyzed values.

Concentrations of mycotoxins in the complete feed samples used in piglets' diet ($\mu\text{g/kg}$ of feed), in the control and experimental groups are presented in Table 2.

Table 2. Concentrations of mycotoxins in the complete feed samples used in piglets' diet ($\mu\text{g/kg}$).

Mycotoxin	Mean value	EC permitted/guidance level (Xu et al., 2022)
Zearalenone	2892.3	100
Fumonisin	72748.1	5000

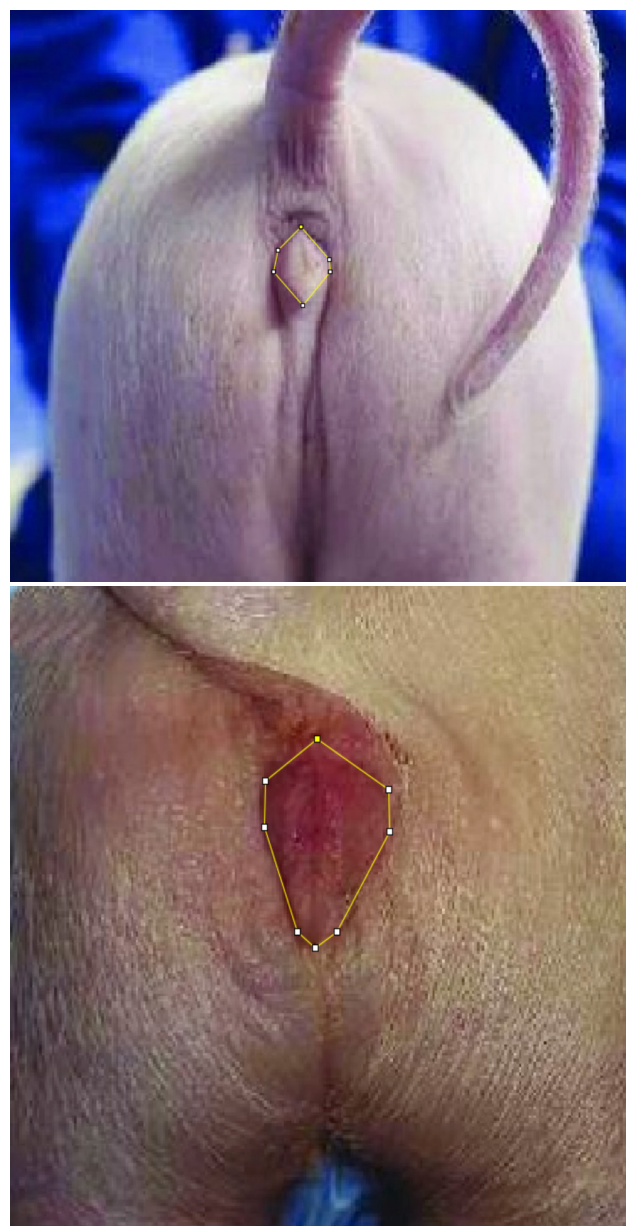Organ weights and vulva measures

At the end of the trial, piglets were subjected to electrical stunning and euthanized by exsanguination. Vulvar measurements including length, width, and area (Figure 1) were performed immediately after euthanasia. Pictures of the vulvas were taken using a digital camera, following picture analysis using the public domain image processing program ImageJ v 1.52a. Graded alcohol was used for the dehydration of the tissue samples, followed by cleaning with xylene, and then embedded in a liquid paraffin. A $5\ \mu\text{m}$ section was stained with hematoxylin-eosin for a descriptive and semiquantitative histopathological analysis in each organ evaluated.

The liver, lungs, kidneys, uterus, and ovaries were separated for evaluation.

Pathohistological tests of ovaries and liver

Ovaries were extirpated and fixed promptly in 10% buffered formalin upon weighing, as well as the liver tissue. After routine processing, the tissues were embedded in paraffin. Graded alcohol was used for the dehydration of the tissue samples, following the

**Figure 1.** Measurement and calculation of vulva size.

sectioned in pieces of $5\ \mu\text{m}$ thickness and stained with hematoxylin and eosin (H&E) for microscopic examination. The slides were examined using an optical microscope (Carl Zeiss, Germany).

Statistical analysis

Data were submitted to analysis of variance (ANOVA) using the statistical software program Statistica 13 for Windows (StatSoft, Inc., Tulsa, OK, USA), to determine whether variables differed among treatments. For multiple comparisons between treatments, the Tukey test was performed. All statements of significance were based on the 0.05 level of probability.

RESULTS AND DISCUSSION

Vulva measurements for all piglets in the experiment are shown in Table 3. Statistical significance between different dietary groups and control group in all the measures studied was found ($p < 0.05$). Compared to the groups, the length, width, and area of vulvas were higher ($p < 0.05$) in piglets from control group fed a naturally mycotoxins contaminated feed, while the supplementation of Mycostop Duplo® adsorbent in the amount of 1 kg/t, and 2.5 kg/t of feed reduced the size values, having a maximum effect with 2.5 kg/ton in group T3 ($p < 0.05$), respectively. The largest vulva area of 4.01 cm² was recorded in the control group, while the smallest vulva area of 1.84 cm² was recorded in the group treated with 2.5 kg/ton mycotoxin adsorbent. All recorded differences between experimental and control groups were statistically significant ($p < 0.05$). Vulvovaginitis is a common reproductive disorder in pigs, often associated with exposure to mycotoxins such as ZEA.

Mycotoxin adsorbents are increasingly used to mitigate mycotoxin contamination in animal feed (Puvača, Ljubojević Pelić, & Tufarelli, 2023). Understanding their mechanisms in preventing vulvovaginitis in piglets contaminated with ZEN is crucial for the effective management of this condition. Mycotoxin adsorbents function through various mechanisms, primarily adsorption, binding, and neutralization (Ndiaye et al., 2022). These adsorbents possess porous structures with high surface areas, allowing them to physically trap mycotoxins within their matrices. In our research of ZEN, adsorbents like bentonite (Mycostop Duplo®), can effectively bind the toxin molecules through electrostatic interactions, hydrogen bonding, and Van der Waals forces. This prevents ZEN from being absorbed in the gastrointestinal tract of piglets, reducing its systemic circulation and subsequent reproductive impacts, which was shown with the results given in Table 3. The prevention of vulvovaginitis in pigs contaminated with ZEN involves interrupting the estrogenic effects of the mycotoxin (Ropejko & Twarużek, 2021). Mycotoxin adsorbents play a crucial role in this process by sequestering

ZEN within the gastrointestinal tract, thereby reducing its bioavailability (Luo et al., 2020). By limiting ZEN absorption, adsorbents mitigate its estrogenic effects on the reproductive system, preventing conditions like vulvovaginitis (Buszewska-Forajta, 2020). Additionally, adsorbents may indirectly enhance gut health and immune function, further protecting piglets from mycotoxin-induced reproductive disorders (Pierron et al., 2016).

The effects of dietary treatments on the growth performance of piglets fed naturally mycotoxin-contaminated feed with or without commercial adsorbents for 42 days were previously described in detail in the research of Puvača, Ljubojević Pelić & Tufarelli (2023). The highest values of relative organ share with significant differences ($p < 0.05$) were observed in the control group compared to the experimental groups T2, and T3, except the relative ovarium weight which did not show any significant differences ($p > 0.05$) between the groups. The individual body weights of pigs at the end of the trial and their respective organ weights were used to calculate the relative weights of the liver, lungs, kidneys, ovarium, and uterus. The results were expressed as g/kg body weight, as presented in Table 4. Dietary addition of mycotoxin adsorbent led to a significant decrease ($p < 0.05$) in the relative organ share of piglets in both groups T2 and T3, at the end of the experimental period. Significant differences ($p < 0.05$) between experimental groups regarding the kidneys (0.55 and 0.48 g/kg body weight) and uterus (0.20 and 0.15 g/kg body weight) weight were observed, while significant differences regarding liver, lungs, and ovarium were not present ($p > 0.05$).

ZEA and FB are often found in contaminated feed-stuffs and can adversely affect various organs, including the liver, kidneys, lungs, uterus, and ovaries (Akbar et al., 2022; Oldenburg et al., 2017). Mycotoxin adsorbents are utilized to mitigate the adverse effects of mycotoxin contamination in animal diets. Combined effects of ZEA and FB can induce hepatotoxicity, leading to liver damage, inflammation, and altered

Table 3. Vulva size in piglets fed with a complete feed contaminated by zearalenone.

Treatments	Vulva length (cm)	Vulva width (cm)	Vulva area (cm ²)
T1	3.10 ± 0.21 ^a	2.59 ± 0.39 ^a	4.01 ± 0.22 ^a
T2	2.43 ± 0.13 ^b	2.05 ± 0.41 ^b	2.50 ± 0.26 ^b
T3	2.11 ± 0.05 ^c	1.74 ± 0.06 ^c	1.84 ± 0.04 ^c
p values	0.02	0.04	0.01

Means within a column followed by the different letters are significantly different ($p < 0.05$)

Table 4. Relative organ weights (g/kg body weight) of piglets after 42 days of intoxication.

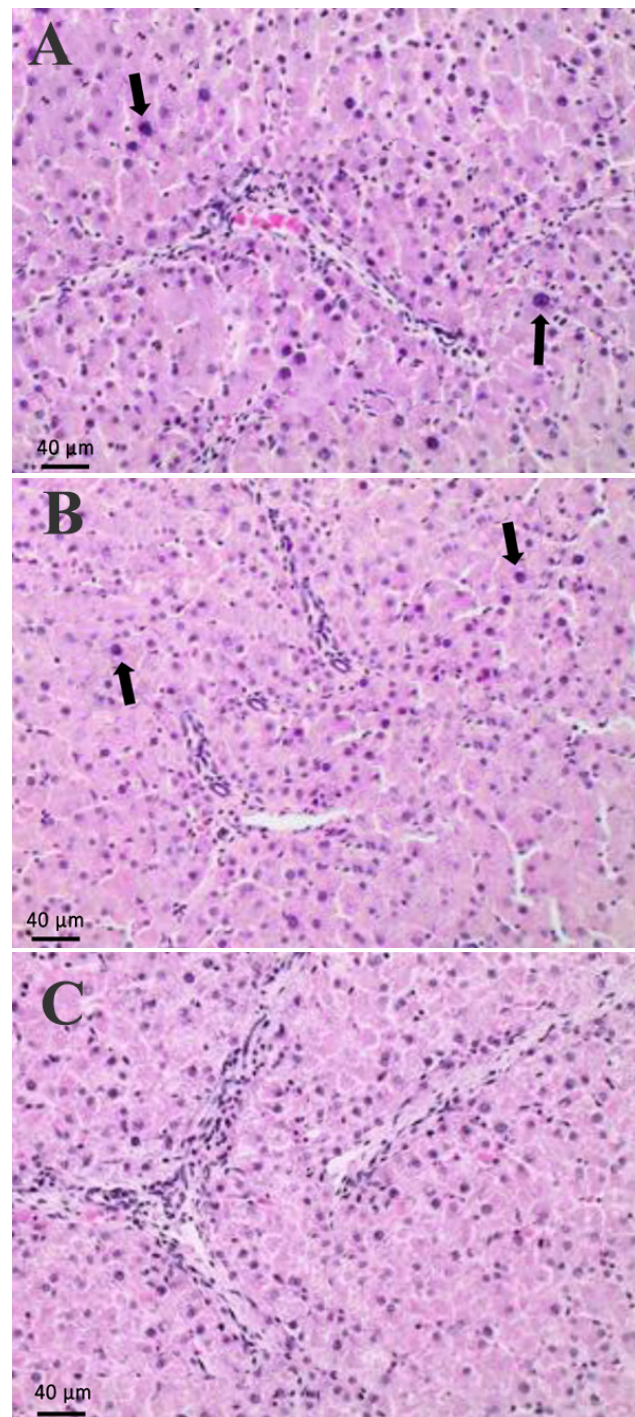
Treatments	Liver	Lungs	Kidneys	Ovarium	Uterus
T1	3.52 ± 0.22 ^a	1.46 ± 0.18 ^a	0.62 ± 0.23 ^a	0.01 ± 0.00 ^a	0.24 ± 0.02 ^a
T2	3.14 ± 0.15 ^b	1.31 ± 0.13 ^b	0.55 ± 0.17 ^b	0.01 ± 0.00 ^a	0.20 ± 0.01 ^a
T3	2.89 ± 0.07 ^b	1.29 ± 0.11 ^b	0.48 ± 0.03 ^c	0.01 ± 0.00 ^a	0.15 ± 0.01 ^b
p value	0.04	0.02	0.01	0.01	0.02

Means within a column followed by the different letters are significantly different ($p < 0.05$); Data are means ± SD of 3 female piglets per group.

hepatic function (Ben Ammar et al., 2023). These toxins may cause serious problems in animals (Gao et al., 2023) such as hepatocyte necrosis, lipid accumulation, and oxidative stress, ultimately affecting liver size and morphology (Figure 2). FBs are known nephrotoxins, capable of causing renal damage and impairing kidney function (Kócsó et al., 2018). The toxins may induce tubular necrosis, interstitial fibrosis, and glomerular lesions, resulting in changes in kidney size and structure. Although less studied, FBs have been associated with pulmonary toxicity, including inflammation, edema, and altered lung function (Soriano et al., 2005). Chronic exposure to FBs may lead to lung tissue damage and changes in lung morphology (Terciolo et al., 2019). ZEN is a potent estrogenic mycotoxin that can disrupt reproductive function in female pigs (Kinkade et al., 2021). Chronic exposure to ZEN may lead to uterine hyperplasia, ovarian cysts, and alterations in the size and structure of the uterus and ovaries, respectively, which is following our findings presented in Table 4.

From the results presented in Figure 2, it can be observed that the ZEA and FB mixture developed moderate liver dysplasia in the control group (A), while the addition of mycotoxin adsorbent in concentration of 1 kg/ton led to the mild hepatic dysplasia (B). However, dietary supplementation of mycotoxin adsorbent in group T3 in the concentration of 2.5 kg/ton of complete feed showed no liver changes (C).

FBs are known hepatotoxic mycotoxins capable of causing liver damage and altering liver histology (Cimbalo et al., 2020). Common histological findings include hepatocyte necrosis, bile duct hyperplasia, fibrosis, and periportal inflammation. These changes disrupt liver architecture and function, contributing to liver dysfunction and disease progression. Mycotoxin adsorbents function by binding them in the gastrointestinal tract, preventing their absorption and systemic distribution. By reducing the bioavailability of these mycotoxins, adsorbents mitigate their hepatotoxic ef-

**Figure 2.** Histopathological findings in the liver of piglets.

fects and prevent histological changes in the liver of piglets. Some mycotoxin adsorbents may neutralize ZEN and FBs through chemical reactions or complex formation, rendering them less toxic to hepatic cells. By neutralizing these toxins, adsorbents protect liver tissue from damage and preserve histological integrity (Ramesh et al., 2021). Certain mycotoxin adsorbents possess anti-inflammatory and antioxidant properties, which can help alleviate ZEN and FBs induced oxidative stress and inflammation in the liver (Sharma & Patial, 2021). By reducing tissue damage and inflammation, adsorbents maintain liver histology and function, preventing histological changes associated with mycotoxin toxicity.

Figure 3 shows histopathological findings of the ovaries in our research. Piglets fed with diets naturally contaminated with mycotoxins showed a reduced oocyte number (A). Further findings showed that supplementation of the dietary mycotoxins adsorbent in both concentrations mitigate overall clinical signs. The addition of mycotoxin adsorbent in concertation of 1 kg/ton of complete feed in group T2 led to a slightly reduced oocyte number (B), while the dietary addition of mycotoxin adsorbent Mycostop Duplo® in the concentration of 2.5 kg/ton of complete feed exhibited no ovarian changes (C).

ZEN exhibits estrogenic properties and can induce reproductive disorders in piglets (Fruhauf et al., 2019). Histopathological changes in reproductive organs, such as ovaries, are common manifestations of ZEN toxicity. Mycotoxin adsorbents are utilized to mitigate the adverse effects of ZEN contamination in pig diets (Čolović et al., 2019). Understanding their potential mechanisms in preventing histopathological changes and ovary count alterations in piglets exposed to ZEN is crucial for the effective management of mycotoxin-related reproductive disorders. ZEN exposure can lead to histopathological alterations in the reproductive organs of female piglets, particularly the ovaries (Chen et al., 2015). Common histopathological findings include follicular degeneration, cystic follicles, and interstitial cell hyperplasia. These changes disrupt ovarian function, leading to later reproductive dysfunction and reduced fertility in affected animals. ZEN exposure may also affect ovarian development and morphology, leading to alterations in ovary size and follicle counts. Increased follicular atresia and reduced ovarian follicle numbers are commonly observed in piglets exposed to ZEN, reflecting impaired ovarian maturation and function. Mycotox-

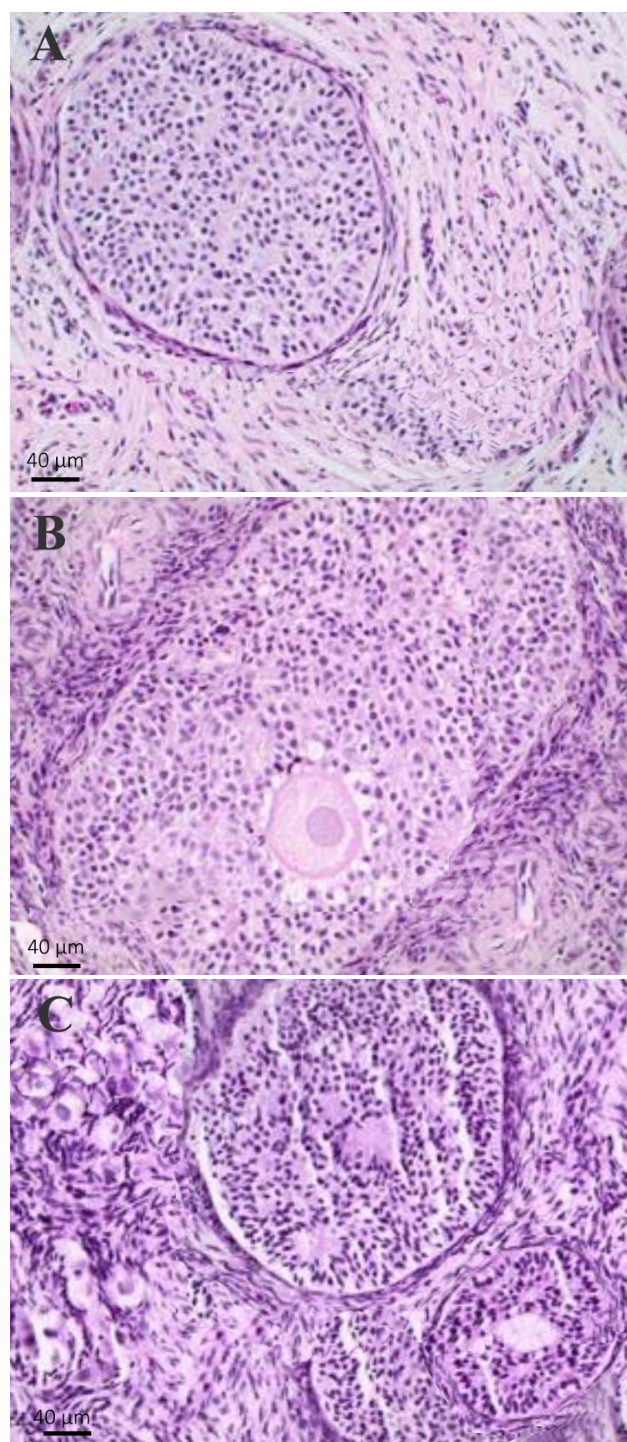


Figure 3. Histopathological findings in the ovaries in piglets.

in adsorbents function by binding to ZEN in the gastrointestinal tract prevent its absorption and systemic distribution (Awuchi et al., 2021). By reducing the bioavailability of ZEN, adsorbents mitigate its estrogenic effects on reproductive organs, including the ovaries. This prevents ZEN-induced histopathological changes and ovary counts alterations in piglets.

ZEN exerts its toxic effects by binding to estrogen receptors and mimicking the action of endogenous estrogen. Mycotoxin adsorbents may competitively inhibit ZEN binding to estrogen receptors, reducing its estrogenic activity and mitigating its adverse effects on ovarian morphology and function (Wang et al., 2019). Based on our results mycotoxin adsorbents possess antioxidant and anti-inflammatory properties, which help alleviate ZEN-induced oxidative stress and inflammation in the ovaries. By reducing tissue damage and inflammation, adsorbents preserve ovarian structure and function, preventing histopathological changes and ovary count alterations (Figure 3, C).

CONCLUSION

Mycotoxin adsorbents offer a promising strategy for preventing vulvovaginitis in piglets contaminated with ZEN. Through their adsorption mechanisms, these additives reduce the bioavailability of ZEN, thereby mitigating its estrogenic effects and prevent-

ing reproductive disorders.

In conclusion, the results of our research show that the dietary supplementation of mycotoxin adsorbent Mycostop Duplo® in the concentration of 2.5 kg/ton of complete feed effectively mitigated the toxic effects of ZEN and FBs on weaned piglets, as evidenced by reduced vulva sizes and ameliorated histological changes in the liver and ovaries. These findings underscore the importance of mycotoxin management strategies in swine nutrition to safeguard animal health and welfare.

ACKNOWLEDGEMENTS

This research was funded by the Ministry of Education, Science, and Technological Development of the Republic of Serbia.

CONFLICT OF INTEREST

The authors declare no conflict of interest.

REFERENCES

- Adegbeye, M. J., Reddy, P. R. K., Chilaka, C. A., Balogun, O. B., Elghandour, M. M. M. Y., Rivas-Caceres, R. R., & Salem, A. Z. M. (2020). Mycotoxin toxicity and residue in animal products: Prevalence, consumer exposure and reduction strategies - A review. *Toxicon*, 177, 96-108. <https://doi.org/10.1016/j.toxicon.2020.01.007>
- Akbar, A., Majeed, F. A., Sadiq, M. B., Khan, S. A., & Rabaan, A. A. (2022). Mycotoxins occurrence in food commodities, their associated hazards and control strategies. *Journal of the Hellenic Veterinary Medical Society*, 73(1), 3853-3866. <https://doi.org/10.12681/jhvms.26023>
- Awuchi, C. G., Ondari, E. N., Ogbonna, C. U., Upadhyay, A. K., Baran, K., Okpala, C. O. R., Korzeniowska, M., & Guiné, R. P. F. (2021). Mycotoxins Affecting Animals, Foods, Humans, and Plants: Types, Occurrence, Toxicities, Action Mechanisms, Prevention, and Detoxification Strategies—A Revisit. *Foods*, 10(6), Article 6. <https://doi.org/10.3390/foods10061279>
- Ben Ammar, R., Zahra, H. A., Abu Zahra, A. M., Alfwuaires, M., Abdulaziz Alamer, S., Metwally, A. M., Althnaian, T. A., & Al-Ramadan, S. Y. (2023). Protective Effect of Fucoxanthin on Zearalenone-Induced Hepatic Damage through Nrf2 Mediated by PI3K/AKT Signaling. *Marine Drugs*, 21(7), Article 7. <https://doi.org/10.3390/md21070391>
- Bulgaru, V. C., Perte, A. M., Grosu, I. A., Anghel, A. C., Pistol, G. C., Marin, D. E., Dinischiotu, A., & Taranu, I. (2023). Effects and Underlying Mechanisms of Zearalenone Mycotoxin at Concentrations Close to the EC Recommendation on the Colon of Piglets after Weaning. *Agriculture*, 13(7), Article 7. <https://doi.org/10.3390/agriculture13071372>
- Burel, C., Tanguy, M., Guerre, P., Boilletot, E., Cariolet, R., Queguiner, M., Postollec, G., Pinton, P., Salvat, G., Oswald, I. P., & Fravalo, P. (2013). Effect of Low Dose of Fumonisin on Pig Health: Immune Status, Intestinal Microbiota and Sensitivity to Salmonella. *Toxins*, 5(4), Article 4. <https://doi.org/10.3390/toxins5040841>
- Buszewska-Forajta, M. (2020). Mycotoxins, invisible danger of feed-stuff with toxic effect on animals. *Toxicon*, 182, 34-53. <https://doi.org/10.1016/j.toxicon.2020.04.101>
- Chen, J., Wei, Z., Wang, Y., Long, M., Wu, W., & Kuca, K. (2021). Fumonisin B1: Mechanisms of toxicity and biological detoxification progress in animals. *Food and Chemical Toxicology*, 149, 111977. <https://doi.org/10.1016/j.fct.2021.111977>
- Chen, Q., Lu, Z., Hou, W., Shi, B., & Shan, A. (2015). Effects of Modified Maifanite on Zearalenone Toxicity in Female Weaner Pigs. *Italian Journal of Animal Science*, 14(2), 3597. <https://doi.org/10.4081/ijas.2015.3597>
- Cimbalo, A., Alonso-Garrido, M., Font, G., & Manyes, L. (2020). Toxicity of mycotoxins *in vivo* on vertebrate organisms: A review. *Food and Chemical Toxicology*, 137, 111161. <https://doi.org/10.1016/j.fct.2020.111161>
- Čolović, R., Puvača, N., Cheli, F., Avantaggiato, G., Greco, D., Đuragić, O., Kos, J., & Pinotti, L. (2019). Decontamination of Mycotoxin-Contaminated Feedstuffs and Compound Feed. *Toxins*, 11(11), 617. <https://doi.org/10.3390/toxins11110617>
- Dänicke, S., Carlson, L., Heymann, A.-K., Grümpel-Schlüter, A., Doupovec, B., Schatzmayr, D., Streit, B., Kersten, S., & Kluess, J. (2023). Inactivation of zearalenone (ZEN) and deoxynivalenol (DON) in complete feed for weaned piglets: Efficacy of ZEN hydrolase ZenA and of sodium metabisulfite (SBS) as feed additives. *Mycotoxin Research*, 39(3), 201-218. <https://doi.org/10.1007/s12550-023-00486-2>
- Deng, Z., Jang, K. B., Jalukar, S., Du, X., & Kim, S. W. (2023). Efficacy of Feed Additive Containing Bentonite and Enzymatically Hydrolyzed Yeast on Intestinal Health and Growth of Newly Weaned Pigs under Chronic Dietary Challenges of Fumonisin and Aflatoxin. *Toxins*, 15(7), Article 7. <https://doi.org/10.3390/toxins15070433>
- D'Mello, J. P. F., Placinta, C. M., & Macdonald, A. M. C. (1999). *Fusarium* mycotoxins: A review of global implications for animal health, welfare and productivity. *Animal Feed Science and Technology*, 80(3), 183-205. [https://doi.org/10.1016/S0377-8401\(99\)00059-0](https://doi.org/10.1016/S0377-8401(99)00059-0)
- Elliott, C. T., Connolly, L., & Kolawole, O. (2020). Potential adverse effects on animal health and performance caused by the addition of mineral adsorbents to feeds to reduce mycotoxin exposure. *Mycotoxin Research*, 36(1), 115-126. <https://doi.org/10.1007/s12550-019-00375-7>
- Fruhauf, S., Novak, B., Nagl, V., Hackl, M., Hartinger, D., Rainer, V., Labudová, S., Adam, G., Aleschko, M., Moll, W.-D., Thamhesl, M., & Grenier, B. (2019). Biotransformation of the Mycotoxin Zearale-

- none to its Metabolites Hydrolyzed Zearalenone (HZEN) and Decarboxylated Hydrolyzed Zearalenone (DHZEN) Diminishes its Estrogenicity In Vitro and In Vivo. *Toxins*, 11(8), Article 8. <https://doi.org/10.3390/toxins11080481>
- Gajęcka, M., Zielonka, L., & Gajęcki, M. (2017). Activity of Zearalenone in the Porcine Intestinal Tract. *Molecules*, 22(1), Article 1. <https://doi.org/10.3390/molecules22010018>
- Gao, Y., Meng, L., Liu, H., Wang, J., & Zheng, N. (2020). The Compromised Intestinal Barrier Induced by Mycotoxins. *Toxins*, 12(10), Article 10. <https://doi.org/10.3390/toxins12100619>
- Gao, Z., Luo, K., Zhu, Q., Peng, J., Liu, C., Wang, X., Li, S., & Zhang, H. (2023). The natural occurrence, toxicity mechanisms and management strategies of Fumonisin B1; A review. *Environmental Pollution*, 320, 121065. <https://doi.org/10.1016/j.envpol.2023.121065>
- Hassan, A. A., Abu Hafs, S. H., Elghandour, M. M. M. Y., Kanth Reddy, P. R., Monroy, J. C., & Salem, A. Z. M. (2019). Dietary Supplementation with sodium bentonite and coumarin alleviates the toxicity of aflatoxin B1 in rabbits. *Toxicon*, 171, 35-42. <https://doi.org/10.1016/j.toxicon.2019.09.014>
- Hussain, D., Mateen, A., & Gatlin, D. M. (2017). Alleviation of aflatoxin B1 (AFB1) toxicity by calcium bentonite clay: Effects on growth performance, condition indices and bioaccumulation of AFB1 residues in Nile tilapia (*Oreochromis niloticus*). *Aquaculture*, 475, 8-15. <https://doi.org/10.1016/j.aquaculture.2017.04.003>
- Kinkade, C. W., Rivera-Núñez, Z., Gorczyca, L., Aleksunes, L. M., & Barrett, E. S. (2021). Impact of Fusarium-Derived Mycoestrogens on Female Reproduction: A Systematic Review. *Toxins*, 13(6), Article 6. <https://doi.org/10.3390/toxins13060373>
- Kócsó, D. J., Szabó-Fodor, J., Mézes, M., Balogh, K., Ferenczi, S., Szabó, A., Bóta, B., & Kovács, M. (2018). Fumonisin B1 exposure increases Hsp70 expression in the lung and kidney of rats without inducing significant oxidative stress. *Acta Veterinaria Hungarica*, 66(3), 394-407. <https://doi.org/10.1556/004.2018.036>
- Luo, Y., Liu, X., Yuan, L., & Li, J. (2020). Complicated interactions between bio-adsorbents and mycotoxins during mycotoxin adsorption: Current research and future prospects. *Trends in Food Science & Technology*, 96, 127-134. <https://doi.org/10.1016/j.tifs.2019.12.012>
- Mahato, D. K., Devi, S., Pandhi, S., Sharma, B., Maurya, K. K., Mishra, S., Dhawan, K., Selvakumar, R., Kamle, M., Mishra, A. K., & Kumar, P. (2021). Occurrence, Impact on Agriculture, Human Health, and Management Strategies of Zearalenone in Food and Feed: A Review. *Toxins*, 13(2), Article 2. <https://doi.org/10.3390/toxins13020092>
- Ndiaye, S., Zhang, M., Fall, M., Ayessou, N. M., Zhang, Q., & Li, P. (2022). Current Review of Mycotoxin Biodegradation and Bioadsorption: Microorganisms, Mechanisms, and Main Important Applications. *Toxins*, 14(11), Article 11. <https://doi.org/10.3390/toxins14110729>
- Ochieng, P. E., Croubels, S., Kemboi, D., Okoth, S., De Baere, S., Cavalier, E., Kang'ethe, E., Faas, J., Doupovec, B., Gathumbi, J., Douny, C., Scippo, M.-L., Lindahl, J. F., & Antonissen, G. (2023). Effects of Aflatoxins and Fumonisin, Alone or in Combination, on Performance, Health, and Safety of Food Products of Broiler Chickens, and Mitigation Efficacy of Bentonite and Fumonisin Esterase. *Journal of Agricultural and Food Chemistry*, 71(36), 13462-13473. <https://doi.org/10.1021/acs.jafc.3c01733>
- Oldenburg, E., Höppner, F., Ellner, F., & Weinert, J. (2017). Fusarium diseases of maize associated with mycotoxin contamination of agricultural products intended to be used for food and feed. *Mycotoxin Research*, 33(3), 167-182. <https://doi.org/10.1007/s12550-017-0277-y>
- Pack, E., Stewart, J., Rhoads, M., Knight, J., Clark, S., Schmale, D. G., & De Vita, R. (2020). Effects of short-term moderate ZEN consumption on uterosacral ligament elasticity in pubertal gilts. *Research in Veterinary Science*, 133, 202-209. <https://doi.org/10.1016/j.rvsc.2020.09.023>
- Perrone, G., Ferrara, M., Medina, A., Pascale, M., & Magan, N. (2020). Toxigenic Fungi and Mycotoxins in a Climate Change Scenario: Ecology, Genomics, Distribution, Prediction and Prevention of the Risk. *Microorganisms*, 8(10), Article 10. <https://doi.org/10.3390/microorganisms8101496>
- Pierron, A., Alassane-Kpembi, I., & Oswald, I. P. (2016). Impact of mycotoxin on immune response and consequences for pig health. *Animal Nutrition*, 2(2), 63-68. <https://doi.org/10.1016/j.aninu.2016.03.001>
- Puvača, N., Ljubojević Pelić, D., & Tufarelli, V. (2023). Mycotoxins Adsorbents Mycostop Premium® and Mycostop Duplo® on Piglets Productive Performance and Blood Serum Enzyme Activities. *Journal of Agronomy, Technology and Engineering Management (JATEM)*, 6(5), 944-952. <https://doi.org/10.55817/GYIC7602>
- Puvača, N., Ljubojević Pelić, D., Tufarelli, V., Nikolova, N., Bursić, V., Vapa, I., & Vuković, G. (2023). Dietary Effects of Mycotoxins Adsorbents Mycostop Premium® and Mycostop Duplo® on Piglets Productive Performance and Blood Serum Enzyme Activities. *Journal of Agronomy, Technology and Engineering Management*, 6(6), 988-997. <https://doi.org/10.55817/KCTC8701>
- Ramesh, M., Sujitha, M., Anila, P. A., Ren, Z., & Poopal, R. K. (2021). Responses of *Cirrhinus mrigala* to second-generation fluoroquinolone (ciprofloxacin) toxicity: Assessment of antioxidants, tissue morphology, and inorganic ions. *Environmental Toxicology*, 36(5), 887-902. <https://doi.org/10.1002/tox.23091>
- Rao, Z.-X., Tokach, M. D., Woodworth, J. C., DeRouchey, J. M., Goodband, R. D., Calderón, H. I., & Dritz, S. S. (2020). Effects of Fumonisin-Contaminated Corn on Growth Performance of 9 to 28 kg Nursery Pigs. *Toxins*, 12(9), Article 9. <https://doi.org/10.3390/toxins12090604>
- Rasheed, U., Ain, Q. U., Yaseen, M., Fan, X., Yao, X., Tong, Z., & Liu, B. (2020). Modification of bentonite with orange peels extract and its application as mycotoxins' binder in buffered solutions and simulated gastrointestinal fluids. *Journal of Cleaner Production*, 267, 122105. <https://doi.org/10.1016/j.jclepro.2020.122105>
- Ropejko, K., & Twarużek, M. (2021). Zearalenone and Its Metabolites—General Overview, Occurrence, and Toxicity. *Toxins*, 13(1), Article 1. <https://doi.org/10.3390/toxins13010035>
- Sharma, V., & Patial, V. (2021). Food Mycotoxins: Dietary Interventions Implicated in the Prevention of Mycotoxicosis. *ACS Food Science & Technology*, 1(10), 1717-1739. <https://doi.org/10.1021/acsfoodscitech.1c00220>
- Soriano, J. M., González, L., & Catalá, A. I. (2005). Mechanism of action of sphingolipids and their metabolites in the toxicity of fumonisin B1. *Progress in Lipid Research*, 44(6), 345-356. <https://doi.org/10.1016/j.plipres.2005.09.001>
- Terciolo, C., Bracarense, A. P., Souto, P. C. M. C., Cossalter, A.-M., Dopavogui, L., Loiseau, N., Oliveira, C. A. F., Pinton, P., & Oswald, I. P. (2019). Fumonisin at Doses below EU Regulatory Limits Induce Histological Alterations in Piglets. *Toxins*, 11(9), Article 9. <https://doi.org/10.3390/toxins11090548>
- Wang, N., Wu, W., Pan, J., & Long, M. (2019). Detoxification Strategies for Zearalenone Using Microorganisms: A Review. *Microorganisms*, 7(7), Article 7. <https://doi.org/10.3390/microorganisms7070208>
- Xu, R., Kiarie, E. G., Yiannikouris, A., Sun, L., & Karrow, N. A. (2022). Nutritional impact of mycotoxins in food animal production and strategies for mitigation. *Journal of Animal Science and Biotechnology*, 13(1), 69. <https://doi.org/10.1186/s40104-022-00714-2>
- Zheng, L., Duarte, M. E., Sevarolli Loftus, A., & Kim, S. W. (2021). Intestinal Health of Pigs Upon Weaning: Challenges and Nutritional Intervention. *Frontiers in Veterinary Science*, 8. <https://doi.org/10.3389/fvets.2021.628258>