

Journal of the Hellenic Veterinary Medical Society

Vol 67, No 3 (2016)



Peritoneopericardial diaphragmatic hernia in the dog and cat

X. NIKIPHOROU, R. CHIOTI, M. N. PATSIKAS, L. G. PAPAZOGLU

doi: [10.12681/jhvms.15638](https://doi.org/10.12681/jhvms.15638)

Copyright © 2018, X NIKIPHOROU, R CHIOTI, MN PATSIKAS, LG PAPAZOGLU



This work is licensed under a [Creative Commons Attribution-NonCommercial 4.0](https://creativecommons.org/licenses/by-nc/4.0/).

To cite this article:

NIKIPHOROU, X., CHIOTI, R., PATSIKAS, M. N., & PAPAZOGLU, L. G. (2018). Peritoneopericardial diaphragmatic hernia in the dog and cat. *Journal of the Hellenic Veterinary Medical Society*, 67(3), 189–194. <https://doi.org/10.12681/jhvms.15638>

■ Peritoneopericardial diaphragmatic hernia in the dog and cat

Nikiphorou X., Chioti R., Patsikas M.N., Papazoglou L.G.

*Clinic of Companion Animals, Department of Clinical Studies, School of Veterinary Medicine,
Aristotle University of Thessaloniki, 11 Voutyra street, 54627 Thessaloniki*

■ Περιτονεοπερικαρδιοδιαφραγματοκήλη στο σκύλο και τη γάτα

Νικηφόρου Ξ., Χιώτη Ρ., Πατσίκας Μ.Ν., Παπάζογλου Λ.Γ.

*Κλινική των Ζώων Συντροφιάς, Τομέας Κλινικών, Τμήμα Κτηνιατρικής,
Αριστοτέλειο Πανεπιστήμιο Θεσσαλονίκης, Βουτυρά 11, 54627 Θεσσαλονίκη*

ABSTRACT. Peritoneopericardial diaphragmatic hernia (PPDH) is a congenital communication between the pericardial sac and the abdominal cavity allowing displacement of abdominal organs to the pericardial sac. Peritoneopericardial diaphragmatic hernia is thought to occur due to a failure of the development of septum transversum. Vomiting, exercise intolerance and respiratory distress are the most common clinical signs. Diagnosis of PPDH is based on plain radiography. Physical examination and diagnostic imaging may detect the presence of other congenital anomalies. Surgical repair of the PPDH is the treatment of choice for animals with clinical signs. Prognosis following surgical repair of PPDH is favorable. Animals with no clinical signs related to PPDH may not undergo surgical repair.

Keywords: *Cat, dog, peritoneopericardial diaphragmatic hernia*

ΠΕΡΙΛΗΨΗ. Η περιτονεοπερικαρδιοδιαφραγματοκήλη (ΠΠΔΚ) είναι μια συγγενής διαμαρτία που φέρει σε επικοινωνία τον περικαρδιακό σάκο με την κοιλιακή κοιλότητα με αποτέλεσμα την μετακίνηση ενδοκοιλιακών οργάνων μέσα στο σάκο. Η ΠΠΔΚ οφείλεται σε αποτυχία ανάπτυξης της εγκάρσιας μοίρας του διαφράγματος. Η συμπτωματολογία της περιλαμβάνει συχνότερα έμετο, εύκολη κόπωση και αναπνευστική δυσχέρεια και η διάγνωση γίνεται με απλή ακτινογραφία. Η κλινική εξέταση και ο απεικονιστικός έλεγχος μπορεί να καταδείξουν τη συνύπαρξη και άλλων συγγενών διαμαρτιών. Σε ζώα με συμπτώματα η χειρουργική θεραπεία είναι η θεραπεία εκλογής για την ΠΠΔΚ. Η πρόγνωση μετά την επέμβαση είναι καλή. Τα ασυμπτωματικά ζώα μπορεί να επιβιώσουν χωρίς να υποστούν χειρουργική αποκατάσταση της κήλης.

Λέξεις ευρητηριασμού: *Γάτα, σκύλος, περιτονεοπερικαρδιοδιαφραγματοκήλη*

Corresponding author: Papazoglou L.G.,
Clinic of Companion Animals, Department of Clinical Studies,
School of Veterinary Medicine, Aristotle University of Thessaloniki,
11 Voutyra street, 54627 Thessaloniki, Greece,
e-mail: makdvm@vet.auth.gr

Αλληλογραφία: Παπάζογλου Λ.Γ.
Κλινική των Ζώων Συντροφιάς, Τομέας Κλινικών, Τμήμα Κτηνιατρικής,
Αριστοτέλειο Πανεπιστήμιο Θεσσαλονίκης, Βουτυρά 11, 54627 Θεσσαλονίκη,
e-mail: makdvm@vet.auth.gr

Date of initial submission: 29.05.2015
Date of acceptance: 19.06.2015

INTRODUCTION

Peritoneopericardial diaphragmatic hernia (PPDH) is a congenital communication between the pericardial sac and the abdominal cavity allowing displacement of abdominal organs to the pericardial sac (McClaran, 2013). Peritoneopericardial diaphragmatic hernia is the most common congenital anomaly affecting the pericardium and the diaphragm in small animals (Detweiler et al., 1960, Clinton, 1967, Evans and Biery, 1980, Wallace et al., 1992, Reimer et al., 2004, Banz and Gottfried, 2010, Burns et al., 2013). Organs more commonly found within the pericardial sac include the liver, small intestine, gallbladder, omentum, spleen, colon, pancreas and falciform ligament (Evans and Biery, 1980, Wallace et al., 1992, Neiger, 1996, Reimer et al., 2004, Banz and Gottfried, 2010, Burns et al., 2013).

EMBRYOLOGICAL DEVELOPMENT

Peritoneopericardial diaphragmatic hernia is thought to occur due to failure of the development of septum transversum, the structure that constructs the ventral diaphragm (Fig. 1). Failure of closure of the septum transversum or failure of fusion of the septum transversum and pleuroperitoneal folds are the proposed mechanisms for PPDH development. Possible causes of failure include genetic defects, prenatal injury and teratogenic agents (Clinton, 1967, Evans and Biery, 1980, Reimer et al., 2004).

DEMOGRAPHIC DATA

Peritoneopericardial diaphragmatic hernia is an uncommon anomaly in dogs and cats accounting for 0.025% of the small animal population in two veterinary teaching hospitals (Burns et al., 2013), that occurs more commonly in cats than in dogs (Reed, 1951, Evans and Biery, 1980, Willard and Aronson, 1981, Wallace et al., 1992, Reimer et al., 2004, Banz and Gottfried, 2010, Burns et al., 2013). Breeds that are overrepresented include Weimeraners, domestic longhair and Persian cats (Evans and Biery, 1980, Cowan and Feeney 1989, Lunney, 1992, Reimer et al., 2004, Rexing and Coolman, 2004, Chalkey et al., 2006, Banz and Gottfried, 2010, Burns et al., 2013). Median age at diagnosis is 14.4 months for dogs and 30 months for cats (Wallace et al., 1992, Reimer et al., 2004, Banz and Gottfried, 2010, Burns et al., 2013). No sex predilection is reported.

CLINICAL SIGNS AND PHYSICAL EXAMINATION FINDINGS

The presence of clinical signs may depend on the degree of herniation (Burns et al., 2013). In large diaphragmatic defects abdominal organ displacement into the pericardial sac may result in adhesion formation of the organs to the pericardium, organ entrapment or strangulation leading to gastrointestinal, respiratory or cardiac disorders (Burns et al., 2013, McClaran 2013). Small defects which do not allow organ protrusion may be asymptomatic (Burns et al., 2013). The most common clinical signs are anorexia, vomiting, exercise intolerance, dyspnoea or tachypnoea (Burns et al., 2013); other signs include lethargy, weight loss, diarrhoea, coughing, or collapse (Evans and Biery, 1980, Wallace et al., 1992, Neiger, 1996, Reimer et al., 2004, Banz and Gottfried, 2010, Burns et al., 2013). On physical examination the most common findings are muffled heart sounds, heart murmurs or decreased lung sounds (Burns et al., 2013); other findings include thoracic borborygmi or an empty abdomen on palpation (Evans and Biery, 1980, Wallace et al., 1992, Neiger, 1996, Reimer et al., 2004, Banz and Gottfried, 2010, Burns et al., 2013). However, many animals are asymptomatic (Evans and Biery, 1980, Wallace et al., 1992, Neiger, 1996, Reimer et al., 2004, Banz and Gottfried, 2010, Burns et al., 2013). Concurrent conditions seen in cats include cardiomyopathy, renal failure, respiratory tract infection, pericardial cyst and effusion, polycystic kidney disease, hyperthyroidism, urinary tract obstruction, chylothorax, seizures, diabetes mellitus, linear foreign bodies, intussusception, inflammatory bowel disease, gastroenteritis (Banz and Gottfried, 2010, Reimer et al., 2004). Pregnancy and cholelithiasis were reported in two dogs with PPDH (Rosenstein et al., 2001, Statz et al., 2007). The most common haematological finding detected in dogs and cats was elevated serum alanine aminotransferase activity and the most common finding seen in cats was increased serum calcium concentration (Banz and Gottfried, 2010, Burns et al., 2013). Other nonspecific laboratory abnormalities observed in dogs were elevated serum alkaline phosphatase activity, neutrophilia, elevated total bilirubin, increased packed cell volume and decreased platelet count (Banz and Gottfried, 2010). Nonspecific laboratory abnormalities detected in cats include anaemia, mild hyperglycaemia, mildly increased creatinine kinase, mildly increased alkaline phosphatase and aspartate aminotransferase,

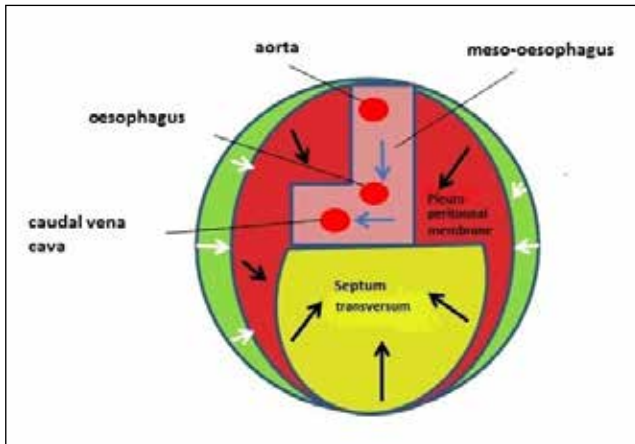


Figure 1. Diaphragm develops embryonically from four structures: the septum transversum, the pleuroperitoneal membrane, the mesoesophagus and portions of the body wall.

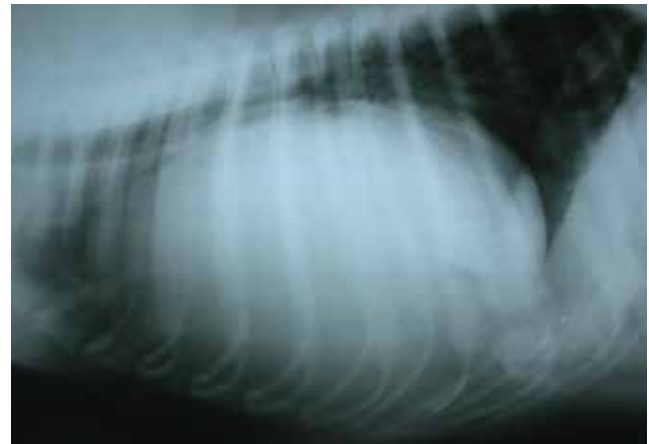


Figure 2. Lateral thoracic radiograph of a dog with PPDH. An enlarged cardiac silhouette is visible.

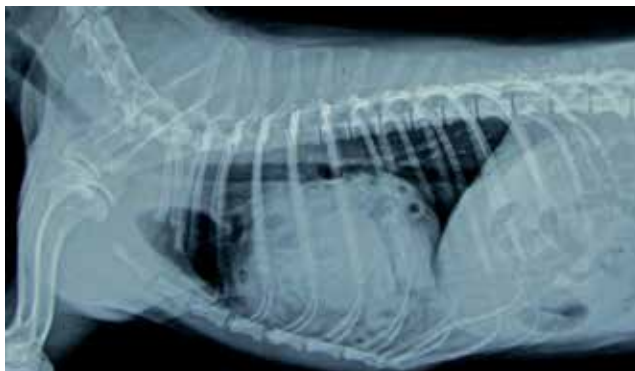

Figure 3. Lateral radiograph of a Shih-Tzu with PPDH. Gas-filled small intestine is visible inside the pericardial sac (Papazoglou L.G., Patsikas M.N., Deligianni A., Wisner E.R., Kazakos G. (2015) Pneumopericardium associated with peritoneopericardial diaphragmatic hernia repair in a dog. *Vet Med* 110: 94-98).

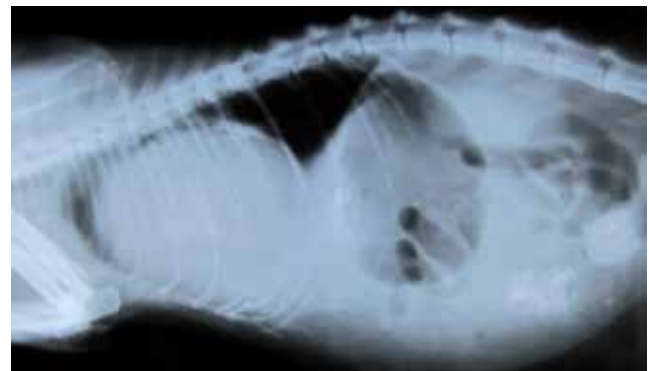


Figure 4. Lateral radiograph of a domestic long hair cat with PPDH and abdominal effusion. The enlarged cardiac silhouette is visualized.

elevated creatinine and bilirubin, eosinophilia, neutrophilia, hyperkalaemia and hypocholesterolaemia (Banz and Gottfried, 2010). The diagnosis of PPDH was an incidental finding in 50% of the cats and 46% of the dogs of a recent study during diagnostic imaging performed for unrelated reasons (Burns et al., 2013).

DIAGNOSTIC IMAGING

Diagnosis of PPDH is usually based on plain radiography. Thoracic radiography may detect an enlarged cardiac silhouette or cardiomegaly, presence of abdominal organs within the pericardial sac or loss of distinction between the heart and the diaphragm (Evans and Biery, 1980, Wallace et al., 1992, Neiger, 1996, Reimer et al., 2004, Banz and Gottfried, 2010, Burns et al., 2013) [Figs. 2, 3, 4]. Barium studies to aid in identifica-

tion of intestinal loops within the pericardial sac may also be performed. Ultrasonographic examination, echocardiography and computed tomography may be performed to aid in diagnosis and to rule out any other congenital anomalies (Lamb et al., 1989, Hay et al., 1989, Wallace et al., 1992, Neiger, 1996, Reimer et al., 2004, Banz and Gottfried, 2010, Burns et al., 2013).

OTHER CONGENITAL ANOMALIES

Physical examination and diagnostic imaging may detect the presence of other congenital anomalies affecting mostly the abdominal wall, skeleton, heart and vessels (Eyster et al., 1977, Evans and Biery, 1980, Bellah et al., 1989, Wallace et al., 1992, Lunney, 1992, Neiger, 1996, Reimer et al., 2004, Banz and Gottfried, 2010, Burns et al., 2013). A list of other congenital anomalies identified in dogs and cats with PPDH are presented in Table 1.

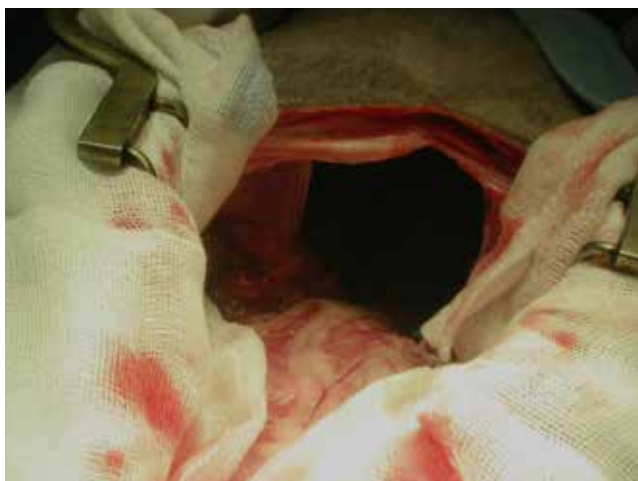

Figure 5. Intraoperative view of the diaphragmatic rent of the dog of figure 2. Omentum is seen lying in the pericardium.

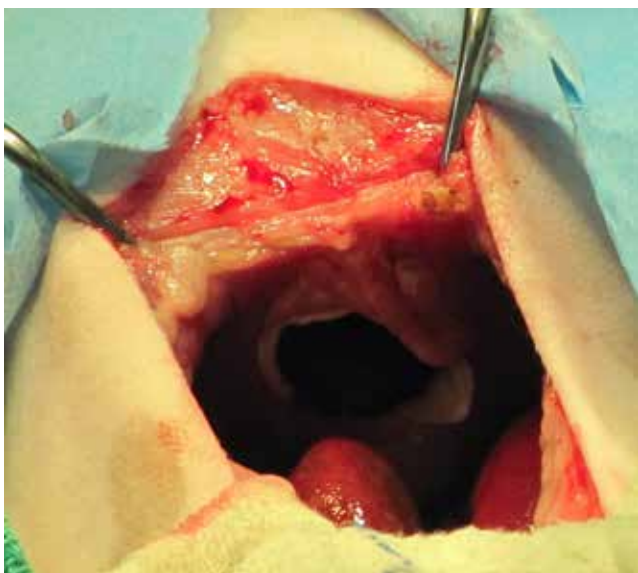


Figure 6. The diaphragmatic rent of the dog of figure 3 as visualized through a midline celiotomy.

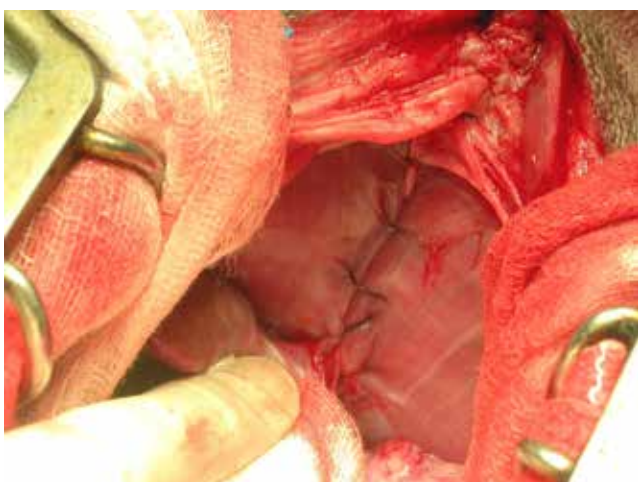


Figure 7. The PPDH of the dog of figure 1 was repaired with placement of a simple continuous polydioxanone suture.

SURGICAL TREATMENT

Surgical repair of the PPDH is the treatment of choice for animals with clinical signs. Surgery is performed under general gas anaesthesia and intermittent positive pressure ventilation. Premedication and anaesthetic induction can be performed using routine protocols. The hernia is approached through a ventral midline celiotomy (Figs. 5, 6). In most of the cases entrance to the pleural cavity is not required. Debridement of the hernia margins will lead to entrance to the pleural cavity. The defect can be closed by apposition of the diaphragmatic margins in one or two layer closure using a simple interrupted or continuous pattern with polydioxanone, polypropylene or nylon suture material, from a dorsal to ventral direction (Bellah et al., 1989, Wallace et al., 1992, Banz and Gottfried, 2010, Burns et al., 2013) [Fig. 7]. A caudal median sternotomy is required to improve surgical access and when adhesions are present between the liver or intestines and the pericardium (Burns et al., 2013). Adhesions of the herniated organs to the pericardium may necessitate partial pericardiectomy (Banz and Gottfried, 2010). Reconstruction of the diaphragm with pericardial flaps or grafts can also be done in cases of large defects or in agenesis of the diaphragm (Burns et al., 2013, McClaran 2013). A thoracostomy tube is placed if the pleural cavity is entered; thoracostomy tube is removed shortly after recovery from anaesthesia or within 12 hours after surgery (Banz and Gottfried, 2010). Median time for tube removal is 22.5 hours (Burns et al., 2013). Management of pneumopericardium is usually not required unless cardiopulmonary function is affected associated with large volumes of air accumulation within the pericardial sac (Papazoglou et al., 2015).

INTRAOPERATIVE COMPLICATIONS

Intraoperative complications are observed mostly in cats including haemorrhage associated with adhesions of the liver to the pericardium or myocardium, hypotension, respiratory acidosis, hypoventilation, hypoxia, loss of palpable pulses and multifocal ventricular premature contractions (Reimer et al., 2004, Banz and Gottfried, 2010, Burns et al., 2013). Blood transfusion is performed for the

management of haemorrhage. Hypotension is treated using intravenous fluids and inotropic drugs. Oxygen is delivered for the management of respiratory complications.

POSTOPERATIVE COMPLICATIONS

Postoperative care is usually performed in the critical care unit; animals are under continuous cardiorespiratory monitoring and receive opioids for pain management and oxygen via a face mask

or intranasal catheter in case of poor oxygenation. Postoperative complications are detected in both cats and dogs. Major complications in cats include hyperthermia, tachypnoea, dyspnoea, hypoventilation, persistent acidaemia, hypoxia, refractory pneumothorax, pleural effusion, pulmonary oedema, respiratory arrest, chylothorax, incisional dehiscence, hernia recurrence and partial blindness (Wallace et al., 1992, Reimer et al., 2004, Banz and Gottfried, 2010, Burns et al., 2013). Dogs suffer fewer postop-

Table 1. Congenital anomalies that are identified in dogs and cats with PPDH (Eyster et al., 1977, Evans and Biery, 1980, Bellah et al., 1989, Wallace et al., 1992, Reimer et al., 2004, Banz and Gottfried, 2010, Burns et al., 2013).

Dogs	Cats
Abdominal wall	
Ventral abdominal hernia	Ventral abdominal hernia
Umbilical hernia	Umbilical hernia
Sternum	
Pectus excavatum	Pectus excavatum
Incomplete xyphoid	Sternabrae fusion
Sternal defects	Sternal defects
Ribs	
Costochondral deformities	
Genital system	
Cryptorchidism	Cryptorchidism
Head and Neck	
Cleft palate	Prognathism
	Stenotic nares
Eyes	
Persistent pupillary membranes	Eyelid atresia and microphthalmia
Cardiovascular	
Pulmonic stenosis	Pulmonic stenosis
Subaortic stenosis	Mitral stenosis
Ventricular septal defects	Atrial septal defect
Persistent left cranial vena cava	Double chambered right ventricle with pulmonic stenosis
Portoazygous shunt	Pseudotruncus arteriosus

erative complications including incisional dehiscence, regurgitation, pericardial steatitis or pneumothorax (Wallace et al., 1992, Banz and Gottfried, 2010, Burns et al., 2013). Hyperthermia usually resolves within 12 hours of detection (Banz and Gottfried, 2010). Oxygen delivery is often required to combat respiratory complications. Short-term postoperative mortality ranged from 3-14% for cats (Reimer et al., 2004, Banz and Gottfried, 2010, Burns et al., 2013) and from 5-12.5% for dogs (Banz and Gottfried, 2010, Burns et al., 2013).

PROGNOSIS

Prognosis following surgical repair of PPDH is usually good with 81-87.5% of the dogs and 86-97% of

the cats survive (Evans and Biery, 1980, Reimer et al., 2004, Banz and Gottfried, 2010, Burns et al., 2013).

MANAGEMENT OF ASYMPTOMATIC HERNIAS

Animals with no clinical signs or with fewer clinical signs related to PPDH may not undergo surgical repair (Reimer et al., 2004, Burns et al., 2013). Monitoring by the owners for respiratory or gastrointestinal signs has been reported in these cases. The median age of these animals was significantly greater than the median age of animals that had surgical reconstruction of PPDH (Burns et al., 2013). Interestingly, long-term survival was not different between animals undergoing surgical repair and those without (Burns et al., 2013).

REFERENCES

- Banz AC, Gottfried SD (2010) Peritoneopericardial diaphragmatic hernia: a retrospective study of 31 cats and eight dogs. *J Am Anim Hosp Assoc* 46: 398-404.
- Burns CG, Bergh MS, McLoughlin MA (2013) Surgical and nonsurgical treatment of peritoneopericardial diaphragmatic hernia in dogs and cats :58 cases (1999-2008). *J Am Vet Med Assoc* 242: 643-650.
- Chalkey J, Salionardy BJ, Bulmer BJ (2006) What is your diagnosis? *J Am Vet Med Assoc* 228: 695-696.
- Clinton JM (1967) A case of congenital pericardio-peritoneal communication in a dog *Vet Radiol* 8: 57-60.
- Cowan WD, Walter PA (1989) What is your diagnosis? *J Am Vet Med Assoc* 194: 1331-1332.
- Detweiler DK, Brodey RS, Flickinger GL (1960) Diaphragmatic hernia *J Am Vet Med Assoc* 137: 177- 182.
- Evans SM, Biery DN (1980) Congenital diaphragmatic peritoneopericardial hernia in the dog and cat: a literature review and 17 additional case histories. *Vet Radiol* 21:108-116.
- Eyster GE, Evans AT, Blanchard GL, Krahnwinkel DJ, Chaffe A, DeYoung D, Karr DR, O'Handley P (1977) Congenital pericardial diaphragmatic hernia and multiple cardiac defects in a letter of Collies *J Am Vet Med Assoc* 170: 516-520.
- Hay WH, Woodfield JA, Moon MA (1989) Clinical, echocardiographic, and radiographic findings of peritoneopericardial diaphragmatic hernia in two dogs and va cat *J Am Vet Med Assoc* 195: 1245-1248.
- Lamb CR, Mason GD, Wallace MK (1989) Ultrasonographic diagnosis of peritoneopericardial diaphragmatic hernia in a Persian cat *Vet Rec* 125: 186.
- Lunney J (1992) Congenital peritoneal pericardial diaphragmatic hernia and portocaval shunt in a cat *J Am Anim Hosp Assoc* 28: 163-165.
- McClaran LK (2013) Diaphragmatic and peritoneopericardial diaphragmatic hernias. In: (ed: Monnet E) *Small Animal Soft Tissue Surgery*. Wiley- Blackwell, Ames, pp 278-285.
- Neiger R (1996) Peritoneopericardial diaphragmatic hernia in cats. *Compend Contin Educ Pract Vet* 18: 461-479.
- Papazoglou LG, Patsikas MN, Deligianni A, Wisner ER, Kazakos G (2015) Pneumopericardium associated with peritoneopericardial diaphragmatic hernia repair in a dog. *Vet Med* 110: 94-98.
- Reed C (1951) Pericardio-peritoneal herniae in mammals, with description of a case in the domestic cat *Anat Rec* 110: 113-119.
- Reimer SB, Kyles AE, Fillipowitz DE, Gregory CR (2004) Long term outcome of cats treated conservatively or surgically for peritoneopericardial diaphragmatic hernia; 66 cases (1987- 2002). *J Am Vet Med Assoc* 224: 728- 732.
- Rexing JF, Coolman BR (2004) Clinical exposures: a peritoneopericardial diaphragmatic hernia in a cat 99: 314-319.
- Rosenstein DS, Reif U, Stickle RL, Watson G, Schall W, Amsellem P (2001) Radiographic diagnosis: pericardioperitoneal diaphragmatic hernia and cholelithiasis in a dog *Vet Radiol Ultrasound* 42: 308-310.
- Statz GD, Moore KE, Murtaugh RJ (2007) Surgical repair of peritoneopericardial diaphragmatic hernia in a pregnant dog *J Vet Emerg Crit Care* 17: 77-85.
- Wallace J, Mullen H S, Lesser MB (1992) A Technique for surgical correction of peritoneal pericardial diaphragmatic hernia in dogs and cats. *J Am Anim Hosp Assoc* 28: 503-510.
- Willard MD, Aronson E (1981) Peritoneopericardial diaphragmatic hernia in a cat *J Am Vet Med Assoc* 178: 481-483.