


Journal of the Hellenic Veterinary Medical Society

Vol 68, No 4 (2017)



Contribution to the parasites and associated pathology of wild Serranidae from the Aegean Sea

V. BAKOPOULOS, A. NIKOLAIDIS, M. KOLYGAS, F. ATHANASSOPOULOU

doi: [10.12681/jhvms.16058](https://doi.org/10.12681/jhvms.16058)

Copyright © 2018, V BAKOPOULOS, A NIKOLAIDIS, M KOLYGAS, F ATHANASSOPOULOU



This work is licensed under a [Creative Commons Attribution-NonCommercial 4.0](https://creativecommons.org/licenses/by-nc/4.0/).

To cite this article:

BAKOPOULOS, V., NIKOLAIDIS, A., KOLYGAS, M., & ATHANASSOPOULOU, F. (2018). Contribution to the parasites and associated pathology of wild Serranidae from the Aegean Sea. *Journal of the Hellenic Veterinary Medical Society*, 68(4), 599–606. <https://doi.org/10.12681/jhvms.16058>

**Contribution to the parasites and associated pathology
of wild Serranidae from the Aegean Sea**

Bakopoulos V.^{1*}, Nikolaidis A.¹, Kolygas M.², Athanassopoulou F.²

¹ *Laboratory of Ichthyology, Aquaculture and Fish Diseases, Department of Marine Sciences,
School of The Environment, University of The Aegean, University Hill, Mytilene 81100, Lesvos, Greece.*

² *Laboratory of Ichthyology and Fish diseases, Department of Veterinary Medicine,
University of Thessaly, Trikalon 224, Karditsa 43100, Greece.*

ABSTRACT. Parasites and associated pathology of wild caught Serranidae in the Aegean Sea were investigated in order to contribute to the scientific information regarding pathological findings of these fish. Various lesions and parasitic organisms, such as Digenean parasites, cysts and metacercaria, Cestode cysts and a nematode, were observed in the gills / pseudobranchs, liver, the wall of the digestive tract, the mesentery and the ovaries. None of these lesions were considered to be of pathogenic bacteria nature based on microscopic observation of stained tissue sections of affected organs. The most frequently observed parasitism among all the species studied was from Digenean parasites (11 out of 16 specimens examined) compared to infection by both cestodes and nematodes (3 out of 16 specimens examined). Heavier infestation was observed for the unidentified Digenean cysts that were found in the mesentery of one specimen (120 counts), followed by Didymozoon parasites (average 19.25 counts per specimen).

Keywords: Serranidae, Digenean, Cestodes, Nematodes, parasites

Corresponding Author:

Vasileios Bakopoulos, Laboratory of Ichthyology, Aquaculture and Fish Diseases,
Department of Marine Sciences, School of The Environment,
University of The Aegean, University Hill, Mytilene 81100, Lesvos, Greece.
Email address: v.bakopoulos@marine.aegean.gr

Date of initial submission: 18-10-2016
Date of revised submission: 12-1-2017
Date of acceptance: 23-1-2017

ΠΕΡΙΛΗΨΗ. Στη παρούσα μελέτη παρουσιάζονται παρασιτώσεις και οι παθολογικές καταστάσεις που προκαλούν, σε άγρια Σερανιδοειδή που συλλέχθηκαν από διάφορες περιοχές του Αιγαίου Πελάγους. Παρατηρήθηκαν διάφορες βλάβες και παρασιτικοί οργανισμοί, όπως Διγενή παράσιτα, κύστει και μετακερκάρια, κύστει Κεστώδων και ένα νηματώδες παράσιτο, στα βράγχια / ψευδοβράγχια, στο ήπαρ, στα τοιχώματα του πεπτικού σωλήνα, στο μεσεντέριο και στις ωοθήκες. Καμία από αυτές τις βλάβες δεν αποδόθηκε σε παθογόνα βακτήρια. Ο συχνότερα παρατηρούμενος παρασιτισμός μεταξύ όλων των ειδών που ελέγχθηκαν ήταν από Διγενή παράσιτα (11 από τα 16 δείγματα που εξετάστηκαν) σε σύγκριση με τις μολύνσεις από Κεστώδη και Νηματώδη παράσιτα (3 από τα 16 δείγματα που εξετάστηκαν). Η πιο έντονη παρασίτωση παρατηρήθηκε από κύστει ενός αταυτοποίητου Διγενούς παρασίτου που βρέθηκαν στο μεσεντέριο ενός από τα ψάρια που ελέγχθηκαν (120 παράσιτα), ακολουθούμενη από τη παρασίτωση με τα Διδυμόζωα παράσιτα (κατά μέσο όρο 19,25 παράσιτα ανά άτομο).

Λέξεις κλειδιά: Σερανιδοειδή, Διγενή, Κεστώδη, Νηματώδη, παράσιτα

INTRODUCTION

Species of Serranidae are mostly bottom/reef fish that are caught at relatively large depths and are consequently of older age. They are carnivorous, supreme predators and this makes them prone to parasitism from various parasitic organisms present in their preys and vulnerable to the long-term effects of different pollutants. Due to the characteristics of Serranid biological cycle, their overfishing, especially by amateur or game fishing without regulatory enforcement makes them a vulnerable species group (Sadovy de Mitcheson et al., 2013).

Wild populations of Serranidae are affected by various fish pathogens and parasites. Groupers are reportedly infected by aquatic *Mycobacterium* spp. (Eissa et al., 2011; Bowser, 2002; Gauthier and Rhodes, 2009) and mycobacteriosis is considered as one important emerging disease of this species group. Wild Serranidae are also susceptible to a very important viral disease, viral nervous necrosis (VNN) caused by *Betanodavirus* (Vendramin et al., 2013; Kara et al., 2014). Regarding parasitic infections, Serranidae have been hosts of nematodes of the Family Philometridae (Baylis and Daubney, 1926) which exhibits large females (Moravec et al., 2003) causing serious damage to the ovaries affecting reproduction (Moravec and Justine, 2005; Moravec and Manoharan, 2014). The former authors have described the presence of large *Philometra lateolabracis* females in the gonads of *Epinephelus marginatus* and *Seriola dumerilii* in the Mediterranean.

Field observations by amateur fishermen revealed the presence of dark brown-black deposits on the surface of the liver of many wild-caught Serranid species. Based on the few information regarding pathological findings of wild Serranidae, the aim of this study was to investigate and attribute these pathologies and their association to parasites in wild caught *Epinephelus marginatus*, *E. costae* and *Mycteroperca rubra*.

MATERIALS AND METHODS

Samples collection, measurements and preservation

Collection of specimens was performed by free diving spear-fishing in depths of 5 to 35m from April to September 2015. Samples were collected from two locations of the Aegean Sea: Saronikos Gulf (Hydra and Spetses Islands) and Lesbos Island. Fish were euthanized by severing the spinal cord and immediately placed on ice on arrival to the shore. In less than 2h, fish were weighed, their total length measured, and a full necropsy and parasitological examination performed according to the methods described by Kolygas (2015). When macroscopic lesions or parasites were observed, part of the affected organ was placed in 10% phosphate buffered formalin for histopathological observation.

Macroscopic and microscopic observation of samples

Dissected samples were observed under a stereomicroscope (Zeiss, Germany, Axioscop). Appropriate parts were then processed for histology and paraf-

fin-embedded. Serial 5µm thick sections were then cut and stained with hematoxylin-eosin (Drury and Wallington, 1980) or with periodic acid Schiff or with Ziehl-Neelsen as described by Roberts (1989) and Bakopoulos et al. (1997). Samples were then observed under a microscope (Olympus CH20) and photographed (Tucsen-Truechrome-HD).

RESULTS

In total 16 fish were collected and their individual characteristics are presented in Table 1. The smaller specimen had 1.94kg weight and the larger 16kg and total length ranged from 53 to 100cm.

Various lesions and parasites in the gills / pseudo-branches, liver, the wall of the digestive tract, the mesentery and the ovaries were observed. None of these lesions were attributed to pathogenic bacteria according to microscopic observation of stained tissue sections. These findings are summarized in table 2, further below.

In 4 of the fish examined (No 13, 14, 15, 16 / *E. marginatus* / Hydra and Lesvos), orange/yellow large cyst-like structures were found in the gills (Fig 1a) and pseudobranchia. These structures were attached by a pointed stem (Fig 1e), consisted from parasites and characterized by internal space which is typically

Table 1. Individual length, weight, location and species sampled

Specimen No / Fish Species	Total Length (cm) (M±SD)	Weight (kg) (M±SD)	Location
(1), (5), (14) <i>Epinephelus marginatus</i>	81.3±19.6	10.3±5.9	Lesvos
(2), (6), (7), (8), <i>Epinephelus costae</i> ; (3), (4), (9), <i>Mycteroperca rubra</i> ; (10), (11), (13), (15), <i>Epinephelus marginatus</i>	69.7±15.7	6±4.9	Hydra
(12), (16), <i>Epinephelus marginatus</i>	81.5±6.4	7.5±0.8	Spetses

Table 2. Summarized findings of each parasitism

Finding / Specimen No-Species / Location	Tissue / organ	Mean / total number of parasites	Number of infected hosts Fish Species	Number of non-infected hosts Fish Species / Serranidae
Digenean cysts unidentified No 10 - <i>E. marginatus</i> / Hydra	Liver, mesentery	(-) / 120	1	8 / 15
Cestode cysts No 3 - <i>M. rubra</i> & 10 - <i>E. marginatus</i> / Hydra	Stomach and pyloric caeca wall, pancreas, mesentery	11 / 22	1 & 1	2 & 8 / 14
Digenean, parasites, forms, metacercaria unidentified No 2, 8, 7 - <i>E. costae</i> / Hydra, No 3, 9 - <i>M. rubra</i> / Hydra, No 5, 10 - <i>E. marginatus</i> / Lesvos, Hydra	Liver, stomach, pyloric caeca, pancreatic tissue	≥35/ specimen	3 / 2 / 2	1 & 1 & 7 / 9
Digenean (<i>Didymozoidae</i> sp) No 13, 14, 15, 16 / <i>E. marginatus</i> / Hydra, Lesvos	Gills, pseudobranchia	19.25 / 77	4	5 / 12
<i>Philometra</i> sp. No 5 / <i>E. marginatus</i> / Lesvos	Ovaries	(-) / 1	1	8 / 15

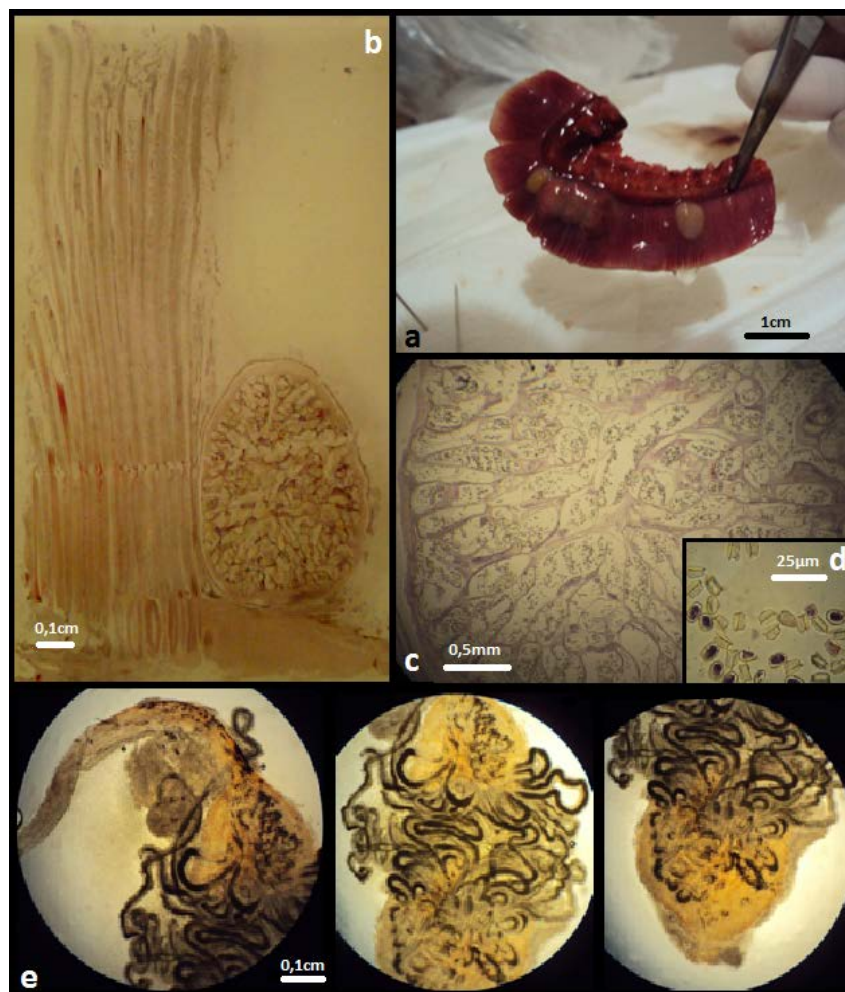
divided to tube-like areas full of sac-looking eggs (Figure 1b & c). Eggs measured 1.5 μm (length) by 0.5 μm (width). One side had a molding extending in length to 1.8 μm . Due to these morphological features and the typical morphology of the scaphoid type eggs, the parasites were identified as belonging to Didymozoidae (Monticelli, 1888) (Williams and Bunkley-Williams, 1999) (Figures 1c & d).

Lesions in the liver and the wall of the digestive tract were observed in 7 specimens (No 2, 8, 7 - *E. costae* / Hydra, No 3, 9 - *M. rubra* / Hydra, No 5, 10 - *E. marginatus* / Lesvos, Hydra) in the form of white to off-white scaly tissue and brown-black spots/areas (Figure 2a). Lesions had various sizes and shapes and scar tissue had replaced significant part of the liver parenchyma (Figure 2a). In some of these lesions

there was evidence of parasites (Figure 2b). In addition, ≥ 35 parasitic eggs / specimen were observed in liver samples and in the pancreatic tissue and the walls of the stomach and pyloric caeca of these specimens. Tissue reactions were weak and in the form of a few layers of connective tissue surrounding the egg. Parasite eggs were also observed in the gut lumen of these specimens (Fig 2d). Histologically, a number of small encapsulated granulomata containing digenean eggs were observed. These were near vessels and had no significant host reaction. All these parasites were identified as Digenea by the presence of frontal and ventral suckers (Noga, 2010) (Figure 2d).

In the ovaries of another specimen (No 5 / *E. marginatus* / Lesvos), a nematode parasite of approximately 30cm long was observed. The body of this

Figure 1. a) gill with parasites. Parasites are in close proximity with cartilage. b) longitudinal gill section containing the digenean parasite, scale bar 0.1cm, H&E stain. c) main body of the parasite, scale bar 0.5mm, H&E stain. Multiple ducts and tubules containing (d) ovarian products. e) wet mounts of anterior, median & posterior part of the parasite.



parasite was entangled inside the ovarian tissue (Figure 2e). Histology revealed intense inflammation due to the nematode's presence (Figure 2g). The histological sections revealed bothrids of the parasite's head (Figure 2f). This nematode was identified as *Philometra* sp. based on the morphological description of Merella et al. (2005) and Moravec et al. (2003).

Further histological findings included the presence of parasitic cysts in two specimens (No 3– *M. rubra* & 10 – *E. marginatus* / Hydra) observed in the serosal layer of the stomach with minimal tissue reaction. These were attributed to cestode parasites as two of the four bothria of the scolex heads (Yamaguti, 1959) were seen. In the intestinal musculature and at the base of the villi, encapsulated cysts were observed. These were demarcated by connective tissue containing either amorphous material or structures similar to cestode parasites with melanisation present in most specimens. These measured approximately 150 µm and all these morphological observations suggest infection of a cestode parasite. Cestode parasites were also observed in the mesentery with the characteristic 4 bothrids of the head (fig 2c). Nematode parasites containing larvae were observed in the pancreatic tissue (Figure 2h).

In the mesentery over a hundred parasitic cysts were observed in one specimen (No 10 – *E. marginatus* / Hydra) (Figure 3a). These cysts were loosely arranged between the pyloric caeca and abdominal fat tissue and were covered by a membrane. Histological examination suggested that these cysts belonged to a yet unidentified Digenean parasite (Figure 3b).

The findings of this study are summarized in Table 2.

The most frequent parasitism was from Digenean parasites (12 specimens out of the 16 examined) compared to the other parasites observed, both cestodes (2 specimens) and nematodes (1 specimen).

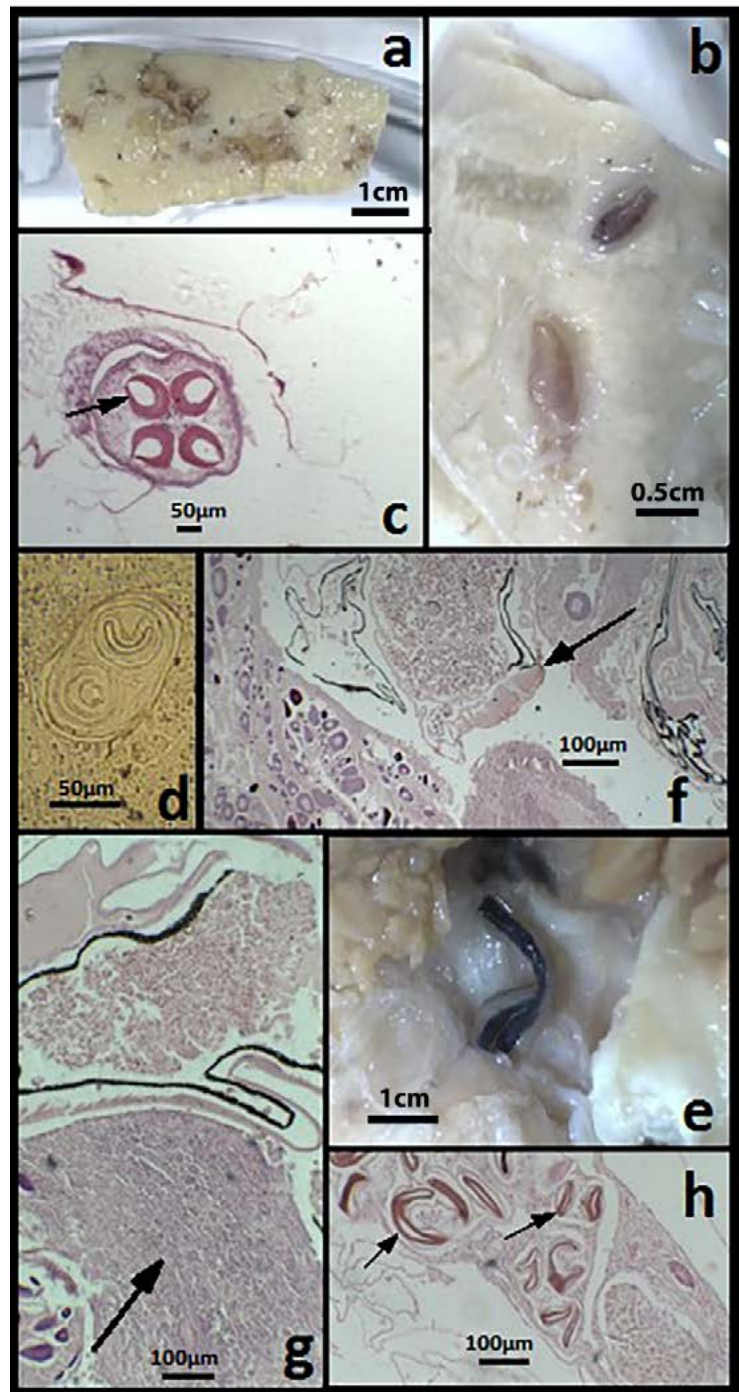
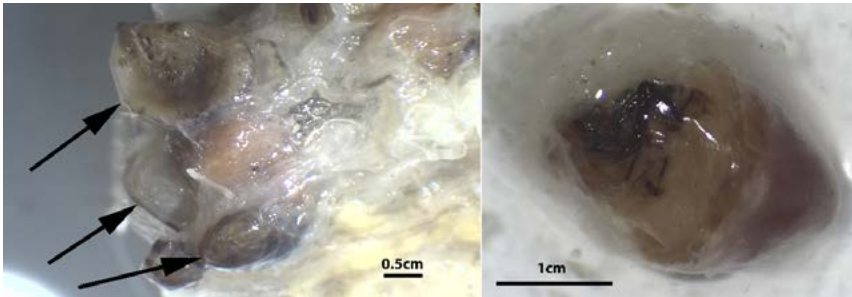


Figure 2. a) Section through liver parenchyma with lesions caused by Digenean parasites; fresh specimen, b) Section through liver parenchyma with Digenean parasitic forms; fresh specimen, c) Bothrids of the head of a cestode parasite in the fat tissue around pyloric caeca; H&E, d) digenean metacercaria in the gut lumen; frontal and posterior suckers; wet mount, e) Body of *Philometra* sp. in the ovaries, Fresh specimen, f) mouthpart of the *Philometra* sp. nematode; H&E, g) inflammatory response of ovaries to the *Philometra* sp. parasite; H&E, h) nematode larvae inside parasite H&E.

Figure 3. a) Digenean parasitic cysts between the pyloric caeca and abdominal fat surrounded by membrane; b) Detail of one Digenean parasitic cyst. Both fresh specimens.



Infections by Digenean parasites were heavier followed by the Didymozoan parasites infections.

DISCUSSION

An interesting observation in this study was the ubiquitous severe parasitism of digenea in liver parenchyma and diffused pancreatic tissue in 7 specimens. In some cases the abundance of Digenea in liver was so excessive that it was impossible to be counted. At the same time the enteric lumens of the above specimens had similar abundance of Digenea parasites. Though in grow out mariculture Digenea infections are rare and are not included in the main pathological problems (Athanasopoulou et al., 2009), they have to be taken into account in the case of *Serranidae* spp. with potential for aquaculture.

Except of the above mentioned digenea, encapsulated digenean cysts aka “Tissue flukes” were prominent in *tunica serrosa* of many internal organs of one fish specimen and in gills and pseudobranchia of four others. The latter tissue flukes belonged to the family Didymozoidae and these parasites are not often mentioned in clinical parasitology books, despite their persistent prevalence in large size commercial fish and especially in *Serranidae* (Williams and Bunkley-Williams, 1996). The life cycles of the family species are not known but some authors (Nikolaeva, 1965; Pearson, 1972) suggest that they have similar adaptation ethics of most digenea, that is, two intermediate hosts are needed to complete a life cycle. The food habits of groupers *E. marginatus* seem to play a key role in the route of infection of Didymozoidae. Squids and several other cephalopods are known to

be infected with Didymozoidae larvae (Overstreet and Hochsberg, 1969), and these animals serve as a common prey for *E. marginatus* (Lopez and Orvay, 2005). The impact of these parasites on fisheries is worth noticing, for in most cases of heavy infections the flesh has significantly reduced organoleptic and preservation characteristics (Williams and Bunkley-Williams, 1996).

As far as the nematode parasites are concerned, in this study the only *Philometra* sp. that was found was a female parasitizing the ovaries (Fig 2). According to WORMS (Word Register of Marine Species) there are more than 20 different recognized *Philometra* spp. and more than 40 species currently characterized as *Nomen Dubium* of whom acceptance is pending. It is worth noticing that nearly half of these 40 species were described in the last decade (Moravec and Manoharan, 2013; Moravec et al., 2016a; Moravec et al., 2016b) because of their impact in reproduction of some teleost fish (Selvakumar et al., 2015). Species of the genus *Philometra* require two hosts to complete their life cycle. The first intermediate hosts are copepods and final hosts are fish. These hosts can be a prey for *Serranidae* predators including Crustaceans (Barreiros and Santos, 1998; Begossi and Silvano, 2008; Lopez and Orvay, 2005) and thus a possible infection reservoir.

Occurrence of Cestode cysts in the present study was low. The encapsulated cestodes were scolices with various morphological features mainly located in the *tunica serosa* of stomach. These findings are common in large *Serranidae* fish (Genc et al., 2005) and in most cases the existence of more than one cestode (scolices) species is common and of minor pathologic importance (Kolygas, 2015).

CONCLUSIONS

The most frequent parasitism of large wild specimens of representative *Serranid* species was from Digenean parasites (12 specimens out of the 16 examined) compared to the other parasites observed, both cestodes (2 specimens) and nematodes (1 specimen).

Four specimens were infected by parasites of the Didymozoidae family. Seven specimens were infected with various Digenean parasites. One of these specimens was also infected by a Digenean parasite which produced numerous cysts loosely arranged between the pyloric caeca and abdominal fat tissue and were covered by a membrane. Digenean parasites caused lesions in the liver and the wall of the digestive tract in the form of scary tissue replacing significant part of liver parenchyma. In contrast, Digenean eggs in liver, the pancreatic tissue and the walls of the stomach and pyloric caeca provoked weak tissue reactions in the form of a few layers of connective tissue surrounding the egg or granulomata. Reactions against Cestode infections were also minimal. One specimen was found infected in the

ovaries by a *Philometra* sp. nematode that caused an intense inflammatory response. The destruction of liver parenchyma by Digenean parasites may affect the function in the liver and *Philometra* sp. infections may impair fecundity. Intensity of infections by Digenean parasites was higher followed by the Didymozoan parasites infections. The field observations of dark brown-black deposits on the surface of the liver that prompted this study are attributed to infections by Digenean parasites.

ACKNOWLEDGEMENTS

This study has been funded by institutional funds from the Department of Marine Sciences, University of The Aegean, for undergraduate studies. ■

REFERENCES

- Athanassopoulou F, Bitchava K, Pappas I (2009) An Overview of the treatments for parasitic disease in Mediterranean aquaculture. In: The use of veterinary drugs and vaccines in Mediterranean aquaculture. Options Mediterranees CIHEAM 86A:65-83.
- Bakopoulos V, Peric Z, Rodger H, Adams A, Richards RH (1997) First report of fish Pasteurellosis from Malta. J Aquat Anim Health 9:26-33.
- Barreiros JP, Santos RS (1998) Notes on the food habits and predatory behaviour of the dusky grouper, *Epinephelus marginatus* (Lowe, 1834) (Pisces: Serranidae) in the Azores Arquipélago. Life Mar Sci 16A:29-35.
- Baylis HA, Daubney R (1926) A synopsis of the families and genera of Nematoda. British Museum (Natural History), 277pp.
- Begossi A, Silvano RAM (2008) Ecology and ethnoecology of dusky grouper, *Epinephelus marginatus* (Lowe, 1834) along the coast of Brazil. J Ethnobiol Ethnomed 4:4-20.
- Bowser PR (2002) Fish diseases: mycobacteriosis of fish. NRAC Publication 202:1-3.
- Drury RAB, Wallington EA (1980) Carleton's histological techniques. 5th Edition. Oxford University Press, Oxford, U.K.
- Eissa AE, Zaki MM, Saeid S (2011) Epidemic mortalities in the dusky grouper, *Epinephelus marginatus* (Lowe, 1834) in Egyptian coastal waters. In Proceedings of the 4th Global Fisheries and Aquaculture Research Conference, the Egyptian International Center for Agriculture, Giza, Egypt: pp 3-5.
- Gauthier DT, Rhodes MW (2009) Mycobacteriosis in fishes: a review. The Vet J 180(1):33-47.
- Genc E, Genc MA, Genc E, Cengizler I, Can MF (2005) Seasonal variation and pathology associated with helminthes infecting two serranids (Teleostei) of Iskenderun Bay (Northeast Mediterranean Sea), Turkey. Turk J Fish and Aquat Sci 5(1):29-33.
- Kara HM, Chaoui L, Derbal F, Zaidi R, Boissésou C, Baud M, Bigarré L (2014) Betanodavirus - associated mortalities of adult wild groupers *Epinephelus marginatus* (Lowe) and *Epinephelus costae* (Steindachner) in Algeria. J Fish Dis 37(3):273-278.
- Kolygas MN (2015) Implementation of innovatory and efficacious treatments against ectoparasites of intensive cultured Mediterranean fish. A PhD Thesis. University of Thessaly, Laboratory of Aquatic Animal Health, Ichthyology and Aquaculture.
- López VG, Orvay FC (2005) Food habits of groupers *Epinephelus marginatus* (Lowe, 1834) and *Epinephelus costae* (Steindachner, 1878) in the Mediterranean Coast of Spain. Hidrobiológica 15(1):27-34.

- Merella P, Reñones O, Garippa G (2005) Reinstatement of *Philometra jordanoi* (López-Neyra, 1951)(Nematoda: Philometridae): a parasite of the Mediterranean dusky grouper *Epinephelus marginatus* (Lowe)(Osteichthyes, Serranidae). *Syst Par* 61(3):203-206.
- Monticelli FS (1888) Saggio di una morfologia dei Trematodi. Napoli, 100pp.
- Moravec F, Glamuzina B, Marino G, Merella P, Di Cave D (2003) Occurrence of *Philometra lateolabracis* (Nematoda: Philometridae) in the gonads of marine perciform fishes in the Mediterranean region. *Dis Aquat Organ* 53(3):267-269.
- Moravec F, Justine JL (2005) Two species of *Philometra* (Nematoda, Philometridae) from serranid fishes off New Caledonia. *Acta Parasitol* 50(4):323-331.
- Moravec F, Manoharan J (2013) Gonad-infecting philometrids (Nematoda: Philometridae) including four new species from marine fishes off the eastern coast of India. *Folia Parasitol* 60(2):105-122.
- Moravec F, Manoharan J (2014) Gonad-infecting species of *Philometra* (Nematoda: Philometridae) from groupers *Epinephelus* spp. (Osteichthyes: Serranidae) in the Bay of Bengal, India. *Acta Parasitol* 59(4):596-605.
- Moravec F, Chaabane A, Neifar L, Gey D, Justine JL (2016a) Descriptions of *Philometra aenei* n. sp. and *P. tunisiensis* n. sp. (Nematoda: Philometridae) from *Epinephelus* spp. off Tunisia confirm a high degree of host specificity of gonad-infecting species of *Philometra* Costa, 1845 in groupers (Serranidae). *Syst Parasitol* 93(2):115-128.
- Moravec F, Ali AH, Abed JM, Shaker SJ (2016b) New records of philometrids (Nematoda: Philometridae) from marine fishes off Iraq, with the erection of two new species and the first description of the male of *Philometroides eleutheronemae* Moravec & Manoharan, 2013. *Syst Parasitol* 93(2):129-144.
- Nikolaeva VM (1965) The life cycle of trematodes of the family Didymozoidae (Monticelli, 1888) Poche, 1907. *Zoologicheskii Zhurnal* 44(9):1317-1327.
- Noga EJ (2010) Fish Disease: Diagnosis and Treatment. 2nd Edition, Wiley-Blackwell publ.
- Pearson JC (1972) A phylogeny of life-cycle patterns of the Digenea. *Adv Parasitol* 10:153-189.
- Overstreet RM, Hochsberg F (1969) Digenetic trematodes of marine teleost fishes from Biscayne Bay, Florida. *Stud Zoo Bot* 15:119-176.
- Roberts RJ (1989) Fish Pathology 2nd Edition, Bailliere Tindall, UK, pp. 467.
- Sadovy de Mitcheson Y, Craig MT, Bertoncini AA, Carpenter KE, Cheung WW, Choat JH, Sanciangco J (2013) Fishing groupers towards extinction: a global assessment of threats and extinction risks in a billion dollar fishery. *Fish Fisheries*, 14(2):119-136.
- Selvakumar P, Sakthivel A, Goplakrishnan A (2015) Occurrence of a nematode *Philometra* (Costa, 1845) in the ovaries of *Epinephelus malabaricus* (Bloch & Schneider, 1801) in southeast coast of India. *J Coast Life Med* 3(4):290-294.
- Vendramin N, Patarnello P, Toffan A, Panzarin V, Cappellozza E, Tedesco P, Cattoli G (2013) Viral Encephalopathy and Retinopathy in groupers (*Epinephelus* spp.) in southern Italy: a threat for wild endangered species? *BMC Vet Res* 9(1):2-7.
- Williams EH Jr, Bunkley-Williams L (1999) Multicellular parasite (macroparasite) problems in aquaculture. In: *The Encyclopedia of Aquaculture*. John Wiley & Sons, Inc.
- Yamaguti S (1959) *Systema Helminthum: The cestode of vertebrates*. Interscience, New York.